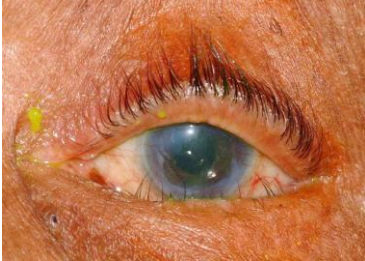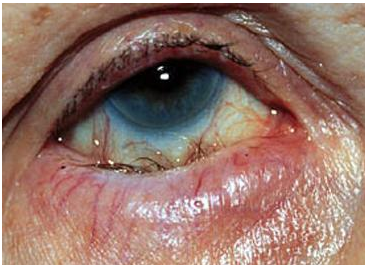




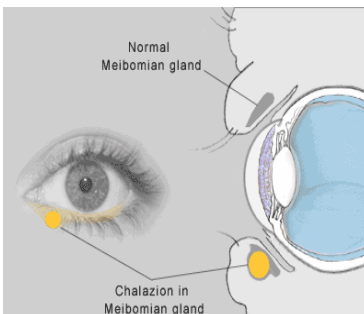
Coloboma : Congenital defect of the iris, ciliary body, choroid or even optic nerve> it will be exactly infranasal.



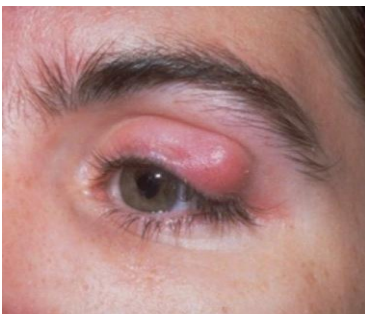Ectropion: Contraction of the anterior lamella causing outward deviation of the lid margin



Entropion: contraction of the posterior lamella causing inward deviation of the margin



Chalazion: chronic granulomatous inflammation of meibomian gland .

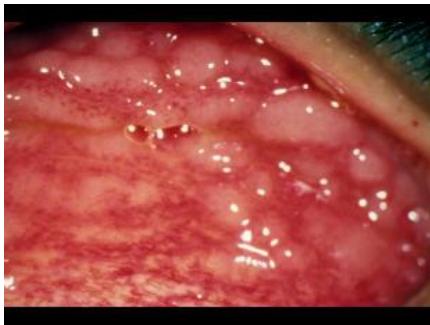


Ptosis (drooping of the eyelid)

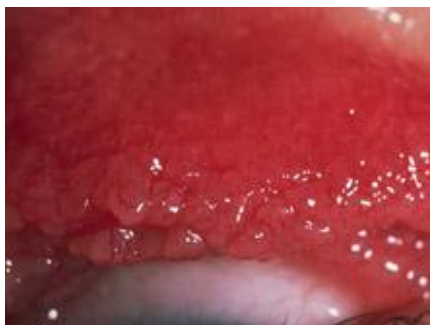


ADAM

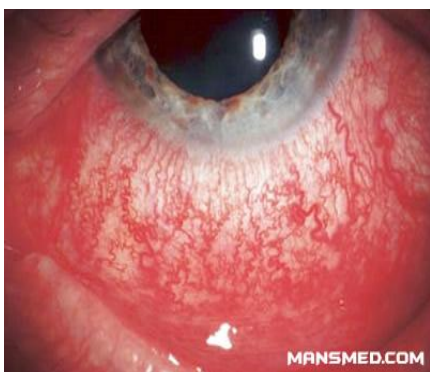Ptosis: dropping of the upper eyelid due to decreased tone of the muscle and power to elevate the eyelid.



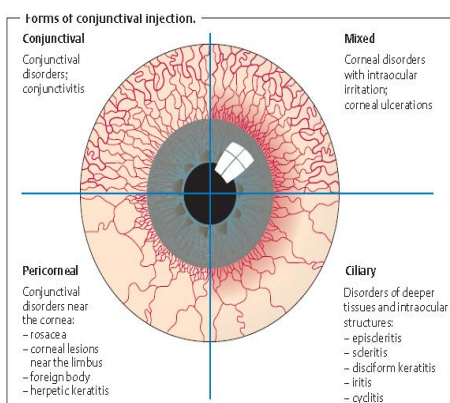
Follicles: aggregation of lymphocyte forms dome shaped gray area surrounded by blood vessels (no central vessel).

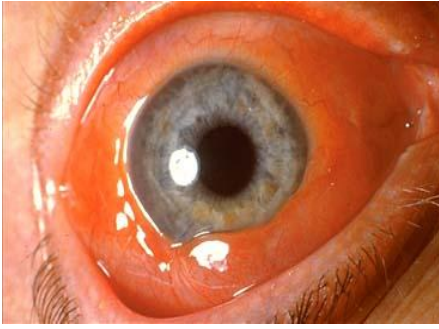

Papillae: proliferation of the epithelium with central blood vessel, mostly due to ocular disease, FB, contact lens.

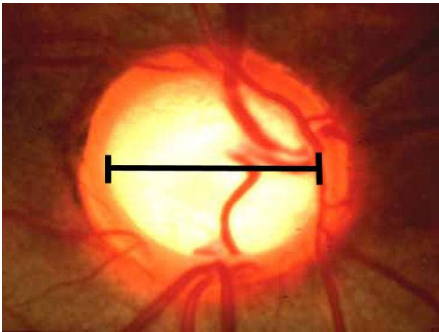


Conjunctival injection

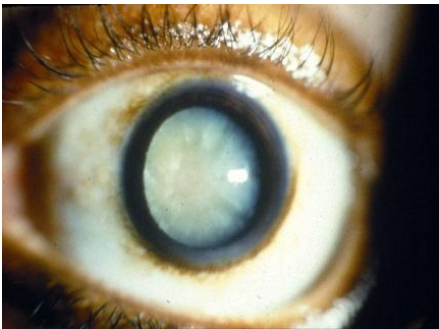




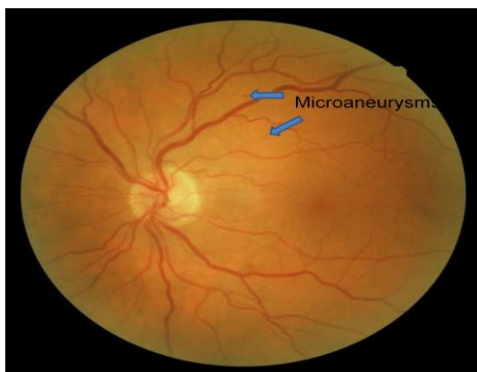
Chemosis



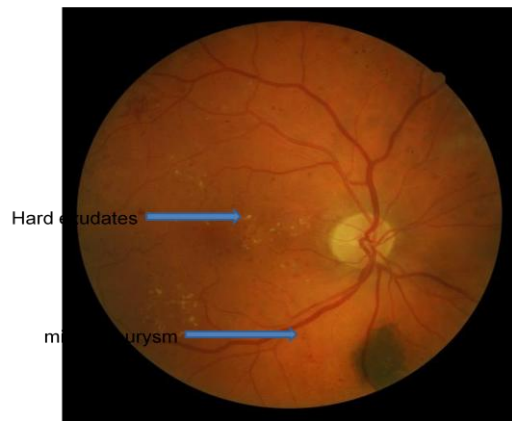
Cupping: sign of glaucoma



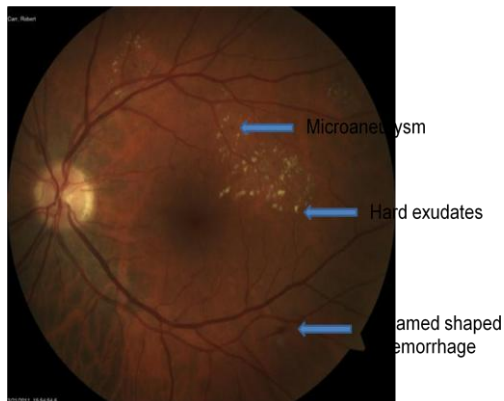
Cataract



Age-related macular degeneration



Age-related macular degeneration



Age-related macular degeneration