

Introduction to Dermatology

Dr. Sami N. Alsuwaidan

ASSOCIATE PROFESSOR AND CONSULTANT
IN DERMATOLOGY AND LASER SURGERY
DEPARTMENT OF DERMATOLOGY
KING SAUD UNIVERSITY
RIYADH, SAUDIA ARABIA

Learning objectives

- To Understand the basic structure of the skin
- To acquire the basic knowledge of the skin functions
- Be able to describe skin lesions and presentations properly
- Be familiar with the standard diagnostic tools in dermatology

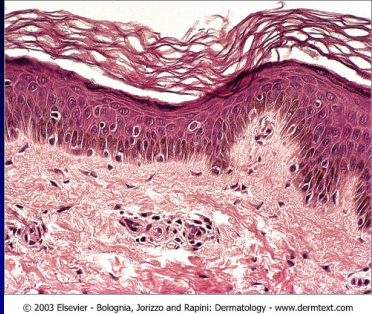
Dermatology

Skin, hair, nails, and mucous
membranes (mouth and genitalia).

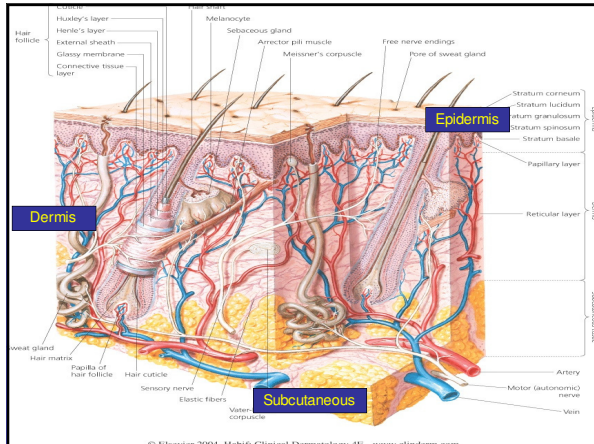
Important functions of the skin

- Protection against external injury
- Fluid balance
- Temperature buffering
- Synthesis of Vit. D
- Immune system
- Cosmetic function

Why Dermatology?



© 2003 Elsevier - Bologna, Jorizzo and Rapini: Dermatology - www.derrtext.com

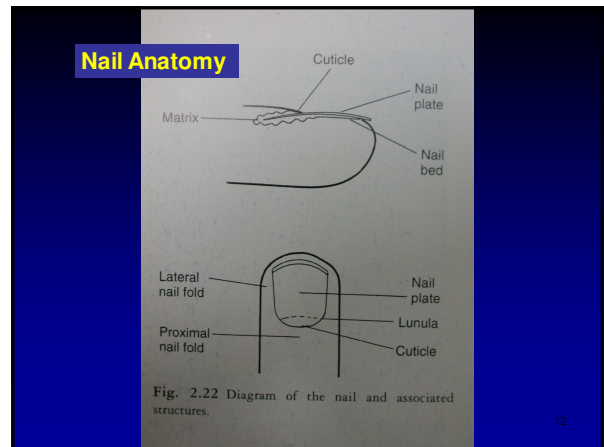
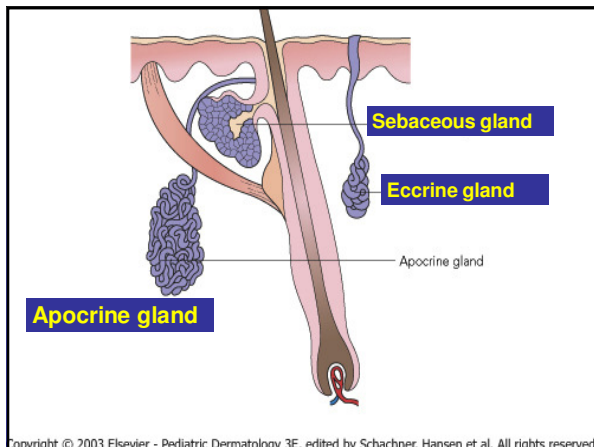
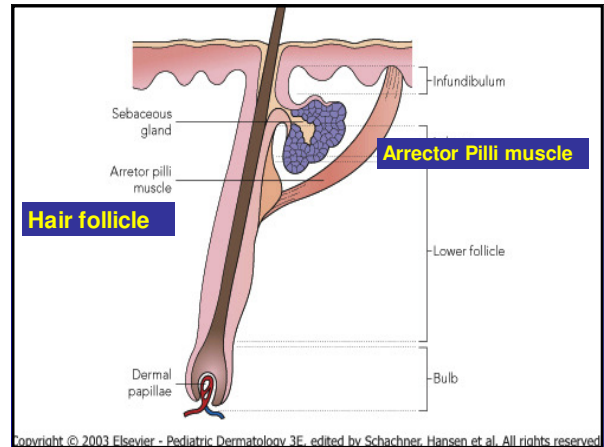


Skin Anatomy

- 1 Epidermis
- 2 Basement membrane (dermoepidermal junction)
- 3 Dermis
- 4 Subcutaneous fat

- ❖ **Epidermis: Four layers (from outside – inside)**
 1. Cornified layer
 2. Granular layer
 3. Spinous layer
 4. Basal layer
- ❖ **Dermis contains:**
 1. Collagen fibers
 2. Elastic fibers
 3. Ground substances
 4. Blood vessels
 5. Nerves.

- **Hair follicle**
- **Sebaceous gland**
- **Arrector pili muscle**
- **Ecrrine sweat gland**
- **Apocrine sweat glands**



Examination

1. Morphology
2. Configuration
3. Distribution

13

Primary Lesions

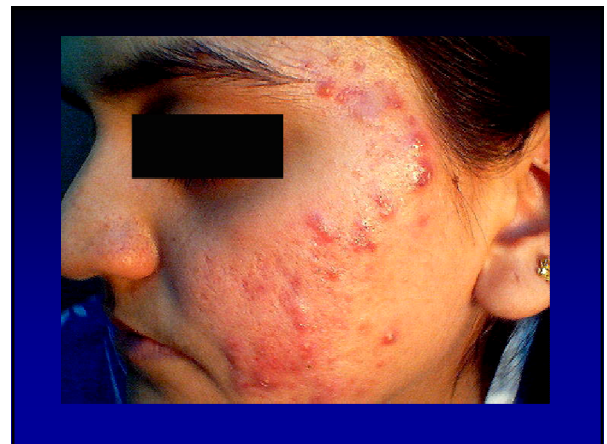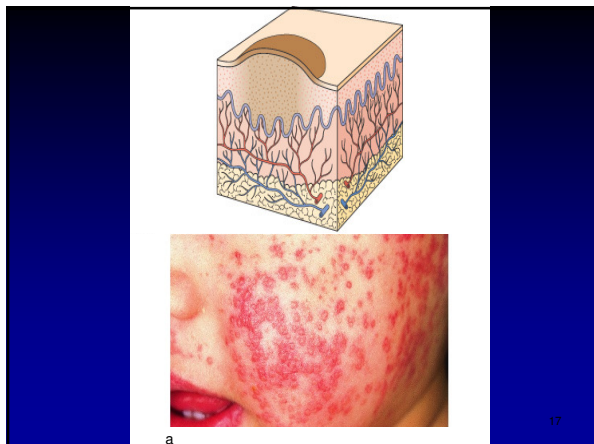
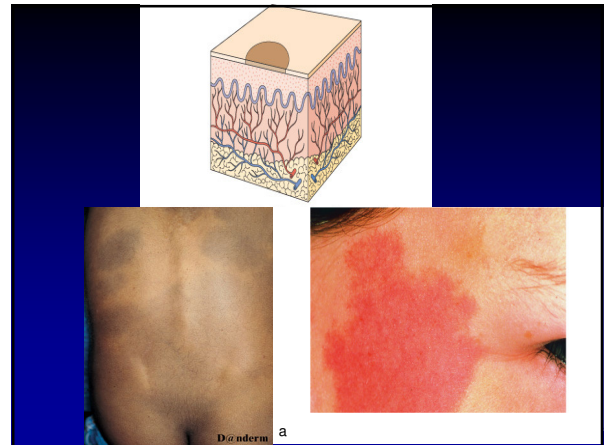
Secondary lesions

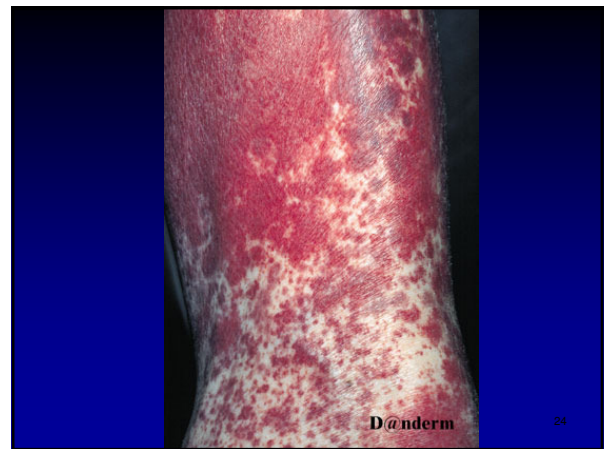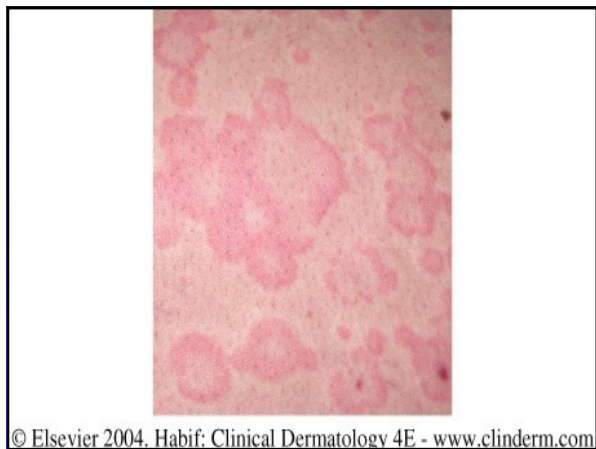
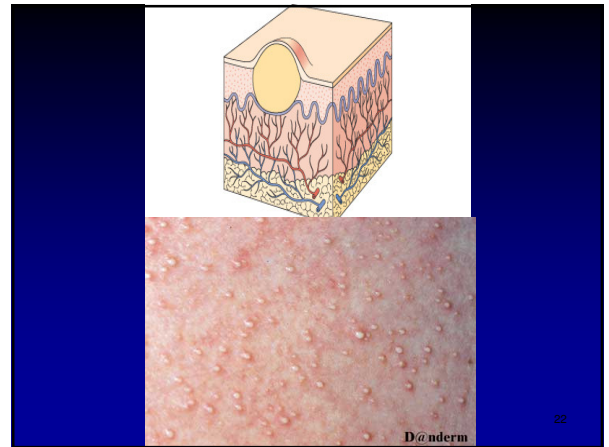
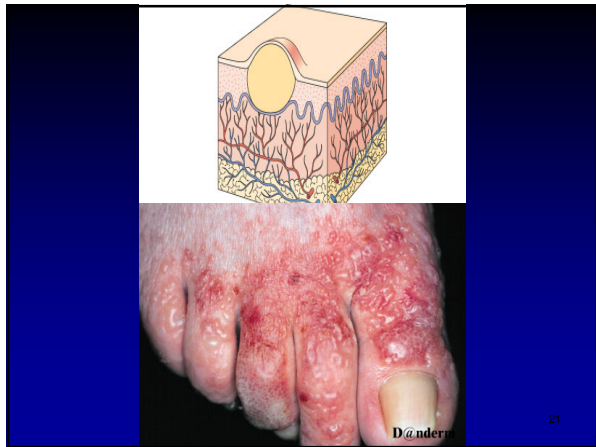
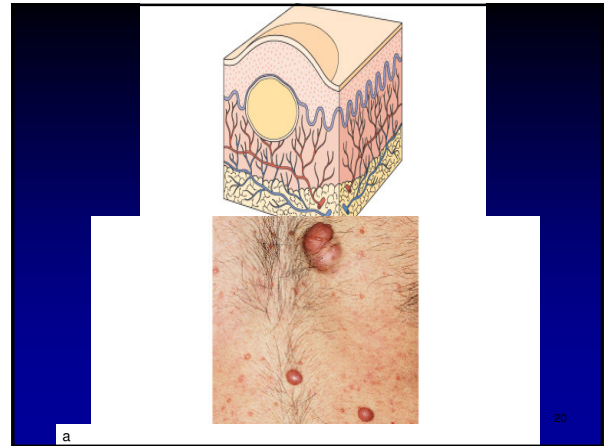
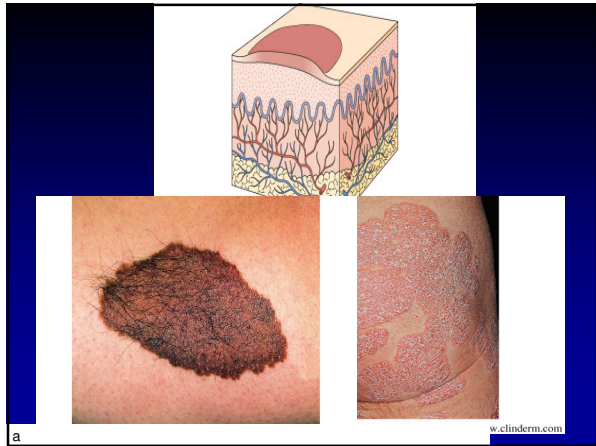14

Primary Lesions

- Macule
- Papule
- Plaque
- Nodule
- Wheal
- Vesicle
- Bulla
- Pustule

15

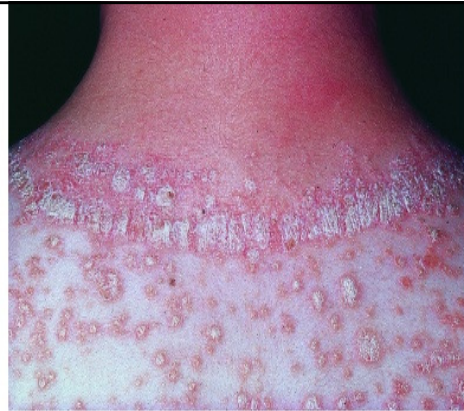



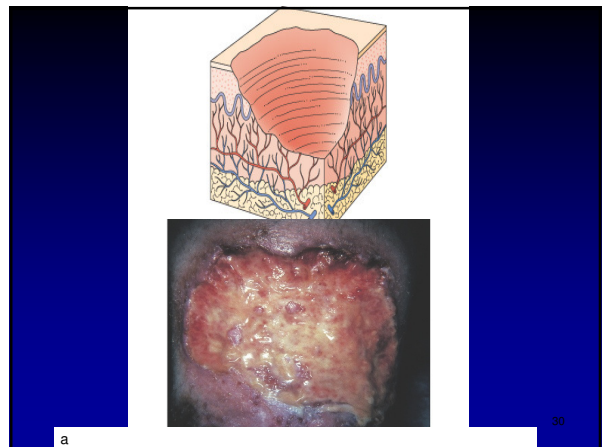
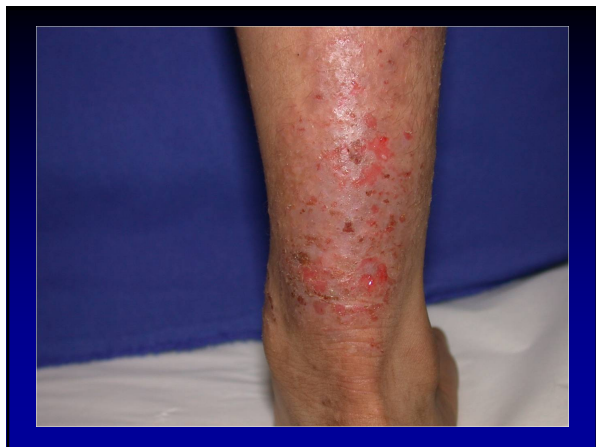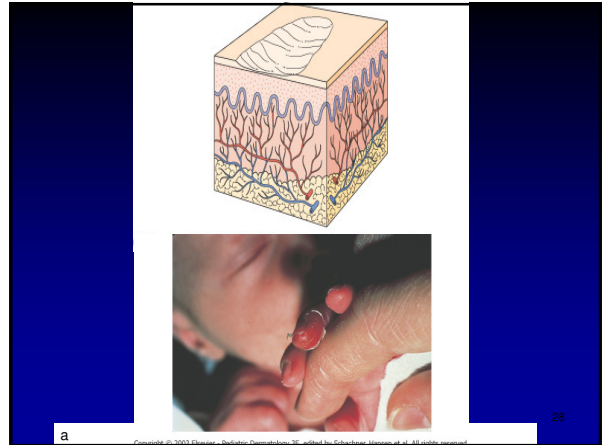
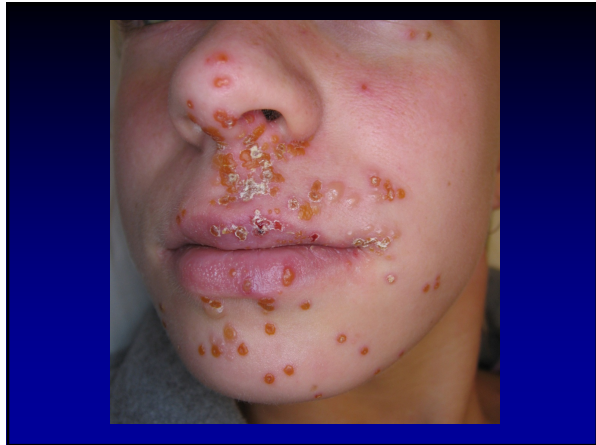Secondary lesions

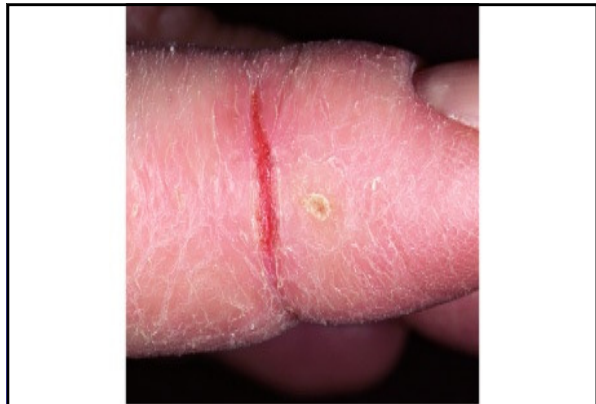Crust
Scale
Ulceration
Excoriation
Scar
Fissure
Lichenification

25

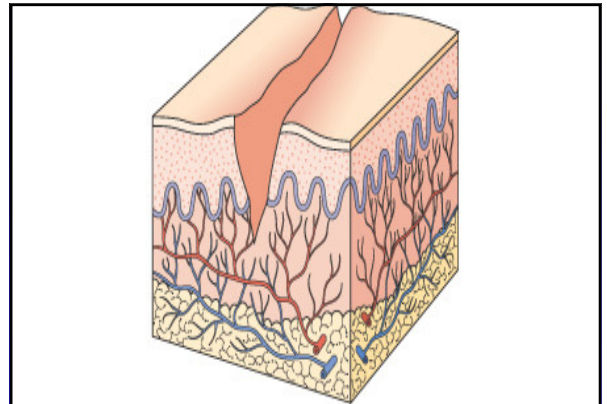


Copyright © 2003 Elsevier - Pediatric Dermatology 3E, edited by Schachner, Hansen et al. All rights reserved

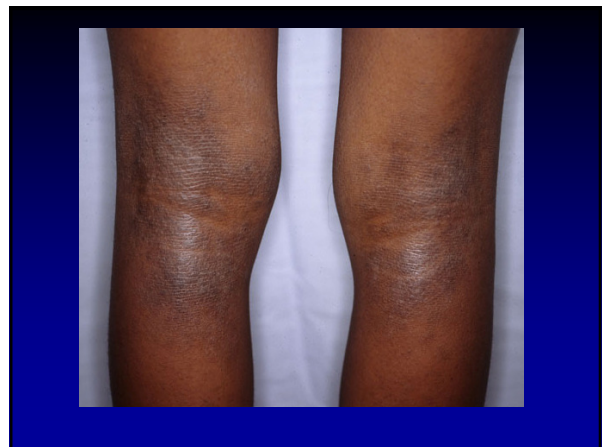
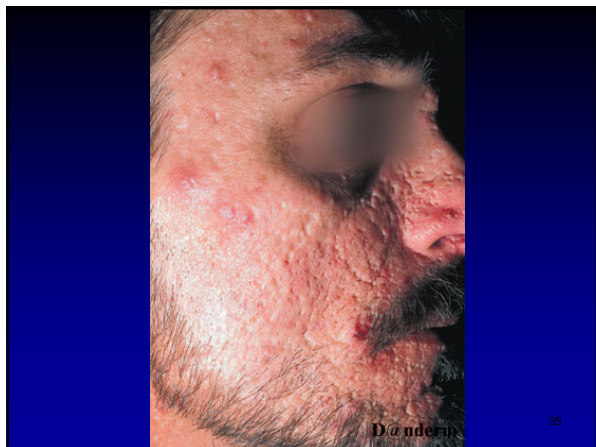
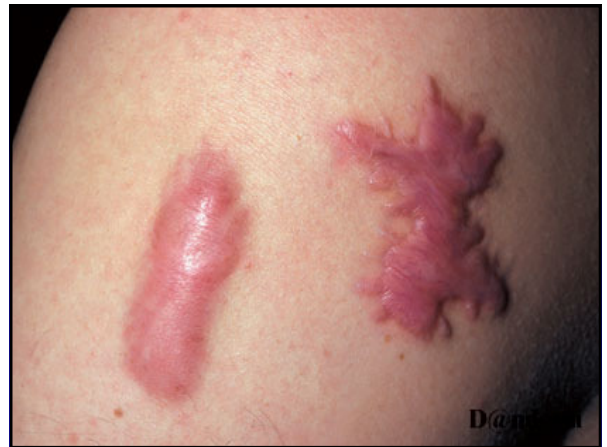
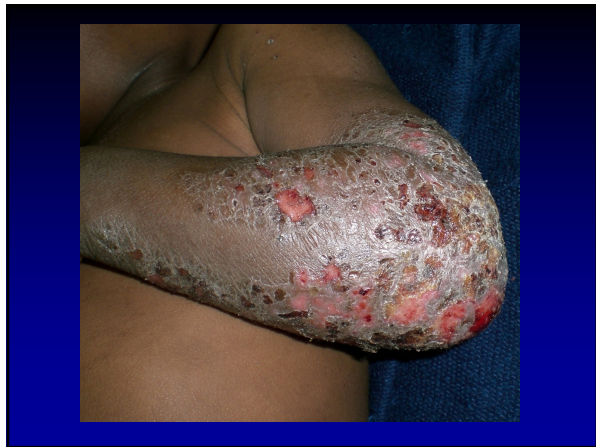
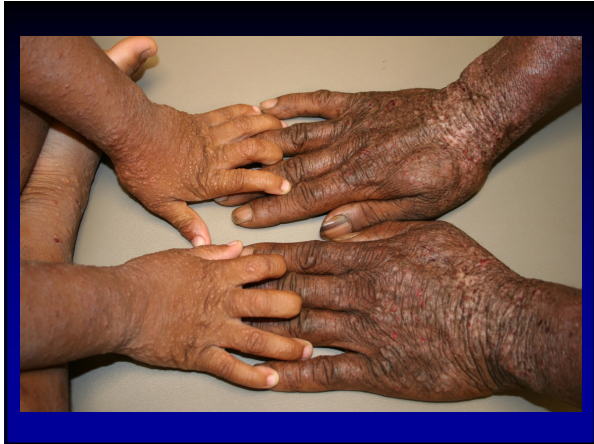© Elsevier 2004. Habif: Clinical Dermatology 4E - www.clinderm.com



© Elsevier 2004. Habif: Clinical Dermatology 4E - www.clinderm.com



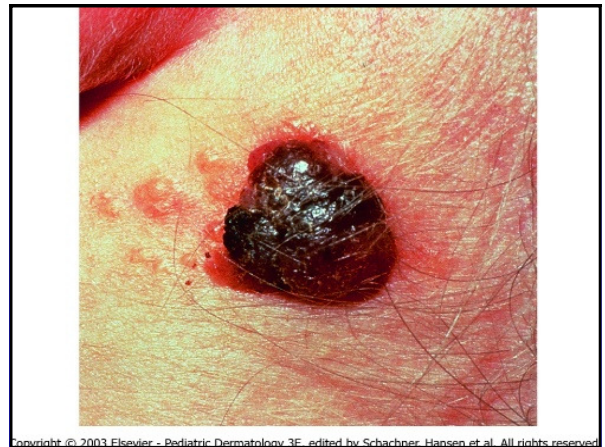

Color and Shape

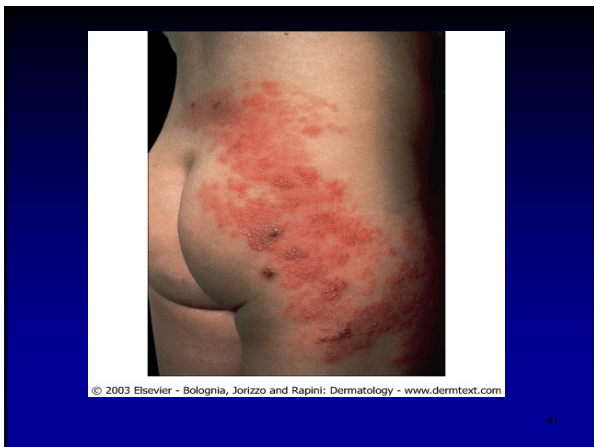Distribution

Configuration

39

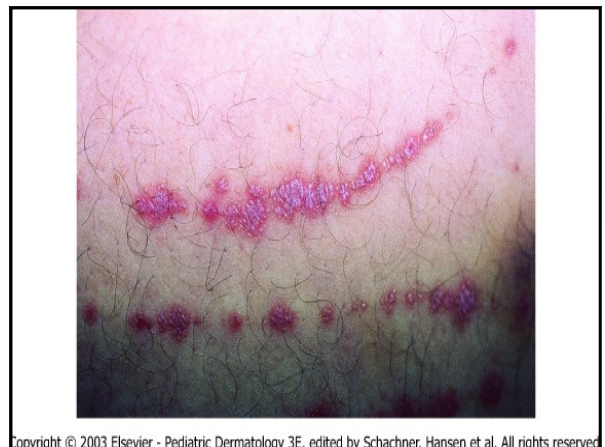

Copyright © 2003 Elsevier - Pediatric Dermatology 3E, edited by Schachner, Hansen et al. All rights reserved

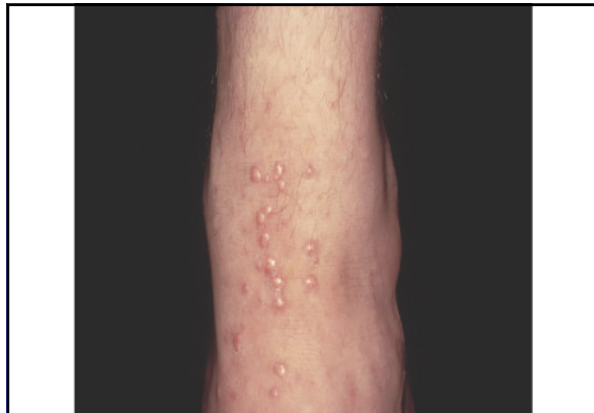

© 2003 Elsevier - Bologna, Jorizzo and Rapini: Dermatology - www.dermtext.com

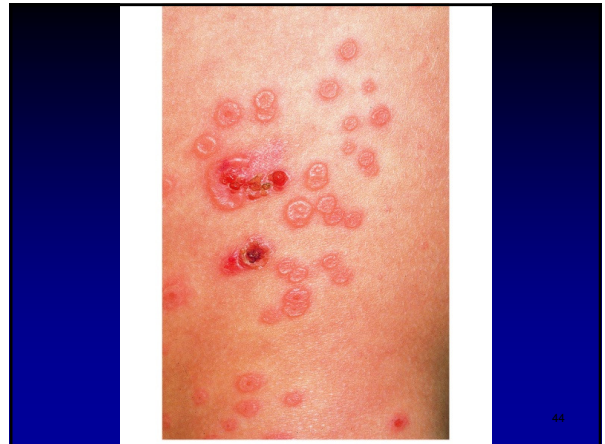41



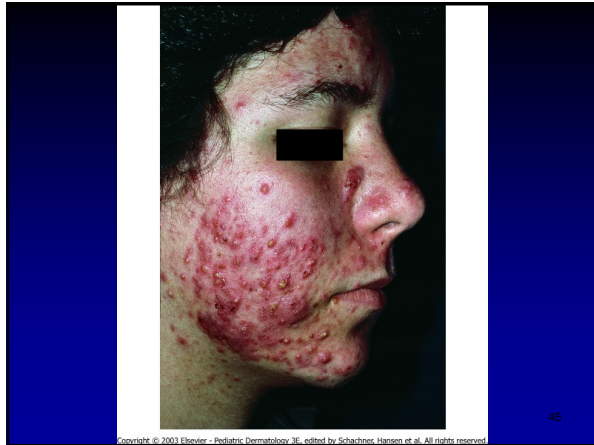Copyright © 2003 Elsevier - Pediatric Dermatology 3E, edited by Schachner, Hansen et al. All rights reserved



Copyright © 2003 Elsevier - Pediatric Dermatology 3E, edited by Schachner, Hansen et al. All rights reserved

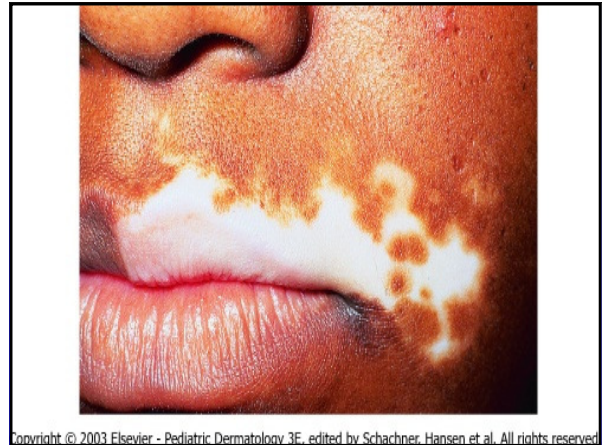

44



Copyright © 2003 Elsevier - Pediatric Dermatology 3E, edited by Schachner, Hansen et al. All rights reserved

45



Copyright © 2003 Elsevier - Pediatric Dermatology 3E, edited by Schachner, Hansen et al. All rights reserved

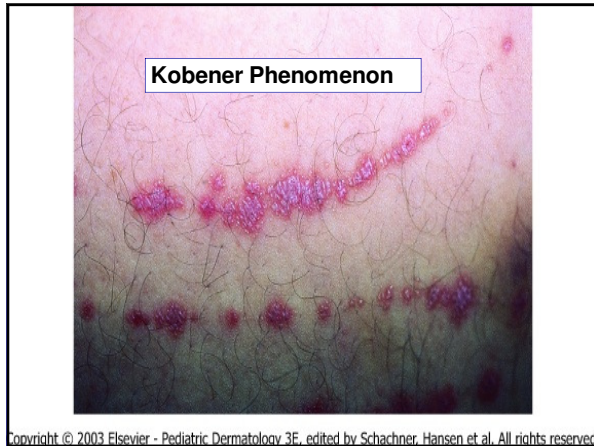Some specific signs in Dermatology

47

❖ **Dermatographism:** When you stroke the normal skin → edema and erythema (you can write on skin!) .Seen in physical urticaria

❖ **Kobener Phenomenon:** Induction of new skin lesions on previously normal appearing skin by trauma e.g. in psoriasis, wart, lichen planus

48



INVESTIGATIVE TOOLS

51

Additional skin examination

~Wood's Lamp:
 Produces long wave ultraviolet light(UVA). e.g.
 Vitiligo → milky white
 Tinea Versicolor → golden
 Tinea Capitis (caused by microsporum) → yellow green
 Erythrasma → coral red

~Dermatoscopy: Helpful to differentiate benign from malignant pigmented lesions.

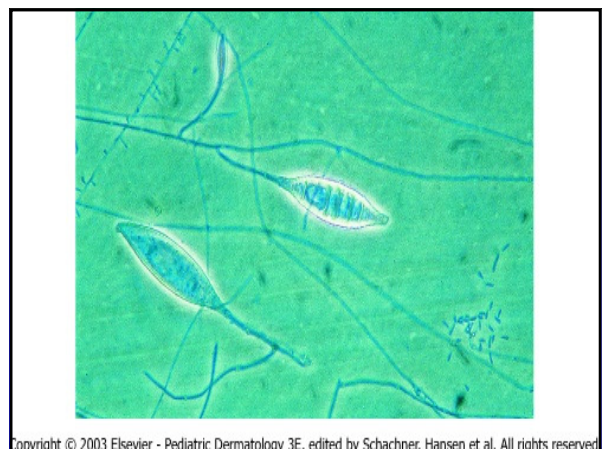52

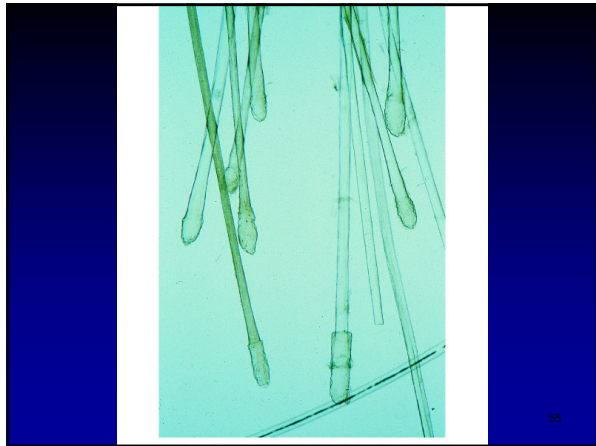
Investigations:

***KOH and fungal culture**

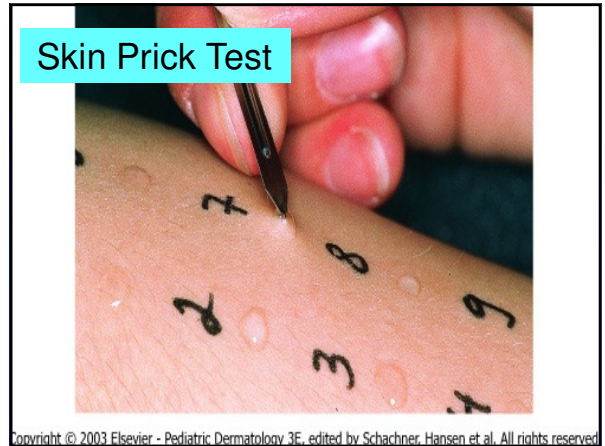- Scrap skin scales → put over glass slide
- Add KOH 10% -- warm gently
- See under microscope
- You may see hyphae and/ or spores

53

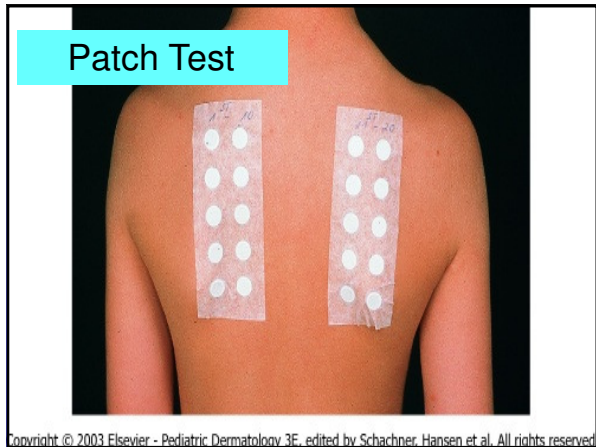




55



Copyright © 2003 Elsevier - Pediatric Dermatology 3E, edited by Schachner, Hansen et al. All rights reserved



Copyright © 2003 Elsevier - Pediatric Dermatology 3E, edited by Schachner, Hansen et al. All rights reserved

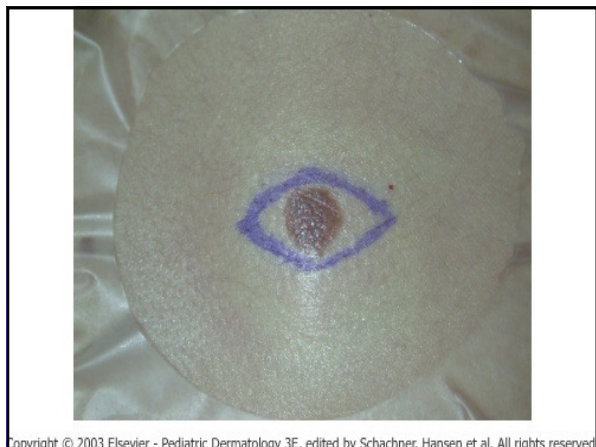
Investigations:

Skin biopsy

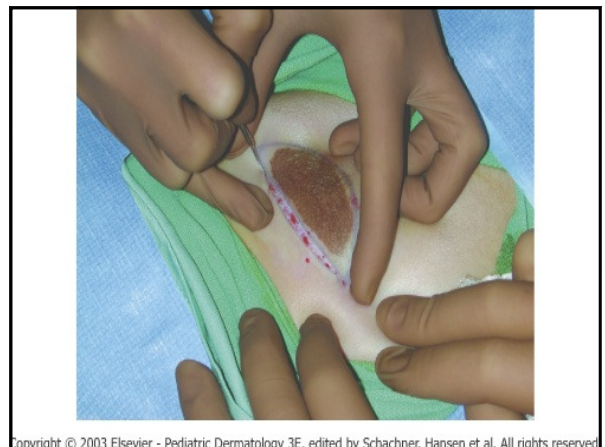
local anesthesia,
different types:

- Punch
- Shave
- Excisional
- Incisional

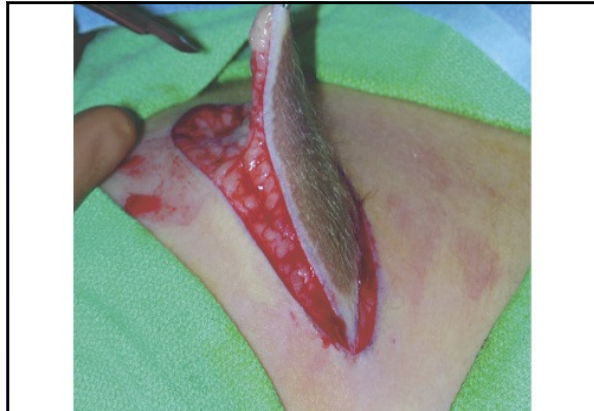58



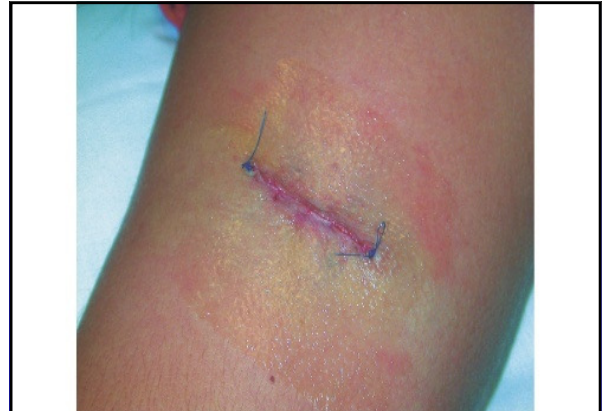Copyright © 2003 Elsevier - Pediatric Dermatology 3E, edited by Schachner, Hansen et al. All rights reserved



Copyright © 2003 Elsevier - Pediatric Dermatology 3E, edited by Schachner, Hansen et al. All rights reserved



Copyright © 2003 Elsevier - Pediatric Dermatology 3E, edited by Schachner, Hansen et al. All rights reserved



Copyright © 2003 Elsevier - Pediatric Dermatology 3E, edited by Schachner, Hansen et al. All rights reserved

Treatment:

Topical

Systemic

63

Topical Treatments

Various formulations:

- Ointment
- Cream
- Gel
- Solution
- Lotion

64

Topical steroids

7 Categories:
according to strength

65

Phototherapy

Ultraviolet light A or B
with or without psoralen

PUVA (Psoralen + UVA)

New modalities:

- Narrow band UVB
- UVA – 1
- Excimer laser(308nm)

66

Dermatology subspecialties

- Pediatric dermatology
- Photomedicine
- Laser
- Hair Disorders and Transplantation
- Dermatologic surgery
- Allergy/Contact dermatitis
- Dermatopathology
- Immunodermatology
- Others

