

CUTANEOUS MANIFESTATIONS OF SYSTEMIC DISEASES

Dr. Saleh Alrasheed

**Consultant in Dermatology and Cutaneous
Laser Surgery**

Assistant Professor - Dermatology Department




College of Medicine

KSU , Riyadh.






Contents:

Introduction:

Connective Tissue Diseases

-  Lupus
-  Dermatomyositis
-  Scleroderma

Endocrinological Diseases

-  Diabetes Mellitus
-  Hyperthyroidism
-  Hypothyroidism
-  Cushing's Syndrome
-  Addison's disease

● GIT:

- u Chronic Liver Disease (CLD)
- u Acrodermatitis enteropathica
- u Peutz Jeghers Syndrome
- u Pyoderma Gangrenosum
- u Hereditary hemorrhagic Telangiectasia

● Metabolic:

- u Hyperlipidemia

● Neurocutaneous diseases

1. Neurofibromatosis
2. Tuberous Sclerosis

● Behcet's Syndrome

- u Nutritional deficiency disorders
 - v Scurvy
 - v Pellagra

● Causes of Generalized pruritus without skin lesions

● Cutaneous manifestations of internal malignancy.

- u Acanthosis Nigricans
- u Dermatomyositis

● Nails:

- u Clubbing
- u Koilonychia
- u Splinter haemorrhages

● When to do HIV testing for skin Disease ?

● Introduction:

- u Skin is the “Gate of the Body”
- u Detection of Systemic disease or internal malignancy through skin presentation.
- u Systemic diseases associated with skin diseases

● SLE:

- u Facial Photosensitivity
- u Butterfly Erythema
- u Multisystem disease (Renal, CNS, Cardiac, Blood, etc....)
- u Positive ANA and anti-ds DNA

Discoid Lupus (DLE)

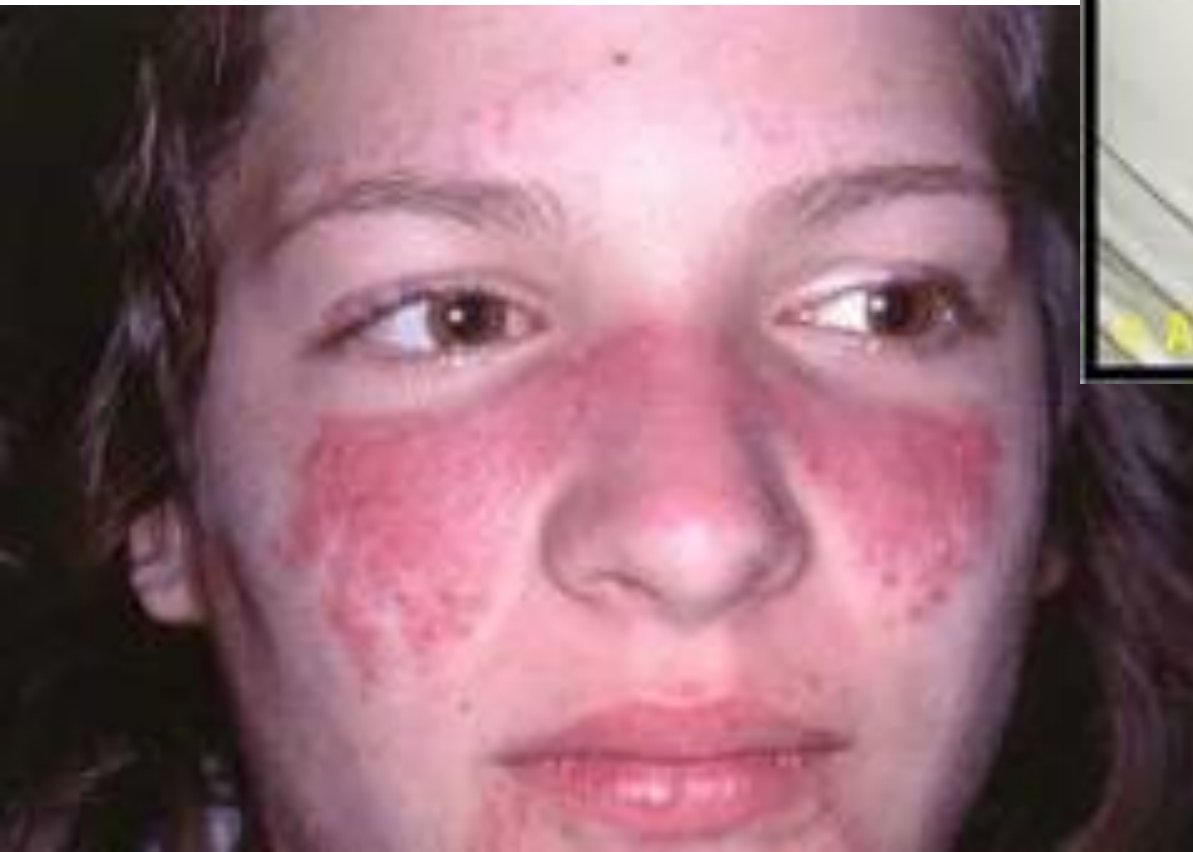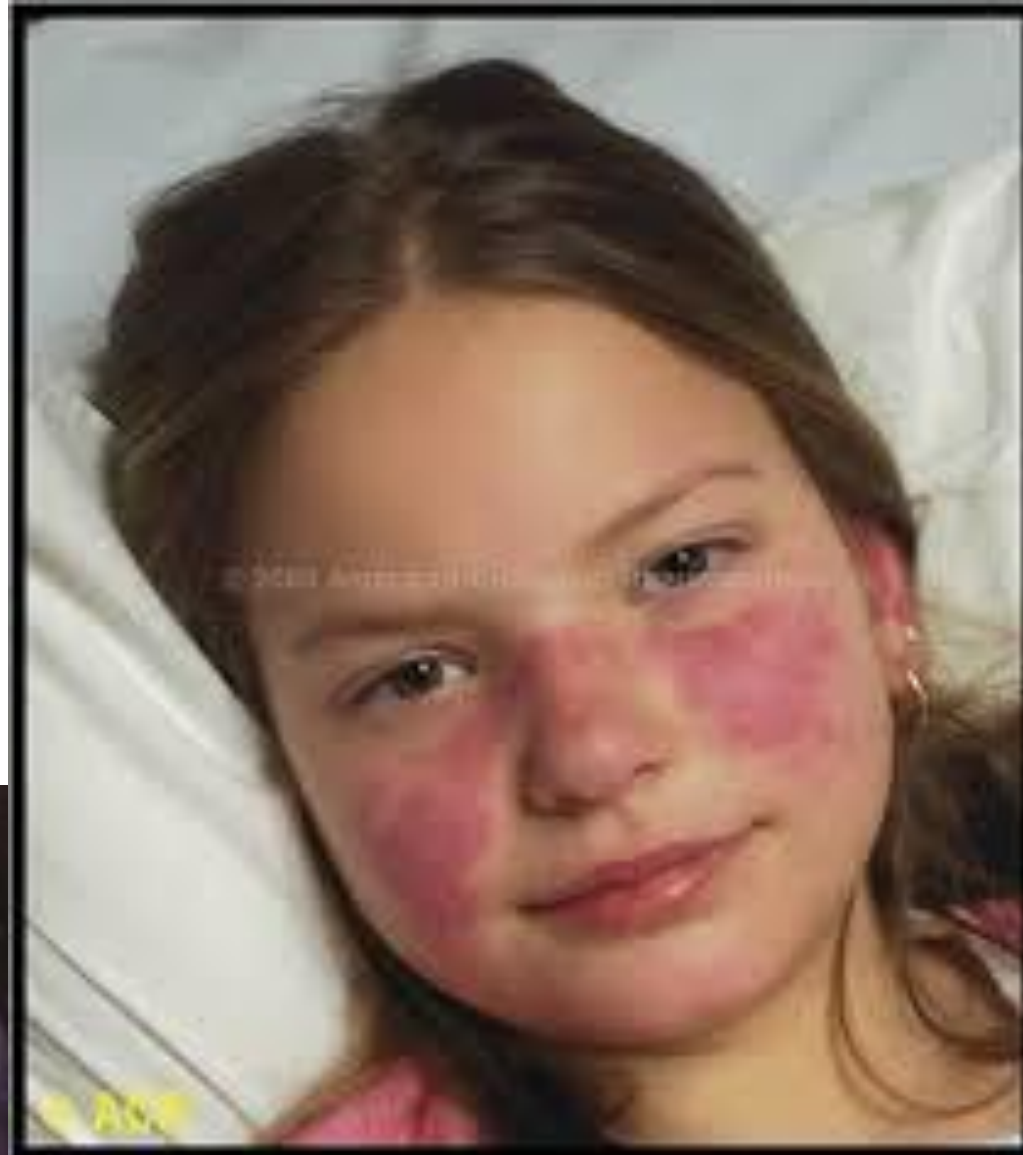- u Usually ANA Negative
- u round scarring lesions on light exposed areas
- u No Systemic involvement

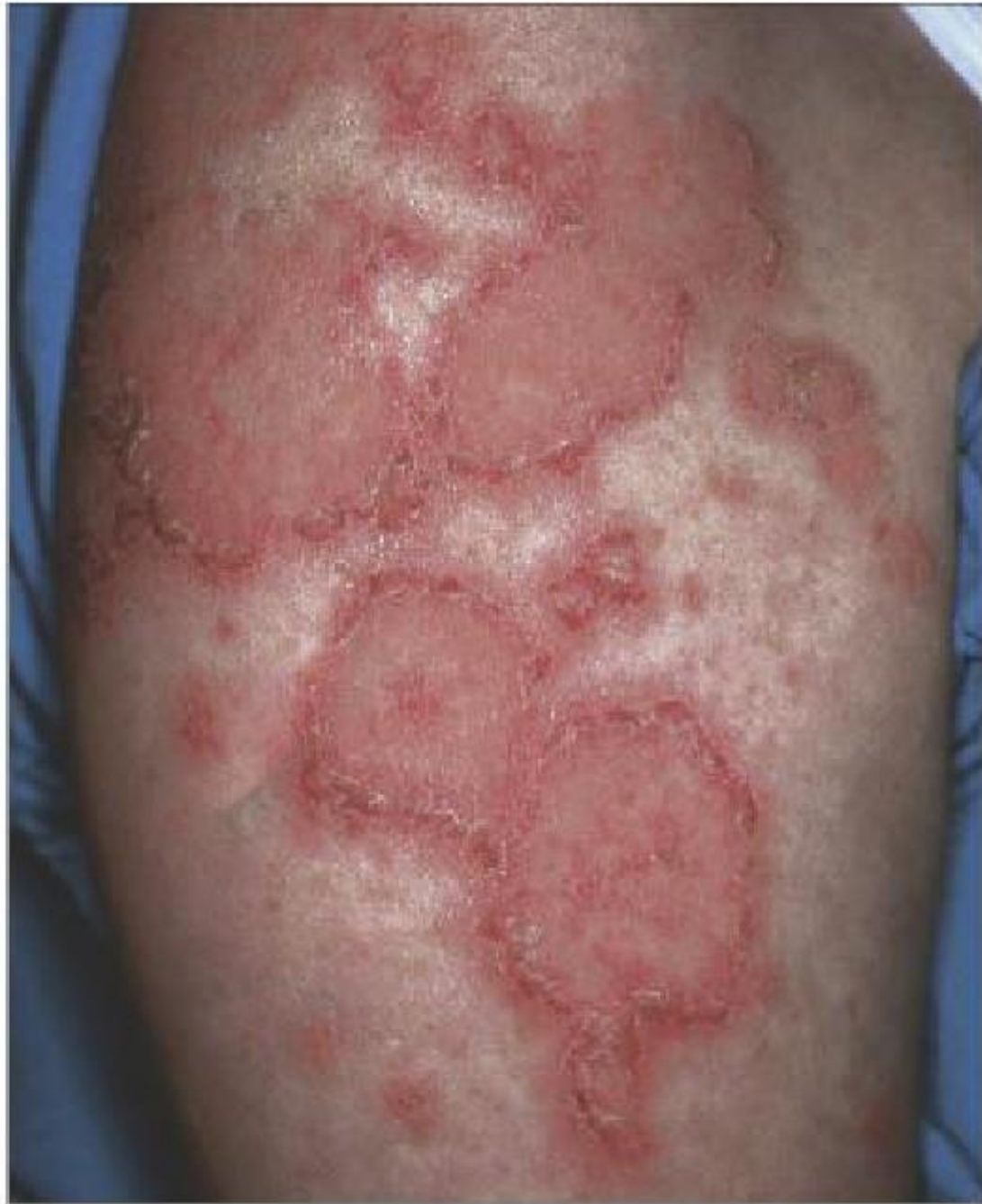● Subacute Cutaneous Lupus (SCLE)

- u papulosquamous or annular presentation
- u Photosensitivity
- u Does not cause scarring
- u Usually ANA negative but anti Ro positive.
- u Mild systemic involvement

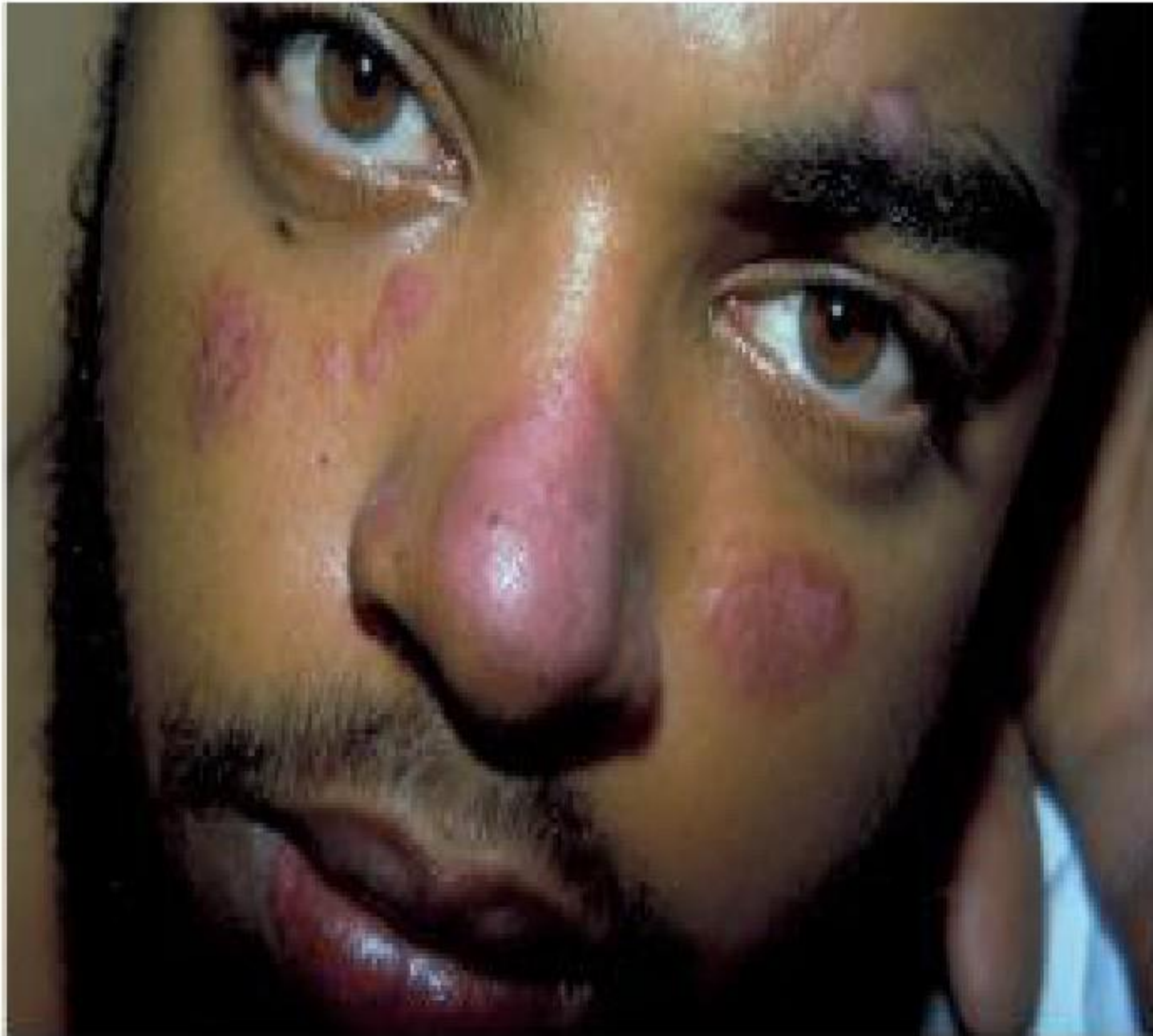Neonatal Lupus:

- u Appears in the first month in a photo-distribution
- u Patterns : Papulosquamous and annular
- u Congenital heart block (complete & permanent) usually needs pacemaker
- u anti Ro positive

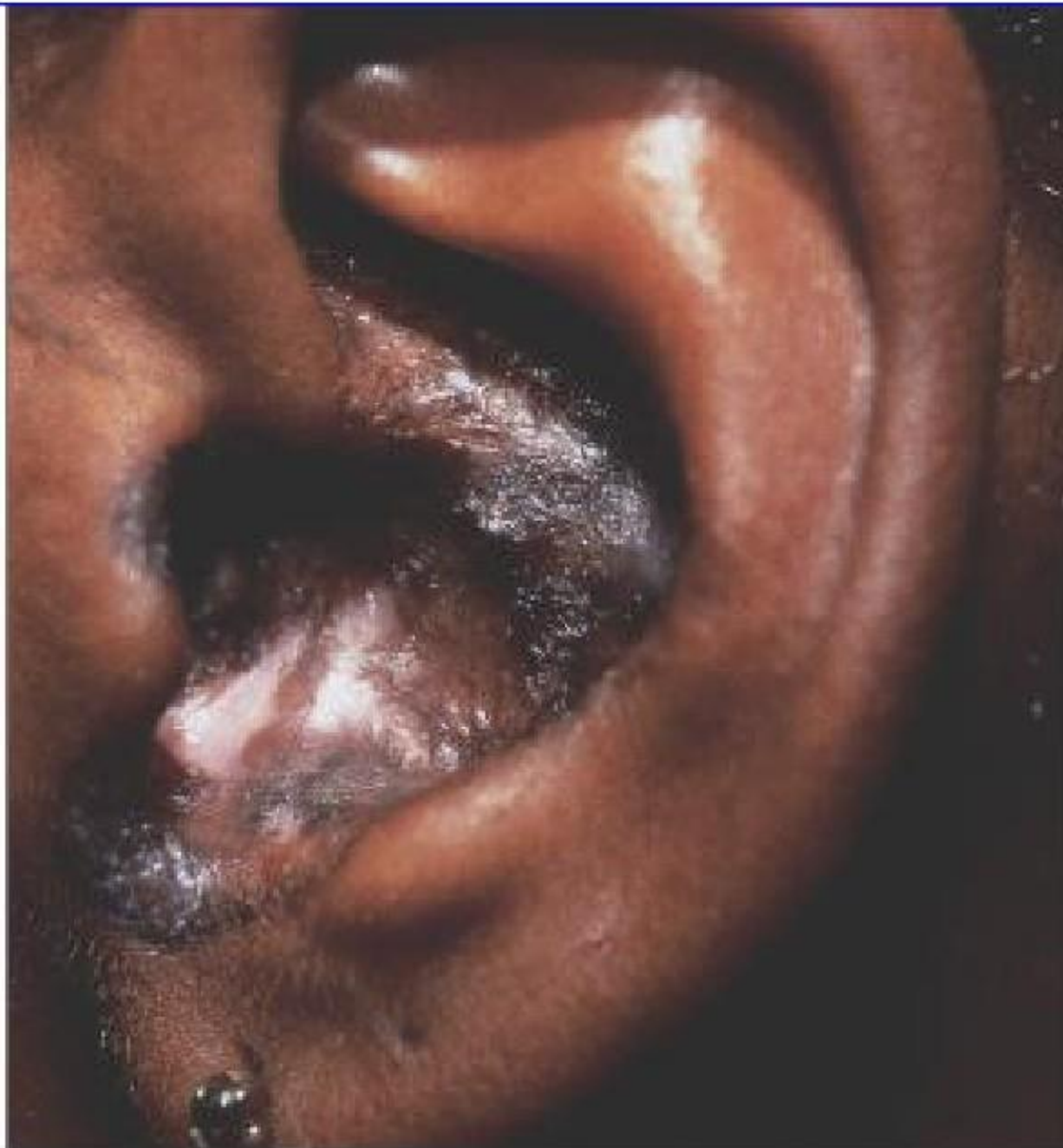




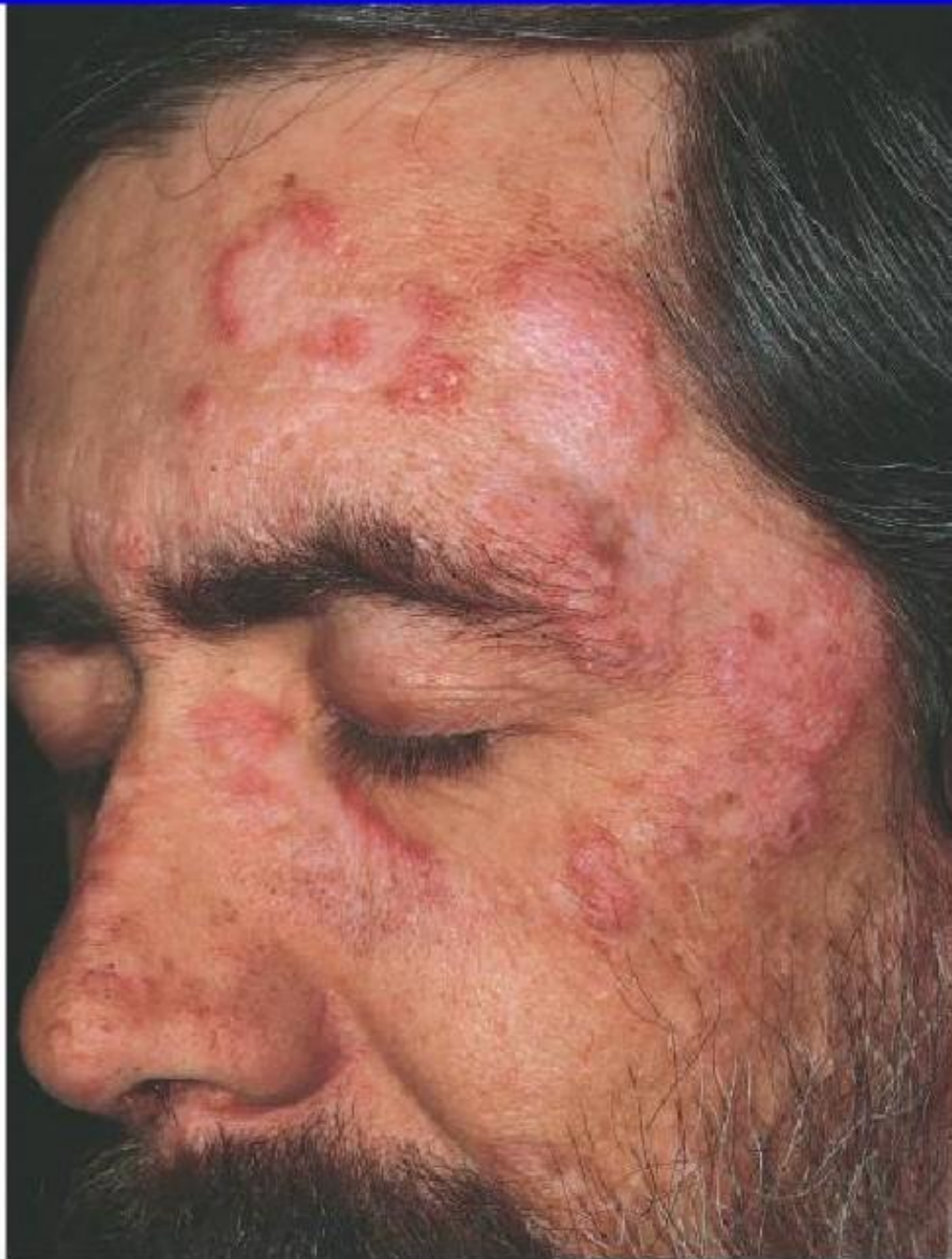© 2003 Elsevier - Bologna, Jorizzo and Rapini: Dermatology - www.dermtext.com



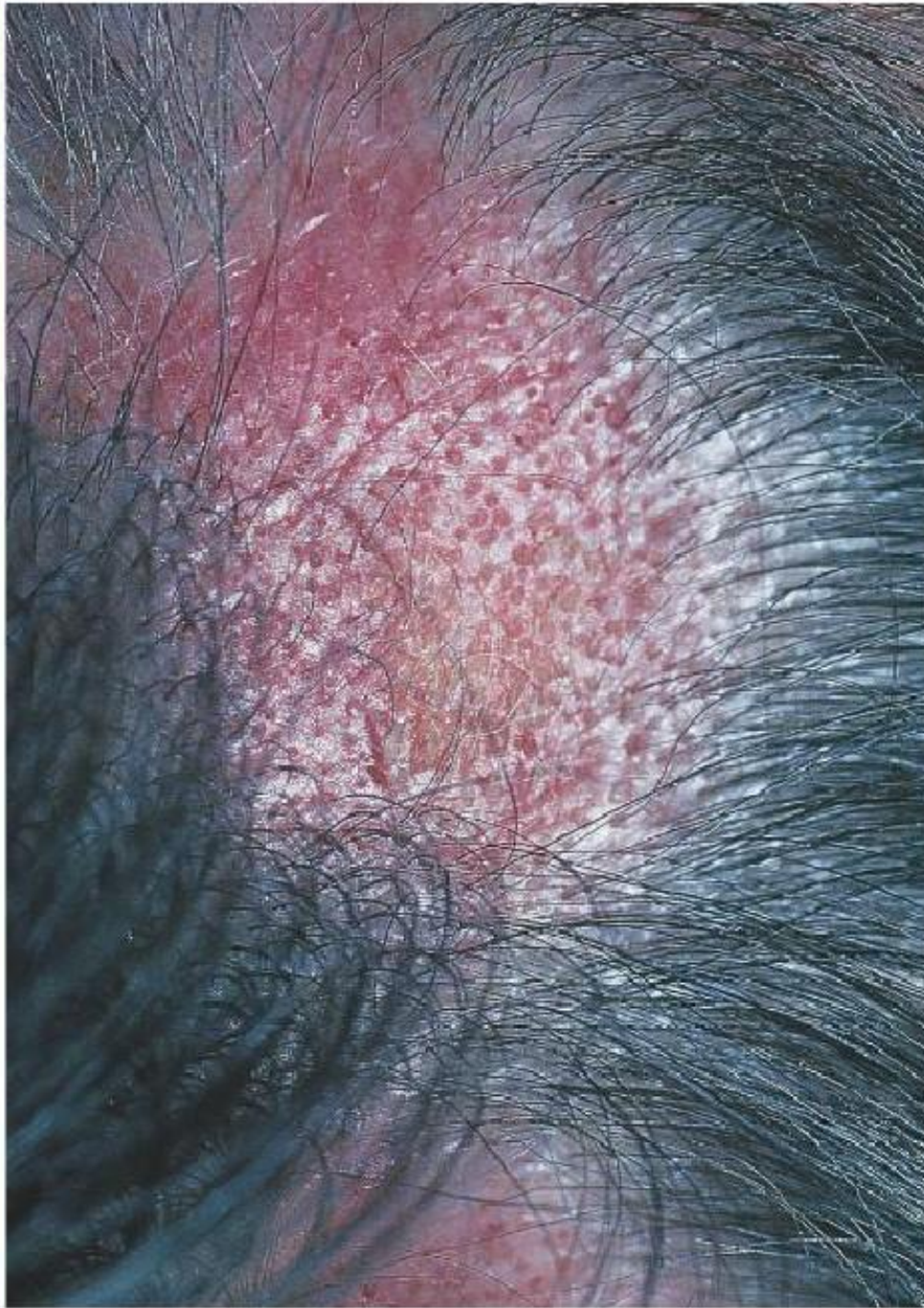
Elsevier 2004, Habif: Clinical Dermatology 4E - www.clinderm.co



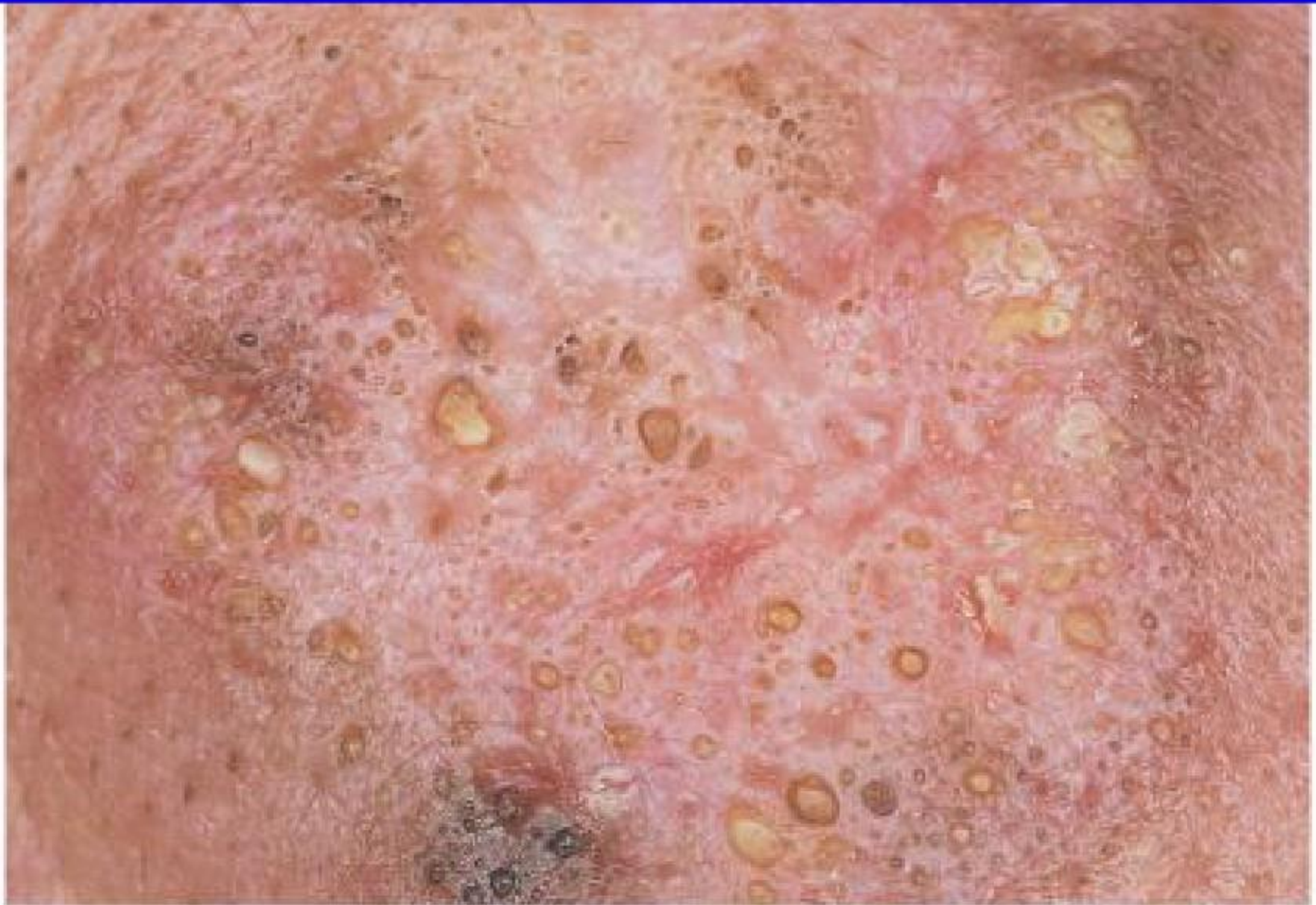© 2003 Elsevier - Bologna, Jorizzo and Rapini: Dermatology - www.dermtext.com



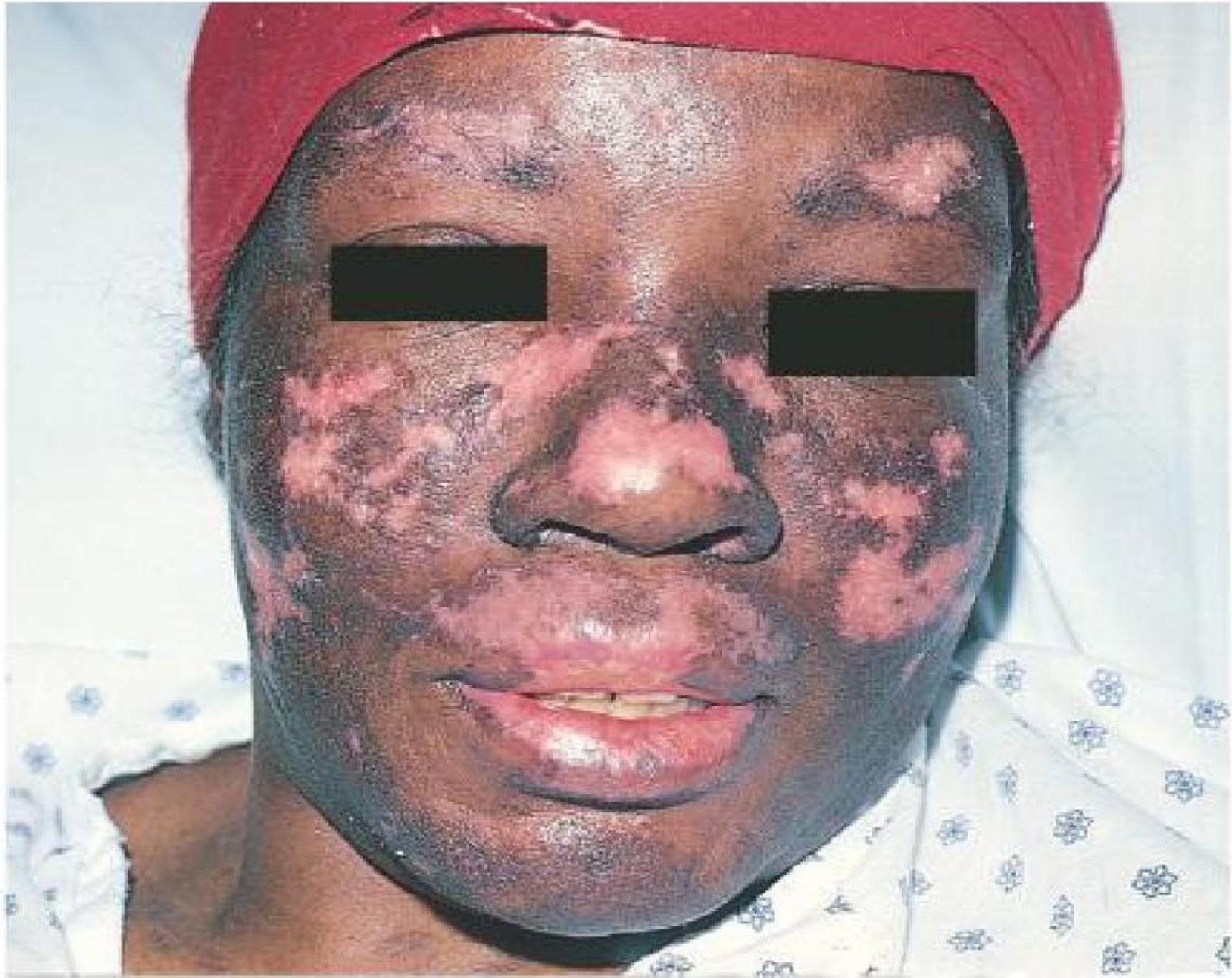© Elsevier 2004. Habif; Clinical Dermatology 4E - www.clinderm.com



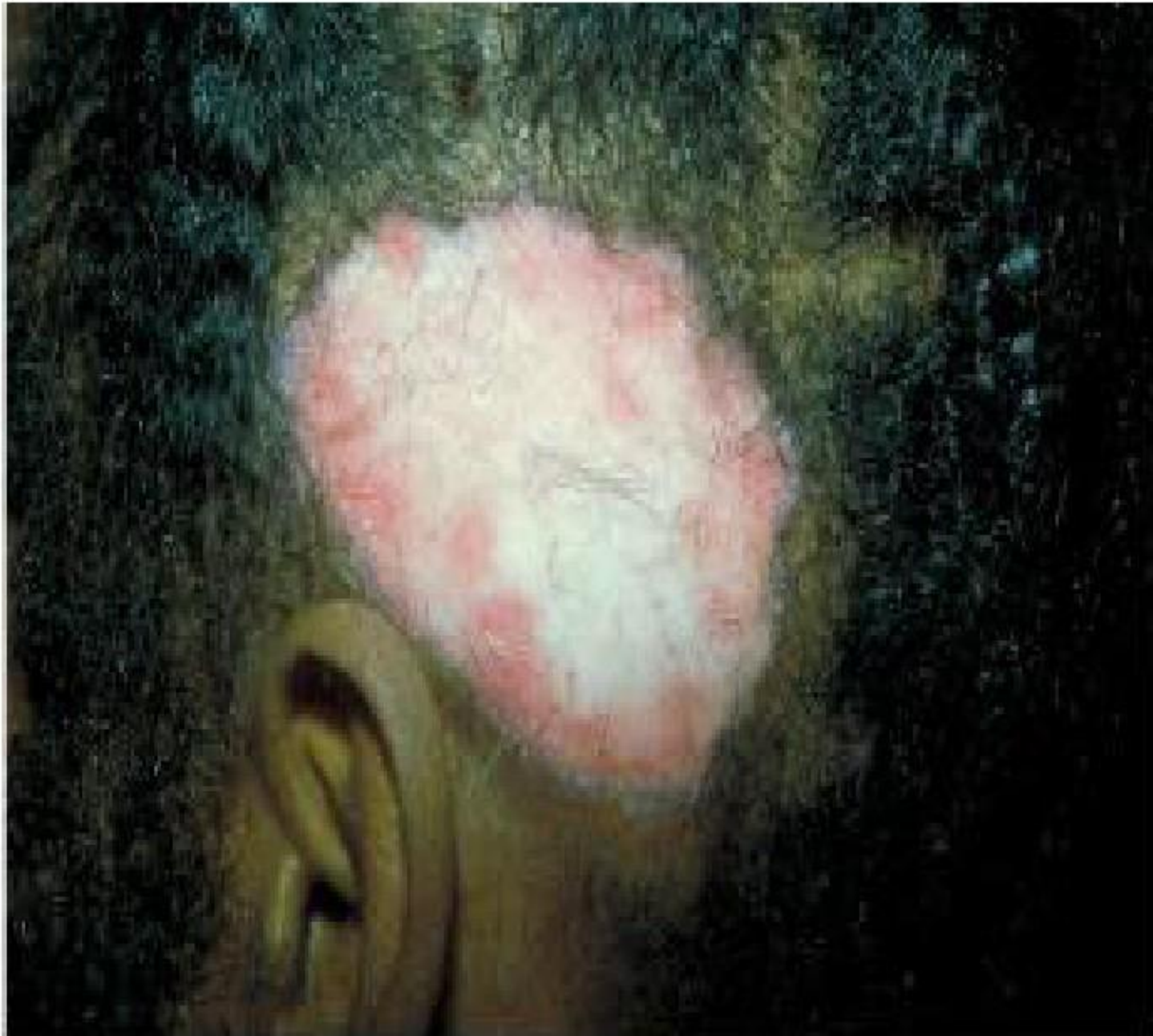© Elsevier 2004, Habif: Clinical Dermatology 4E - www.clinderm.com



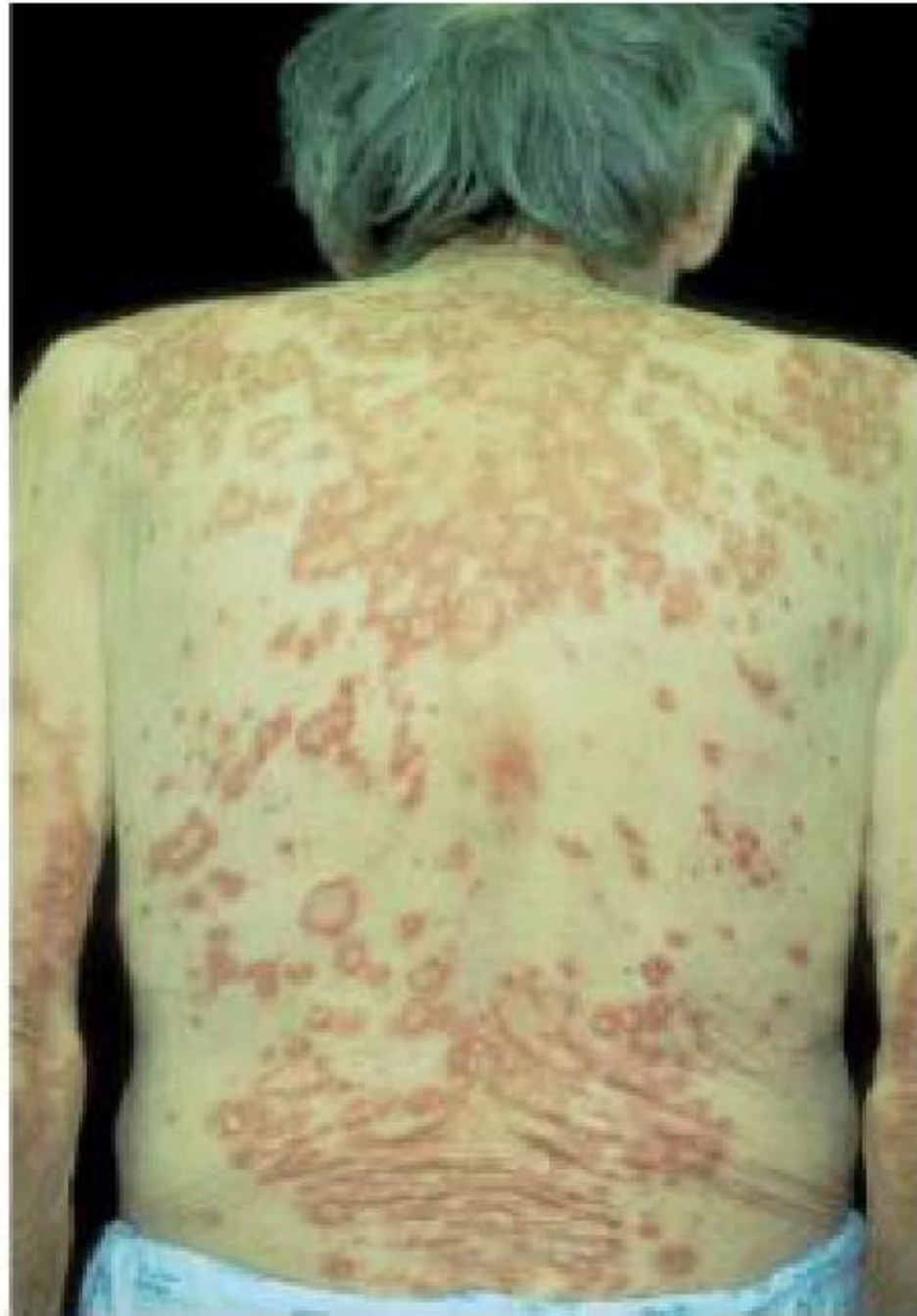© Elsevier 2004. Habif: Clinical Dermatology 4E - www.clinderm.com



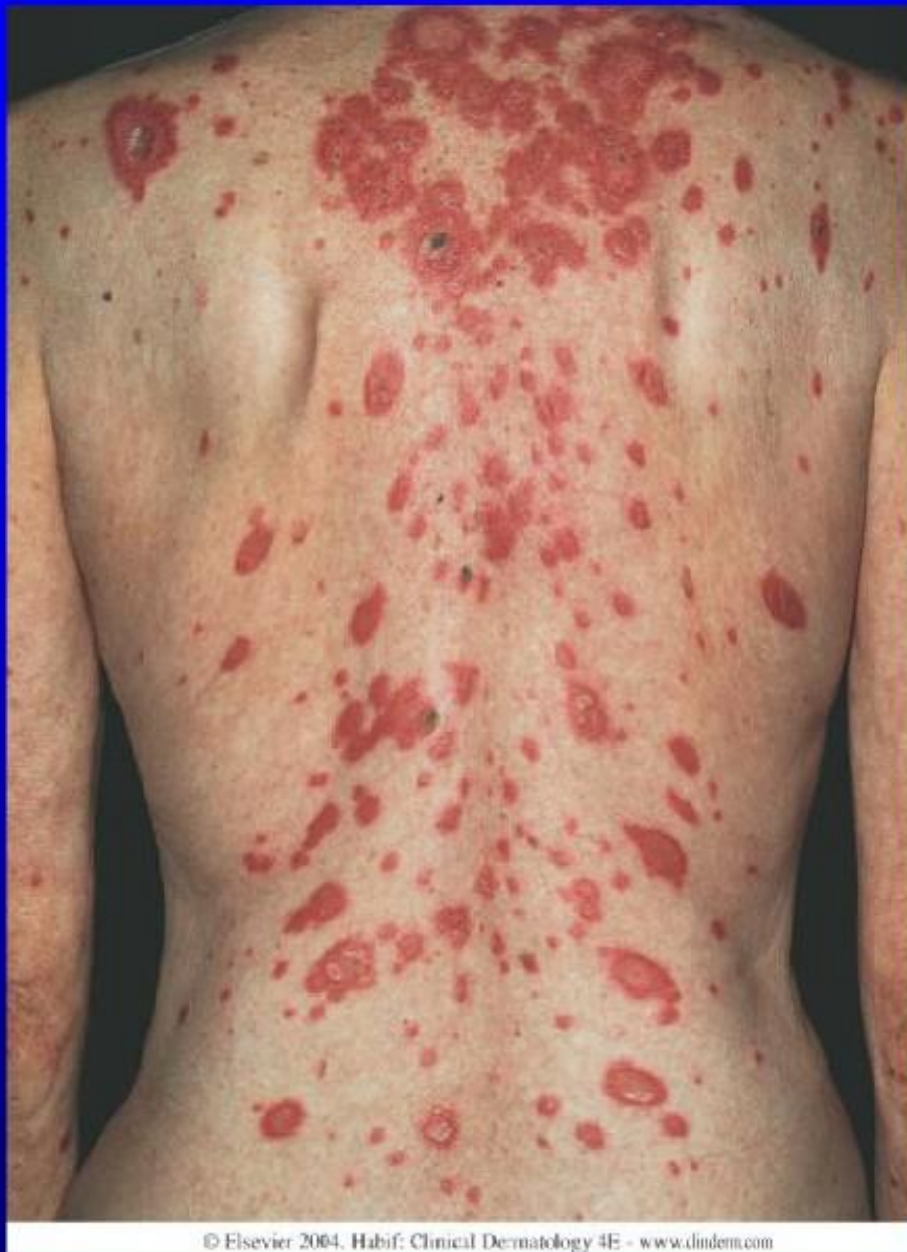© Elsevier 2004. Habif: Clinical Dermatology 4E - www.clinderm.com



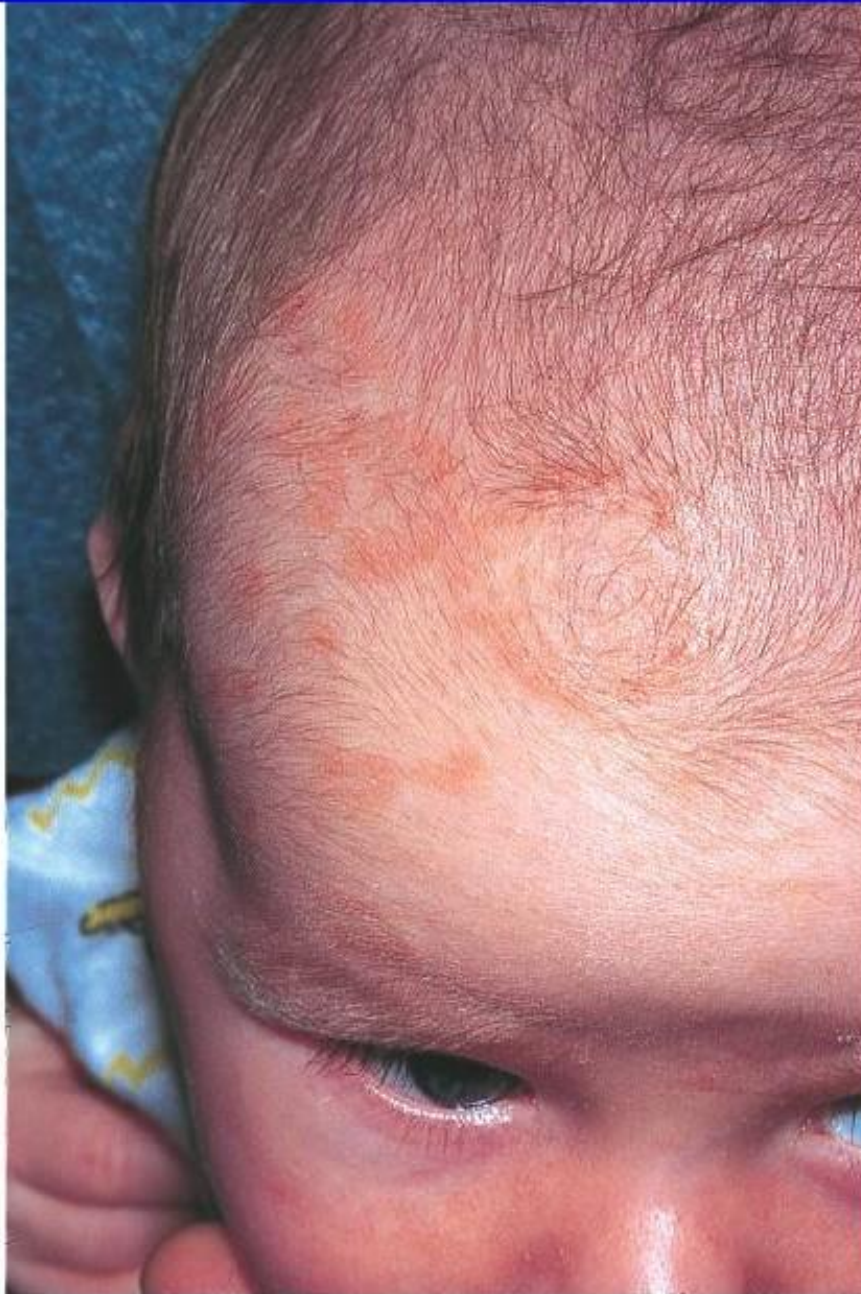Elsevier 2004, Habif: Clinical Dermatology 4E - www.clinderm.co



Elsevier 2004. Habif: Clinical Dermatology 4E - www.clinderm.co



© Elsevier 2004, Habif: Clinical Dermatology 4E - www.clinem.com



© Elsevier 2004. Habif; Clinical Dermatology 4E - www.clinderm.com

● Drug - Induced Lupus:

- u Cause:

- v Procainamide

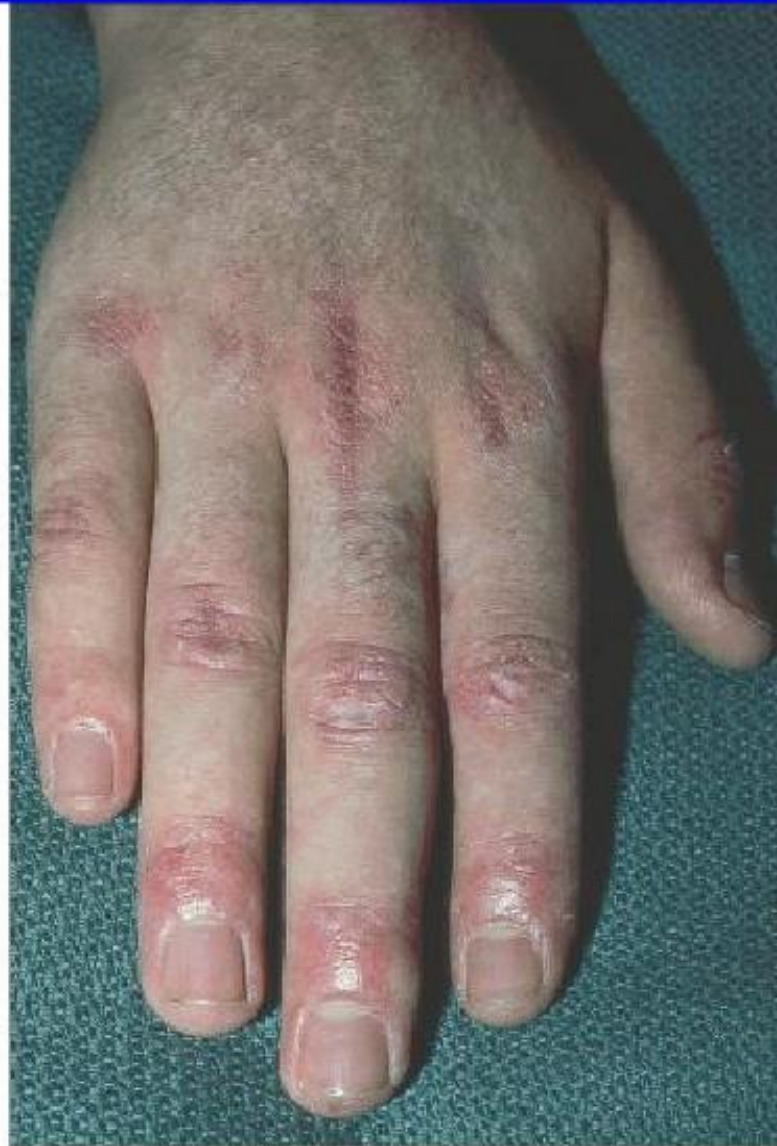- v Hydralazine

- v Others

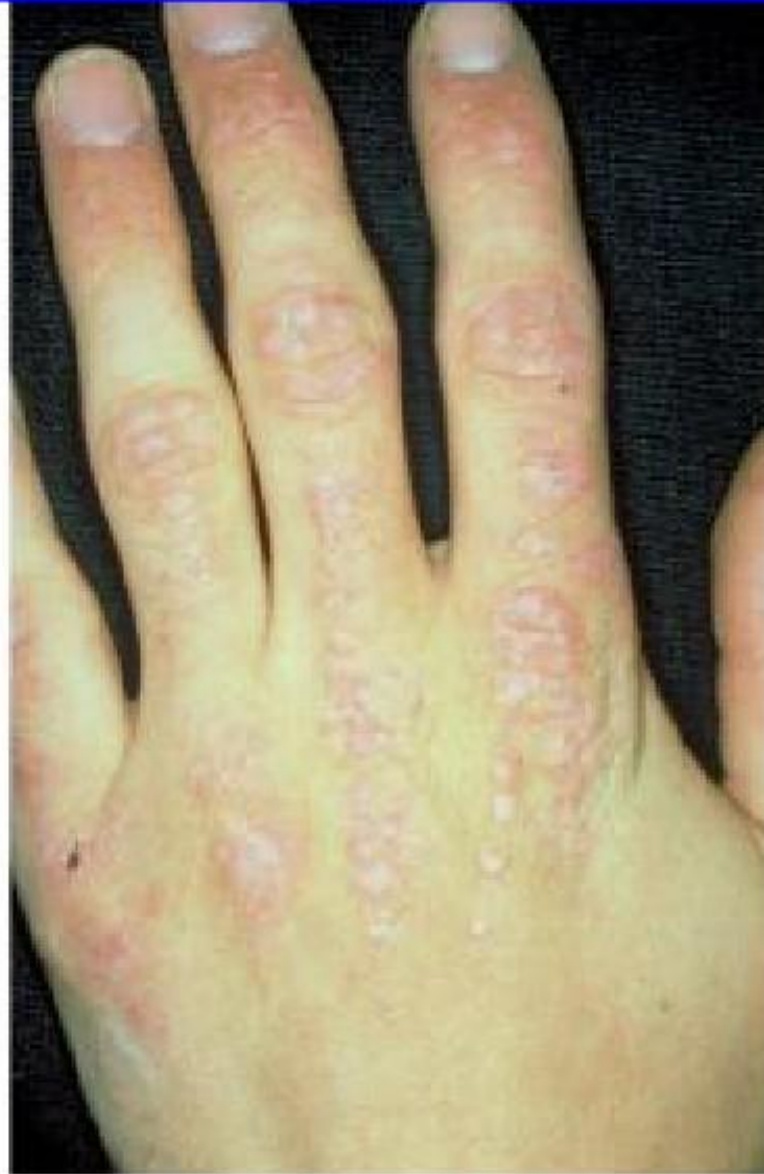- u Antihistone positive

● Dermatomyositis (Skin Rash + Muscle Weakness):

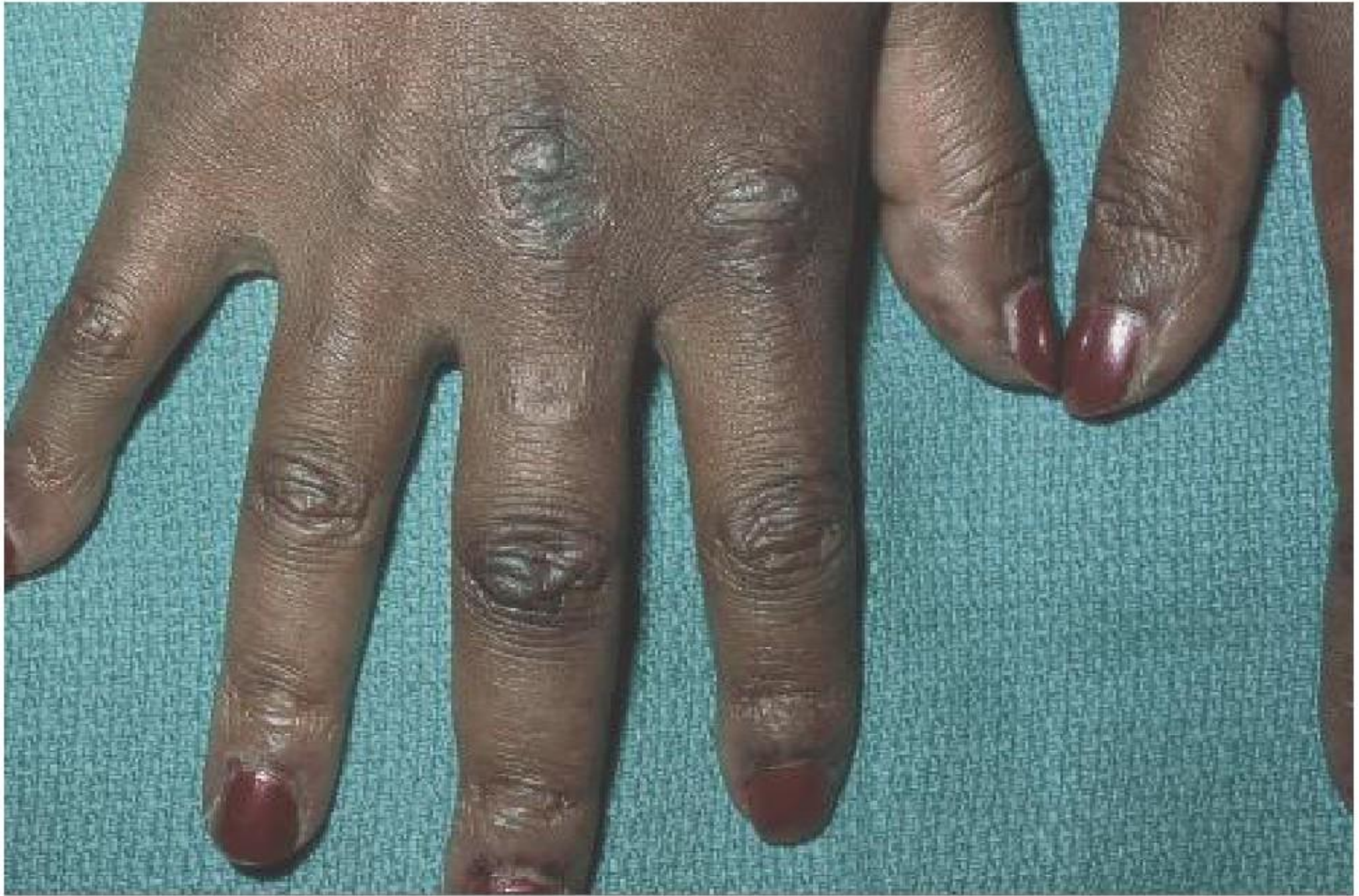- u Heliotrope : Violeceous color over the upper eyelids
- u Gottron's papules: Flat- topped violaceous papules over knuckles of hands
- u Calcifications especially in kids
- u Bilateral proximal muscle weakness (with high CPK, Positive EMG and Muscle biopsy)
- u In adults (especially over 50 yrs)
associated with internal malignancy (e.g. GI, Prostrate, ovary & breast)



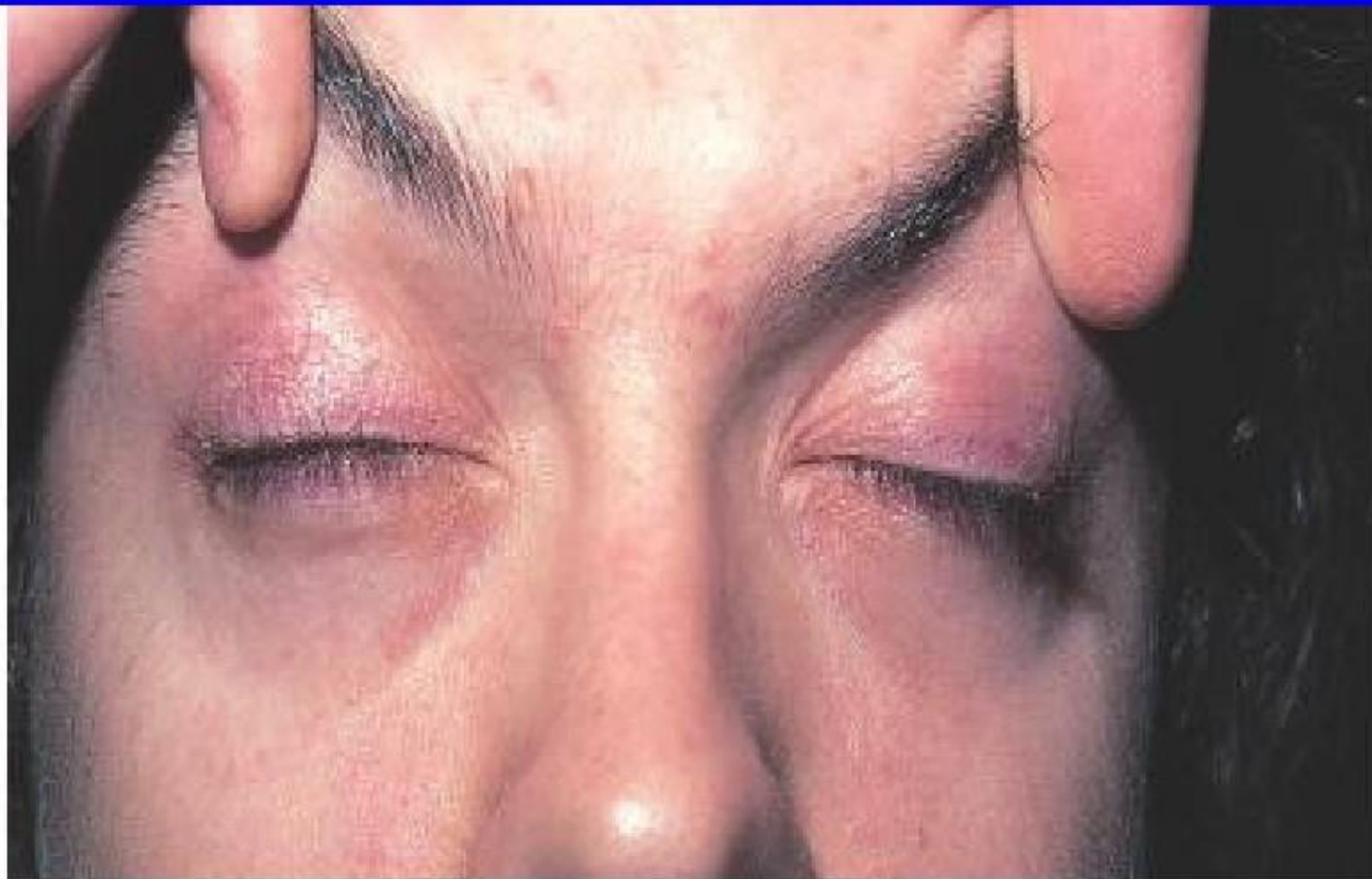© 2003 Elsevier - Bologna, Jorizzo and Rapini: Dermatology - www.dermtext.com



© Elsevier 2004. Habif: Clinical Dermatology 4E - www.clinderm.com



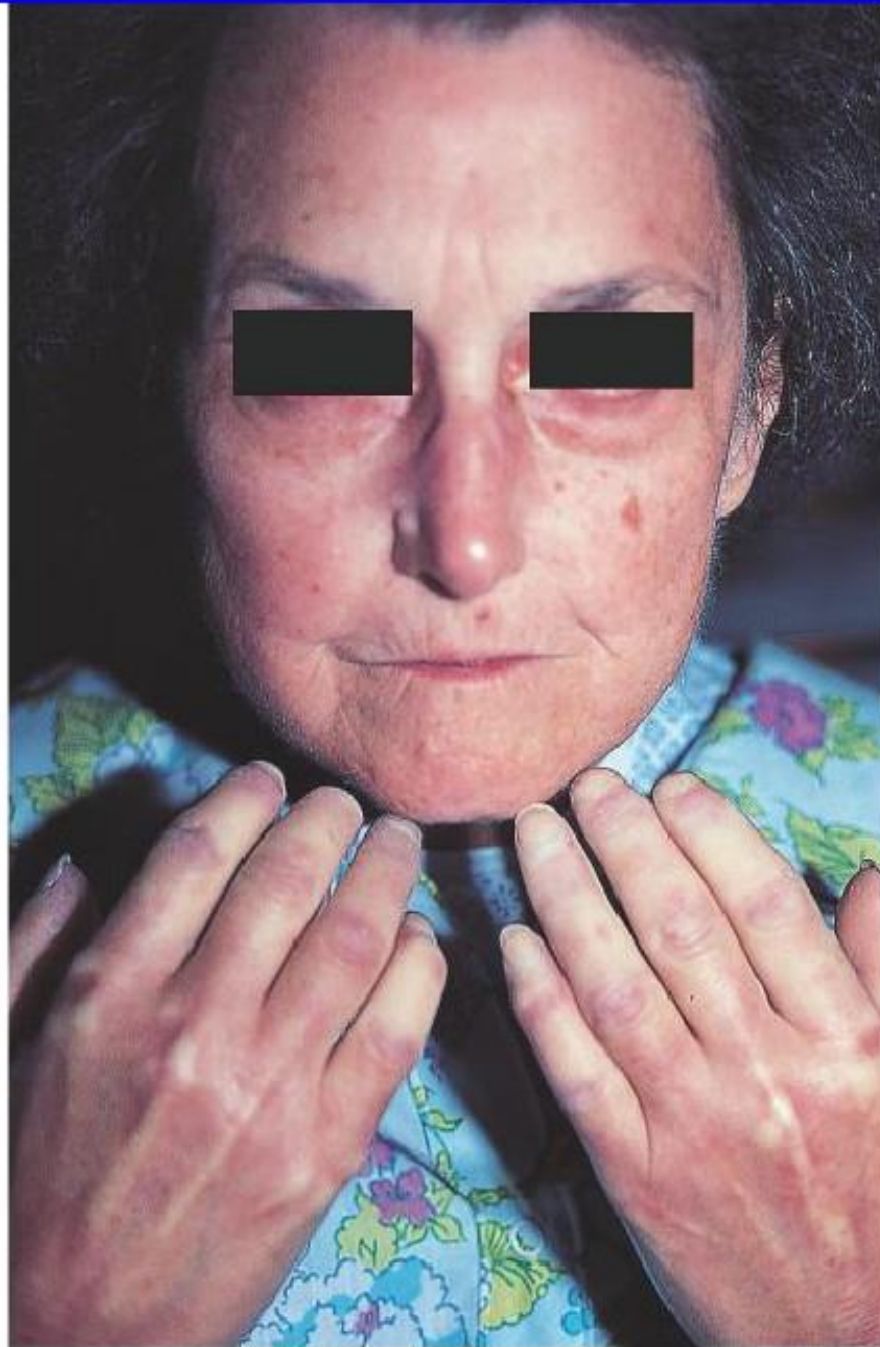© 2003 Elsevier - Bologna, Jorizzo and Rapini: Dermatology - www.dermtext.com



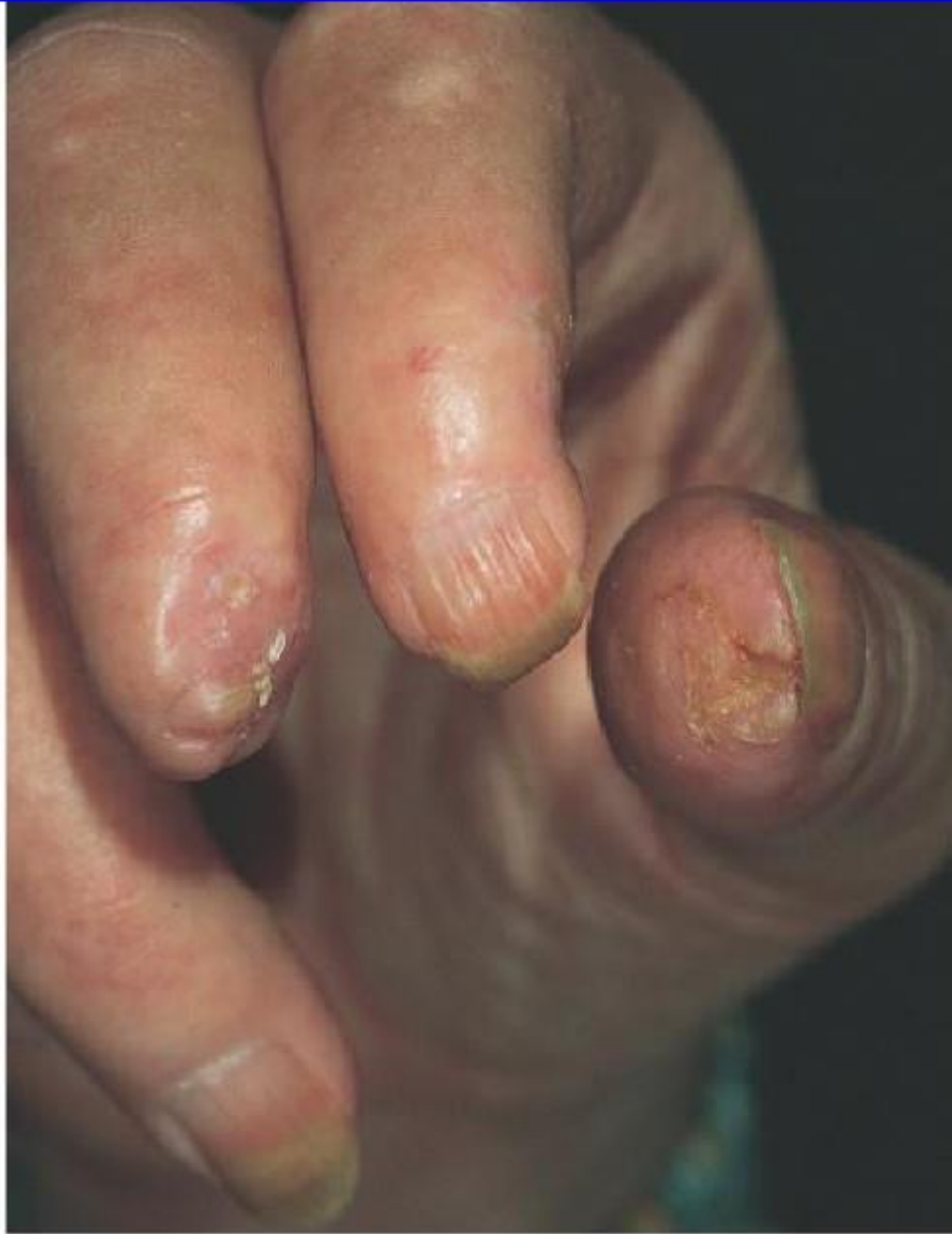© Elsevier 2004. Habif: Clinical Dermatology 4E - www.clinderm.com

Scleroderma (Systemic Sclerosis)

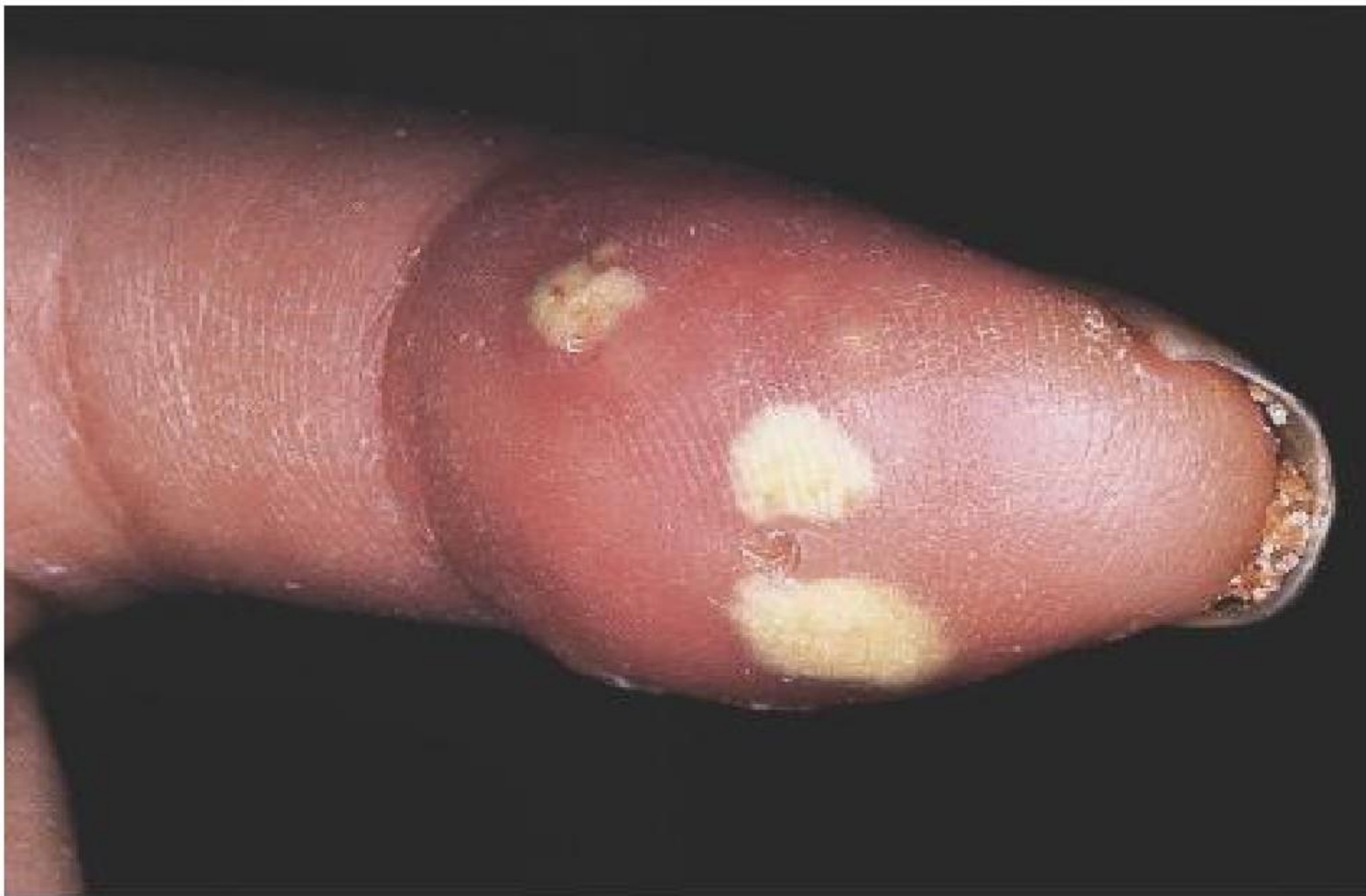- u Thickened & tight skin
- u Sclerodactyl
- u Face: loss of forehead lines
- u beaked nose, small mouth, radial furrowing around the mouth)
- u Telangiectasia and calcification
- u Systemic involvement:
 - v Lung, GI, Kidneys
 - v Positive anti scl-70



© Elsevier 2004, Habif: Clinical Dermatology 4E - www.clinderm.com



© Elsevier 2004. Habif: Clinical Dermatology 4E - www.clinderm.com



2003 Elsevier - Bologna, Jorizzo and Rapini: Dermatology - www.dermtext.com

● CREST (milder variant of scleroderma)

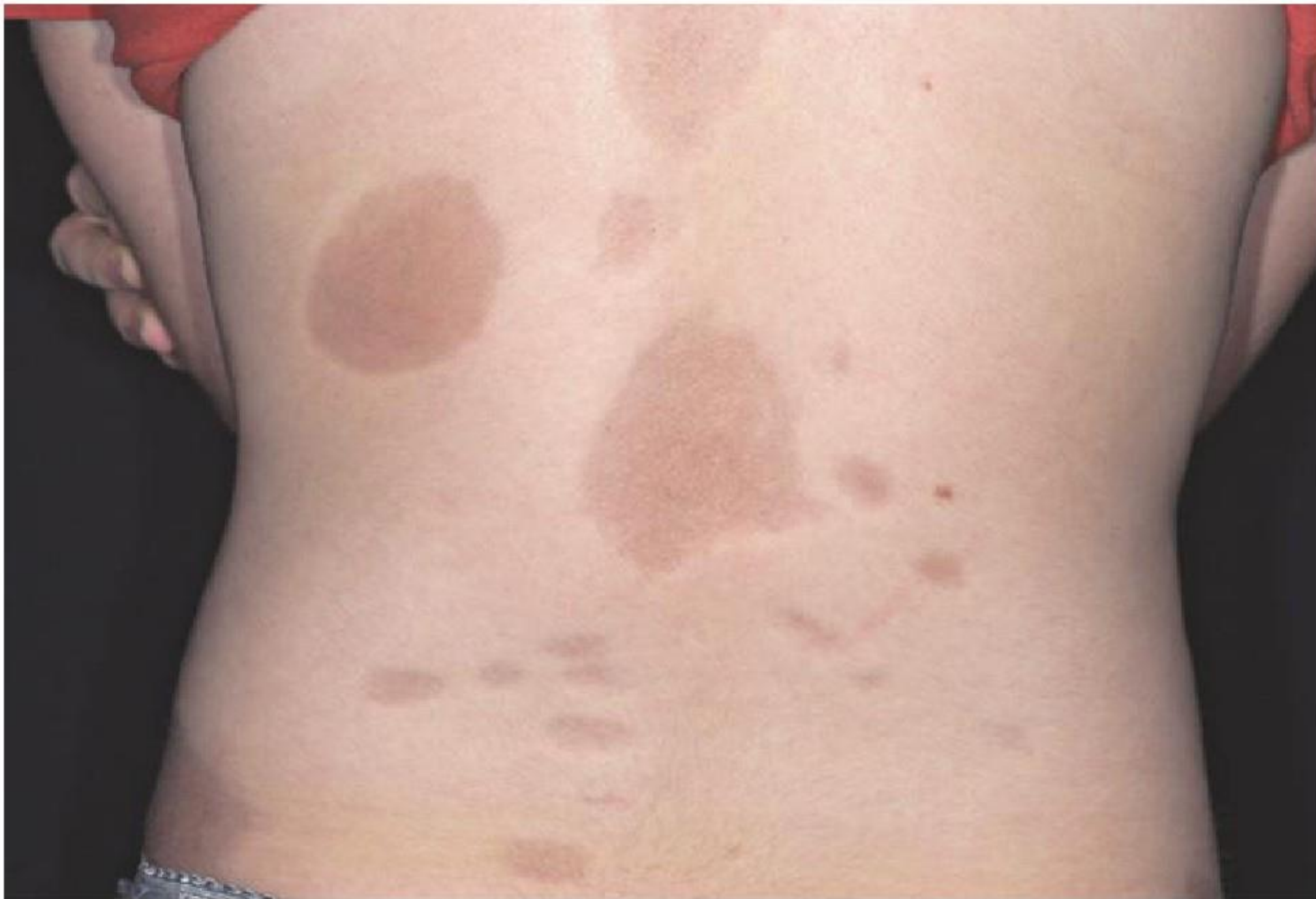- u C=Calcification
- u R =Raynand's
- u E =Eosopheagal dysfunction
- u S= Sclerodactasia
- u T=Telangectasia
- u Positive anti- centromere
- u Less systemic involvement.

● Morphea:

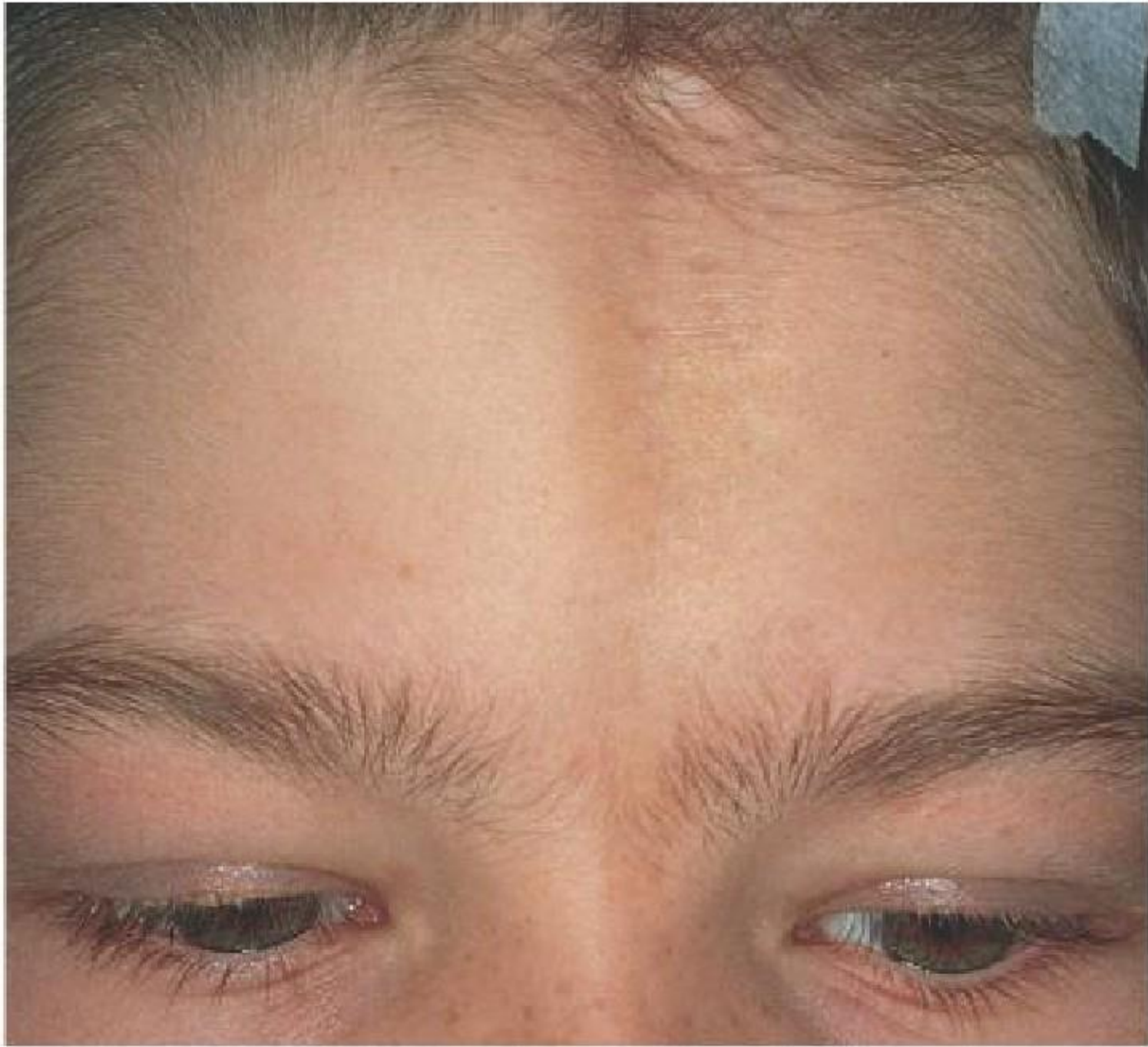- u Localized scleroderma without systemic involvement.
 - v Firm, white patch of skin surrounded by violaceous ring

● En coup de sabre

- u Linear scleroderma on the scalp and face which may give scarring alopecia + it may affect muscle or even bone

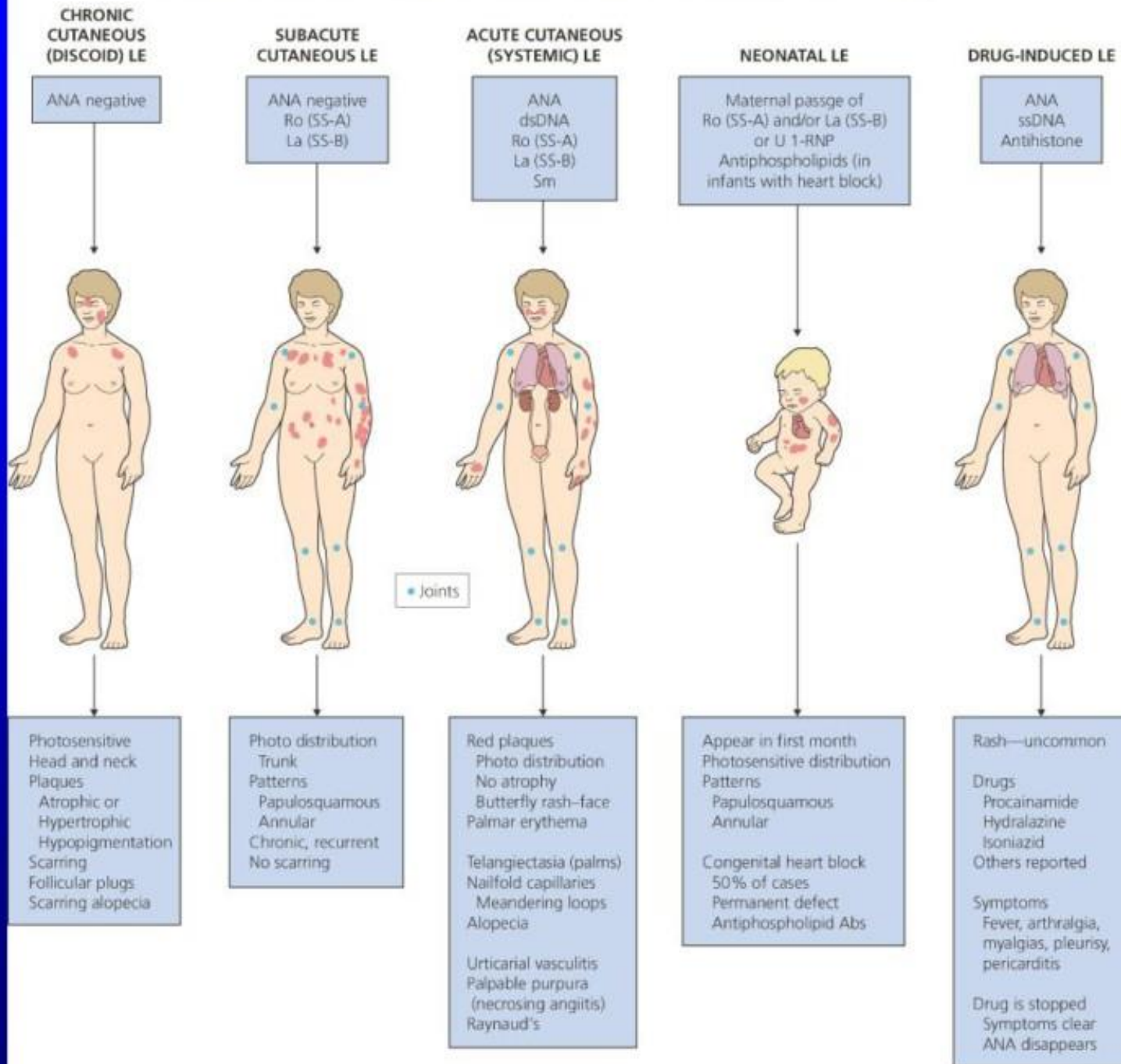


© Elsevier 2004. Habif: Clinical Dermatology 4E - www.clinderm.com



© Elsevier 2004. Habif; Clinical Dermatology 4E - www.clinderm.com

OVERVIEW OF LUPUS SYNDROMES: AUTOANTIBODY PROFILES AND CUTANEOUS MANIFESTATIONS



Antibody testing for CTD (table)

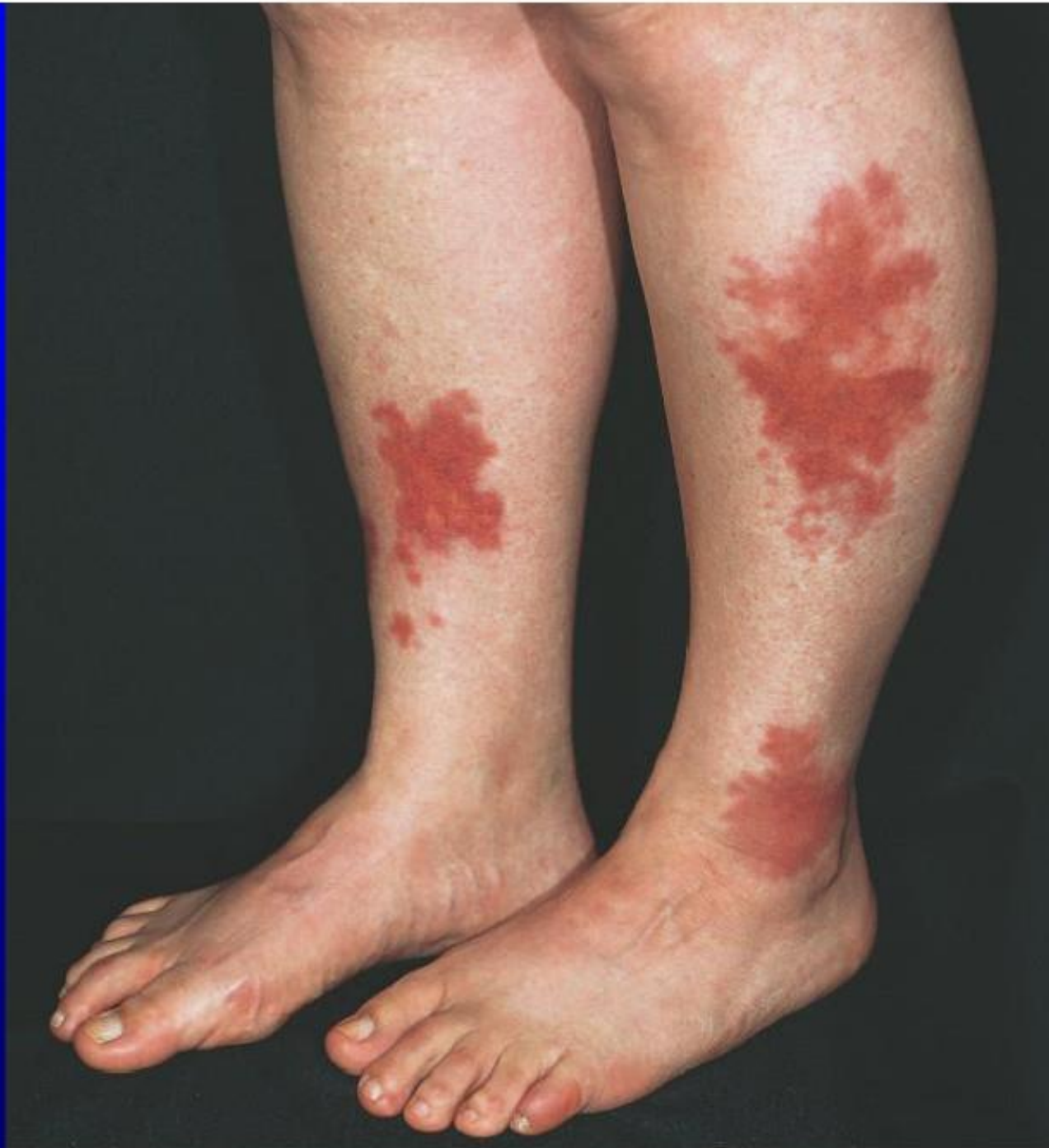Antibody	Clinical significance
ANA	Screening for SLE and other CTD
Anti-Centromere	Marker for CREST
Anti-histone	Marker for Drug-Induced Lupus
Anti-Smith	Specific for SLE
Anti - RNP	For MCTD
Anti - Ro	Neonatal Lupus, SCLE
Scl - 70 antibody	For Scleroderma
Anti ds- DNA	For SLE

Endocrine :

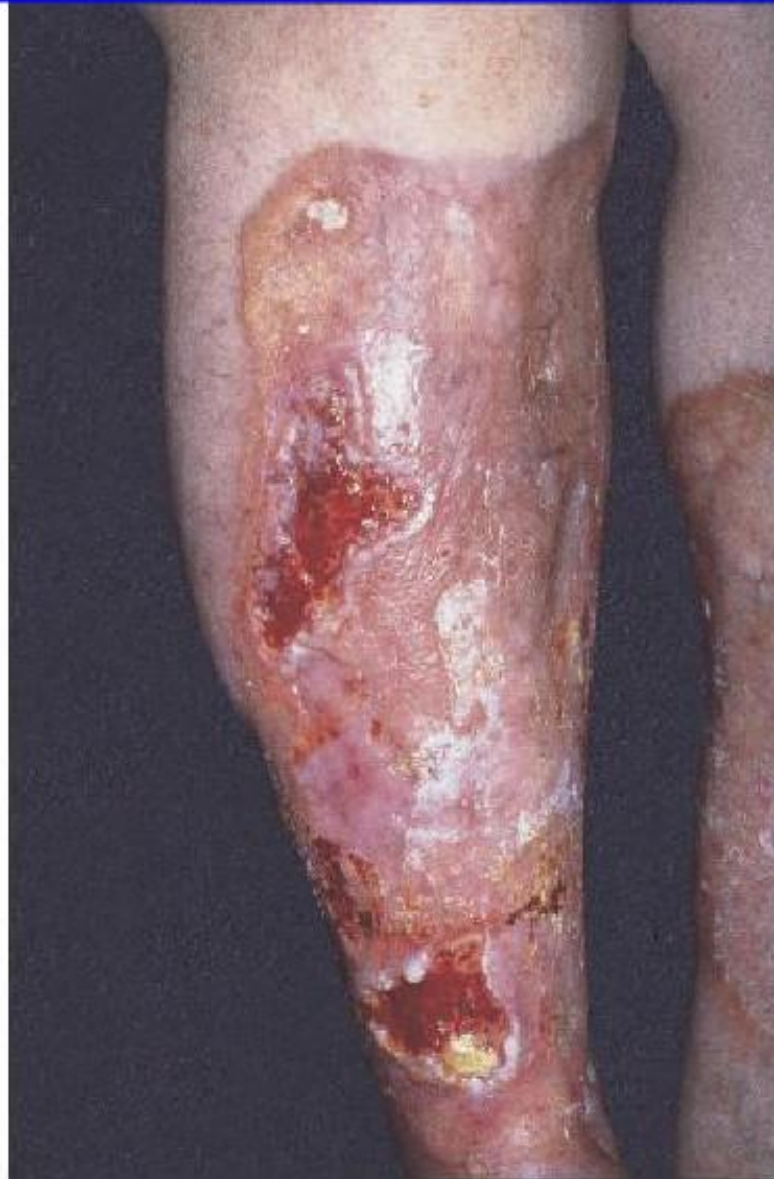u Diabetes

- ✓ Necrobiosis Lipoidica diabetorum (NLD) :Asymptomatic
- ✓ Usually seen on the shins
- ✓ May predate frank development of diabetes by several years
- ✓ Shiny atrophic red or yellowish plaques with telangiectasia over their surface + ulceration
- ✓ Severity of NLD is not directly related to severity of diabetes.

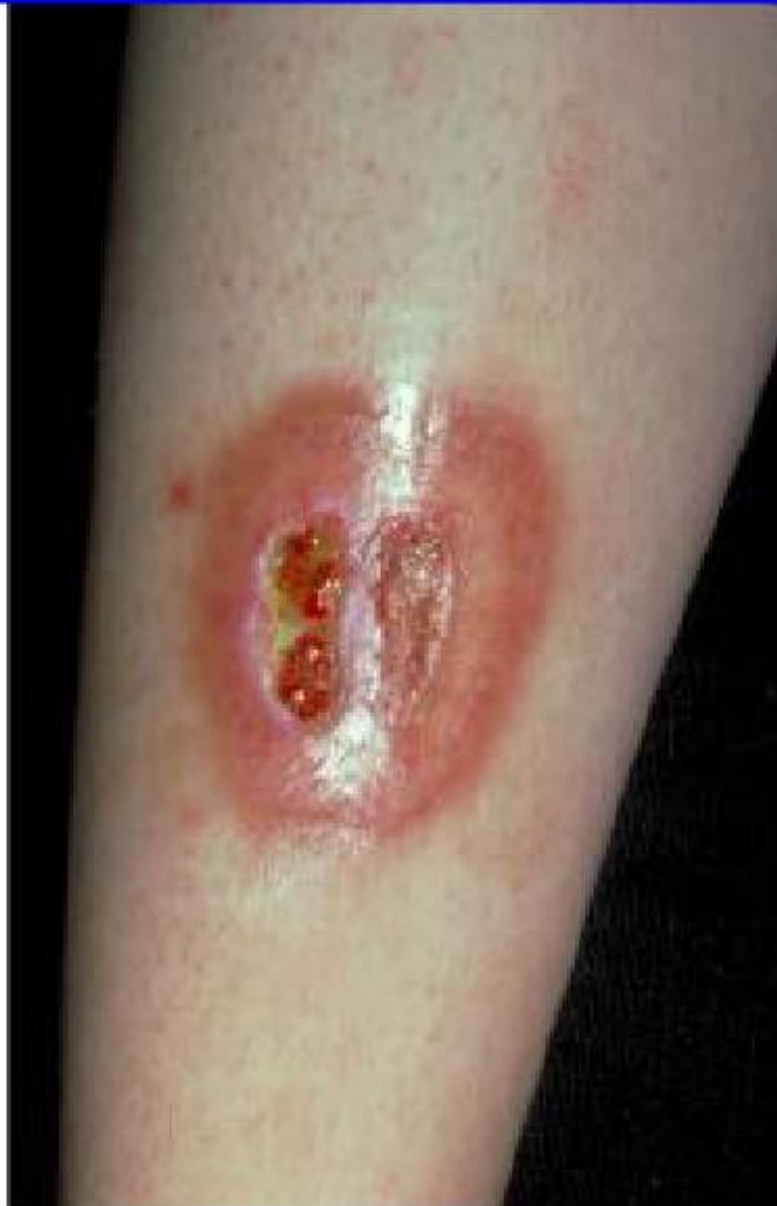**Increased risk of fungal and bacterial infection*



© Elsevier 2004. Habif: Clinical Dermatology 4E - www.clinderm.com



© 2003 Elsevier - Bologna, Jorizzo and Rapini: Dermatology - www.dermtext.com



© Elsevier 2004. Habif: Clinical Dermatology 4E - www.clinderm.com

● Hyperthyrodism:

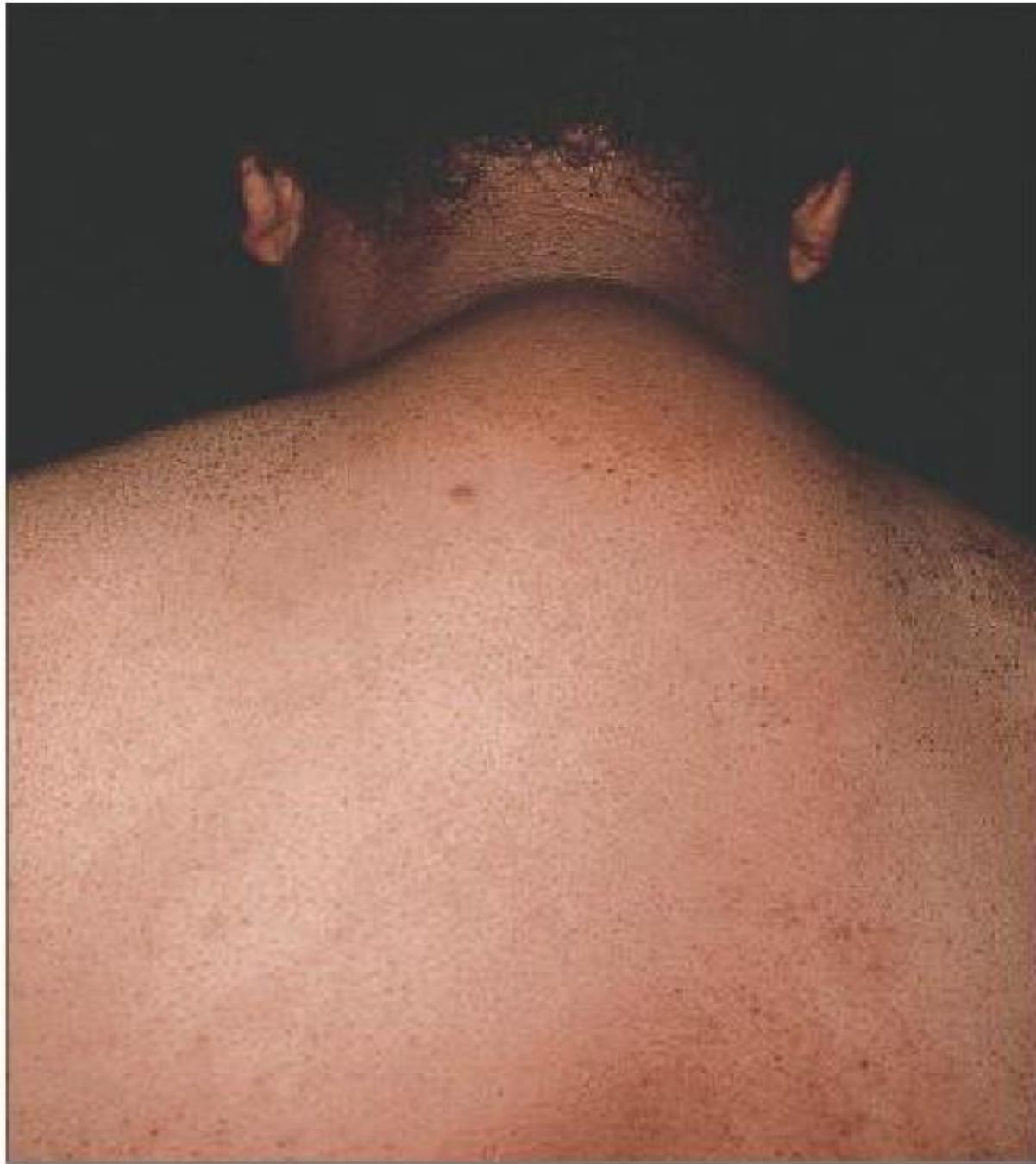- u Smooth, warm, moist (due to increase sweating) skin
- u Peritibial myxedema (asymptomatic red plaques over shins)
- u Thin & fine hair
- u Onycholysis
- u Clubbing.

● Hypothyrodism

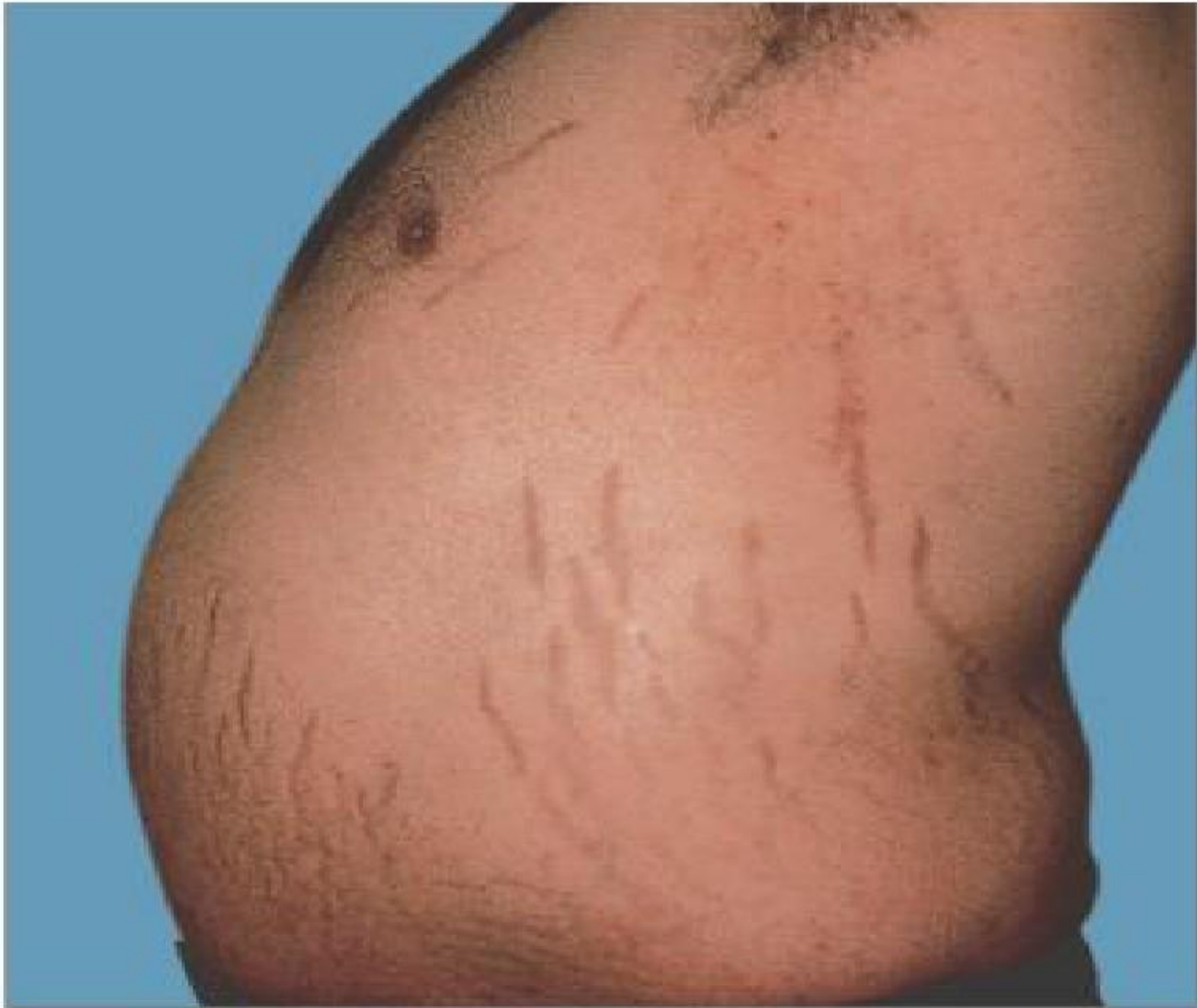- u Dry, cold, skin
- u Edematous skin (myxedema)
- u Hair loss of lateral third of eyebrows
- u Brittle hair or nails

Cushing's Syndrome:

- u Rounded face with fullness of cheeks (Moon face)
- u Buffalo hump (fat deposit over upper back)
- u Central obesity with thin arms & legs & “lemon with sticks”
- u Atrophy of skin
- u Striae
- u Purpura
- u Hirsutism
- u Acne



© 2003 Elsevier - Bologna, Jorizzo and Rapini: Dermatology - www.dermtext.com

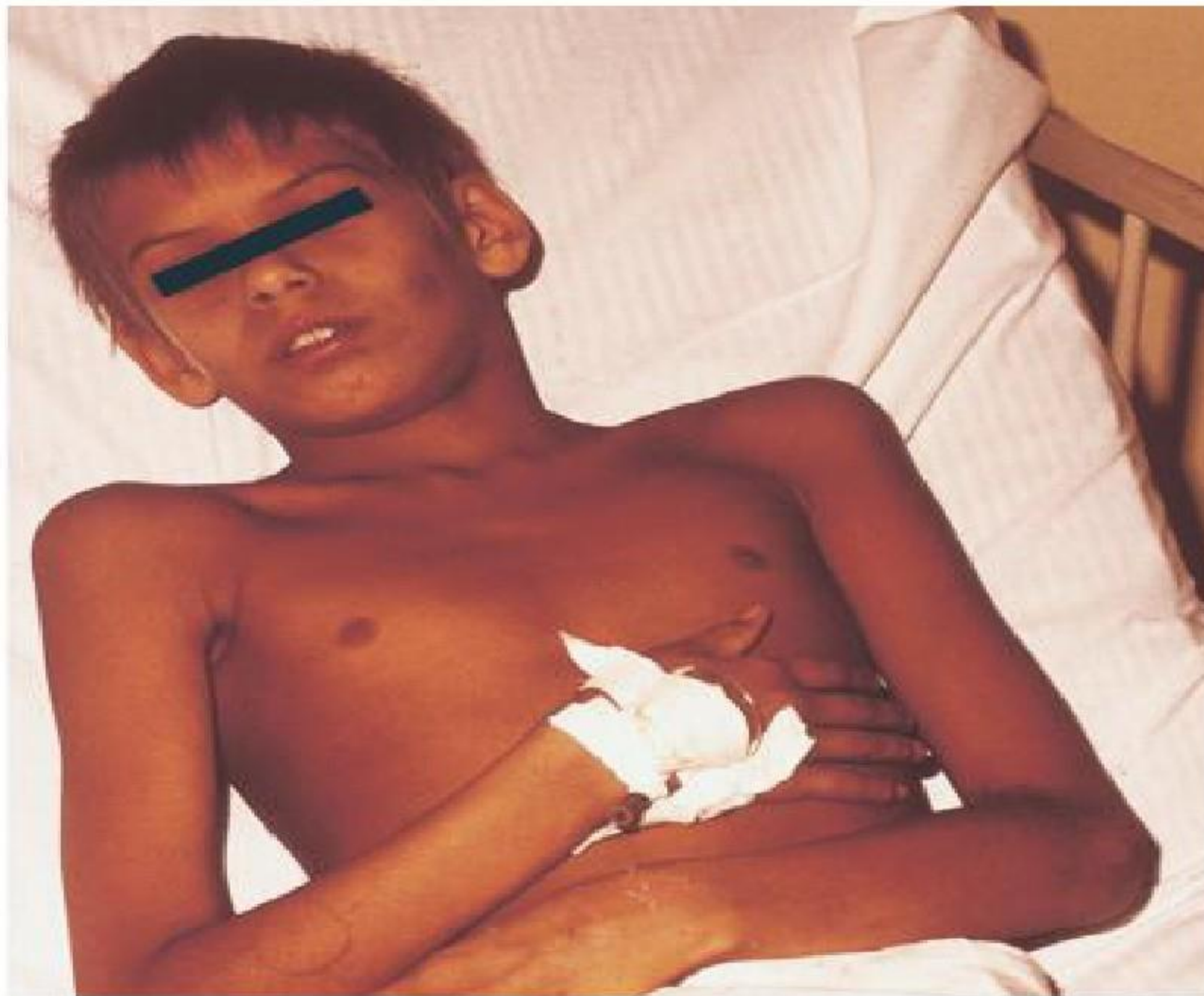

2003 Elsevier - Bologna, Jorizzo and Rapini: Dermatology - www.dermtext.com

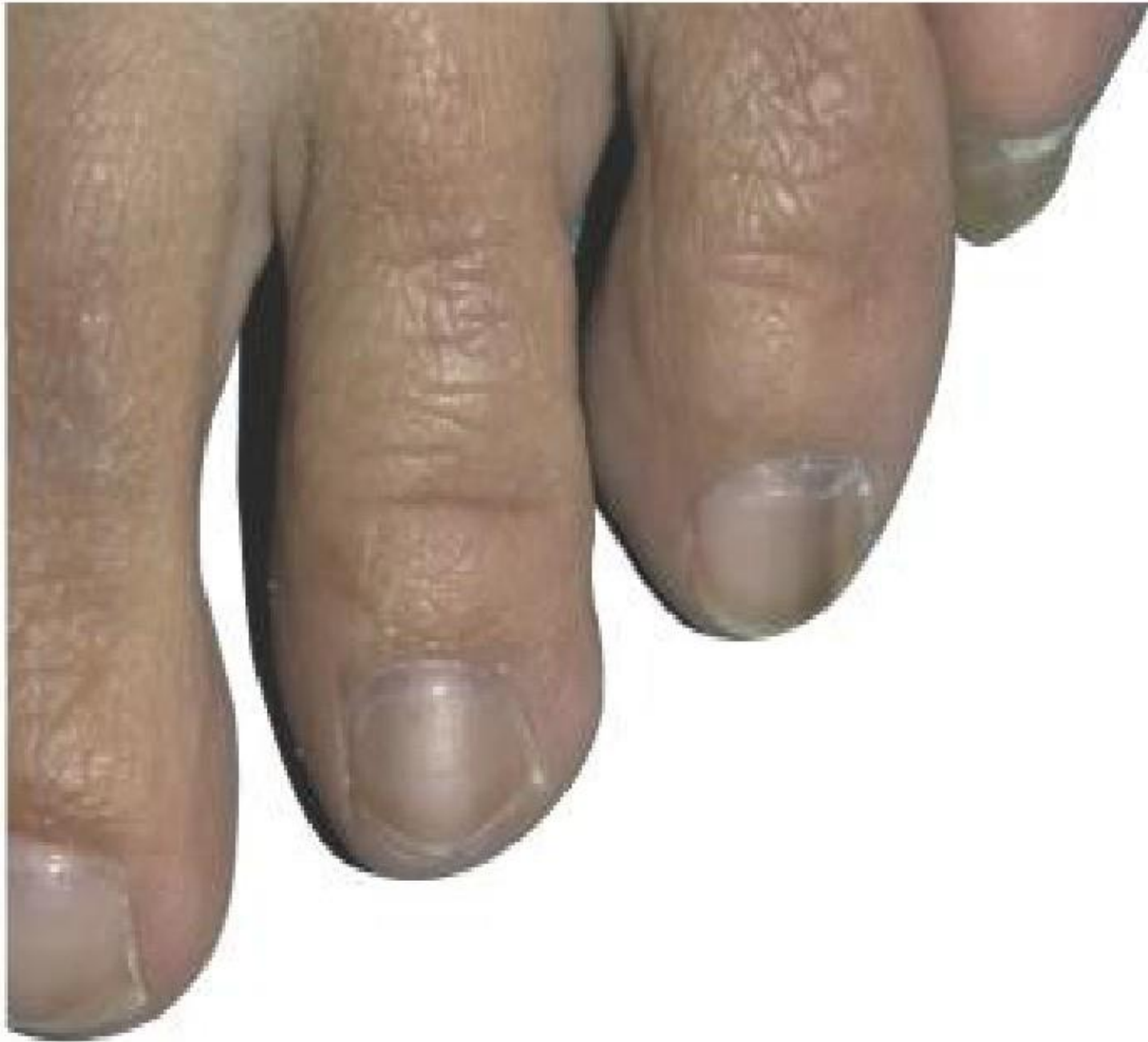■ Addison's disease:

■ Hyperpigmentation:

■ at Sun exposed skin, sites of trauma, axillae, palmar creases, old scars ,nevi and mucous membranes



Copyright © 2003 Elsevier - Pediatric Dermatology 3E, edited by Schachner, Hansen et al. All rights reserved.



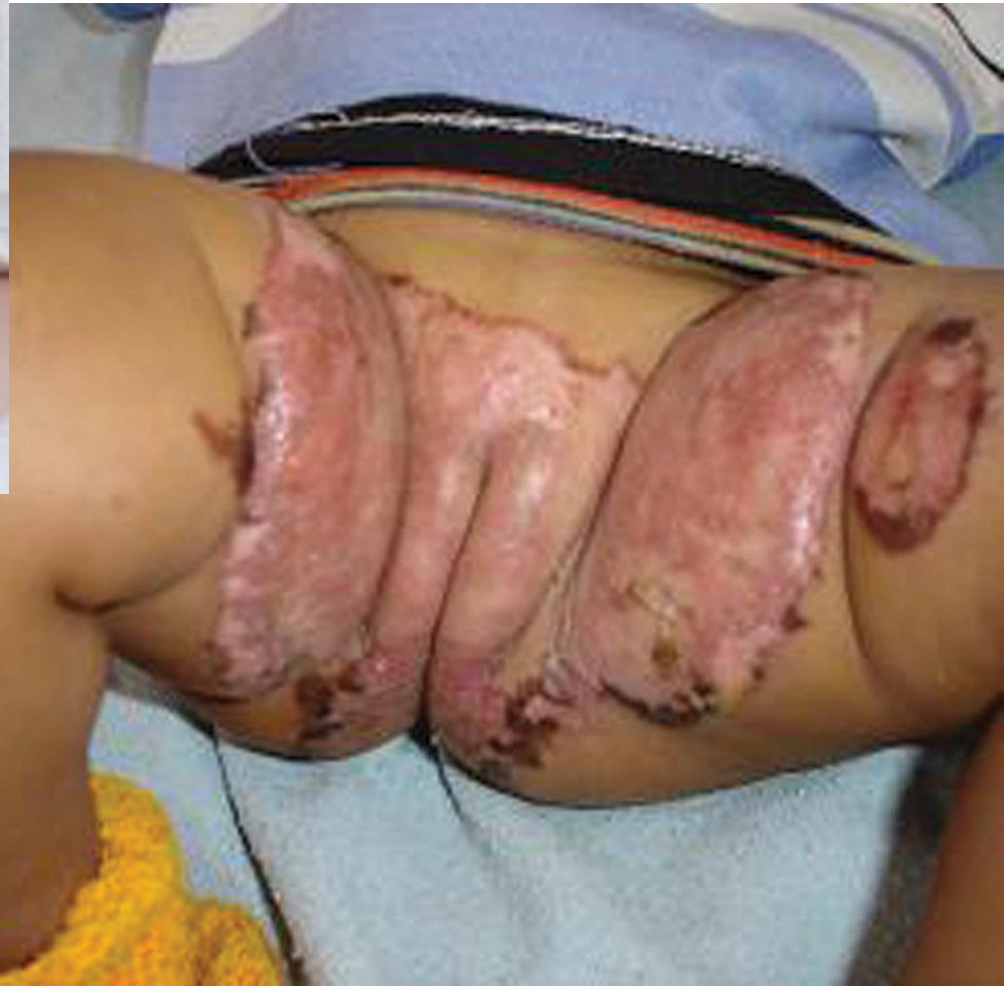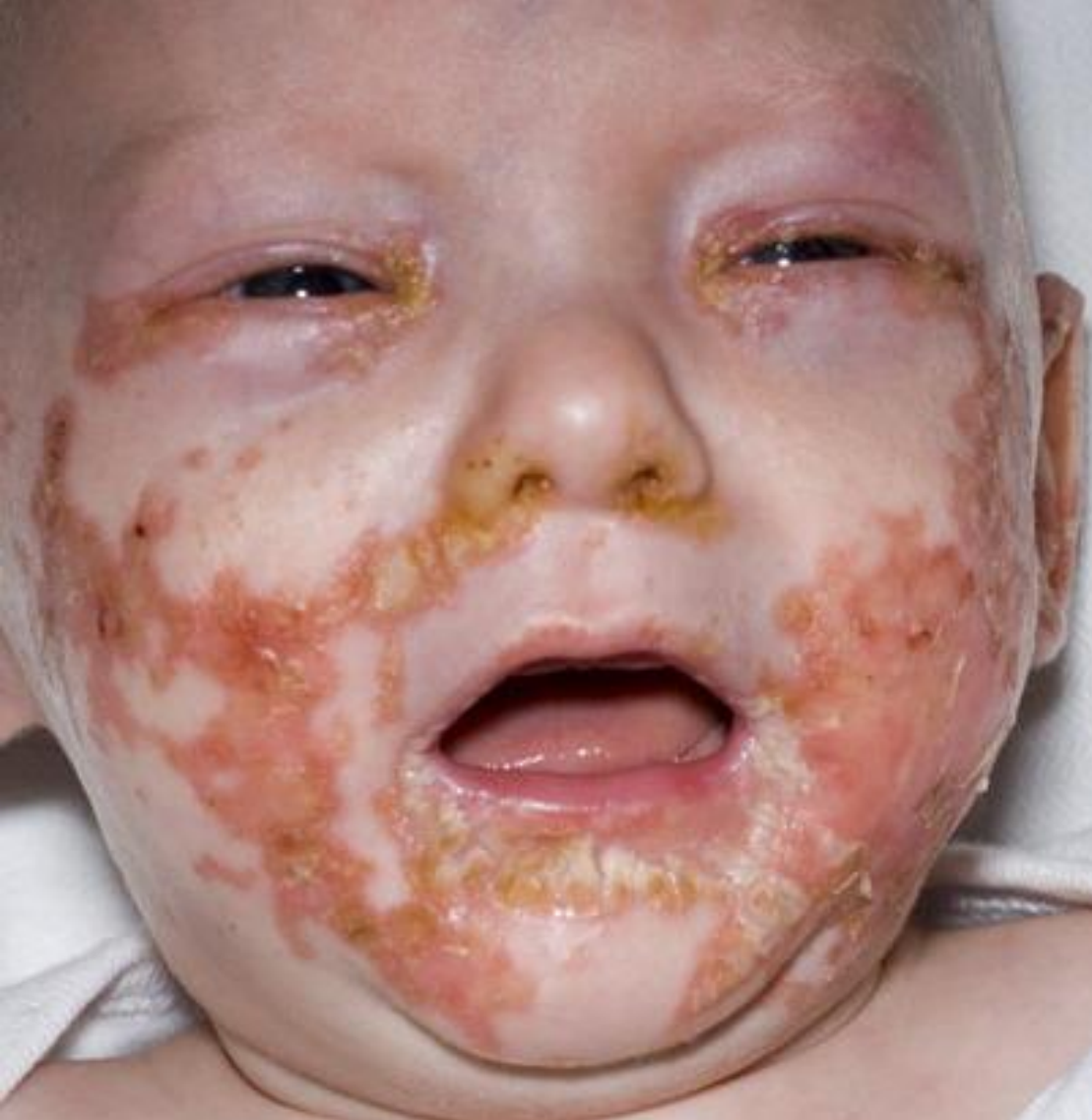GIT

Chronic Liver Disease

- u Jaundice
- u Spider telangectasia
- u Acne
- u Gynecomastia
- u Purpura
- u Collateral veins
- u Striae
- u Palmer erythema
- u Dupuytren's contracture
- u White nails.

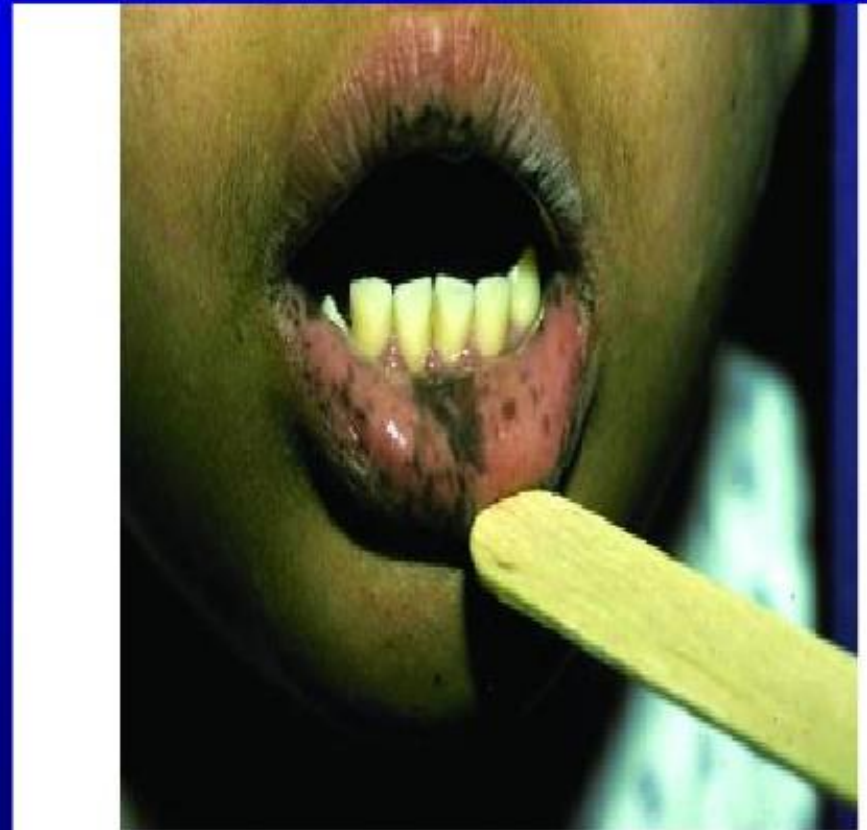Acrodermatitis enteropathica (genetic disease)

- u Due to zinc deficiency
- u Seen in infants as erythematous erosive rash around orifices (mouth, ears, anus) also on hands & feet.
- u Alopecia and nail dystrophy
- u Diarrhea or abdominal pain.

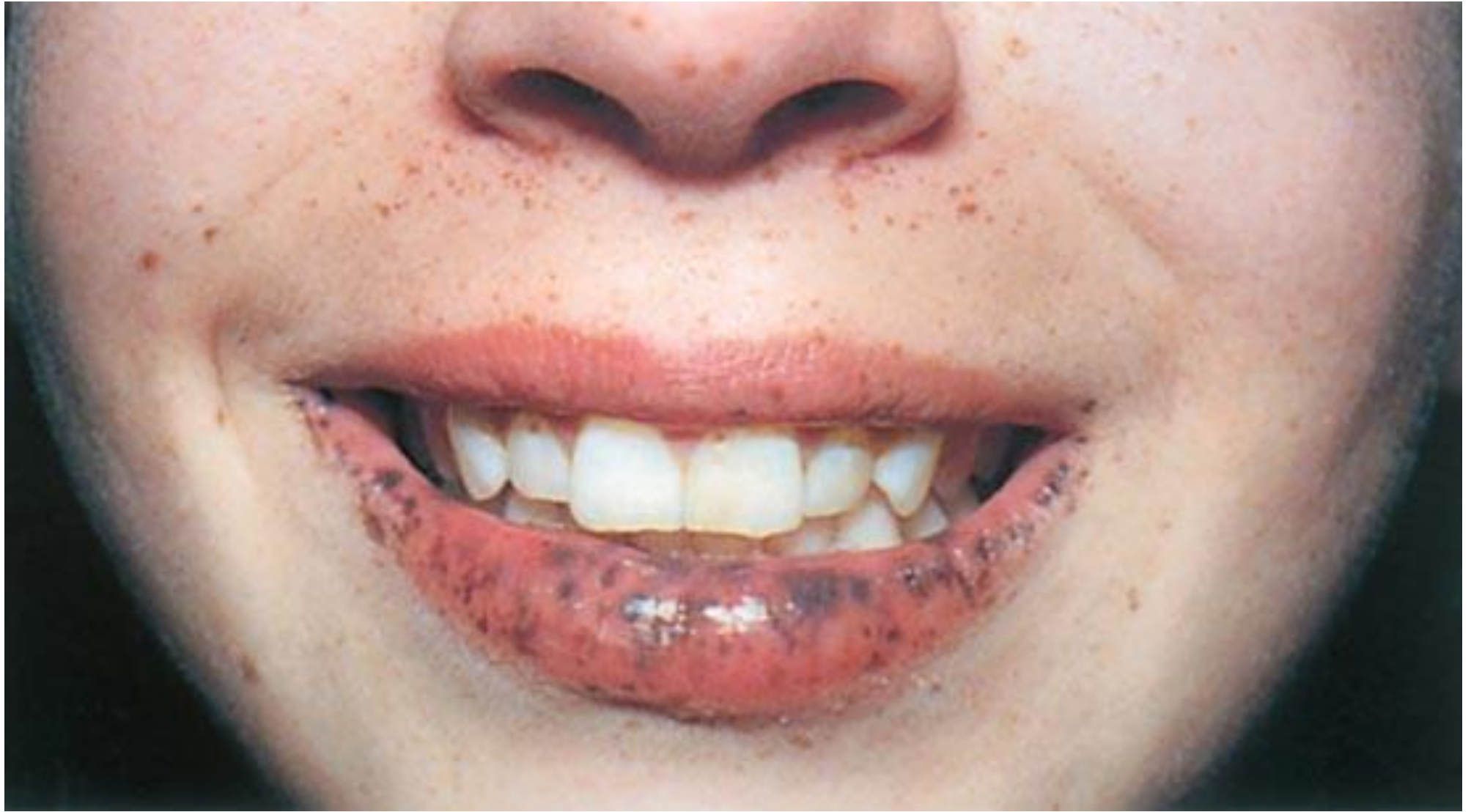

Peutz-Jeghers Syndrome

- u Small brown macules on lips, buccal mucosa and small intestinal polyps
- u rarely polyps can be premalignant.

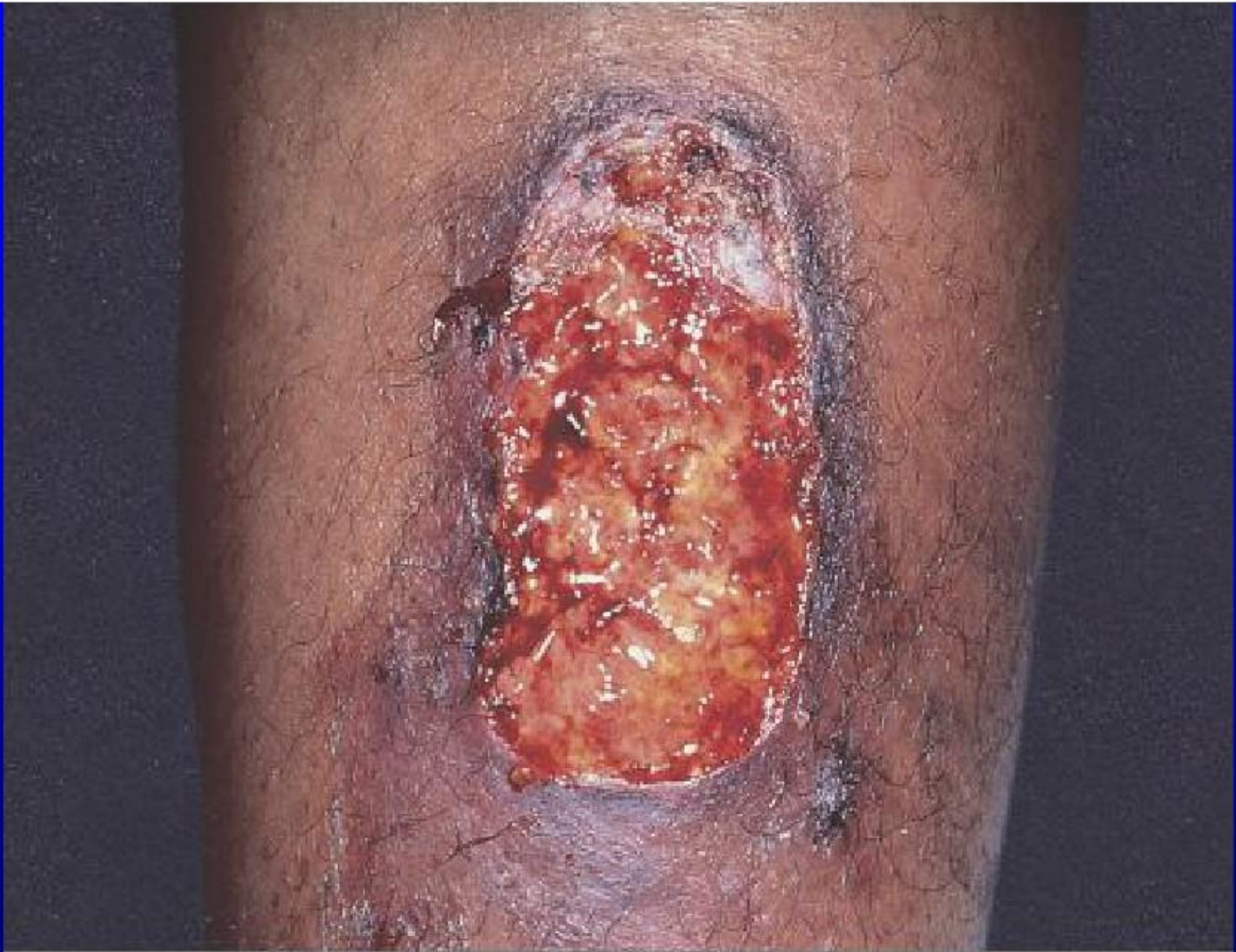

Copyright © 2003 Elsevier - Pediatric Dermatology 3E, edited by Schachner, Hansen et al. All rights reserved.



Pyoderma Gangrenosum:

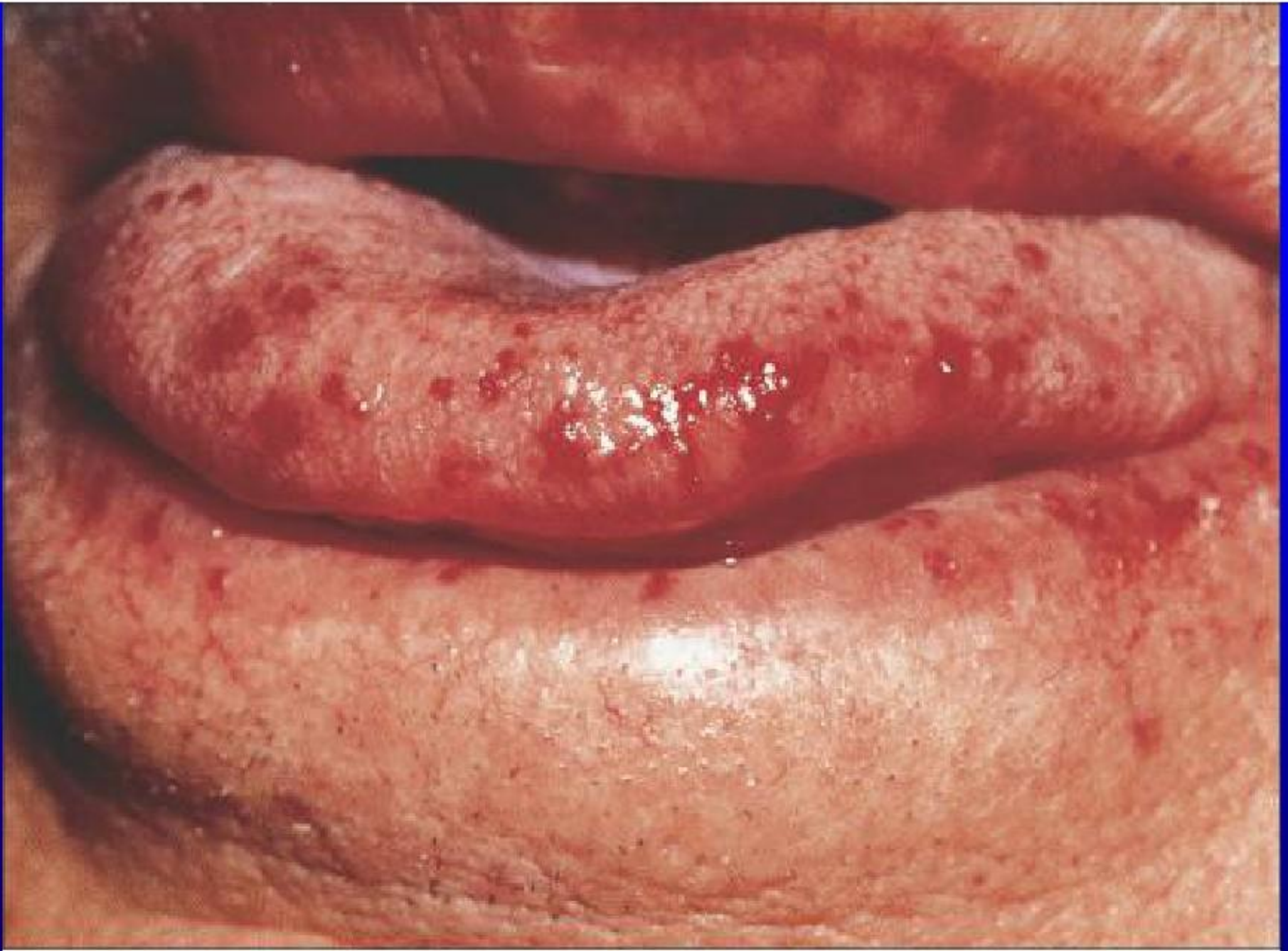- u Acute painful leg ulceration, surrounded by violaceous border
- u Associated with inflammatory bowel disease
- u Other associations; Rheumatoid Arthritis and leukemia



© 2003 Elsevier - Bologna, Jorizzo and Rapini: Dermatology - www.dermtext.com

● Hereditary haemorrhagic Telangiectasia

- u Telangiectasia (dilated capillaries) over lip, nose, tongue, fingers and toes.
- u Hx of recurrent epistaxis
- u Associated with recurrent upper GI bleed



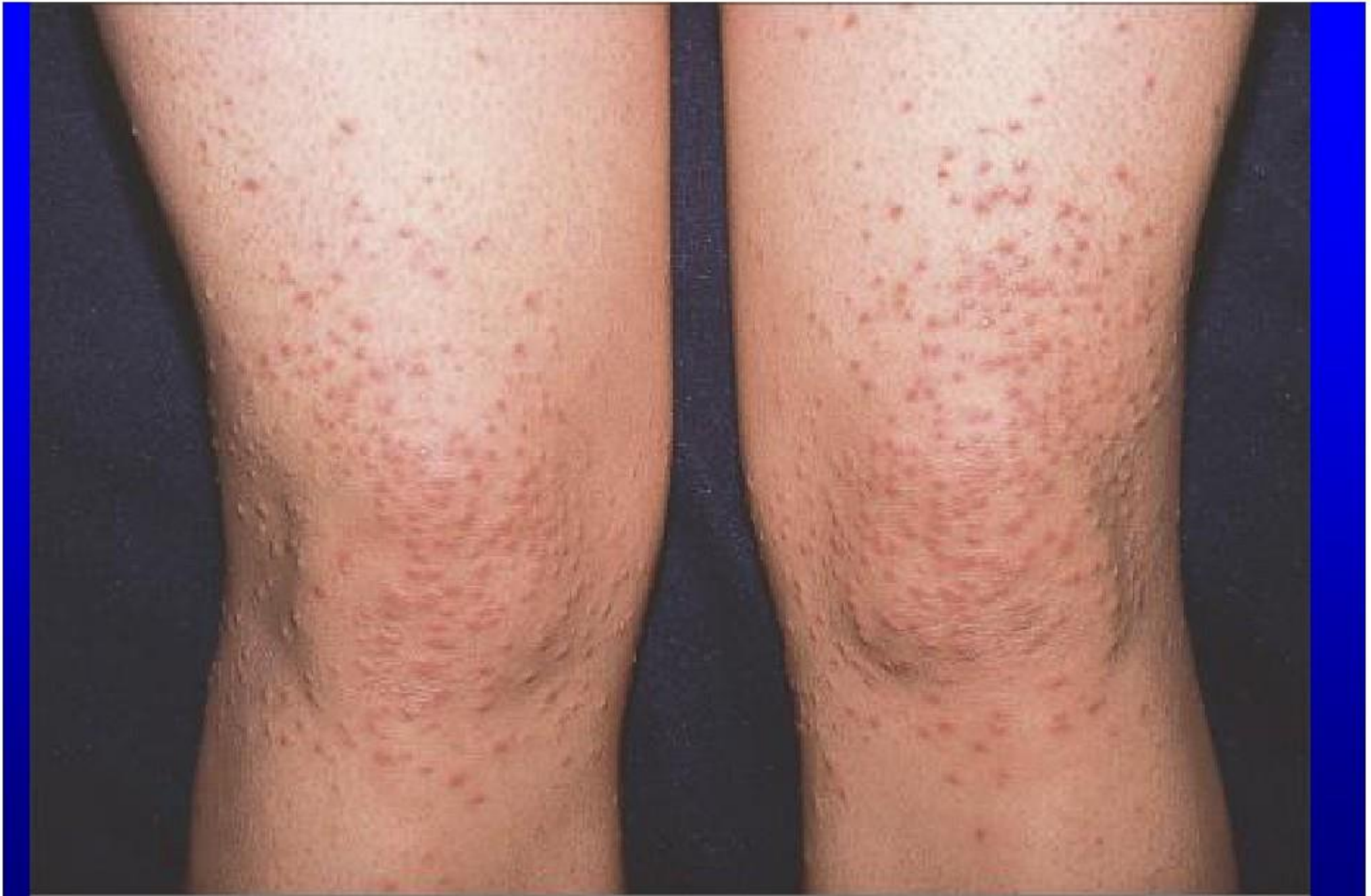© 2003 Elsevier - Bologna, Jorizzo and Rapini: Dermatology - www.dermtext.com

Hyperlipidemia:

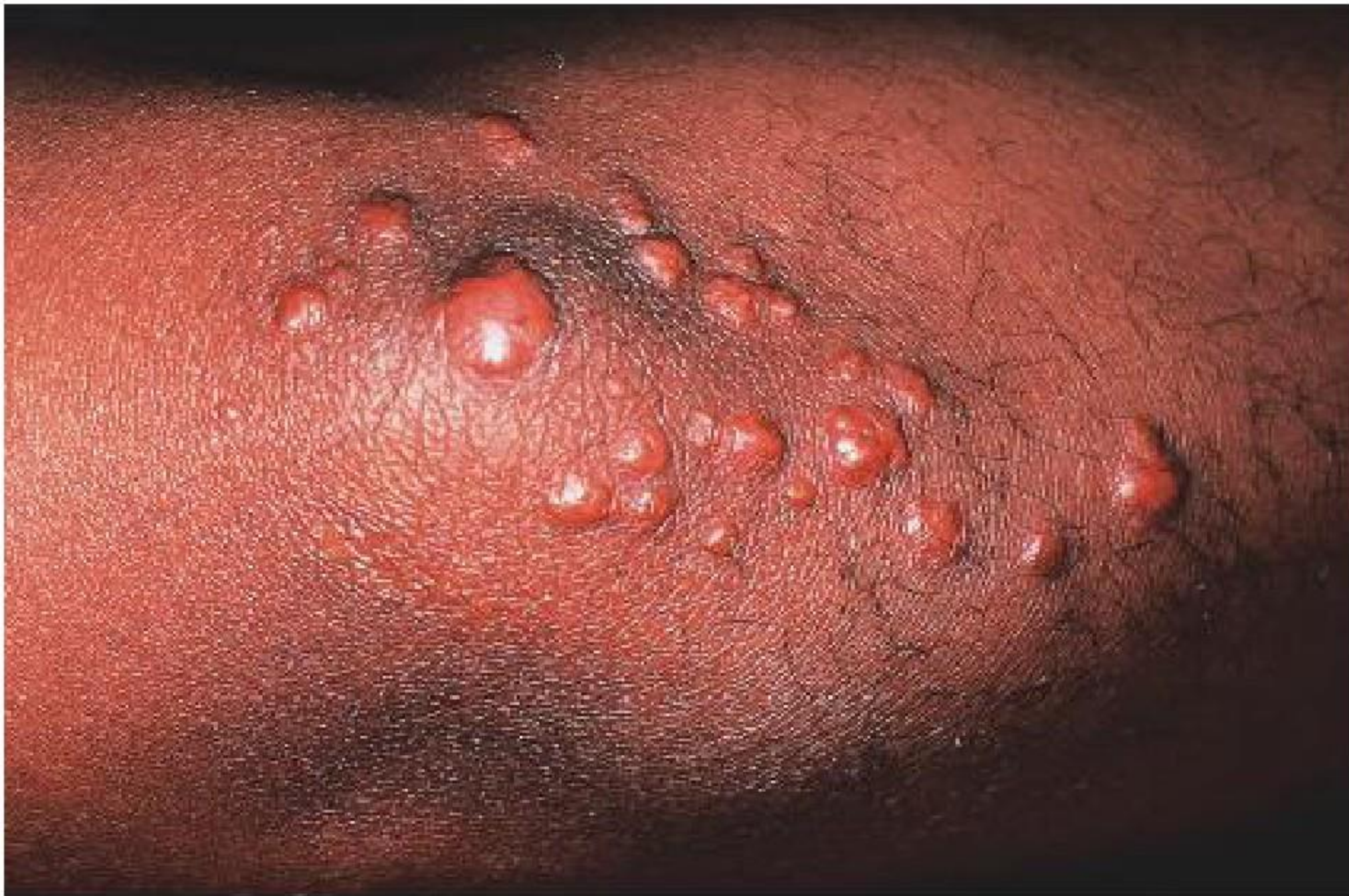- u Present with different types of xanthomas
- u Yellow color is characteristic

● Types of Xanthomas

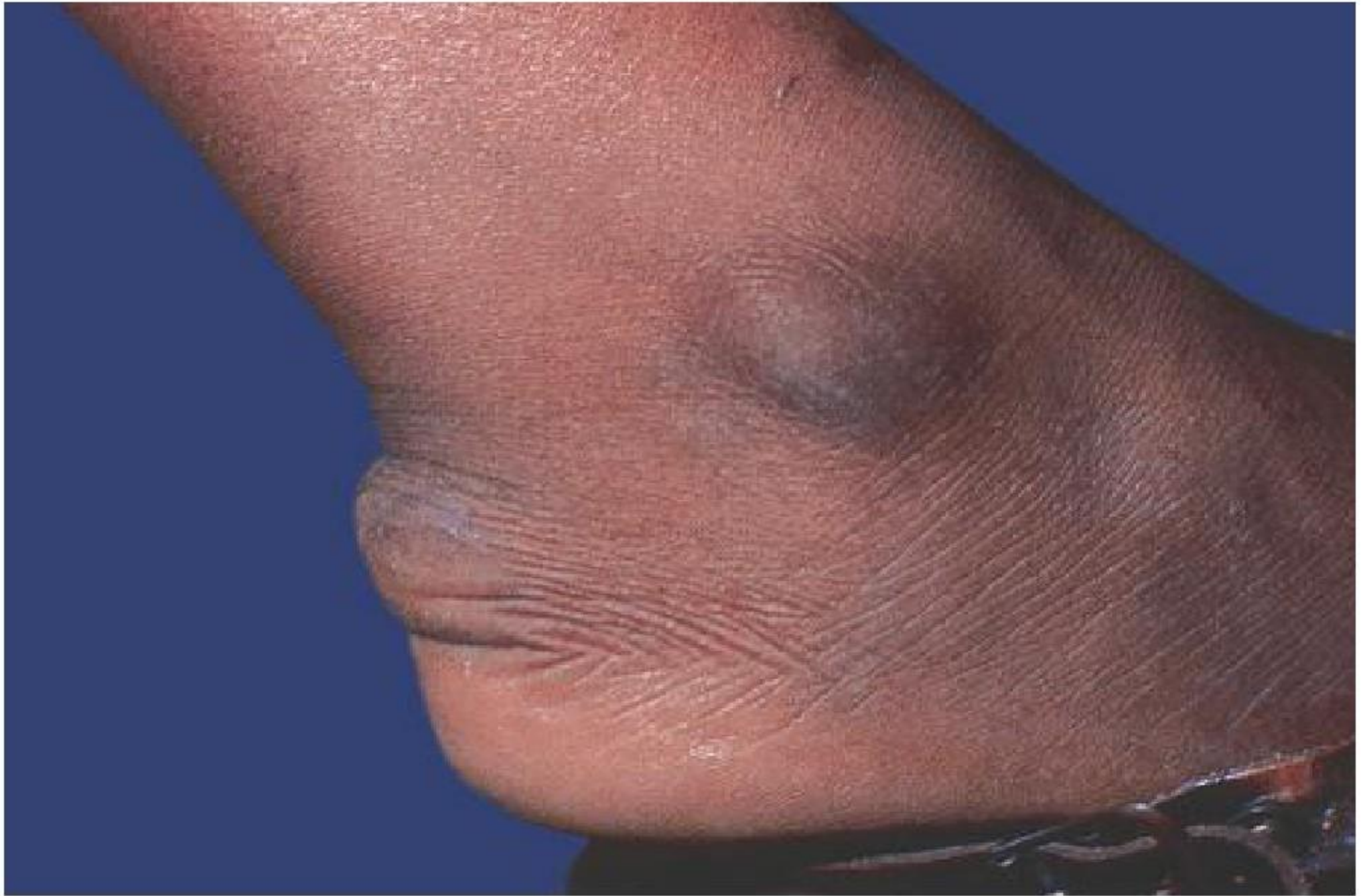- u **Eruptive:** small papules appear in crops over buttocks & extensors
- u **Tendinous:** Nodules over tendons e.g. extensor tendons of hands & feet and Achilles tendon.
- u **Palmar crease** xanthoma: on palms
- u **Tuberous:** Papules & nodules over knees and elbows
- u **Xanthelasma:** Bilateral symmetrical over both eyelids.



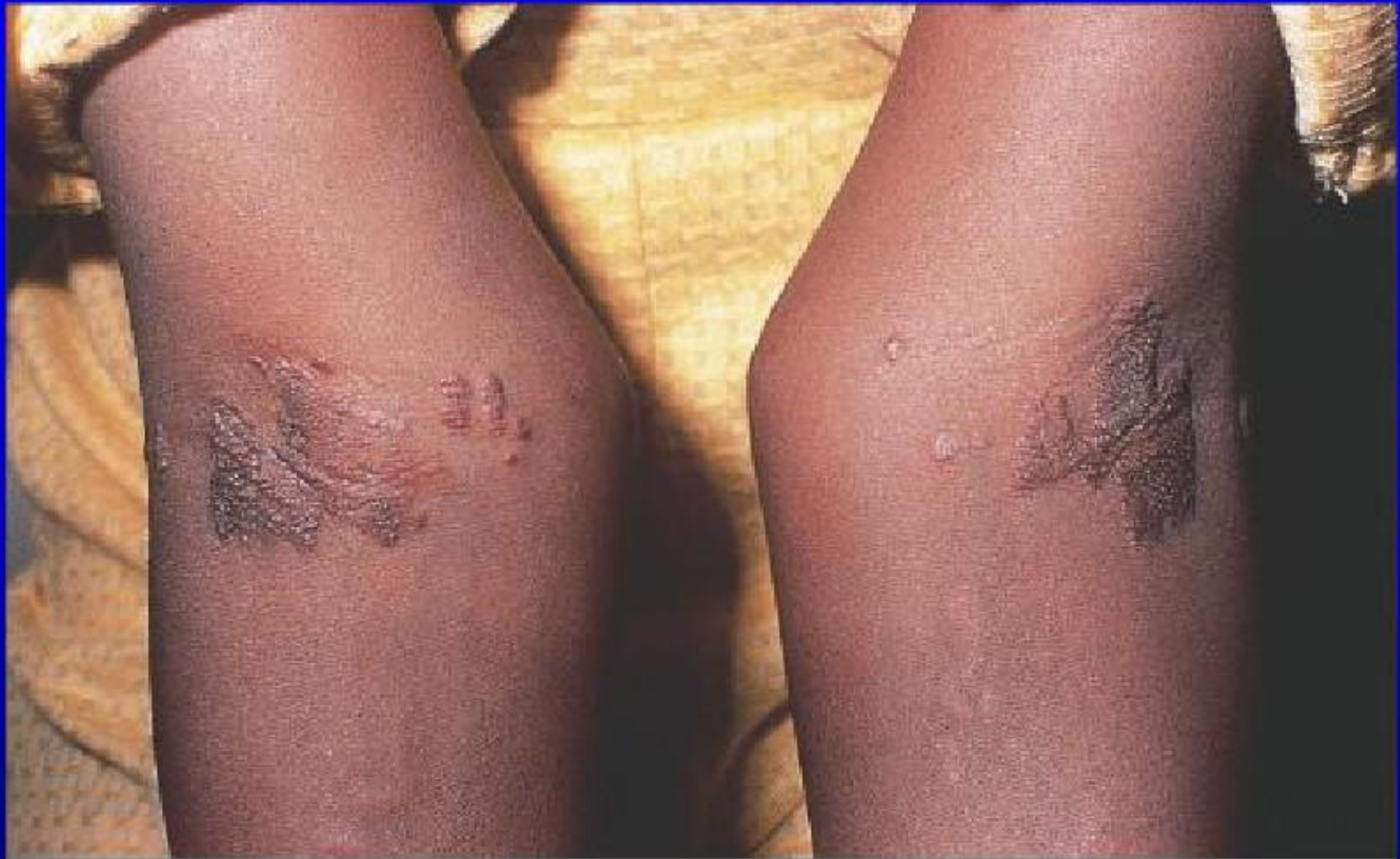© 2003 Elsevier - Bologna, Jorizzo and Rapini: Dermatology - www.dermtext.com



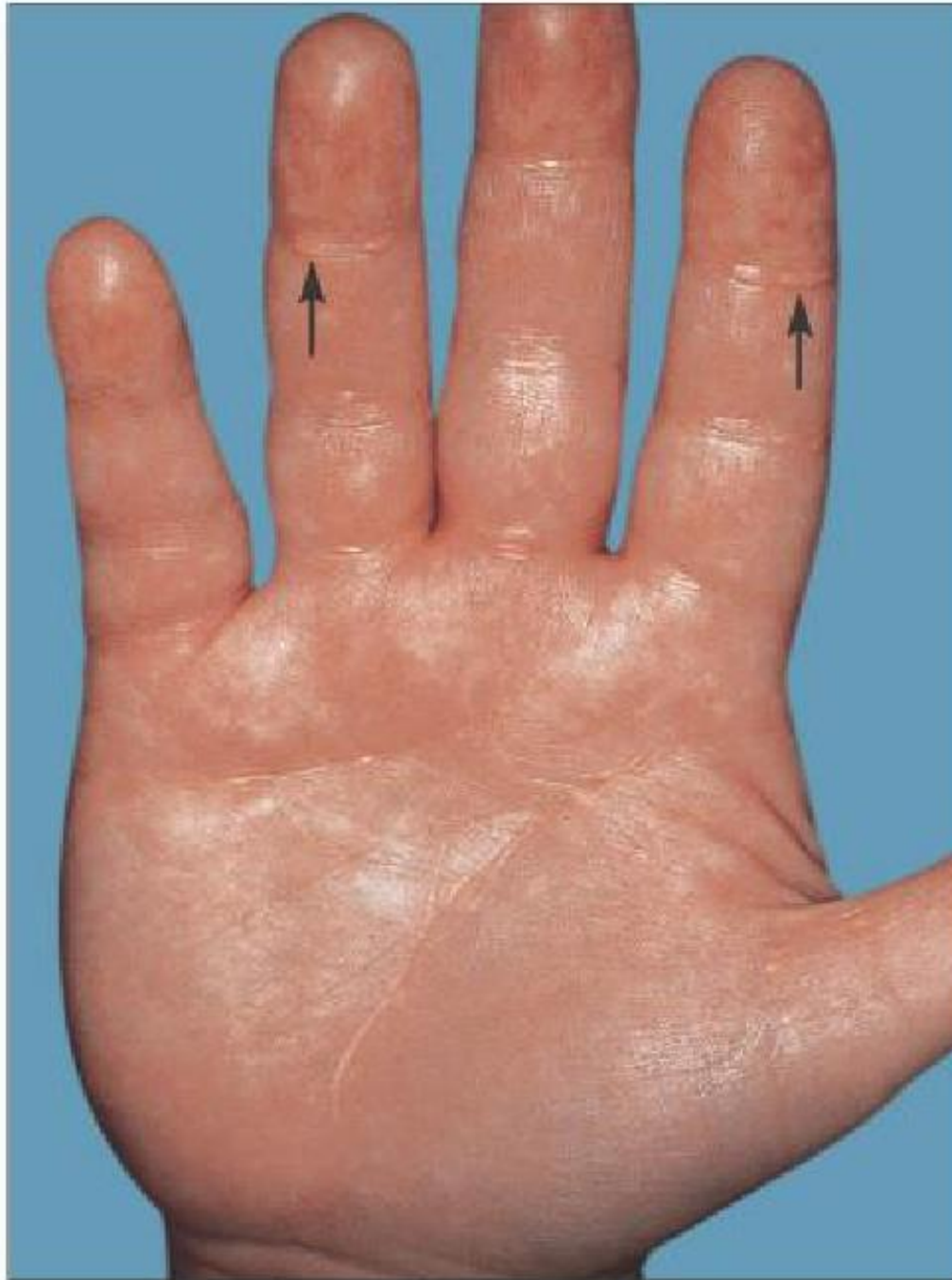© 2003 Elsevier - Bologna, Jorizzo and Rapini: Dermatology - www.dermtext.com



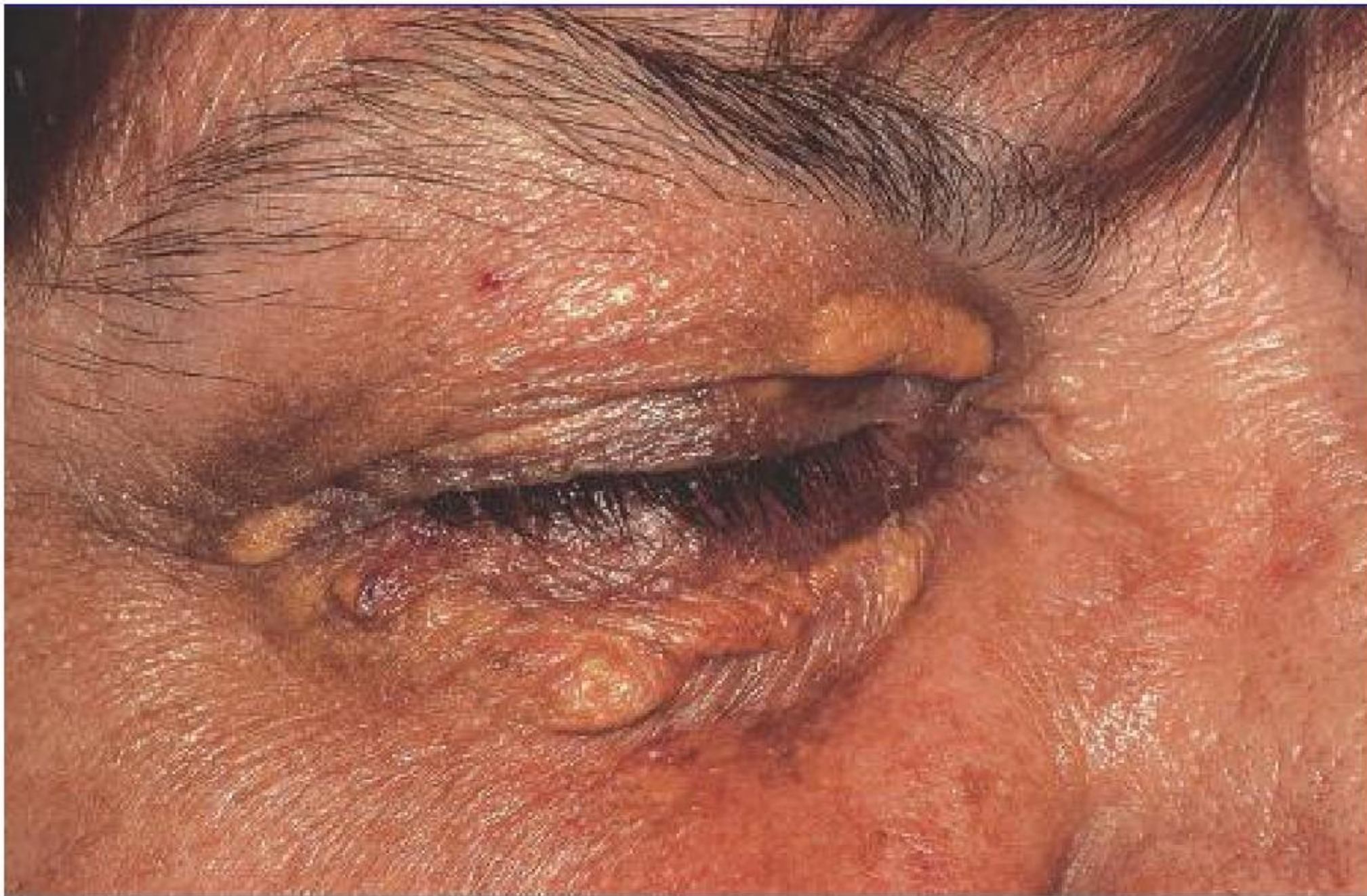© 2003 Elsevier - Bologna, Jorizzo and Rapini: Dermatology - www.dermtext.com



© 2003 Elsevier - Bologna, Jorizzo and Rapini: Dermatology - www.dermtext.com



© 2003 Elsevier - Bologna, Jorizzo and Rapini: Dermatology - www.dermtext.com



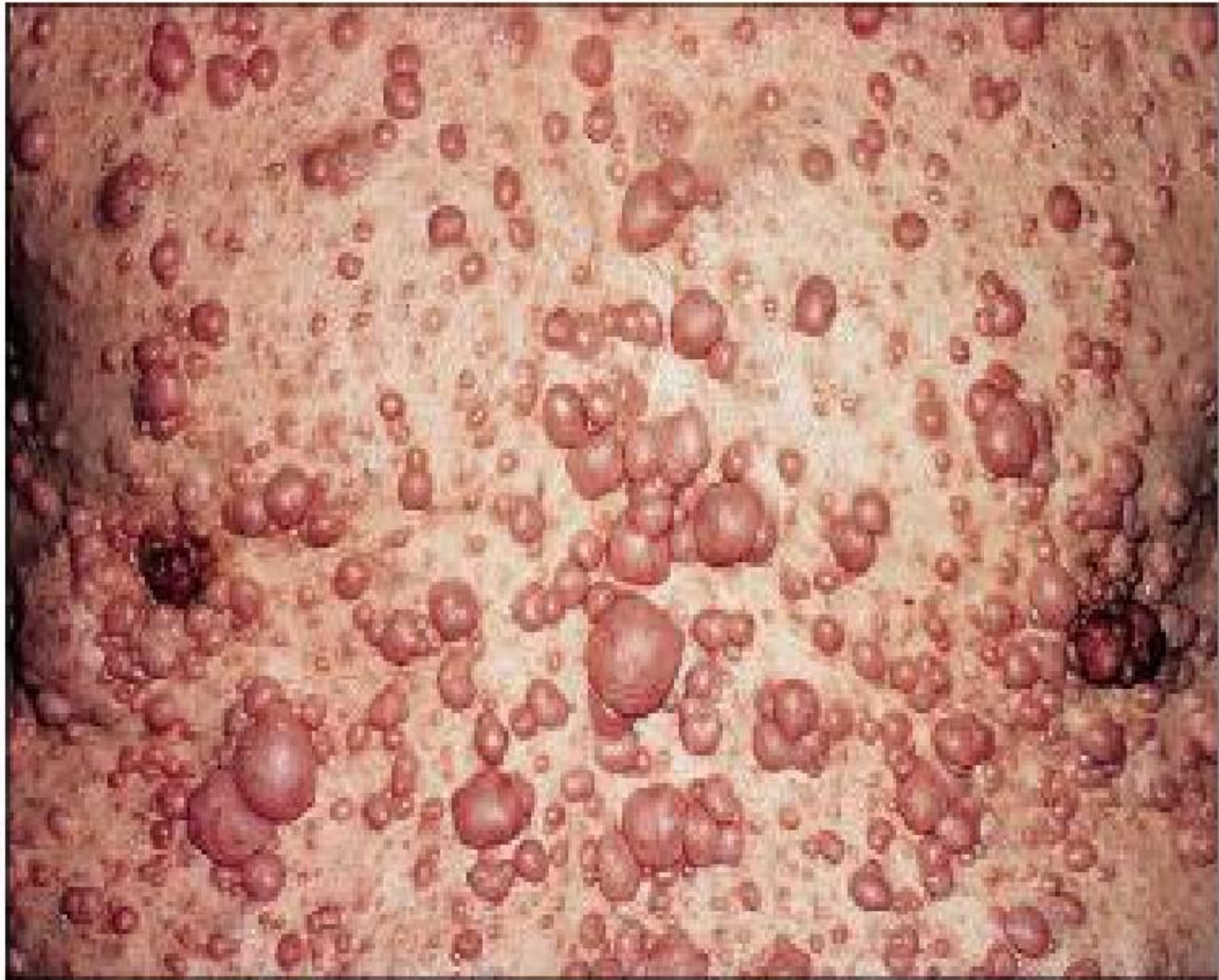
● Xanthoma may be a pointer to:

- u Primary hyperlipemic status due to genetic abnormality
- u Secondary hyperlipemic status due to renal, hepatic, endocrine or pancreatic disease
- u Normo-lipemic status.

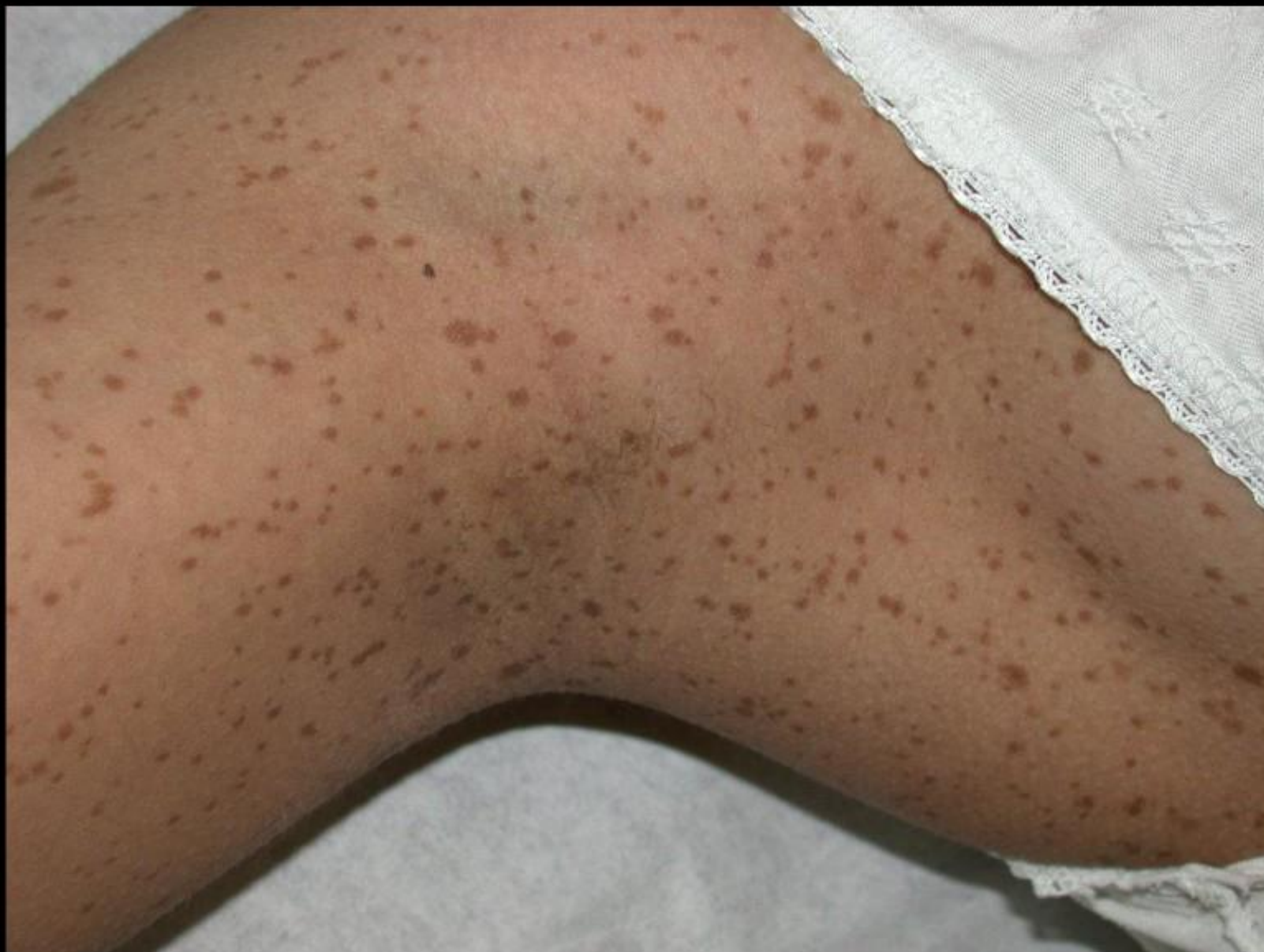Neurocutaneous Disorders

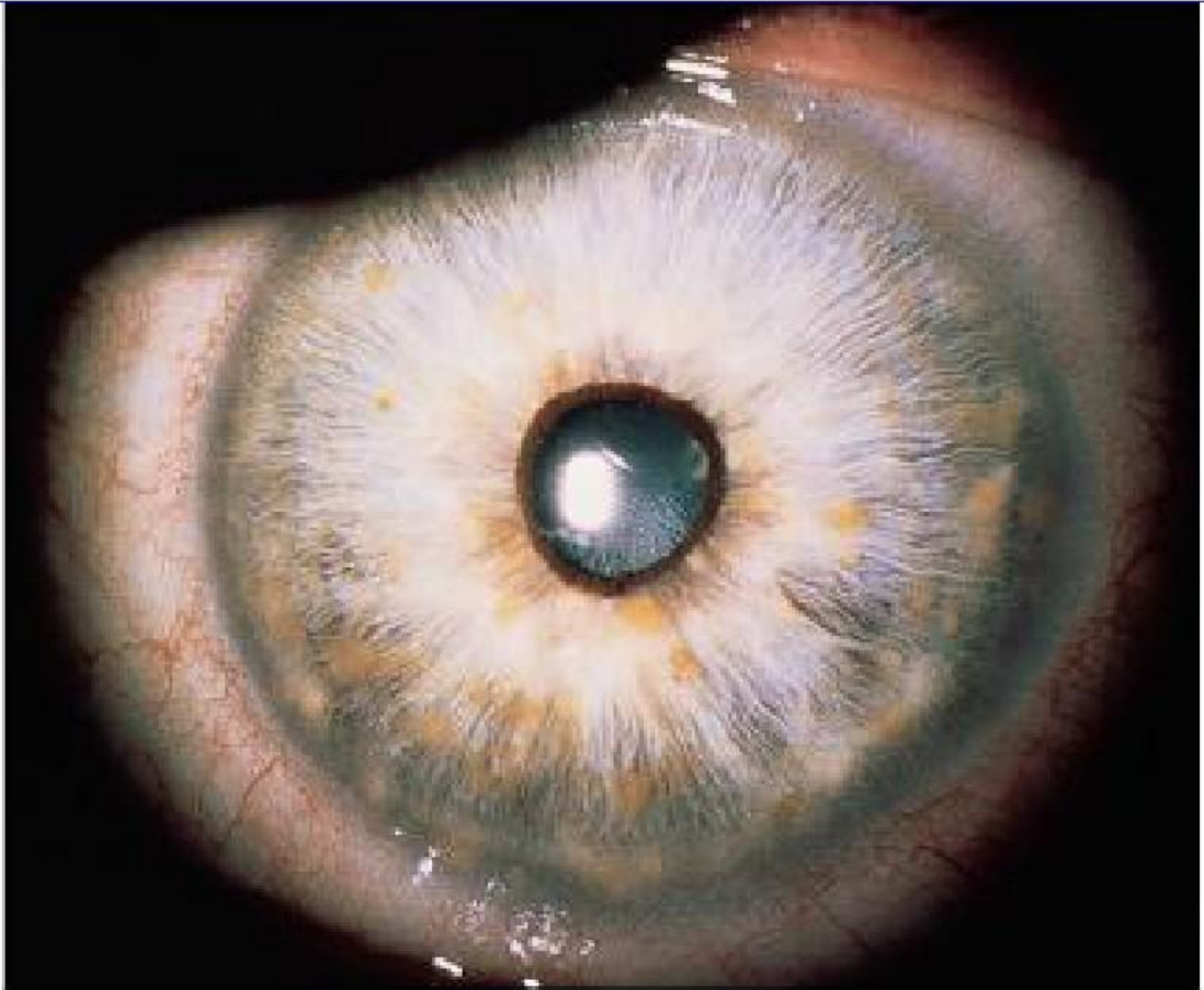Neurofibromatosis:

- u Autosomal dominant
- u Café-au-lait macules(light brown)
- u Neurofibromas(soft pink or skin- colored papules and nodules)
- u Axillary freckling
- u Optic glioma
- u Lisch nodules (iris hamartoma, seen by slit-lamp examination)
- u Associated with Neurological complications e.g. tumors, seizures and mental retardation.

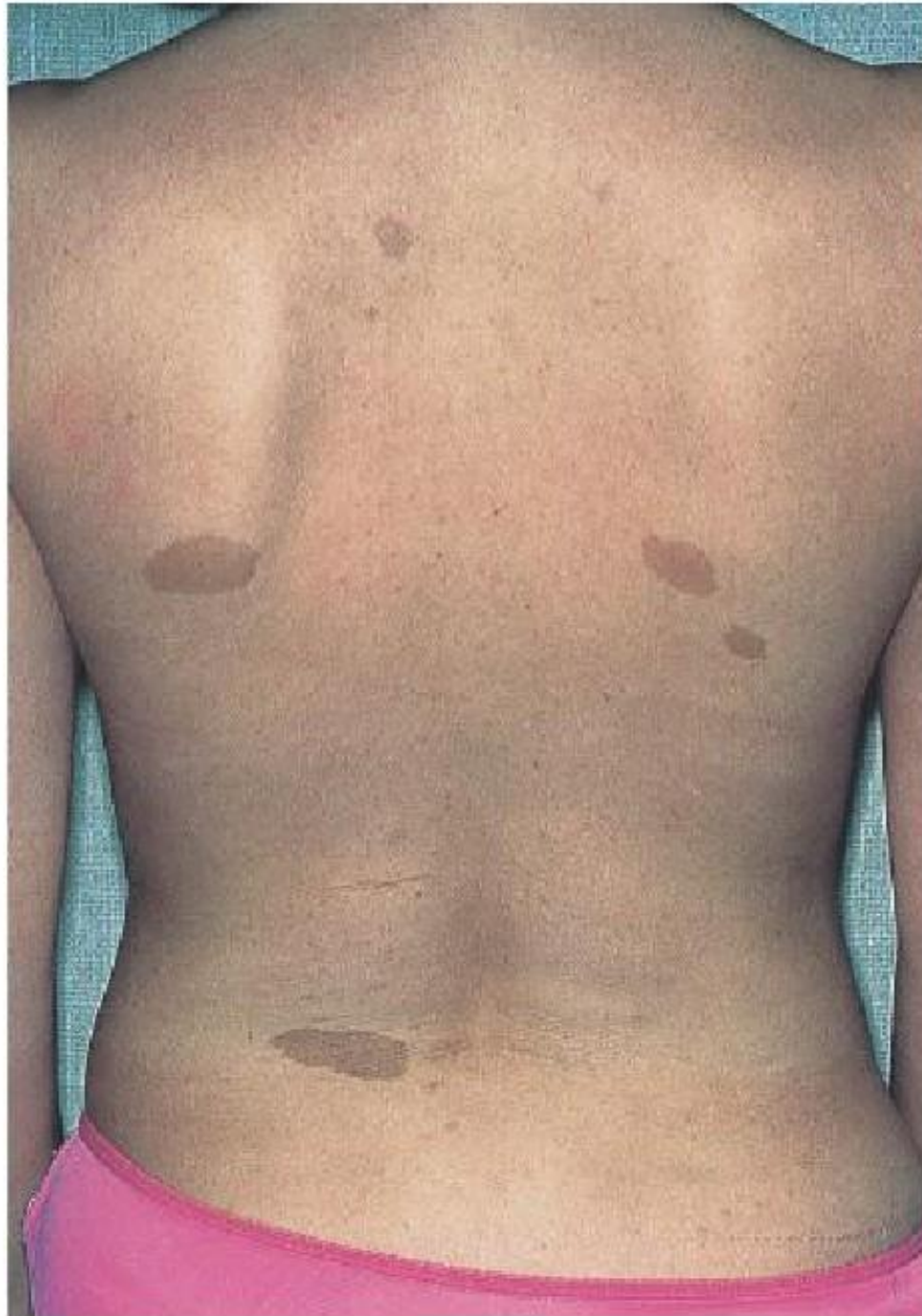


2003 Elsevier - Bologna, Jorizzo and Rapini: Dermatology - www.dermtext.com





2003 Elsevier - Bologna, Jorizzo and Rapini: Dermatology - www.dermtext.com



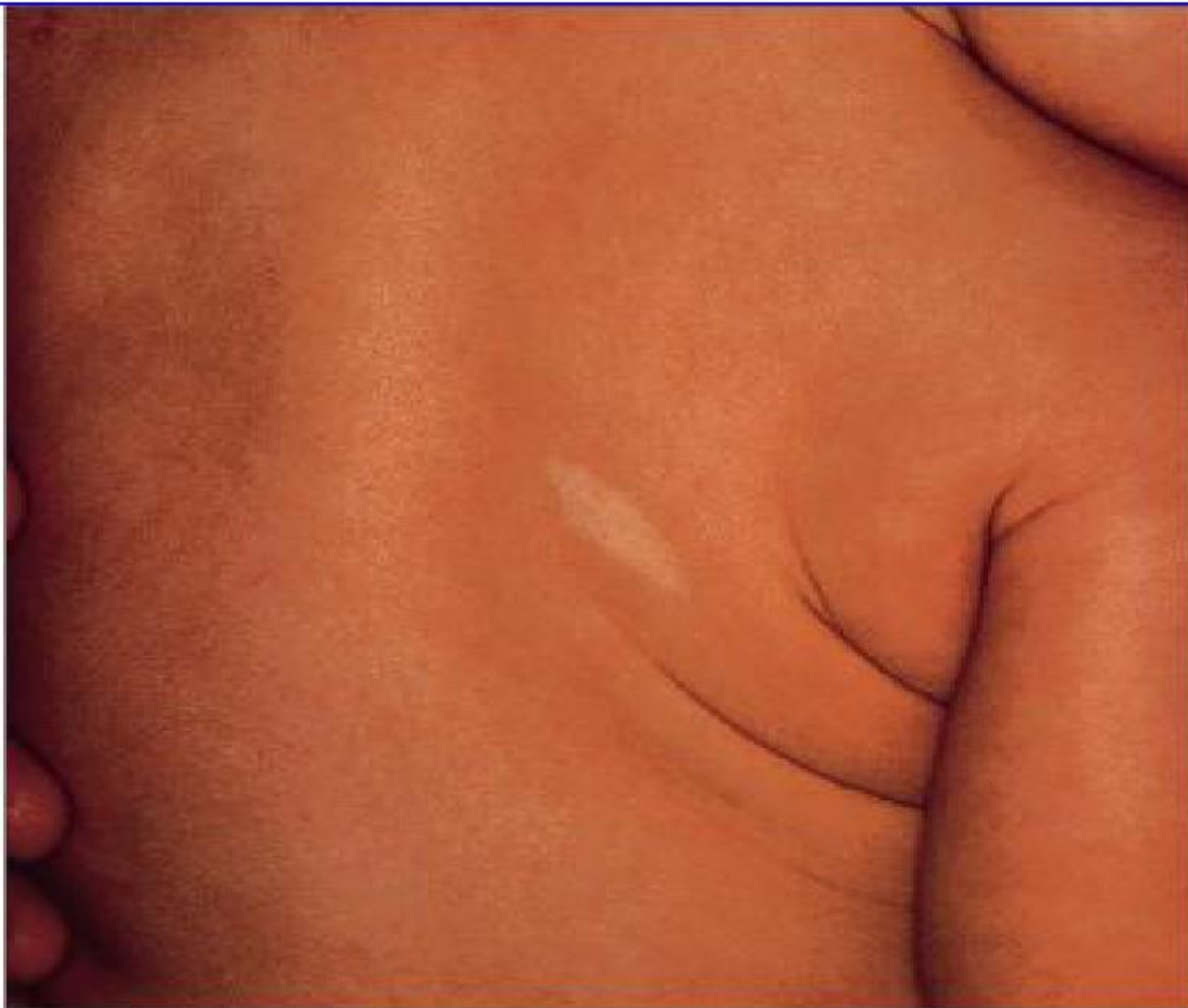© Elsevier 2004. Habif: Clinical Dermatology 4E - www.clinclerm.com

■ Tuberous Sclerosis (Epiloia) :

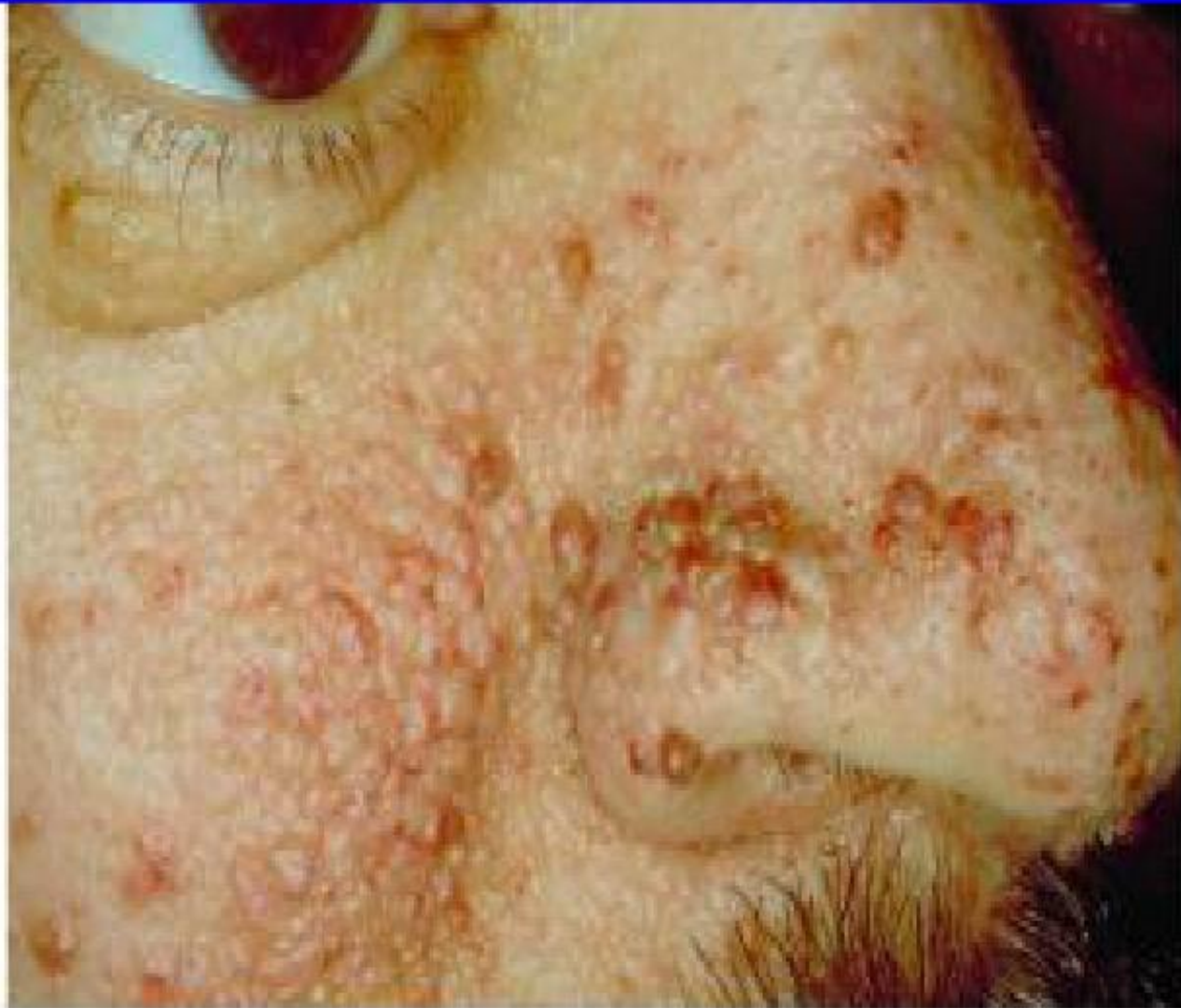- ✓ Epi = Epilepsy
- ✓ Loi = Low intelligence
- ✓ a = adenoma sebaceum

■ Skin features

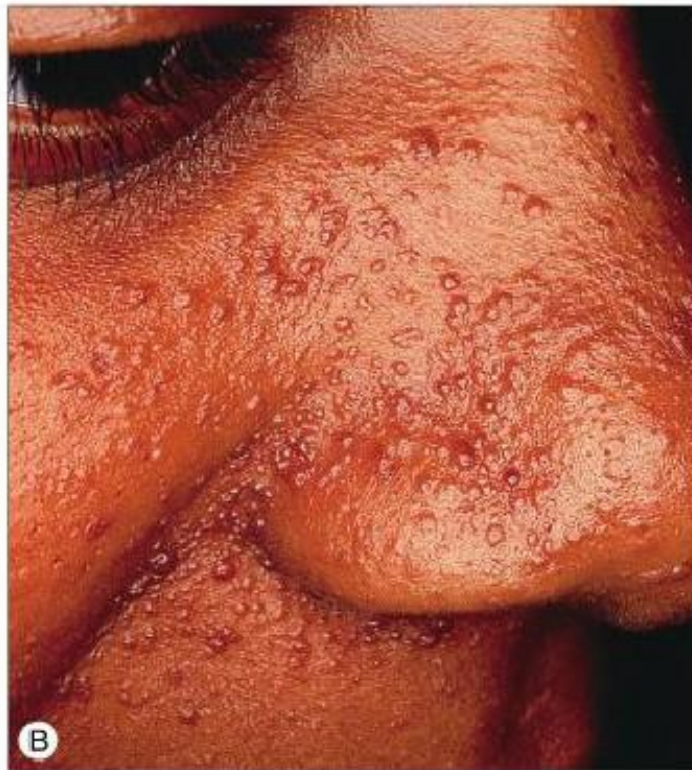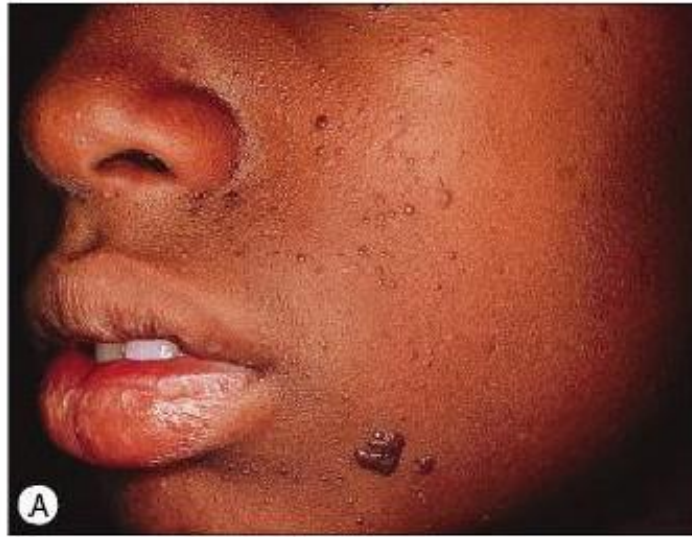1. Adenoma sebaceum (anigofibroma): red papules around the nose and on chin
2. Ash-leaf hypopigmentation: oval area of hypopigmentation *This is the earliest sign of TS*
3. Periungal fibroma: multiple papules & nodules around the nail
4. Shagreen patch: skin colored plaque on the trunk with “orange-peel” surface



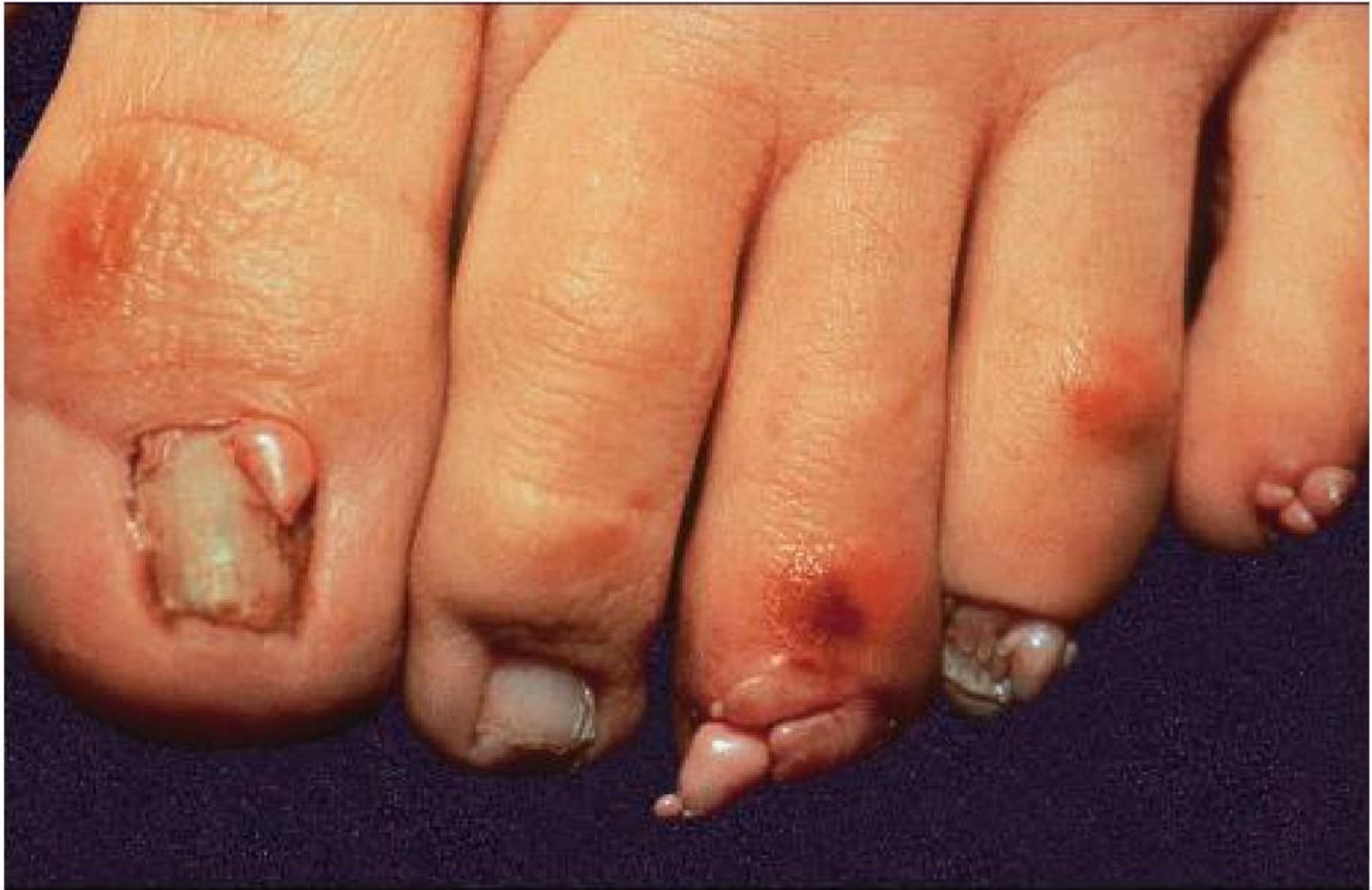2003 Elsevier - Bologna, Jorizzo and Rapini: Dermatology - www.dermtext.com



© Elsevier 2004, Habif: Clinical Dermatology 4E - www.clinderm.com



© 2003 Elsevier - Bologna, Jorizzo and Rapini: Dermatology - www.dermtext.com



© 2003 Elsevier - Bologna, Jorizzo and Rapini: Dermatology - www.dermtext.com

● Behcet's Syndrome:

- u Oral ulcer (the most common)
- u Genital ulcers (mainly scrotal)
- u Iritis and arthoropathy
- u May have CNS involvement

● Scurvy :

- u Vitamin C deficiency
- u Bleeding gums
- u Can cause teeth loss (permanent complication)

■ Scurvy(cont'd)

- u Easy bruising
- u Diagnosis : Low ascorbic acid (Vit-C) level in Leukocyte

■ Pellagra:

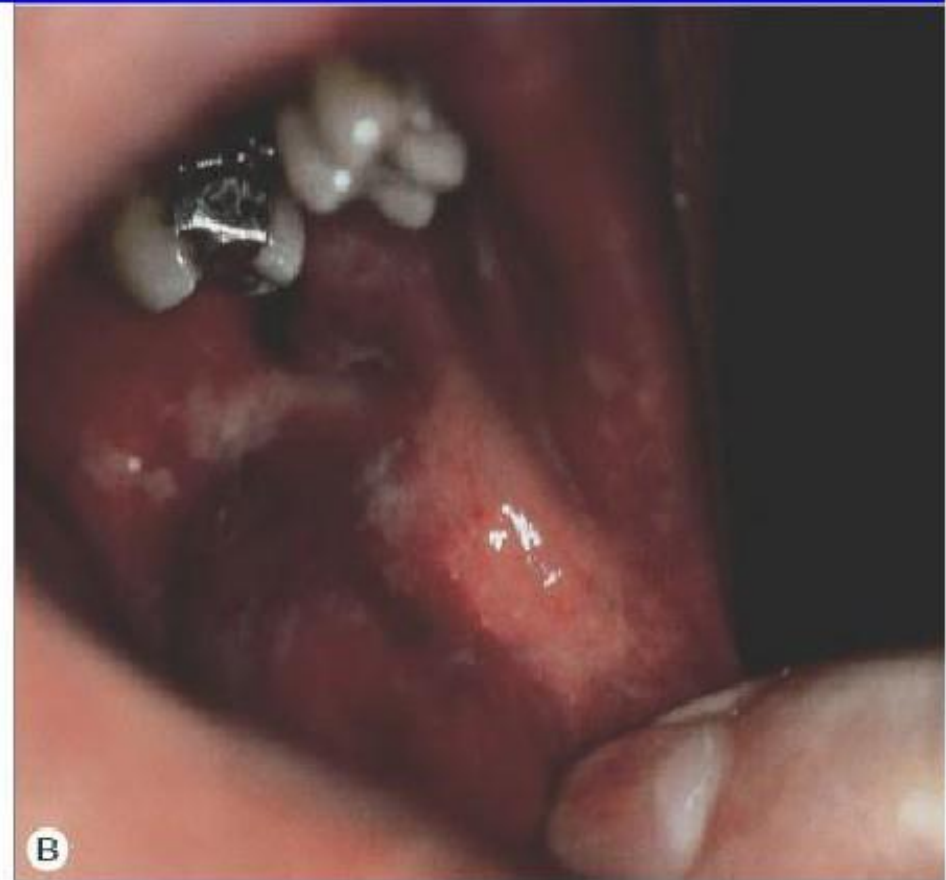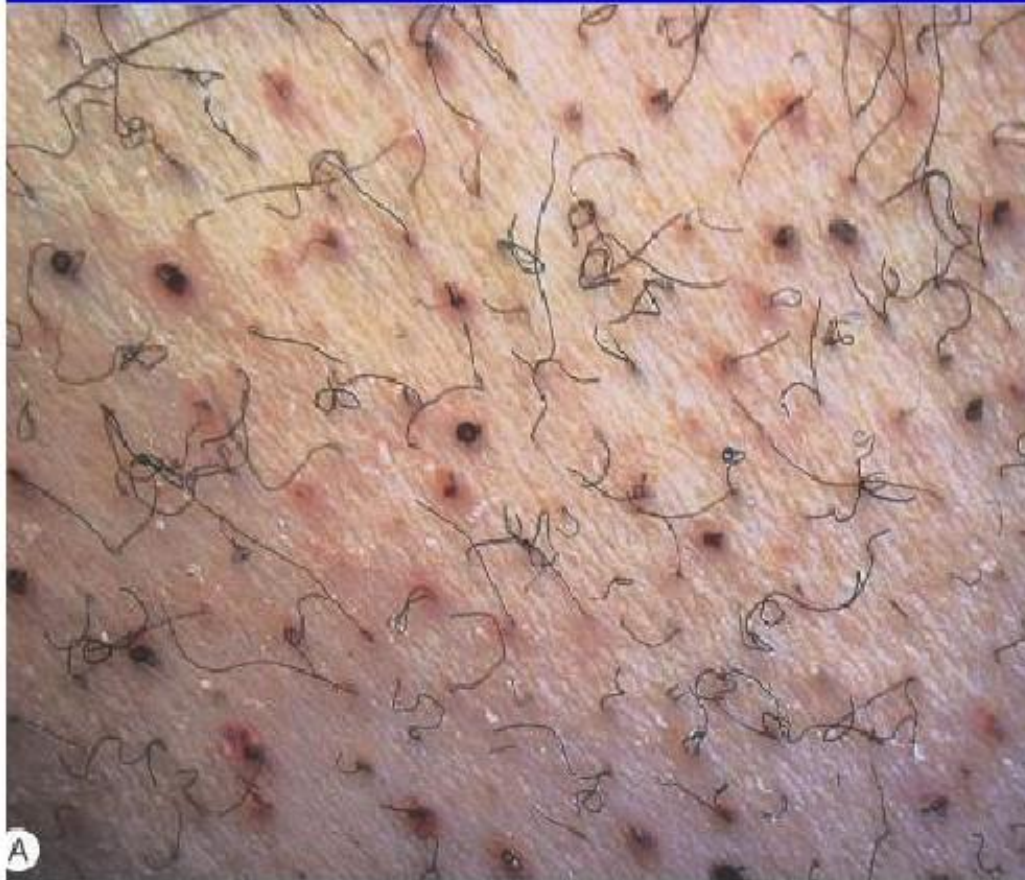- u Nicotinic acid deficiency
- u 4 “D”s

Dermatitis (Photodermatitis)

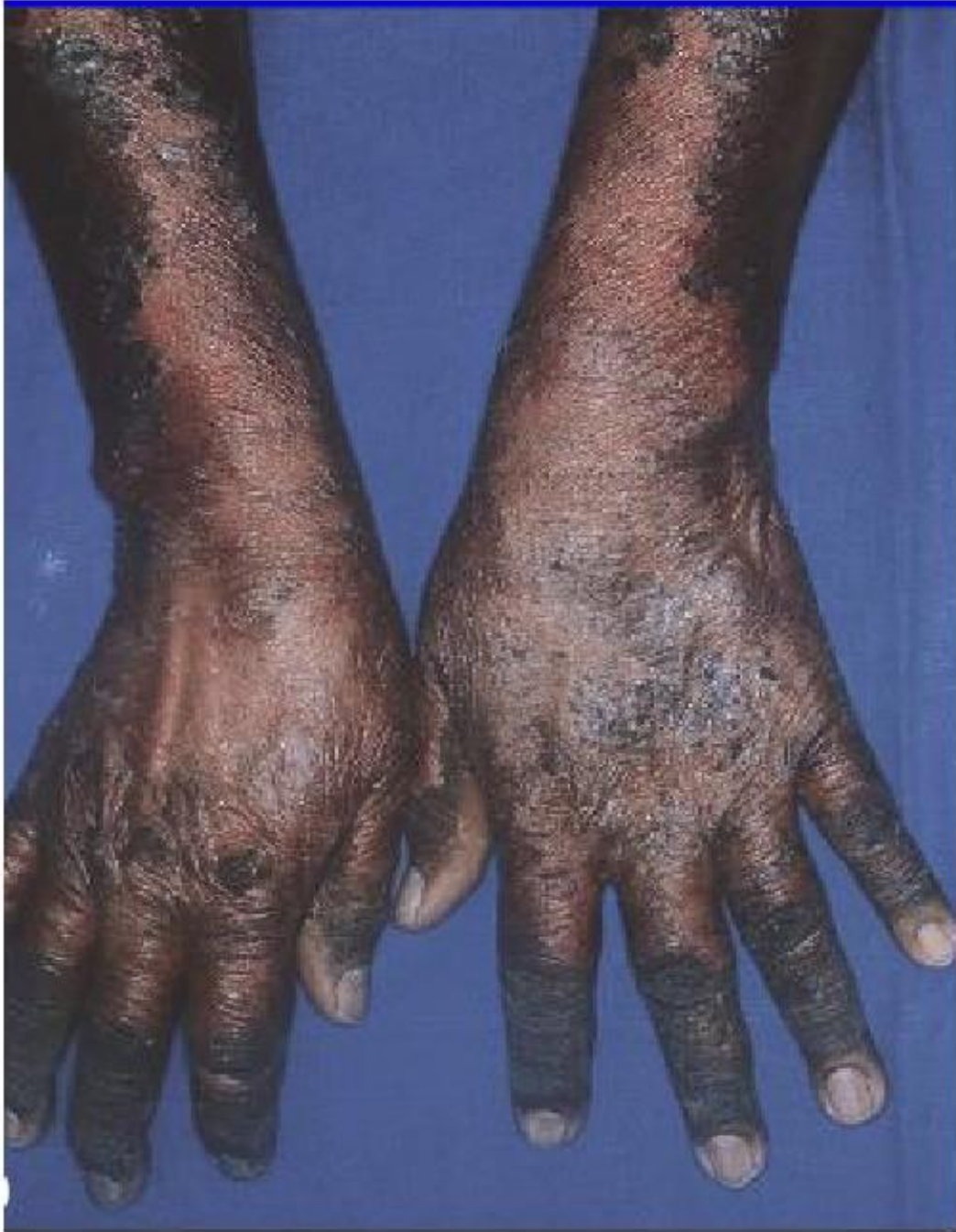Diarrhea

Dementia

Death (if not treated)



© 2003 Elsevier - Bologna, Jorizzo and Rapini: Dermatology - www.dermtext.com



Pellagra

© 2003 Elsevier - Bologna, Jorizzo and

■ Causes of generalized pruritus without skin lesions:

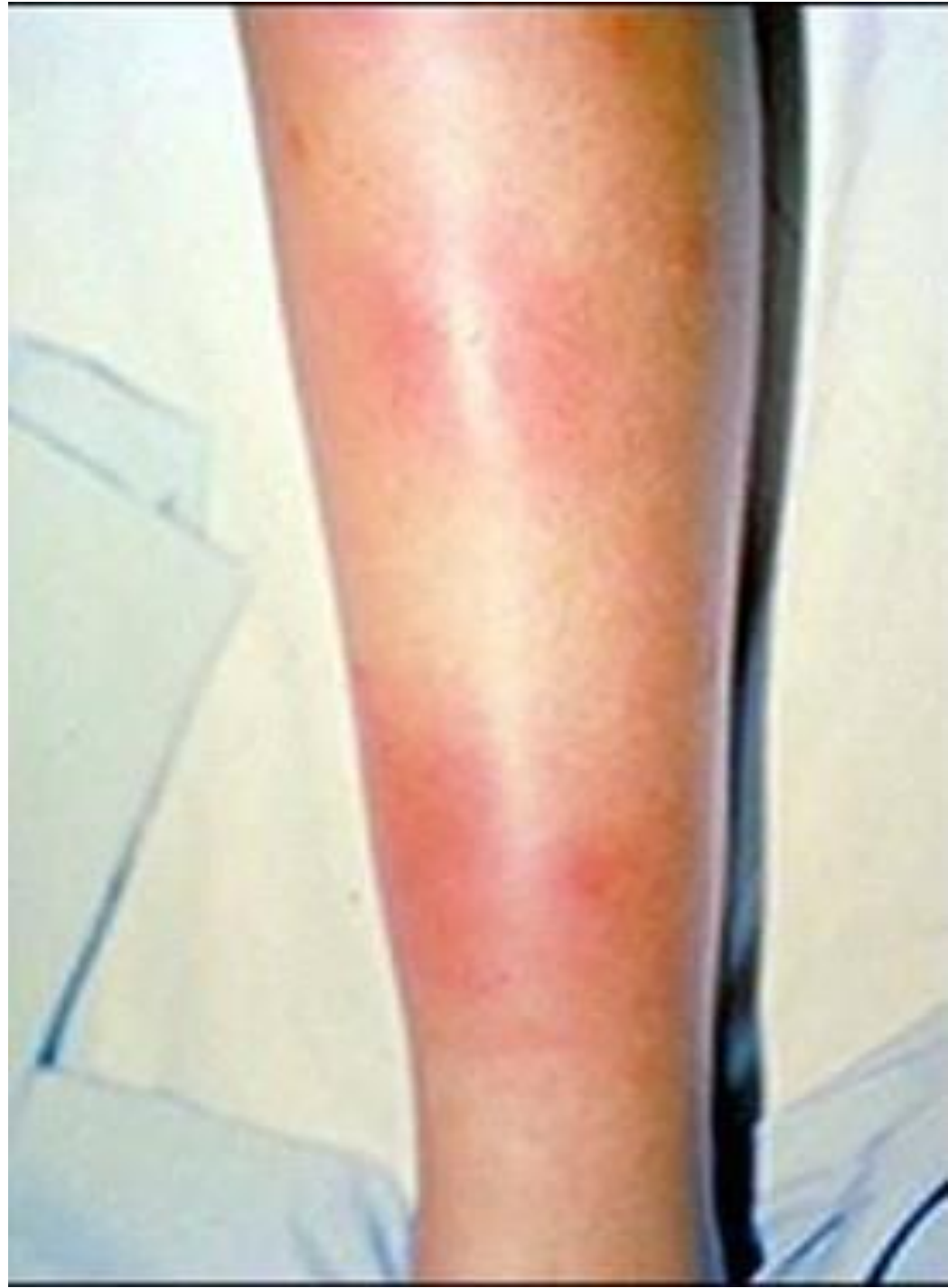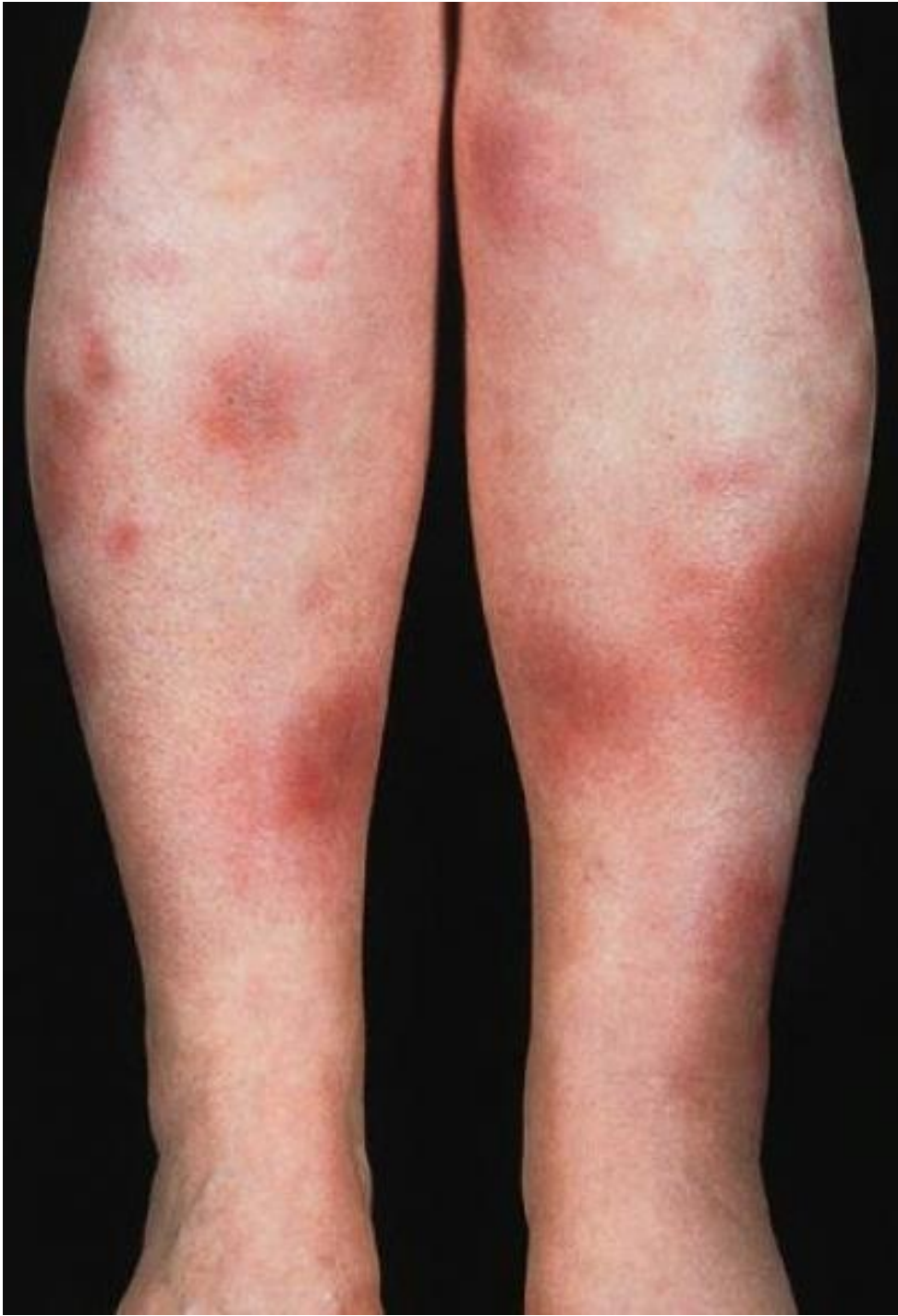1. Endocrine: DM, hypo& hyperthyroidism
2. Haematological: polycythemia rubra vera, iron def anemia
3. Malignancy; e.g. Lymphoma
4. Hepatic: primary biliary cirrhosis
5. Renal: CRF

The commonest manifestation of CRF is pruritus

6. Neurological : e.g. Tabes dorsalis
7. Others:
 - ✓ Psychogenic
 - ✓ Drugs
 - ✓ Idiopathic

Erythema Nodosum

- u Multiple bilateral tender erythematous subcutaneous nodules
Over shins
- u More common in females
- u Causes:
 - v Infectious: Streptococcus, Tuberculosis, Hepatitis ,Chlamydia
 - v Sarcoidosis
 - v Drugs : Oral contraceptive pills, sulfonamides
 - v Lymphoma & leukemia
 - v Pregnancy
 - v Behcet's disease
 - v Idiopathic



Acanthosis Nigricans:

- u Brown hyperpigmentation & increased thickening of skin with velvety texture at neck, axillae and groin

Causes:

Obesity

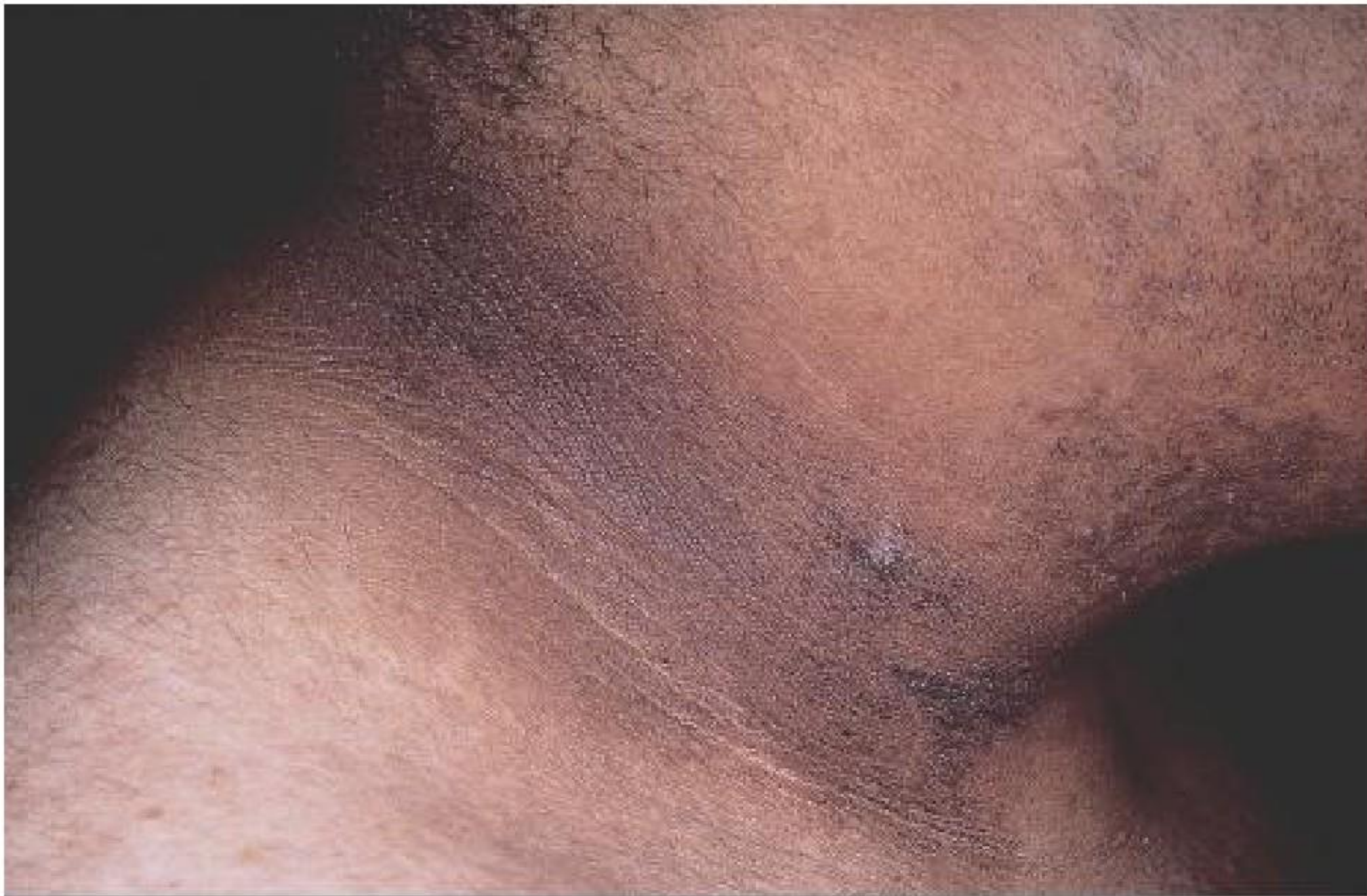Endocrinopathy : Diabetes, Thyroid disease, Insulin resistance

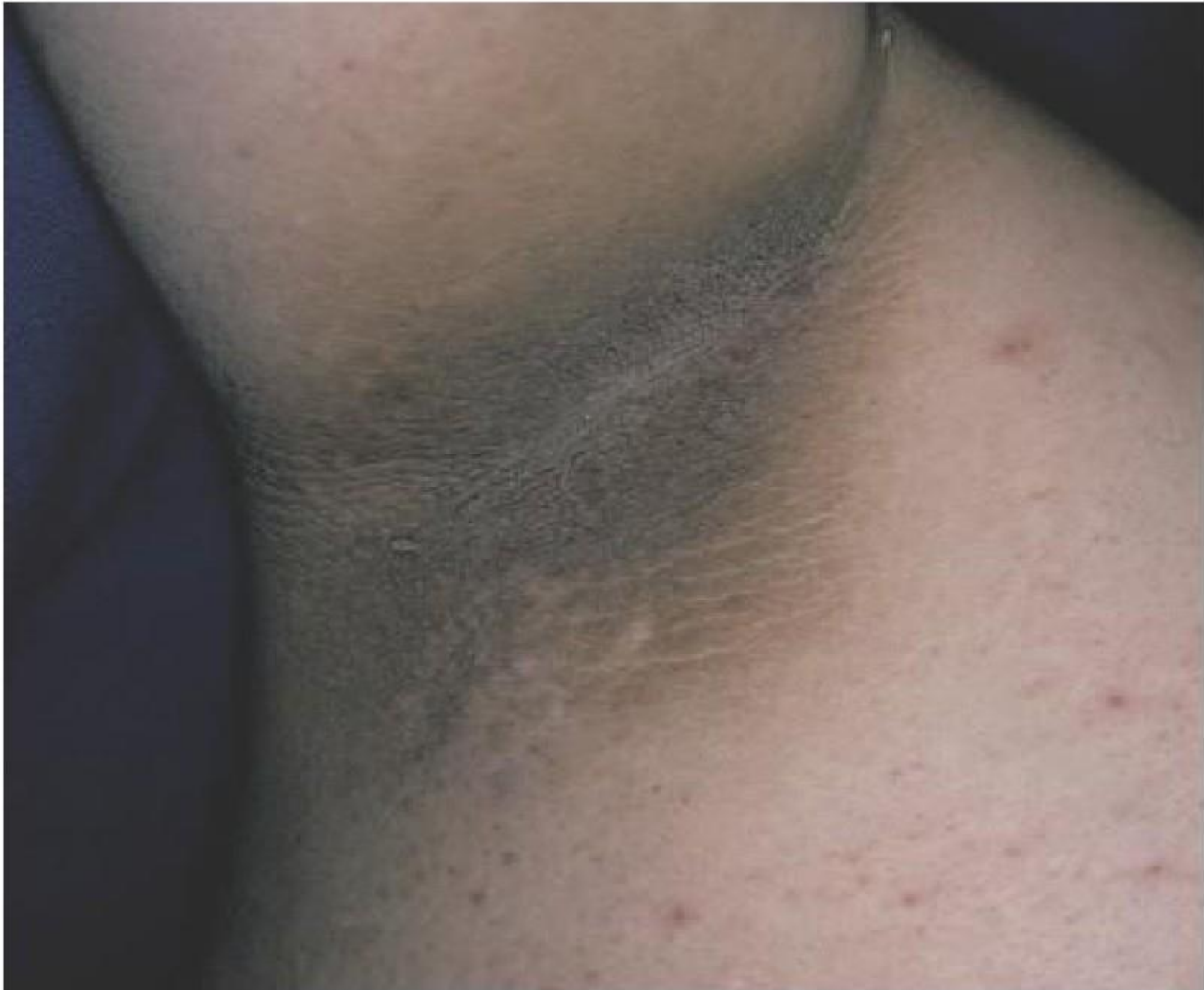Internal malignancy: the most common is adenocarcinoma of stomach

Drugs: Nicotinic acid

Familial

Idiopathic

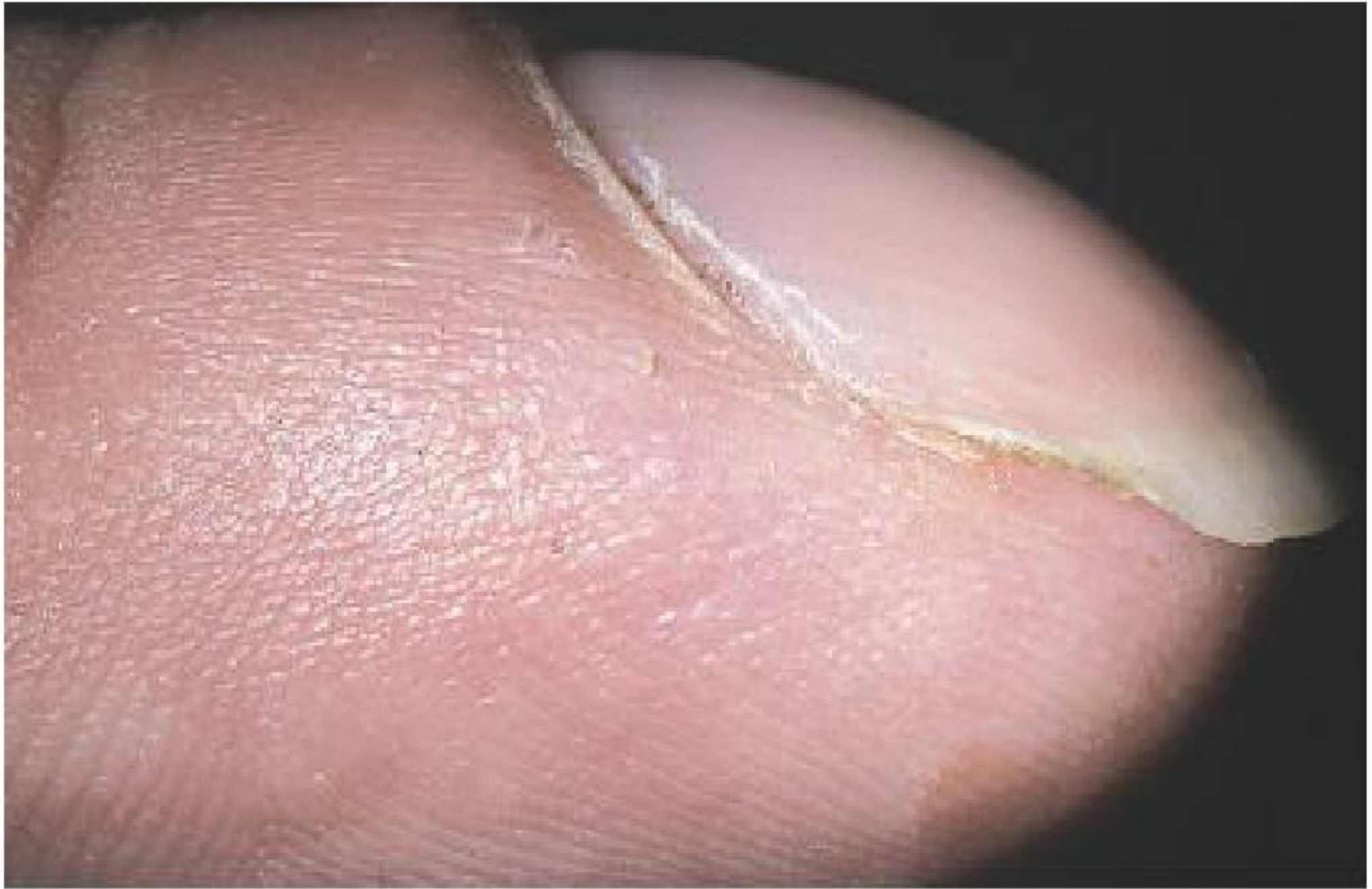



Nails

Clubbing :

- ✓ Exaggeration of the normal nail curve associated with loss of the normal angle between nail and posterior nail fold
- ✓ Causes:
 1. Thoracic: Lung abscess, Lung CA
 2. CVS: Congenital cyanotic heart disease
 3. GIT: GI carcinoma, Inflammatory bowel disease
 4. Endocrine: Thyroid disease
 5. Idiopathic:

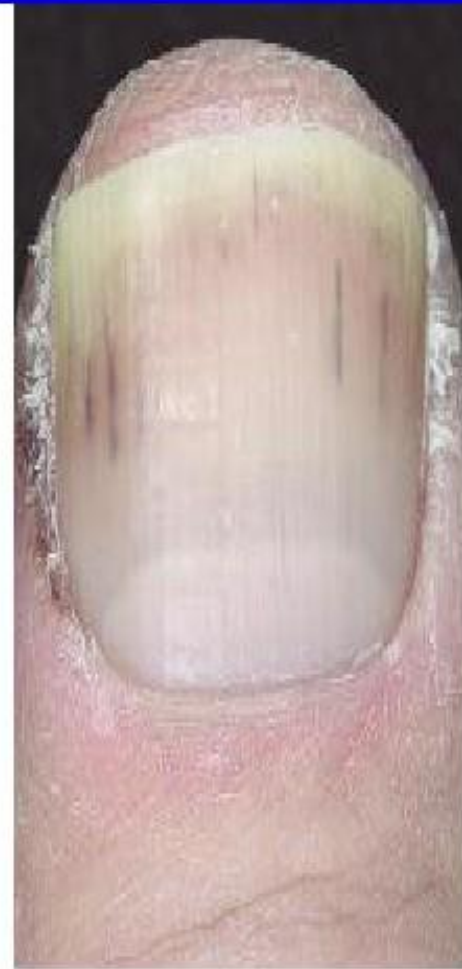

Elsevier 2004. Habif: Clinical Dermatology 4E - www.clinderm.cc

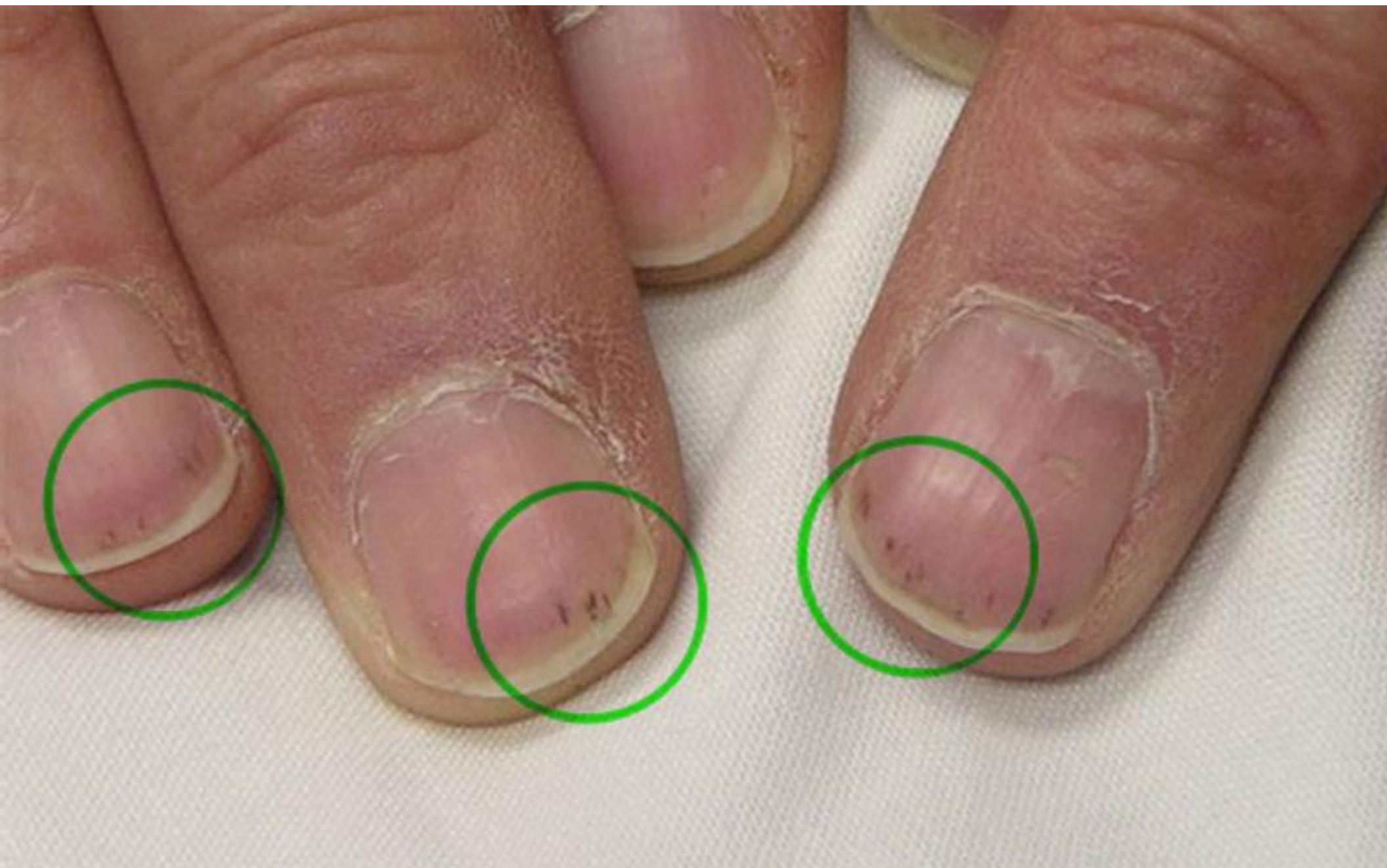■ Splinter Haemorrhages :

u Causes :

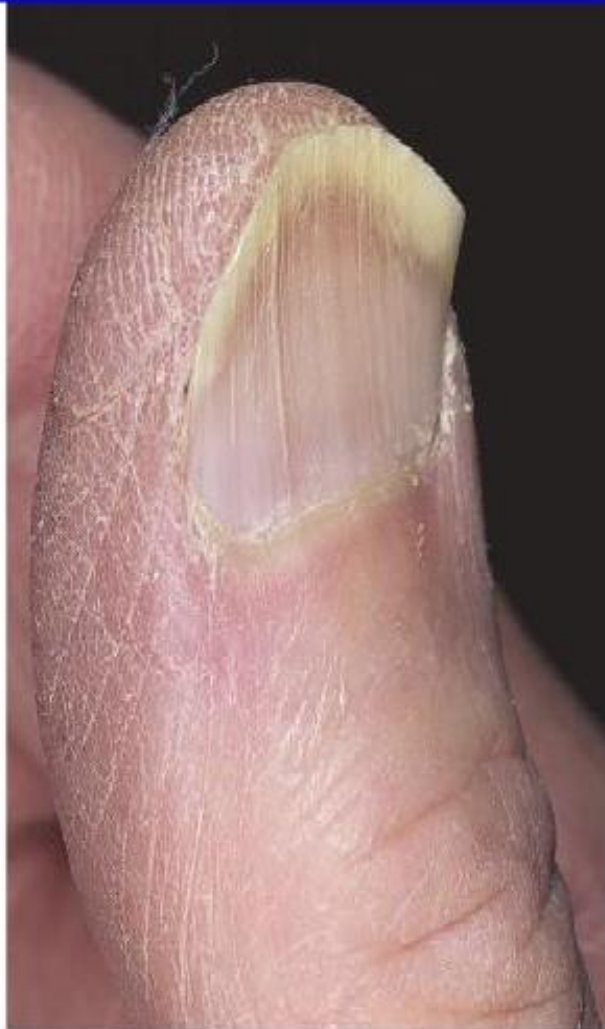1. Bacterial endocarditis
2. Septic emboli
3. CTD
4. Trauma
5. Idiopathic



© Elsevier 2004, Habif: Clinical Dermatology 4E - www.clinderm.com



● Koilonychia :



- u Spoon- shaped appearance

- u Causes:

1. Iron deficiency anemia
2. Thyroid disease
3. Physiological; early childhood
4. Dermatoses: Lichen planus

Alopecia Areata and others

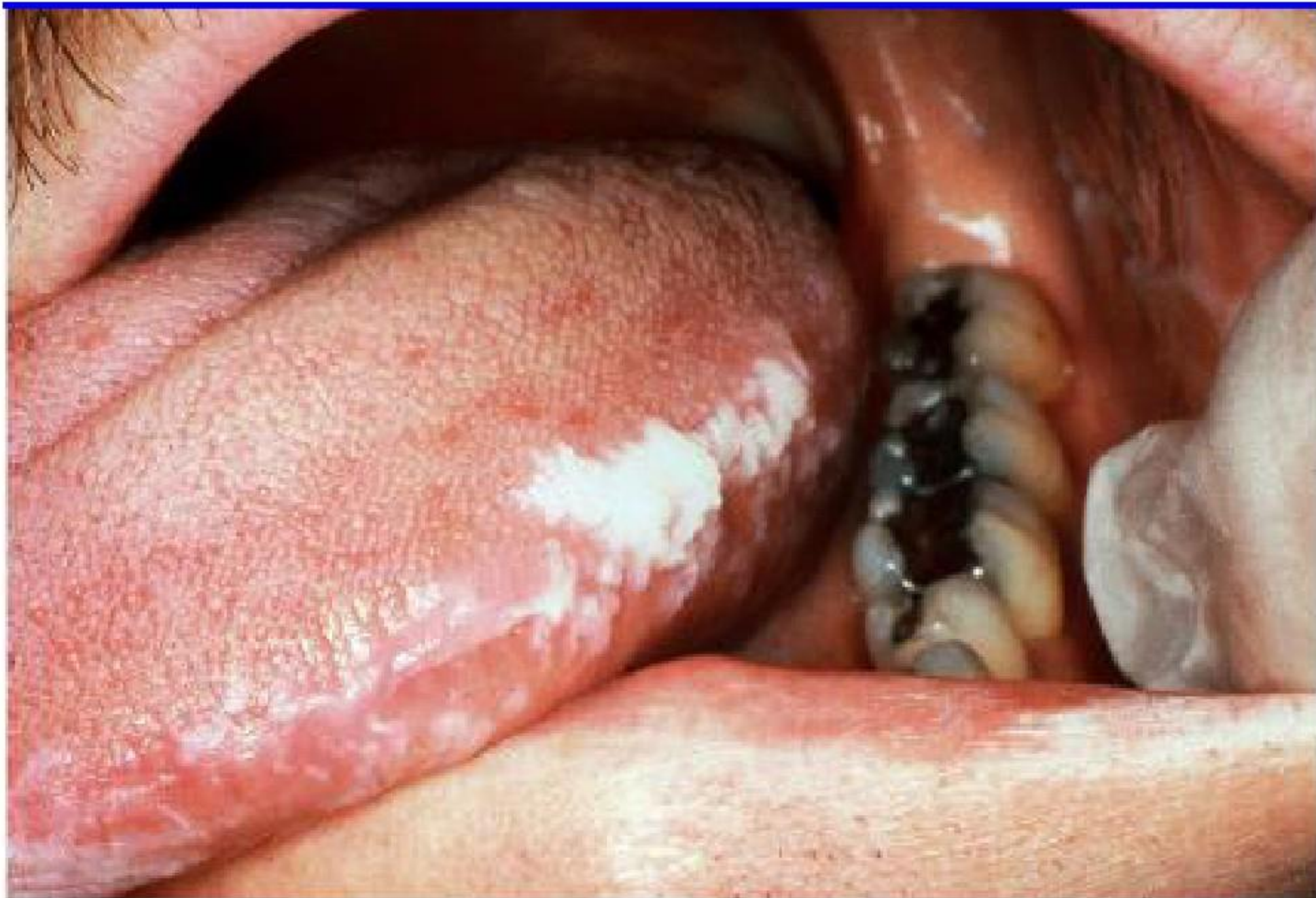Some mucocutaneous disorders in which you need to do HIV testing?

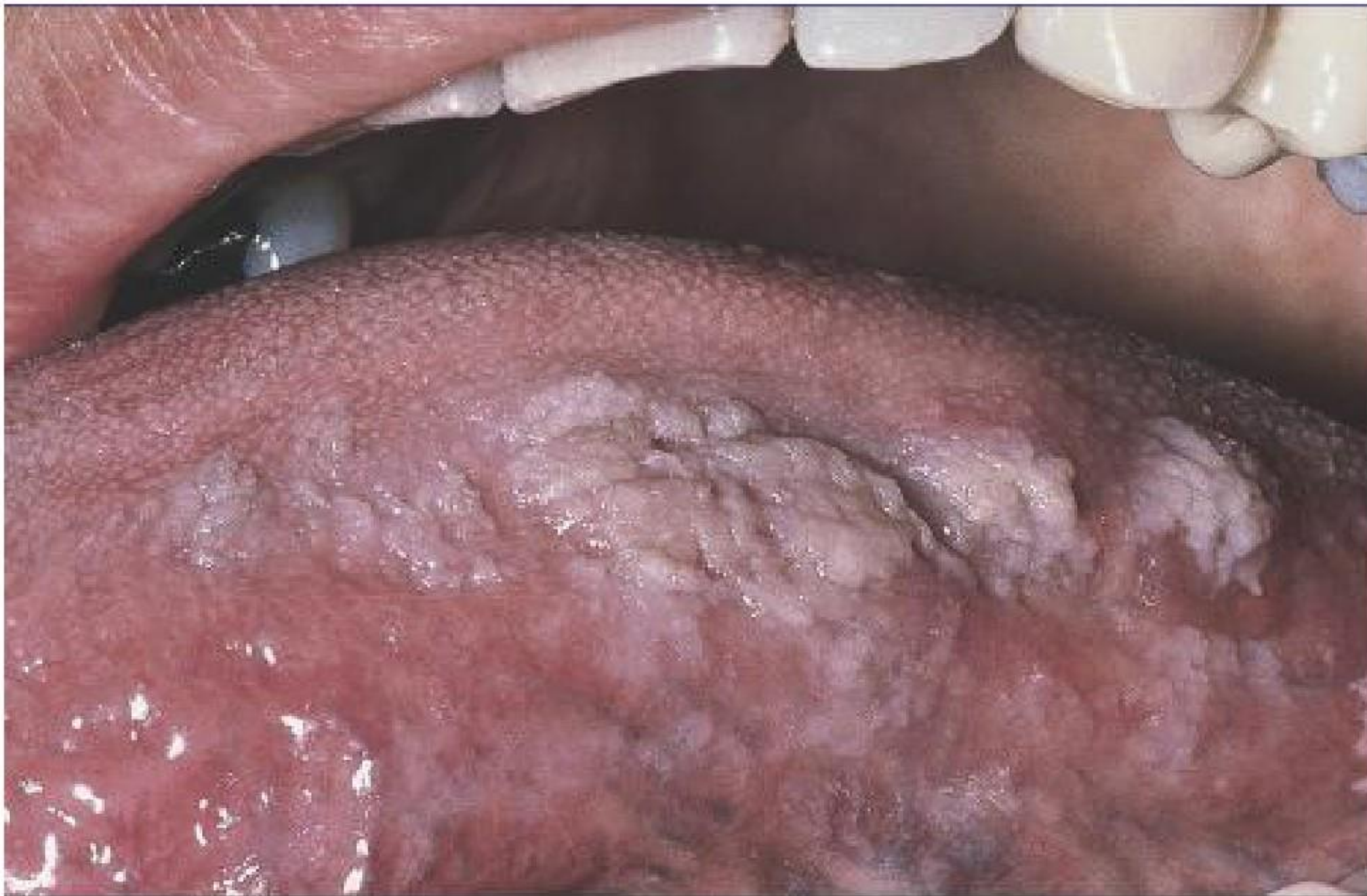- u Oral hairy leukoplakia:

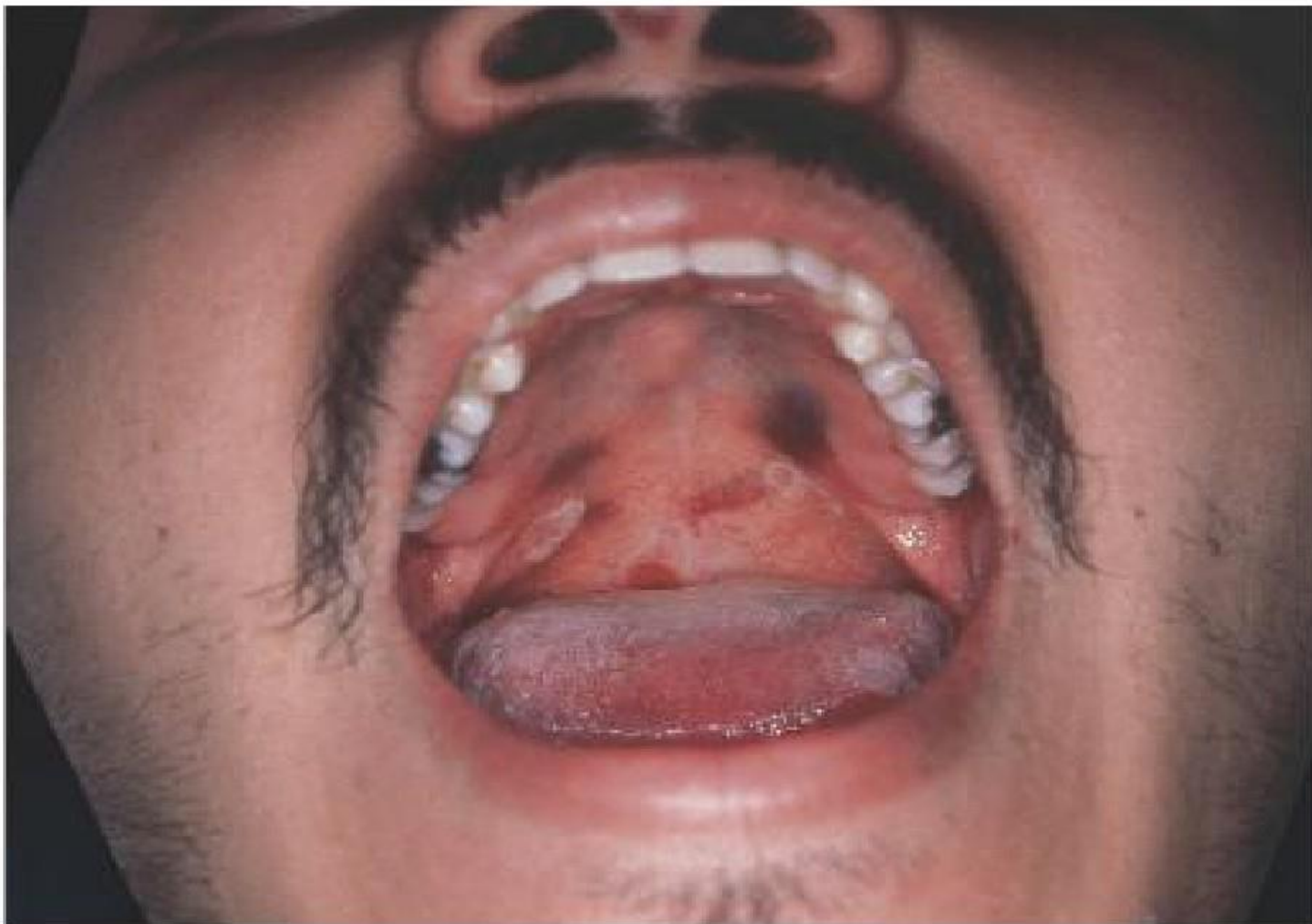- ✓ Corragated white plaques on the lateral aspect of the tongue.

- u Kaposi Sarcoma:

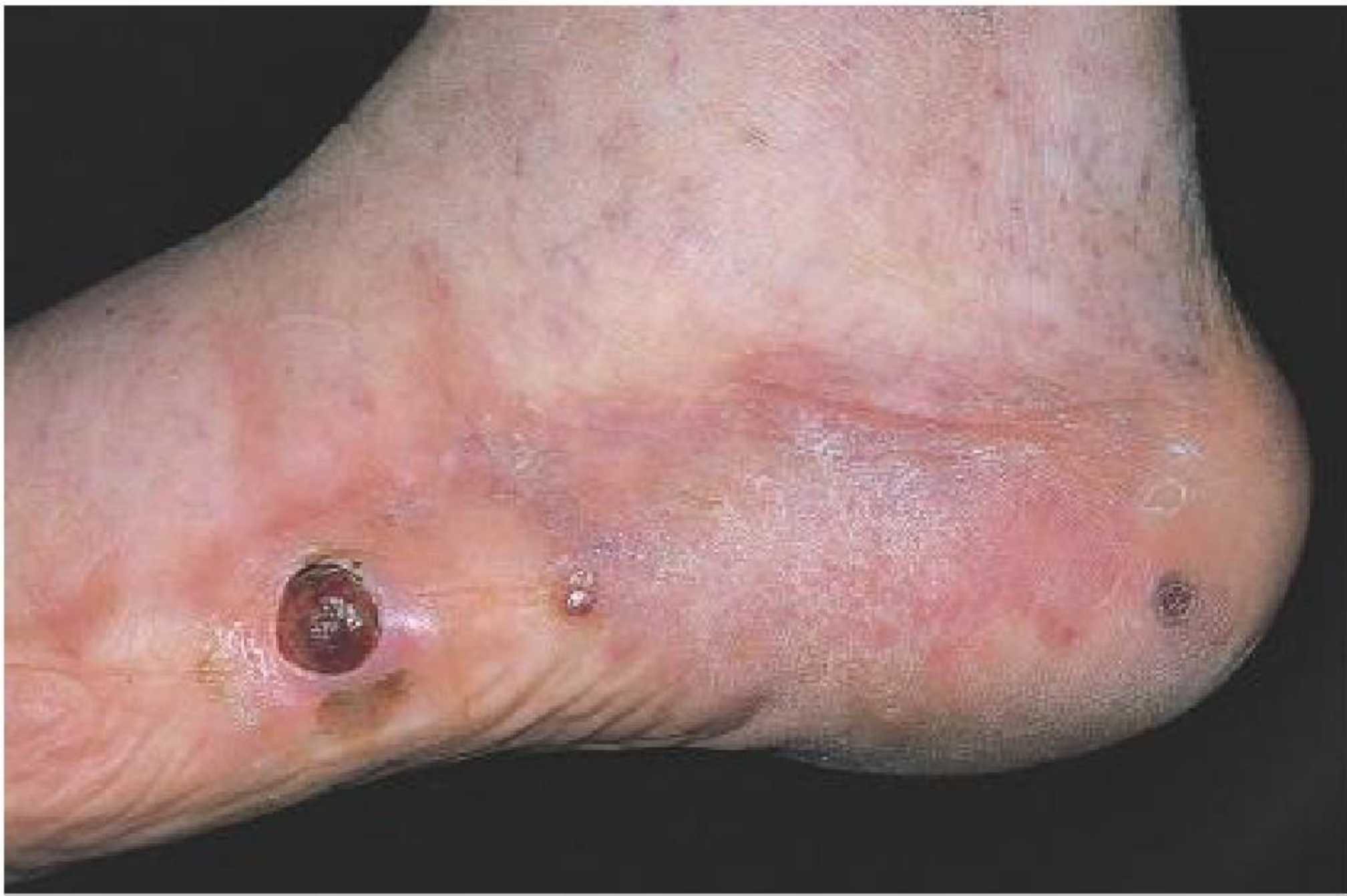- ✓ Caused by HHV -8
- ✓ Blue macules ,patches or nodules which is in essence a vascular tumor
- ✓ Associated with low CD4 count
- ✓ May resolve or diminish if CD4 count rises
- ✓ Types of Kaposi sarcoma :Classic type (in elderly),Immunosupperssion associated ,HIV associated ,and African endemic type
- ✓ Metastasis to Lymph nodes , and Viscera



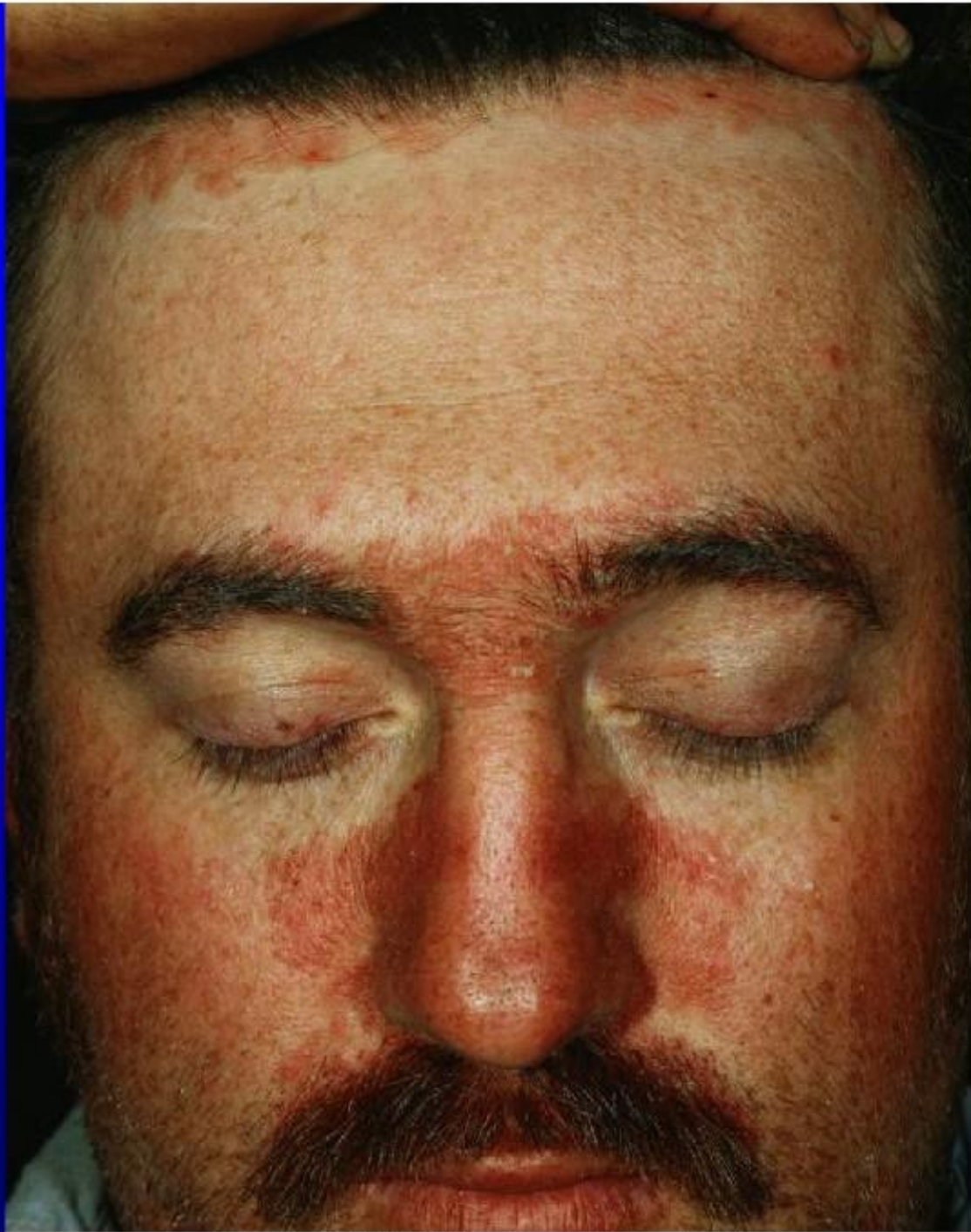




2003 Elsevier - Bologna, Jorizzo and Rapini: Dermatology - www.dermtext.com



Elsevier 2004. Habif: Clinical Dermatology 4E - www.clinderm.cc



© Elsevier 2004. Habif: Clinical Dermatology 4E - www.clinderm.com

- *Multiple molluscum contagiosum in adult (on face)
- *Any STD
- *Seborrheic Dermatitis (extensive & refractory to therapy)
- *Severe extensive relacitrant apthous ulceration

Examples of some skin diseases where you may find systemic associations:

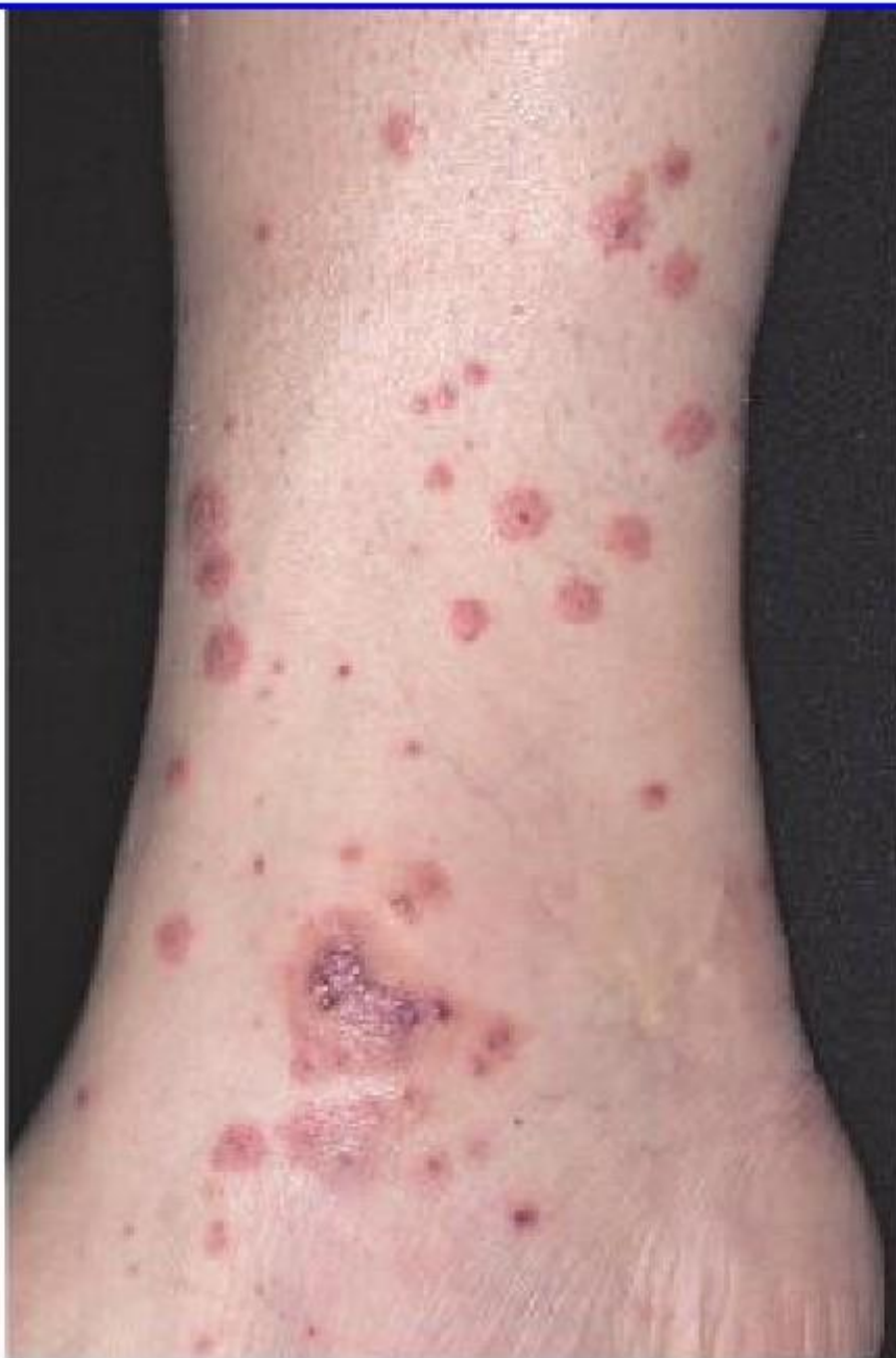1. Lichen planus; associated with Hepatitis B and C

2. Vitiligo and

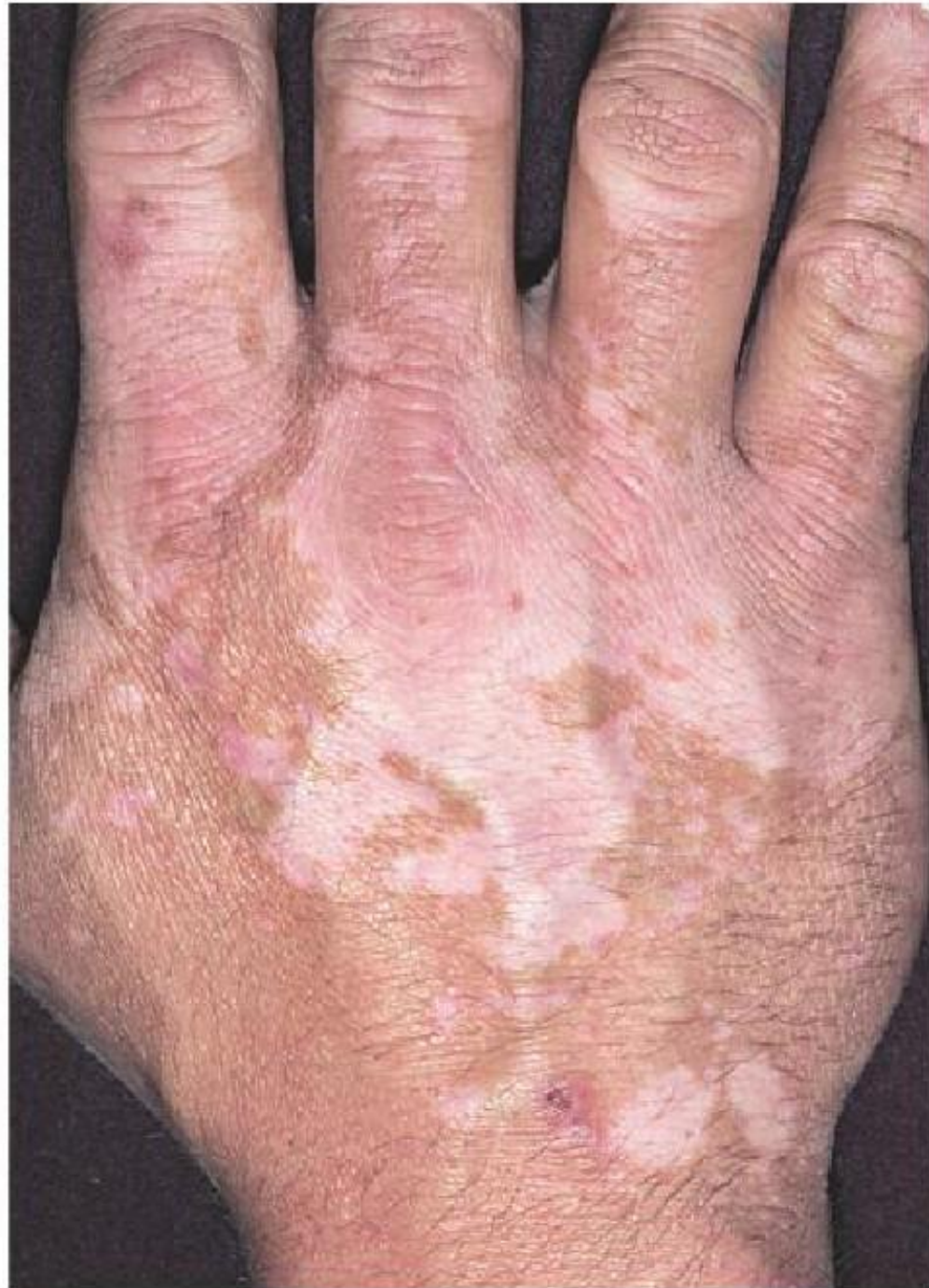3. Alopecia Areata :

both associated with autoimmune diseases like: Autoimmune

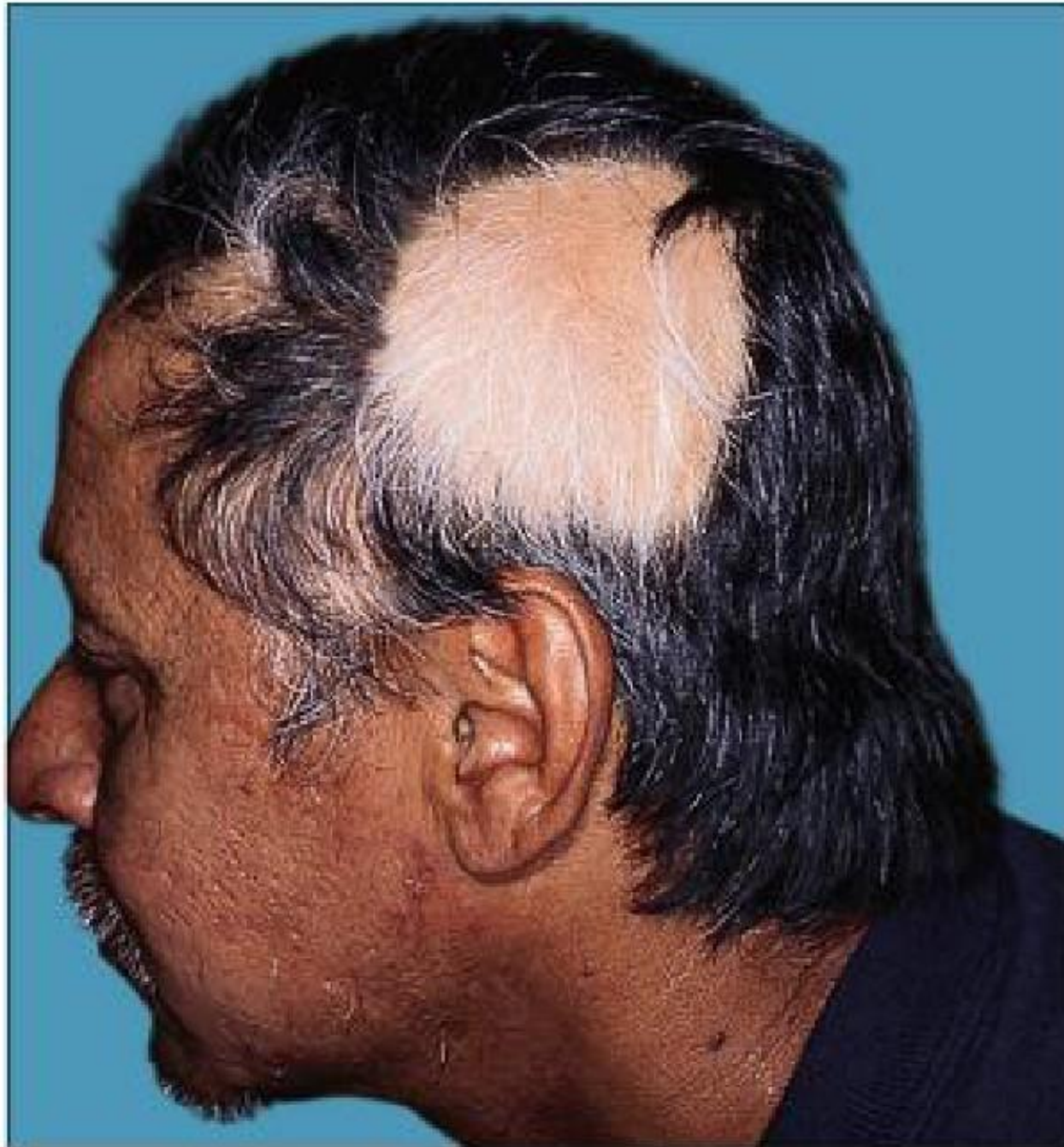
Thyroid dis, Diabetes mellitus , Pernicious anemia, Myasthenia gravis etc



© Elsevier 2004. Habif: Clinical Dermatology 4E - www.clinderm.com



© Elsevier 2004. Habif: Clinical Dermatology 4E - www.clinderm.com



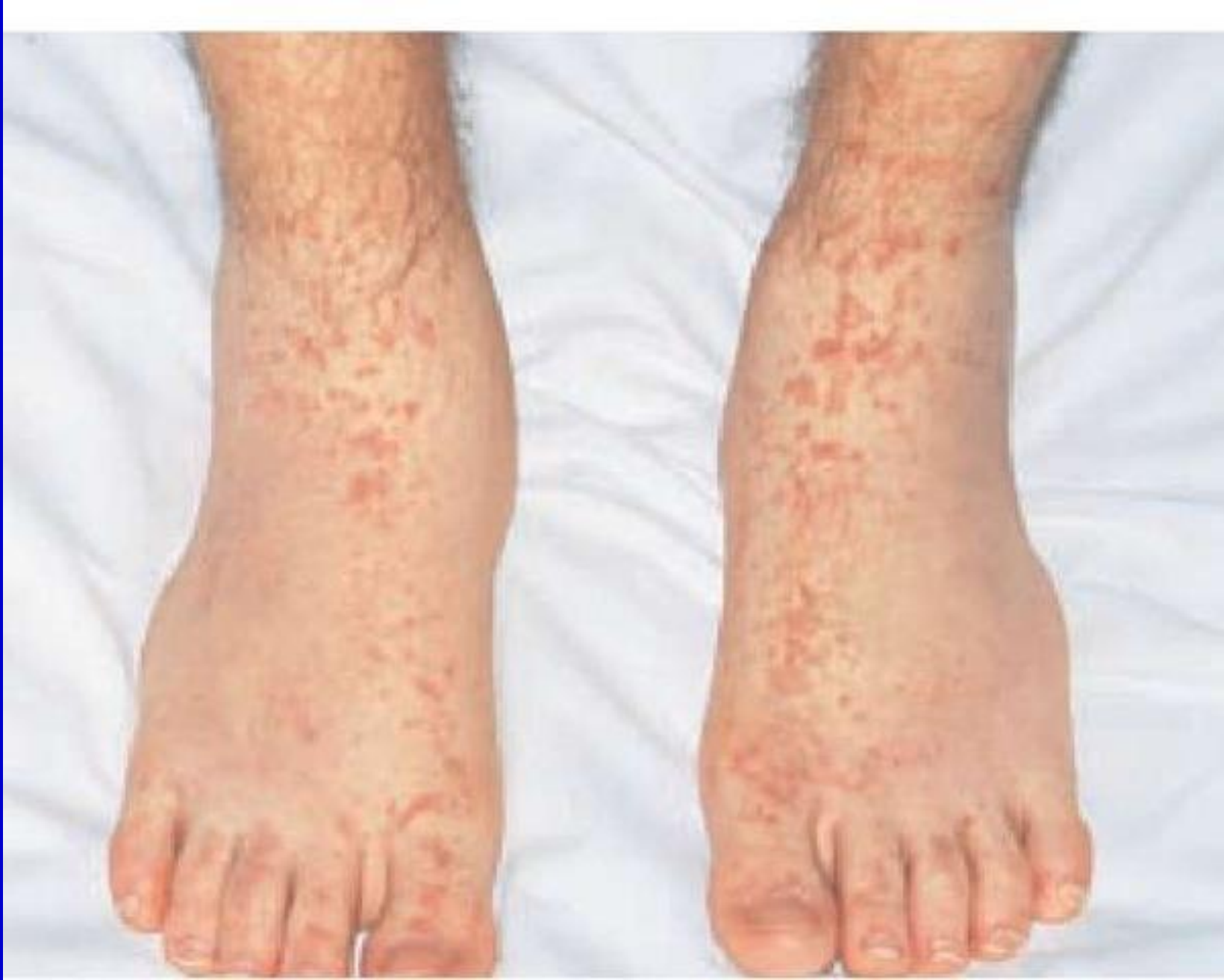© 2003 Elsevier - Bologna, Jorizzo and Rapini: Dermatology - www.dermtext.com

Table 7.2 Possible laboratory studies in the evaluation of pruritus. These laboratory tests should be performed according to the patient's history, in particular in cases of generalized pruritus of unknown etiology.

POSSIBLE LABORATORY STUDIES IN THE EVALUATION OF PRURITUS

- Erythrocyte sedimentation rate (ESR)
- Complete blood cell count (CBC) with differential and platelet count
- Blood urea nitrogen, creatinine
- Liver transaminases, alkaline phosphatase, bilirubin
- Fasting glucose
- Thyroid function tests (thyroid stimulating hormone (TSH) and thyroxine levels)
- Parathyroid function (calcium and phosphate levels)
- Serum iron, ferritin
- Chest radiograph
- Stool for ova, parasites and occult blood
- Viral hepatitis screen
- Serum protein electrophoresis
- Serum immunofixation
- Antinuclear antibodies (ANA), antimitochondrial antibodies
- Human immunodeficiency virus (HIV)
- Allergy panel: total IgE, histamine, serotonin (plasma)
- Prick tests of major atopy antigens and additives, patch tests
- Urine for sediment, 5-hydroxyindolacetic acid (5-HIAA) and mast cell metabolites
- Additional radiographic studies, e.g. abdominal CT scan
- Anti-tissue transglutaminase antibody
- Anti-smooth muscle antibody

Purpura and vasculitis



Definition

Visible hemorrhage into the skin or mucous membrane subdivided as a follow:

-Petechiae less than or equal 4 mm

-Purpura (>4mm - < 1cm)

which can be either Palpable or non-palpable(macular)

-Ecchymoses > or equal to 1 cm

Purpura

Causes

```
graph TD; A[Causes] --> B[Platelet disease]; A --> C[Coagulation defect]; A --> D[Blood vessel wall pathology];
```

Platelet disease

Coagulation defect

Blood vessel wall pathology

Causes

1-Platelet Disorders

Thrombocytopenia

Platelet Dysfunction

2-Coagulation Factor Deficiency

Congenital

Factor VIII Deficiency

Factor IX Deficiency

Von Willebrands disease

Acquired

*Disseminated Intravascular
Coagulopathy*

Liver disease

Uremia

Vitamin K deficiency

3-Vascular Factors

Congenital

Hereditary Hemorrhagic Telangiectasia

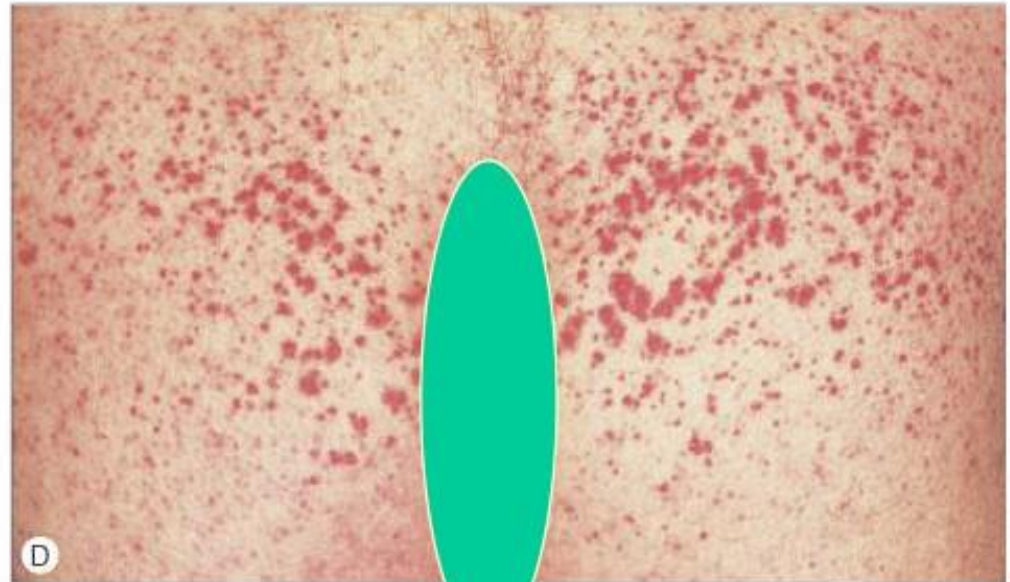
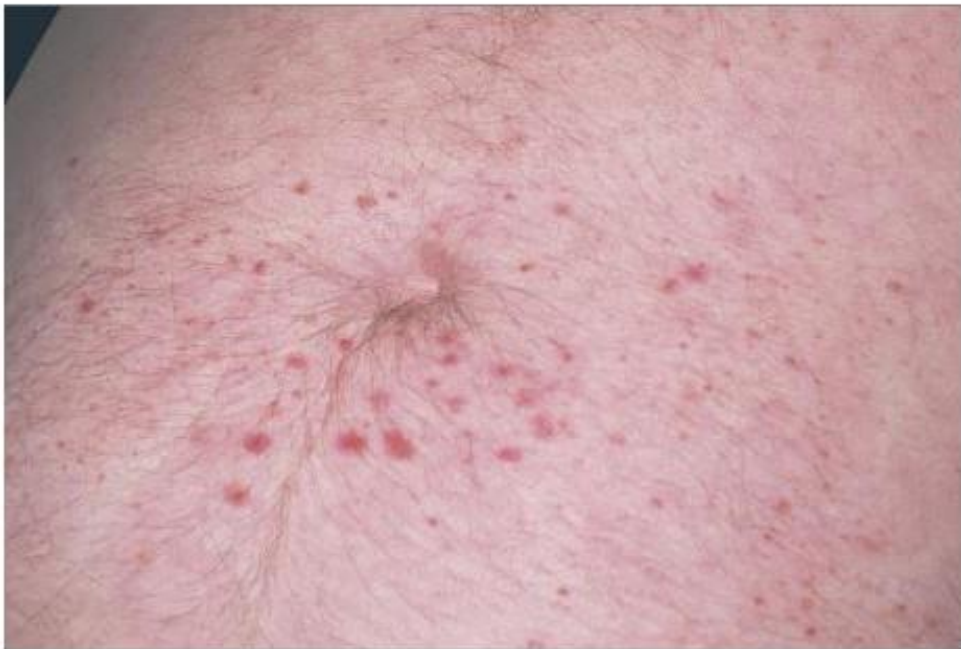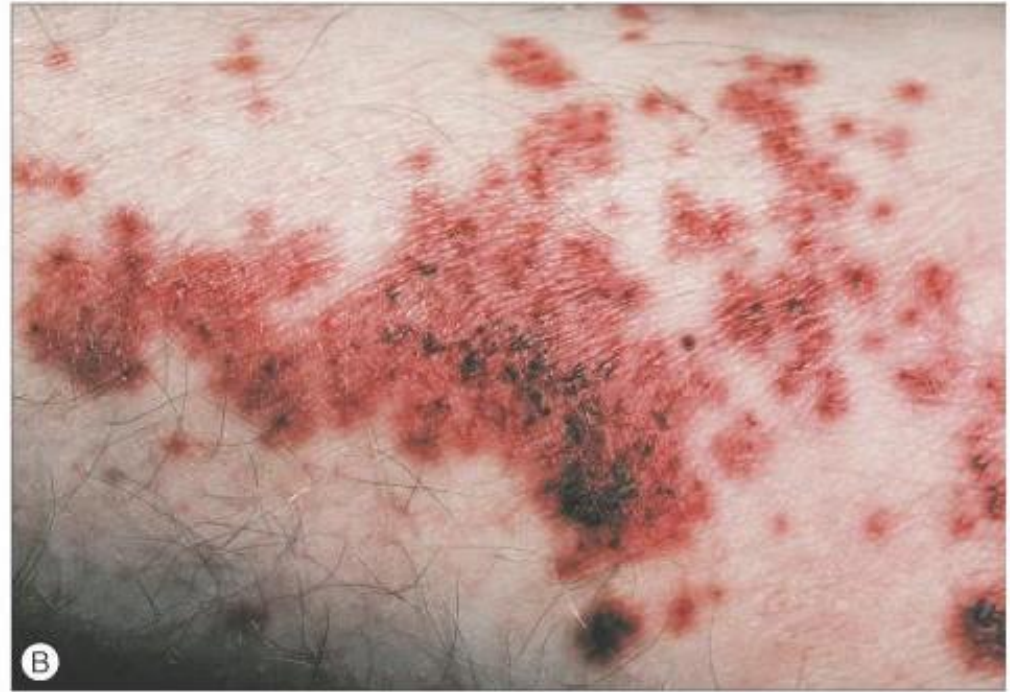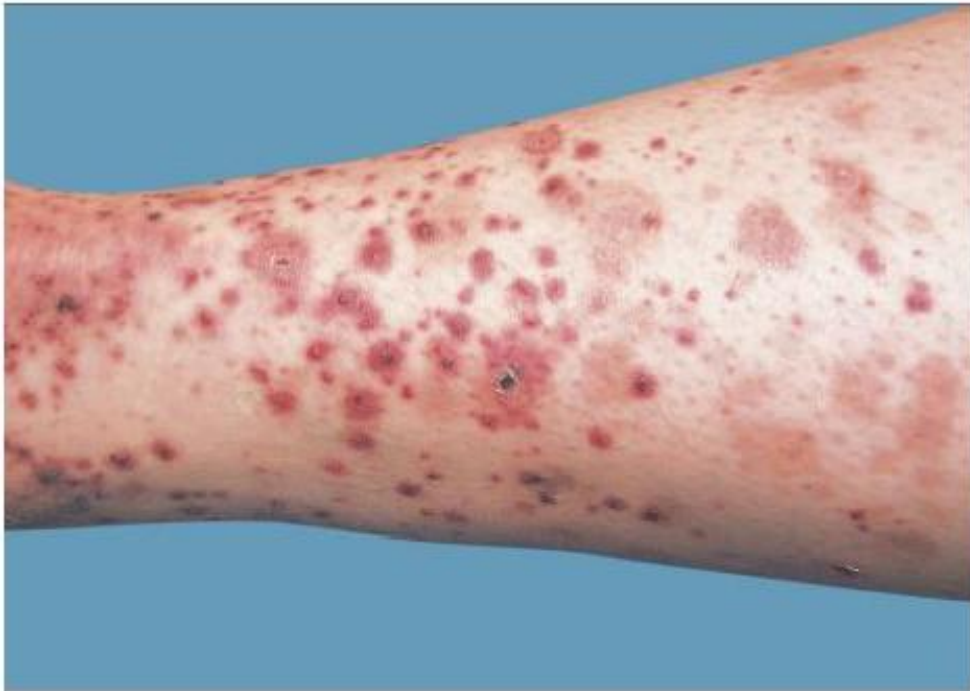Ehlers-Danlos Syndrome (Type IV)

Acquired:

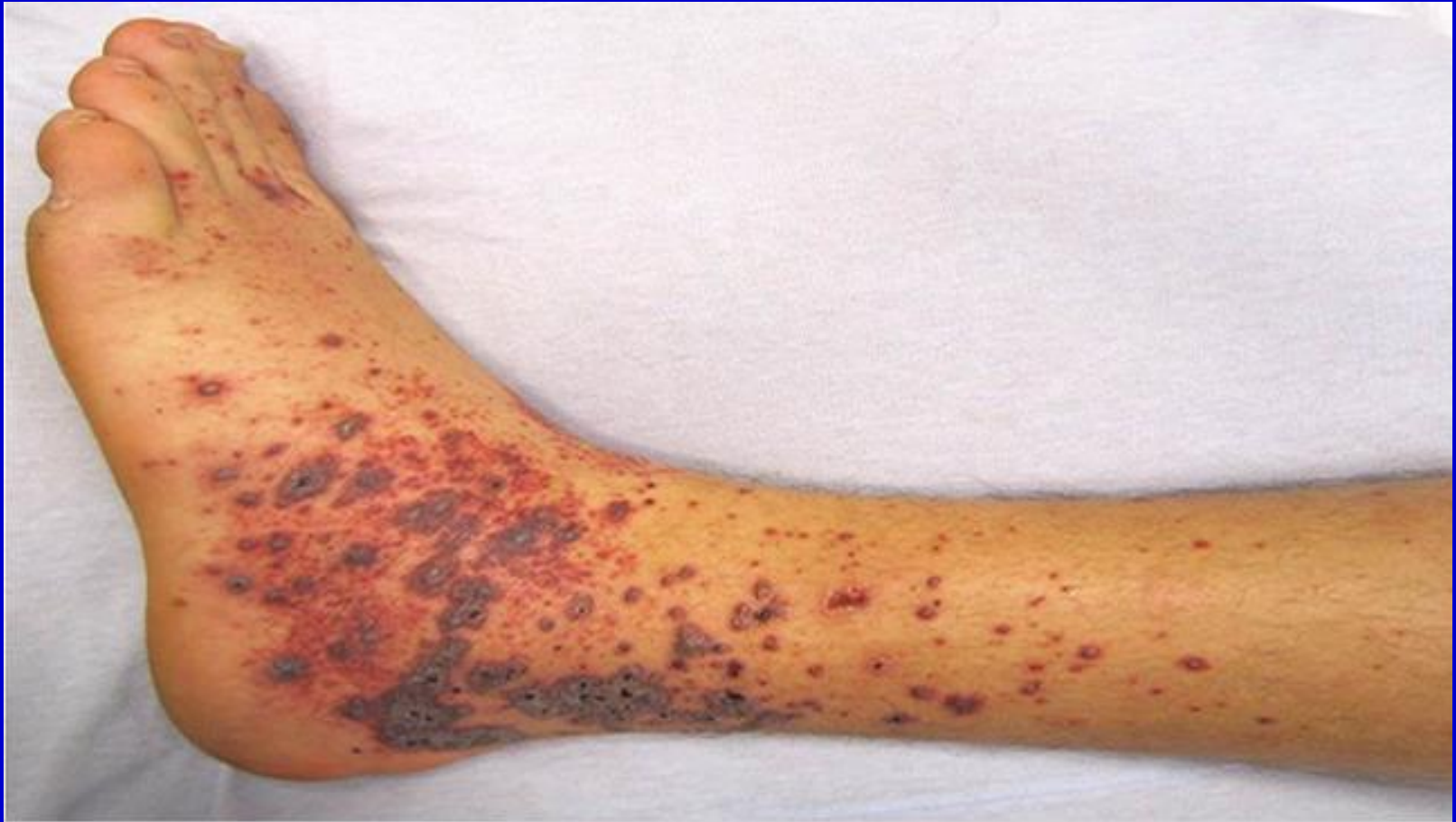Inflammation(Vasculitis)

Trauma

Vitamin c deficiency (scurvy)



vasculitis



Definition

A clinicopathologic process characterized by inflammatory destruction of blood vessels that results in occlusion or destruction of the vessel and ischemia of the tissues supplied by that vessel.

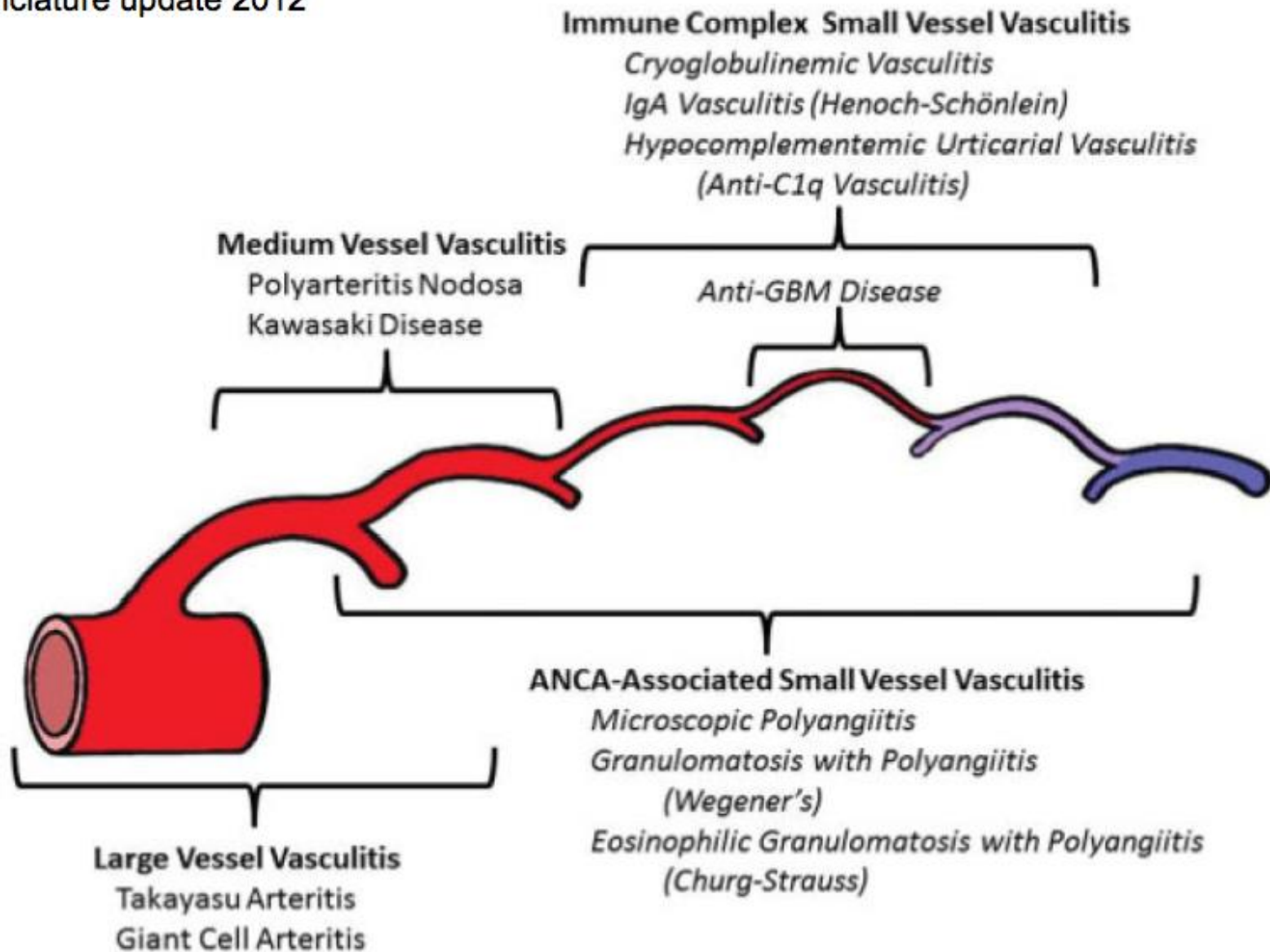
classification

Table 26.2 Chapel Hill consensus classification.

CHAPEL HILL CONSENSUS CLASSIFICATION
Large-vessel vasculitis
<ul style="list-style-type: none">• Giant cell arteritis• Takayasu's arteritis
Medium-vessel vasculitis
<ul style="list-style-type: none">• Classic polyarteritis nodosa• Kawasaki disease
Small-vessel vasculitis
<ul style="list-style-type: none">• Wegener's granulomatosis• Churg–Strauss syndrome• Microscopic polyangiitis (polyarteritis)• Henoch–Schönlein purpura• Essential cryoglobulinemia• Cutaneous leukocytoclastic vasculitis

Classification of Vasculitis

Chapel Hill Consensus Criteria
Nomenclature update 2012



Classification

-Large-vessel vasculitis

Aorta and the great vessels (subclavian, carotid)

Claudication, blindness, stroke

-Medium-vessel vasculitis

Arteries with muscular wall

*Mononeuritis multiplex (wrist/foot drop), mesenteric ischemia,
cutaneous ulcers*

-Small-vessel vasculitis

Capillaries, arterioles, venules

Palpable purpura, glomerulonephritis, pulmonary hemorrhage

Cutaneous small vessel vasculitis

*-Is the most common type of vasculitis
and it primarily affect post-capillary
venules*

Cutaneous small vessel vasculitis

Pathogenesis:

- Many forms of small-vessel vasculitis are felt to be caused by circulating immune complexes*
- These lodge in vessel walls and activate complement*

Cutaneous small vessel vasculitis

Table 3. Causes of cutaneous vasculitis^{5,6}

Infections Bacterial Viral Mycobacterial	<ul style="list-style-type: none"> • Streptococcal, meningococcal, urinary tract infections • Hepatitis B and C, HIV • Tuberculosis
Connective tissue disorders	<ul style="list-style-type: none"> • SLE and related conditions • Rheumatoid arthritis • Systemic sclerosis, Sjogren syndrome • Dermatomyositis • Medium vessel vasculitides (Wegener granulomatosis, polyarteritis nodosa, Churg-Strauss syndrome)
Malignancy	<ul style="list-style-type: none"> • Haematologic <ul style="list-style-type: none"> – myeloproliferative – lymphoma – monoclonal gammopathy – multiple myeloma
Drugs	Including antibiotics, antihypertensives
Idiopathic	Henoch-Schonlein purpura

Cutaneous small vessel vasculitis

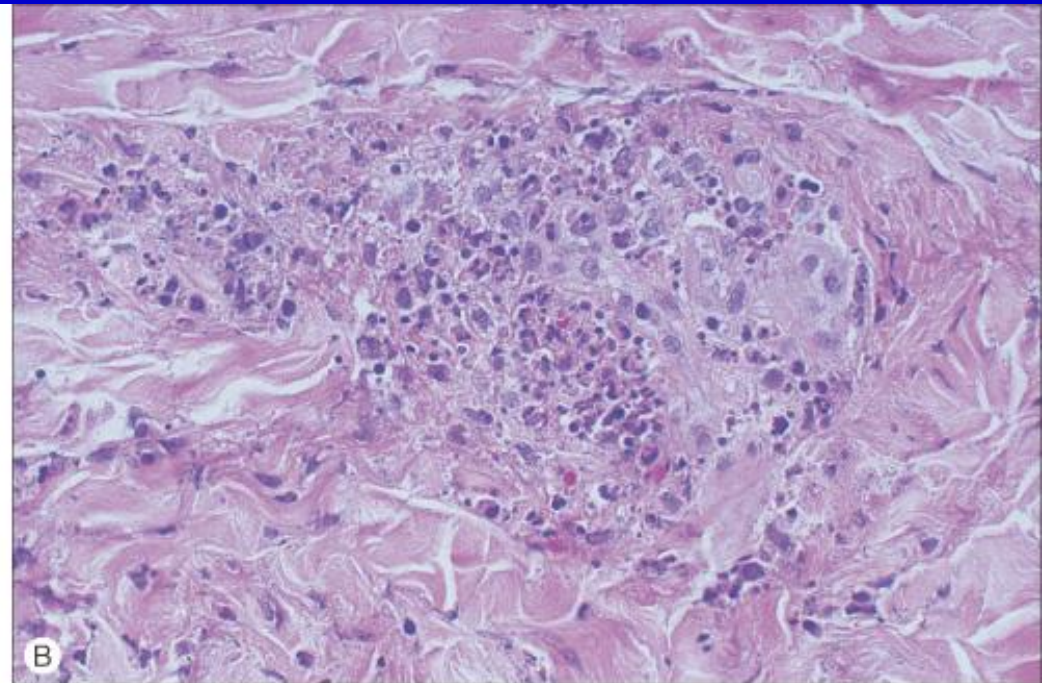
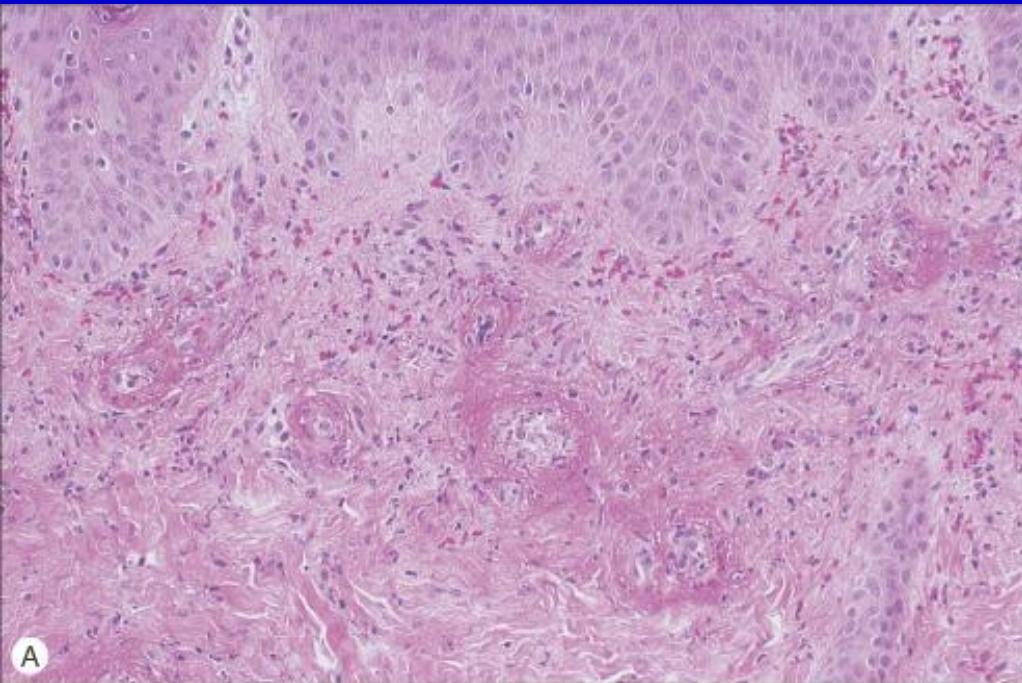
Palpable purpura is the hallmark

- Pinpoint to several centimeters
- Early on lesion may not be palpable, Papulonodular, vascular, bullous, pustular or ulcerated forms may develop
- Predominate on the ankles and lower legs i.e dependent areas

- may be localized to the skin or may manifest in other organs.*
- The internal organs affected most commonly include the joints, GIT, and the kidneys.*
- Renal involvement present as glomerulonephritis*
- The prognosis is good in the absence of internal involvement*

Histology

- *Agiocentric segmental inflammation, endothelial cell swelling, fibrinoid necrosis of blood vessel walls and a cellular infiltrate composed of neutrophil with RBC extravasation.*



Work up

- Detailed history and physical examination*
- History should focus on possible infectious disorders, prior associated diseases, drugs ingested, and a thorough review of systems*
- CBC, strep throat culture or ASO titer, Hep B & C serologies and ANA are a reasonable initial screen, renal profile*
- URINALYSIS FOR RBC , PROTIEN & CAST**

Table 26.4 Laboratory evaluation in known or suspected vasculitis.

LABORATORY EVALUATION IN KNOWN OR SUSPECTED VASCULITIS

System	Technique
Heme	Complete blood count with differential and platelet count, erythrocyte sedimentation rate (ESR), C-reactive protein
Renal	Urinalysis, BUN, creatinine
Liver	Abnormal liver function tests, hepatitis B and C antibody, cryoglobulins
Immunologic	Serum complement, rheumatoid factor, antinuclear antibody, anti-dsDNA, extractable nuclear antigen, antineutrophil cytoplasmic autoantibodies (ANCA)
Infectious	Blood and cultures
Head and neck	Sinus radiographs and CT
Pulmonary	Chest radiograph or CT
Cardiovascular	Electrocardiogram, creatine phosphokinase, echocardiogram
Neurologic	Nerve conduction studies
Musculoskeletal	Electromyography

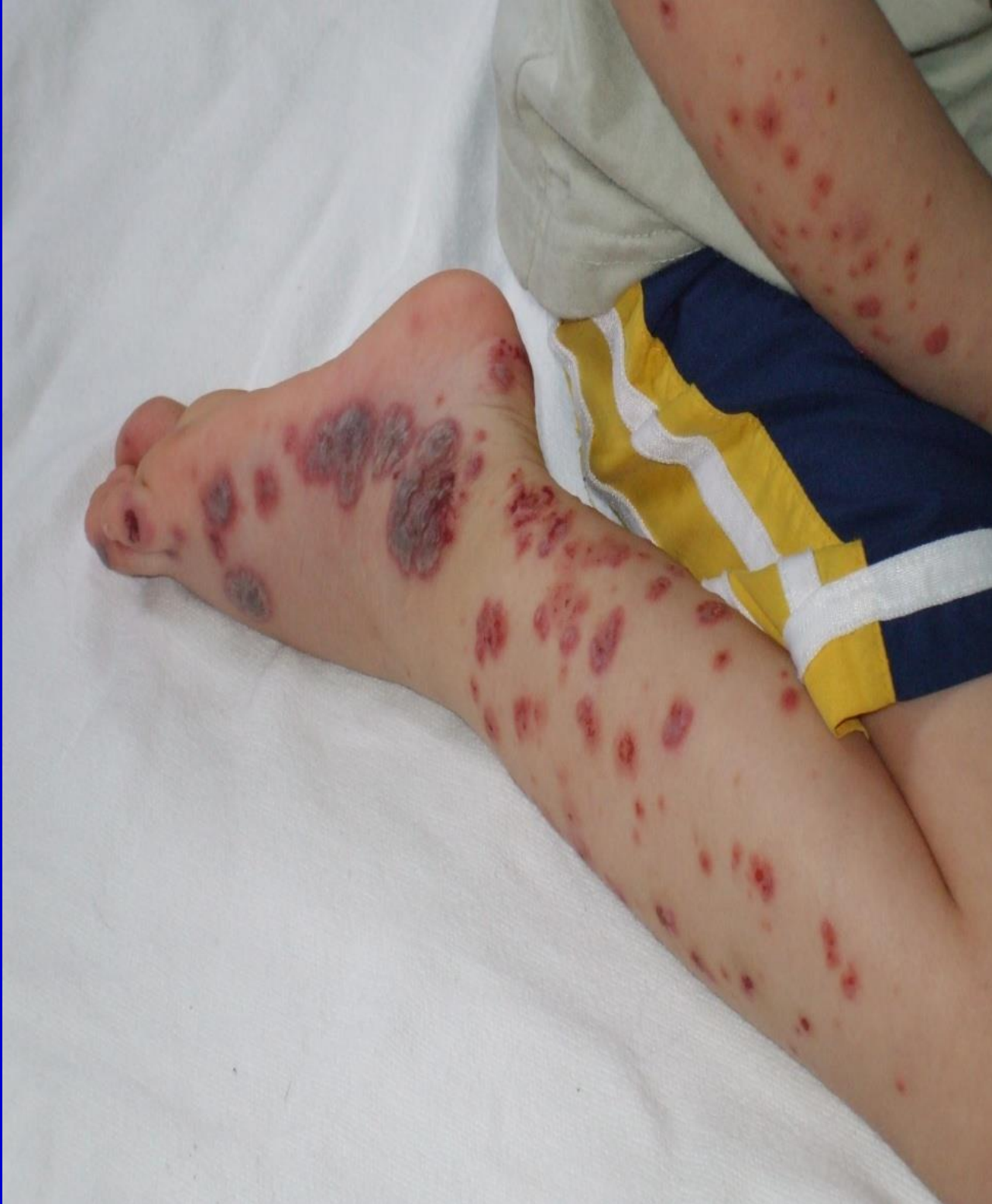Treatment

treatment of cause.

- Symptomatic treatment (if skin is only involved): rest ,NSAIDS ,Antihistamine*
- severe visceral involvement may require high doses of corticosteroids with or without an immunosuppressive agent*
- Immunosuppressive agents for rapidly progressive course and severe systemic involvement**

Henoch-Schönlein purpura HSP

- Primarily occurs in male children*
- peak age 4-8 years*
- Adults may be affected*
- A viral infection or streptococcal pharyngitis are the usual triggering event*
- In about 40 % of the cases the cutaneous manifestations are preceded by mild fever, headache, joint symptoms, and abdominal pain for up to 2 weeks*



- Characterized by intermittent purpura, arthralgia, abdominal pain, and renal disease*
- Typically purpura appears on the extensor surfaces of the extremities*
- Become hemorrhagic within a day and fades in 5 days*
- New crops appear over a few weeks*

May be associated with:

pulmonary hemorrhage

Abdominal pain and GI bleeding

- GI radiographs may show
“cobblestone” appearance

- Renal manifestations may occur in 25%
or more but only 5% end up with
ESRD

- The long-term prognosis in children with gross hematuria is very good; however, progressive glomerular disease and renal failure may develop in a small percentage*
- IgA, C3 and fibrin depositions have been demonstrated in biopsies of both involved and uninvolved skin by immunofluorescence techniques*

Thank you