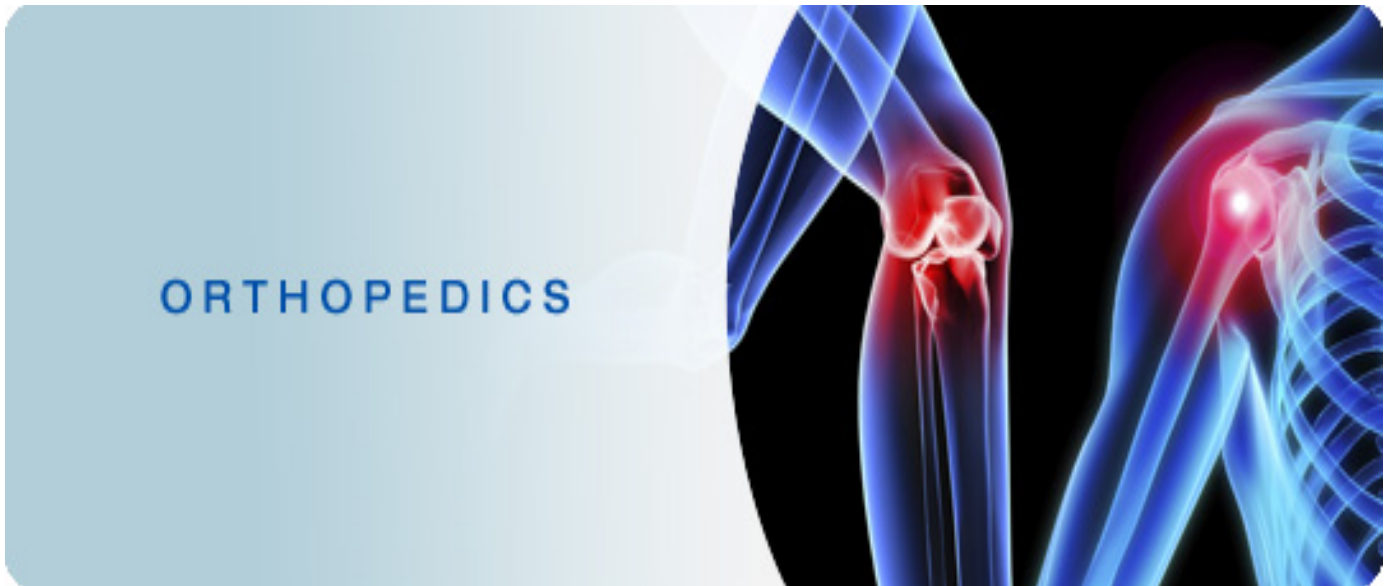


*Isn't it funny how someone can say "I believe in Allah " but still follow the Satan who by the way also, " believes " in Allah...*

## 430 ORTHOPEDICS TEAM



### Lecture: X-ray interpretation.

#### Team Members:

Faten Al-Mohideb.

Hanan Al-Salman.

Aliya Al-Awaji.

Hadeel Al-Ghamdi.

Ghadeer Al-Wuhayd.

Hissa Al-Balla.

Lujain Al-Yousef.

Nouf Al-Hammad.

Jawaher Al-Faraydi.

Hiba Al-Rahiem.

Nour Al-Enezi.

Wejdan Al-Swayyid.

Arwa Abudawood.

Leena Al-Shaman.

Areej Al-Qunaitir.

#### Team Leader:

**Ayedah Al-Ruhaimi.**

-The slides were provided by the doctor.

-Important notes in **Red**.

-Copied slides in **Black**.

-Doctor's notes in **green**.



## Objectives

- Review a systematic approach to interpreting orthopedic x-rays
- Review the language of fracture description

### Medical Decision Making is a Triad of:

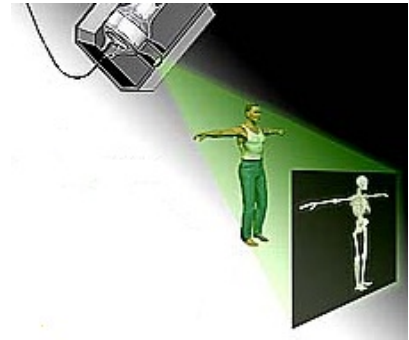
- History – from patients/records
- Physical Examination
- Confirming Studies – Imaging, Labs, etc.

### Imaging

- X-ray
- Ultrasound
- CT Scan
- MRI
- Nuclear Medicine

### X-RAY

- Radiation Source
- Patient Exposed
- Capture Image
- Interpret Image
- Ionizing Radiation
- Radiation damages cells
- Patient Blocks Transmission of Radiation
  - Soft tissues Less
  - Bones More
- Capture Image
  - Films
  - Digital
- Interpret Image
  - Radiologist
  - Orthopaedist
- Best for:
  - Hard tissue
  - Bones
  - Often combined with other imaging



#### Ionizing radiation hazard:

- 1) DNA damage incompatible with life → apoptosis.
- 2) DNA damage which is fixable → cell return normal.
- 3) DNA damage which leads to transformation either non harmful or harmful, if harmful → tumor.

### ABCs APPROACH:

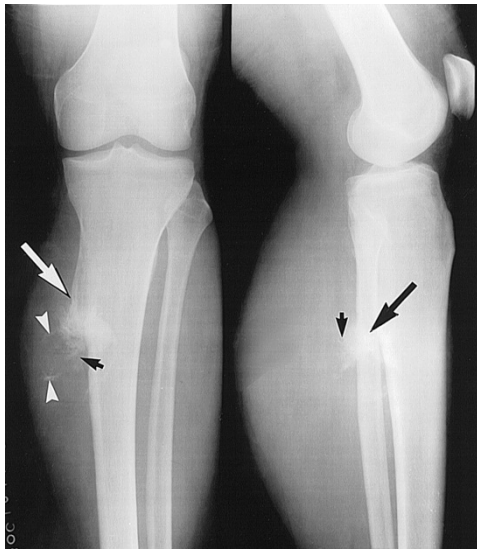- **Pre ABC:** identify pt, read provided info (the most important to confirm the x-ray belongs to him/her and avoid mistakes).

<b>A</b>	-Adequacy. -Alignment.
<b>B</b>	-Bones.
<b>C</b>	-Cartilage.
<b>S</b>	-Soft tissues

- Apply ABCs approach to every orthopedic film you evaluate.

## ADEQUACY

- All x-rays should have an adequate number of views.
  - Minimum of 2 views—AP and lateral (optimally two orthogonal views "2 perpendicular views" at least).
  - 3 views preferred (to enhance our brain to reconstruct a 3D image).
  - Joint above and joint below (if x-ray of joint: distal half of the proximal bone and proximal part of the distal bone. If x-ray of bone: the proximal and distal joints should be included).
- All x-rays should have adequate penetration (not the concern in this lect.)

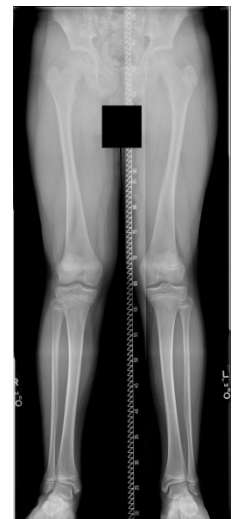

Inadequate: 2 orthogonal views (A-P and lateral). The distal half of femur is not shown. So, it's not adequate.

Note: in A-P view fibula is lateral. In lateral view fibula is posterior.

## ALIGNMENT

- Alignment: Anatomic relationship between bones on x-ray
  - Bone alignment vs other side
  - Bone alignment relative to proximal and distal bones
- 2 things to comment on alignment, first the distal part of the bone relative to the proximal (e.g. tibiovara → means the distal part of tibia is medial in relative to the proximal part of tibia) , second at the level of the joint, the distal bone relative to proximal bone (e.g. genu valgus → tibia is lateral in relative to femur. Genu=knee).
- Normal x-rays should have normal alignment
- Fractures and dislocations may affect the alignment on the x-ray
- In alignment you describe the distal part in reference to the proximal part.  
(Example: valgus means the distal part is lateral to the proximal part)
- 5-10 degree valgus in the knee is normal.



## BONES

1. Identify bone
2. Examine the whole bone for
  1. Discontinuity → fractures or lytic changes
  2. Change in bone shadow consistency → change in density
3. Describe bone abnormality
  1. Location (because treatment differ).
  2. Shape

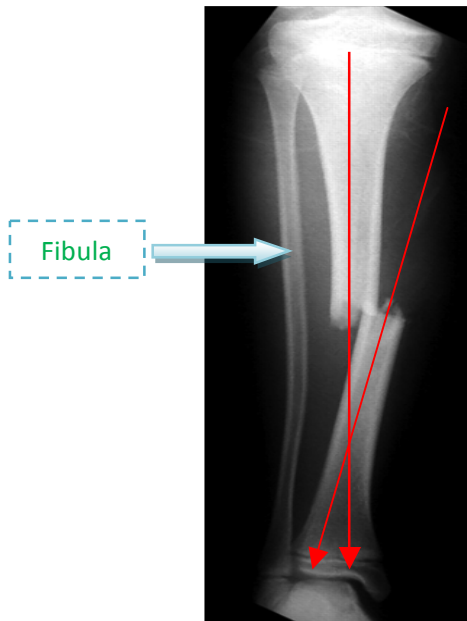
In deformity we describe two elements:

- 1) angulation
  - 2) translation which has 2 components:
    - magnitude
    - direction, if A-P view → medial or lateral translation. If lateral view → ant. & post.
- remember: we describe distal relative to proximal.

In AP view: deformity is described as either varus or valgus, if apex of angle lateral → varus deformity. If apex medial → valgus deformity.

In lateral view: deformity is described as either extension or flexion. If apex of angle anterior → extension deformity, if apex post. → flexion deformity.

The Mid Line



**Pre ABCs:** Patient identity unknown. No history or examination information. X-ray of right tibia

**A:** Not adequate because only one view (AP). And joint above is not fully visible.

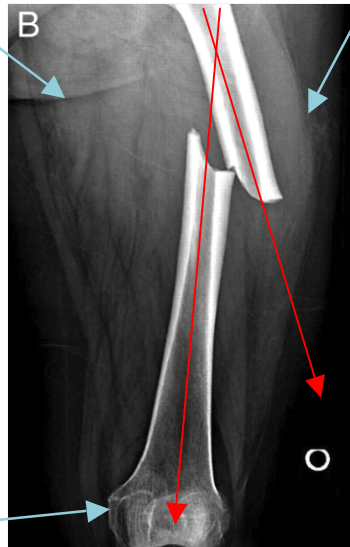
**B:** Transverse fracture (one cortices is opposite to the other cortices) in mid shaft of tibia, Distal part of tibia is going away from the mid line → valgus deformity, angulation 30 (always proximal is the reference & distal is the one which we are checking). Apex of the angle is medial. Translation (It's the displacement of distal fragment relative to the proximal one. If it's AP view we say either medial or lateral while if its lateral view we say either anterior or posterior): medial displacement 75-80%.

**C:** insignificant

**S:** insignificant

**Landmarks:**

- 1) Femur curve.
- 2) Gluteal line.
- 3) Medial epicondyle larger than



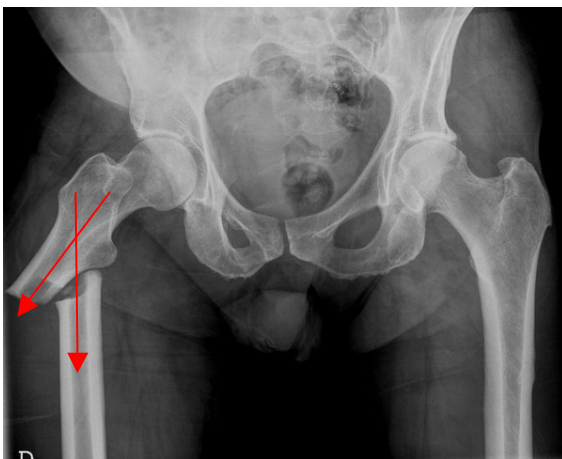
**Pre ABCs:** Patient identity unknown. No history or examination info. X-ray of right femur.

**A:** not adequate because only one view and the knee and hip joints are not visible.

**B:** short oblique fracture in mid shaft of right femur, apex of the angle is lateral, varus deformity, angulation 40-50. Translation: medial displacement of 90% approximately (or 10% apposition),

**C:** insignificant

**S:** insignificant



**Pre ABCs:** Patient identity unknown. No history or examination information. X-ray of the pelvis.

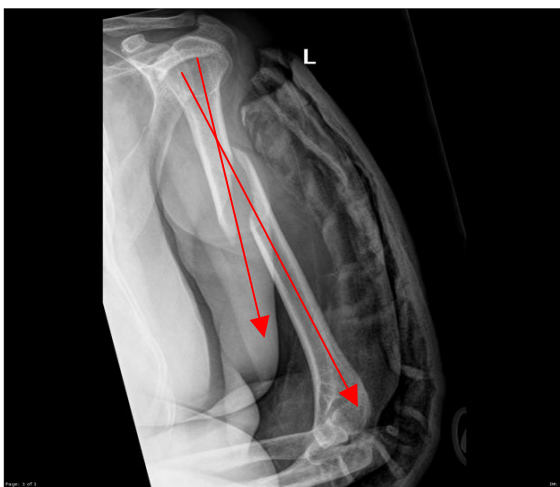
**A:** not adequate because only one view and the distal femur is not fully visible.

**B:** short oblique fracture in the upper third of right femur, apex of angle is lateral, varus deformity, angulation 60°.

Translation: 100% medial displacement.

**C:** insignificant

**S:** insignificant



**Pre ABCs:** Patient identity unknown. No history or examination information. X-ray of left humerus.

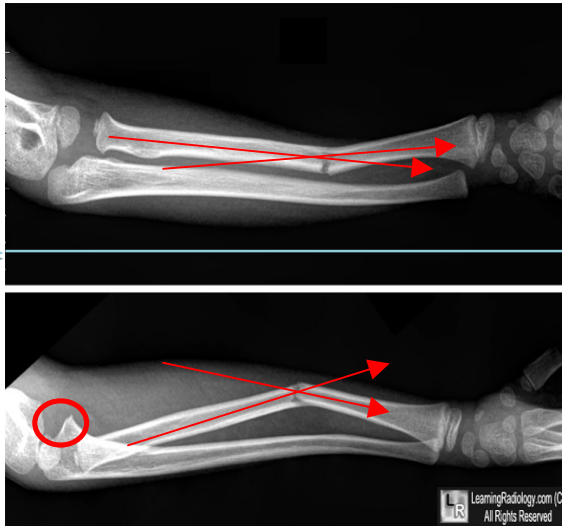
**A:** not adequate because only one view.

**B:** complete spiral fracture at shaft of left humerus. Apex of angle anterior. Extension deformity, we can't say here varus or valgus because its lateral view not AP view.

Translation: 100% posterior displacement.

**C:** insignificant

**S:** insignificant



The Mid  
Line

Landmarks: thumb and coronoid process (red circle) is always anterior. Olecranon is posterior.

**Pre ABCs:** Patient identity unknown. No history or examination information. X-ray of forearm.

**A:** adequate x-ray

**B:** transverse fracture in lower third of radius, A) A-P → apex of angle medial. Valgus deformity (distal part away from midline). Angulation of 20-30°.

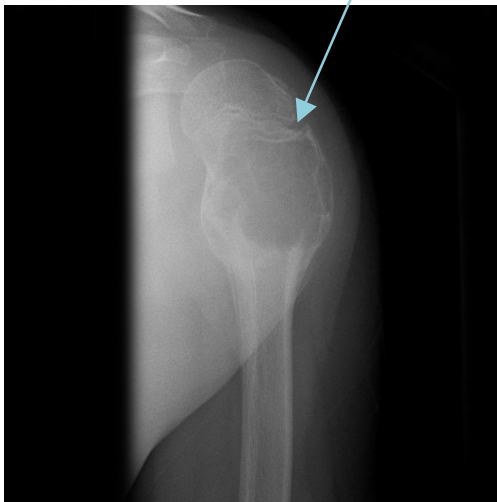
B) lateral view → apex of angle is anterior, extension deformity, angulation 30°.

N.B. in lateral view you describe the deformity as extension/flexion not varus/valgus.

**C:** insignificant

**S:** insignificant

it's a growth plate not a fracture.



**Pre ABCs:** Patient identity unknown. No history or examination information. X-ray of proximal humerus.

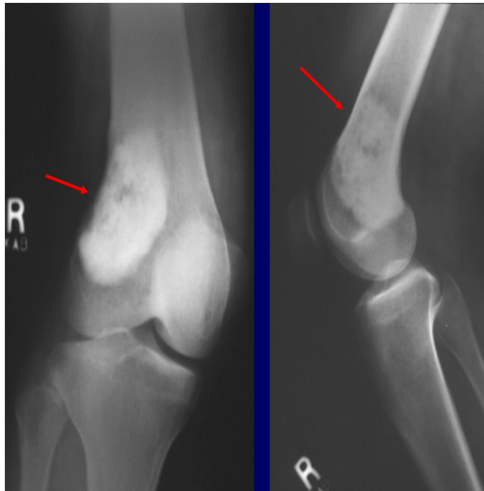
**A:** not adequate because only one view and no joint above joint below.

**B:** Hypodense well circumscribed lesion with septae and ballooning, not clear if there is a fracture or not.

**C:** Cartilage can't be seen in x-ray because it's less dense. So, instead of that we look to the joint space if its decrease this means that the cartilage is gone (e.g. in osteoarthritis). But if you see increase in the joint space this means there is instability (the collateral ligaments aren't there).

**S:** insignificant





**Pre ABCs:** patient identity unknown. No history or examination information. X-ray of right femur.

**A:** not adequate because above and below the joint is not fully visible.

**B: AP view:** hyperdense well circumscribed lesion with some hypodense areas in metaphysis of distal right femur.

**lateral view:** lesion is occupying the full thickness.

**C:** decreased joint space at the lateral side.

**S**

## CARTILAGE

- Cartilage
  - joint spaces on x-rays
  - you cannot actually see cartilage on x-rays
- Widening of joint spaces → signifies ligamentous injury and/or fractures
- Narrowing of joint spaces → arthritis

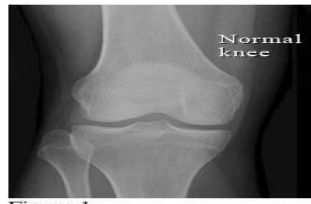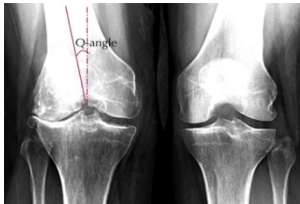


Figure 1

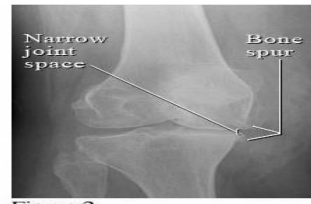
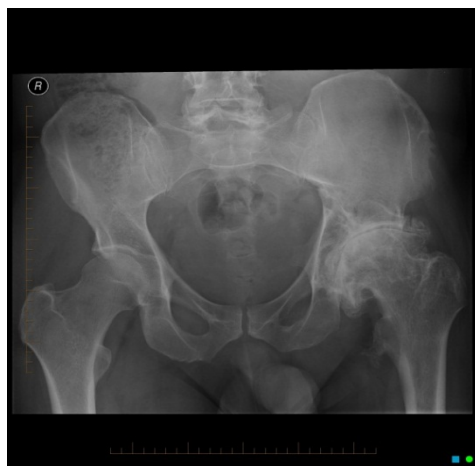
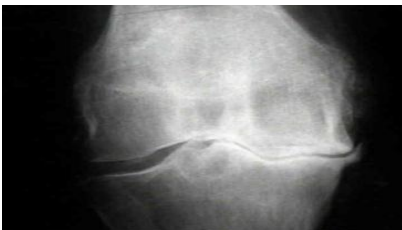

Figure 2



**Pre ABCs:** Patient identity unknown. No history or examination information. X-ray of pelvis.

**A:** not adequate because only one view.

**B:** left femoral head is deformed and distorted.

**C:** left femoral head is deformed and distorted, no joint space, cartilage is worn out, sclerosis, multiple osteophyte.

The right side has arthritis but not as bad as the other side.

**S:** insignificant

## SOFT TISSUES

- Soft tissues implies to look for soft tissue swelling and joint effusions
- These can be signs of
  - Trauma
  - occult fractures
  - Infection
  - Tumors

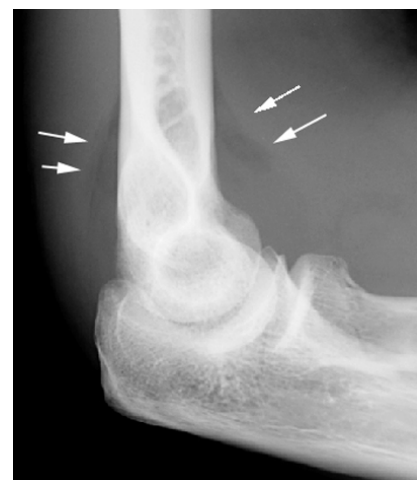## REVIEW: ABCs

- |          |  |
|----------|--|
| <b>A</b> | - Assess <i>adequacy</i> of x-ray which includes proper number of views and penetration.<br>- Assess <i>alignment</i> of x-rays. |
| <b>B</b> | - Examine <i>bones</i> throughout their entire length for fracture lines and/or distortions.                                     |
| <b>C</b> | - Examine <i>cartilages</i> (joint spaces) for widening.   |
| <b>S</b> | - Assess <i>soft tissues</i> for swelling/effusions.   |

## EXAMPLES:

### EXAMPLE # 1

- Inadequate x-ray only one view disatl and proximal not visualized.
- This x-ray demonstrates a lateral elbow x-ray.
- Bone is normal
- There is swelling anteriorly which is displaced known as a pathologic anterior fat pad sign
- There is swelling posteriorly known as a posterior fat pad sign
- Both of these are signs of an occult fracture although none are visualized on this x-ray
- Remember, *soft tissue swelling can be a sign of occult fracture!*

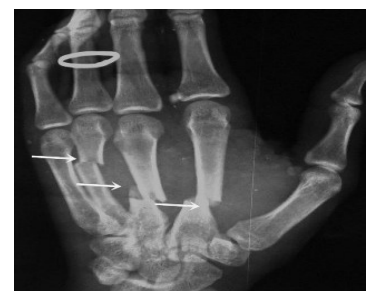

Capsule of joint is pushed by fluid: what could be the cause?

- 1) Septic arthritis
- 2) Trauma (hemarthrosis)
- 3) RA (effusion from inflammation)

### EXAMPLE # 2... WHERE ARE THE FRACTURES?

- If you follow ABCs, you will notice there are problems with alignment on this x-ray (A)
- (B)...You will notice there are fracture lines through the 2<sup>nd</sup>, 3<sup>rd</sup>, and 4<sup>th</sup> metacarpals
- These are 2<sup>nd</sup>, 3<sup>rd</sup>, and 4<sup>th</sup>, mid shaft metacarpal





fractures.

- A teaching point: Notice the ring on this film. Always remove rings of patients with fractured extremities because swelling may preclude removal later.

## LANGUAGE OF FRACTURES

- Important for use to describe x-rays in medical terminology.
- Improves communication with orthopedic consultants
- Things you must describe (clinical and x-ray):
  - Open vs Closed fracture
  - Anatomic location of fracture
  - Fracture line
  - Relationship of fracture fragments
  - Neurovascular status

## OPEN VS CLOSED

- Must describe to a consultant if fracture is open or closed
- Closed fracture
  - Simple fracture
  - No open wounds of skin near fracture
- Open fracture
  - Compound fracture
  - Cutaneous (open wounds) of skin near fracture site. Bone may protrude from skin
  - Open fractures are open complete displaced and/or comminuted

## OPEN FRACTURES

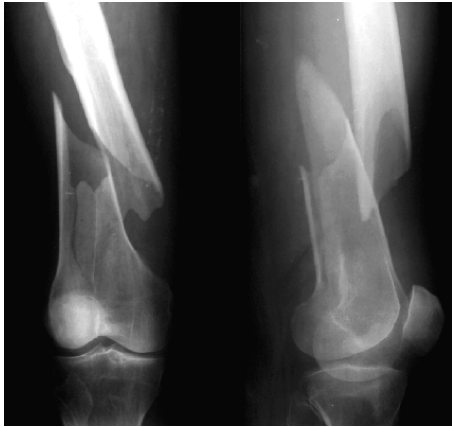- Orthopedic emergency
- Requires emergency orthopedic consultation
- Bleeding must be controlled
- Management
  - IV antibiotics
  - Tetanus prophylaxis
  - Pain control
  - Surgery for washout and reduction

## ANATOMIC LOCATION

- Describe the precise anatomic location of the fracture
- Include if it is left or right sided bone
- Include name of bone

- Include location:
  - Proximal...Mid...Distal
  - To aid in this, divide bone into 1/3rds

### FOR EXAMPLE....WHERE IS THIS LOCATED?



**Pre ABCs:** patient identity unknown. No history or examination information. X-ray of femur.

**A:** not adequate because no joint below joint above

**B:** metaphyseal spiral fracture with comminution, (or fracture in the distal shaft of femur). Apex of angle medial, valgus deformity, angulation 200. 100% lateral translation.

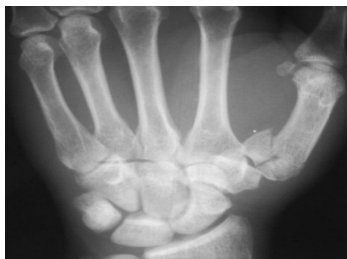**C:** insignificant      **S:** insignificant

- This is a closed L distal femur fracture.
- The main thing I want you to take from this example is the description of location.

### ANATOMIC LOCATION

- Besides location, it is helpful to describe if the location of the fracture involves the joint space—intra-articular

INTRA-ARTICULAR  
FRACTURE OF  
BASE 1<sup>ST</sup>  
METACARPAL



**Pre ABCs:** patient identity unknown. No history or examination information. X-ray of hand.

**A:** inadequate because only one view.

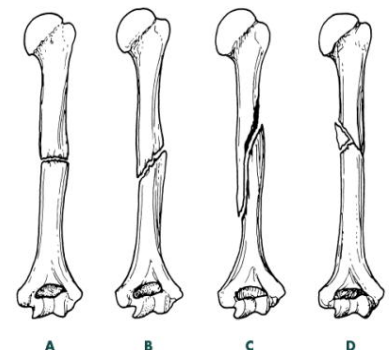
**B:** multiple fragmental fracture of base 1<sup>st</sup> metacarpal bone.

**C:** insignificant

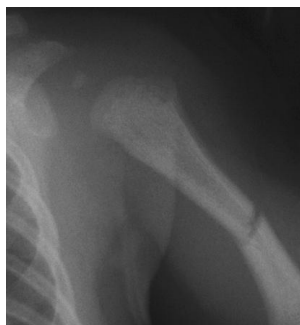**S:** insignificant

### FRACTURE LINES

- Next, it is imperative to describe the type of fracture line
- There are several types of fracture lines
- A is a transverse fracture
- B is an oblique fracture
- C is a spiral fracture
- D is a comminuted fracture
- There is also an impacted fracture where fracture ends are compressed together



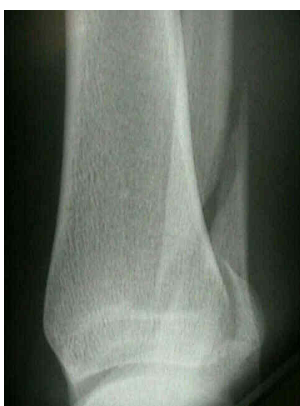### WHAT TYPE OF FRACTURE LINE IS THIS???



ANS: TRANSVERSE FRACTURE

- Transverse fractures occur perpendicular to the long axis of the bone.
- To fully describe the fracture, this is a closed midshaft transverse humerus fracture.

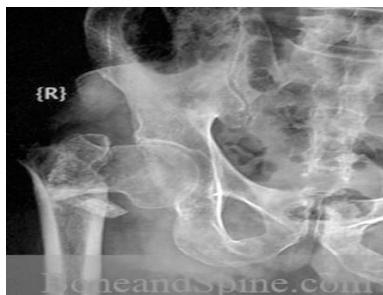### ANOTHER EXAMPLE OF FRACTURE LINE...



ANS: SPIRAL FRACTURE

- Spiral fractures occur in a spiral fashion along the long axis of the bone
- They are usually caused by a rotational force
- To fully describe the fracture, this is a closed distal spiral fracture of the fibula

### ONE MORE EXAMPLE...



ANS: COMMINUTED FRACTURE

- Comminuted fractures are those with 2 or more bone fragments are present
- Sometimes difficult to appreciate on x-ray but will clearly show on CT scan
- To fully describe the fracture, this is a closed R comminuted intertrochanteric fracture

### FRACTURE FRAGMENTS

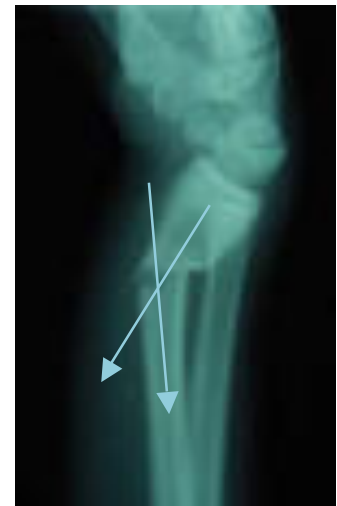- Terms to be familiar with when describing the relationship of fracture fragments
  - Alignment
  - Angulation
  - Apposition
  - Displacement
  - Bayonette apposition
  - Distraction
  - Dislocation

## ALIGNMENT/ANGULATION

- Alignment is the relationship in the longitudinal axis of one bone to another
- Angulation is any deviation from normal alignment
- Angulation is described in degrees of angulation of the distal fragment in relation to the proximal fragment—to measure angle draw lines through normal axis of bone and fracture fragment

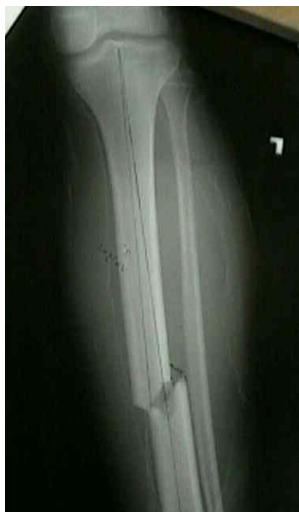## OTHER TERMS

- Apposition: amount of end to end contact of the fracture fragments
- Displacement: use interchangeably with apposition
- Bayonette apposition: overlap of fracture fragments
- Distraction: displacement in the longitudinal axis of the bones
- Dislocation: disruption of normal relationship of articular surfaces



20 DEGREES OF ANGULATION

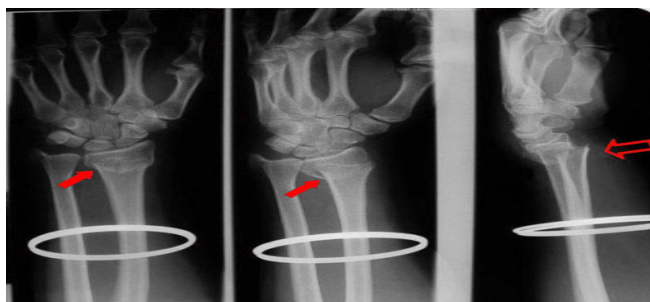
## DESCRIBE FRACTURE FRAGMENTS



### ANSWER

- This is a closed midshaft tibial fracture....But how do we describe the fragments?
- This is an example of partial apposition; note part of the fracture fragments are touching each other
- Alternatively you can describe this as displaced 1/3 the thickness of the bone
- Remember apposition and displacement are interchangeable—we tend to describe displacement
- Final answer: Closed midshaft tibial fracture with moderate (33%) displacement

## ANOTHER ONE...

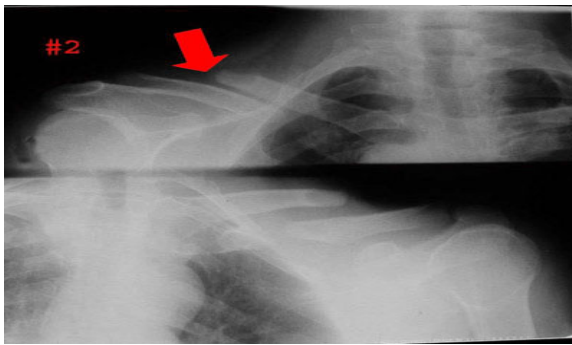


### ANSWER

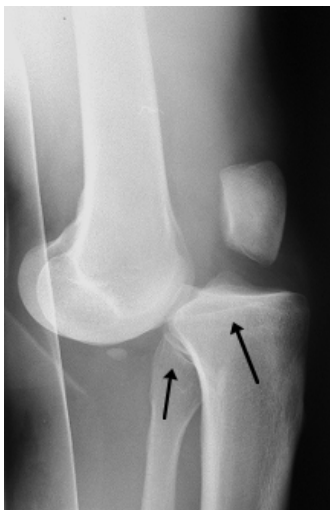
- There are 2 fractures on this film

- Closed distal radius fracture with complete displacement. Also there is an ulnar styloid fracture which is also displaced
- The displacement is especially prominent on the lateral view highlighting the importance of multiple views.
- There may be intra-articular involvement as joint space is close by
- Remember, remove all jewelry from extremity fractures

### BAYONETTE APPPOSITION



### DISLOCATION



- Note the dislocation; the articular surfaces of the knee no longer maintain their normal relationship
- Dislocations are named by the position of the distal segment
- This is an Anterior knee dislocation.

**Landmarks to help identify the direction of dislocation:**  
Fibula always posterior, patella anterior & condyles posterior.

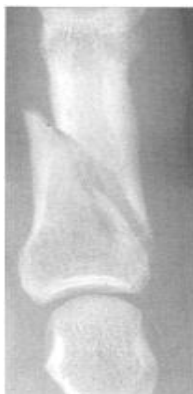### NEUROVASCULAR STATUS

- Finally when communicating a fracture, you will want to describe if the patient has any neurovascular deficits
- This is determined clinically

## LANGUAGE OF FRACTURES

- To review, when seeing a patient with a fracture and the x-ray, describe the following:
  - Open vs closed fracture
  - Anatomic location of fracture (distal, mid, proximal) and if fracture is intra-articular
  - Fracture line (transverse, oblique, spiral, comminuted)
  - Relationship of fracture fragments (angulation, displacement, dislocation, etc)
  - Neurovascular status

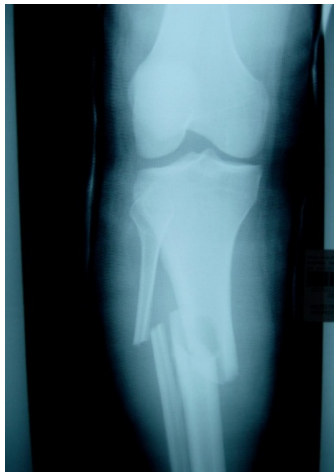### DESCRIBE THIS R MIDDLE PHALANX FRACTURE



#### ANSWER

- Oblique fracture of midshaft of R 4<sup>th</sup> middle phalanx with minimal displacement and no angulation
- Remember to comment if open vs closed & neurovascular status

### DESCRIBE TO ORTHO ATTENDING...



#### ANSWER

- This one is a bit more challenging!
- R midshaft tibia fracture displaced ½ the thickness of the bone without angulation; also there is bayonette appositioning of the fracture fragments
- R midshaft fibular fracture with complete displacement and
- Also comment if the fracture is open vs closed & neurovascular status