

***Head & Neck Tumours***  
***Part I***

**Khalid Hussain AL-Qahtani**

**MD, MSc, FRCS(c)**

**Medical Director KAUH**

**Associate Professor & Consultant**

**Head & Neck Oncology**

**& Skull Base Surgeon**

**KSU, KFMC**

**Riyadh, Saudi Arabia**

# *Content*



- **Neck Masses**
- **Thyroid Gland**

# *Evaluation and Management of the Patient with a Neck Mass*



- **Introduction**
- **Diagnostic Steps**
- **DDX**

# *Introduction*



- **Common clinical finding**
- **All age groups**
- **Very complex differential diagnosis**
- **Systematic approach essential**

# *Diagnostic Steps*



- **History**
  - Developmental time course
  - Associated symptoms (dysphagia, otalgia, voice)
  - Personal habits (tobacco, alcohol)
  - Previous irradiation or surgery
- **Physical Examination**
  - Complete head and neck exam (visualize & palpate)
  - Emphasis on location, mobility and consistency

# ***Risk Factors***



- **Smoking**
- **Alcohol**
- **Wood dust exposure**
- **Sun exposure**
- **Previous burn or scar**
- **Family history**
- **Immune deficiency**
- **History of other cancer**

# *Alarming sings*



- **Neck mass**
- **Hoarseness**
- **Unilateral nasal blockage**
  - In children
  - In adult and elderly
- **Ear pain with normal exam**
- **Epistaxis**
  - In adult
  - In children
- **None healing ulcer**
- **Facial weakness or numbness**
- **Dysphagia or odynophagia**
- **Diplopia**
- **Pain with denture or poorly fitting denture**

# *General Considerations*

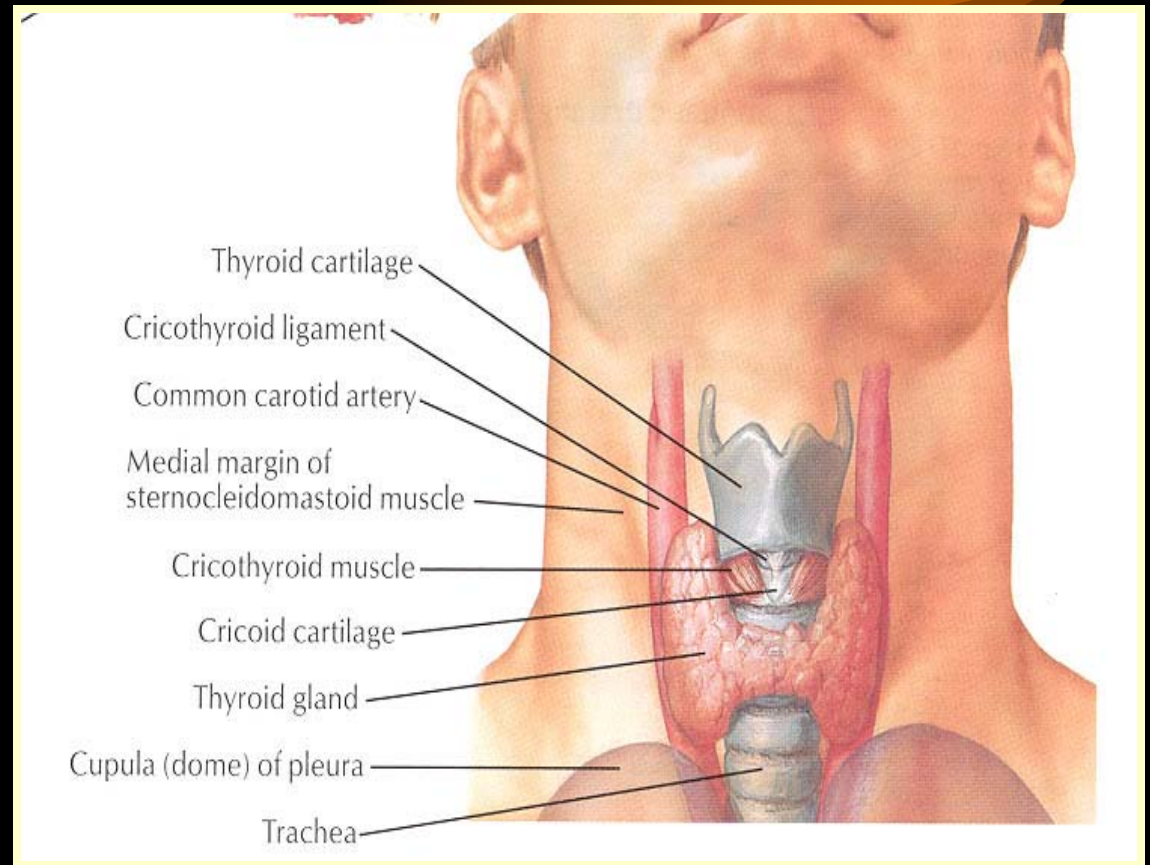


- **Location**
  - Congenital masses: consistent in location
  - Metastatic masses: key to primary lesion
- **Patient age**
  - Pediatrics (0 – 15 years): mostly benign
  - Young adults (16 – 40 years): similar to pediatric
  - old adults (>40 years): High risk of malignancy
- **Time Line**



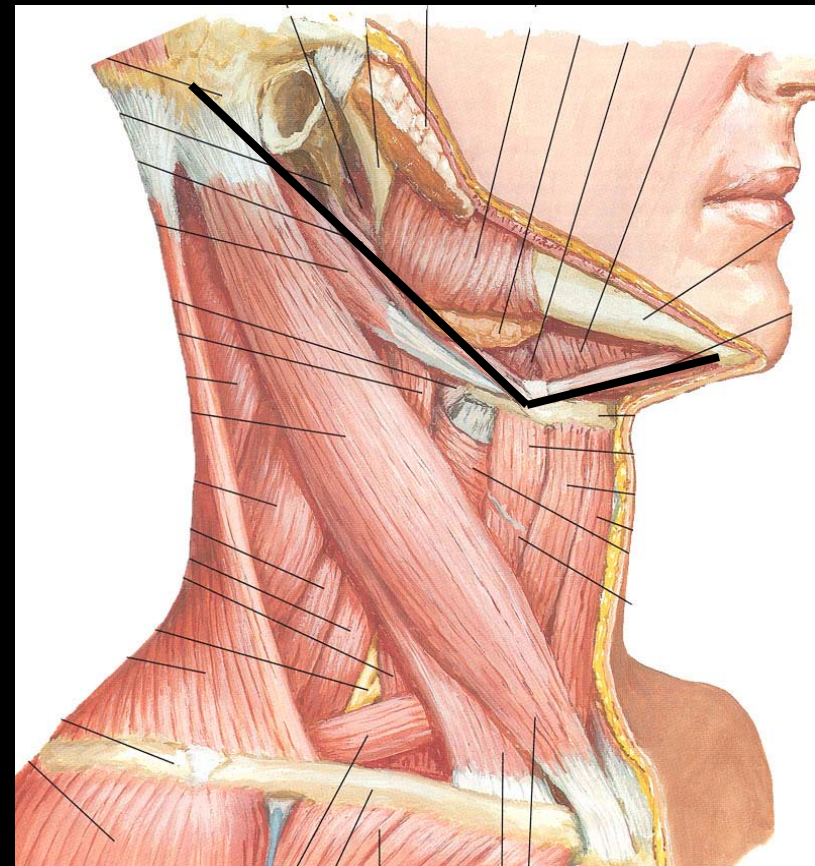
# *Anatomical Considerations*

- **Prominent landmarks**
- **Triangles of the neck**
  - Lymphatic levels
- **Carotid bulb**



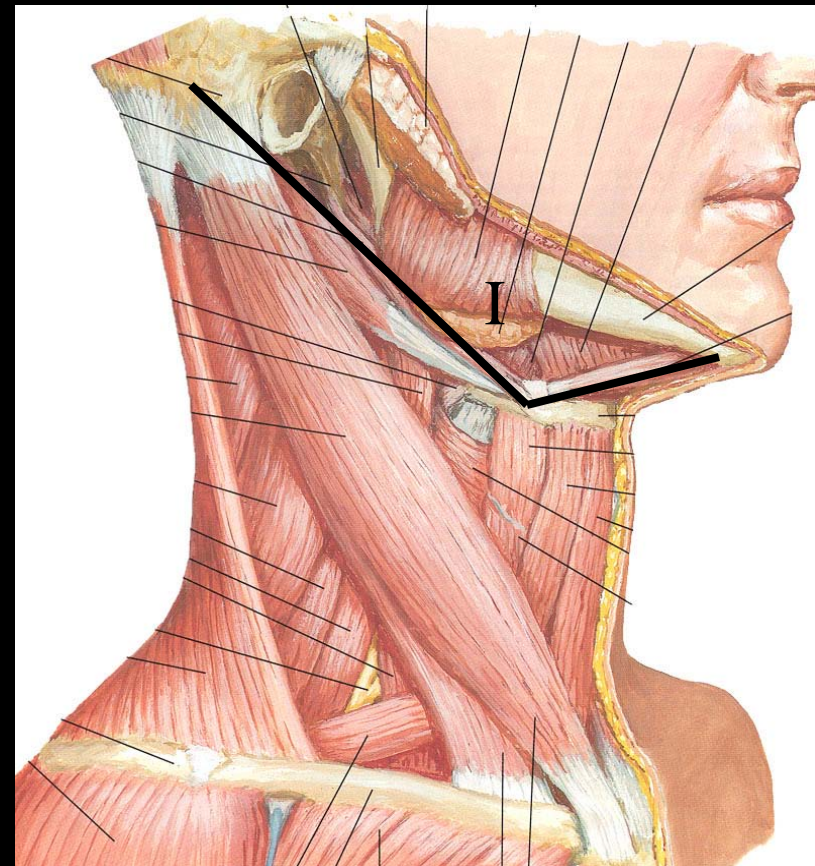
# *Anatomical Considerations*

- **Prominent landmarks**
- **Triangles of the neck**
  - Lymphatic levels
- **Carotid bulb**



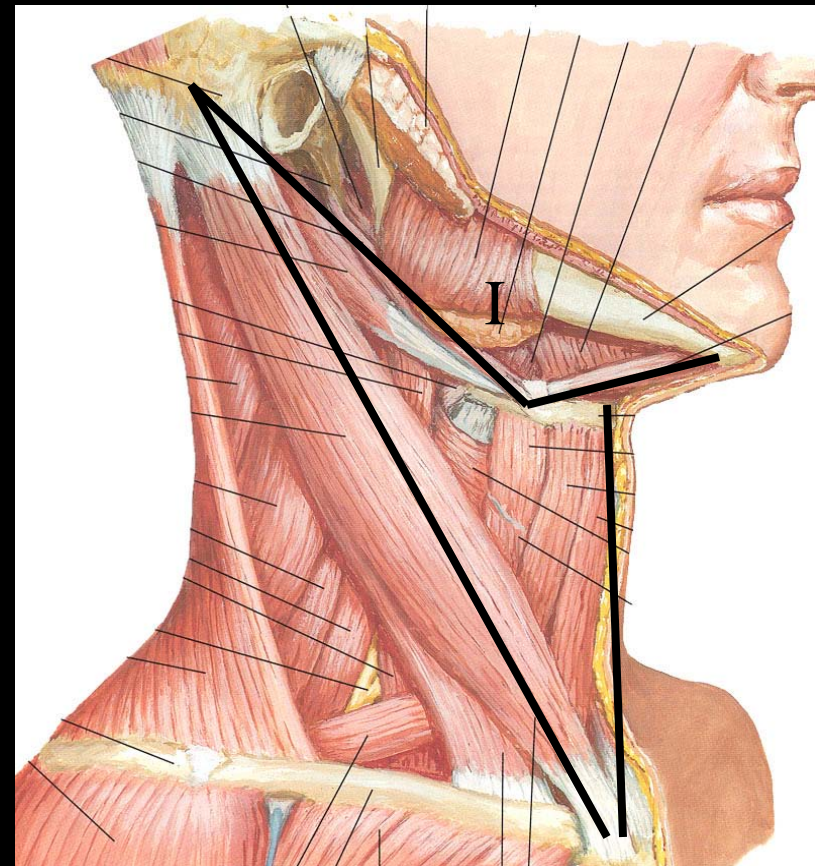
# *Anatomical Considerations*

- **Prominent landmarks**
- **Triangles of the neck**
  - Lymphatic levels
- **Carotid bulb**



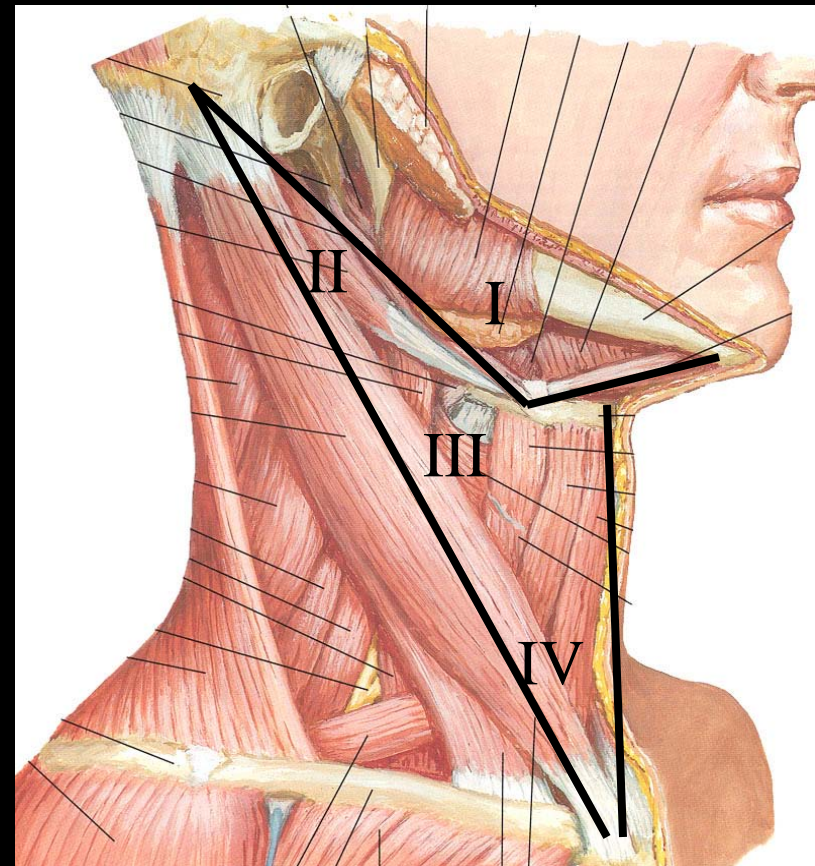
# *Anatomical Considerations*

- **Prominent landmarks**
- **Triangles of the neck**
  - Lymphatic levels
- **Carotid bulb**



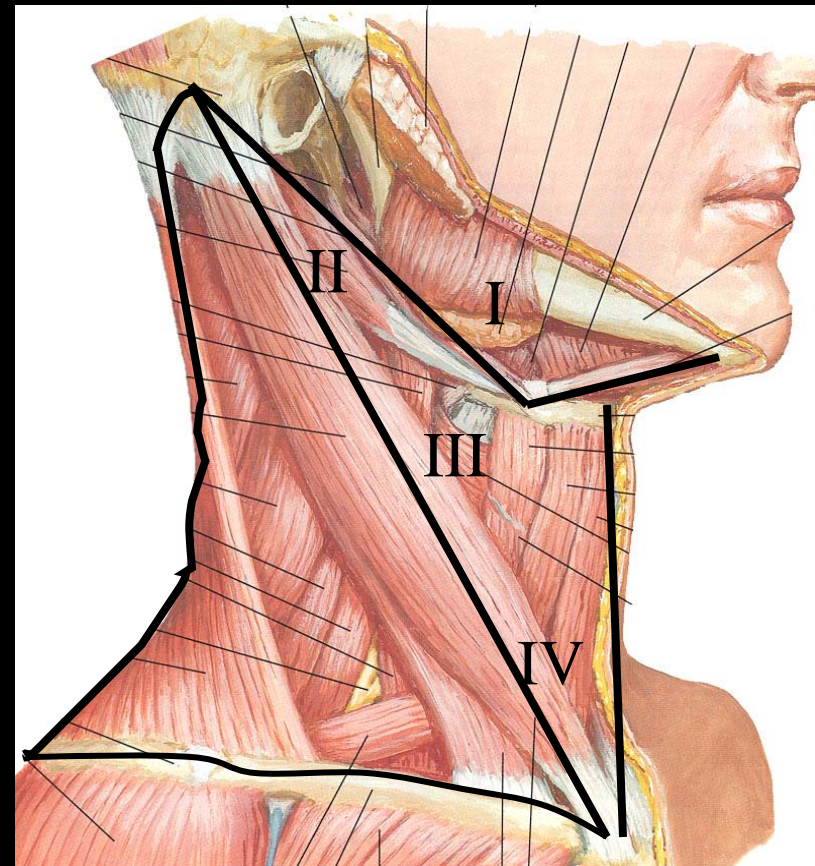
# *Anatomical Considerations*

- **Prominent landmarks**
- **Triangles of the neck**
  - Lymphatic levels
- **Carotid bulb**



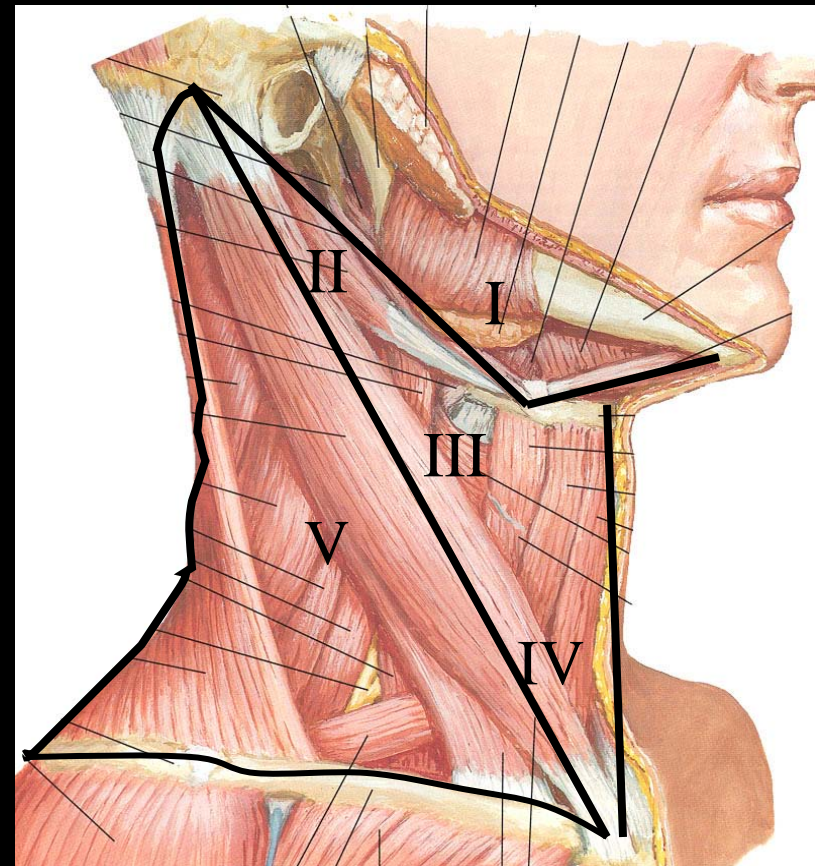
# *Anatomical Considerations*

- **Prominent landmarks**
- **Triangles of the neck**
  - Lymphatic levels
- **Carotid bulb**



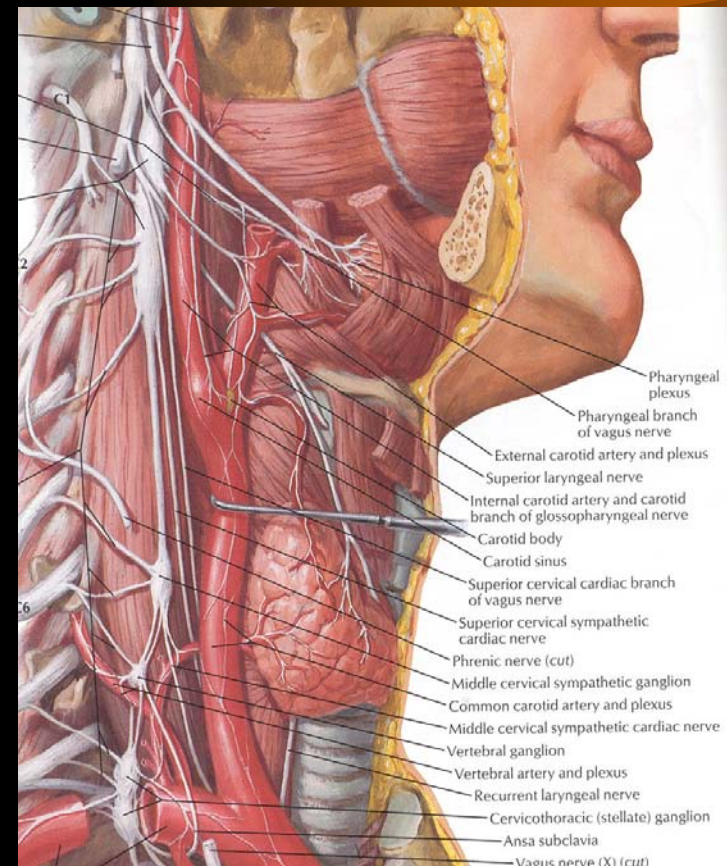
# *Anatomical Considerations*

- **Prominent landmarks**
- **Triangles of the neck**
  - Lymphatic levels
- **Carotid bulb**

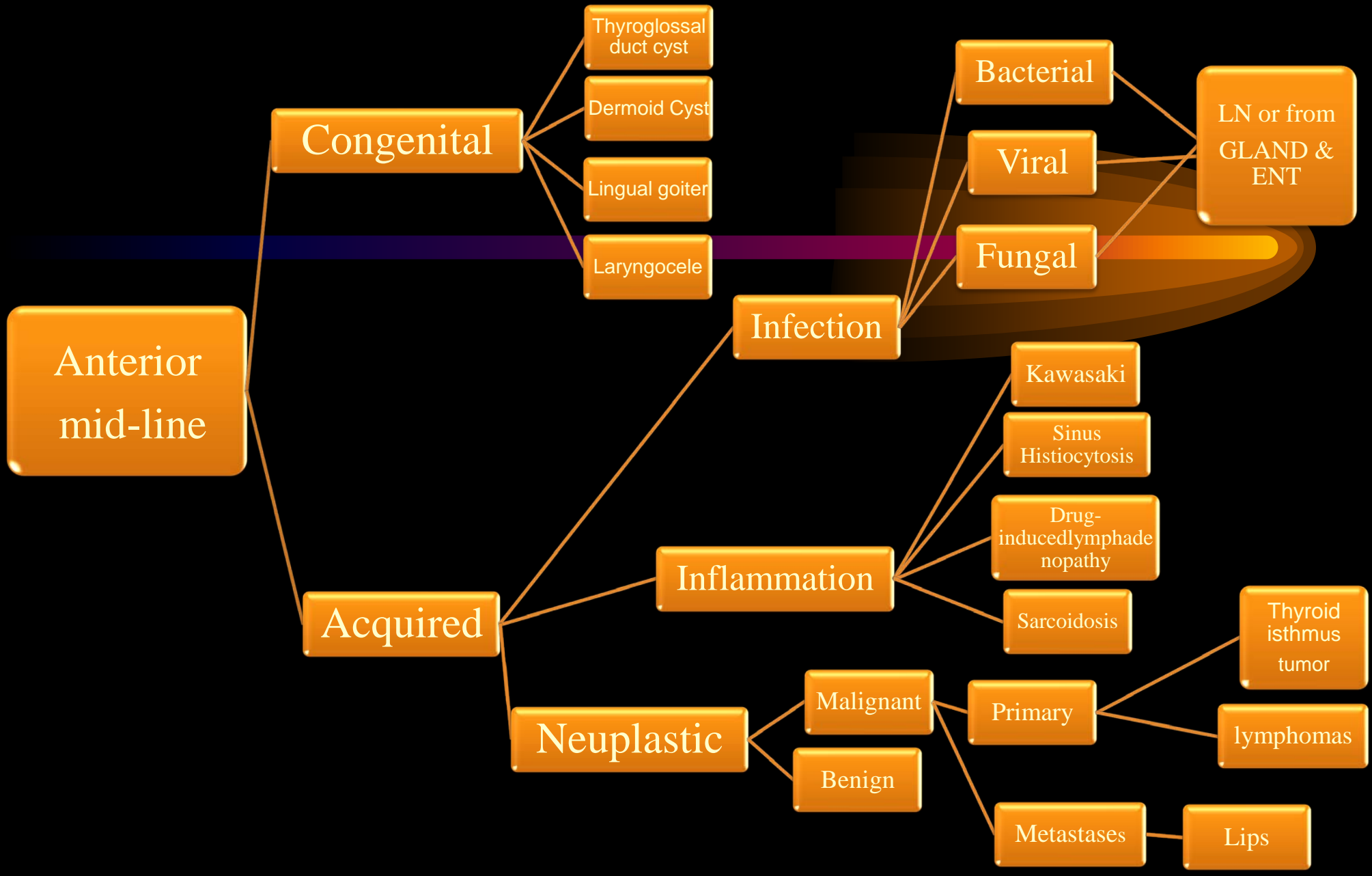


# *Anatomical Considerations*

- **Prominent landmarks**
- **Triangles of the neck**
  - Lymphatic levels
- **Carotid bulb**







Anterior mid-line

Congenital

- Thyroglossal duct cyst
- Dermoid Cyst
- Lingual goiter
- Laryngocele

Infection

- Bacterial
- Viral
- Fungal

LN or from GLAND & ENT

Acquired

Inflammation

- Kawasaki
- Sinus Histiocytosis
- Drug-induced lymphadenopathy
- Sarcoidosis

Neoplastic

- Malignant
- Benign

Primary

- Thyroid isthmus tumor
- lymphomas

Metastases

Lips

# *Anterior triangle*

## **Congenital**

- Branchial cyst
- Thymic cyst
- Hemangioma
- Torticollis

## **Acquired**

### **Infection And inflammation**

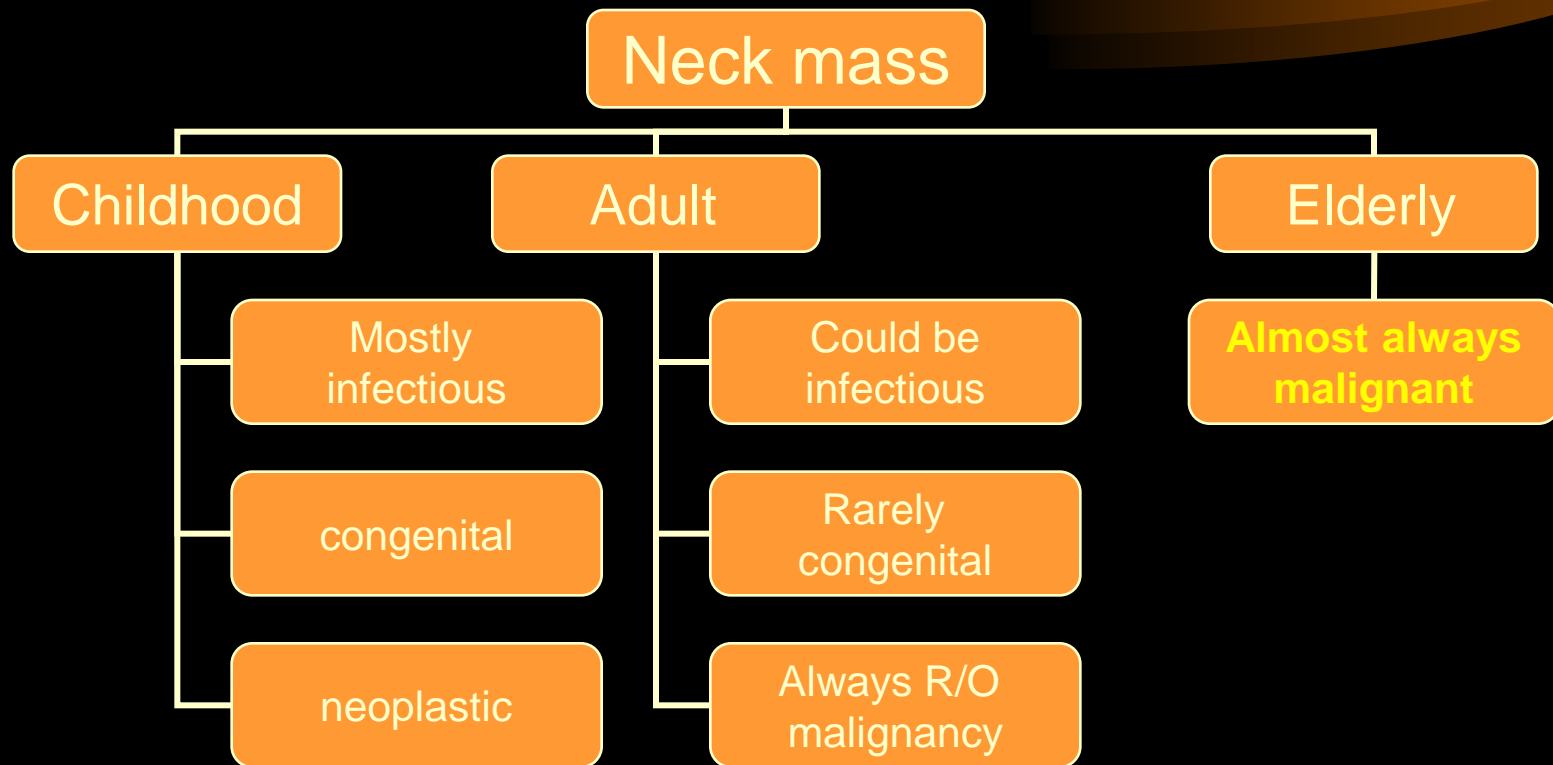
## **Acquired**

- **Benign**
  - i. Lipoma
  - ii. Neurofibroma
  - iii. Carotid body tumour
  - iv. Salivary G lesions
  - v. Thyroid
- **Malignant**
- **Primary**

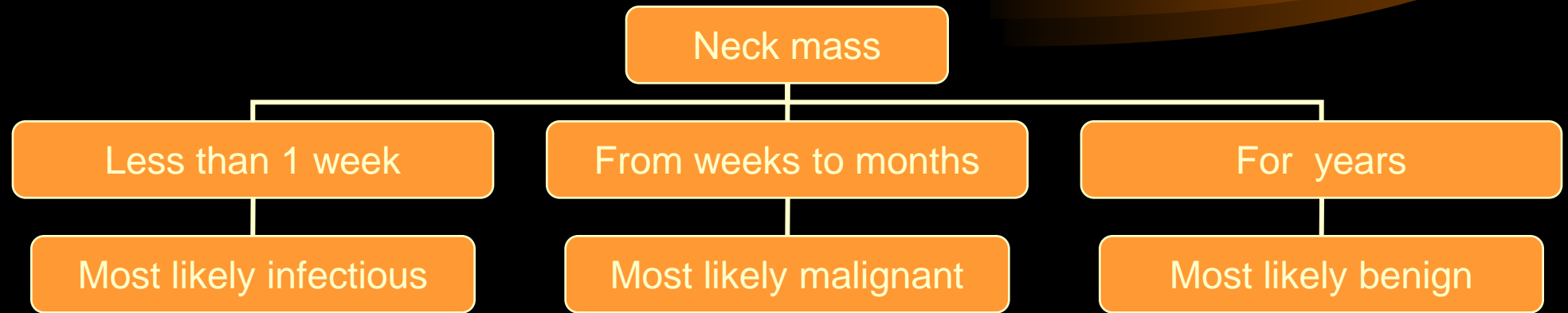
# Posterior triangle

- Congenital :  
Lymphangioma (cystic hygroma)
- Acquired:  
Lymphadenitis  
Lymphoma  
Metastatic ca.

# Age



# *Time line*



# *Empirical Antibiotics*



- **Inflammatory mass suspected**
- **Two week trial of antibiotics**
- **Follow-up for further investigation**

# *Diagnostic Tests*

- **Fine needle aspiration biopsy (FNAB)**
- **Computed tomography (CT)**
- **Magnetic resonance imaging (MRI)**
- **Ultrasonography**
- **Radionucleotide scanning**

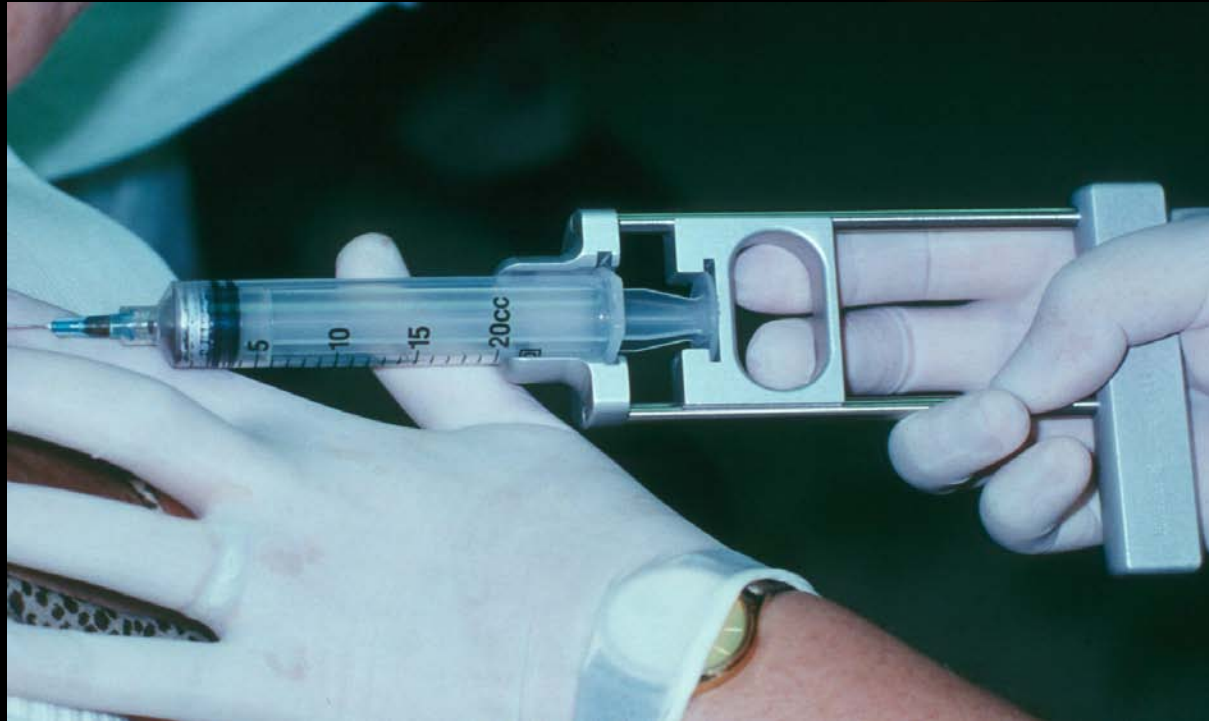
# ***Fine Needle Aspiration Biopsy***

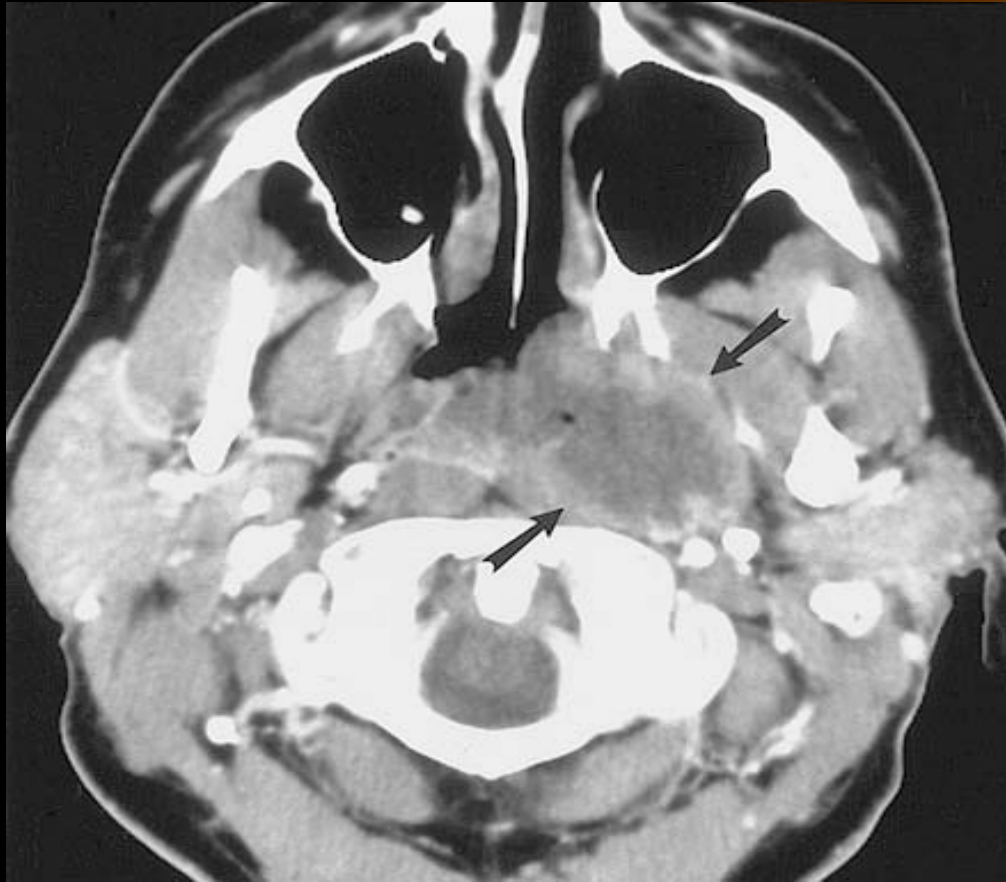

- **Standard of diagnosis**
- **Indications**
  - Any neck mass that is not an obvious abscess
  - Persistence after a 2 week course of antibiotics
- **Small gauge needle**
  - Reduces bleeding
  - Seeding of tumor – not a concern
- **No contraindications (vascular ?)**



# *Fine Needle Aspiration Biopsy*

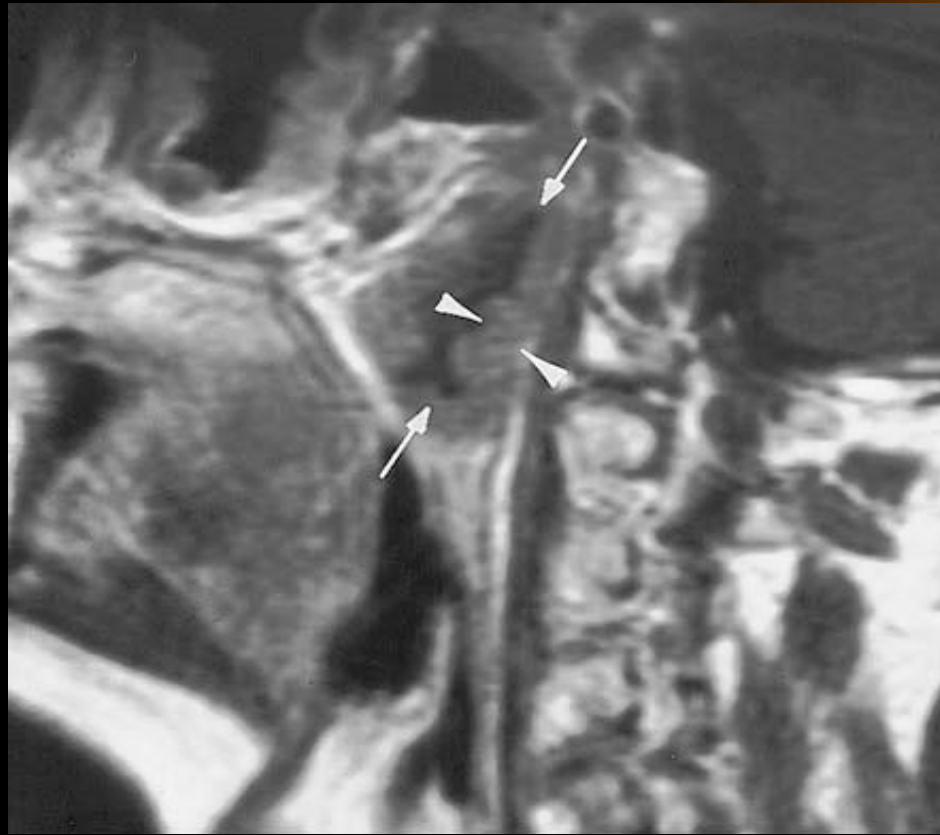




# *Computed Tomography*



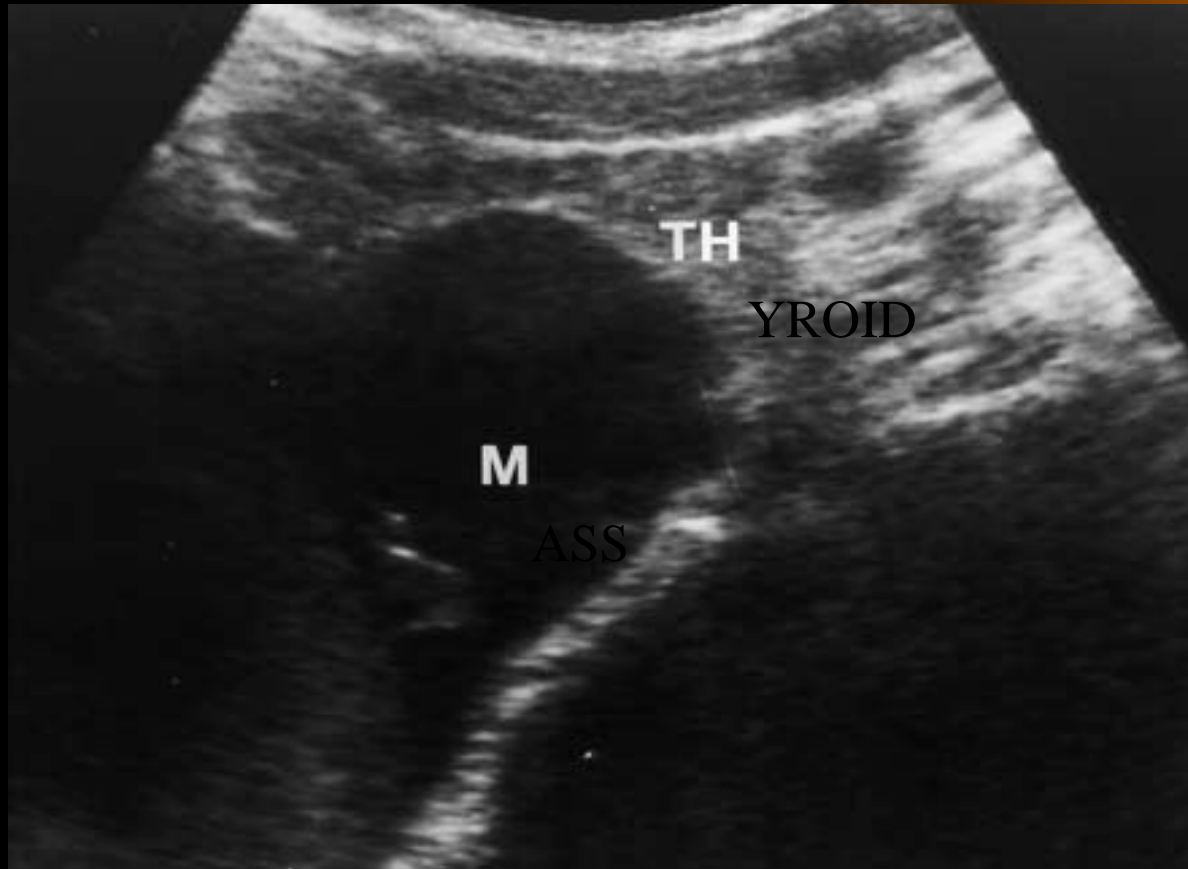
- **Distinguish cystic from solid**
- **Extent of lesion**
- **Vascularity (with contrast)**
- **Detection of unknown primary (metastatic)**
- **Pathologic node (lucent, >1.5cm, loss of shape)**
- **Avoid contrast in thyroid lesions**



# *Magnetic Resonance Imaging*



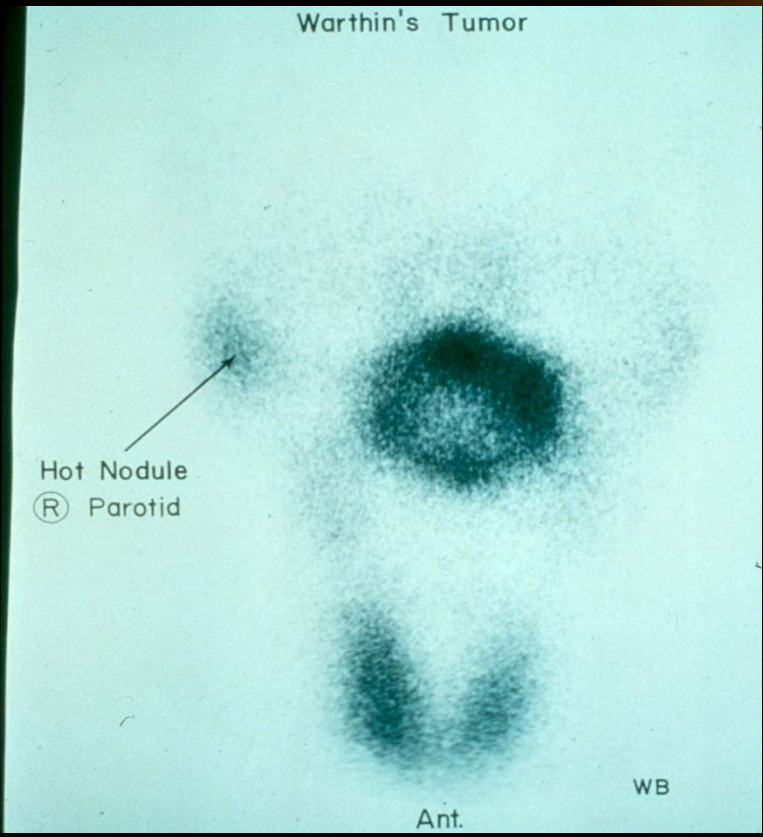
- **Similar information as CT**
- **Better for upper neck and skull base**
- **Vascular delineation with infusion**



# *Ultrasonography*



- **Less important now with FNAB**
- **Solid versus cystic masses**
- **Congenital cysts from solid nodes/tumors**
- **Noninvasive (pediatric)**





# *Radionuclide Scanning*



- **Salivary and thyroid masses**
- **Location – glandular versus extra-glandular**
- **Functional information**

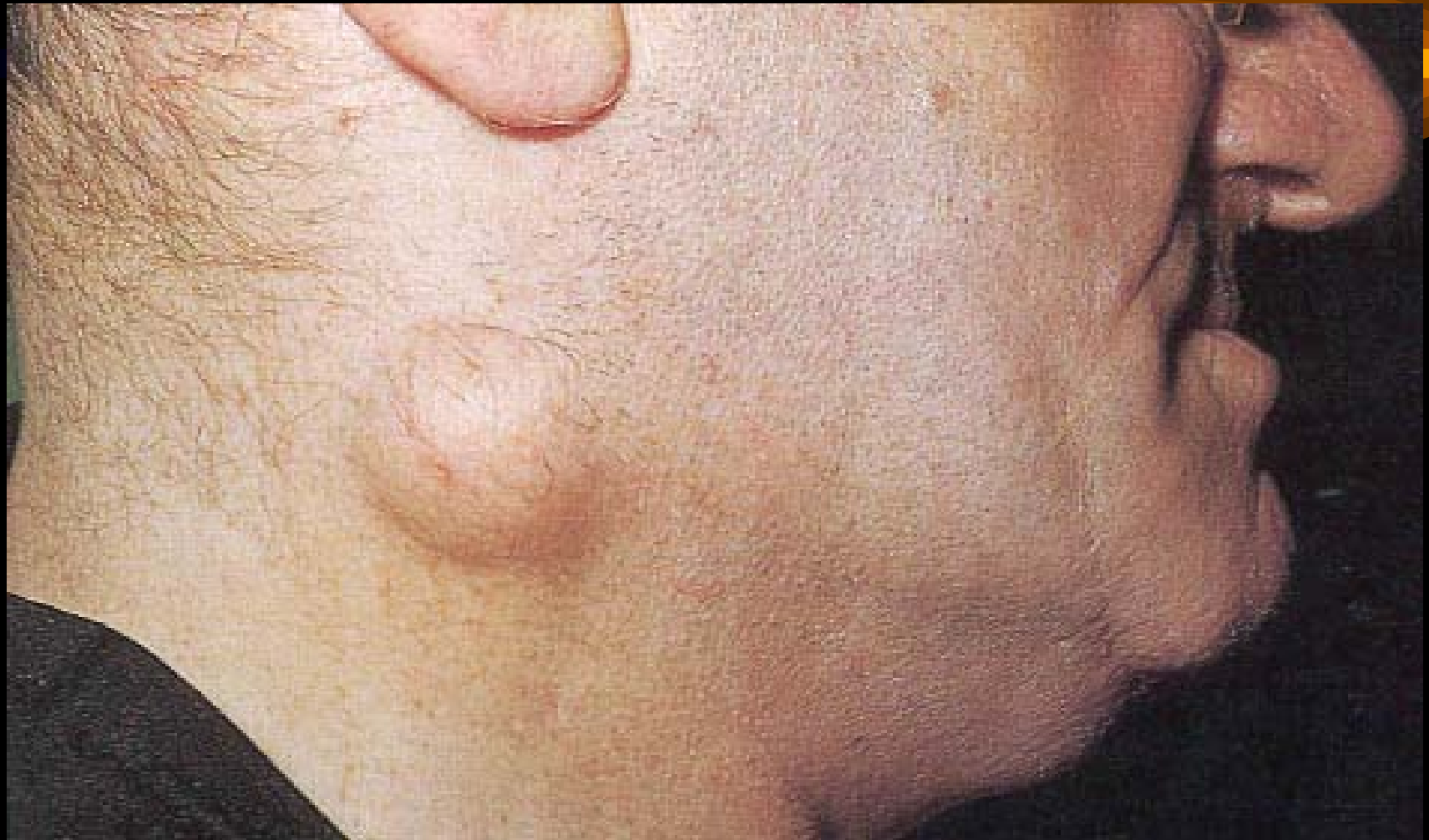
# Differential Diagnosis

**Table 1. Common Neck Masses**

Neoplastic	Congenital/Developmental	Inflammatory
Metastatic Unknown primary epidermoid carcinoma	Sebaceous cysts Branchial cleft cysts	Lymphadenopathy Bacterial Viral Granulomatous
Primary head and neck epidermoid carcinoma or melanoma	Thyroglossal duct cysts	
Adenocarcinoma	Lymphangioma/hemangioma	Tuberculous
Thyroid	Dermoid cysts	Catscratch
Lymphoma	Ectopic thyroid tissue	Sarcoidosis
Salivary	Laryngocele	Fungal
Lipoma	Pharyngeal diverticulum	Sialadenitis
Angioma	Thymic cysts	Parotid Submaxillary
Carotid body tumor		Congenital cysts
Rhabdomyosarcoma		Throtrast granulomas

# ***Congenital and Developmental Mass***

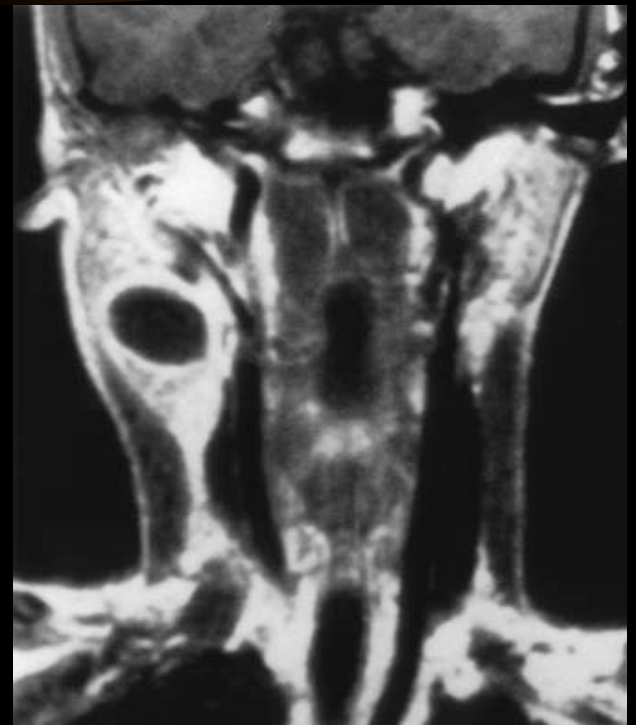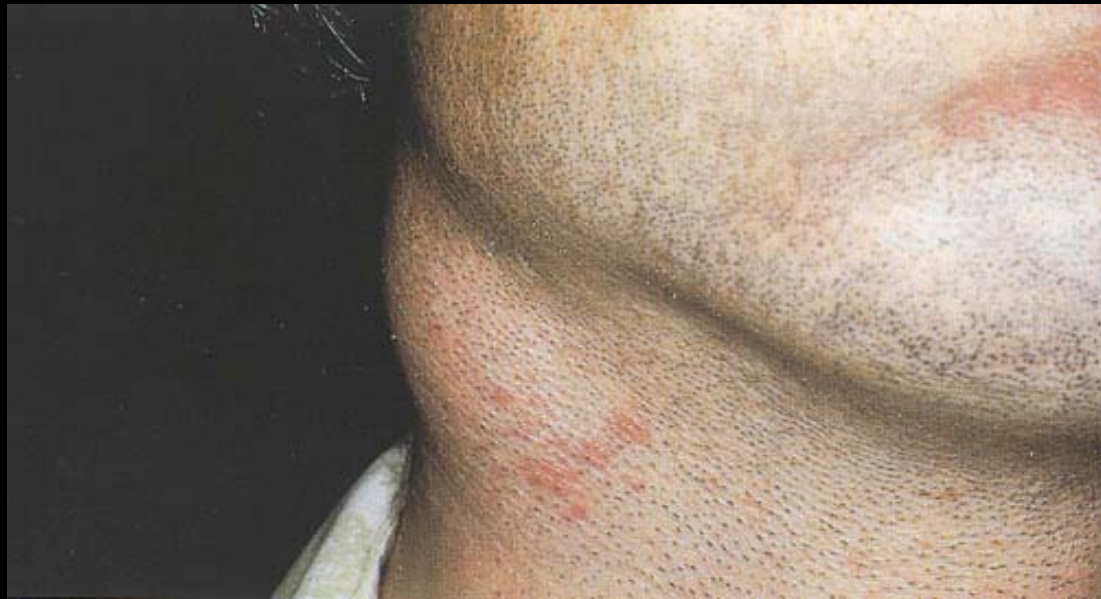- **Epidermal and sebaceous cysts**
- **Branchial cleft cysts**
- **Thyroglossal duct cyst**
- **Vascular tumors**



# *Sebaceous Cysts*



- **Older age groups**
- **Clinical diagnosis**
  - Elevation and movement of overlying skin
- **Rx: Excision**



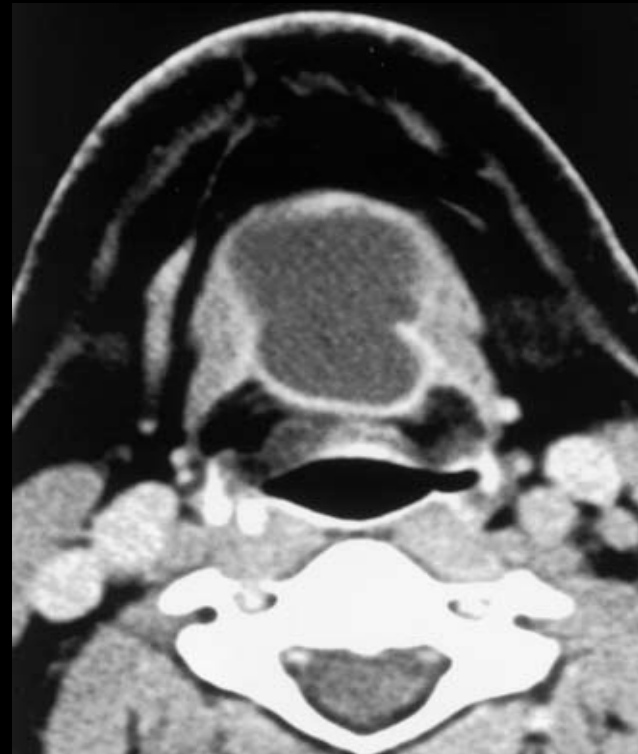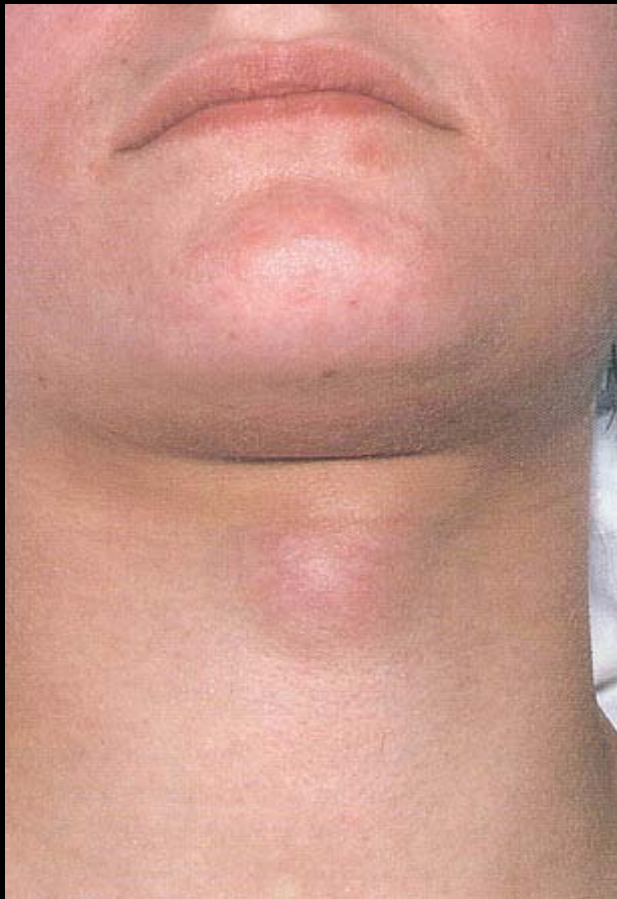# *Branchial Cleft Cysts*

- Present in older children or young adults often following URI
- 2<sup>nd</sup> cleft most common (95%) – tract medial to XII nerve between internal and external carotids
- 1<sup>st</sup> cleft less common – close association with facial nerve possible
- 3<sup>rd</sup> and 4<sup>th</sup> clefts rarely reported

# *Branchial Cleft Cysts*

- **Most common as smooth, fluctuant mass underlying the SCM**
- **Skin erythema and tenderness if infected**
- **Treatment**
  - Initial control of infection
  - Surgical excision, including tract
  - May necessitate a total parotidectomy (1<sup>st</sup> cleft)





# *Thyroglossal Duct Cyst*

- **Most common congenital neck mass (70%)**
- **50% present before age 20**
- **Midline (75%) or near midline (25%)**
- **Usually just inferior to hyoid bone (65%)**
- **Elevates on swallowing/protrusion of tongue**
- **Treatment:surgical removal (Sis trunk) after resolution of any infection**

# *Summary*



- **Extensive differential diagnosis**
- **Age of patient is important**
- **Accurate history and complete exam essential**
- **FNAB – important diagnostic tool**
- **Possibility for malignancy in any age group**
- **Close follow-up and aggressive approach is best for favorable outcomes**

# HN Cancers

```
graph TD; HN[HN Cancers] --> Known[Known Primary]; HN --> Unknown[Unknown Primary]; Known --> Mucosal[Mucosal]; Known --> NonMucosal[Non-Mucosal]; Mucosal --> MucosalList["-Oral<br/>- Sinonasal<br/>- Pharyngeal<br/>-Laryngeal"]; NonMucosal --> NonMucosalList["-Endocrine<br/>- Salivary<br/>- Skin<br/>- Paragangliomas"];
```

The diagram is a hierarchical flowchart. At the top is a box labeled 'HN Cancers'. A line descends from this box and splits into two horizontal branches leading to 'Known Primary' and 'Unknown Primary'. From 'Known Primary', another line descends and splits into two vertical branches leading to 'Mucosal' and 'Non-Mucosal'. Below 'Mucosal' is a list of cancer types: '-Oral', '- Sinonasal', '- Pharyngeal', and '-Laryngeal'. Below 'Non-Mucosal' is a list of cancer types: '-Endocrine', '- Salivary', '- Skin', and '- Paragangliomas'. The 'Unknown Primary' branch is not further detailed in this diagram.

Known Primary

Unknown Primary

Mucosal

Non-Mucosal

- Oral
- Sinonasal
- Pharyngeal
- Laryngeal

- Endocrine
- Salivary
- Skin
- Paragangliomas

# *Thyroid Gland*



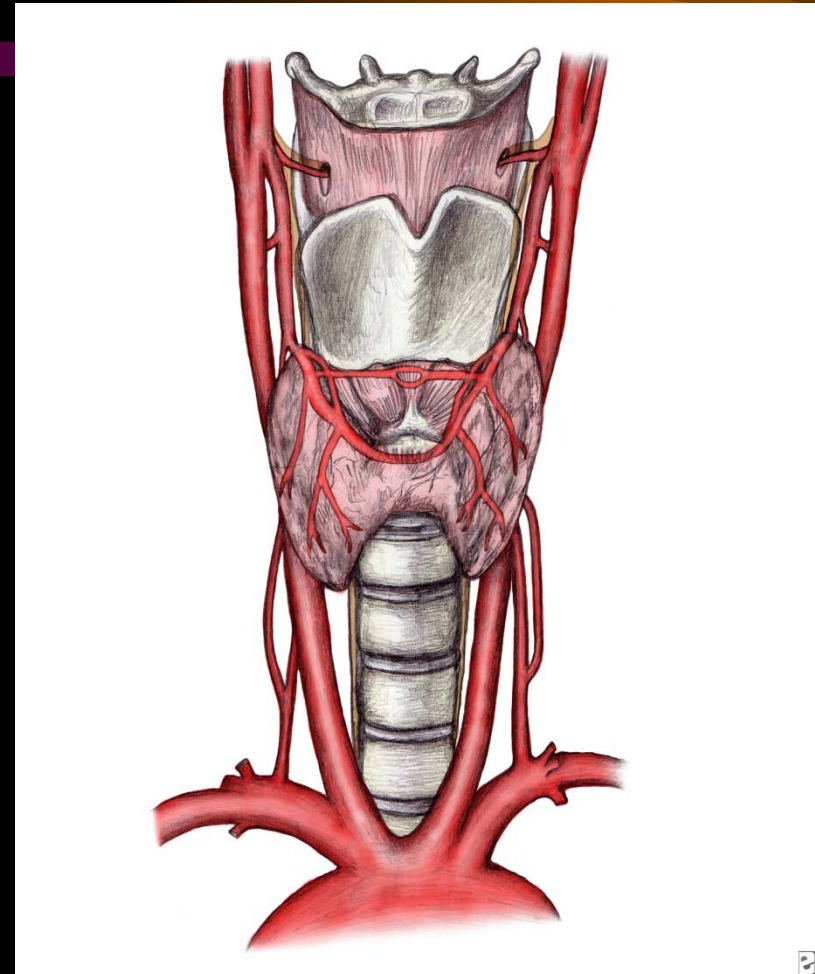
# *Thyroid Gland*



- **Anatomy**
- **Evaluation of Thyroid Nodule**
- **Thyroid Cancer: Types & Treatment**

# *Thyroid Anatomy*

- **Shield shaped, may be H- or U-shaped**
- **2 lateral lobes connected by an isthmus**
- **Isthmus at level of 2<sup>nd</sup> to 4<sup>th</sup> tracheal cartilages (may be absent)**



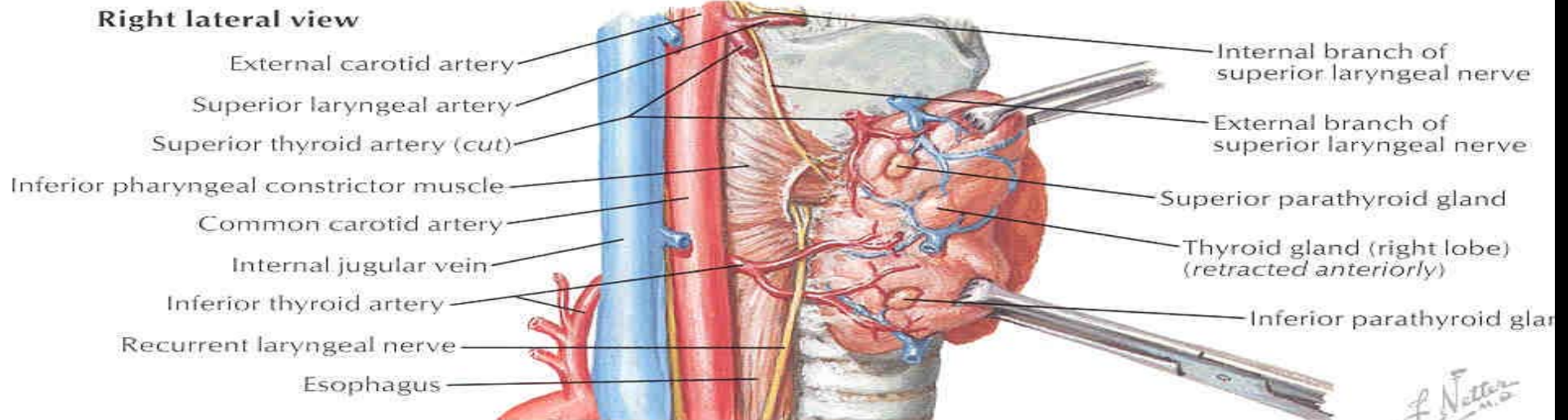
# *Lobes of Thyroid*

- **Each lobes measures approx 4cm high, 1.5cm wide, 2cm deep**
  - Lobes have superior and inferior poles
- **Superior pole: may extend as far as the oblique line of the thyroid cartilage**
- **Inferior pole: may extend inferiorly as far as the 5<sup>th</sup> or 6<sup>th</sup> tracheal rings**



# Arterial Blood Supply

- **Superior thyroid artery (STA)**
  - 1<sup>st</sup> branch of ECA
  - Followed by SLN until superior pole
  - Anastomoses with contralateral STA
- **Inferior thyroid artery (ITA)**
  - From thyrocervical trunk (1<sup>st</sup> part of subclavian at 1<sup>st</sup> rib)



# Venous Drainage

- **3 pairs of veins**
  - Superior thyroid vein
    - Parallels course of STA on ant surface thyroid
    - Ascends to drain into internal jugular vein (IJV)
  - Middle thyroid vein
    - Direct lateral course from thyroid to IJV
    - Shortest of 3 veins
  - Inferior thyroid vein
    - Ant surface thyroid (opposite of ITA)
    - Vertical downward course to brachiocephalic v.

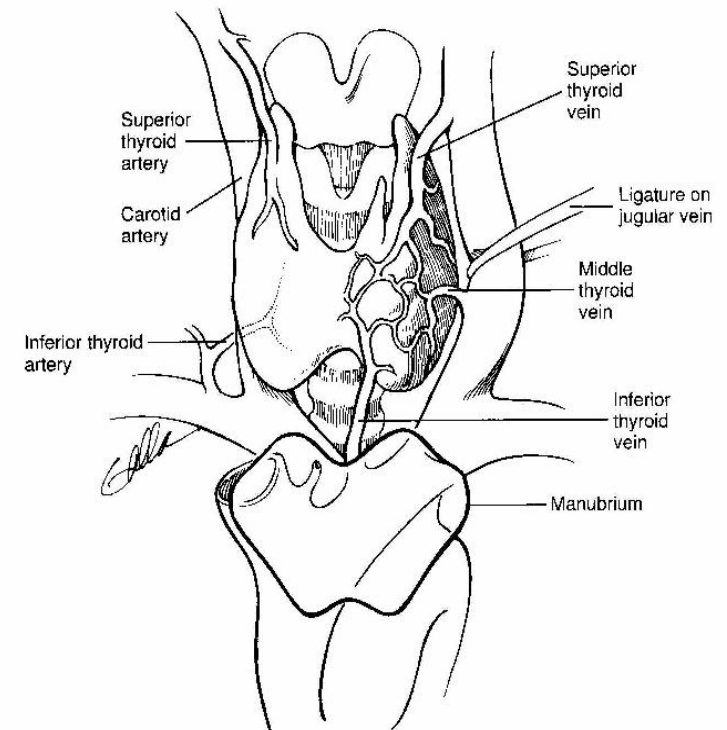


Figure 28-3. Superior thyroid and inferior thyroid arteries (left figure) and superior, middle, and inferior thyroid veins (right figure).

# *Thyroid Nodule - Evaluation*



- **Start with Hx ,P/E**
- **Pre-operative Laryngoscopy**
  - Assess RLN function / infiltration
  - Essential in revision cases (6.7% of patients with previous thyroid surgery had VC paralysis)

# *Thyroid Nodule - Evaluation*

- **U/S**
- **FNA**
- **Thyroid Function Tests**

# *Thyroid Imaging*



- U/S
  - Often first modality, helps delineate architecture
  - Accessible, inexpensive, safe
  - Help locate nodule, assist with FNA
  - Micro-calcifications and central blood flow
    - Suggests CA
  - Not useful for large masses

# *Thyroid Imaging Cont'd*

- **CT**
  - Useful for cervical lymphadenopathy
  - Dye can interfere with function testing and radioactive treatment for up to 8 weeks
- **MRI**
  - Used less commonly
- **Scintigraphy**
  - Hard to distinguish benign vs malignant nodule

# *Thyroid Biopsy*



- **FNA**

- Gold standard
- Sensitivity → 65% to 98%
- Specificity → 72% to 100%

- **Results**

- Benign → adenoma, goitre, thyroiditis
- Malignant → most common PTC
- Indeterminate → FTC and Hurthle most common
- Non-diagnostic → re-aspiration diagnostic in 50%

# *Thyroid Biopsy*



- **FNA Disadvantages**

- Inability to distinguish benign microfollicular adenomas from differentiated FTC
  
- Inability to distinguish Hurthle cell lesion from adenoma or Hashimoto thyroiditis



# *Management of the Thyroid Nodule*

## **Serial exam**

- **Physical examination**
  - Benign
  - Asymptomatic palpable nodule
- **U/S**
  - F/u a benign, non palpable nodule
  - F/u a cystic nodule for reaccumulation

# *Management of the Thyroid Nodule*

- **Trial of suppression of TSH**
  - Benign or indeterminate FNA (controversial)
  - Maintain TSH level between 0.1 and 0.5 mIU/L per day
  - Decrease tumor volume up to 50% in 40% pts.
  - A shrinking tumor is not likely malignant

# ***Malignant Thyroid Lesions***

## **1. Well Differentiated (85%)**

- Papillary Thyroid Carcinoma (PTC)
- Follicular Thyroid Carcinoma (FTC)
- Hurthle Cell Carcinoma (HCC)

## **2. Poor differentiated malignant neoplasms**

- Medullary thyroid carcinoma (MTC)
- Anaplastic thyroid carcinoma (ATC)

## **3. Other malignant tumors:**

- Lymphoma
- Metastatic tumors

# ***Malignant Thyroid Lesions***

- **Risk factors for Thyroid Cancer**
  - Age (<20 or >60)
  - Male (Female > risk of nodules)
  - Rapid Growth
  - Invasive or compressive Symptoms
  - Previous Radiation exposure
  - Prior Thyroid disease
    - Goiter, Hashimoto, Grave's, adenomas
  - Family Hx

# *Papillary Thyroid Carcinoma (PTC)*

- **Lymph node involvement in 30%**
- **Distant mets least common**
  - 1 - 25% during illness or 1 - 7% at Dx
- **Predisposing Factors**
  - Ionizing radiation
  - 5 - 10% of pts have +ve Family Hx
- **Clinical presentation**
  - Young females, palpable mass in thyroid or cervical LN ( 1/3rd have lymphadenopathy)

# *Follicular Carcinoma*

- **13% of all thyroid carcinomas**
- **Hematogenous spread more common than PTC**
- **More aggressive, well differentiated compared to PTC**
- **10 yr survival = 60% (PTC = 95%)**
- **Malignant lesion = capsular +/- vascular invasion**

# *Hurthle Cell Carcinoma*

- **Subtype of FTC (15% of FTC's)**
- **Like FTC, cannot exclude carcinoma vs adenoma based of FNA or frozen**
- **Clinical Presentation**
  - Thyroid nodule or mass
  - 35 % will have distant mets during illness
  - Higher rate of nodal mets than FTC

# *Management WDTC*



## **Surgical options:**

- **Total thyroidectomy (>1.5cm)**
- **Thyroid lobectomy (<1.5cm)**
- **+/- Neck dissection**

## **Adjuvant Therapy:**

- **Post-op I-131**
- **External beam RT**
  - Tumors that do not pick up I-131
  - Advanced disease (mets, residual disease)



# *Medullary Thyroid Carcinoma*

- **Sporadic (80%)**
  - More aggressive type
  - Late presentation (age 40 – 60)
  - Early mets to regional lymph nodes (50%)

# Medullary Thyroid Carcinoma

- **Familial (20%)**
  - MEN IIA, MEN IIB, Non-endocrinopathic
  - Mutation in RET-protooncogene
  - Autosomal Dominant
  - Early presentation (birth – 20's)

**TABLE 115.4. MULTIPLE ENDOCRINE NEOPLASIA SYNDROMES**

Wermer syndrome (MEN type I)
Parathyroid adenomas or hyperplasia, usually adenomas
Pituitary tumors
Pancreatic tumors
Miscellaneous
Carcinoid tumors
Ovarian tumors
Differentiated thyroid carcinoma
Melanoma
Sipple syndrome
Type IIA
Parathyroid hyperplasia or adenoma
Medullary thyroid carcinoma (100%)
Pheochromocytoma (bilateral in 60%–75% of patients)
Type IIB
Same as type IIA except for
Presence of mucosal neuromas
Marfanoid habitus with pectus excavatum
No hyperparathyroidism

MEN, multiple endocrine neoplasia.

# ***Treatment of MTC***

- **Total thyroidectomy with bilateral SLND**
- **Prophylactic surgery for relatives with RET mutation (preferably before age 7)**
- **No adjuvant therapy advocated**
- **Radiotherapy and chemotherapy for palliation (usually ineffective)**

# *Anaplastic Thyroid Carcinoma*

- **Less than 5% of thyroid malignancies**
- **Highly aggressive and fatal**
- **Median survival 3 - 6 months**
- **Distant mets common (lung)**
- **Grossly, large and bulky tumors**
  - Invade into surrounding tissue
  - Rapid expansion

# *ATC Cont'd*



- **P/E**
  - Firm, irregular mass fixed to surrounding structures
  - RLN involvement and VC paralysis common
  
- **Tx (often palliative intent)**
  - Surgery
  - Adjuvant RT
  - Chemotherapy

# *Lymphoma*



- **Rarely presents within thyroid gland**
- **Dx in 60's**
- **Females > males**
- **Low - intermediate grade B-cell NHL**
- **Increased risk wth Hashimoto**
- **Clinically**
  - Rapidly expanding mass on background of Hashimoto
  - Hoarsness, dysphagia, VC paralysis, Horner Syndrome
- **Tx**
  - RT, Chemo

# *Post Op Complications*



- **RLN Injury**
- **Hypocalcemia**
- **Hematoma**

# *Head & Neck Tumours*

## *Part II*

**Khalid Hussain AL-Qahtani**

**MD, MSc, FRCS(c)**

**Medical Director KAUH**

**Associate Professor & Consultant**

**Head & Neck Oncology & Skull Base Surgeon**

**KSU, KFMC**

**Riyadh, Saudi Arabia**



# HN Cancers

```
graph TD; A[HN Cancers] --> B[Known Primary]; A --> C[Unknown Primary]; B --> D[Mucosal]; B --> E[Non-Mucosal]; D --> D1["-Oral"]; D --> D2["-Sinonasal"]; D --> D3["-Pharyngeal"]; D --> D4["-Laryngeal"]; E --> E1["-Endocrine"]; E --> E2["-Salivary"]; E --> E3["-Skin"]; E --> E4["-Paragangliomas"];
```

The diagram is a hierarchical flowchart titled 'HN Cancers'. It starts with a root node 'HN Cancers' at the top. This node branches into two main categories: 'Known Primary' on the left and 'Unknown Primary' on the right. The 'Known Primary' category further branches into 'Mucosal' and 'Non-Mucosal'. Under 'Mucosal', there are four sub-items: '-Oral', '-Sinonasal', '-Pharyngeal', and '-Laryngeal'. Under 'Non-Mucosal', there are four sub-items: '-Endocrine', '-Salivary', '-Skin', and '-Paragangliomas'. The 'Unknown Primary' category is currently empty. The nodes are light orange rounded rectangles, and the connections are thin orange lines. A decorative purple and orange gradient bar is positioned behind the 'Known Primary' and 'Non-Mucosal' nodes.

Known Primary

Unknown Primary

Mucosal

Non-Mucosal

-Oral

- Sinonasal

- Pharyngeal

-Laryngeal

-Endocrine

- Salivary


- Skin

- Paragangliomas

# *Salivary Glands*

A decorative graphic consisting of a horizontal line that transitions from dark blue on the left to purple and then to a bright yellow-orange glow at the right end. This line is enclosed within a larger, semi-transparent, pointed arrow shape that also tapers to a bright yellow-orange glow at its tip on the right.

# *Content*

- **Anatomy**
  - **Physiology**
  - **Acute and Chronic Infections**
  - **Auto Immune Diseases**
  - **Tumours of Salivary Glands**
- 

# *Basics*



- **6 major salivary glands: 2 parotid, 2 submandibular, 2 sublingual.**
- **100's of minor salivary glands lining the upper aerodigestive tract**
- **Main job.... Saliva!!!!**

# *Anatomy-Parotid*



- **Serous cells only**
- **On side of the face, deep to skin, subcutaneous tissue, superficial to the masseter.**
- **Tail of parotid extends superficial to SCM.**

# *Parotid duct*



- **Stensen's duct begins at anterior border of the gland 1.5cm below the zygoma.**
- **Traverses the masseter 5-6cm, pierces the buccinator.**
- **Opens in mouth lateral to 2<sup>nd</sup> upper molar.**

# *Submandibular gland*



- Mucous and serous cells.
- **Submandibular triangle: anterior and posterior bellies of digastric and inferior margin of the mandible.**
- **Medial and inferior to the mandible.**

## *Wharton's duct*

- Exits the gland from the medial surface travels b/w the hyoglossus and mylohyoid muscles enters the genioglossus muscle and opens into mouth just lateral to lingual frenulum.
- CN XII inferior to the duct and lingual nerve is superior to the duct.



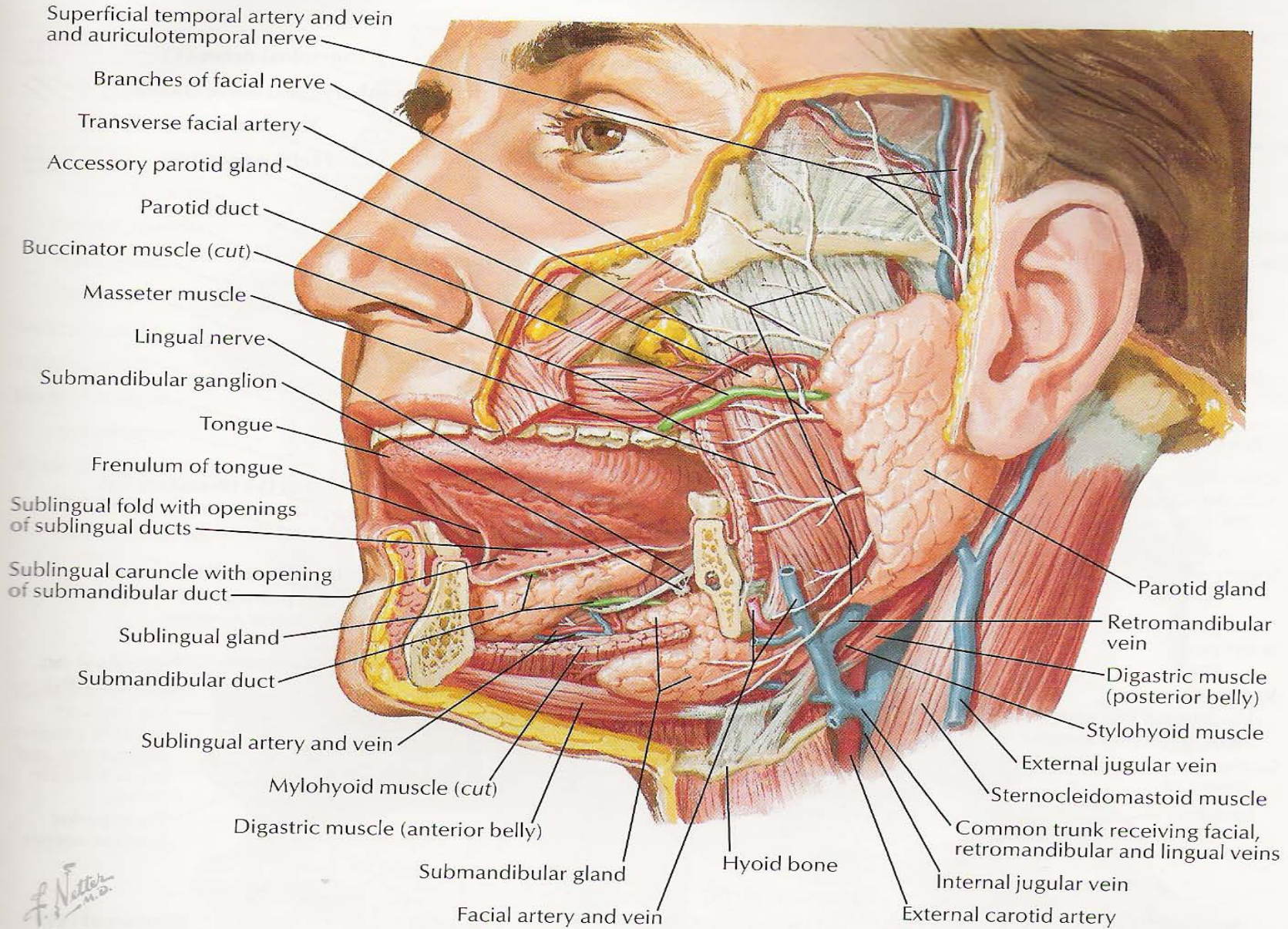
# *Sublingual glands*



- **Mucous secreting.**
- **Just below the floor of mouth mucosa.**
- **Bordered by genioglossus/hyoglossus medially, mandible laterally, and mylohyoid inferiorly.**
- **Wharton's duct and lingual n. travel b/w SL gland and genioglossus muscle.**
- **No fascial capsule.**

## ***SL glands cont'd***

- **Ducts of Rivinus (~10) along the superior aspect of the gland open into the mouth along sublingual fold in the floor of mouth.**
- **Innervated by the PNS/SNS systems in the same way as the SM gland.**



# *Minor salivary glands*



- **Either mucous serous or both**
- **600-1000 /person**
- **Each gland has it's own duct**
- **Found most commonly in buccal, labial, palatal, and lingual regions**

# *Physiology*



- **Role of saliva:**
  - Lubricates
  - Moistens, help with mastication
  - Cools hot food
  - Buffers chemicals
  - Cleans the mouth (lavage)
  - Protects mucosa
  - Prevent dental caries
  - Antibacterial (lysozyme, IgA, peroxidase)
  - Homeostasis

# *Salivary flow rates*

- **~1000-1500 ml/24hrs, or 1 ml/min.**
- **Unstimulated 69% of flow from SM gland, 26% parotid, 5% SL.**
- **Stimulated parotid and SM .**
- **Minor glands independent of stimulation usually account for 7-8% total flow.**

# *Infections of the Salivary Glands*

A decorative graphic element consisting of a horizontal line with a gradient from dark purple to bright yellow, ending in a large, stylized arrowhead shape pointing to the right. The arrowhead is filled with a gradient from dark brown to bright yellow.

# ***Viral Infections - Mumps***

- **Most common nonsuppurative infection**
- **Children**
- **Parotid (occ. SMG)**
- **Bilateral, generalized swelling**
- **Paramyxovirus**
  - Highly contagious
  - Air-borne droplet spread
  - Incubation 18 days
  - Virus spread for 1 week following swelling



# *Mumps-Rx*



- **Hydration**
- **Rest**
- **Modify diet to decrease gland stimulation**

# *Acquired Immunodeficiency Syndrome*

- **HIV**
- **Lymphoproliferative and cystic enlargement of the major salivary glands**
- **High suppressor T-cells and lymphocytosis**
- **Can be initial presentation**
- **Parotid (15- 30% bilateral) with lymphocytic interstitial pneumonitis**
- **HIV in saliva**

# *Acute Suppurative Sialoadentitis*

- “Surgical parotitis”, “Surgical mumps”
- **Retrograde migration of bacteria from the oral cavity**
- **Parotid gland most frequently involved**
  - Inferior bacteriostatic properties

# *Pathogenesis of Acute infections*

- **Stasis permits retrograde flow**
- **Compromised host resistance**
- **Poor oral hygiene (increase oral bacteria)**
- **Chronic disease or prolonged recovery**
- **DEHYDRATION**
- **Anticholinergics or diuretics**
- **Anorexia reduces salivation**
- **25% bilateral**

# *Symptoms of Acute infections*

- **Rapid onset of pain, swelling, induration**
- **Fever, chills, malaise**
- **Increased WBC count**
- **Suppurative discharge from the gland**
- **S. aureus**

# *Treatment*



- **Antibiotics**
- **Steroids**
- **Analgesics**
- **Local heat application**
- **Increased fluid intake**
- **Surgical treatment if no improvement**
- **CT or US to rule out abscess**
- **Sialogram C/I in acute phase**

# *Chronic Sialoadenitis*



- **Repeated episodes of pain and inflammation**
- **Parenchymal degeneration and fibrous replacement of the gland**
- **Initial severe acute infection**
- **Duct obstruction**
- **Depressed glandular secretion**
- **Parotid**
- **More infections = more damage to gland and duct**

# *Pathophysiology and Treatment*

- **Obstruction of salivary flow**
- **Intraductal calculus**
- **Stricture**
- **Mucous plug**
- **Ductal papilla lesion**
- **Extrinsic compression**
- **No consistent Tx**
- **Tympanic neurectomy**
- **Duct ligation**
- **Gland excision**



# *Sialolithiasis*

- **Formation of hardened intraluminal deposits in the ductal system**
- **Common with chronic sialoadenitis**
- **Causes:**
  - Stagnation of saliva
  - Focus for formation from duct injury
  - Biologic factors (Calcium salts)

# *Location*



- **80% Wharthon's duct**
- **19% Stenson's**
- **1% sublingual**
- **Why Wharthon's?**
  - Alkaline and viscous saliva
  - Increased Ca and Phos
  - Angulation of the duct at Mylohyoid
  - Vertical orientation at the distal segment

# *Symptoms and Management*

- Colicky postprandial pain
- Swelling
- Plain films
- Sialography
- CT
- Like sialoadenitis
- Avoid vigorous probing
- Incise duct orifice
- Stenting
- Surgical excision

# *Salivary Gland Neoplasms*

- **Diverse histopathology**
  - Determines Aggressiveness
- **Relatively uncommon**
  - 2% of head and neck neoplasms
- **Distribution**
  - 95% in adults
  - Parotid: 80% overall; 80% benign
  - Submandibular: 15% overall; 50% benign
  - Sublingual/Minor: 5% overall; 40% benign

# *Most Common Parotid Tumours*

- **Benign**
  - 1) Pleomorphic adenoma
  - 2) Warthin tumour
  
- **Malignant**
  - 1) MEC
  - 2) AdenoCa

# *Most Common SMG , Minor Salivary Gland Tumours*



- **Benign**
  - 1) Pleomorphic adenoma
  
- **Malignant**
  - 1) ACC
  - 2) MEC
  - 3) Malignant mixed

# *Common Salivary Gland Tumours in Children*

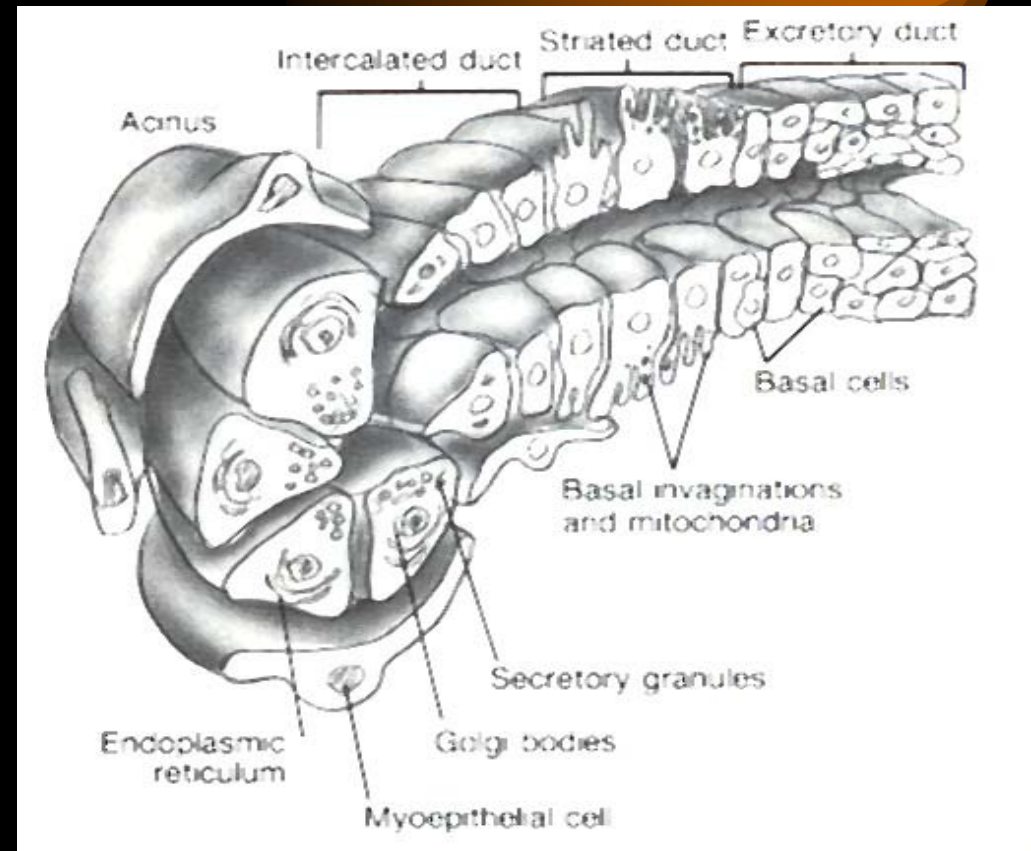


- **Benign**
  - 1) Hemangioma (mesenchymal)
  - 2) Pleomorphic adenoma (epithelial)
  - 3) Lymphangioma
- **Malignant**
  - 1) 85% in parotid
  - 2) MEC
  - 3) Acinic cell carcinoma
  - 4) AdenoCa

# *Multicellular Theory*

*Neoplastic cells originate from secretory unit counterparts*

- **Striated duct—oncocytic tumors, Warthin's, adenoca**
- **Acinar cells—acinic cell carcinoma**
- **Excretory Duct—squamous cell and mucoepidermoid carcinoma**
- **Intercalated duct and myoepithelial cells—pleomorphic tumors, adenoid cystic & adenoca**





# Bicellular Theory

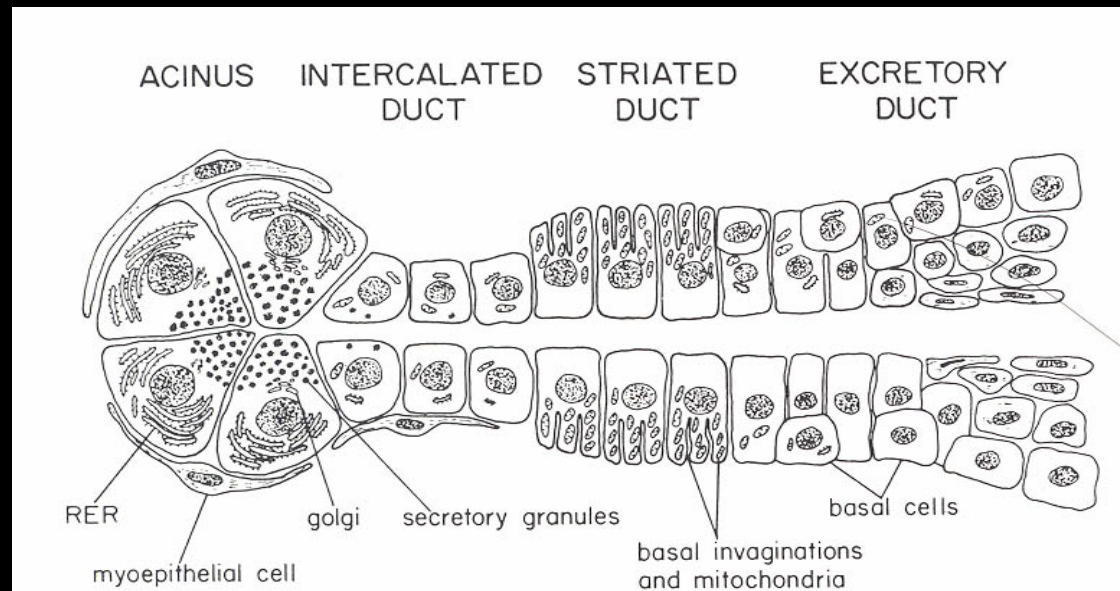
*Neoplastic cells originate from basal cells in intercalated and excretory ducts*

- **Intercalated Ducts**

- Pleomorphic adenoma
- Warthin's tumor
- Oncocytoma
- Acinic cell
- Adenoid cystic

- **Excretory Ducts**

- Squamous cell
- Mucoepidermoid





*Benign Neoplasms*

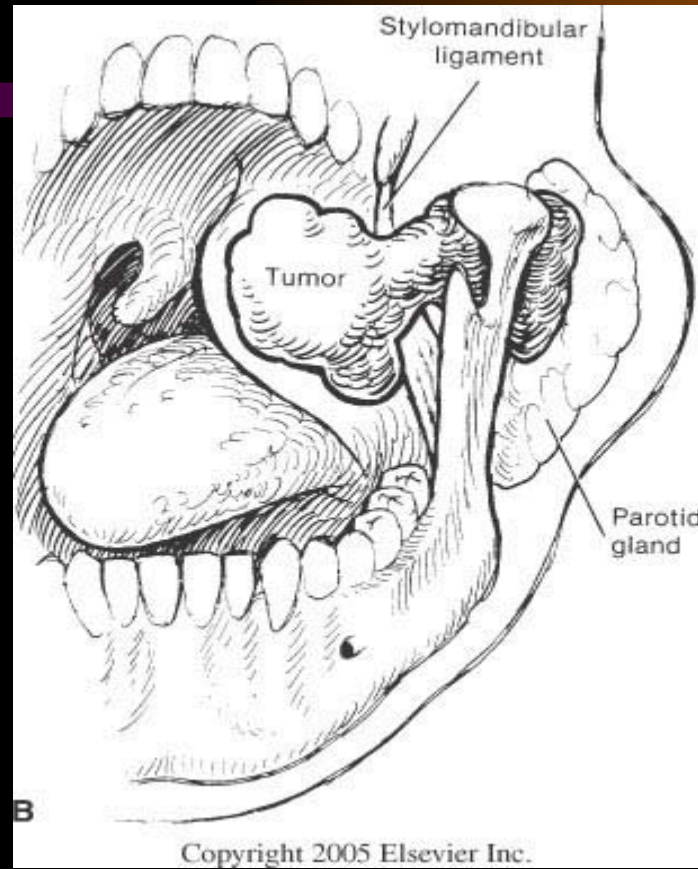
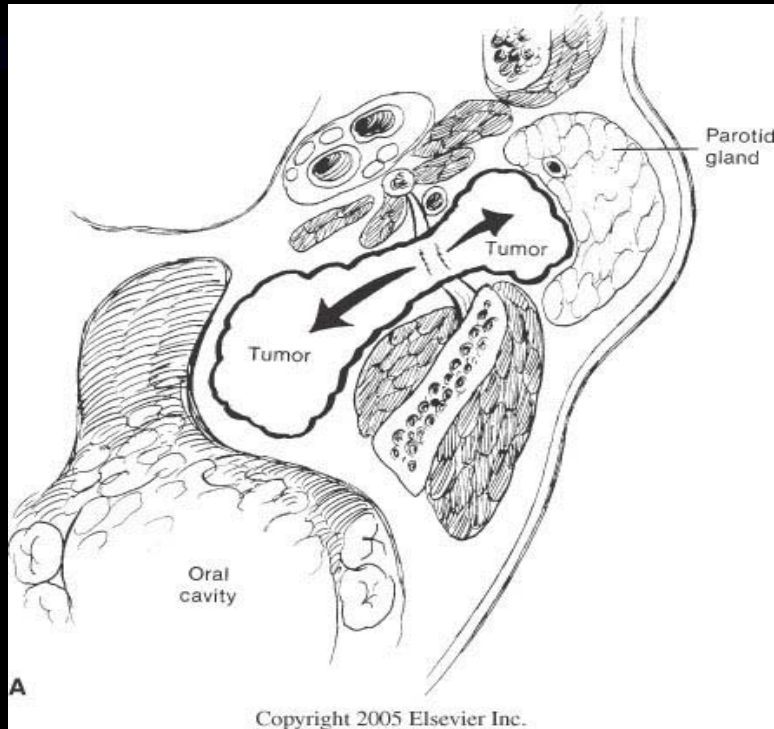
# *Pleomorphic Adenoma*

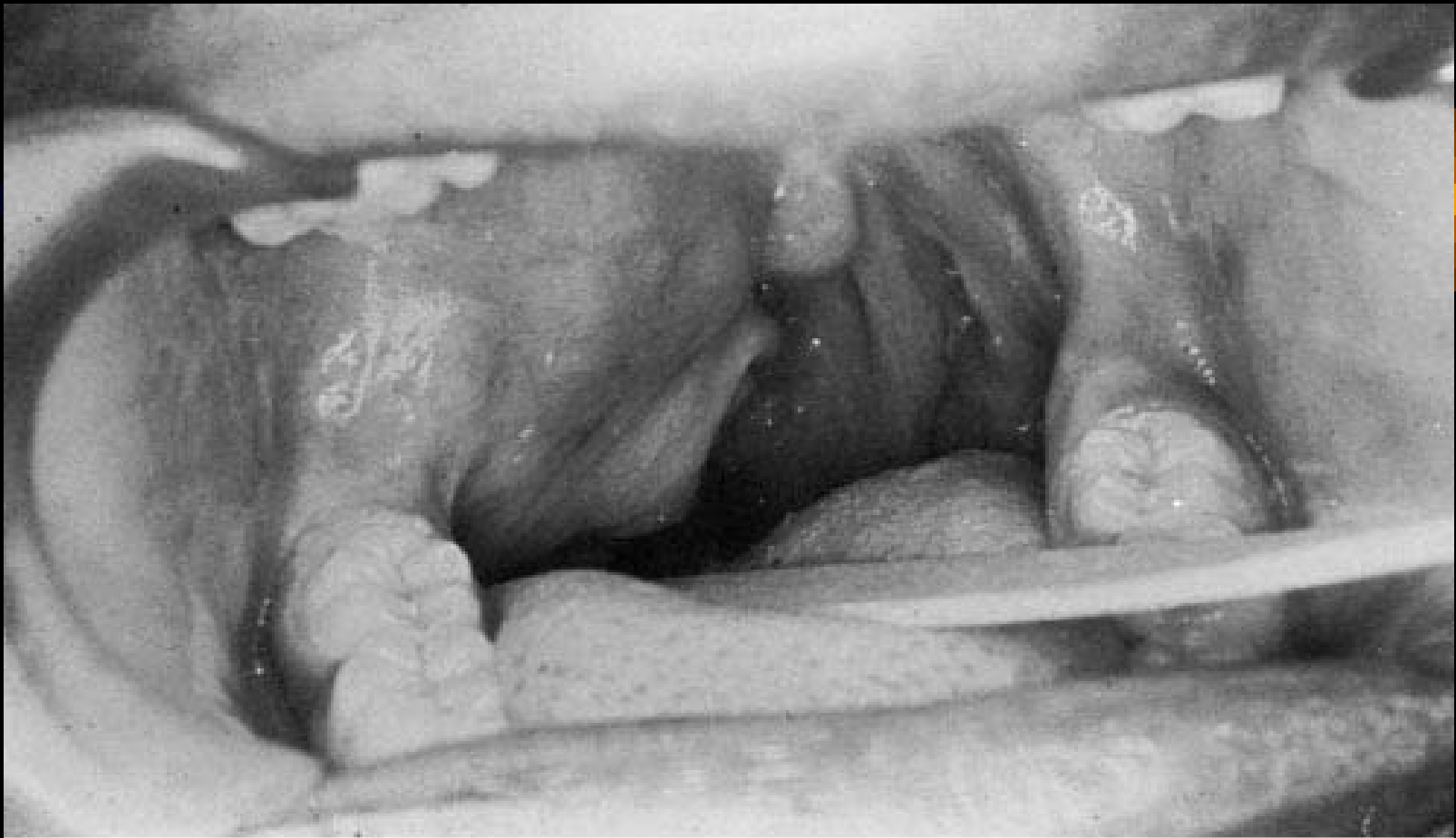
- **Most common of all salivary gland neoplasms**
  - 70% of parotid tumors
  - 50% of submandibular tumors
  - 45% of minor salivary gland tumors
  - 6% of sublingual tumors
- **4<sup>th</sup>-6<sup>th</sup> decades**
- **F:M = 3-4:1**

# *Pleomorphic Adenoma*



- **Slow-growing, painless mass**
- **Parotid: 90% in superficial lobe, most in tail of gland**
- **Minor salivary gland: lateral palate, submucosal mass**





Copyright 2005 Elsevier Inc.

# *Pleomorphic Adenoma*

- **Treatment: complete surgical excision**
  - Parotidectomy with facial nerve preservation
  - Submandibular gland excision
  - Wide local excision of minor salivary gland
- **Avoid enucleation and tumor spill**
  - 20-45% recurrence
- **Can metastasize and yet remain benign histologically**

# *Warthin's Tumor*

- **Papillary Cystadenoma Lymphomatosum**
- **6-10% of parotid neoplasms**
- **Older, males**
- **10% bilateral; 20% multicentric**
- **3% with associated neoplasms**
- **Presentation: slow-growing, painless mass in parotid tail**
- **RX: Surgery**





# *Malignant Tumors*

# ***Mucoepidermoid Carcinoma***

- **Most common salivary gland malignancy**
- **5-9% of salivary neoplasms**
- **Parotid 45-70% of cases**
- **Palate 18%**
- **3<sup>rd</sup>-8<sup>th</sup> decades, peak in 5<sup>th</sup> decade**
- **F>M**

# *Mucoepidermoid Carcinoma*

- **Presentation**

- Low-grade: slow growing, painless mass
- High-grade: rapidly enlarging, +/- pain
- \*\*Minor salivary glands: may be mistaken for benign or inflammatory process

# *Mucoepidermoid Carcinoma*

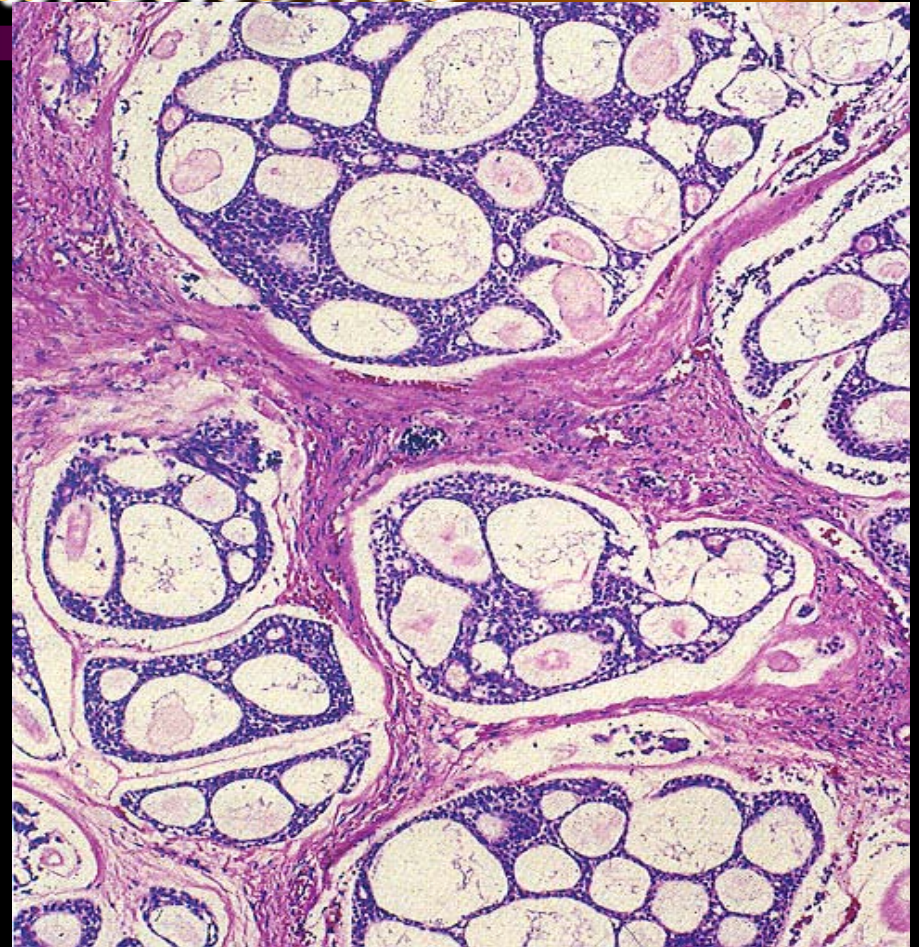
- **Treatment**
  - Influenced by site, stage, grade
  - Low-grade tumors: complete resection by parotidectomy
  - High-grade: parotidectomy, neck dissection (N0 neck) & Radiotherapy

# *Adenoid Cystic Carcinoma*

- Overall, 2<sup>nd</sup> most common salivary gland malignancy
- 2<sup>nd</sup> most common of parotid
- Most common in submandibular, sublingual and minor salivary glands
- M = F
- 5<sup>th</sup> decade
- Presentation
  - Asymptomatic enlarging mass
  - Pain, paresthesias, facial weakness/paralysis

# *Adenoid Cystic Carcinoma*

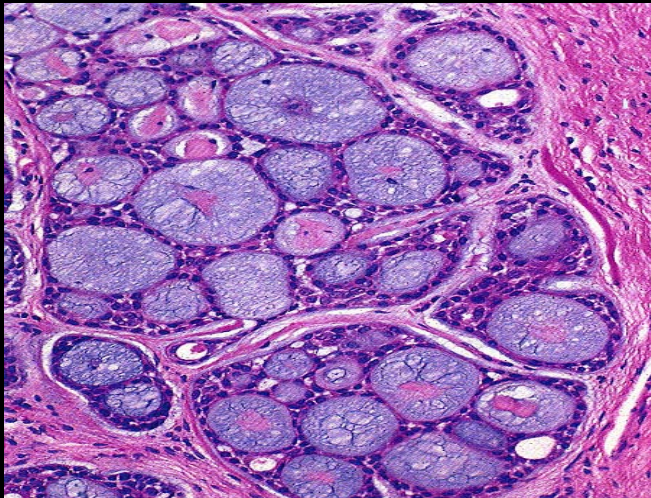
- **Histology**
- **i) cribriform pattern**
  - Most common
  - “swiss cheese” appearance



# *Adenoid Cystic Carcinoma*

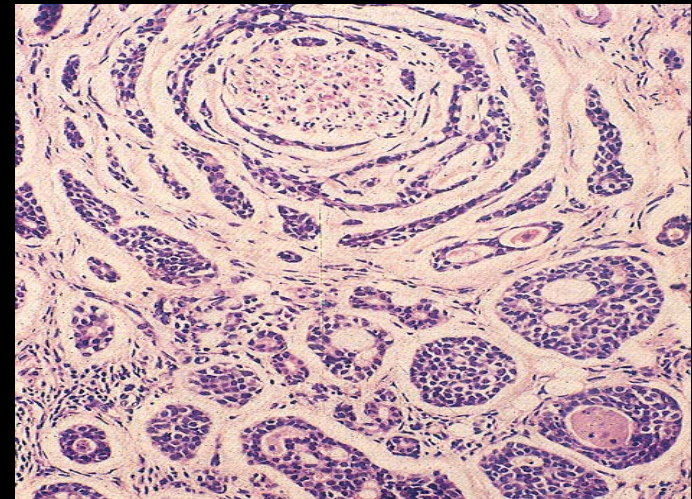
- **ii) tubular pattern**

- Layered cells forming duct-like structures
- Basophilic mucinous substance



- **iii) solid pattern**

- Solid nests of cells without cystic or tubular spaces



# *Adenoid Cystic Carcinoma*



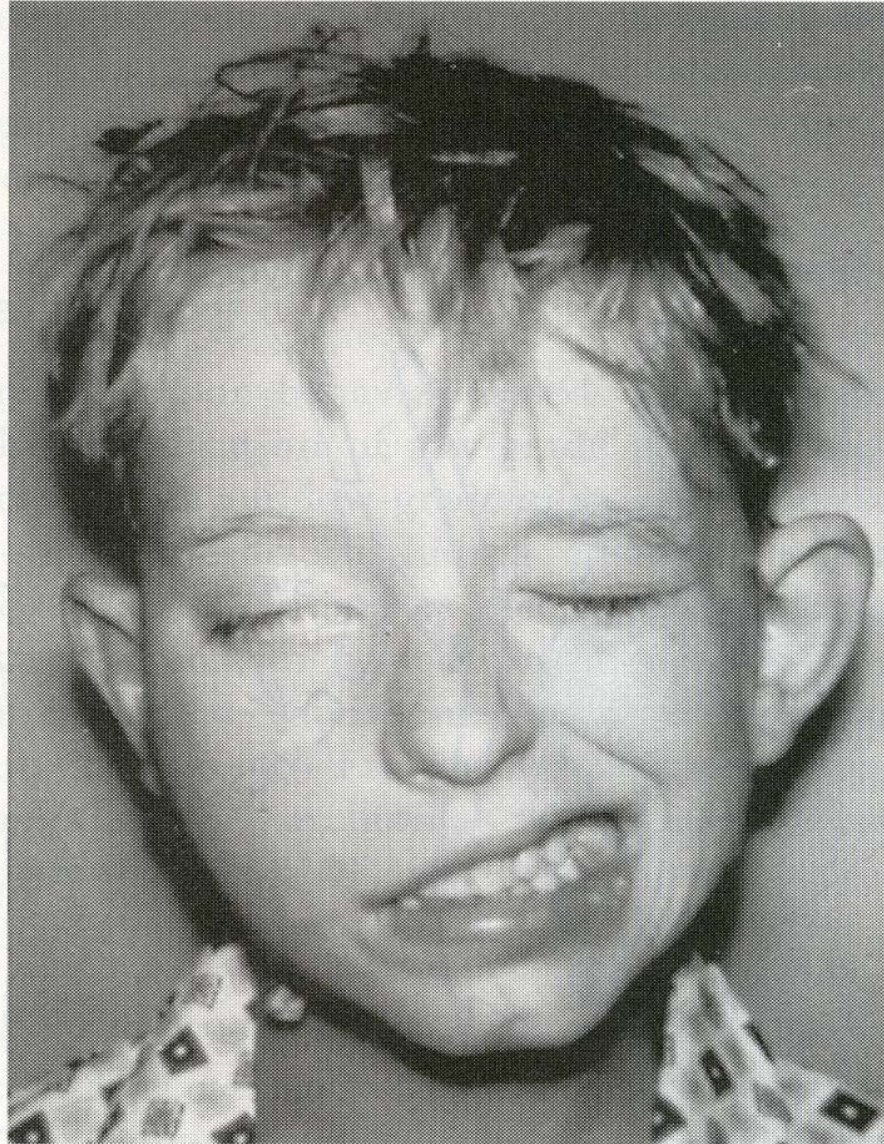- **Treatment**

- Complete local excision
- Tendency for perineural invasion: facial nerve sacrifice
- Postoperative *Neutron Beam XRT*





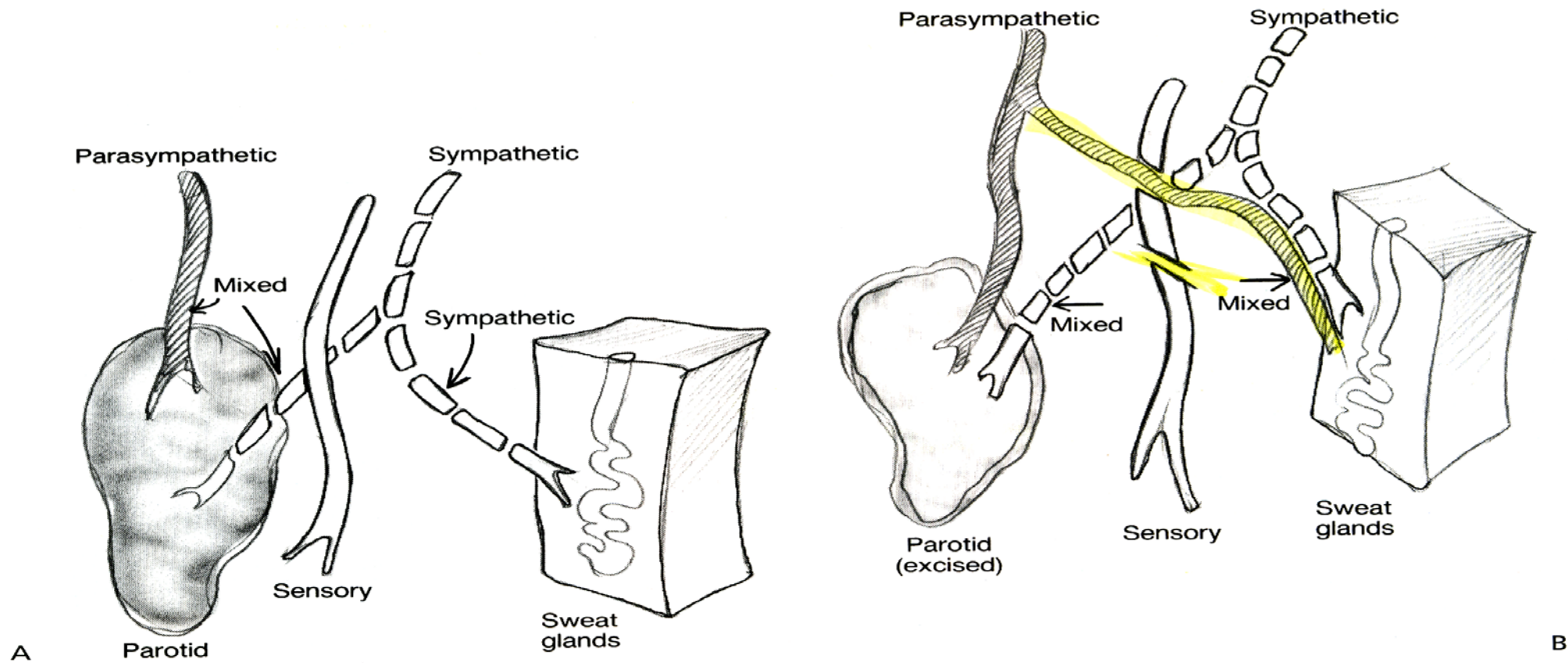
# *Complications*



**FIGURE 107.17.** Right facial paralysis after parotidectomy.

# *Frey's syndrome (Gustatory sweating)*

- *Aberrant reinnervation of postganglionic parasympathetic nerves to the sweat glands of the face*
- 10% of patients overtly symptomatic
- Diagnosis: Minor's starch iodine test



**FIGURE 107.18. A:** Normal innervation of parotid and sweat glands. **B:** Proposed mechanism of gustatory sweating (Frey's syndrome).

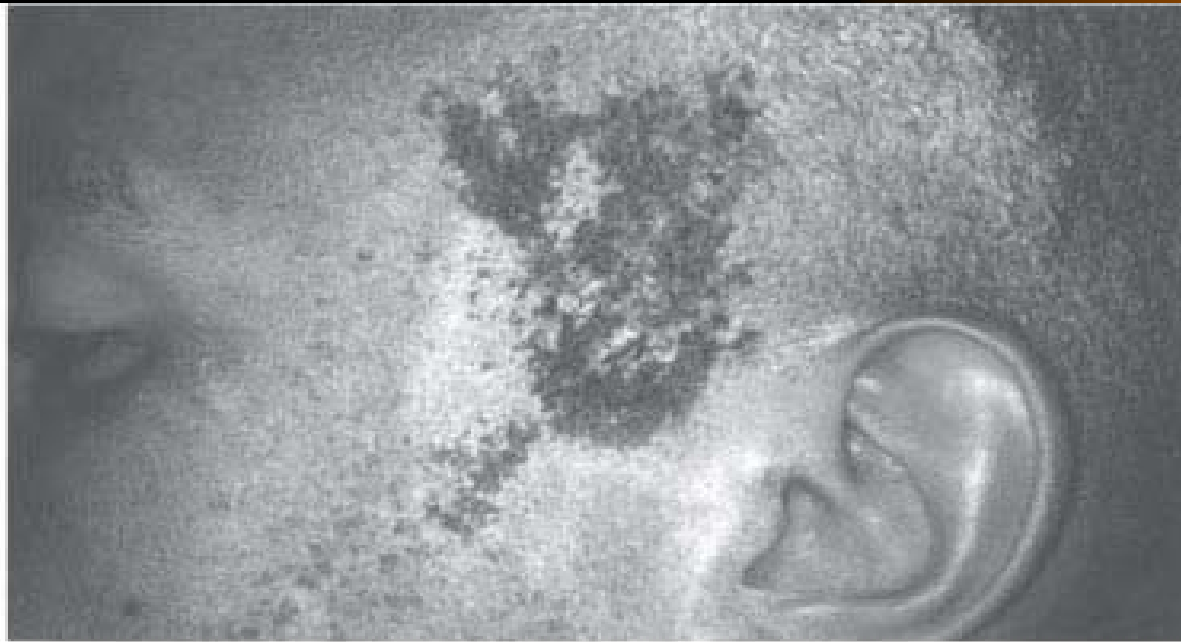

Figure 3. The Minor's test showed areas where the secretion of sweat gland diluted with iodine, which reacted with the starch.

## BOX 61-13

### TREATMENT OF GUSTATORY SWEATING

#### Nonsurgical

- Topical glycopyrrolate
- Topical antiperspirant

#### Botox injection

#### Surgical

- Fat grafting
- Dermal grafting
- Temporalis fascia interposition flap
- Sternocleidomastoid interposition flap
- Tympanic neurectomy

# *Head & Neck Tumours*

## *Part III*

**Khalid Hussain AL-Qahtani**

**MD, MSc, FRCS(c)**

**Medical Director KAUH**

**Associate Professor & Consultant**

**Head & Neck Oncology & Skull Base Surgeon**

**KSU, KFMC**

**Riyadh, Saudi Arabia**

# HN Cancers

```
graph TD; A[HN Cancers] --> B[Known Primary]; A --> C[Unknown Primary]; B --> D[Mucosal]; B --> E[Non-Mucosal]; D --> D1["-Oral"]; D --> D2["-Sinonasal"]; D --> D3["-Pharyngeal"]; D --> D4["-Laryngeal"]; E --> E1["-Endocrine"]; E --> E2["-Salivary"]; E --> E3["-Skin"]; E --> E4["-Paragangliomas"];
```

The diagram is a hierarchical flowchart titled 'HN Cancers'. It starts with a root node 'HN Cancers' at the top. This node branches into two main categories: 'Known Primary' on the left and 'Unknown Primary' on the right. The 'Known Primary' category further branches into 'Mucosal' and 'Non-Mucosal'. Under 'Mucosal', there are four sub-items: '-Oral', '-Sinonasal', '-Pharyngeal', and '-Laryngeal'. Under 'Non-Mucosal', there are four sub-items: '-Endocrine', '-Salivary', '-Skin', and '-Paragangliomas'. The 'Unknown Primary' category is currently empty. The nodes are light orange rounded rectangles, and the connections are thin orange lines. A decorative purple and orange gradient bar is positioned behind the 'Known Primary' and 'Non-Mucosal' nodes.

Known Primary

Unknown Primary

Mucosal

Non-Mucosal

-Oral

- Sinonasal

- Pharyngeal

-Laryngeal

-Endocrine

- Salivary

- Skin

- Paragangliomas



# HN Mucosal Cancers

	DDX	Risk Factors	Presentation	RX
Sinonasal				
Oral				
Pharynx				
Larynx				

# *Content*



- **Tumours of the Mouth**
- **Tumours of the Pharynx**
- **Tumours of the Larynx**

# *Oral Cavity Cancer*



- **Introduction**
- **Premalignant Lesions**
- **Malignant Lesions**

# *Premalignant Lesions*



- **Leukoplakia**
  - Hyperkeratosis, dysplasia
  - Malignant transformation greater in non-smokers
  - Treatment:
    - Surgical or laser excision
    - Topical bleomycin, retinoids
- **Erythroplasia**
  - Greater risk of malignancy

# *Epidemiology*

- **95% are squamous cell carcinoma**
- **Risk factors**
  - Smoking (depends on dosage and type)
  - Alcohol
  - Tobacco chewing
  - HPV (subtype 16)
  - ?Poor dentition / mechanical irritation (dentures)

# *Differential Diagnosis*

- **Granular cell myoblastoma**
- **Minor salivary gland neoplasm**
  - Adenoid cystic, mucoepidermoid, adeno-ca.
- **Sarcomas (rhabdo, lipo, MFH, leiomyo)**
- **Hodgkin and NH lymphoma**
- **Malignant melanoma**
- **Hairy leukoplakia, Kaposi sarcoma**
  - HIV, immunocompromised

# *Treatment*



- **Team approach**
  - Surgeons and Radiation Oncologists
  - SLP
  - Oral Surgeon
- **T1 and T2 – surgery or radiation**
- **T3 and T4 – combined modality**

# *Tumours of Pharynx*



- **Nasopharyngeal Carcinoma**
- **Oropharyngeal Carcinoma**
- **Hypopharyngeal Carcinoma**



# *Nasopharyngeal Carcinoma*

## *Introduction*



- **Rare in the US, more common in Asia**
- **High index of suspicion required for early diagnosis**
- **Nasopharyngeal malignancies**
  - SCCA (“nasopharyngeal carcinoma”)
  - Lymphoma
  - Salivary gland tumors
  - Sarcomas

# *Classification*



- **WHO classes**
  - Based on light microscopy findings
  - All SCCA by EM
- **Type I - “SCCA”**
  - 25 % of NPC (in North Amer population)
  - 1-2 % NPC of endemic populations
  - moderate to well differentiated cells similar to other SCCA ( keratin, intercellular bridges)

# *Classification*



- **Type II - “non-keratinizing” carcinoma**
  - 12 % of NPC
  - variable differentiation of cells (mature to anaplastic)
  - minimal if any keratin production

# *Classification*



- **Type III - “undifferentiated” carcinoma**
  - 60 % of NPC in North Amer population, majority of NPC in young patients, and 95% of endemic cases
  - Difficult to differentiate from lymphoma by light microscopy requiring special stains & markers

# *Epidemiology*



- **Chinese native (esp Guangdong province) > Chinese immigrant > North American caucasian**
  - Both genetic and environmental factors
- **Genetic**
  - HLA histocompatibility loci possible markers
    - HLA-A2, B17 and Bw46

# *Epidemiology*



- **Environmental**

- Viruses

- EBV- well documented viral “fingerprints” in tumor cells and also anti-EBV serologies with WHO type II and III NPC
    - HPV - possible factor in WHO type I lesions

- Nitrosamines - salted fish

- Others - polycyclic hydrocarbons, chronic nasal infection, poor hygiene, poor ventilation

# *Clinical Presentation*



- **Often subtle initial symptoms**
  - unilateral HL (SOM)
  - painless, slowly enlarging neck mass (70%)
    - Lymphatic channels cross midline in NP, bilateral disease common
- **Larger lesions**
  - nasal obstruction
  - epistaxis
  - cranial nerve involvement

# *Treatment*



- **External beam radiation**
- **Adjuvant Chemotherapy**



# *Oropharyngeal Cancer*

## *Introduction*



- **Relatively uncommon**
- **6<sup>th</sup> and 7<sup>th</sup> decades mainly**
- **Male predominance**
- **SCC = 90%**
- **Tobacco and alcohol**
- **Complex, multimodal treatment**
- **Team approach**

# *Anatomy*



- **Pharyngeal walls**
- **Tonsils sit in tonsillar fossa**
- **Soft Palate**
- **Base of Tongue**

# ***Etiology***



- **SCC arise from the accumulation of multiple genetic alterations to genes important to the regulation of cell growth and death**
- **Cells have selective growth advantage**
  - Genetic
  - Environmental
    - Tobacco and alcohol
    - Dose related
    - Synergistic
  - HPV and EBV
  - Dietary factors
  - Immunosuppression

# *Histopathology*



- **Premalignant lesions**
  - Leukoplakia
  - Erythroplakia
  
- **SCC and variants >90%**

# *Treatment*



- **Team approach**
  - Surgeons and Radiation Oncologists
  - SLP
  - Oral Surgeon
- **T1 and T2 – surgery or radiation**
- **T3 and T4 – combined modality**

# *Hypopharyngeal Cancer*

- Incidence – 5-10% of all upper aerodigestive cancers (0.5% of all malignancies)
- M>F: males have 8X increased risk

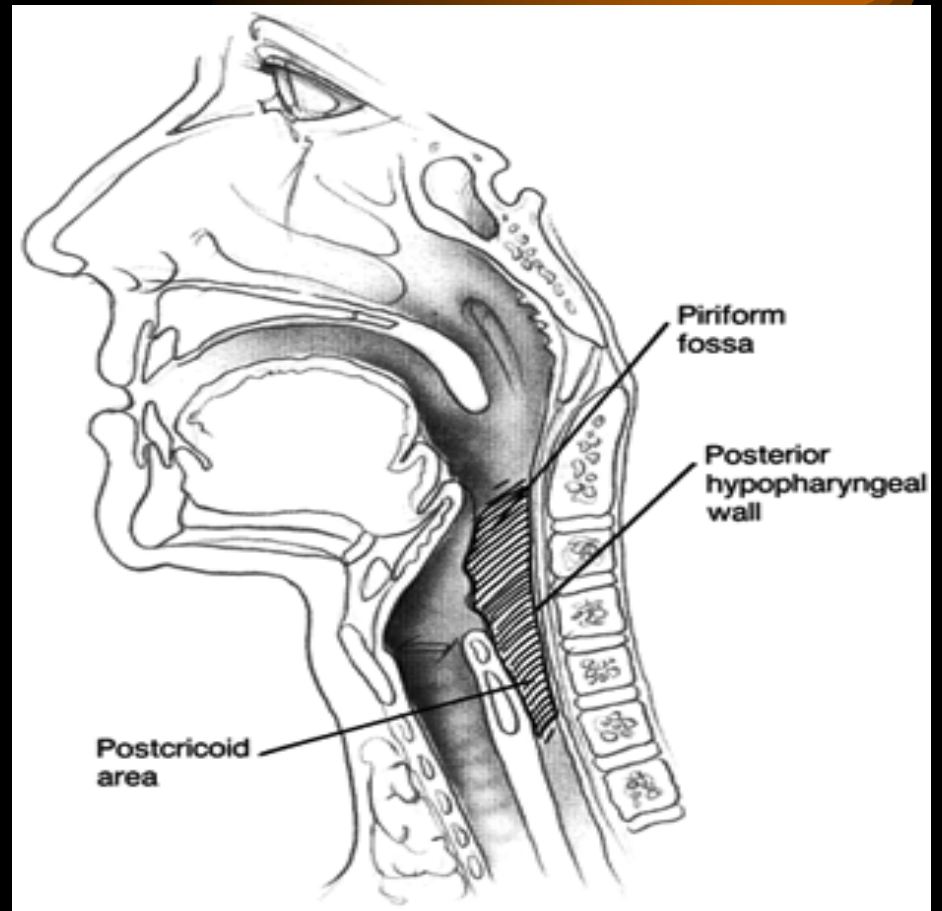
# *Hypopharyngeal Cancers*



- **Risk Factors**
  - Smoking
  - EtOH
  - Chronic reflux disease
- **Treatment Challenge:**
  - Patients often present with advanced disease
  - May be complicated by severe malnutrition

# *Hypopharynx - Anatomy*

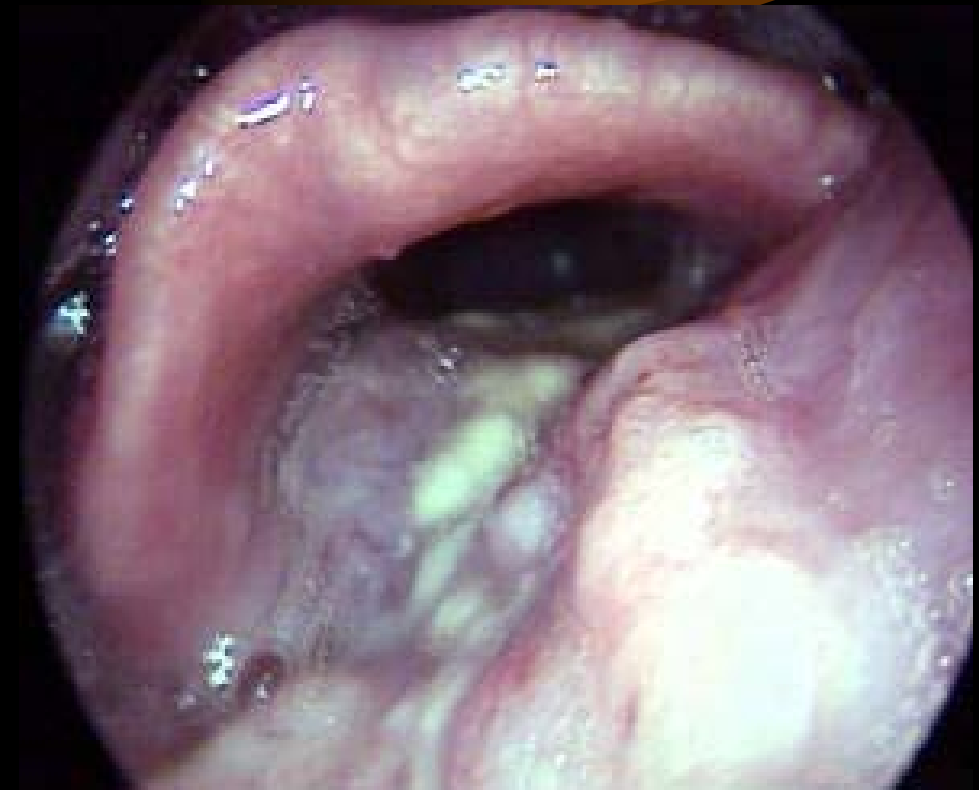- Abuts the oropharynx at the level of the hyoid, extends to the level of the inferior border of the cricoid
- 3 sub-sites: piriform fossa(e), post-cricoid region, posterior pharyngeal wall





# *Staging Endoscopy*

- **Most important component of procedure (secondary to obtaining Bx samples for diagnosis) is determining the inferior limit of the tumour**
- **Common site: piriform fossae, post pharyngeal wall, post-cricoid region**



# *Pathology*



- **~95% of cancers of the hypopharynx are SCC**
- **Lymphomas**
  - Angiocentric T-cell lymphoma
  - MALT (mucosa associated lymphoid tissue)
  - Non-hodgkins lymphoma
- **Adenocarcinomas**
  - May originate in the minor salivary glands of the hypopharynx

# *Surgical Tx Options*



- **Based on Site of Involvement**
  - Piriform Fossa (64%)
  - Posterior Pharyngeal Wall (30%)
  - Post-cricoid (4%)
- **Team approach**
  - Surgeons and Radiation Oncologists
  - SLP
  - Oral Surgeon
- **T1 and T2 – surgery or radiation**
- **T3 and T4 – combined modality**

# *Laryngeal Tumours*



- **Introduction**
- **Benign Lesions**
- **Malignant Lesions**

# *Epidemiology*



- **11 600 new cases laryngeal cancer per year in USA**
- **~1% of all cancers (excluding skin)**
- **79% occur in ♂**
- **>90% are squamous cell carcinomas (SCC)**

# ***Etiology***



- **EtOH – supraglottic**
- **Tobacco – glottic**
- **GERD – chronic laryngeal irritation**
- **Viral infection**
- **Radiation**

# *Laryngeal Papillomatosis*

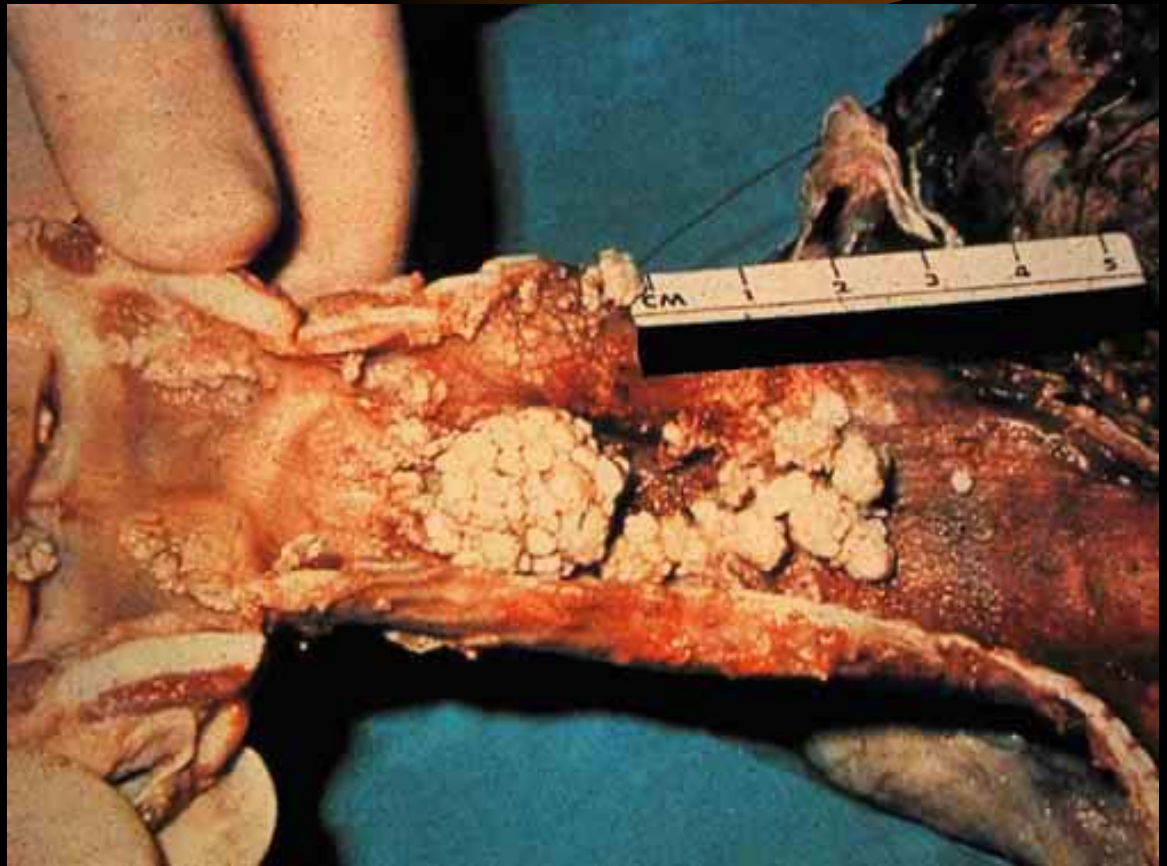- **Most common benign laryngeal tumor, HPV etiology**
- **Vocal folds and subglottis most common laryngeal sites**

# *Laryngeal Papillomatosis*

- **More prevalent in children, less common in individuals over 30 years of age**
  - HPV is transmitted to child through birth canal from cervix
  - Risk of transmission 1:400
- **Papillomas appear multinodular, and may be either sessile or exophytic**
  - May resemble carcinoma-in-situ or even invasive SCC



*Exophytic,  
warty,  
friable, tan-  
white to red  
growths*



# *Laryngeal Papillomatosis*

- **Most common viral subtypes are 6 or 11, but 16 or 18 have higher potential for malignant change**
- **Hoarseness is common early symptom followed by airway obstruction and respiratory difficulty**

# *Laryngeal Papillomatosis*

- **Laryngeal papillomas presenting in adults seem to be less aggressive than juvenile form but remission rate unpredictable**
  - In adults, growth may be rapid during periods of hormone change such as during pregnancy
- **Malignant degeneration of laryngeal papillomas rare and usually associated with history of radiotherapy, tobacco abuse or both**

# *Treatment*



## – Surgery


- Laser microlaryngoscopy (most commonly CO<sub>2</sub> [10.6um] or Nd:YAG [1.06um]) at power setting of 2-8W pulse or continuous
- Powered microdebrider
- Always biopsy before remainder of case proceeds

# *Cont Treatment*



- Interferon
  - Bad chronic side-effects (myalgias, flu-like symptoms)
  - Lesions tend to return after interferon finished
- Intralesional cidofovir (acyclic nucleoside analogue)
- Indole-3-carbinol (found in cruciferous vegetables, works via inhibition of estrogen metabolism)
- Acyclovir
- Photodynamic therapy

# *Anatomy - Glottis*

- **True vocal cords**
  - **Anterior and posterior commissures**
  - **Superior limit – apex of ventricle**
  - **Inferior limit – 1 cm inferior to line through apex**
- 
- A decorative graphic consisting of a horizontal line with a gradient from purple to yellow, ending in a large, stylized arrowhead shape pointing to the right. The arrowhead is filled with a gradient from dark brown to light brown.

# *Symptoms*



- **Hoarseness >4 weeks – investigate**
- **Occasionally may present without hoarseness**
- **Dysphagia**
- **Hemoptysis**

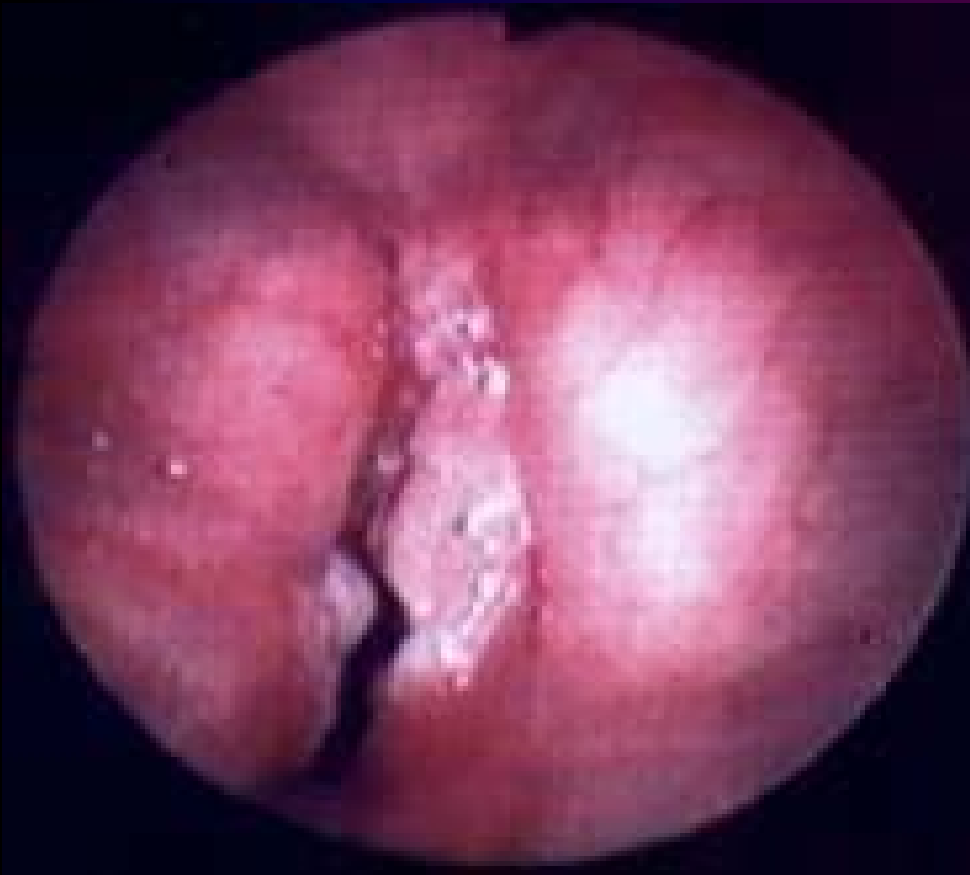# *Glottic Carcinoma*



- **Early: irregular area of mucosal thickening**
- **Advanced: exophytic, fungating, endophytic, ulcerated mass**
- **More commonly keratinizing, well to moderately differentiated**
- **In situ component**
- **Invasive component predominantly infiltrative**

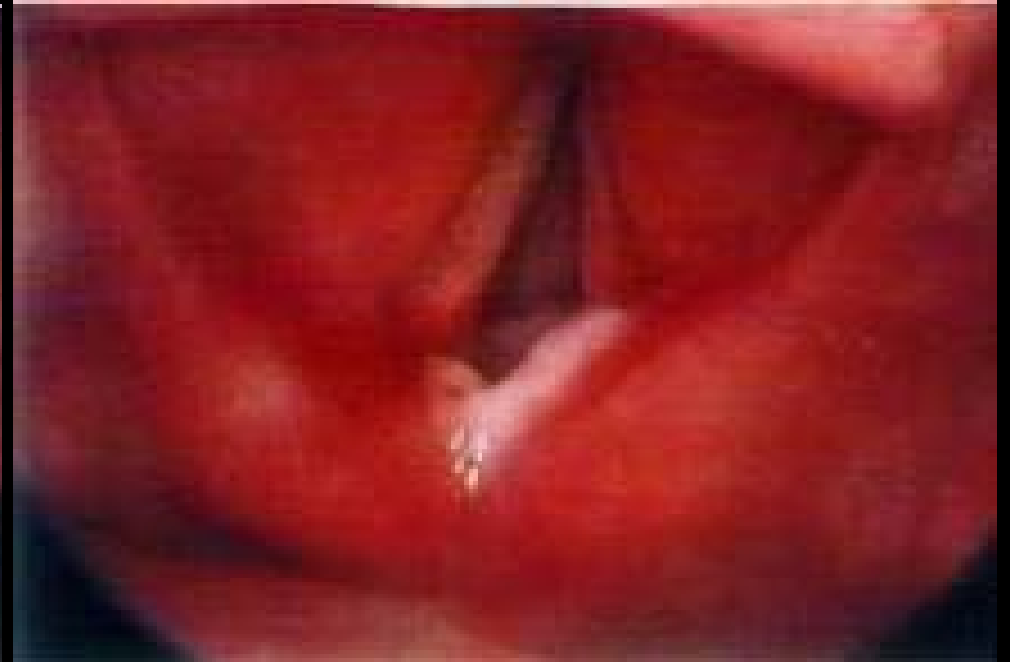
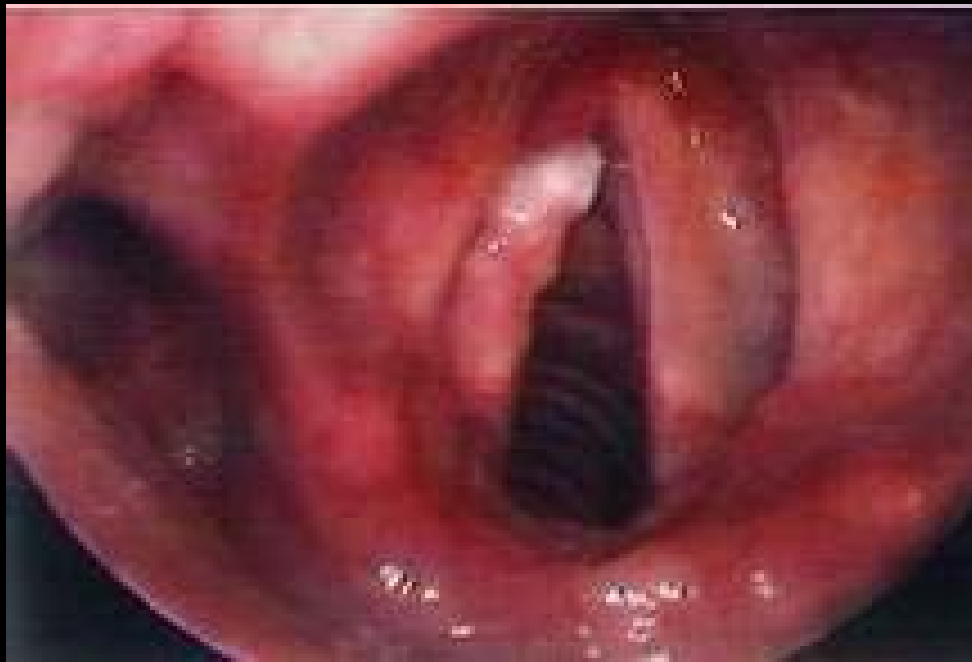
# *Glottic Carcinoma*



- **Most tumors originate on free surface of vocal cord**
- **Anterior 2/3**

# *Glottic Carcinoma*



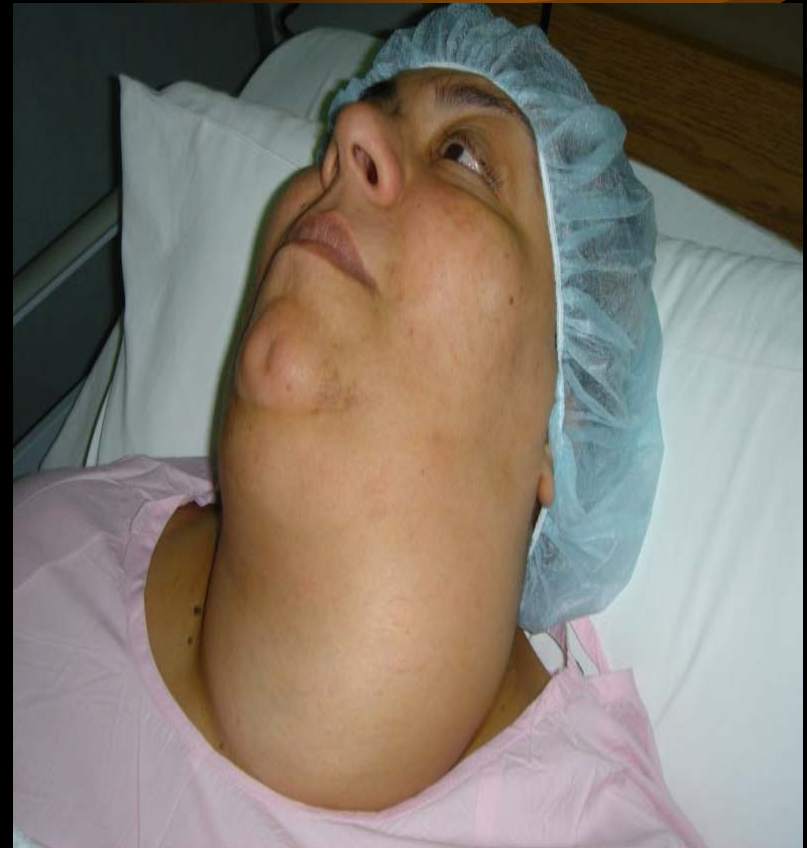
# *Treatment*

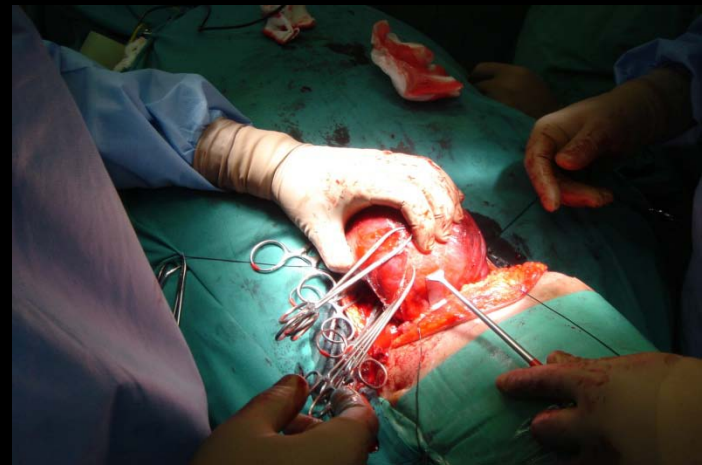
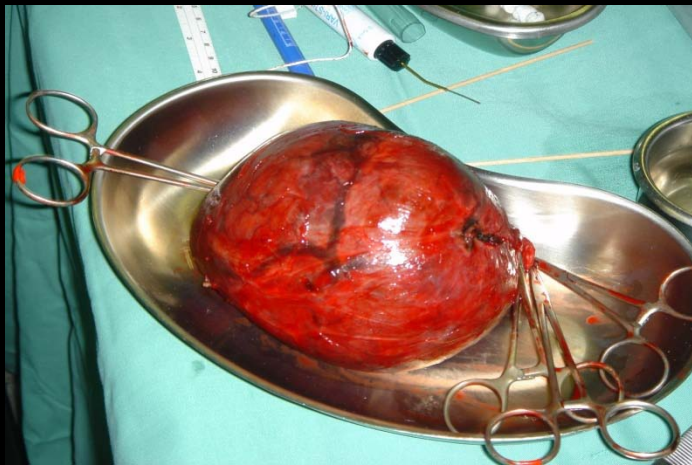
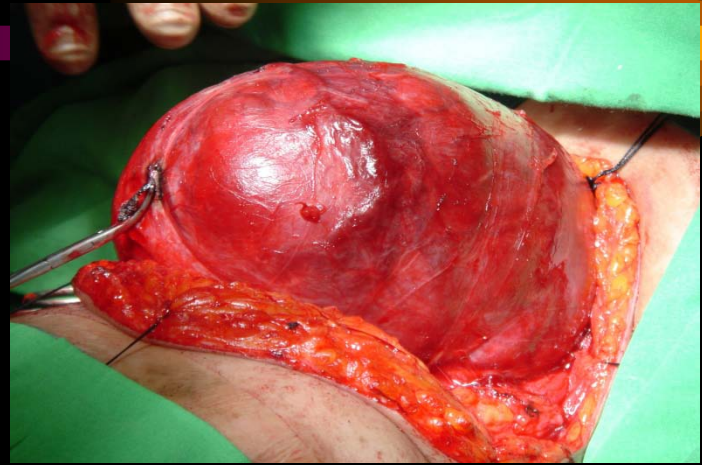
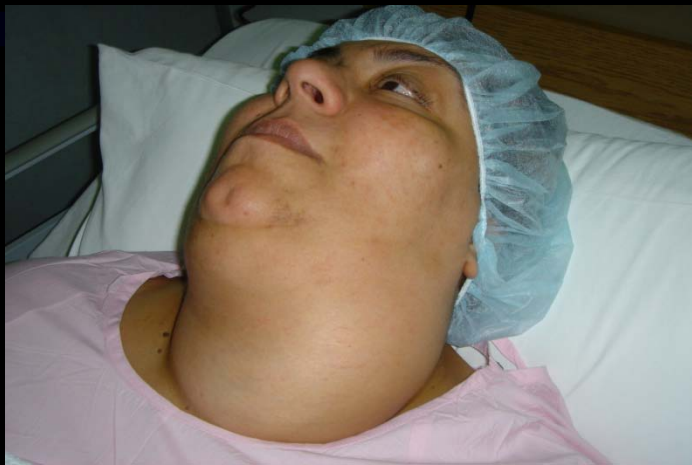

- **Early Stage:**  
**Laser or Radiation**
- **Advance Stage:**  
**Chemo+Radiation**  
**Surgery+Radiation**

# *Case 1*

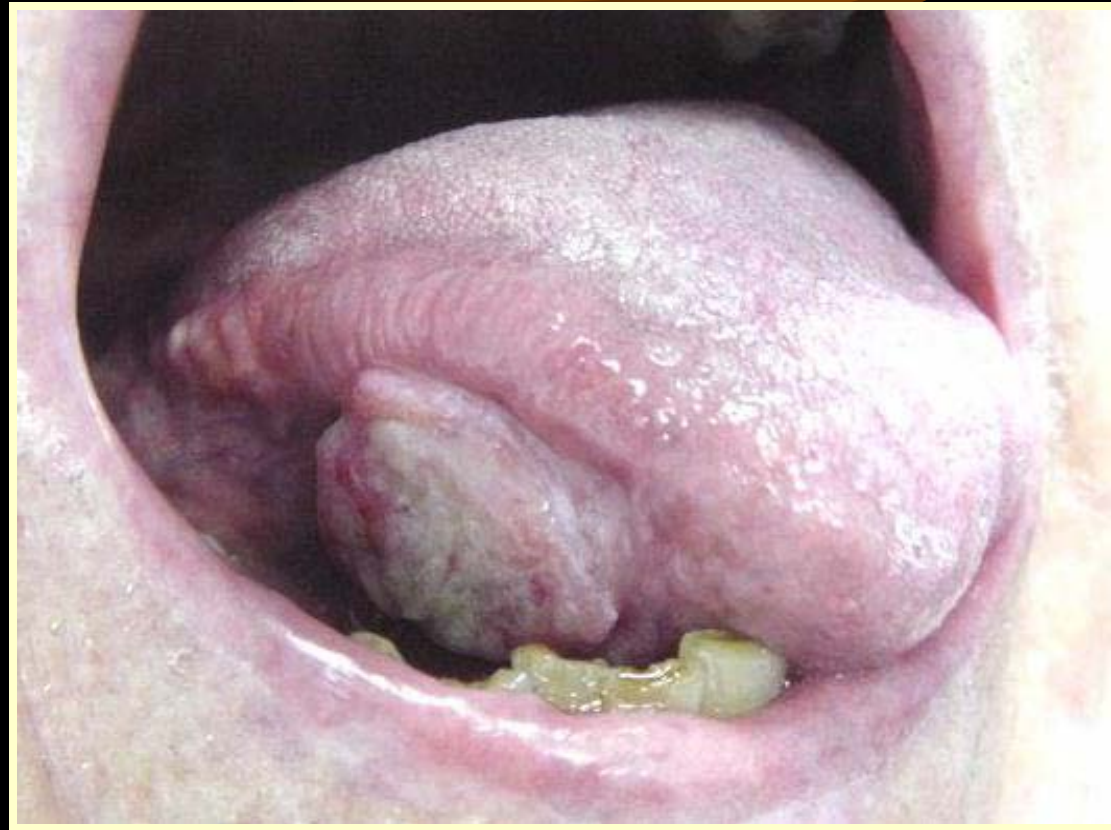- **What is abnormal?**
- **What is your DDx?**
- **What is the most likely Dx?**
- **Work up**
- **Management**





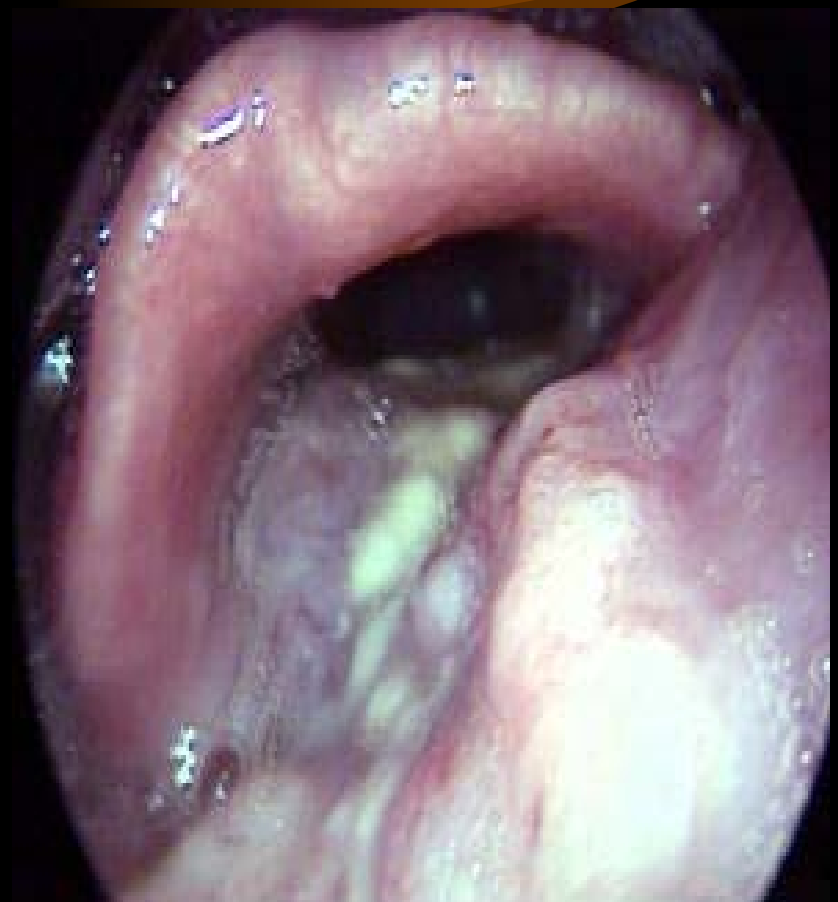## *Case 2*

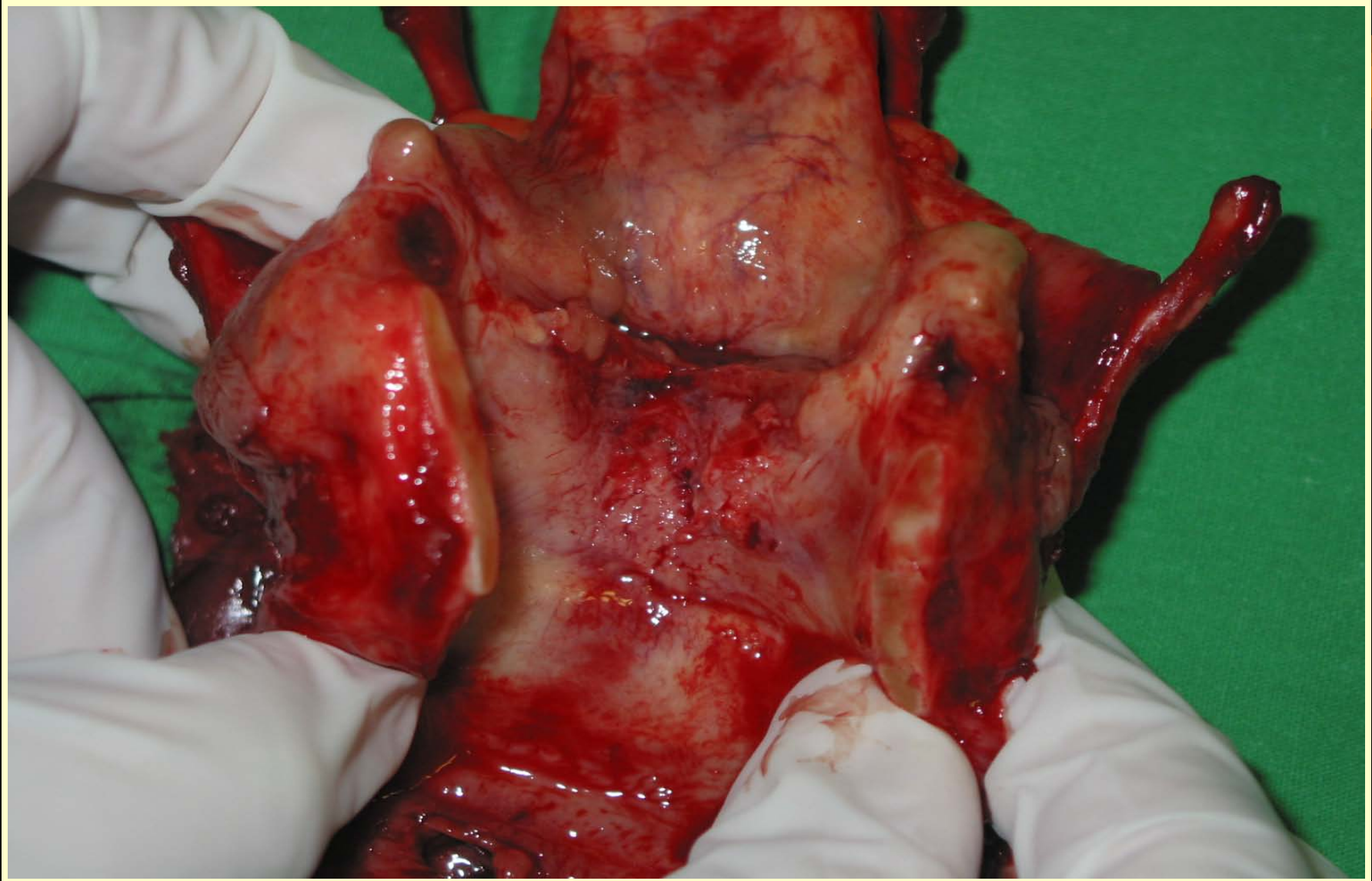- **What is abnormal?**
- **What is your DDx?**
- **What is the most likely Dx?**
- **Work up**
- **Management**



## *Case 3*

- **65 y old**
- **C/O : hoarseness X 10 Months**
- **Heavy smoker-2p/day X 40 years**
- **O/E :**
  - hoarse voice
  - Mild stridor
  - Neck mass 5X4 CM

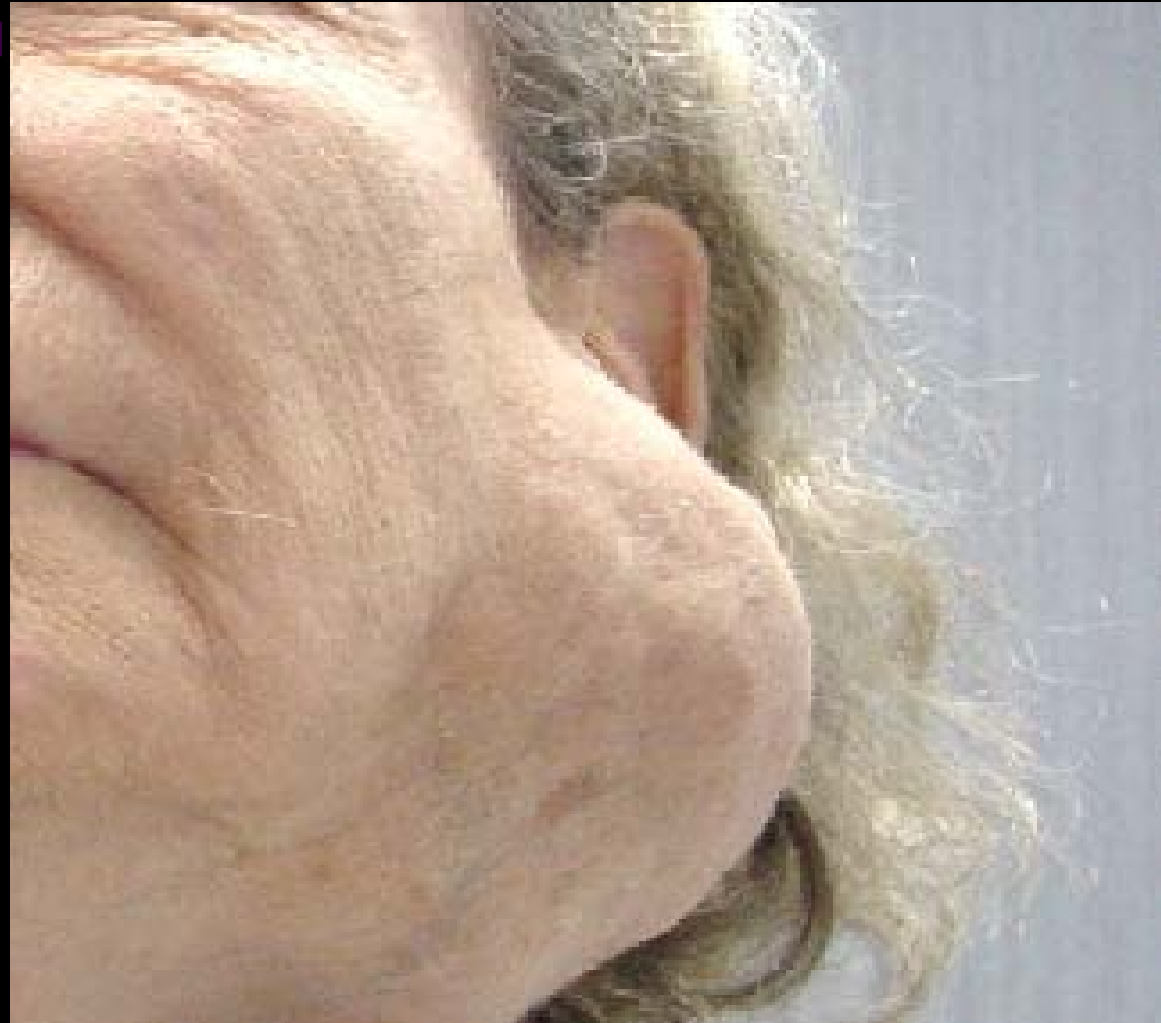

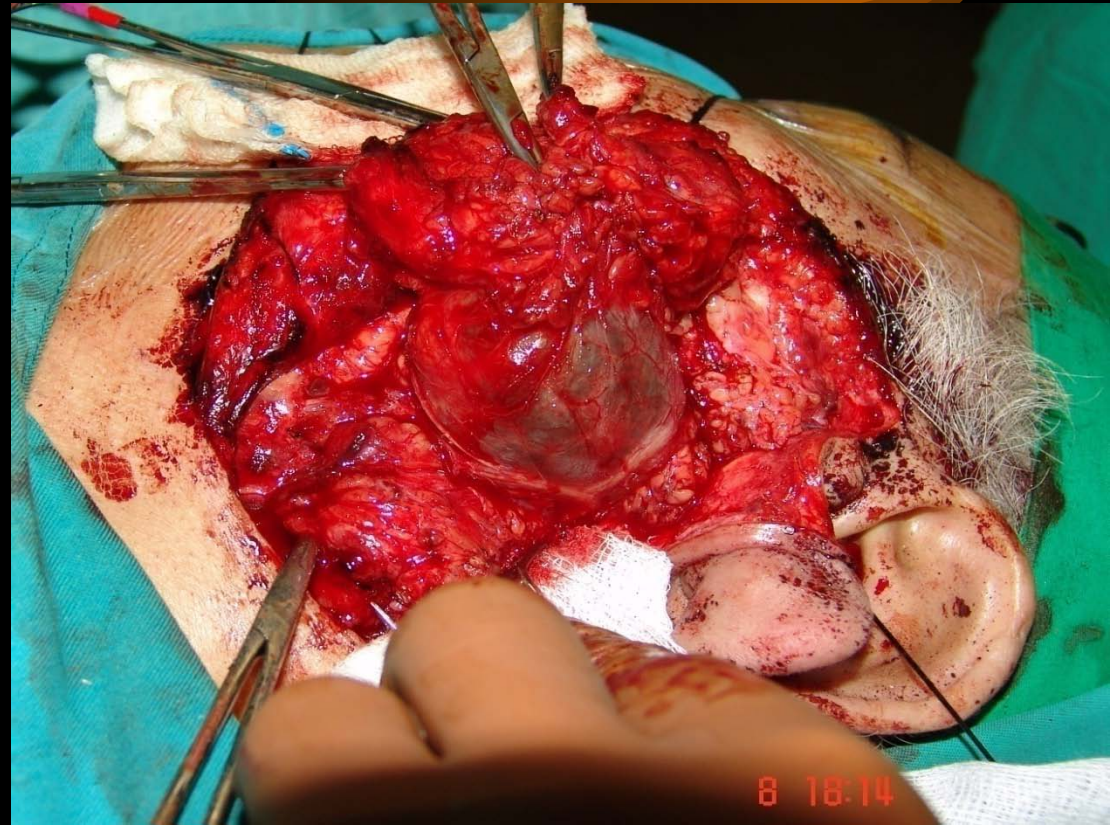

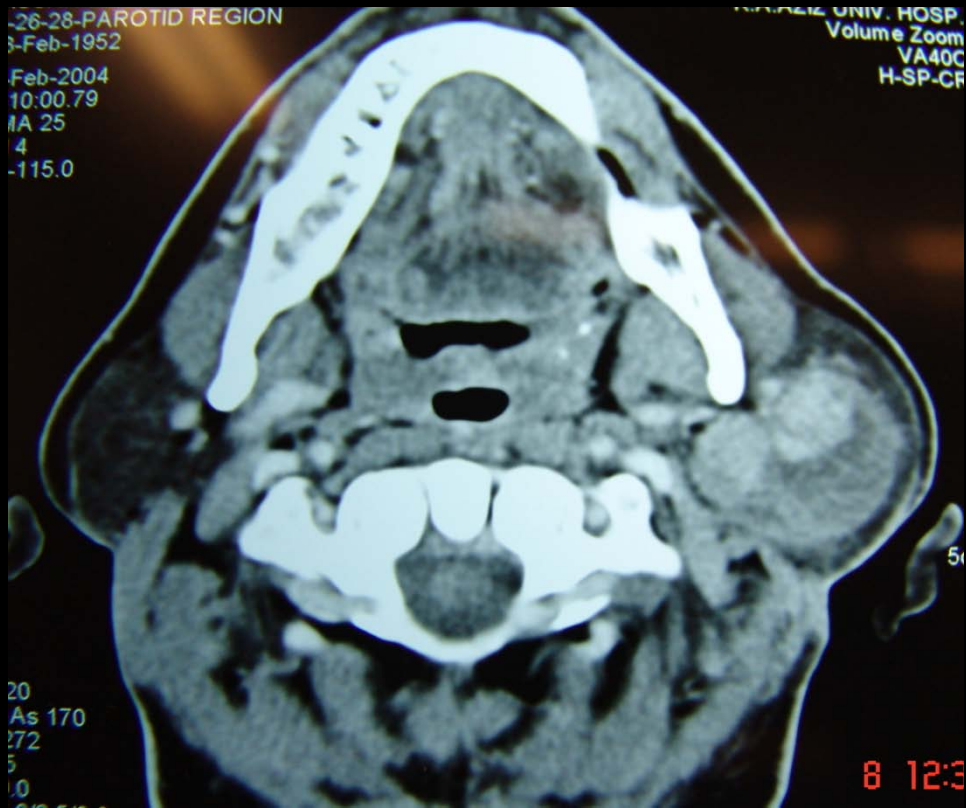
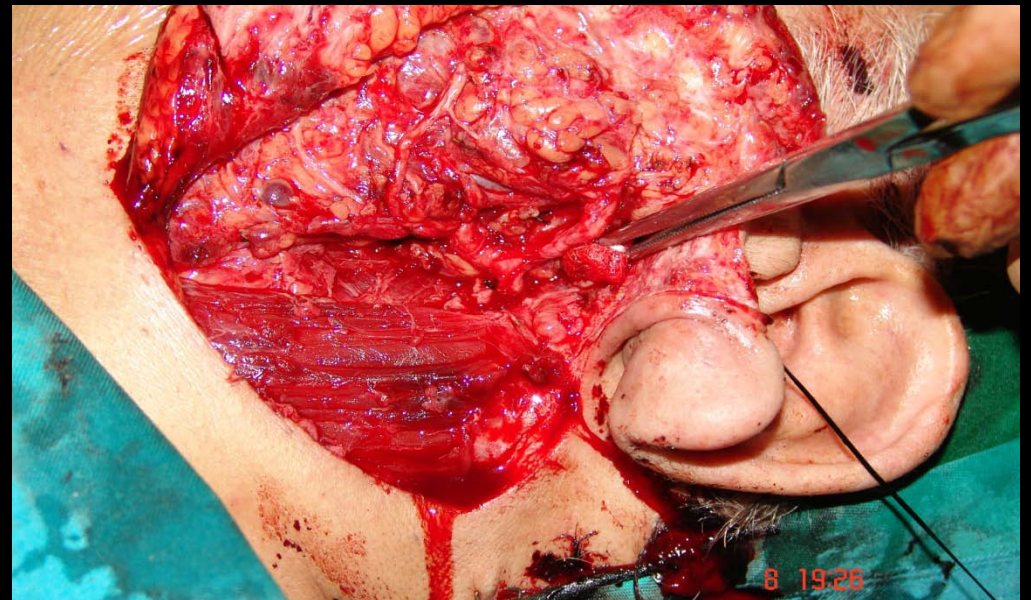
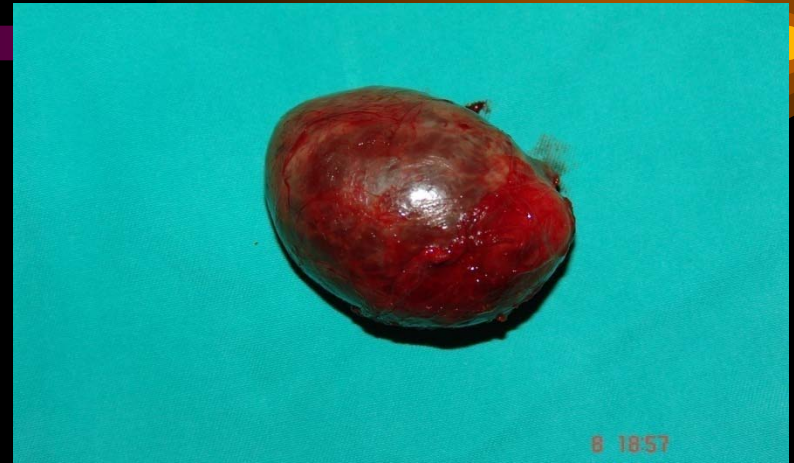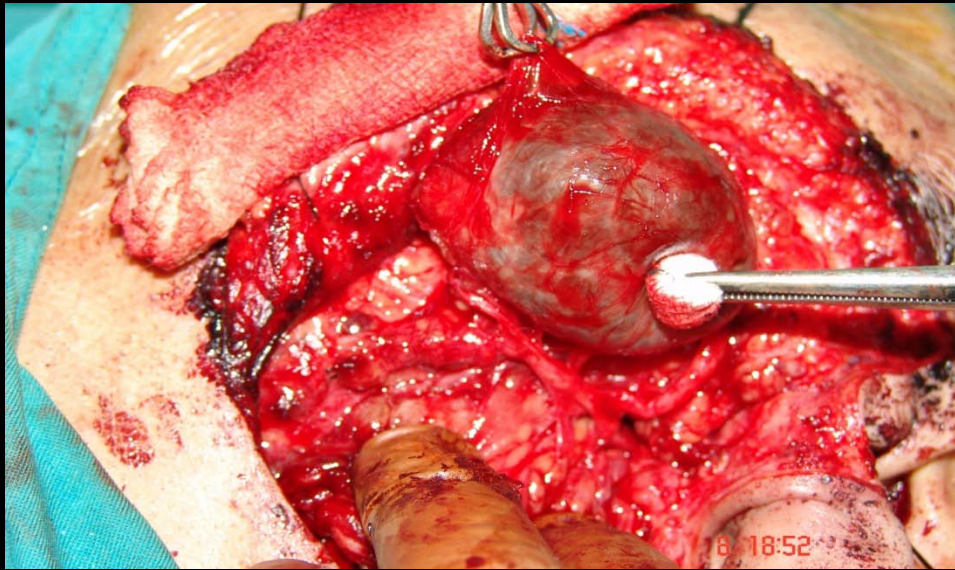


## *Case 4*

- **What is abnormal?**
- **What is your DDx?**
- **What is the most likely Dx?**
- **Work up**
- **What are the areas you should examine?**
- **Management**
- **Can we leave it?**

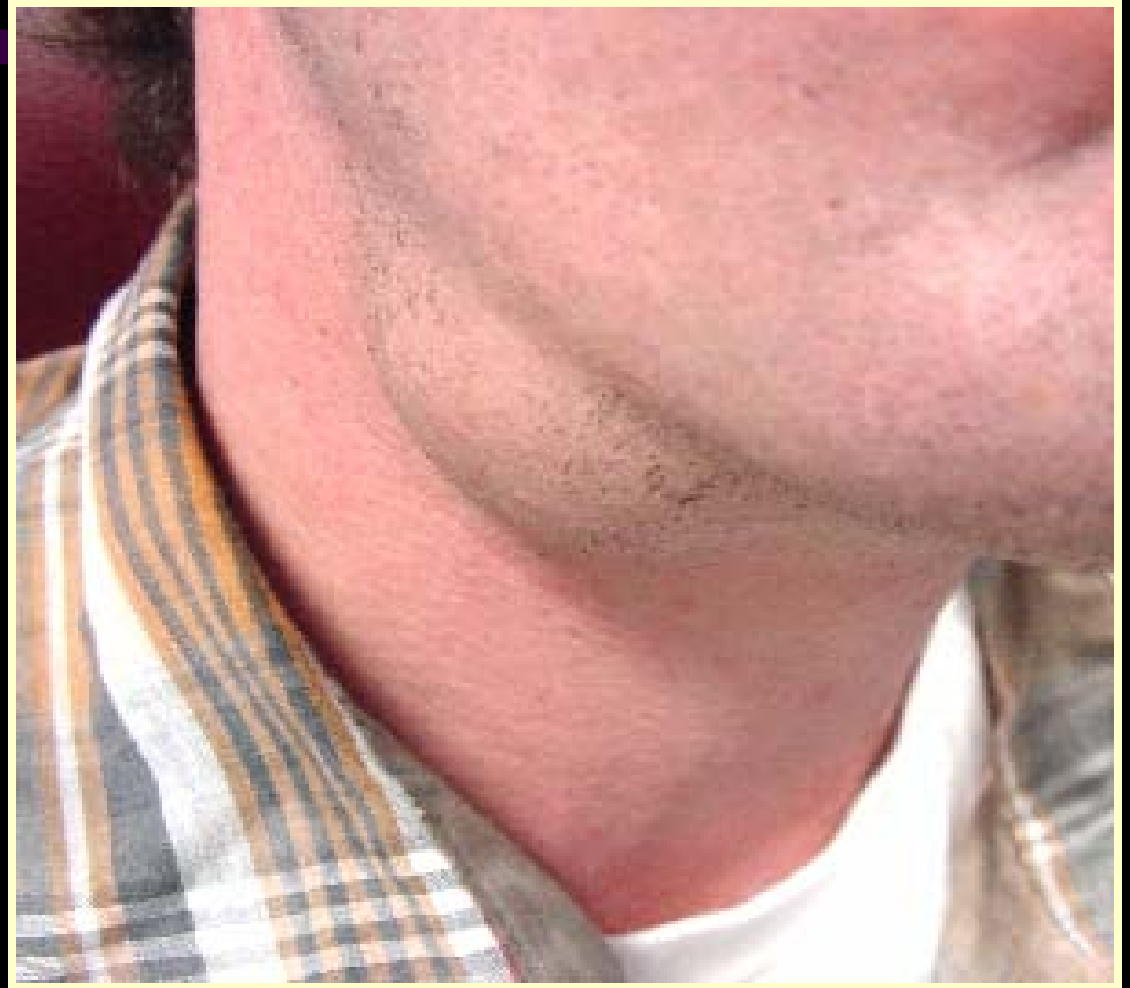

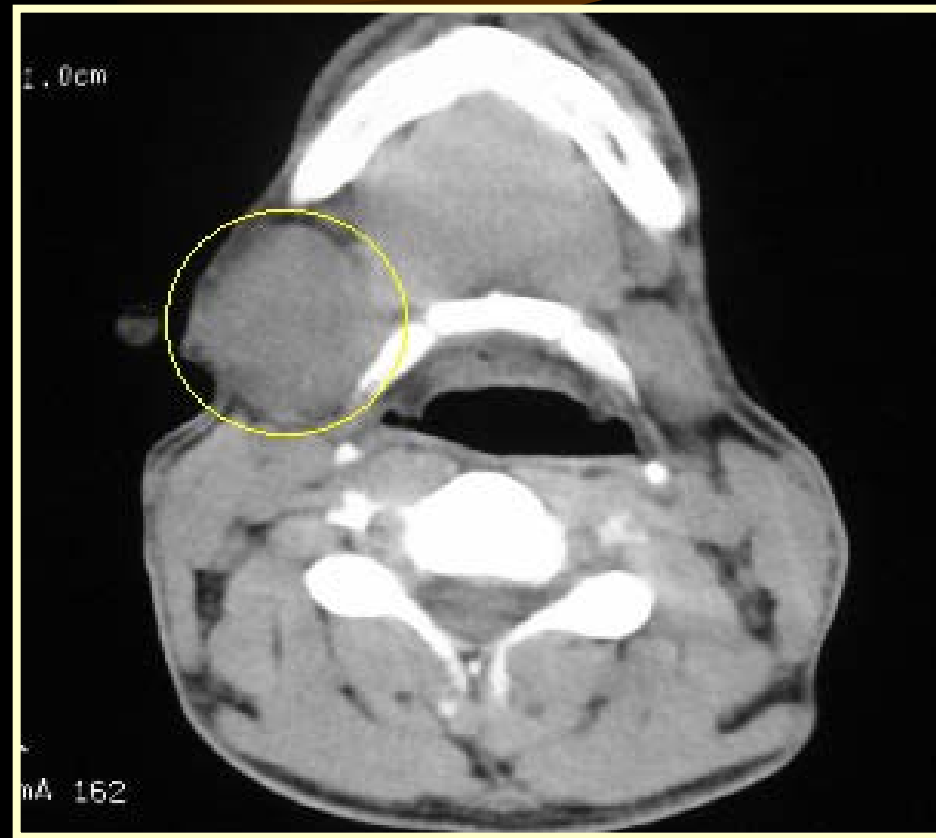
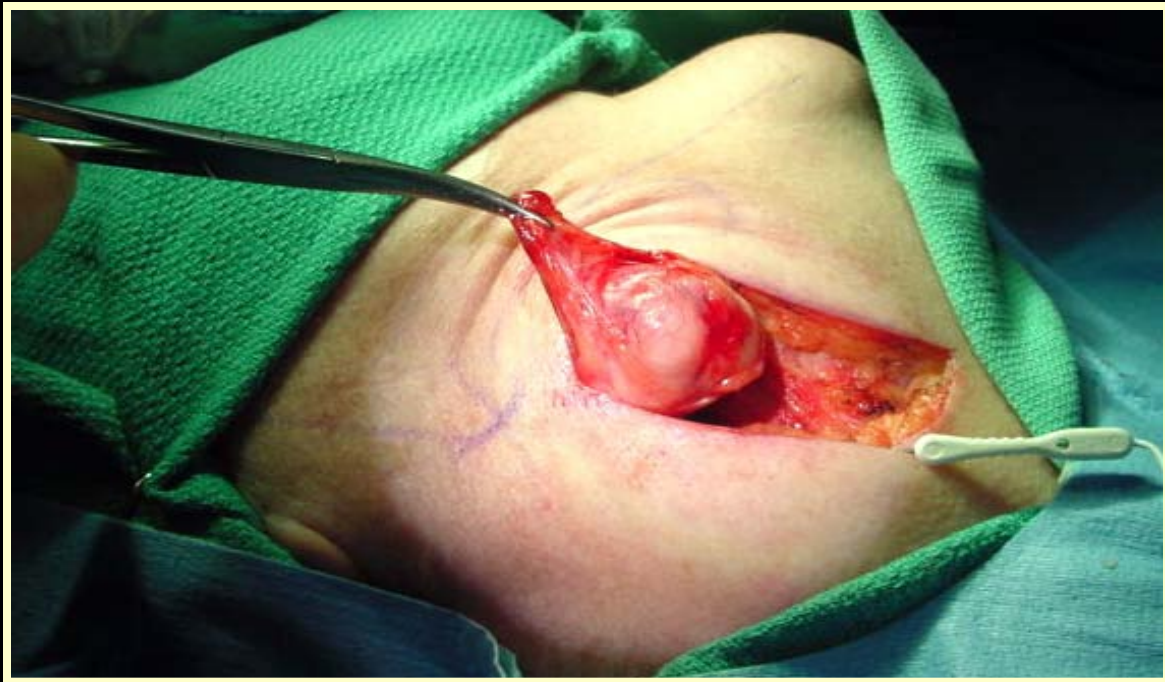




## *Case 5*

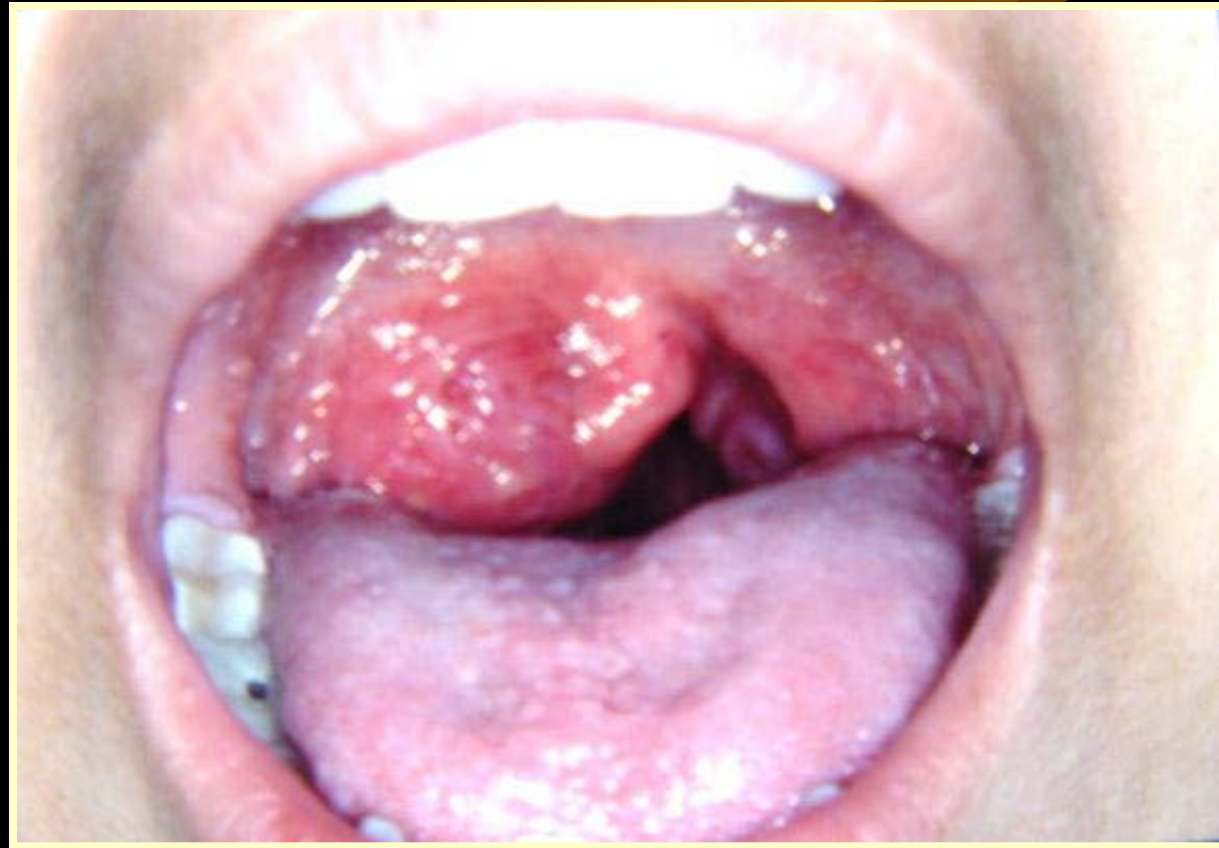- **What is abnormal?**
- **What is your DDx?**
- **What is the most likely Dx?**
- **Work up**
- **Management**





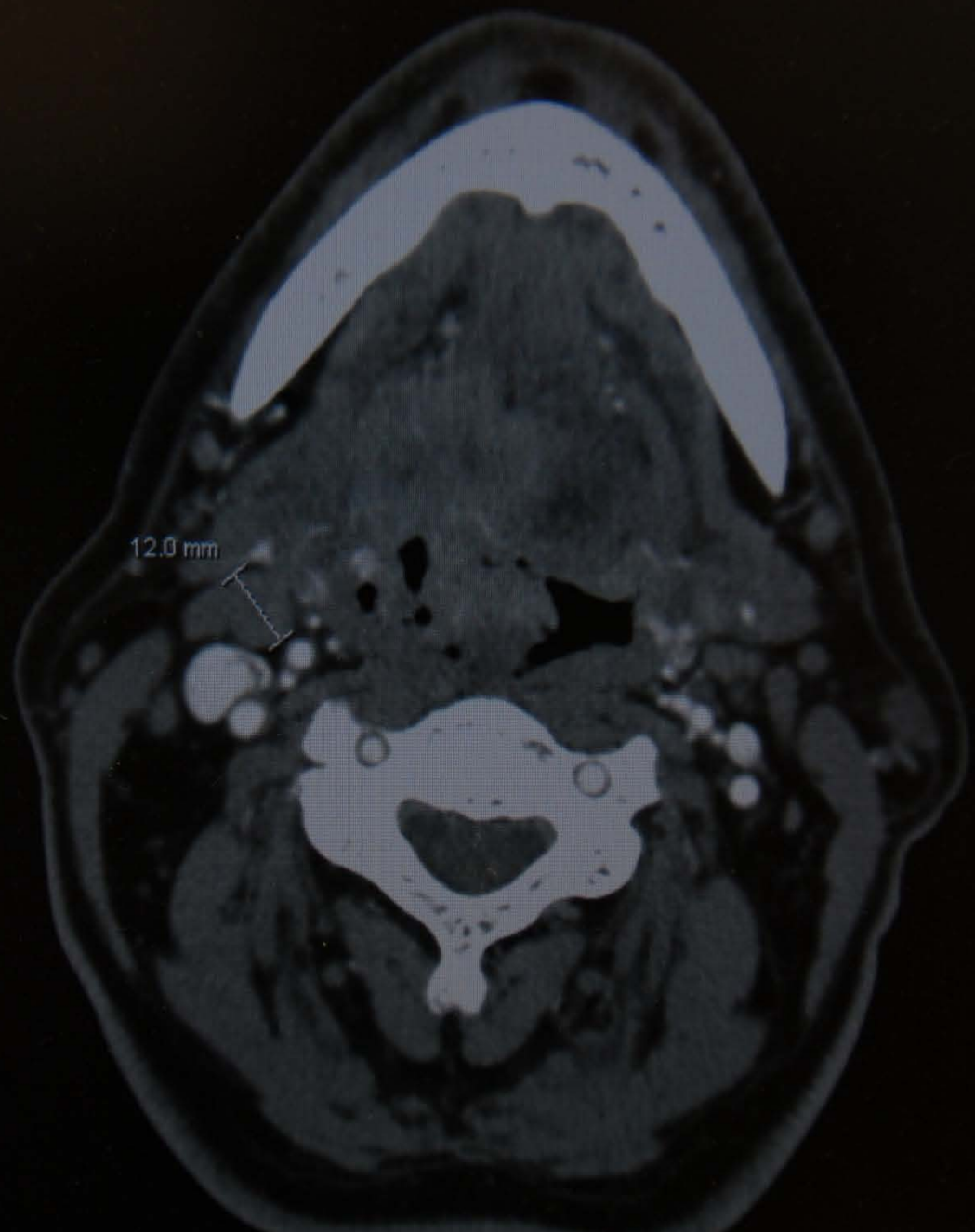
## *Case 6*

- **What is abnormal?**
- **What is your DDx?**
- **What is the most likely Dx?**
- **Work up**
- **Management**

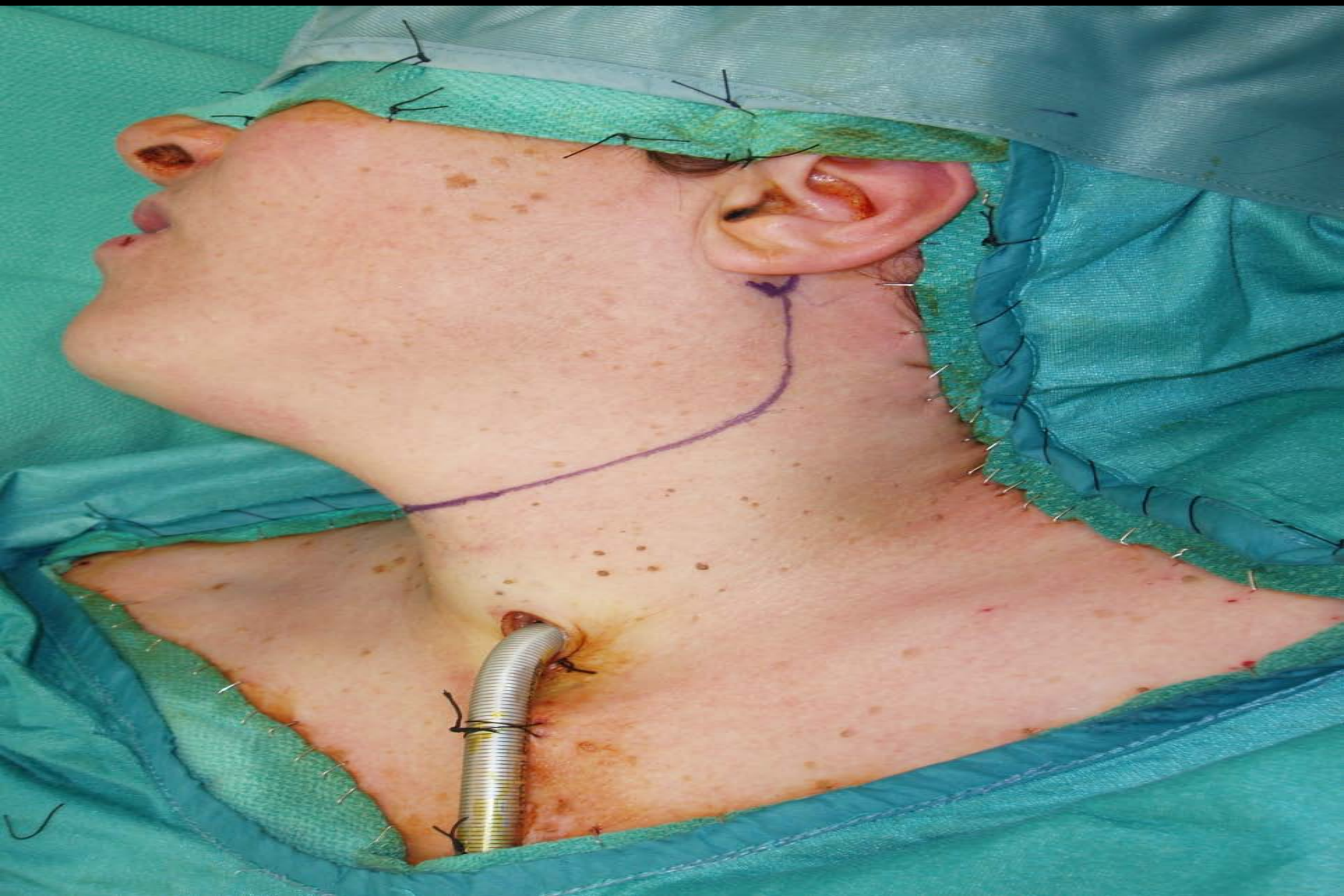

ase, random  
ATININE  
um  
ubin, Total  
aline Phosphatase  
umin  
a  
osphorus  
ECTROLYTES  
EATININE  
cium  
bumin  
(4/4)  
TT  
ROTHROMBIN TIME  
TT  
ROTHROMBIN TIME  
(2/3)  
COMPLETE BLOOD COUNT  
BC AND DIFFERENTIAL  
CBC AND DIFFERENTIAL  
ns (2/2)  
CHUA, NEIL - CCI  
JHA, NARESH - CCI  
Records (1/1)  
rocedures (0/1)  
(DI) (4/8)  
8 CHEST ERECT PA + LATERAL  
8 MOD BA SWALLOW W/WO S  
8 Chest to Include Upper Abdom  
8 Prep 30 Minutes - CCI  
8 Abdomen, complete, 8101-

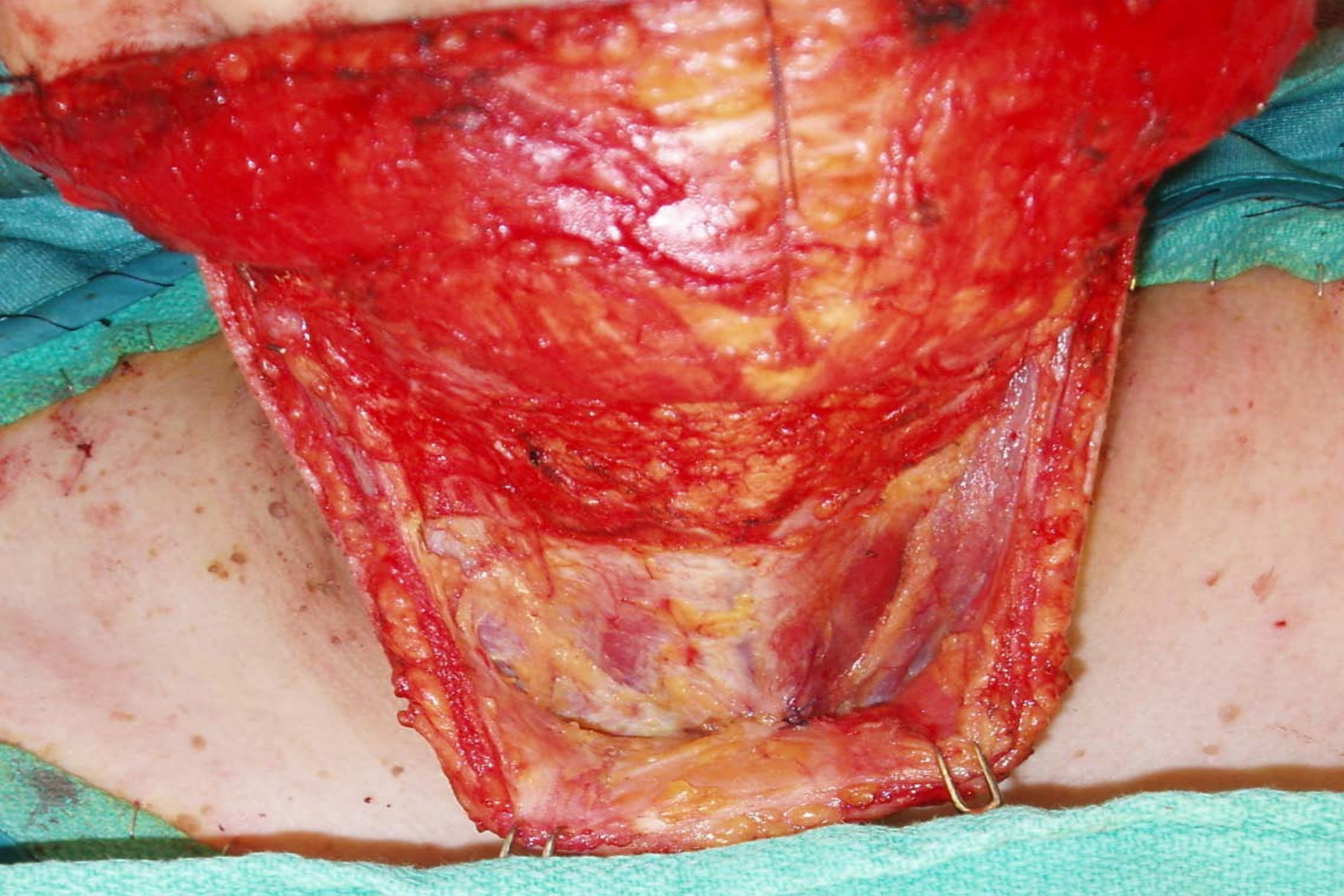
R  
1  
1  
1  
1

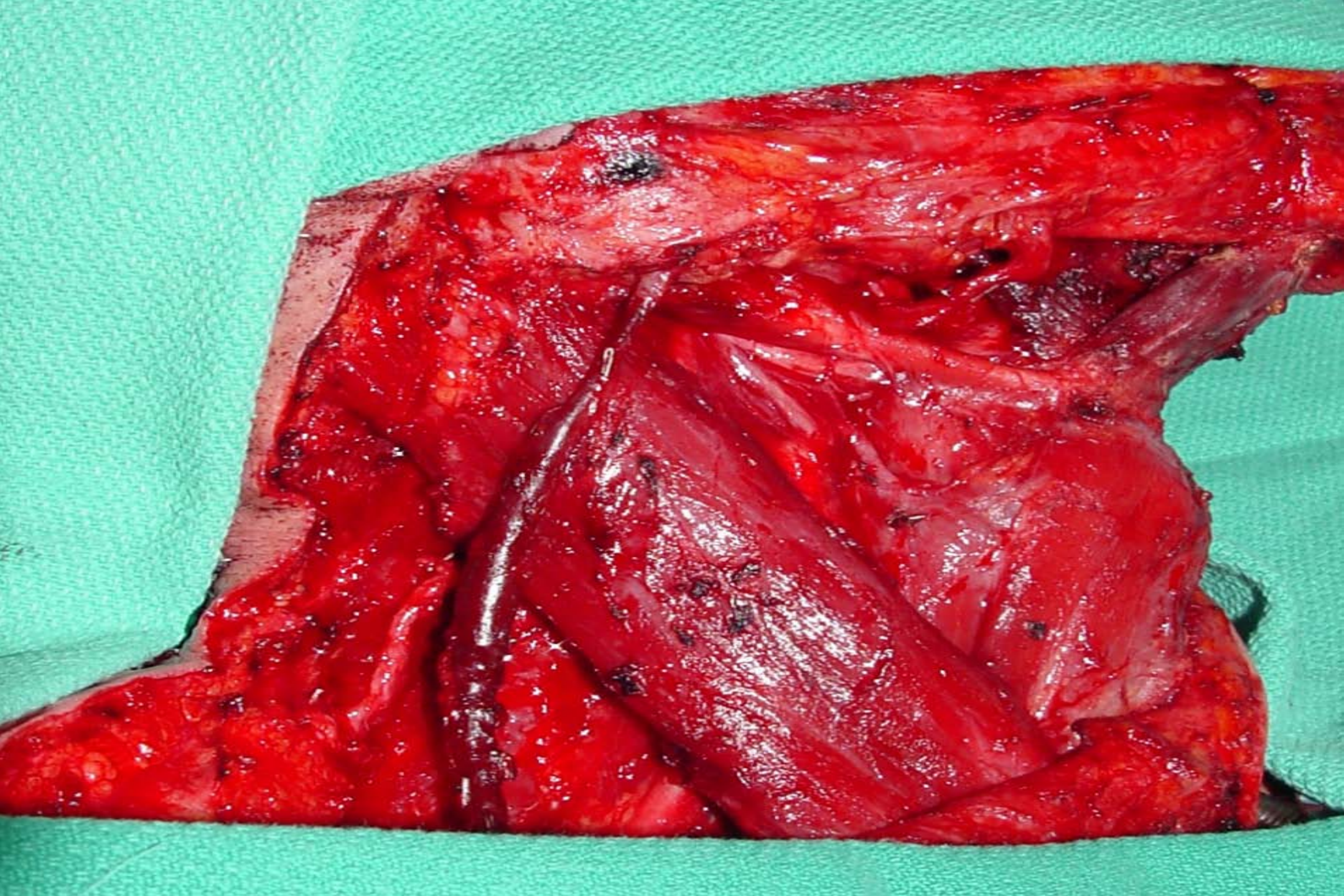


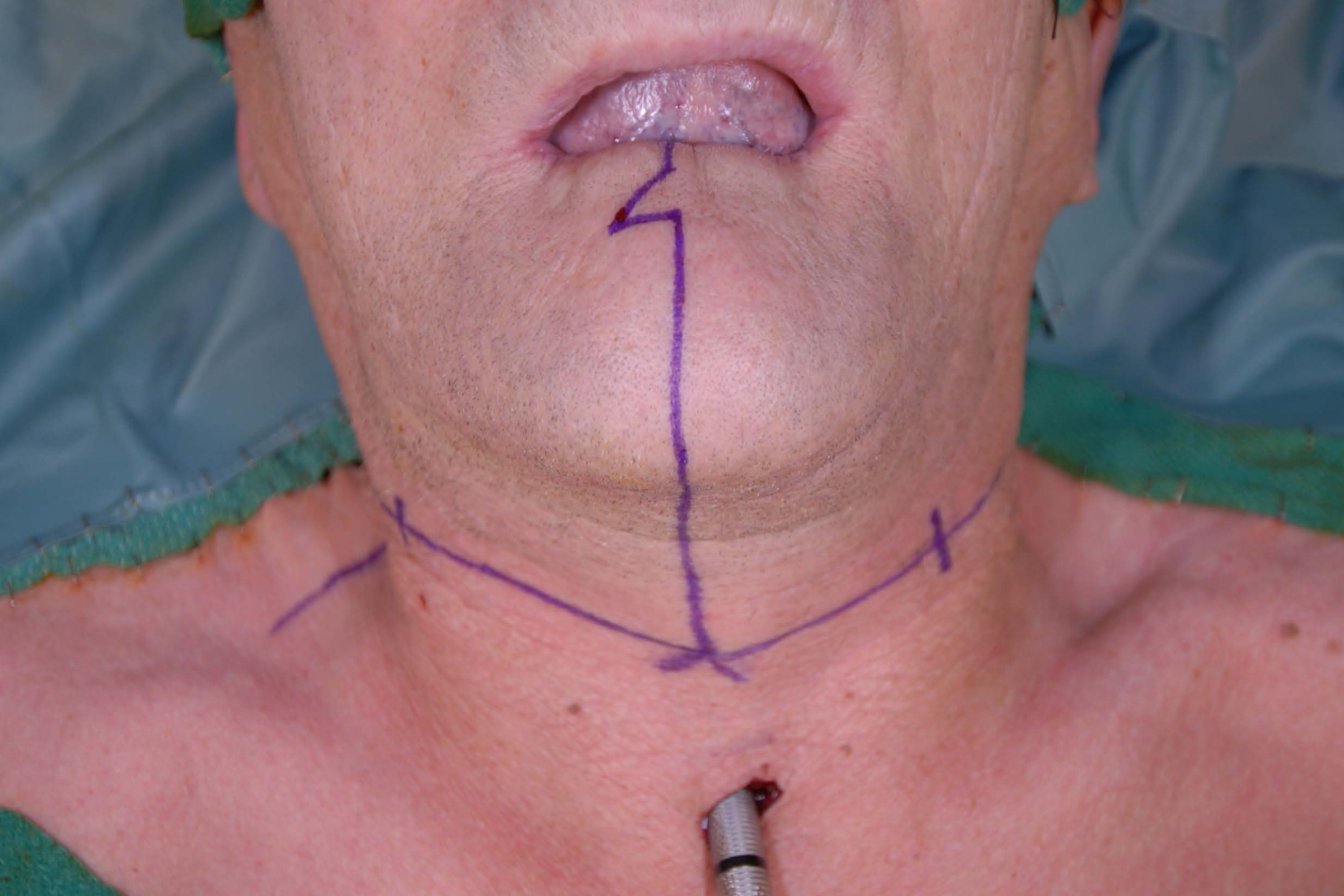
L  
1  
1  
1  
1

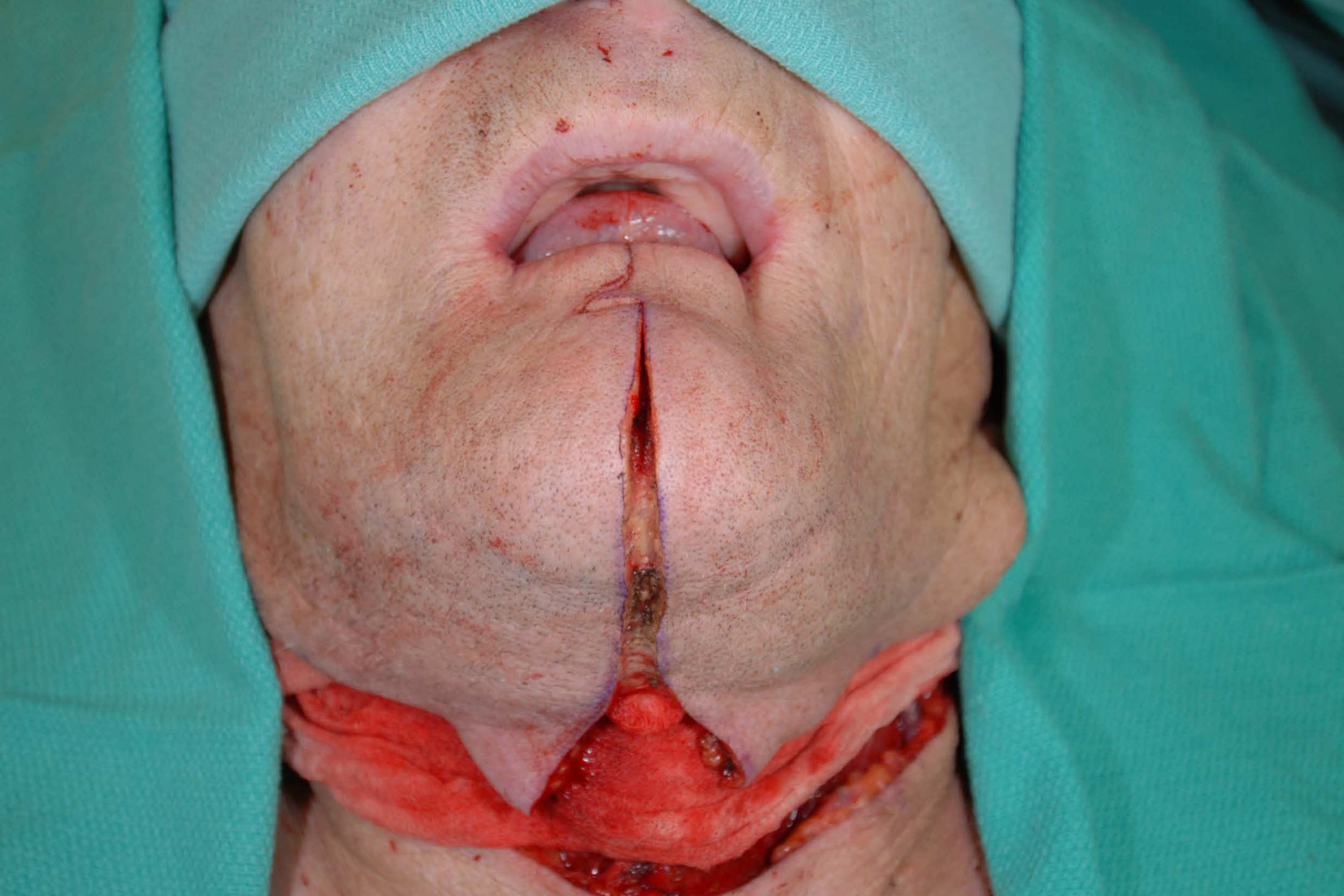


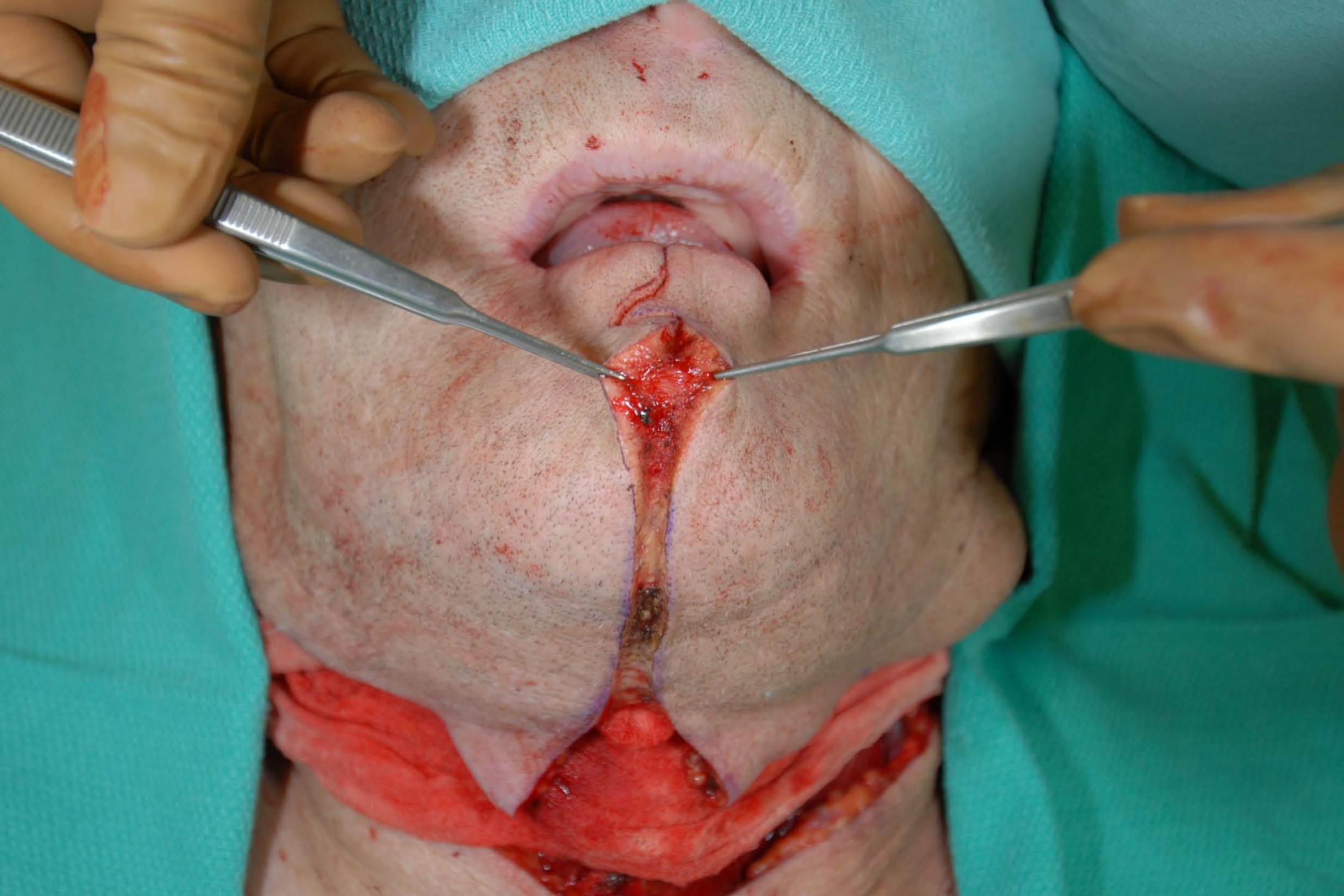
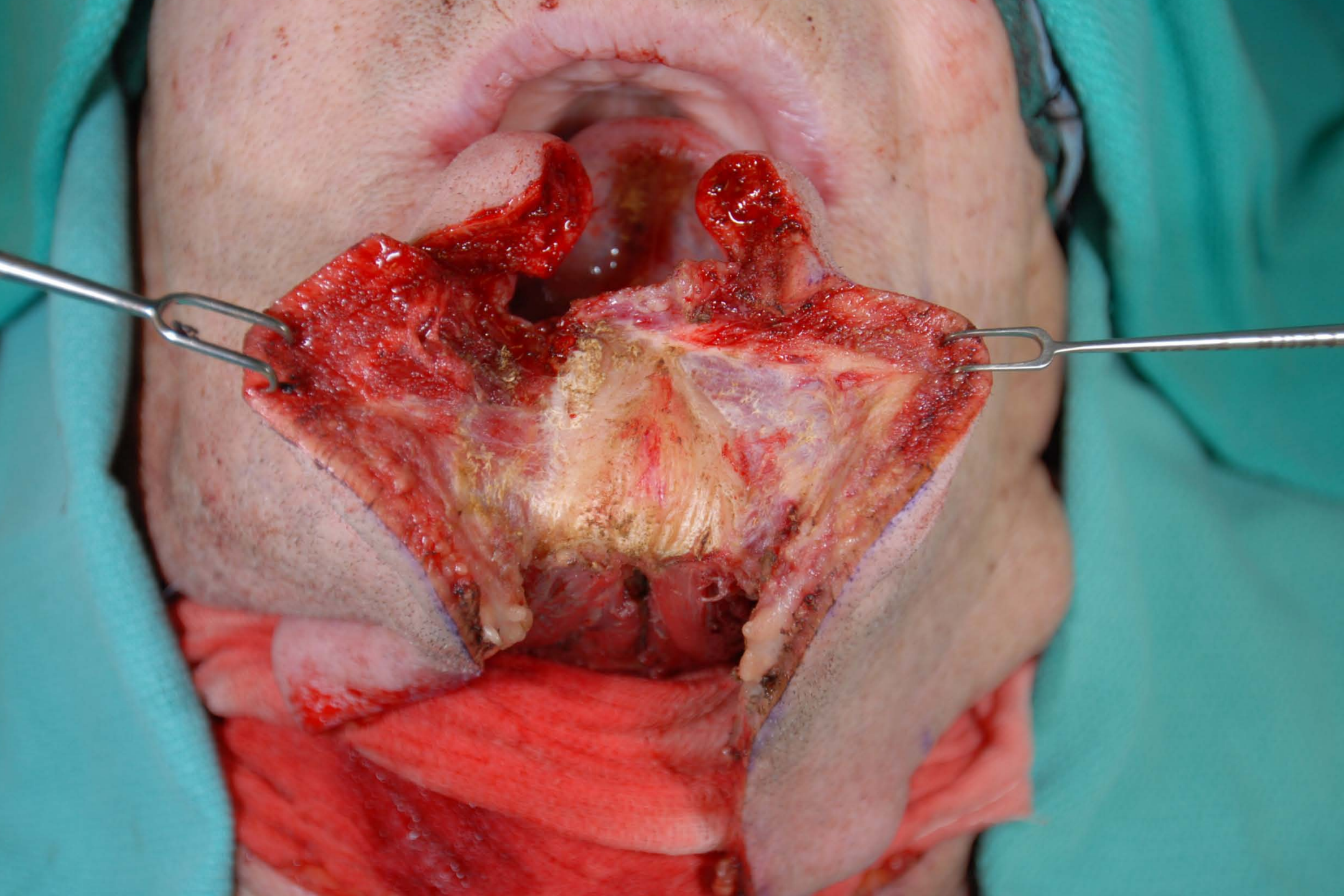


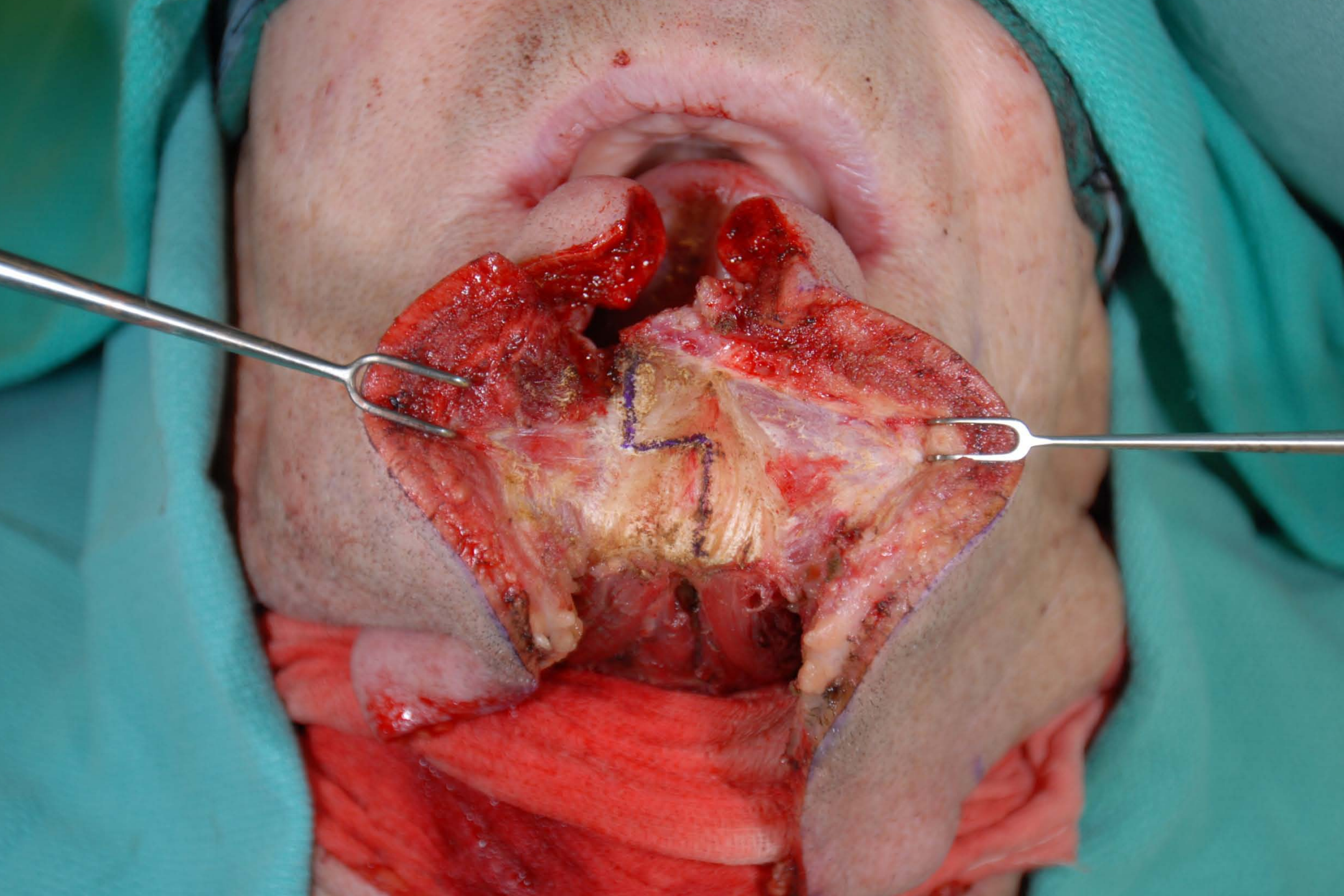


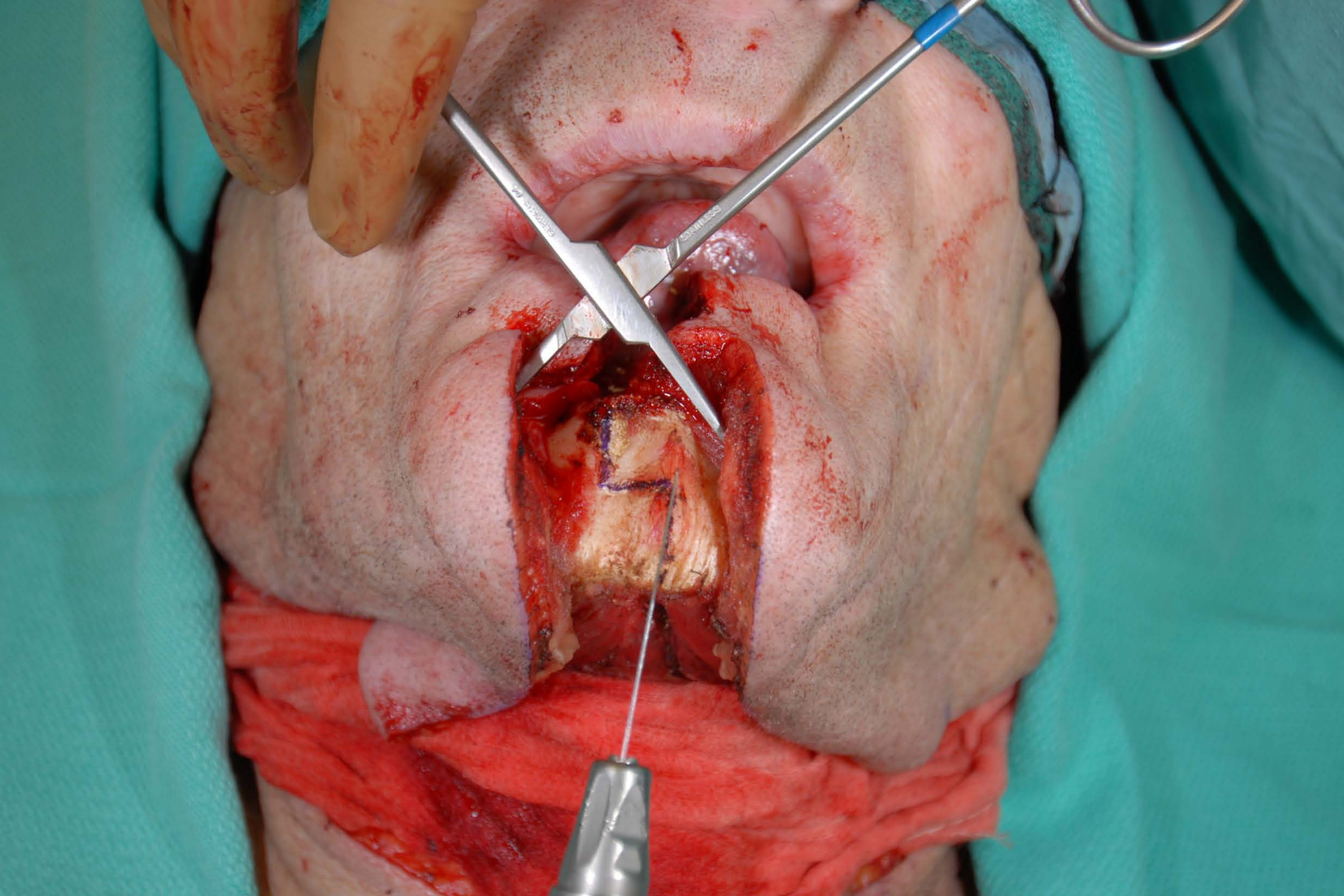






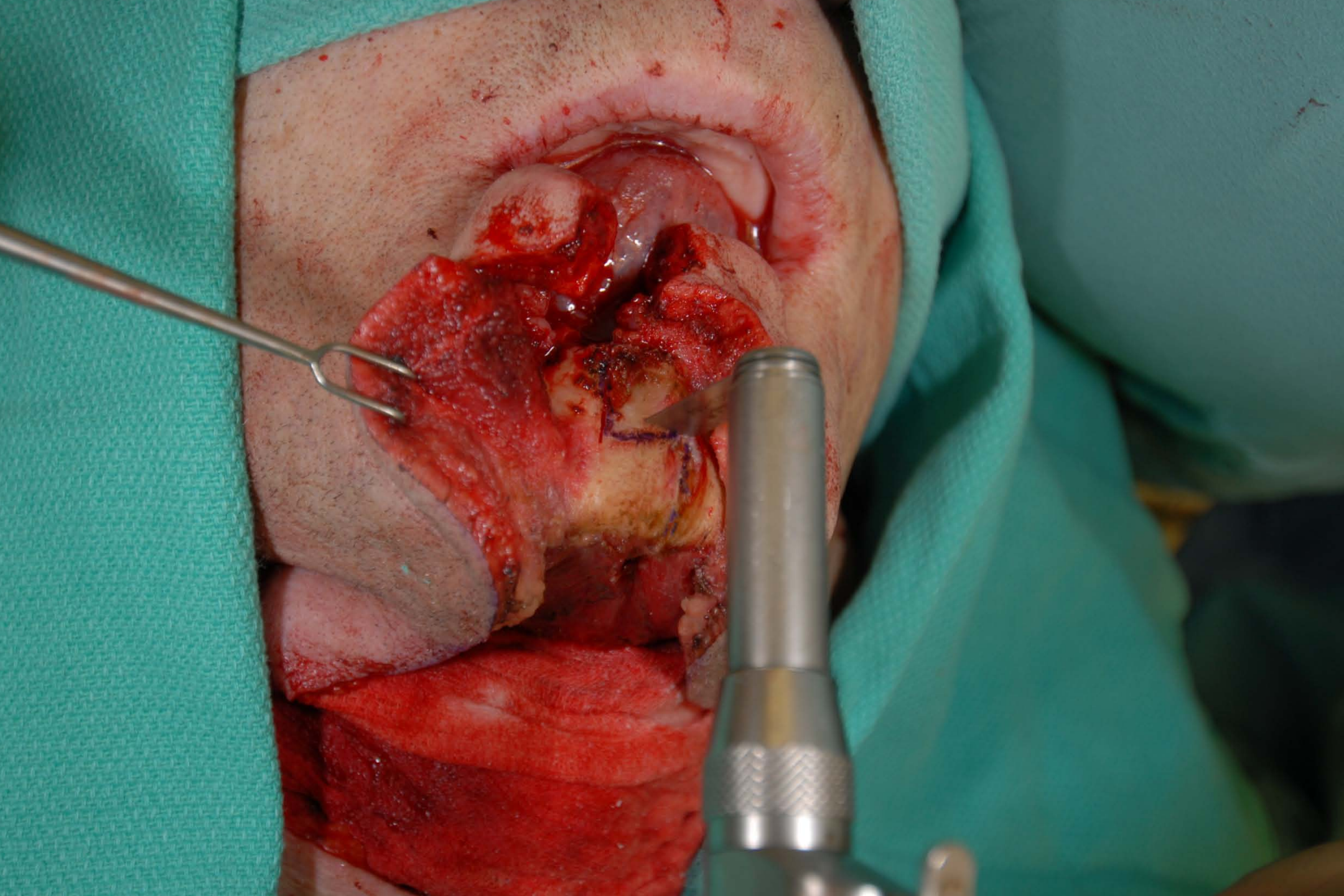

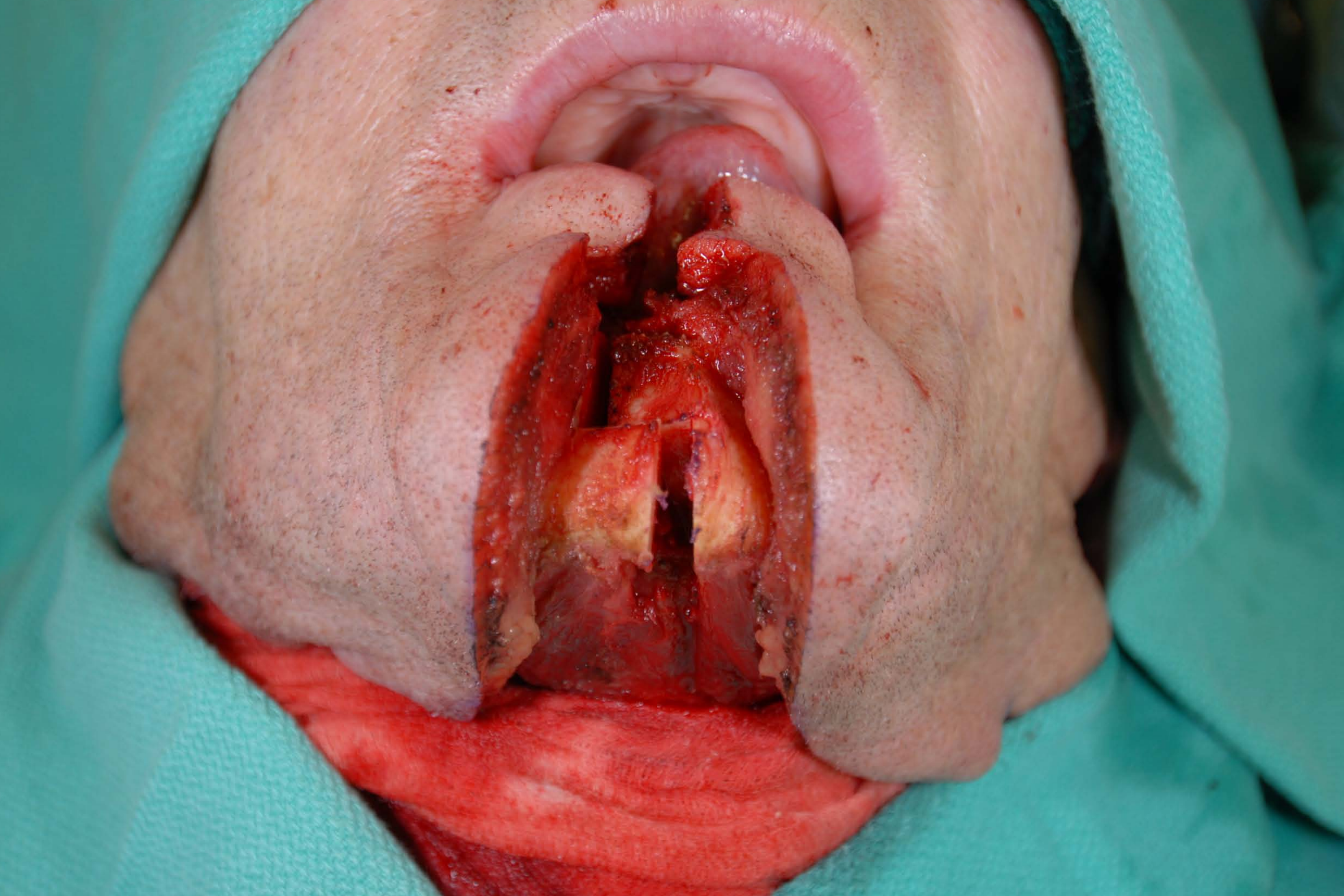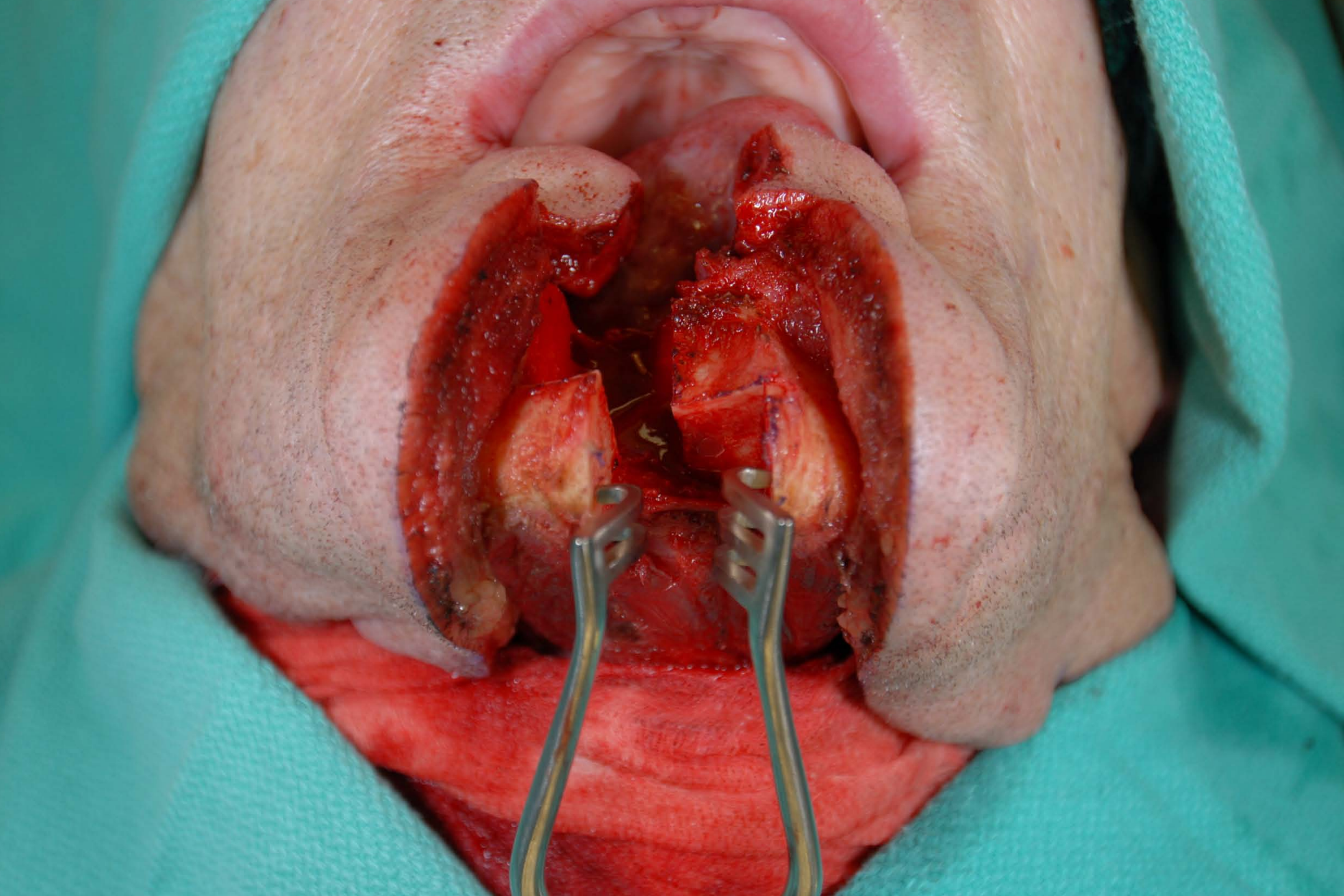


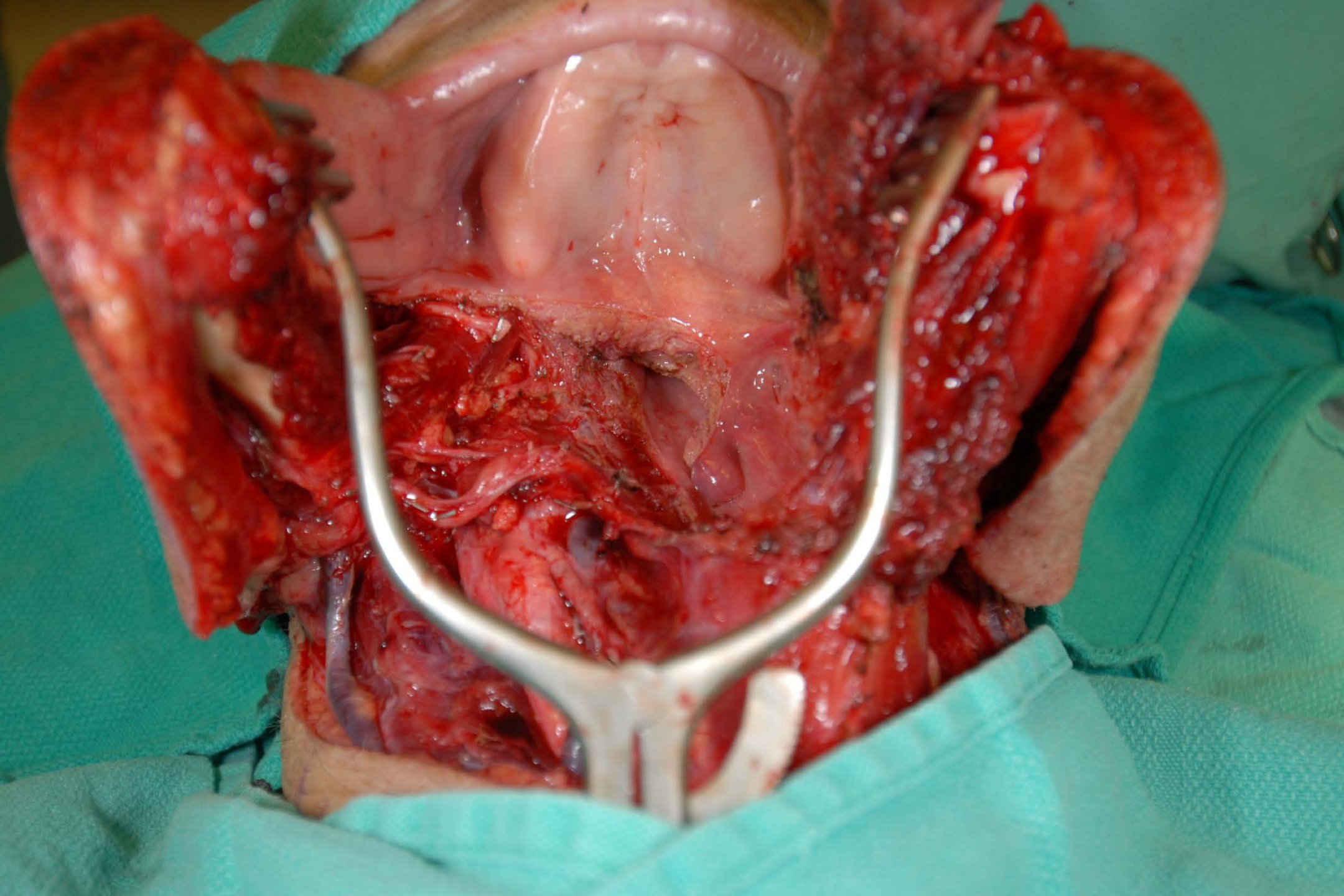






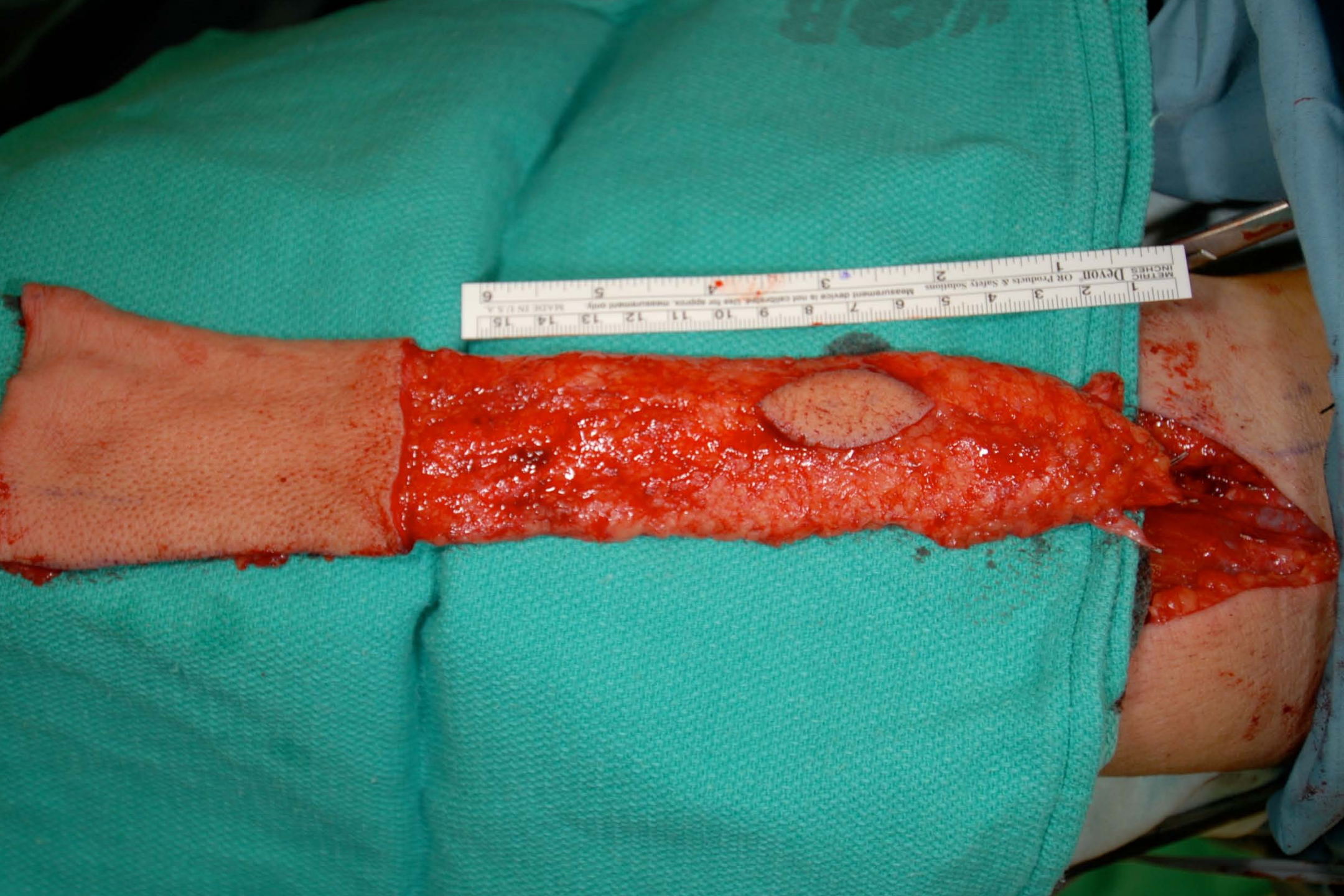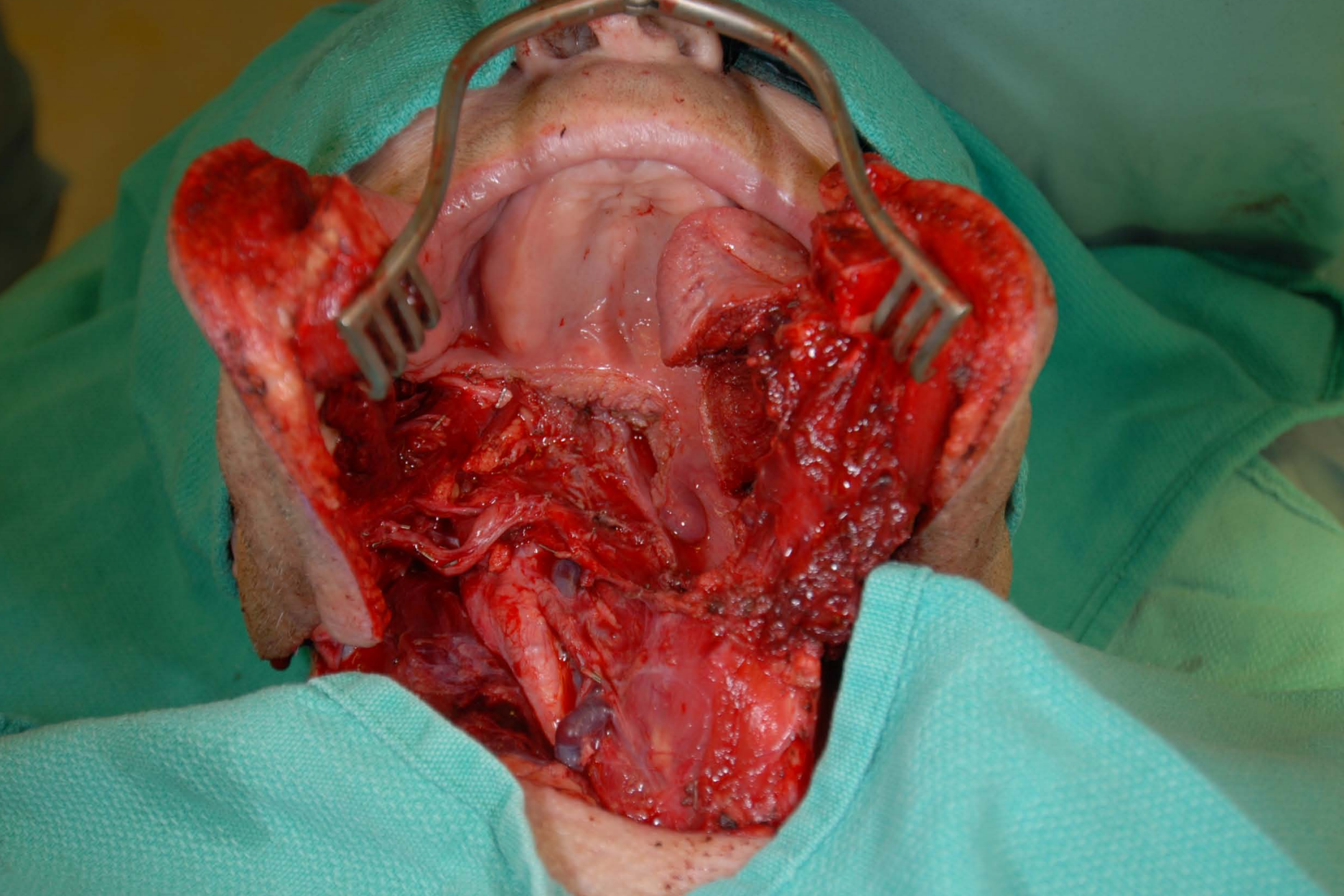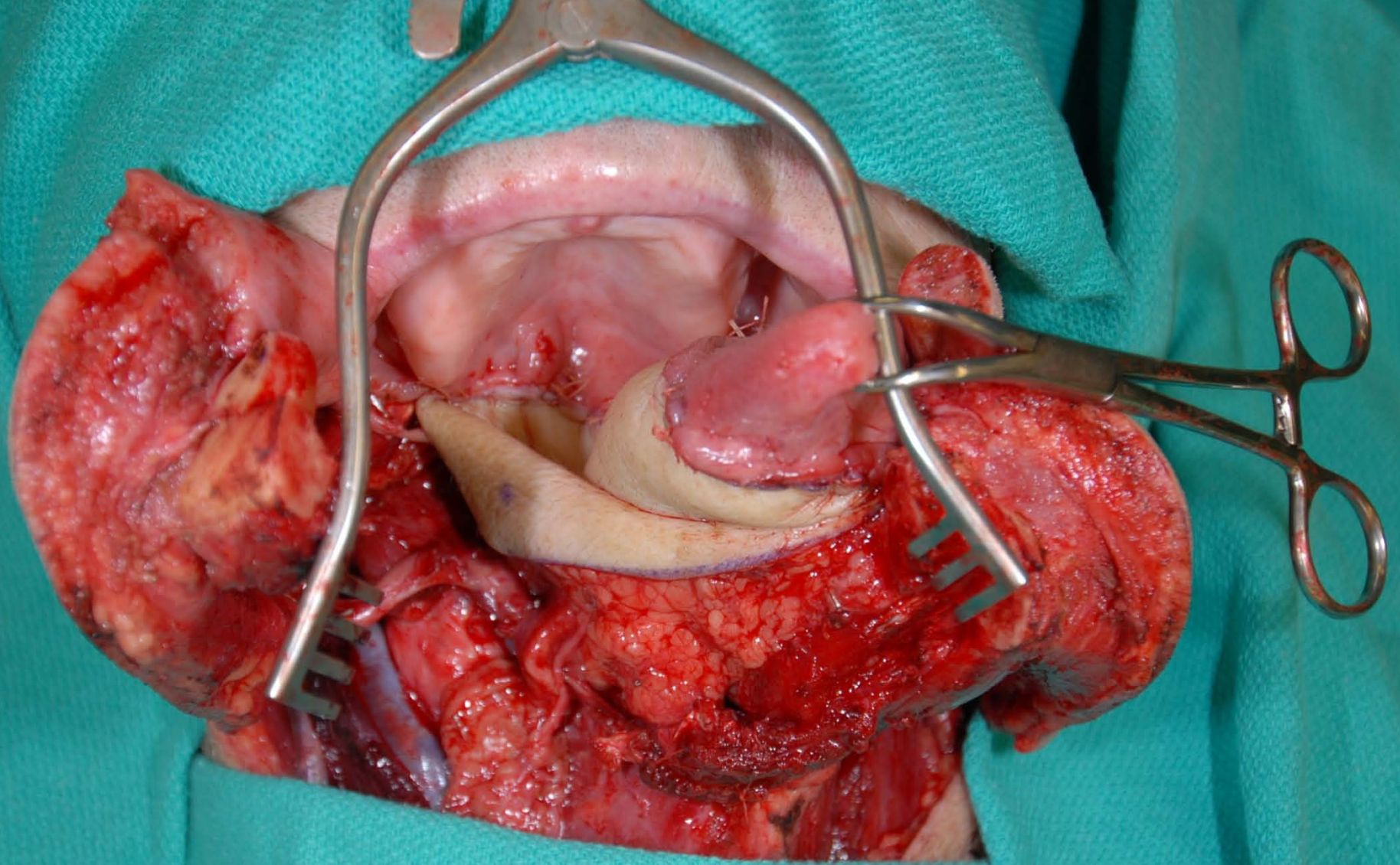








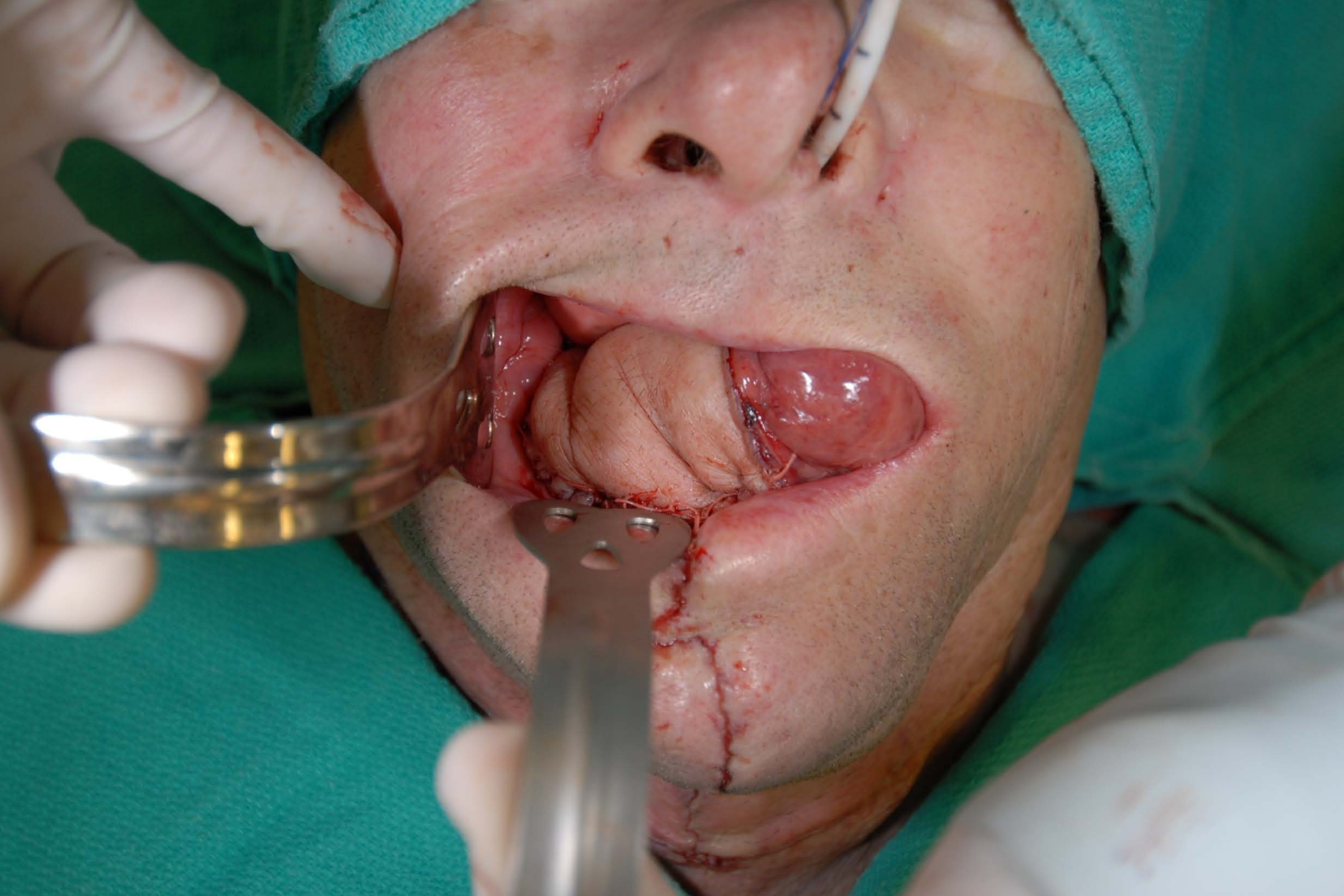




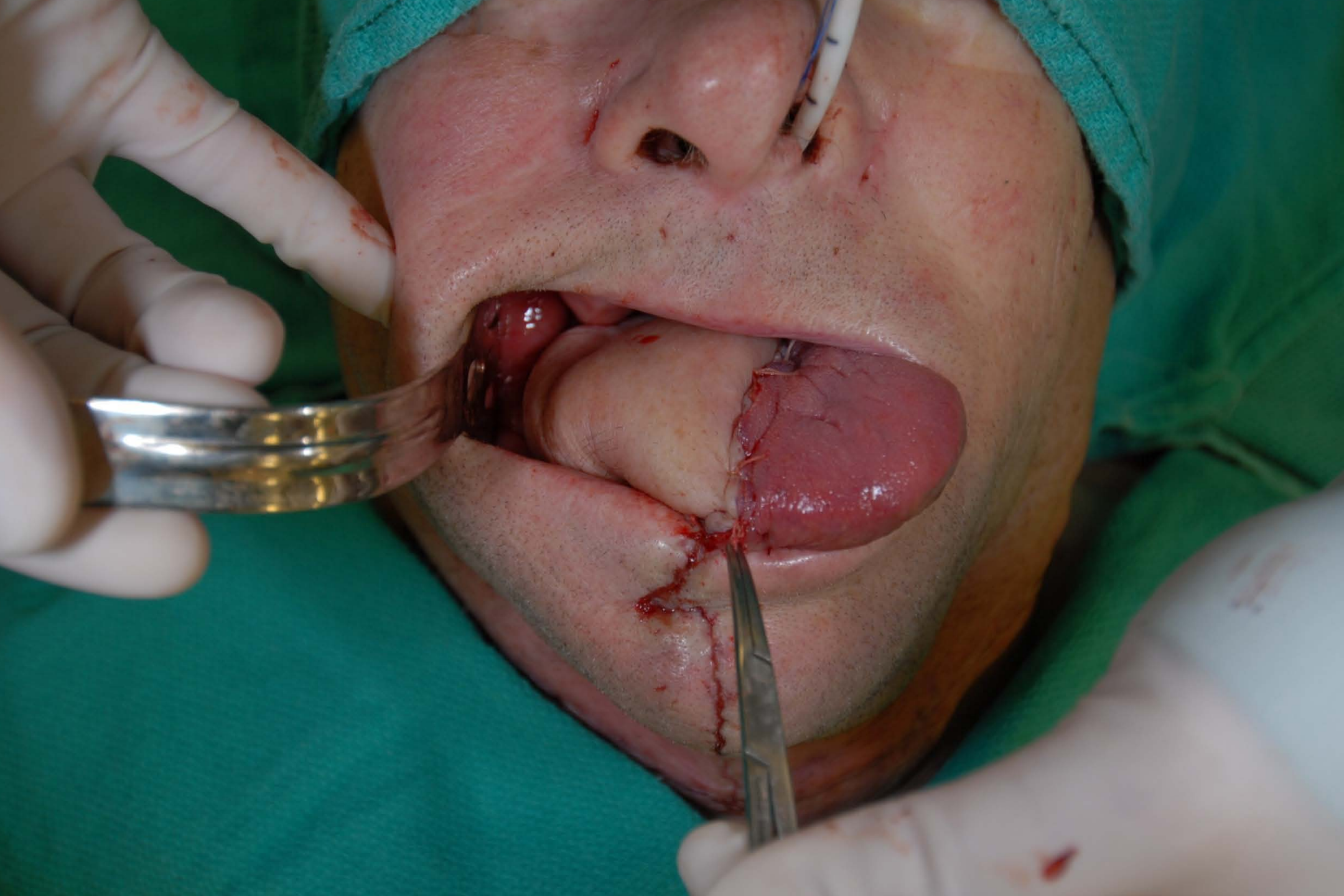


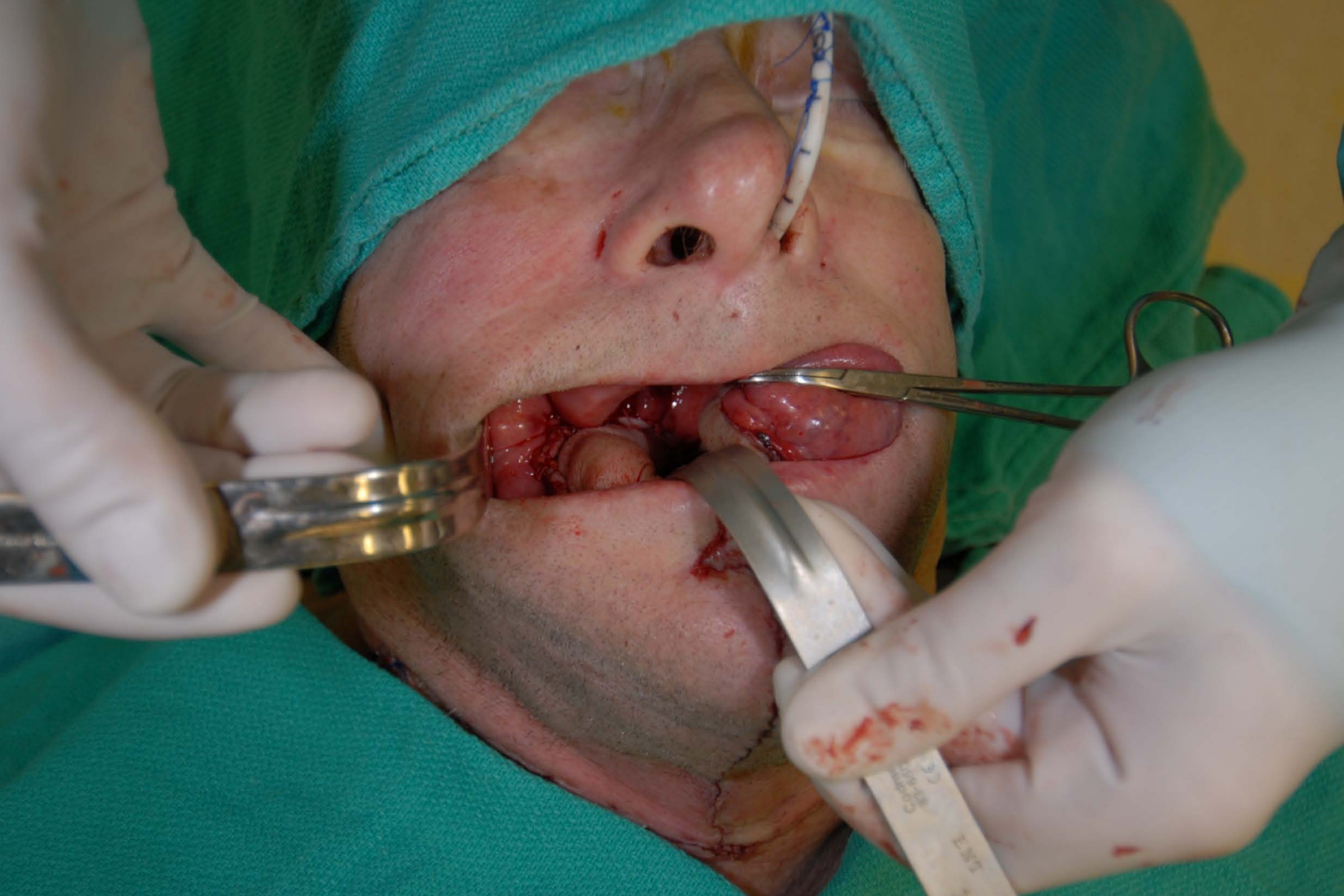





**Thank You**