

Neuro-ophthalmology Review

First Hour

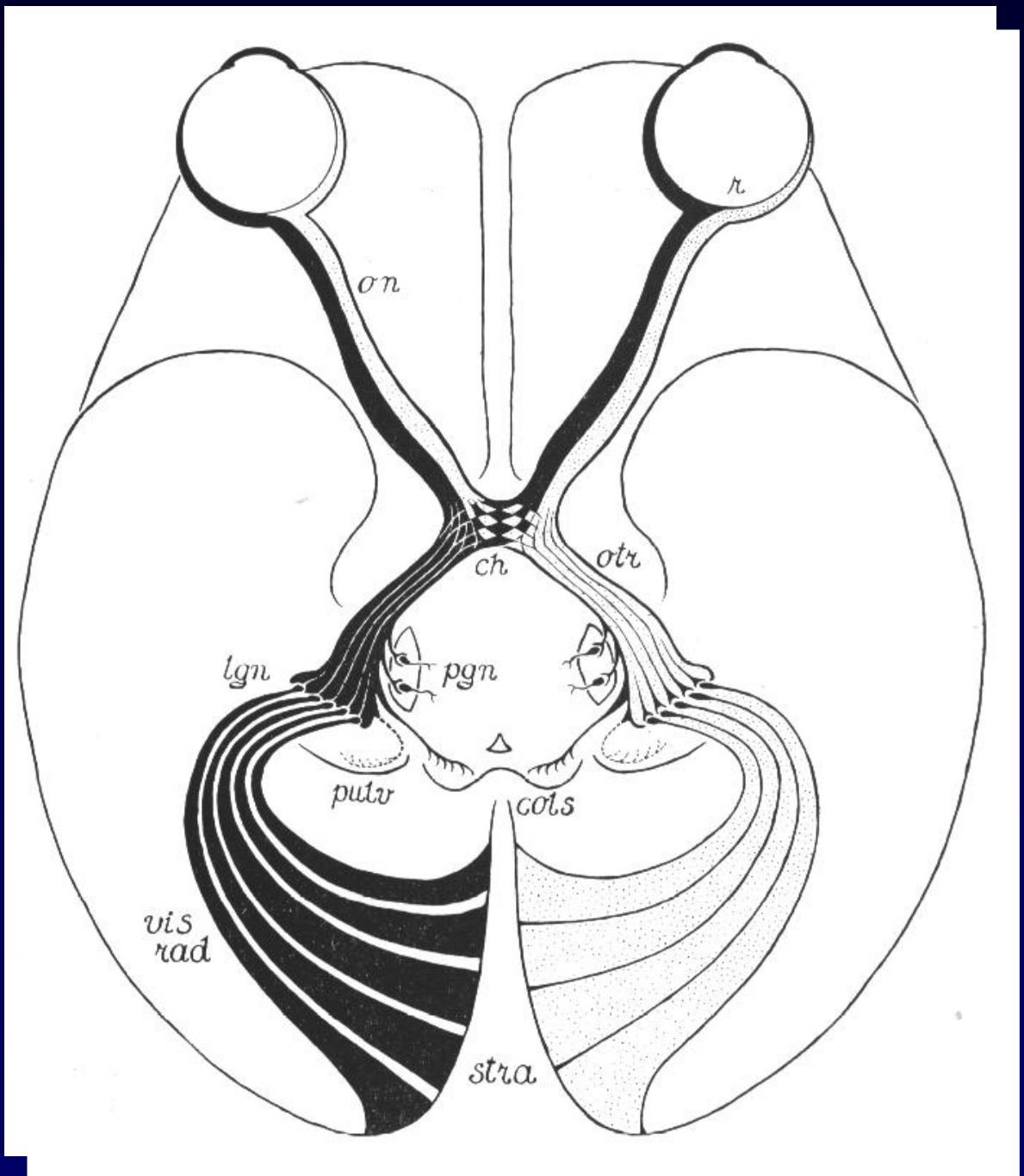
Thomas M. Bosley, MD
Professor of Ophthalmology
King Saud University

Neuro-ophthalmology

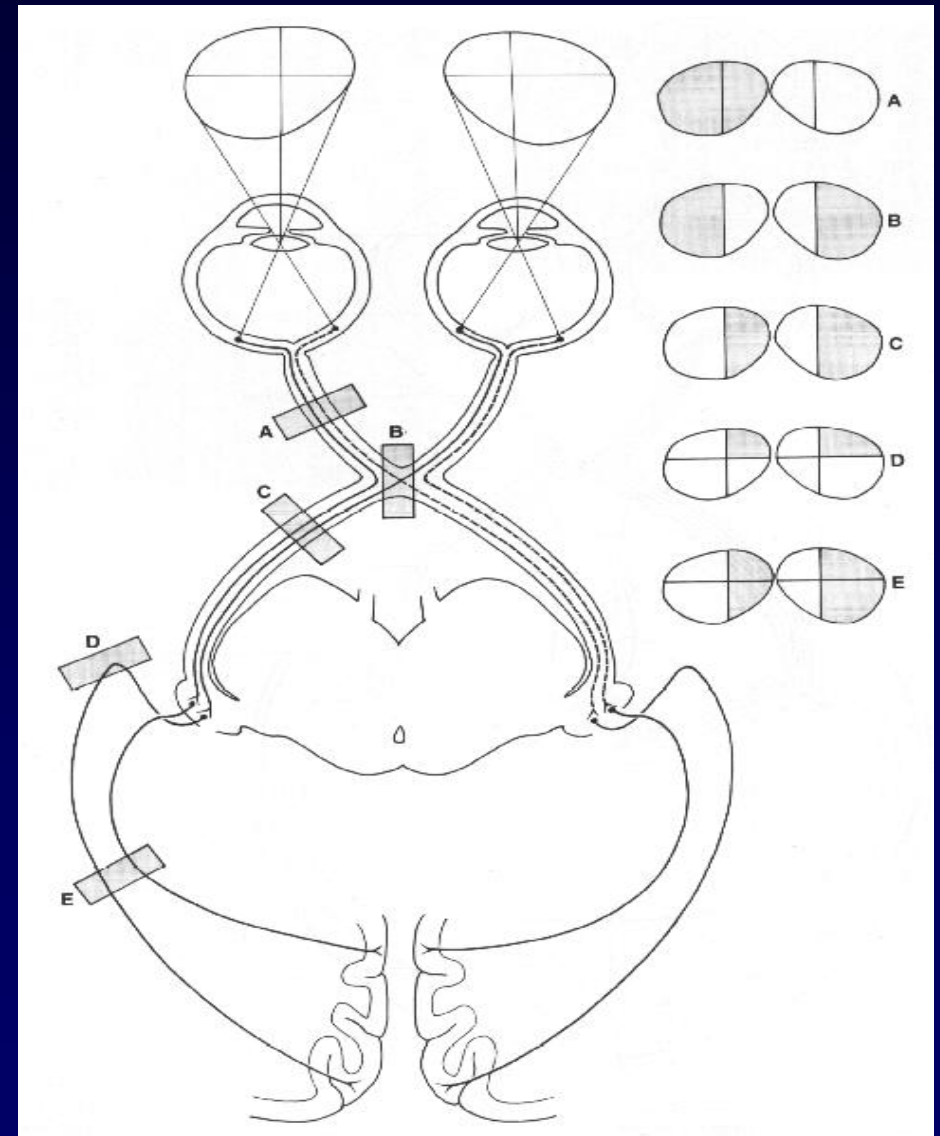
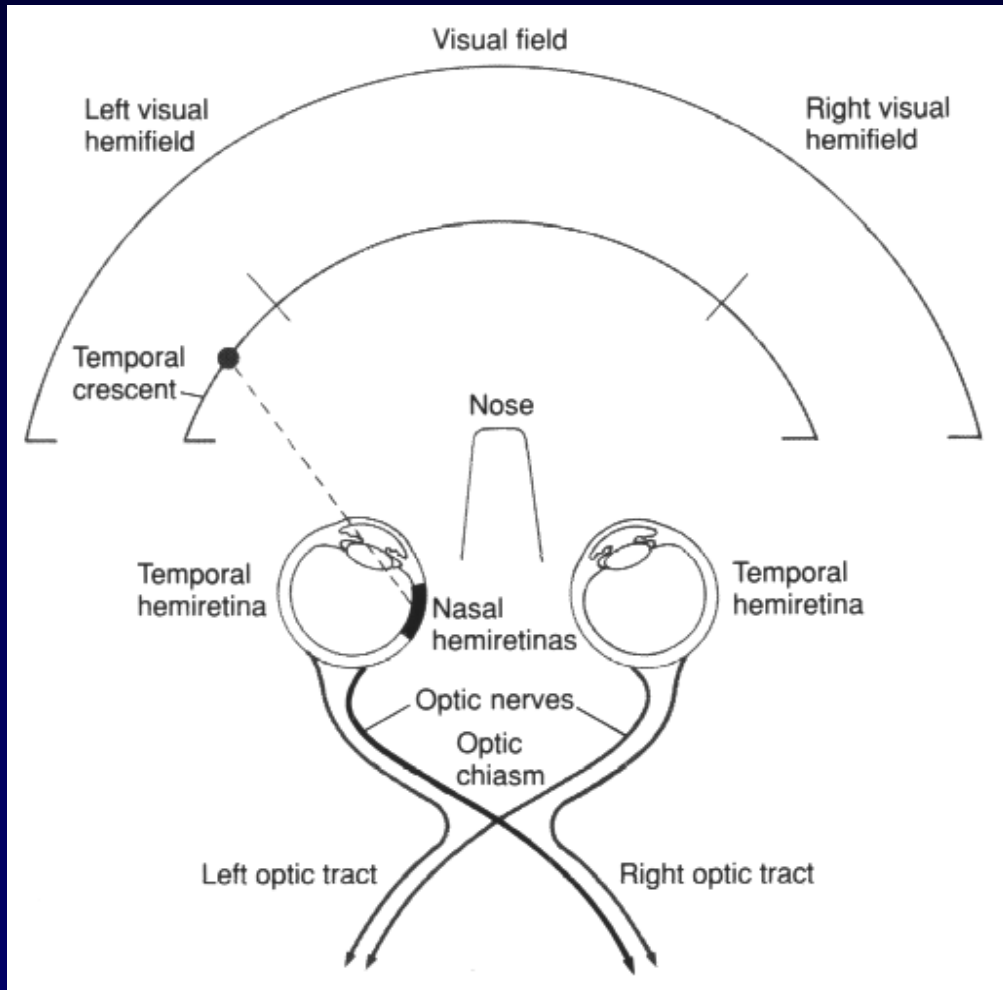
- Afferent
- Efferent
- Other
- Anatomy
- Examination
- Diagnoses
- Tests

Human Afferent Visual System

Polyak, THE VERTEBRATE
VISUAL SYSTEM, 1957



Afferent Anatomy



Afferent Visual System

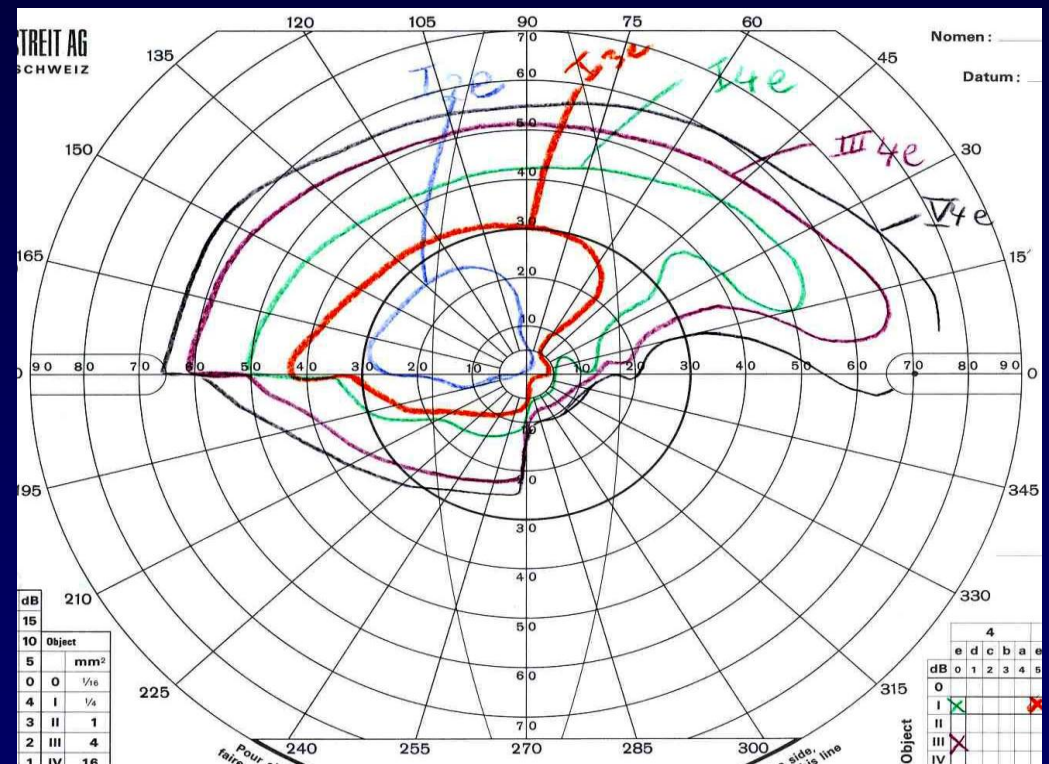
- Visual acuity
- Color vision
- Visual field
- Pupil examination
- Fundoscopy
- Anatomy
- Examination
- Diagnoses
- Tests

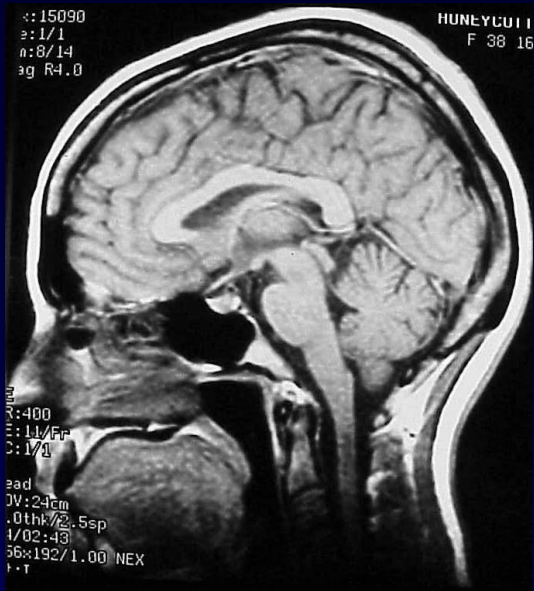Examination

- Visual acuity Distance
 - Color vision Ishihara
 - Visual field Near
 - Pupil examination Confrontation
 - Fundoscopy AOC
- Gitman
Gittmann
Direct ophthalmoscopy
Dumphy
Slit lamp and lens
Indirect ophthalmoscopy

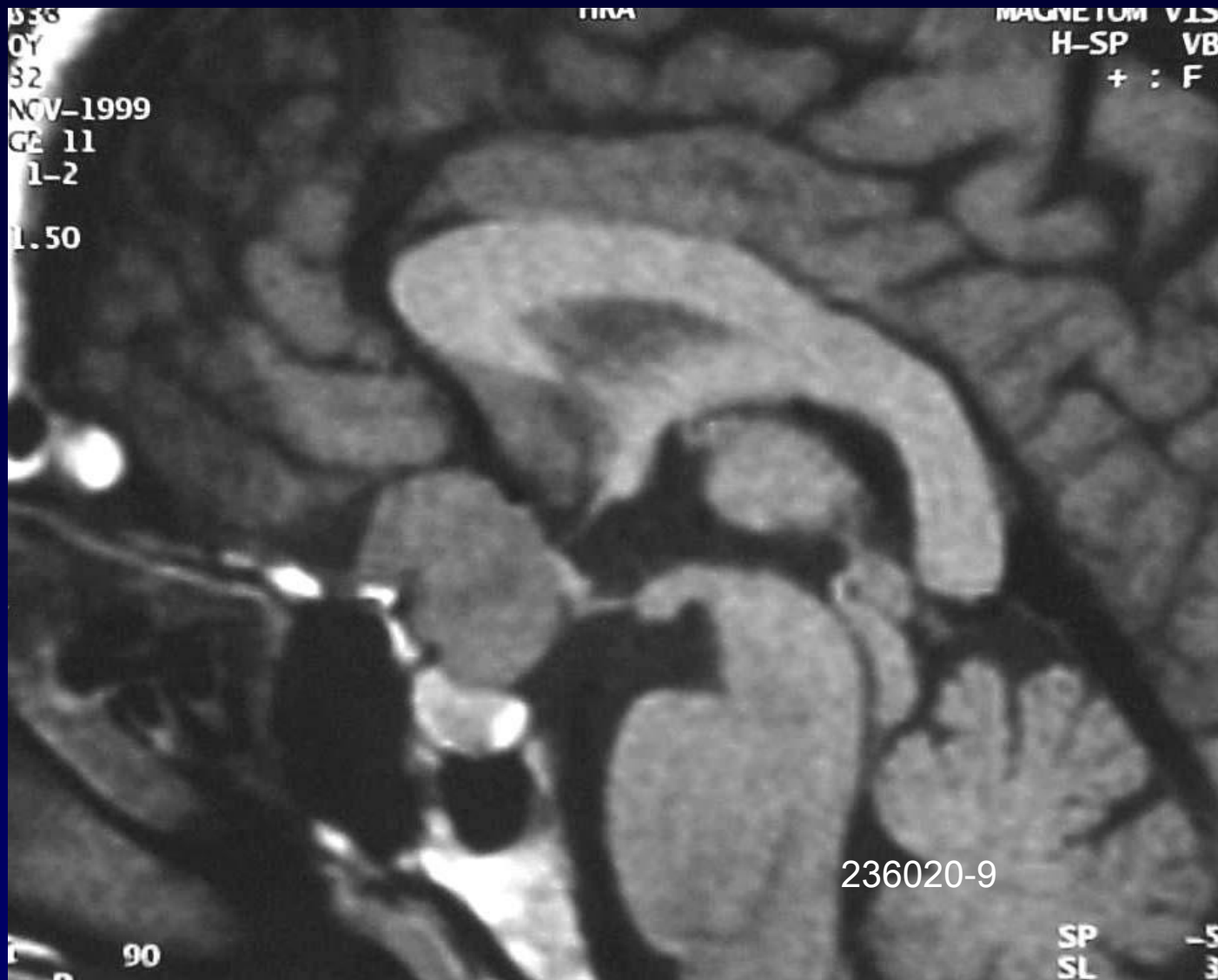35 yo woman

- Reported 3 months of gradual visual loss OU
- 7 months pregnant
- Rapid visual loss OU over 1 week before N-O evaluation
- VA at presentation OD 20/40 and OS NLP

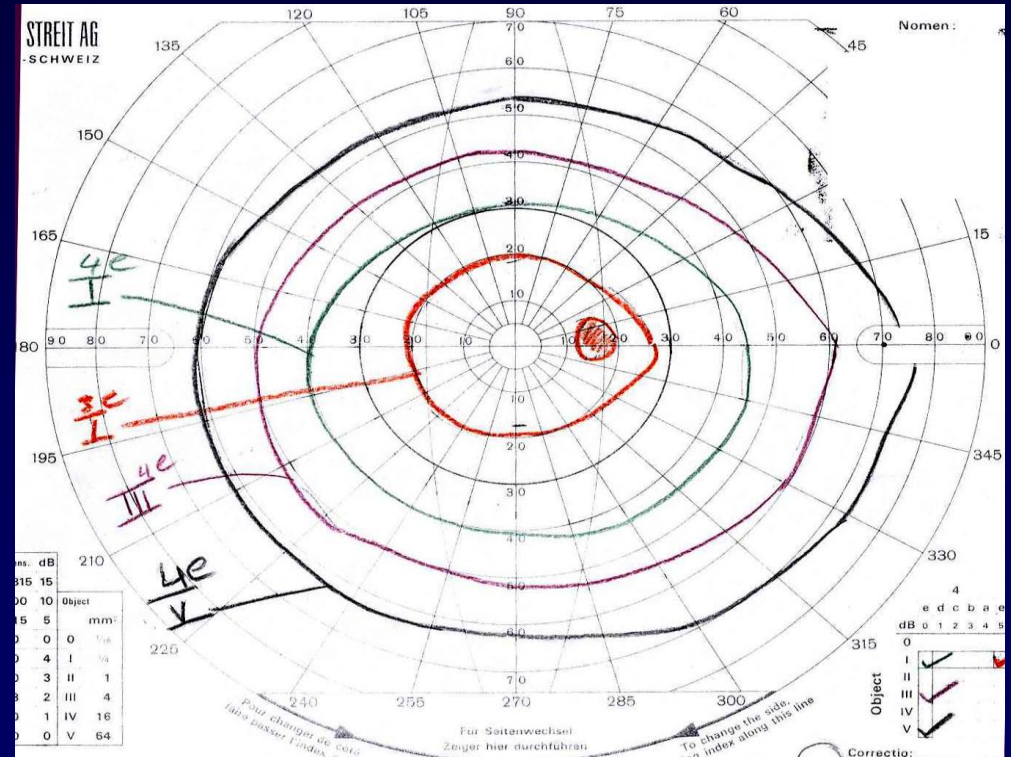
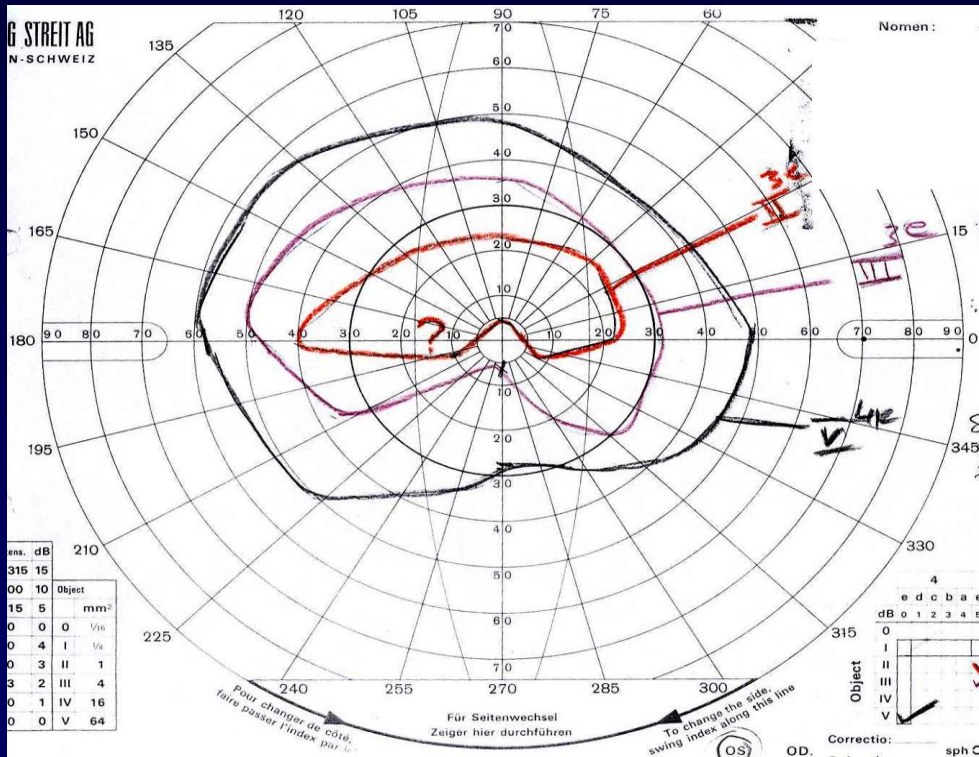




Normal sagittal scan

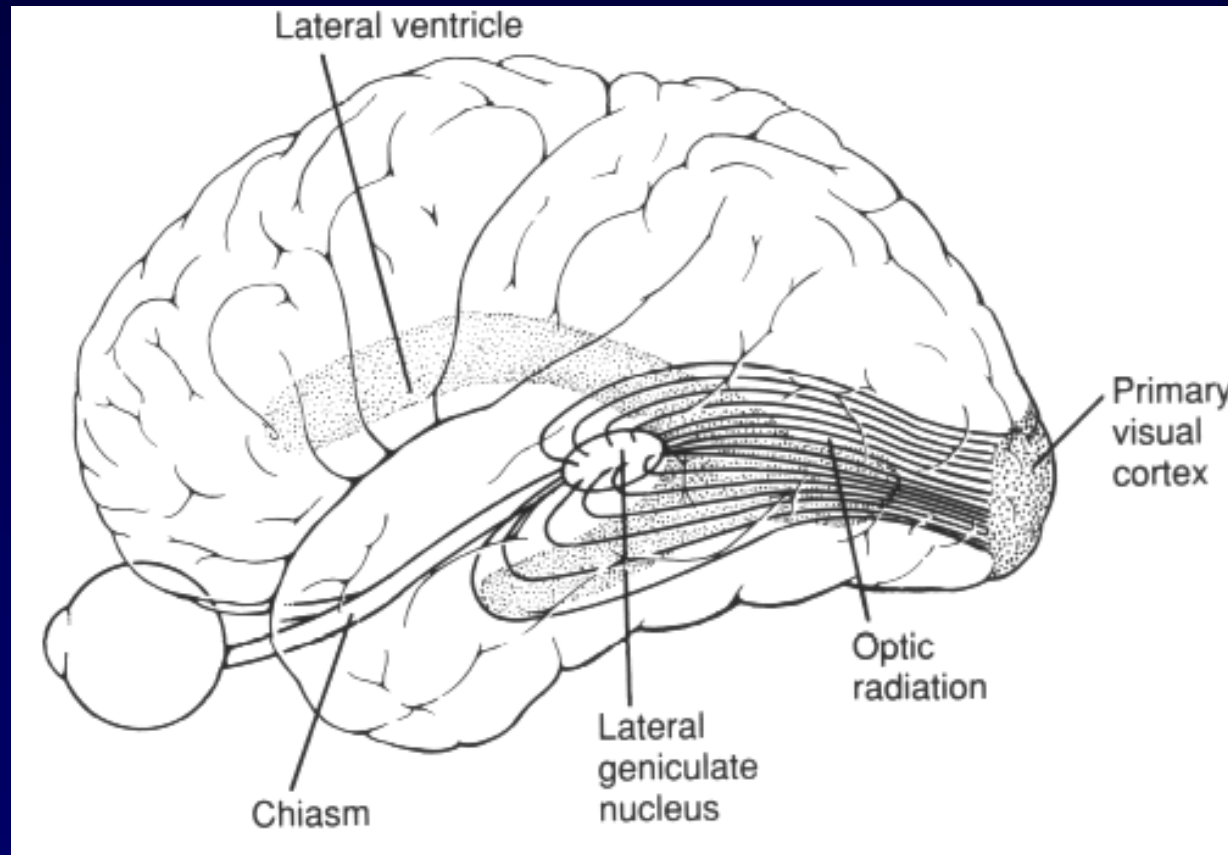


Post-op visual fields

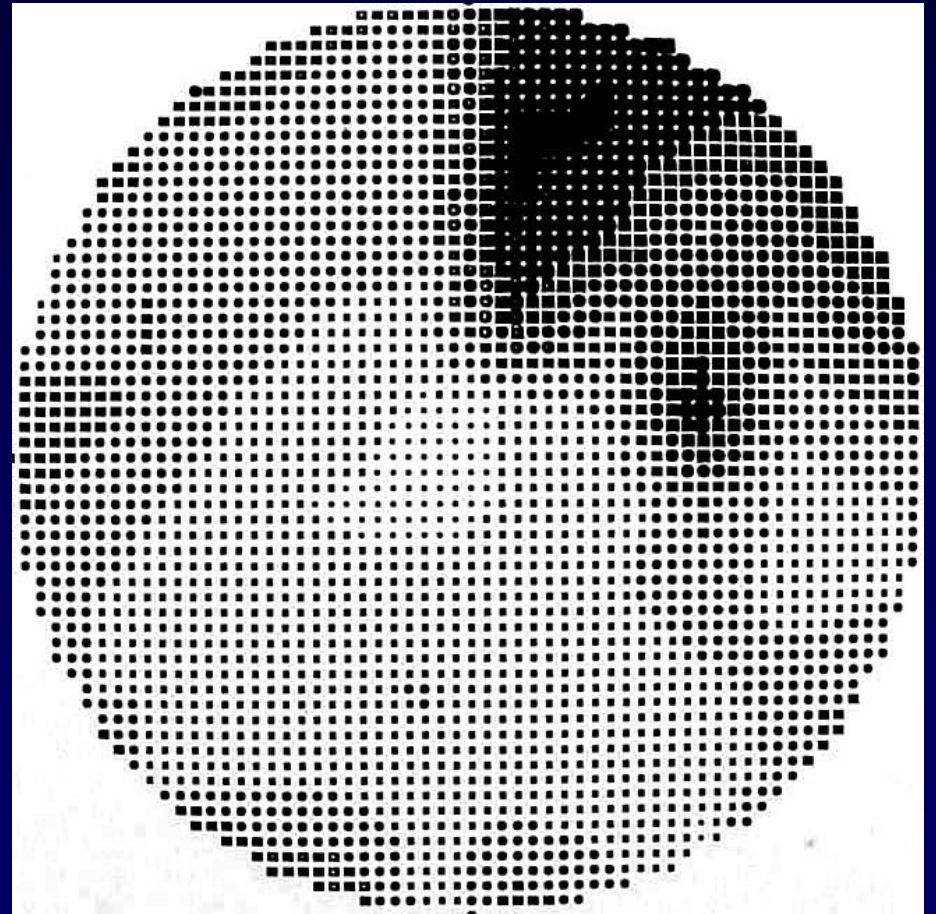



236020-9

Before Temporal Lobectomy



After temporal lobectomy



Afferent Visual System

- Compression
- Trauma
- Inflammation
- Ischemic
- Congenital and genetic problems
- Anatomy
- Examination
- Diagnoses
- Tests

Afferent Diagnoses

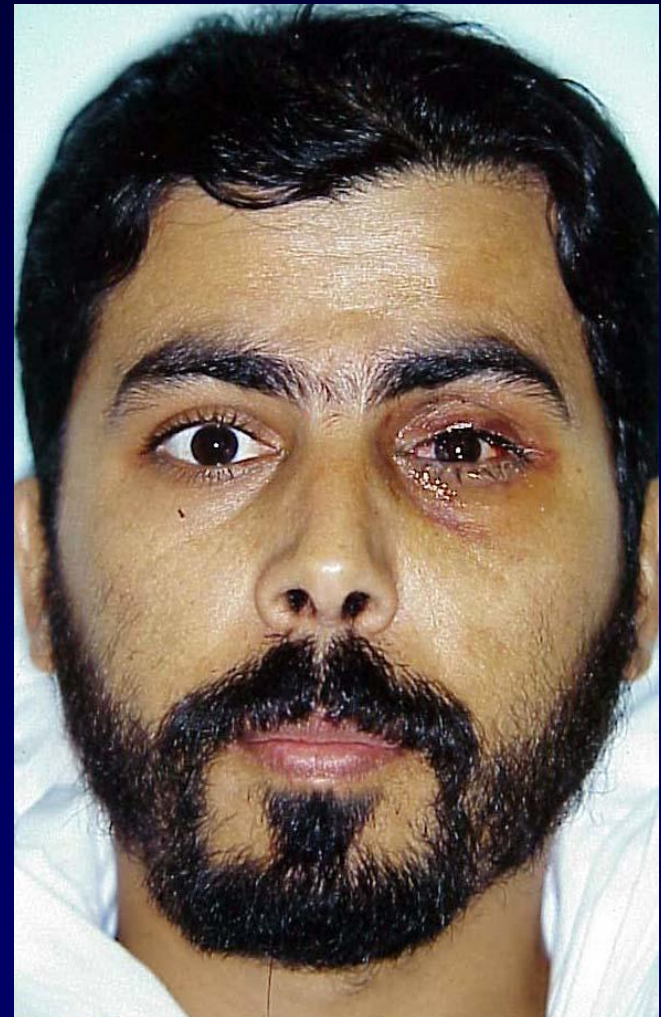
- Compression
 - Intraorbital ON
- Trauma
 - Intracranial ON
- Inflammation
 - Optic chiasm
- Ischemic
 - Optic tract
- Congenital and genetic problems
 - Posterior afferent system

Afferent Diagnoses

- Compression
- Trauma
 - Globe
- Inflammation
 - Intraorbital ON
- Ischemic
 - Optic canal
- Congenital and genetic problems
 - Optic chiasm
 - Occipital lobe

25 yo man

- Firecracker exploded near left eye
- NLP OS

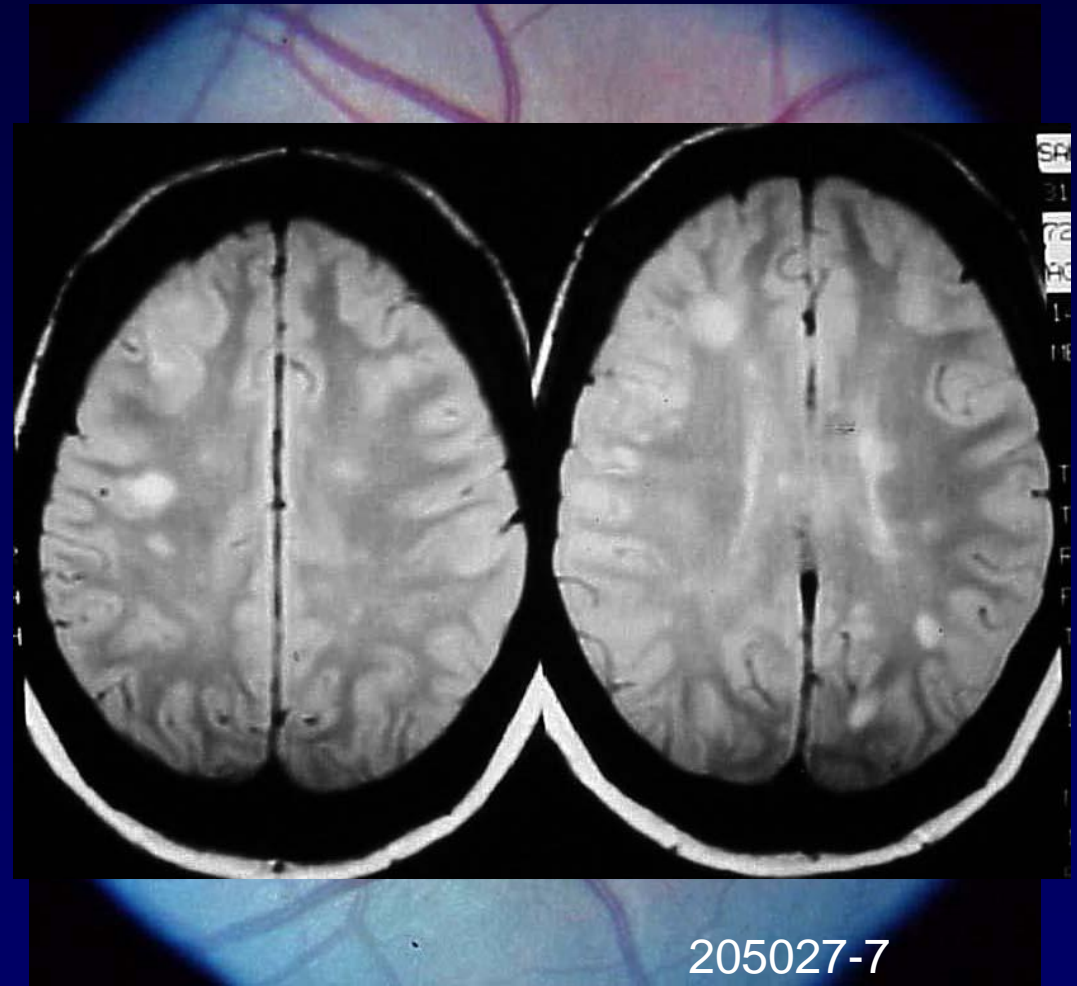


Afferent Diagnoses

- Compression
- Trauma
- Inflammation
 - Optic neuritis
 - Orbital pseudotumor
 - Other
- Ischemia
- Congenital and Genetic problems

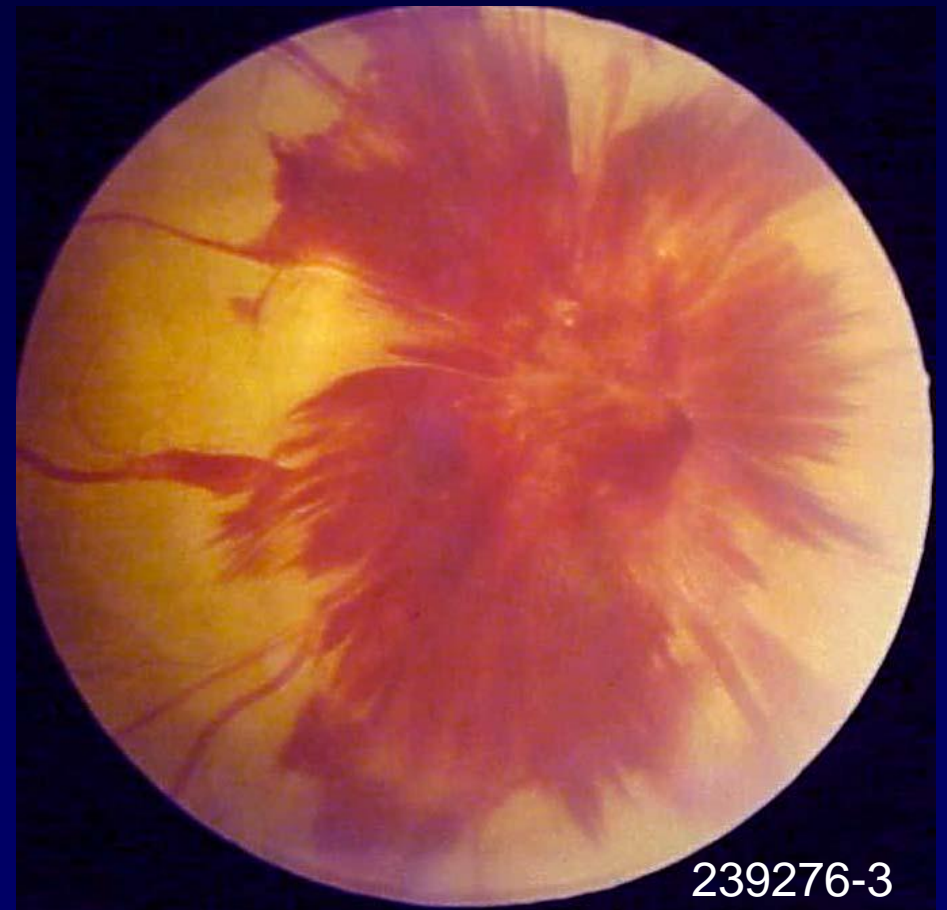
27 yo woman

- Developed blurred vision OD and mild right periorbital pain
- VA 20/50
- MRI abnormal
- Diagnosis multiple sclerosis



28 yo woman

- Developed modest left periorbital pain 3 weeks ago
- Some blurring of vision OS
- B-scan showed posterior scleritis



239276-3

Afferent Diagnoses

- Compression
- Trauma
- Inflammation
- Ischemia
- Congenital and genetic problems

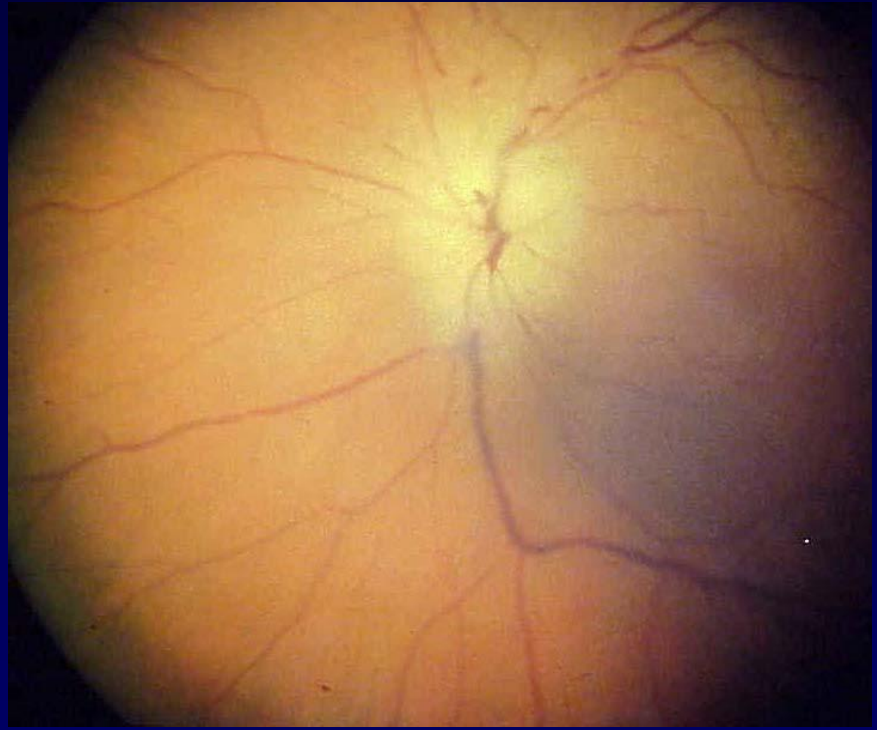
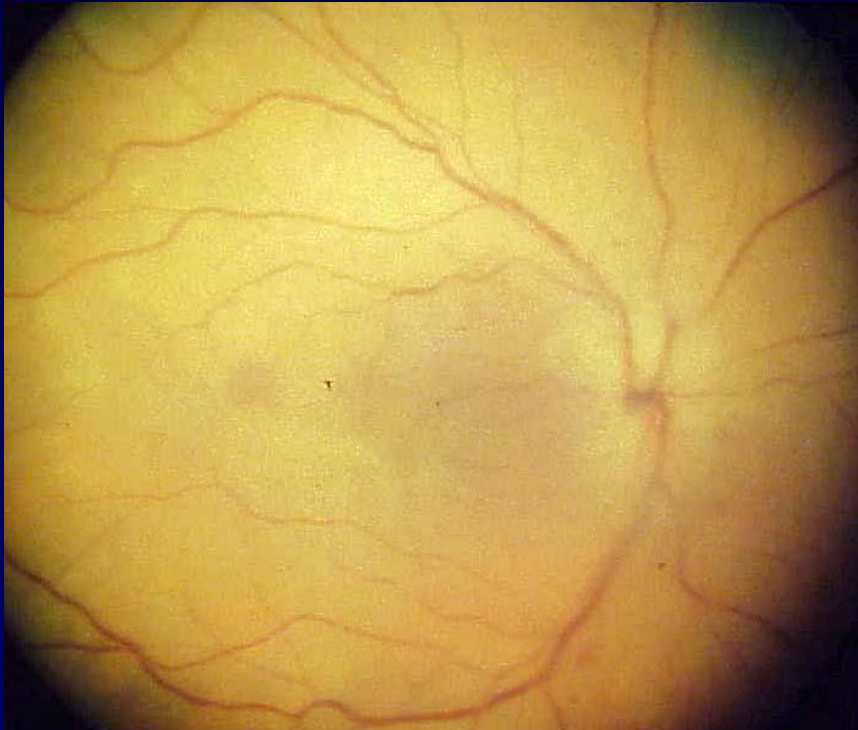Non-arteritic ischemic optic neuropathy

Central retinal artery occlusion

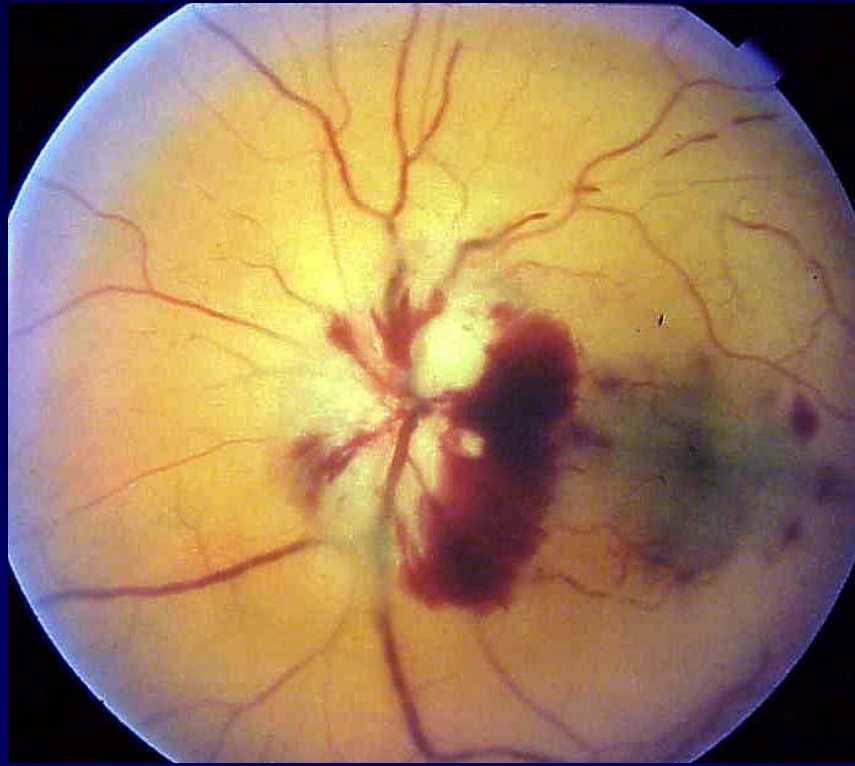
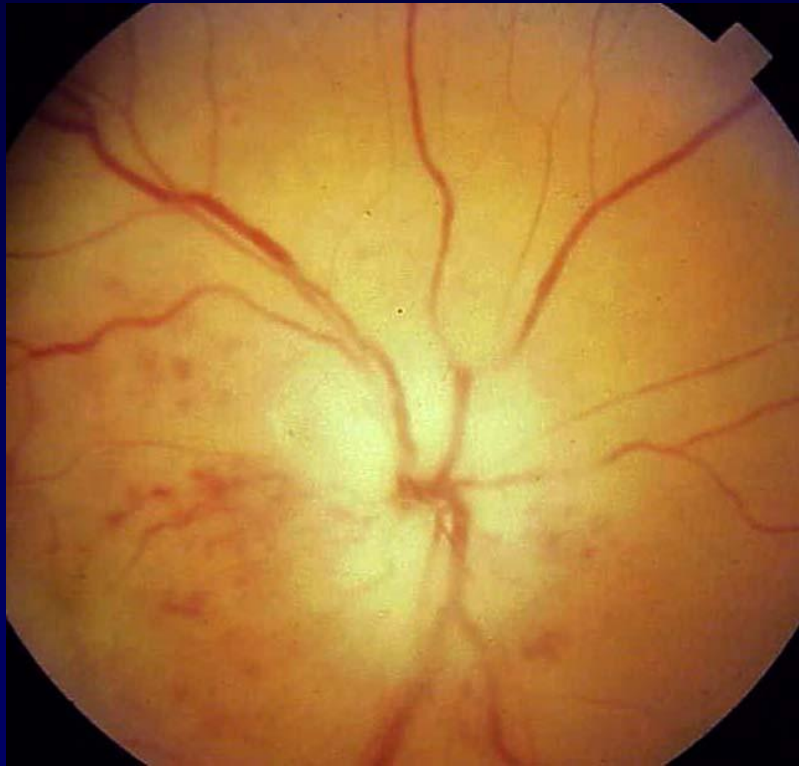
Other retinal emboli

Giant cell arteritis with ION

Giant Cell Arteritis, Day 2



Giant Cell Arteritis, Day 4



Afferent Diagnoses

- Compression
- Trauma
- Inflammation
- Ischemia
- Congenital and genetic problems

Congenital retinal dystrophies

Optic nerve hypoplasia

Leber hereditary optic neuropathy

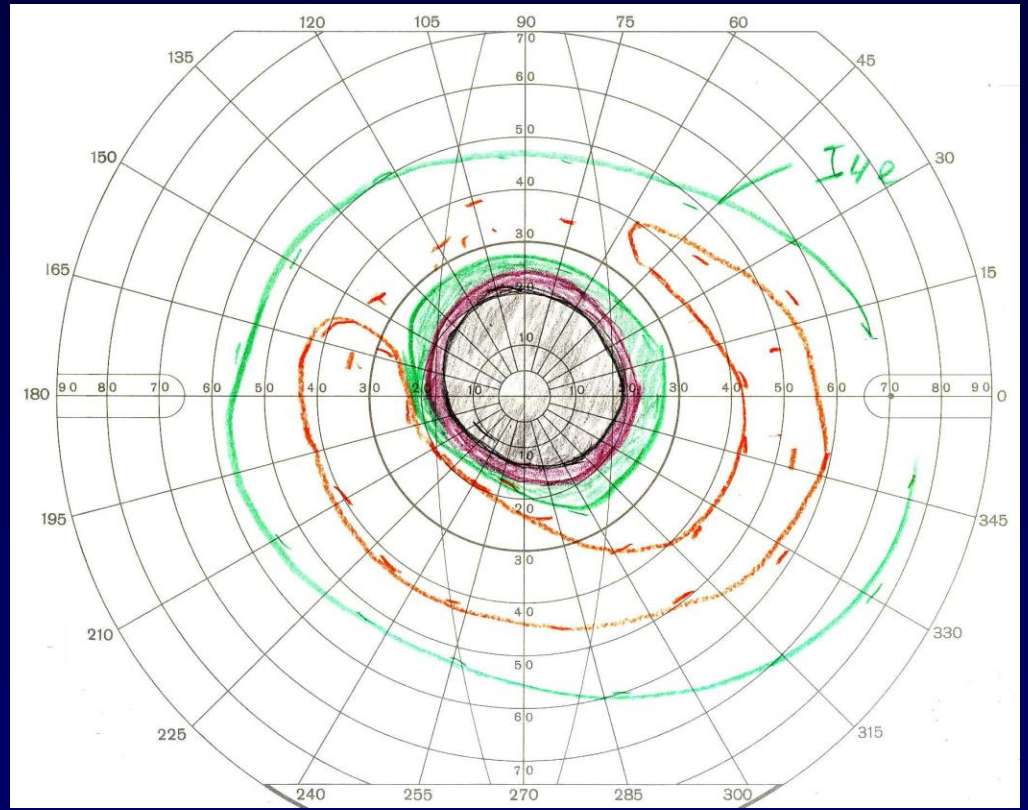
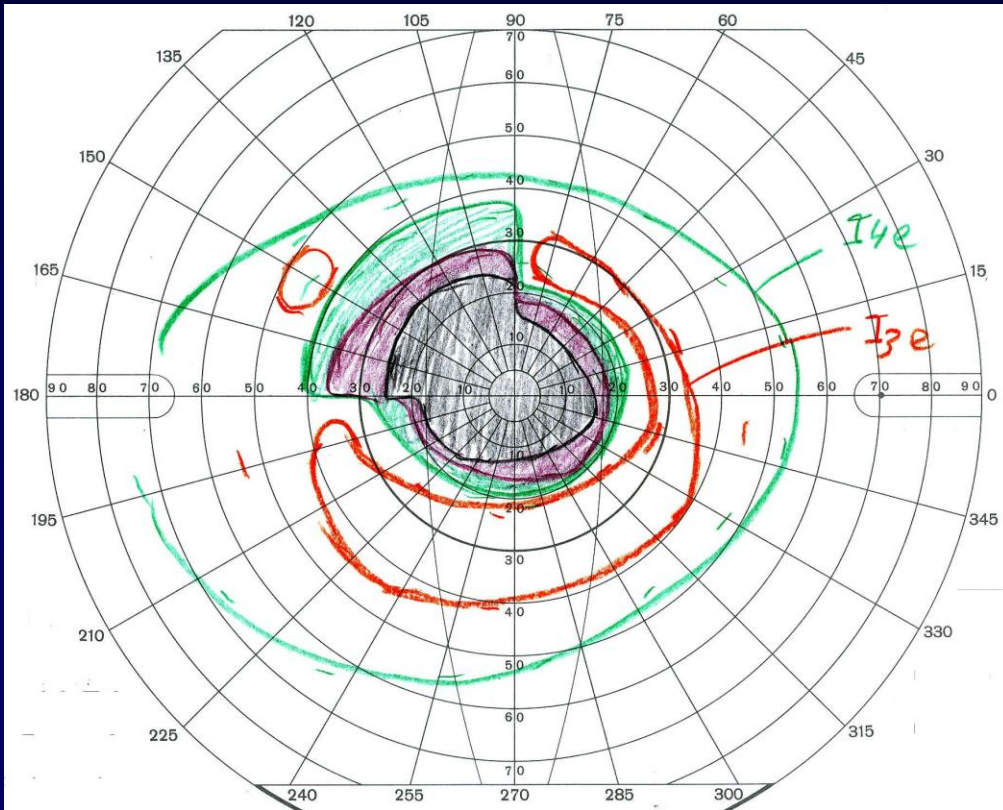
Dominant and recessive optic atrophy

Glaucoma

14 yo girl

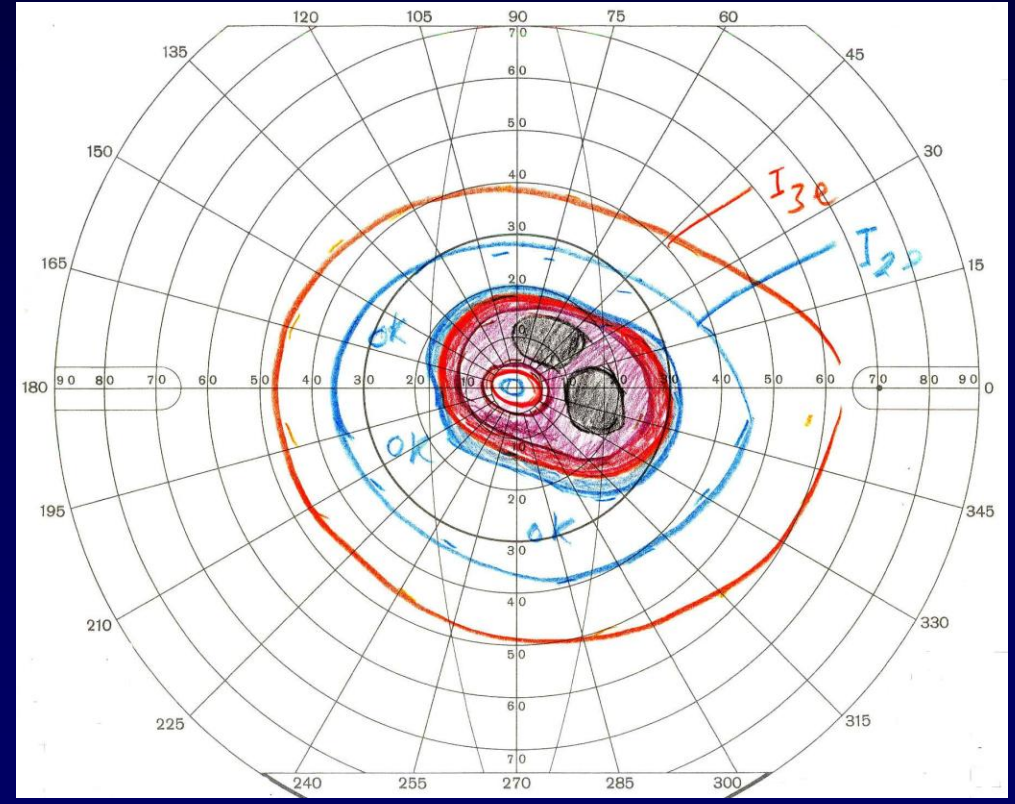
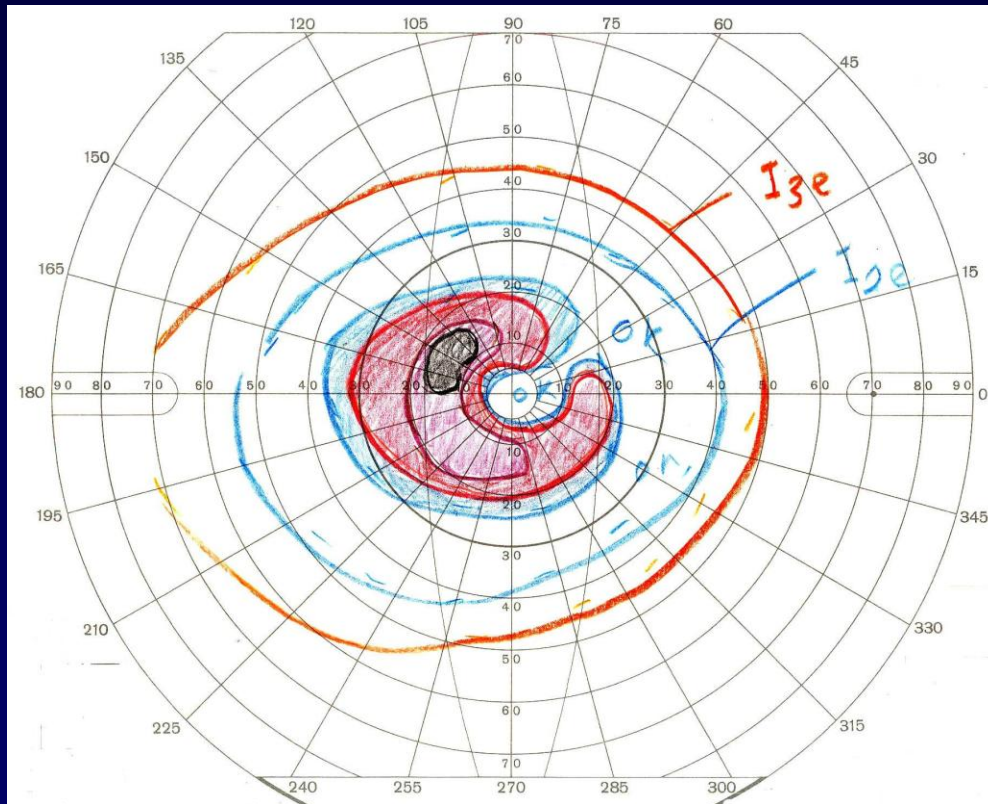
- Vision OS began to decline gradually without pain
- First visit with VA OD 20/40 and OS CF at 3'
- Pale, flat optic disks OU
- VA 1 month later CF at 3' OU
- VA 10 months later 20/20 OU
- Diagnosis LHON-like optic neuropathy

VF 1 month later



234962-1

VF 10 months later



234962-1

Afferent Visual System

- During exam
- Neuro-imaging
- Blood tests
- Ultrasound
- Anatomy
- Examination
- Diagnoses
- Tests

Tests

- During exam
- Neuro-imaging
 - CT and MRI scans
 - Vasculitis (ESR, CBC, ANA, VDRL)
 - PET scan
- Blood tests
 - ERG/VEP
 - Orenal (BUN, Creatinine, U/A)
 - Carotid Doppler
 - Liver function tests (SGOT, SGPT, alkaline phosphatase)
- Ultrasound
 - Electrolytes
 - Genetic evaluation