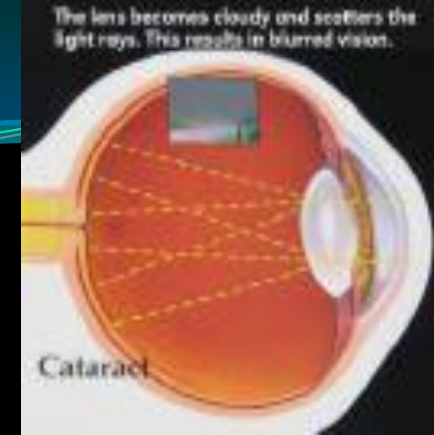



# CHRONIC VISUAL LOSS

**DR ESSAM OSMAN**  
**ASSISTANT PROFESSOR**  
**GLAUCOMA CONSULTANT**  
**Email: [essamosman@hotmail.com](mailto:essamosman@hotmail.com)**  
**[www.ksu.edu.sa/68905](http://www.ksu.edu.sa/68905)**

# CHRONIC VISUAL LOSS

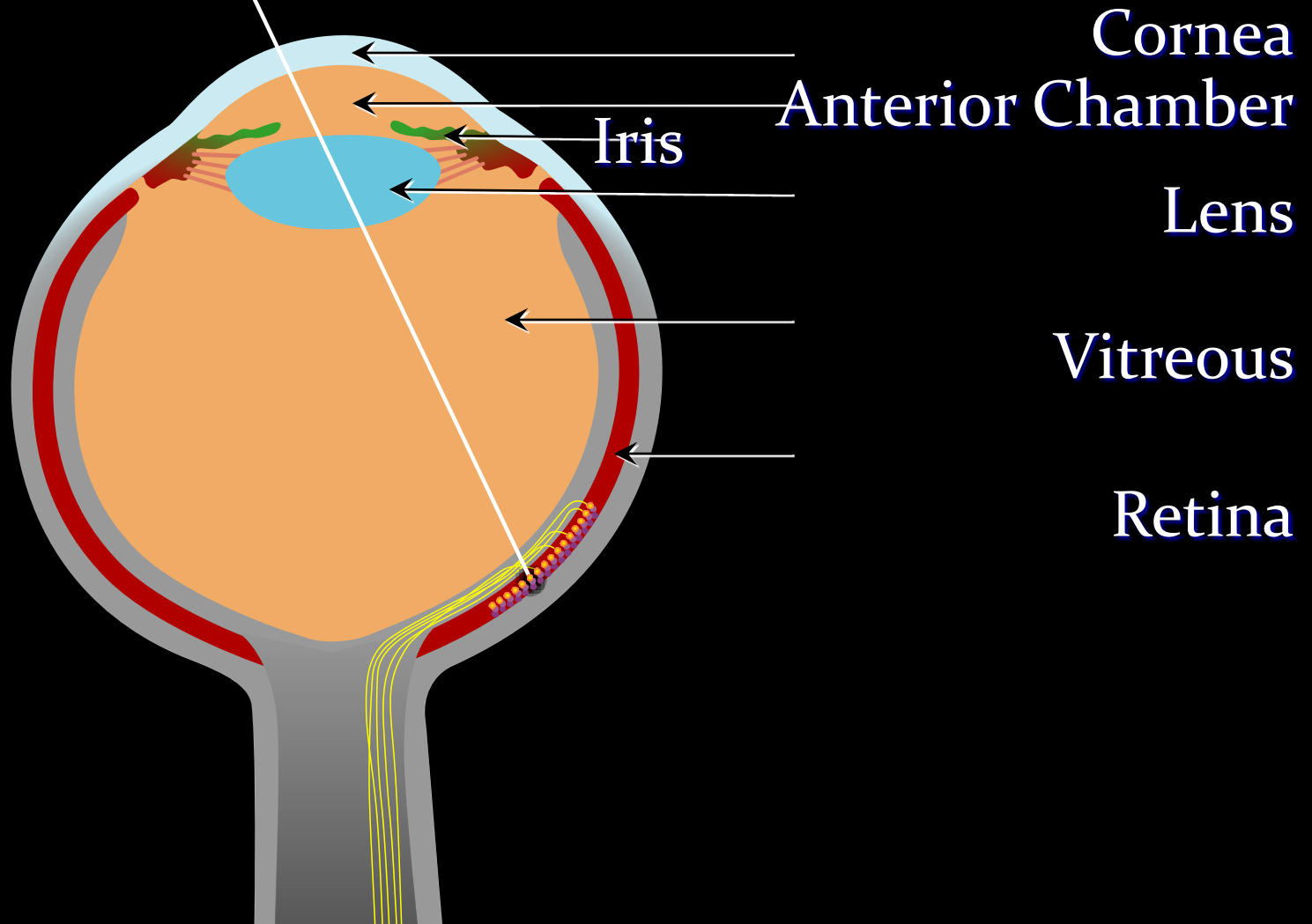
Causes of slowly progressive visual loss  
in an adult patient

1. Glaucoma.
2. Cataract.
3. Macular degeneration.
4. Diabetic retinopathy .

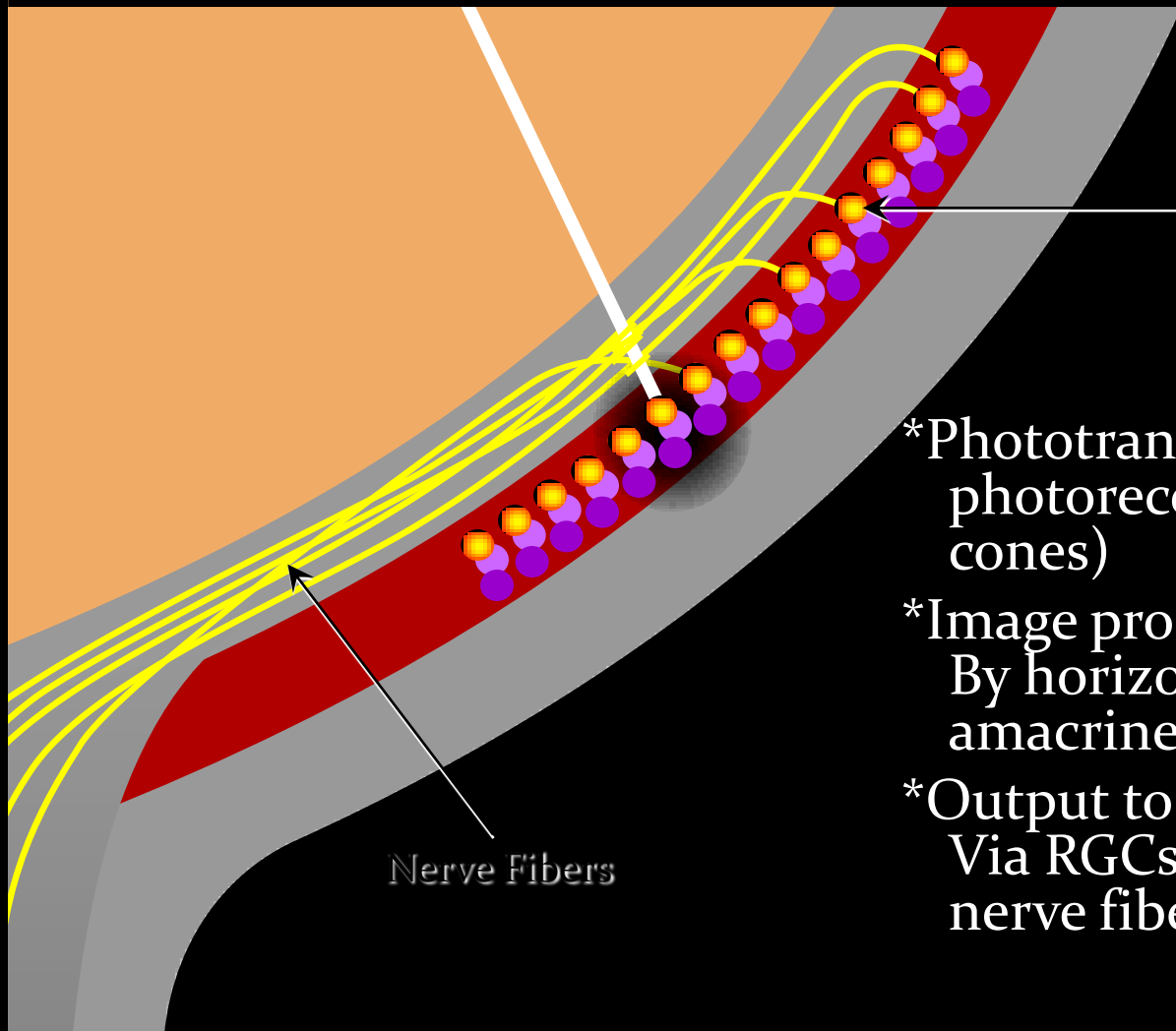
# CHRONIC VISUAL LOSS

1. Measure intraocular pressure with a tonometer
2. Evaluate the nerve head, classifying it as normal, or abnormal
3. Evaluate the clarity of the lens
4. Evaluate the function and appearance of the macula.

# The Visual Pathway



# The Visual Pathway

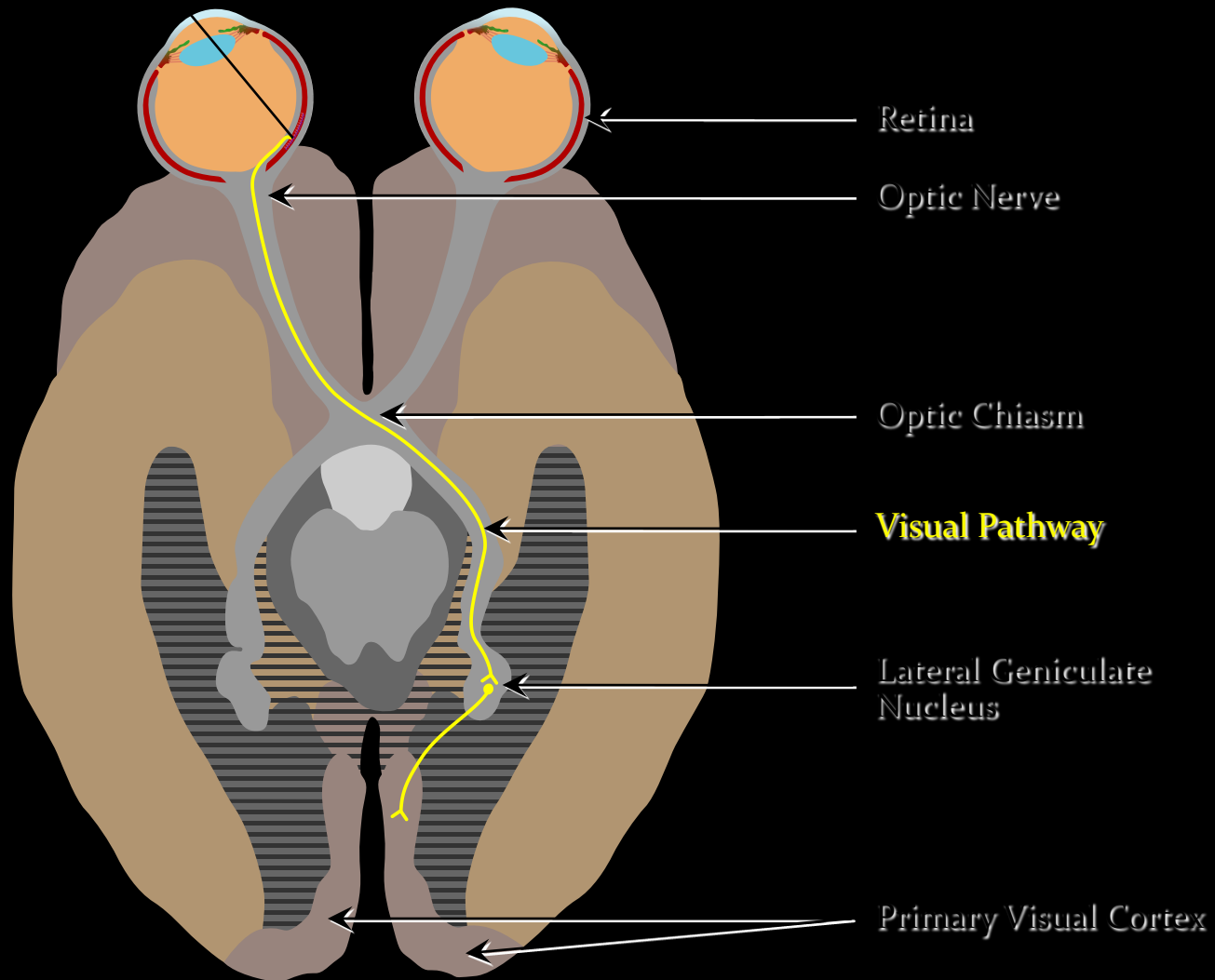


RGCs

Nerve Fibers

- \*Phototransduction: By photoreceptors (rods and cones)
- \*Image processing: By horizontal, bipolar, amacrine and RGCs
- \*Output to optic nerve: Via RGCs and nerve fiber layer

# The Visual Pathway



# GLAUCOMA

- \*A major cause of blindness.
- \*Often A symptomatic; in early stage.
- \*Damage is irreversible.
- \*Effective treatment is available.

# TYPES OF GLAUCOMA

**Acute glaucoma**

**Chronic glaucoma**

**Congenital glaucoma**



# GLAUCOMA

## *EGS definition:*

progressive optic neuropathies, that have in common characteristic morphological changes at the optic nerve head and retinal fiber layer in the absence of other ocular disease or congenital anomalies. Progressive retinal ganglion cell death and visual field loss are associated with these changes.”

— *EGS, Terminology and Guidelines for Glaucoma, 2nd Edition, 2003*

# GLAUCOMA

## RELEVANCE

- Glaucoma is the second most important cause of blindness in the United States and the single most important cause of blindness in African Americans.
- If glaucoma is detected early and treated medically or surgically, blindness can be prevented. Most patients with early glaucoma are asymptomatic.

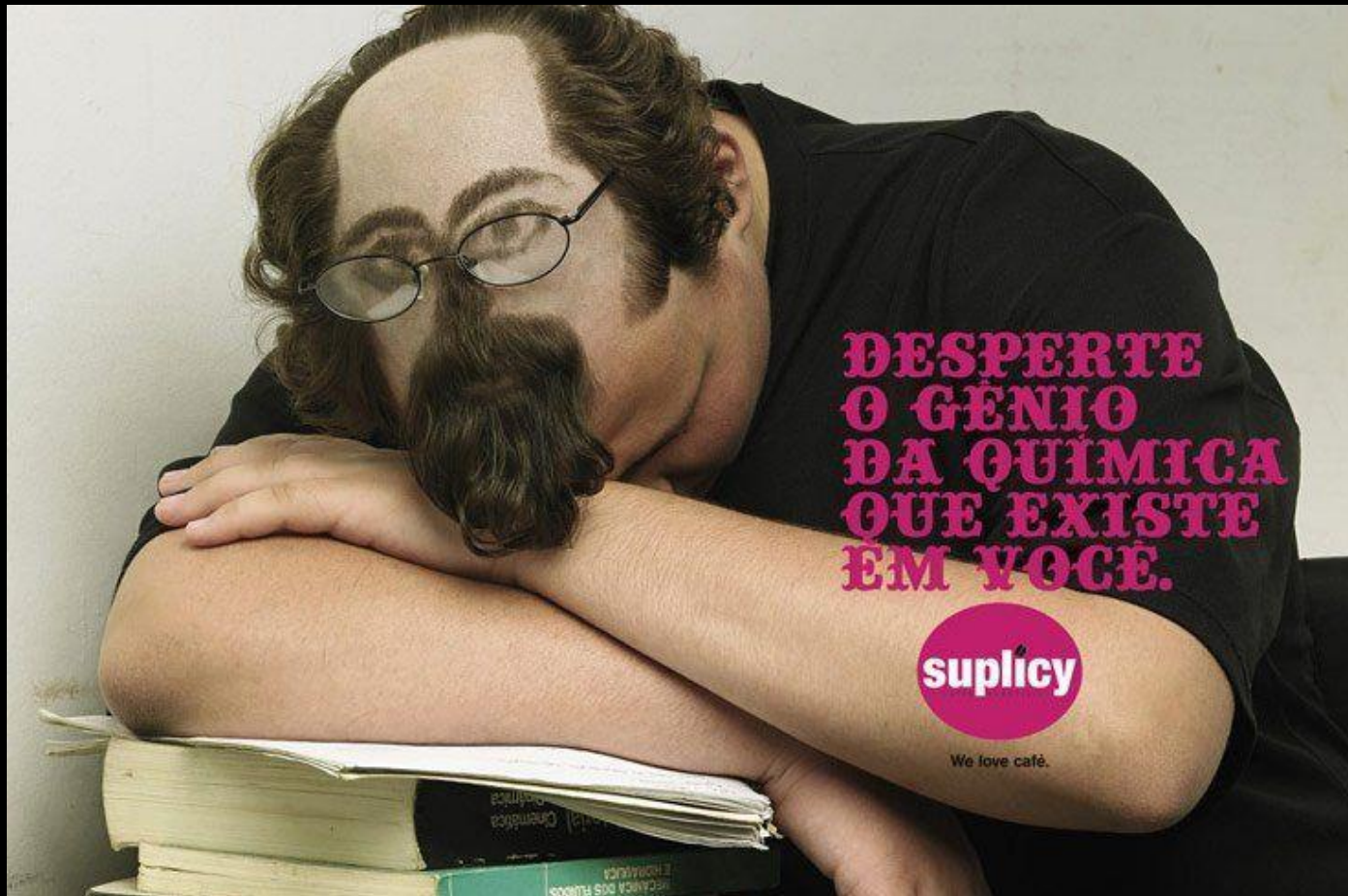
# GLAUCOMA

- The great majority of patients lack pain, ocular inflammation.
- Much peripheral vision can be lost before the patient notices **visual** impairment.

# GLAUCOMA

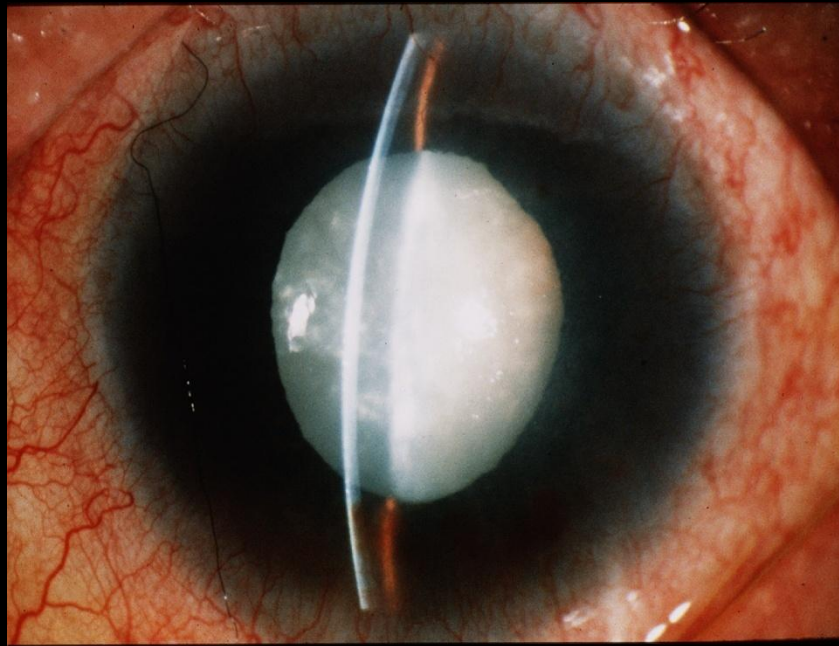
- Because glaucoma involves elevated pressure in the eye, routine measurement of Intraocular pressure is a valuable means of screening for glaucoma.
- elevation of intraocular pressure can lead to optic nerve damage; therefore, examination of the optic nerve is another way to detect glaucoma.

Email: [essamosman@hotmail.com](mailto:essamosman@hotmail.com)  
[www.ksu.edu.sa/68905](http://www.ksu.edu.sa/68905)



# CATARACT

Opacity of the lens



# CATARACT

## Causes

Age related

subcapsular

Nuclear

cortical

Traumatic



# CATARACT

## Metabolic

diabetic

galactosemia

Glucokinase deficiency

Mannosidosis

Fabry's disease

Lowes syndrome

Hypocacemic syndrome



# CATARACT

## Cataratogenic drugs

Chlorpromazine

Miotics

Myleran

Amiodarone

gold

# CATARACT

## Complicated cataract

Uveitis

Retinal dystrophy, retinitis pigmentosa

High myopia

Acute glaucoma

## Intrauterine causes

rubellatoxo, cmv

## Syndroms

dowen syndrome, wernerrothman

## Hereditary 1/3

# CATARACT

## Classification

### 1-morphologic

nuclear,subcapsular,cortical

### 2-maturity

immature,mature,imminent,hypermaturation

### 3-age of onset

congenital,infantile,presenile,senile

# CATARACT

## Management

Congenital lens aspiration±IOL

Acquired

ICCE

ECCE

ECCE IOL

PHACO IOL

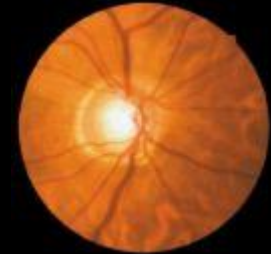
# Macular Degeneration



## RELEVANCE

- In the United States, age-related macular degeneration is the leading cause of irreversible central **visual loss** (20/200 or worse) among people aged 52 or older.
- Because certain types of macular degeneration are treated effectively with laser, it is important to recognize this entity and to refer for appropriate care.
- It is important to distinguish between the possible causes of **visual loss**, whether cataract (surgically correctable), glaucoma (medically or surgically treatable), or macular
- degeneration (potentially laser treatable).

# Macular degeneration



## Macular Anatomy

The macula is an oval area situated about 2 disc diameters temporal to the optic disc. The macula is composed of both rods and cones and is the area responsible for detailed, fine central vision.

The central macula is a vascular and appears darker than the surrounding retina. The fovea is an oval depression in the center of the macula. There is a high density of cones but no rods are present.

The central depression of the fovea may act like a concave mirror during ophthalmoscopy, producing a light reflection (i.e., foveal reflex).

# Macular degeneration

Test for macular function

V/A

Pupillary light reaction

Color vision

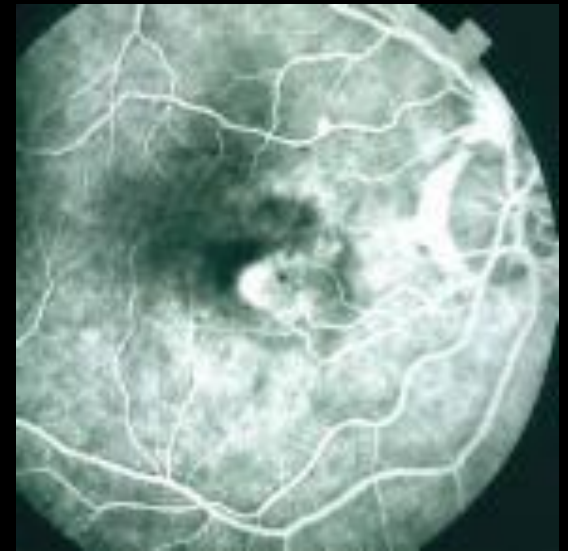
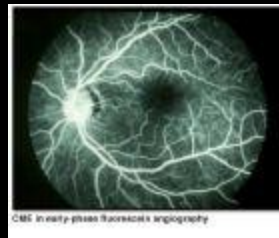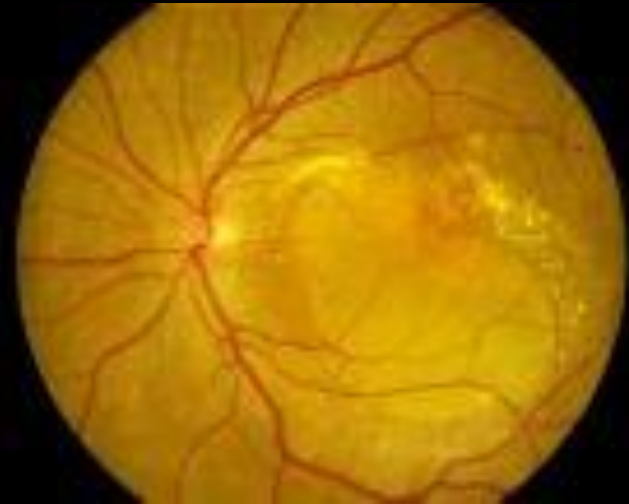Ophthalmoscopy

Amsilar grid

Phtosterss test

Laser inferometry

Flourescine angiography



# Macular degeneration

## Age related

Some degree of visual loss

associated with drusen & atrophy of RPE  
subretinal neovascularization

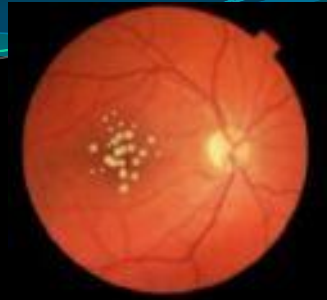## Types

Dry type 90% slow progressive atrophy of RPE and photoreceptors

Wet type 10% RPE detachment and choroidal neovas.



# Macular Degeneration



- Drusen are hyaline nodules (or colloid bodies) deposited in Bruch's membrane, which separates the inner choroidal vessels from the retinal pigment epithelium. Drusen may be small and discrete or larger, with irregular shapes and indistinct edges. Patients with drusen alone tend to have normal or near normal visual acuity, with minimal metamorphopsia

# Macular degeneration

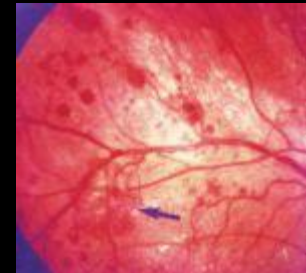As the most common cause of vision loss among people over the age of 60, macular degeneration impacts millions of older adults every year. The disease affects central vision and can sometimes make it difficult to read, drive or perform other activities requiring fine, detailed vision.

# macular degeneration

- **What Risk Factors You Can't Control**
- **Age**
- **Race**
- **Gender**
- **Genetics**

# Macular Degeneration

- **Risk Factors You Can Control**
  - **Smoking**
  - **High Blood Pressure**
  - **High Cholesterol**
  - **Poor Nutrition**
  - **Unprotected Exposure to Sunlight**
  - **Ultraviolet (UV) light has been**
  - **Excessive Sugar Intake**
  - **Obesity**
  - **Sedentary Lifestyle**



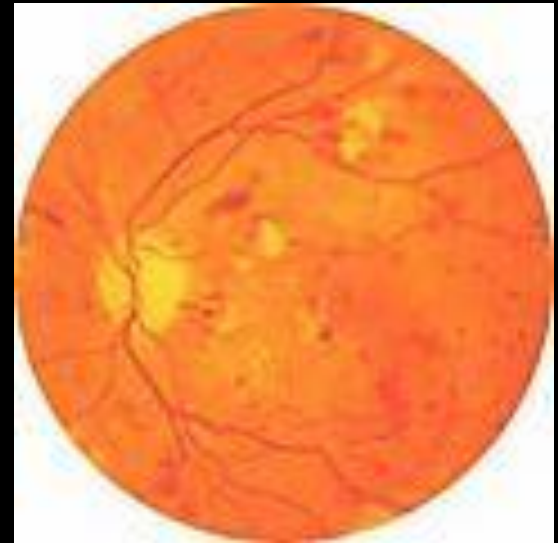
# Diabetic retinopathy

- Risk factors

Duration of the disease

Good metabolic control

Pregnancy, hypertension, renal disease, anaemia



# Diabetic retinopathy

- Pathogenesis

Microvascular occlusion

Microvascular leakage

# Diabetic retinopathy

## Microvascular occlusion

Thickened capillary basement membrane

Capillary endothelial cell damage

Changes in RBC

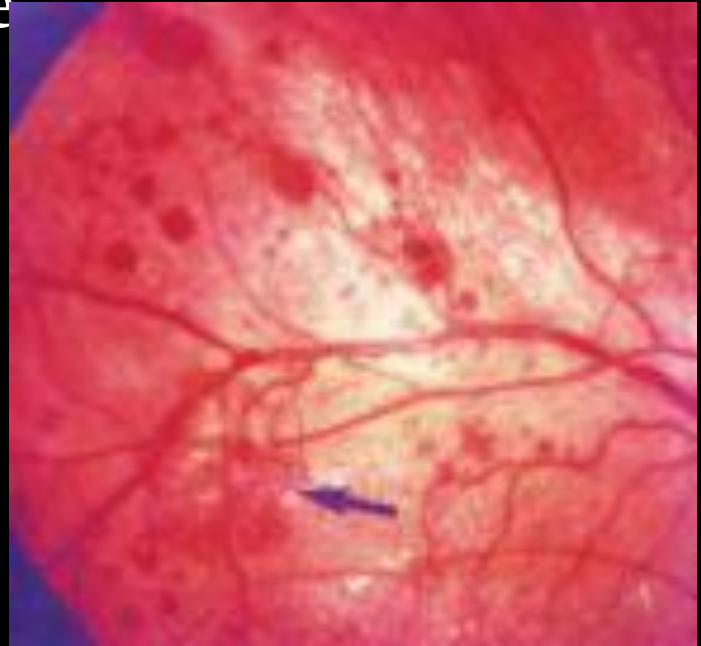


Retinal ischemia



AV SHUNT

NEOVASCULARIZATION

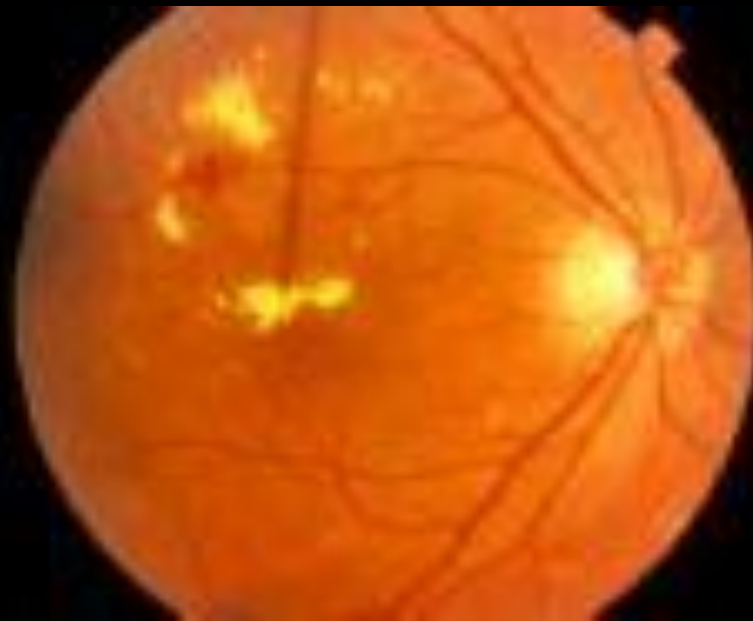

# Diabetic retinopathy

## Microvascular leakage

Loss of pericyte cells between endothelial cells

Leakage of plasma constituents in the retina (exudate)





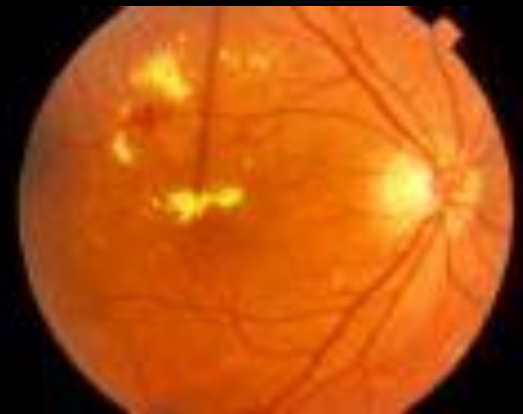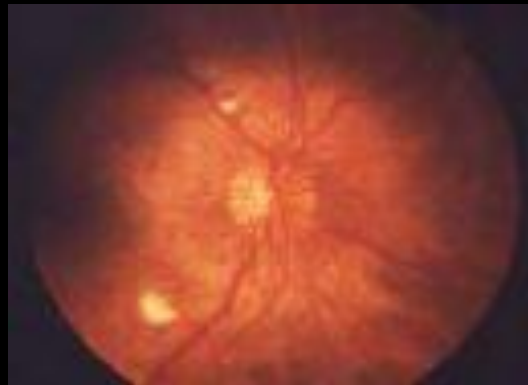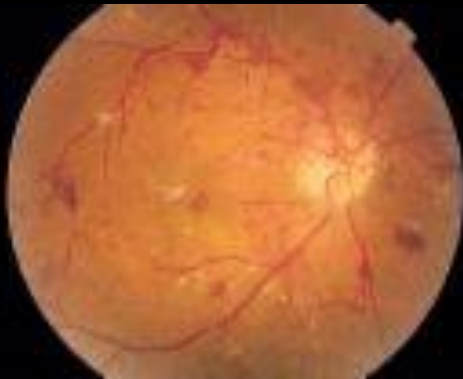# Diabetic retinopathy

- **Types**

Non proliferative

Proliferative

Macular oedema



# Diabetic retinopathy

- Management

NPDR      OBSERVATION

PDR      PRP

MACULAR OEDEMA      FOCAL&GRID LASER

