

Ocular manifestations of systemic diseases






431
Teams
medical students

Ophthalmology Team

Sources :Most of the work is from 430 team

Lecture notes,11th edition

Doctor's notes



■ From slides ■ Doctor's Notes ■ Team's Notes ■ From the book ■ Important

Introduction:

- Many systemic diseases can affect the eye particularly the retina, and systemic involvement of the eye can cause blindness.
- In fact, most of the cases seen are blindness unless the disease is detected early and treated aggressively.
- Most infections involve the retina microvasculature.

1. Diabetes Mellitus: (imp)

- The most common disease that affects the eye is diabetes, 30% of the population are diabetics and almost 30% of diabetic patients have retinopathy.
- Diabetic retinopathy (DR) is the commonest cause of legal blindness in individuals between the ages of 20 and 65 years.
- The risk of blindness is 2-5 times more in diabetics than non diabetics.
- By 20 years of diabetes, almost all patients with type 1 diabetes will develop hemianopsia and 6% of type 2 diabetes will have hemianopsia.
- Consider diabetes in the case of unexplained retinopathy, cataract, new vessels on iris, extra-ocular muscle palsy, optic neuropathy or sudden change in refractive error.
- Most important factor in development of Diabetic retinopathy is: **duration** of the disease (**non modifiable** risk factor).
- Other important **modifiable** risk factors:

1. Glycemic control:

A study was done that included only patients with type 1 diabetes, one group on tight control blood sugar with insulin pump, the other one on conventional treatment.

After 6.5 years, the study showed:

Tight control patients were protected against diabetic retinopathy, nephropathy and neuropathy. So this study shows for sure that reduction of blood sugar is very important. The only side effect is the hypoglycemic attack.

Also many years later after this study termination, they found that patients who were tight control and converted to conventional treatment are still yet protected.

2. Blood pressure control .

3. Hyperlipidemia & obesity (magnify macular edema)

4. Smoking .

5. Pregnancy (accelerates progression)

- There's a strong association between nephropathy and diabetes.
- Retinopathy is a microangiopathy: disease of microvasculature of the retina involving the capillary arterioles and venules, the same pathogenesis as microangiopathy is seen in the CNS and kidneys.

1.1 The Retina:

- The most important structure affected by DM.

Pathophysiology: 2 major changes that occur in the retina:

1st: the first early change is break down of the blood retinal barrier (which is formed by the tight junctions between the endothelial cells and capillaries) → early loss of pericytes and early loss of tight junction proteins between endothelial cells → vessels leak fluid, blood and lipoproteins → retinal edema → visual loss (edema of the macula is one of the common causes of visual impairment among patients with diabetes).

- Can happen long before detachment
- Due to loss of pericytes, microaneurysms develop
- Hemorrhages can occur (flame-shaped)

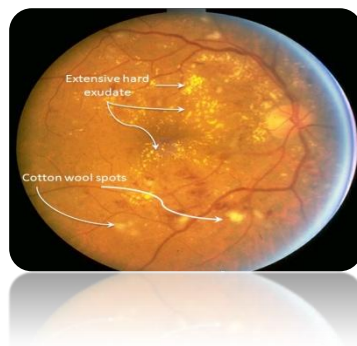
2nd: the second change is progressive occlusion of retinal microvasculature → ischemia and hypoxia (The retina is metabolically reactive, so how does it react to hypoxia? by releasing angiogenic molecules like vascular endothelial growth factor and others which will lead to vascular hyper permeability) → leakage → neovascularization → angiogenesis (occur by proliferation of endothelial cells and migration) → bleeding → vitreous hemorrhage → fibrous tissue formation (myofibroblasts will produce proteins like collagen) → traction of the retina → detachment.

From doctor's explanation on pictures:

- Macula is the area responsible for sharp vision.
- Focal laser will stop the leakage from microaneurysms.

-Central signs of retinal ischemia:

1. **Cotton wool spots:** a clinical sign of retinal infarction due to occlusion of retinal arterioles.
2. **Hard exudates:** a sign of leakage, they are composed of lipoproteins and leydin macrophages.
3. **Venous changes:** most important and reliable sign of retinal ischemia. (Venous beading means there are areas of dilations and constrictions and venous looping, if the patient has this sign they call it: severe non proliferative diabetic retinopathy).



-Signs of Severe non proliferative diabetic retinopathy:

1. **Venous changes (in the form of beading and looping).**
2. **Intra retinal microvasculare collaterals: dilations of intra retinal blood vessels in response to ischemia.**

3-Presence of multiple hemorrhages in 4 quadrants.

-signs of proliferative diabetic retinopathy:

neovascularization of iris, disc, retina and vitreous → vitreous hemorrhage from bleeding of fragile new vessels → fibrous tissue can contract causing tractional retinal detachment.

Treatment:

1-Non proliferative diabetic retinopathy:

- Focal laser is effective to control diabetic macular edema.
- We can inject into the eye a monoclonal antibodies against vascular endothelial growth factor to stop its action in macular edema. (combined with the laser)

2- proliferative diabetic retinopathy:

Pan retinal photocoagulation: they apply laser burns throughout the retina sparing the macula and optic nerve. (It's a destructive way of treatment but it keeps the vision of the patient).

If untreated → new vessels will develop within the optic nerve causing bleeding and vitreous hemorrhage.

They are considered emergency cases, if the patients with those signs are left untreated, 50% of them will have high risk proliferative disease within 1 year.

- New vessels: always develop from the veins (because they are darker and broader than arteries).
- When the new vessels arise from the disc → called new vessels of the optic nerve head.

1.2 The Iris:

- Neo-vascularization of iris (**rubeosis iridis**): a very severe complication of diabetes because those new vessels will obstruct the angle of anterior chamber leading to increase in pressure → leads to neo-vascular glaucoma.
- Sign of severe retinopathy.
- Treated by pan retinal photocoagulation.

1.3 The Lens:

- Earlier onset of senile sclerosis and cortical cataract
- May get hyperglycemic cataract due to sorbitol accumulation (rare)
- Poor glycemic control can suddenly cause refractive changes by 3-4 diopters

1.4 The Extra-Ocular Muscles & Optic Nerve:

- Usually CN III infarct
- Pupils usually spared in diabetic CN III palsy but get ptosis (Why? Parasympathetic fibers run around the nerve not in it)
- May involve CN IV and VI
- Usually recover within few months
- Visual acuity loss due to infarction of optic disc/nerve

- Screening and Prevention:

- How do we prevent blindness in diabetics?

The only way is to establish regular screening programs where a picture of the fundus (digital fundal photography) is taken on a regular basis, using non mydriatic fundus cameras, then the photo would be sent to a reading center which will provide certain instructions

- **Why do we need screening programs?**

Because the patient may have a blinding disease while still asymptomatic. The only case where the patient will have a complaint is if they develop vitreous hemorrhage, which is very late.

2. Grave's Disease: (imp)

Is an autoimmune condition characterized by excessive deposition of inflammatory cells, edema and mucopolysaccharides in the orbit, extra orbital muscles and periocular tissue leading to proptosis. Fibrosis of the levator palpebrae superioris and sympathetic over stimulation lead to upper eyelid retraction . There is optic neuropathy due to increase pressure in the orbit. Also there is restriction of ocular motility due to fibrosis of extra ocular muscles.

- i. **Lid retraction:**

- Unilateral or bilateral; upper or lower lids
- Due to hyper stimulation of the sympathetic nervous system and contraction + fibrosis of levator palpebrae superioris muscle.

- ii. **Exophthalmos:**

- Usually asymmetric; may be unilateral
- Due to an increase in the bulk of the ocular muscles and the orbital fat .The increase is due to infiltration by inflammatory cells
- Diagnosis: MRI/CT

- iii. **Ophthalmoplegia:**

- Restrictive myopathy is due to fibrosis of extra-ocular muscles
- Limitation of elevation is the most common finding – due to **tethering** and fibrosis of the inferior rectus.

- iv. **Retinal and optic nerve changes:**

- Compression of the globe may lead to elevation of intra-ocular pressure
- Optic neuropathy occurs either as a result of compression or due to ischemia

- v. **Corneal changes:**

- Normally, the upper lid covers 1-2 mm of the cornea
- Lagophthalmos is the inability to close eyelids completely
- Keratitis lagophthalmos: is inflammation of the cornea due to dryness and formation of ulcers in the lower 1/3 of cornea during sleep because the patient can't close his eyes which lead to excessive exposure .

-So the patient should fill the eye with lubricating ointment to prevent corneal dryness before sleep.

3 .Granulomatous Diseases:

3.1 Tuberculosis:

- Eye inflammation of uveitis secondary to tuberculosis.

1st most common cause of uveitis is **Vogt- koyanagi- harada disease.**

2nd most common cause of uveitis is **Tuberculosis.**

3rd most common cause of uveitis is **Behcet's disease.**

4th common cause of uveitis is **toxoplasmosis.**

- Tuberculosis can mimic any type of eye inflammation.
- Whenever you see a patient with chronic uveitis → rule out tuberculosis.

Diagnosed by: history and tuberculin skin test (usually 15 mm or more in duration).

- It's a common disease in the kingdom.
- It can cause granulomatous inflammation manifested as keratic precipitates on the cornea, iris nodules, inflammation of the vitreous, cystoid macular edema, retinal vasculitis (Eale's disease), choroiditis (inflammation of the choroidal granulomas).

From doctor's explanation on pictures:

- It presents as multiple nodules (granulomas) in the anterior chamber.
- If the patient has vasculitis it will manifest as whitish exudate inflammation around the blood vessels and hemorrhages.
- Tuberculosis can cause the most aggressive retinal vasculitis that can lead to blindness if left untreated.
- But remember that you can have TB uveitis without pulmonary TB.
- **TB affects the eye in 2 ways:**
 - 1- Direct infection: choroidal granuloma (appears as pinkish nodules).
 - 2-Type 4 hypersensitivity immune reaction to tuberculin protein causes retinal vasculitis.
 - appearance: whitish vessels; "sheathing".
 - Suspect TB in a patient with eye inflammation who has been receiving steroids for long time without benefit.
- **Treatment:** TB responds only to anti-tuberculosis drugs and needs a long course of treatment (6-9 months) ± a short course of steroids.

3.2 Syphilis:

- Important cause of uveitis
- It's a rare cause of eye inflammation in our country.
- More prevalent in Western countries due to higher prevalence of HIV infection.

Ocular features:

a) Congenital : (due to infection during 3rd trimester; if infection occurs in 1st trimester → abortion). It causes:

- 1) Interstitial keratitis
- 2) Chorioretinitis

b) Acquired:

- 1) Ocular chancre
- 2) Iridocyclitis
- 3) Interstitial keratitis
- 4) Chorioretinitis
- 5) Neuro-ophthalmic manifestations

Any patient with uveitis rule out syphilis → by doing VDRL test and fluorescent treponemal antibody absorption test (FTA-Abs).

3.3 Sarcoidosis:

- Sarcoidosis is a multisystem disease characterized by non-caseating granulomatous infiltration of affected tissues.
- Patients may present with pulmonary, ocular, joint or reticuloendothelial system manifestations
- The most common cause of uveitis in Japan & **Blacks** (not common here).

Ocular features:

- 1) Lid margin and conjunctival granuloma
- 2) Acute iridocyclitis
- 3) Chronic granulomatous iridocyclitis
- 4) Peripheral retinal periphlebitis
- 5) Choroidal granulomas
- 6) Retinal granulomas
- 7) Optic nerve granulomas
- 8) Retinal vasculitis: less aggressive than T.B

• Diagnosis by:

- chest x-ray
- CT chest

From doctor's explanation on pictures:

- Causes granulomatous uveitis.
- **Mutton fat keratic precipitate**: accumulation (whitish deposits) of inflammatory cells in the cornea (diagnostic) → indicates granulomatous inflammation.
- **Posterior synechiae** (adhesions): between the iris and the lens, it's a complication of chronic inflammation.
- Vasculitis
- On chest x ray: Hilar lymph adenopathy.

Causes of granulomatous uveitis:

1. Sarcoidosis
2. Tuberculosis
3. Syphilis
4. Herpes
5. Vogt- koyanagi-harada disease
6. sympathetic ophthalmia.

- So if there are granulomas + synechiae → granulomatous inflammation.
- But large granulomas are either due to sarcoidosis or tuberculosis.
- **Treatment**: unlike T.B, granulomatous uveitis due to sarcoidosis responds well to corticosteroids.

4. Viral: Rubella:

- Maternal rubella during the 1st trimester causes serious congenital anomalies.
- rare in our country.
- **Features**:
 1. Eyes: small eyes (microphthalmos), **cataracts (most common)**, glaucoma, retinopathy
 2. Ears: deafness
 3. Heart: congenital anomalies.

5. Hereditary Metabolic Disorders: Wilson's Disease:

- Also called “hepatolenticular degeneration”.
- Pediatric disease.
- Deficiency of alpha-2 globulin ceruloplasmin (copper binding protein) → abnormal copper metabolism, this will allow copper metabolism in the tissues.
- Kayser-Fleischer rings (copper deposits in Descemet's membrane); more common in patients with CNS involvement, present in 50% if only liver involvement

6. Heritable Connective Tissue Disorders: Marfan's Syndrome:

• Ocular features:

- 1) **Lens subluxation** (Ectopia lentis) (important; usually superiorly and nasally)
 - 2) Angle anomaly
 - 3) Glaucoma
 - 4) Hypoplasia of the dilator muscle
 - 5) Axial myopia
 - 6) Retinal detachment
- Rare syndrome due to fibrillin-1 gene mutation on chromosome 15; autosomal dominant
 - Features: increased length of long bones, esp. fingers and toes (arachnodactyly) +
 - Scanty (little) subcutaneous fat
 - Relaxed ligaments
 - Congenital heart disease
 - Deformities of the spine and joints

What are the other causes of lens subluxation (Ectopia lentis) :

1. Trauma
2. Homocysteinemia
3. Hyperlysinemia
4. Weill–Marchesani syndrome: is a rare, genetic disorder characterized by short stature, broad head (brachycephaly) and other facial abnormalities; hand defects and distinctive eye abnormalities. The eye manifestations typically include unusually small, round lenses of the eyes (spherophakia), which may be prone to dislocating.

Multisystem Autoimmune:

7.1 Systemic Lupus Erythematosus (SLE):

- Features: butterfly rash, pericarditis, Raynaud's, renal disease, arthritis, anemia, and CNS signs

• Ocular features:

Most important and most common is **retinopathy** that occurs only during active disease, “flare-ups” and affects the cornea causing corneal melting.

- **Findings:** **Cotton wool spots** and large areas of infarction and ischemia in the peripheries (signs of arteriolar occlusion), intra retinal hemorrhage
- **Diagnosis:** elevated ESR, antibodies: anti-nuclear antibodies (ANA), anti-double-stranded DNA antibodies, anti-phospholipid antibodies. Low complements 3 and 4.

- If the patient has Anti-Phospholipid Antibodies, anti lupus antibodies and anticardiolipin antibodies → high risk of retinopathy.
- **Anti-Phospholipid Antibody Syndrome:** recurrent thromboembolism, recurrent abortions, and +ve anti-phospholipid antibodies → produces any kind of retinal vascular occlusive disease.

7.2 Rheumatoid Arthritis (RA):

Seropositive, rheumatoid factor.

Ocular features:

- 1) Keratoconjunctivitis sicca (dry eye syndrome)
 - 2) Scleritis, lead to melting of the sclera
 - 3) Keratitis
 - 4) Melting of the cornea
- **Dryness of the cornea and conjunctiva because it destroys the accessory lacrimal glands and it's diagnosed by Rose Bengal staining** (shows dead and devitalized tissue as well as tissue that is inadequately protected by mucin)
 - The scleritis may lead to **scleromalacia perforans (necrotizing scleritis):** thinning of the sclera, it's common in western countries. This can lead to uveal tissue herniation and perforation of the globe.

7.3 Ankylosing Spondylitis (AS):

Seronegative

Ocular features:

Acute recurrent non-granulomatous iridocyclitis.

non-granulomatous means : no mutton fat , no iris nodules, limited to the anterior segment of the eye.

- History: **young man** with acute recurrent non-granulomatous anterior uveitis
- Ask if he has **lower back pain** which is worse in the morning and decrease in the evening.

• investigations:

1. **HLA B27** detection → acute recurrent non-granulomatous anterior uveitis.
2. x-ray of sacroiliac joints.

Other conditions associated with HLA B27 positivity that can cause recurrent non-granulomatous anterior uveitis:

1. Inflammatory bowel disease
2. Reiter's Syndrome(Reactive arthritis)
3. Psoriatic arthritis

7.4 Juvenile idiopathic Arthritis:(imp)

The disease tends to affect the eye causing uveitis, mostly anterior uveitis.

Types:

- 1) Systemic onset “Still’s disease” (the child presents with **fever, lymphadenopathy, rash & pericarditis**) → Uveitis is extremely **rare**
- 2) Polyarticular onset (*5 joints or more*) → Uveitis is fairly **rare**
- 3) **Pauciarticular** (oligoarticular) onset (*4 joints or less; esp. elbow, knee, & wrist*) → the risk to develop uveitis is high. **20%** develop uveitis.

Risk factors:

1. Girls are more prone than boys (x3).
2. If the child develops the disease before the age of 4, the risk of eye involvement is high.
3. Associated with positive antinuclear antibodies (ANA); increases the risk of eye involvement.
4. Oligoarticular type.

- Referral to a pediatric ophthalmologist is necessary as soon as the diagnosis is made, because uveitis may be asymptomatic and this can lead to blindness due to cataract and glaucoma, they need aggressive treatment to control the inflammation.

7.5 Behcet's Disease:

- Behcet's disease is a very aggressive type of eye inflammation and a blinding disease if not treated; it causes severe **occlusive retinal vasculitis** (most important destructive complication) leading to atrophy of the retina, venous occlusions and hemorrhages.
- **HLA B51** association.
- Common in areas of the "Ancient Silk Road" it extends from the Mediterranean up to the Far East passing by Japan, China, and Korea. It has a genetic predisposition, **very rare** in Caucasians (Europe). Most common and prevalent in **Turkey**.
- **Diagnosed clinically: recurrent oral ulcers (aphthous ulcers) they are very painful and 2 of the following:**
 - 1-**Recurrent Genital ulcers**
 - 2-**Skin lesions**
 - 3- **Eye inflammation. Anterior uveitis**, occasionally with **hypopyon** (present in about 30% of patients with Behcet's Disease), which is pus collection in anterior chamber)
 - 4-**Positive Behcet's test**

Treatment:

Corticosteroids combined with immunosuppressive therapy, for example: cyclosporine, azathioprine (Imuran), mycophenolate.

If no response: biological treatment: **infliximab (anti α -TNF)** it changes the management of the disease and saves the vision of the patient. It's also very effective in Rheumatoid arthritis and inflammatory bowel disease.

7.6 Sjogren's Syndrome:

- Autoimmune disease. Causes **dryness**.
- Involvement of salivary glands leading to dryness of the mouth.
- Involvement of bronchial epithelium
- Involvement of vaginal epithelium
- **Ocular features:** keratoconjunctivitis sicca : dryness of the conjunctiva.

7.7 Vogt- Koyanagi- Harada Syndrome: (imp)

- Disease of Pigmented individuals (**common here in the Kingdom** but rare in the white population in Europe and Caucasians).

- Cutaneous signs
- Neurological signs
- **Ocular features:** Anterior and posterior uveitis
- Multisystem and Autoimmune disease with **HLA DR4** association.
- **Most common cause of eye inflammation especially in the kingdom.**
- **T-lymphocytes attack melanin containing structures:**
 - Skin → vitiligo
 - Hair → alopecia and white hair
 - Lashes → poliosis (white lashes)
 - Meninges → severe headache, meningitis
 - Inner ear → tinnitus, deafness
 - Eye → Uveitis
- When the choroiditis is exudative → (accumulation of fluid under retina) → serous **retinal detachment**.
- Irregular pupil (not rounded) due to synechiae.
- The inflammation could be granulomatous leading to Mutton fat keratic precipitates (due to anterior uveitis)**
- Treatment:**
 - Should be very early in the acute phase by large doses of systemic steroids for at least 1 year + immunosuppressive therapy like mycophenolate mofetil (Cellcept) and cyclosporin, to prevent permanent visual loss.
 - Prognosis: visual recovery is not always complete → residual depigmentation of the fundus

7.8 Giant-Cell Arteritis: (imp)

- One of the top emergencies in ophthalmology.
- The patient comes to the emergency room because of **sudden loss of vision**.
- Autoimmune vasculitis of large and medium sized arteries
 - More common in **elderly >60 years**
 - **Features: Sudden visual loss** due to ischemic anterior- posterior optic neuropathy (infarction of optic nerve); due to occlusion of the small circulation supplying the optic nerve, disc will be **pale and swollen**, and other features:
 - Pain over the temporal artery
 - Jaw claudication (pain with chewing)
 - Scalp tenderness (gangrene of the scalp may occur)
 - Polymyalgia rheumatica (muscular pain, esp. neck, shoulders and hips)
 - Constitutional symptoms
 - **Diagnosis:** Erythrocyte Sedimentation Rate (ESR: very high), C reactive protein (CRP: high), **temporal artery biopsy (gold standard)**.
 - **Treatment:** immediately and urgently with **large doses of systemic steroids** to **prevent visual loss in the other eye** (the affected eye will be **irreversibly damaged** at the time of presentation).

8- Toxoplasmosis:

- **Most common cause of infectious uveitis.**

- Common in Brazil (they found that the organism is transmitted by drinking water). Some European countries like France (they eat raw meat which increases the risk of toxoplasmosis).

- Typically causes necrotizing retinitis.

1) Etiology: *Toxoplasma gondii*, obligate intracellular protozoan parasite

2) Congenital:

- If the mother is infected for the first time during 1st trimester, the pregnancy will be terminated because the baby won't survive.

- If the mother is infected during 3rd trimester, the baby will present with congenital toxoplasmosis with:

1. Convulsions

2. Chorioretinitis

3. Intracranial calcifications

3) Acquired: either by:

1. Reactivation of old lesion of retinitis (if develops near old scar).

2. New infection:

It may lead to blindness because of severe toxoretinitis involving the macula.

4) Treatment:

It's sensitive to many antibiotics: clindamycin, azithromycin, minocycline, sulfonamides, cotrimoxazole pyrimethamine (Daraprim).

For patients with recurrent attacks of toxoretinitis (because the lesion develops from an old scar due to its reactivation): prophylactic treatment: cotrimoxazole, 6 mg twice a week .

9. Sickle Cell Disease: (skipped by the doctor).

10. Vascular: Hypertensive Retinopathy:

-Ocular features:

Stage 1: Attenuation of arteries (\downarrow diameter) and increase light reflex , sometimes referred to as “copper/silver wiring” .

Copper wire arterioles where the central light reflex occupies most of the width of the arteriole and *Silver wire arterioles* where the central light reflex occupies all of the width of the arteriole, due to thickening of the walls of arteries.

Stage 2: as grade 1 + Nipping of the retinal veins where they are crossed by arterioles

Stage 3: as grade 2+ Narrowing of arterioles \rightarrow breakdown of blood-retina barrier:

hard exudates, hemorrhages, macular star and retinal edema.

If severe \rightarrow signs of capillary occlusion: **cotton wool spots**

Stage 4: Optic disc edema (bilateral = papilledema) \rightarrow blurring of vision and temporary visual loss

N.P; radial distribution of hard exudates is **pathognomic** for hypertensive retinopathy.

Summary:

Disease	Structure involved and presentation	Comments
<p>Diabetes Mellitus</p>	<p>-The Retina: 2 changes: 1-Break down of the blood retinal barrier → early loss of peri-cytes and early loss of tight junction proteins between endothelial cells → vessels leak fluid, blood and lipoproteins → retinal edema → visual loss 2- progressive occlusion of retinal microvasculature → ischemia and hypoxia leakage → neovascularization → angiogenesis → bleeding → vitreous hemorrhage → fibrous tissue formation → traction of the retina → detachment.</p> <p>Central signs of retinal ischemia: Cotton wool spots, Hard exudates, Venous beading and looping</p> <p>-The Iris: Neo-vascularization of iris (rubeosis iridis): Sign of severe retinopathy.</p> <p>-The Extra-Ocular Muscles & Optic Nerve: -Usually CN III infarct -Pupils usually spared in diabetic CN III palsy.</p>	<p>2 types: i. Proliferative: neovascularization of iris, disc, retina and vitreous → vitreous hemorrhage from bleeding of fragile new vessels → fibrous tissue can contract causing tractional retinal detachment. ii. Non-proliferative: -Venous changes -Intra retinal microvasculare collaterals -Presence of multiple hemorrhages in 4 quadrants.</p> <p>Treatment: 1-Non proliferative: Focal laser + monoclonal antibodies 2- proliferative: Pan retinal photocoagulation</p>
<p>Grave's Disease</p>	<p>Lid retraction: Due to hyper stimulation of the sympathetic nervous system and contraction + fibrosis of levator palpebrae superioris muscle. Exophthalmos: Due to an</p>	

	<p>increase in the bulk of the ocular muscles and the orbital fat</p> <p>Ophthalmoplegia: Restrictive myopathy is due to fibrosis of extra-ocular muscles.</p> <p>Retinal and optic nerve changes: Compression of the globe may lead to elevation of intra-ocular pressure</p> <p>Corneal changes: keratitis due to dryness and formation of ulcers in the lower 1/3 of cornea during sleep because the patient can't close his eyes which lead to excessive exposure</p>	
Tuberculosis	<p>-Tuberculosis can mimic any type of eye inflammation</p> <p>-Whenever you see a patient with chronic uveitis → rule out tuberculosis.</p> <p>- It can cause - granulomatous inflammation manifested as keratic precipitates on the cornea, iris nodules, inflammation of the vitreous, systoid macular edema, retinal vasculitis (Eale's disease), choroiditis.</p>	<p>-2nd most common cause of uveitis is Tuberculosis.</p> <p>- Affect the eye by:</p> <ol style="list-style-type: none"> 1- Direct infection: choroidal granuloma (appears as pinkish nodules) 2- Type 4 hypersensitivity immune reaction to tuberculin protein causes retinal vasculitis.(whitish) <p>-Tx: anti-tuberculosis drugs +steroids</p>
Syphilis	<p>Important cause of uveitis</p> <p>Ocular features: In congenital syphilis: Interstitial keratitis and Chorioretinitis</p> <p>In acquired syphilis:</p> <ol style="list-style-type: none"> 1.Ocular chancre 2.Iridocyclitis 3.Interstitial keratitis 4.Chorioretinitis 5.Neuro-ophthalmic manifestations 	<p>Any patient with uveitis rule out syphilis→ by doing VDRL test and fluorescent treponemal antibody absorption test (FTA-Abs).</p>

Sarcoidosis	<p>-Sarcoidosis is a multisystem disease characterized by non-caseating granulomatous infiltration of affected tissues. Patients may present with pulmonary, ocular, joint or reticuloendothelial system manifestations.</p> <p>Ocular features:</p> <ol style="list-style-type: none"> 1) Lid margin and conjunctival granuloma 2) Acute iridocyclitis 3) Chronic granulomatous iridocyclitis 4) Peripheral retinal periphlebitis 5) Choroidal granulomas 6) Retinal granulomas 7) Optic nerve granulomas 8) Retinal vasculitis: less aggressive than T.B <p>-Mutton fat keratic precipitate is diagnostic feature</p> <p>-Posterior synechiae</p>	<p>The most common cause of uveitis in Japan & Blacks.</p> <p>Tx :corticosteroids</p>
Rubella	<p>Maternal rubella during the 1st trimester causes serious congenital anomalies.</p> <p>Eyes: small eyes (microphthalmos), cataracts (most common), glaucoma, retinopathy</p>	
Wilson's Disease	<p>-Also called hepato-lenticular degeneration.</p> <p>-Kayser-Fleischer rings (copper deposits in Descemet's membrane); more common in patients with CNS involvement, present in 50% if only</p>	

	liver involvement	
Marfan's Syndrome	<p>Ocular features:</p> <p>1. Lens subluxation (Ectopia lentis), Angle anomaly, Glaucoma, Hypoplasia of the dilator muscle, Axial myopia, and Retinal detachment</p>	
SLE	<p>Ocular features:</p> <p>-Most important and most common is retinopathy that occurs only during active disease, “flare-ups” and affects the cornea causing corneal melting.</p> <p>- Cotton wool spots and large areas of infarction and ischemia in the peripheries (signs of arteriolar occlusion), intra retinal hemorrhage.</p>	<p>Diagnosis: elevated ESR, anti-nuclear antibodies (ANA), anti-double-stranded DNA antibodies, anti-phospholipid antibodies and Low complements 3 and 4.</p>
Rheumatoid Arthritis	<p>Ocular features:</p> <ol style="list-style-type: none"> 1. Keratoconjunctivitis sicca 2. Scleritis, lead to melting of the sclera 3. Keratitis 4. Melting of the cornea <p>- Dryness of the cornea and conjunctiva because it destroys the accessory lacrimal glands and it's diagnosed by Rose Bengal staining.</p> <p>- The scleritis may lead to scleromalacia perforans (thinning of sclera)</p>	
Ankylosing Spondylitis	<p>Presentation could be a young man with acute recurrent non-granulomatous anterior uveitis.</p>	<p>Investigations:</p> <p>HLA B27 detection. x-ray of sacroiliac joints</p>
Juvenile idiopathic Arthritis	<p>Mostly causes anterior uveitis.</p> <p>Types: Systemic “Still’s disease, Polyarticular, and Pauciarticular (oligoarticular).</p>	<p>Risk factors of eye involvement:</p> <ol style="list-style-type: none"> 1. Girls are more prone than boys (x3). 2. before the age of 4 3. Associated with

		+(ANA) 4. Oligoarticular type.
Behchet's Disease	<p>- Is a very aggressive type of eye inflammation and a blinding disease if not treated; it causes severe occlusive retinal vasculitis.</p> <p>-Anterior uveitis, occasionally with hypopyon (present in about 30% of patients with Behchet's Disease).</p>	<p>-HLA B51 association -Common in areas of the "Ancient Silk Road" - Diagnosed clinically: recurrent oral ulcers (aphthous ulcers) and 2 of the following: 1-Recurrent Genital ulcers 2-Skin lesions 3-Anterior uveitis, occasionally with hypopyon 4- Positive Behcet's test -Tx: Corticosteroids combined with immunosuppressive therapy. If no response, infliximab (anti α-TNF).</p>
Sjogren's Syndrome	Ocular features: keratoconjunctivitis sicca : dryness of the conjunctiva	
Vogt- Koyanagi-Harada Syndrome	<p>-Disease of Pigmented individuals (common here in the Kingdom) - is a multisystem disorder presenting with a bilateral panuveitis with exudative retinal detachments and followed by neurological and cutaneous manifestations such as baldness and loss of lash and skin pigments (poliosis and vitiligo). - The inflammation could be granulomatous leading to Mutton fat keratic precipitates (due to anterior uveitis).</p>	<p>Most common cause of eye inflammation in our country.</p> <p>Tx: Should be very early in the acute phase by large doses of systemic steroids for at least 1 year + immunosuppressive therapy like mycophenolate mofetil (Cellcept) and cyclosporin, to prevent permanent visual loss.</p>
Giant-Cell Arteritis	<p>-Autoimmune vasculitis of large and medium sized arteries -sudden loss of vision due to ischemic anterior-posterior optic neuropathy</p>	<p>- One of the top emergencies in ophthalmology</p> <p>- investigations: Erythrocyte Sedimentation</p>

	<p>- Disc will be pale and swollen.</p> <p>-Other symptoms: Pain over the temporal artery ,Jaw claudication, Scalp tenderness (gangrene of the scalp may occur), Polymyalgia rheumatica (muscular pain, esp. neck, shoulders and hips) and Constitutional symptoms</p>	<p>Rate (ESR: very high), C reactive protein (CRP: high), temporal artery biopsy (gold standard).</p> <p>Tx : immediately and urgently with large doses of systemic steroids to prevent visual loss in the other eye.</p>
Toxoplasmosis	<p>-Typically causes necrotizing retinitis</p> <p>-If the mother is infected during 3rd trimester, the baby will present with congenital toxoplasmosis with:</p> <ol style="list-style-type: none"> 1 .Convulsions 2. Chorioretinitis 3. Intracranial calcifications <p>Acquired: Either reactivation of old infection or new infection.</p>	<p>-Common in Brazil -Most common cause of infectious uveitis.</p> <p>Tx: It's sensitive to many antibiotics: clindamycin, azithromycin, minocycline sulfonamides, cotrimoxazole pyrimethamine (Daraprim) prophylactic treatment in pt. with recurrent attacks.</p>
Hypertensive Retinopathy	<p>Ocular features: Stage 1: Attenuation of arteries (↓ diameter) and increase light reflex , sometimes referred to as “copper/silver wiring” Stage 2: as grade 1 + Nipping of the retinal veins where they are crossed by arterioles Stage 3: as grade 2+ Narrowing of arterioles → breakdown of blood-retina barrier: hard exudates, hemorrhages, macular star and retinal edema Stage 4: Optic disc edema (bilateral = papilledema) → blurring of vision and temporary visual loss</p>	<p>Radial distribution of hard exudates is pathognomic for hypertensive retinopathy</p>

Questions :

1- Ankylosing Spondylitis is associated with:

- A. Anterior uveitis
- B. Episcleritis
- C. Kerato conjunctivitis

2- Which of the following indicates ischemic retina in diabetic retinopathy:

- A. Venous beading/looping
- B. Macular edema
- C. Retinal detachment.

3- A patient presented to the uveitis clinic, on examination there was fine keratic precipitate over the posterior cornea and irregular pupil, what is your diagnosis:

- A. sarcoidosis
- B. rubella
- C. toxoplasmosis
- D. Behchet's Disease

Answers:

A,A,A