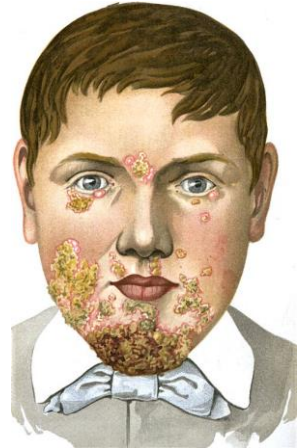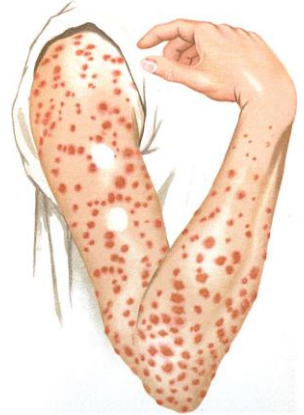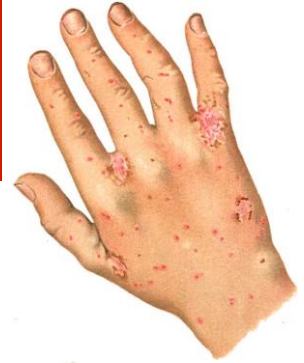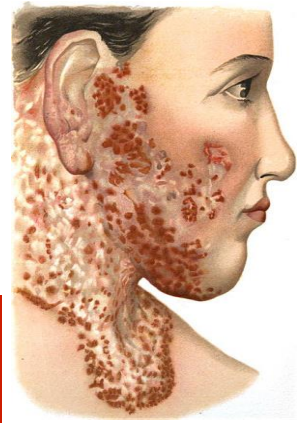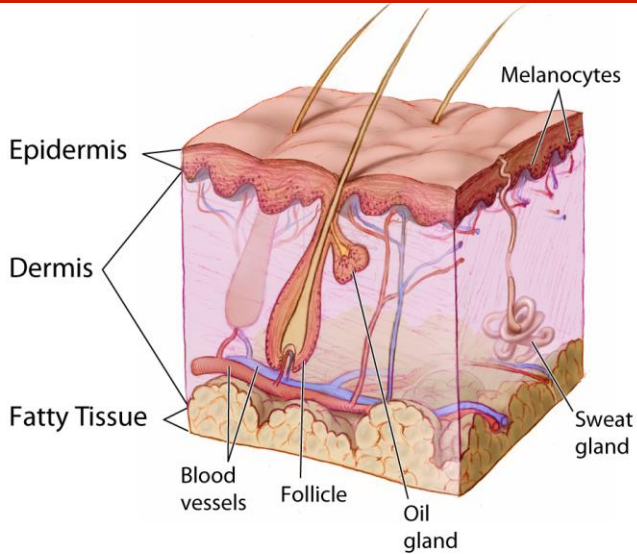


432 Teams

Dermatology



Structure and Function of the Skin

Color Code: Original, **Team's note**, Important, Doctor's note, Not important, **Old teamwork**



Done by: Mohammed Alshehri & Basil Al Suwaine

Reviewer: Abdullah bin Saeed

Team Leader: Basil Al Suwaine

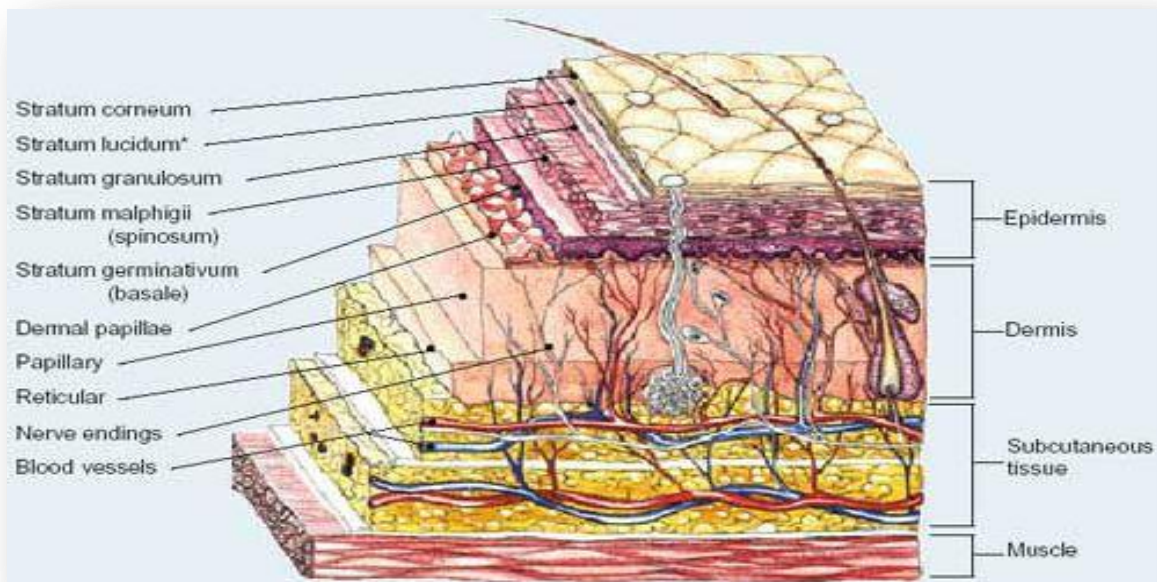
Objectives

- **To be familiar with the different structures of the skin.**
- **To have basic knowledge of anatomy and function of the skin.**
- **To be familiar with different tools to investigate skin disorders.**
- **The relation between anatomy and diseases.**
- **To have a general idea about different therapeutic options used in dermatology practice.**

Introduction

- The skin is the largest organ of the human body (1.75 m²), and the weight about 15% of the body
- It is divided into epidermis (ectoderm), dermis (mesoderm), subcutaneous fat and skin appendages (ectoderm and mesoderm).
- Dermal- Epidermal junction is called basement membrane, the weakest part in the skin and the usual site of blisters.
- Palms, soles, genitalia and scalp skin have slightly different structure.

Useful video <https://www.youtube.com/watch?v=z5VnOS9Ke3g>

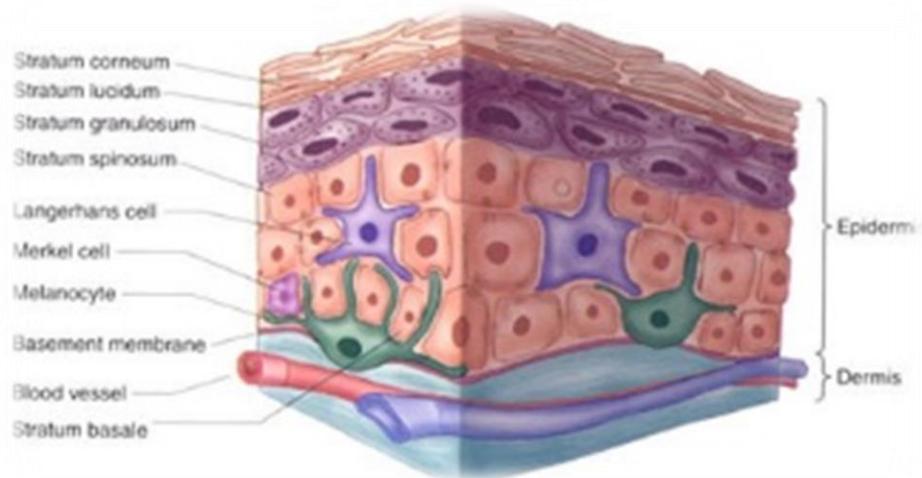


The skin is a complex, dynamic organ.

- It is the largest organ of the body.
- It consists of many cell types and Specialized structures like “the Basement Membrane”
- It serves multiple functions that are crucial to health and survival.

The skin consists of:

- Epidermis (has 4 layers)
- Basement membrane (between epidermis and dermis) thin 4 lyres
- Dermis (2 layers)
- Subcutaneous tissue
- Skin appendages

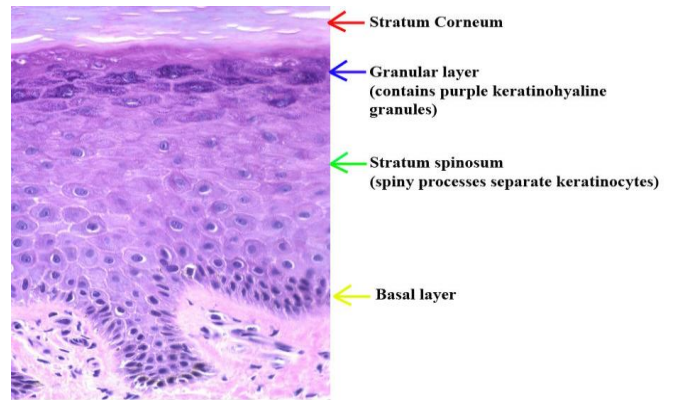


Function:

- Prevent infections via innate and adaptive immunity (infections, autoimmunity, cancers).
- Maintain a barrier (infections, dehydration, eczema).
- Repair injury (cancer, ulcers).
- Provide circulation (infarction, vasculitis).
- Communicate (sensory neuropathy, pruritus).
- Provide nutrition (vit D deficiency).
- Regulate temperature (hypo and hyperthermia).
- Attract attention (photo ageing, vitiligo, alopecia).

Epidermis

- The epidermis consists of many cells 95% are Keratinocytes, and other prominent cells are melanocytes, Langerhans cells, and merkel's cells.
- The epidermis doesn't have blood vessels it obtains its nutrients from the blood vessel of dermis diffusing through the dermoepidermal junction (papillary layer of dermis).
- Very important layer for the protection of the skin against chemical agents and pathogens



1- Basal cell layer: (Stratum basale)

Keratinocytes:

- 95% of the cells in epidermis.
- Division of these cells only occur in the basal layer where 10% of them are stem cells.
- In the spinous layer they are connected to each other by desmosomes and gap junctions.
- Keratinocytes in basal layer express keratin 5 and 14, other keratinocytes express keratin 1 and 10.
- The normal transit time of a differentiating keratinocyte from basal layer to the outer surface of the stratum corneum is 28 days. (in psoriasis it is much shorter).

Cornification (keratinization)

- It is the cytoplasmic events that occur in the cytoplasm of epidermal keratinocytes during their terminal differentiation into dead horny cell (corneocyte)
- The total process takes **approximately 2 months**
- It involves the formation of keratin polypeptides.
- **Abnormalities in this process leads to roughness and scaling of the skin like PSORIASIS (In psoriasis it takes 3 days which will result in a lot of scales)**

Melanocytes

- Between every 10 basal cells there is a melanocyte (**On the face the ratio of melanocytes to basal keratinocytes is around 1 to 5, that's why it's sometimes darker than the rest of the body, the face is more sun exposed, therefore it requires more protection**), while on the lower back it is around 1 to 20.
- Melanocytes are also found in the iris, retina, meninges, hair, and nails
- Melanin stored in melanosomes.
- Melanosomes are transferred to adjacent cells by means of dendrites thus forming the "Epidermal Melanin Unit"
- Melanocytes are responsible for producing skin pigment
- Mainly seen in the basal layer
- Melanocytes are found in the epidermis, the hair bulb, the eye, and the brain.
- Melanin provide protection from ultraviolet light.
- The size of melaosomes and packaging differentiate white from dark skin. "The number of melanocytes are equal in white and dark skin"

2- Spinous cell layer: (Stratum spinosum)

- Keratinocyte adhere to each other by **desmosomes** (complex modification of the cell membrane) which appear like spines.

Langerhans cells

- Derived from the bone marrow.
- Usually situated in the middle of the spinous layer.

- Birbeck granules can be seen by electron microscope in the cytoplasm.
- The only cell in the skin that express MHC class 2 antigens.
- Act as antigen presenting cells.
- Langerhans cells are also found in the epidermis (all of its layers, unlike the melanocytes which is available only in the basal layer), they work as surveillance though the whole layers of the epidermis to check for any abnormality (infections, cancers or others)
- Abnormal proliferation of these cells is seen in Langerhans cell histiocytosis.

3- Granular cell layer (Stratum granulosum)

- Diamond shaped cells.
- Cytoplasm is filled with **keratohyaline granules**.
- Thickness of this layer is proportional to the thickness of the stratum corneum
- “In thin skin it is 1 -3- cell layers and 10 cell layers in thick skin like palms and soles”

4- Cornified layer (Stratum corneum)

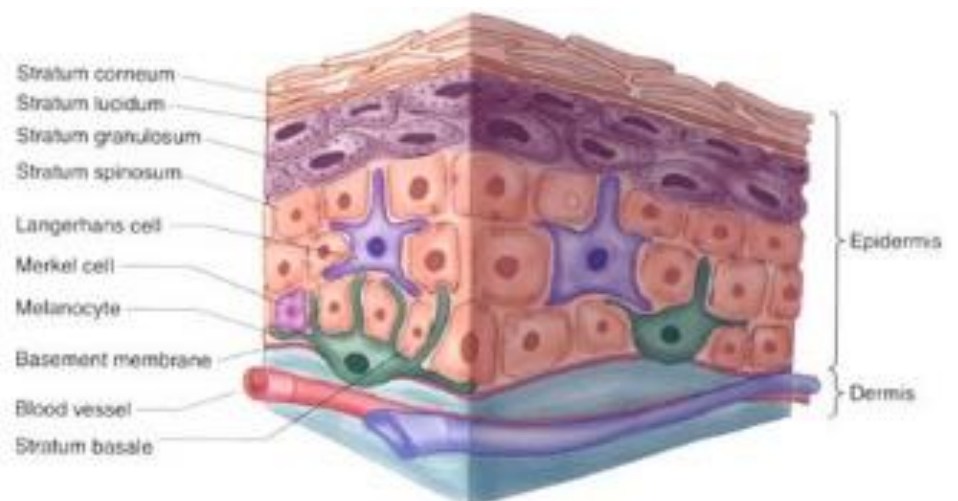
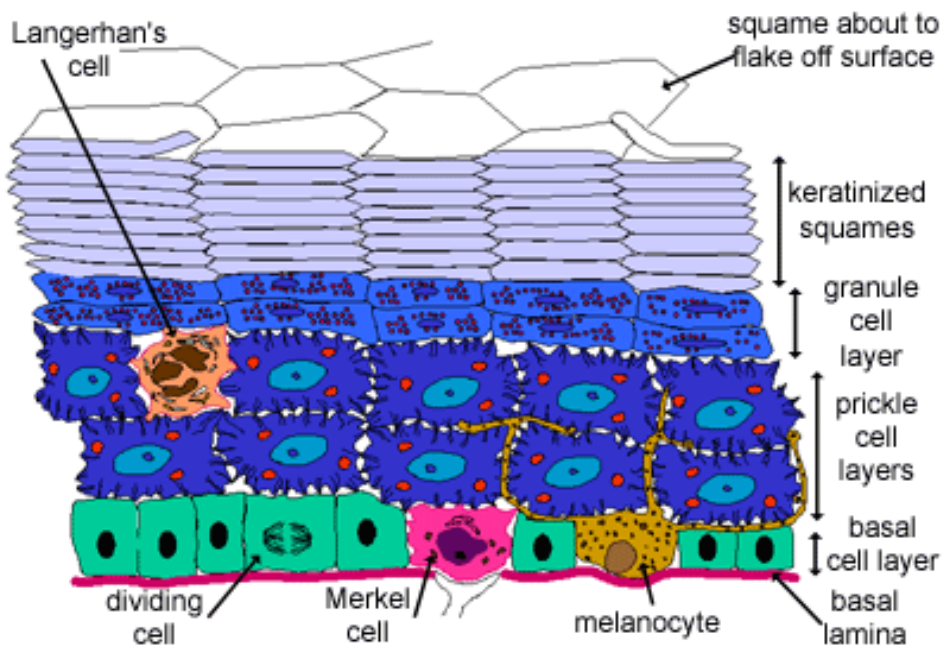
- It is 25 cells Layer.
- The cells in this layer have no nucleus.
- It is the part of the skin that is exfoliated
- Cells have thick envelope that resist chemicals.
- **Provides protection against chemical and pathogens**

5- Stratum lucidum

- It is found in thick skin below Stratum corneum.
- Between the granular layer and stratum corneum
- It is a lucid zone (an empty zone [not really empty], when you process a sample of skin with formalin this layer dissolves).

Merkel cells

- They are found in great numbers in touch sensitive sites like fingertips and lips.
- Usually around basement membrane area and around nerve endings.
- Cytoplasm has dense granules which contain large quantities of catecholamine.
- Their function is not well understood.
- Merkel cell carcinoma is aggressive malignant tumor.

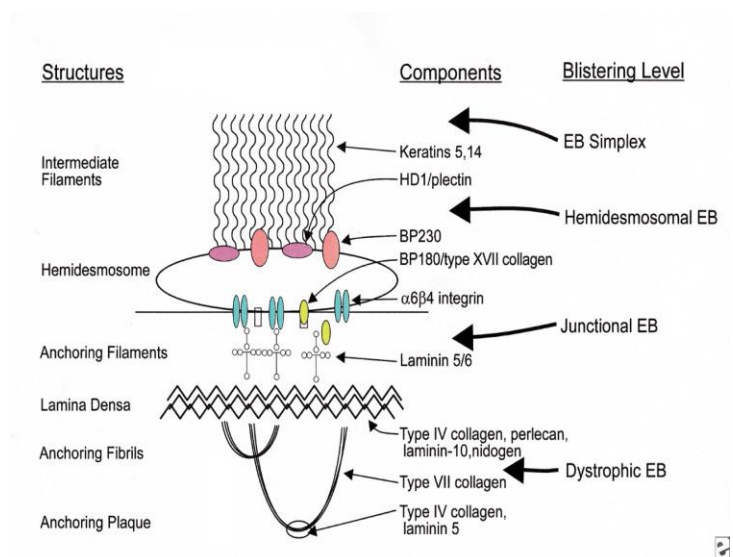
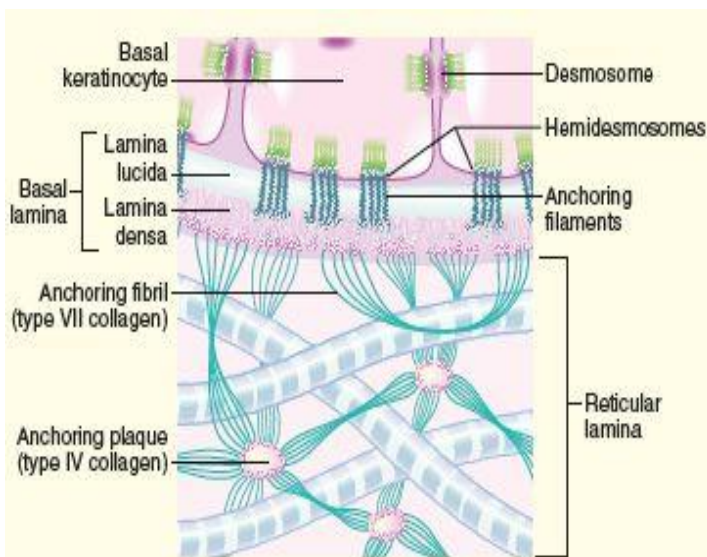


Basement membrane

- It is a pink undulated homogenous area between the epidermis and dermis.
- It consists of number of proteins. (Such as Laminin, which is attacked in some bullous diseases).
- Complex multi layered structure.
- Has 2 layers, lamina lucida and lamina densa.
- Keratinocytes attach to basement membrane via hemidesmosomes. (Desmosomes attaches cell to cell but here there is no cell in front of it so we have a hemidesmosome {half})
- Anchoring filaments connects lamina lucida to lamina densa.
- Anchoring fibrils connects lamina densa to papillary dermis.
- Many bullous disorders whether congenital or autoimmune have their pathology in this area.

Formed by:

- Thin clear amorphous space (Lamina Lucida)
- An electron dense area (lamina dense)



Dermis

- Upper layer is called papillary dermis, and the lower part is called reticular dermis.
- Mucopolysacchride gel held together by collagen and elastin fibrous matrix.
- The cells in the dermis include: fibroblasts (produce collagen), macrophages, dermal dendritic cells and mast cells (immune functions).
- Also has blood vessels, nerves, lymphatics and muscles.
- It provides nourishment to the epidermis and interact with it during wound repair. [\(Elements for wound repair come from the dermis\)](#)
- It gives the skin its strength, elasticity, and softness.

Consists of:

Collagen fibers: -

- **Provides strength**
- **Thin fibers in papillary dermis but thick and coarse in the reticular dermis.**

Elastic Fibers: -

- **Provides elasticity**
- **Protection against shearing forces.**

Ground substance: -

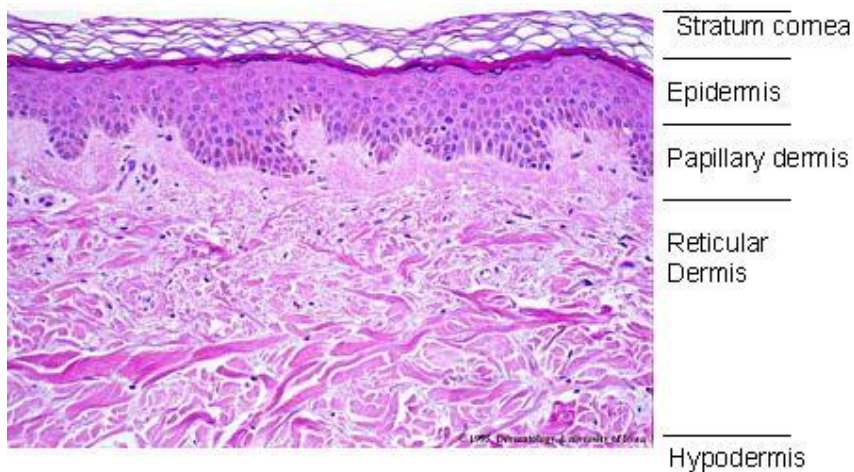
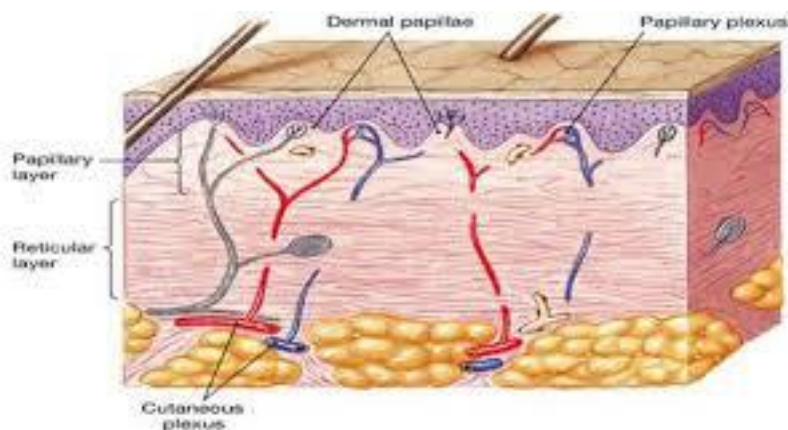
- **Binds water and maintain the skin turgor**
- **Absorbs a lot of water and makes the skin soft and smooth**
- **Made up of proteins and sugars (proteoglycans)**
- **As we age ground substance, collagen and elastic fibers decrease -> wrinkles and dry skin**

Blood vessels and Nerves: -

- To nourish the overlying epidermis also. “Fibroblasts produce the above elements”

Fibroblasts: -

- Produces collagen, elastic fibers and ground substance



Subcutaneous Tissue

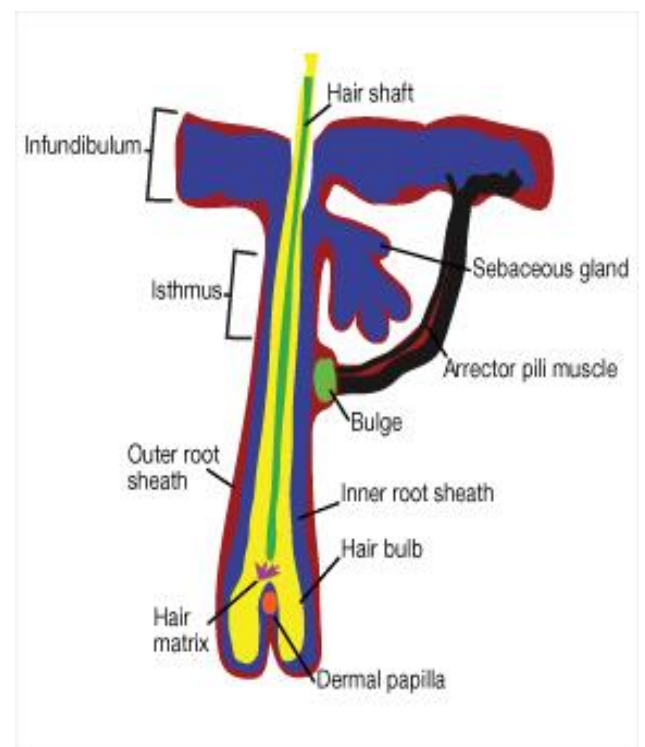
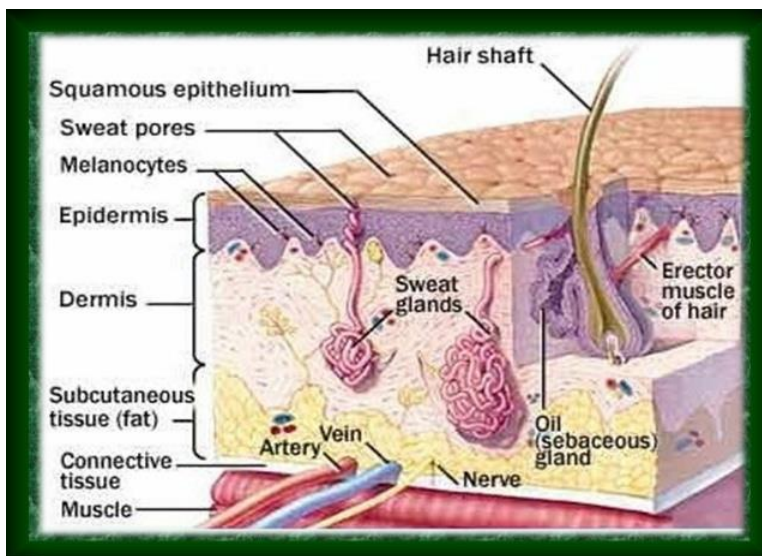
Subcutaneous Fat

- Composed of lipocytes.
- Lipocytes are either lobular or septal.
- Subcutaneous Fat helps in protection, insulation and and acts as a cushion.
- In some diseases where subcutaneous fat is lost, we feel the skin is hard.

Skin appendages

Include:

- **Pilosebaceous unit, Eccrine & Apocrine** sweat glands, and the **Nails**.
- Pilosebaceous unit include: hair follicle + sebaceous gland + arrector pili muscle.



Eccrine Sweat Glands: -

- Open freely on the SKIN
“ not attached to hair follicles “
- Under the influence of **CHOLINERGIC STIMULI**
- Present everywhere **EXCEPT:**
 - The vermilion border
 - Nail beds
 - Labia minore
 - Glans penis
- Most numerous on the sole of the foot and least abundant on the back.

Apocrine Sweat Glands: -

- Attached to hair follicles.
- Secrete viscous material that give musky odor when acted upon by bacteria.
- Their secretion through a process called decapitation secretion.
- They only become functional after puberty.
- Under **ADRENERGIC STIMULI.**
- Present **ONLY** in: -
 - The axillae
 - Anogenital area (groin)
 - Modified glands in the external ear canal
 - The eye lids (moll's glands) and areolae.

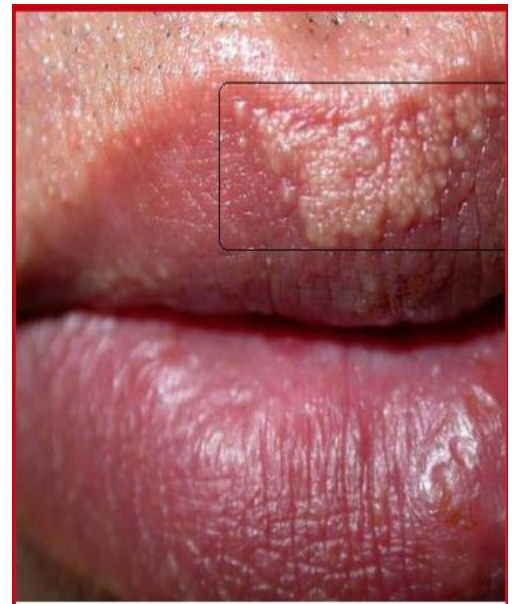
Periglandular acetylcholine is the major stimulant of sweat secretion.

Sebaceous glands: -

- Attached to hair follicles or open freely.
- Present in oily areas (Scalp, forehead, face, upper chest EXCEPT palms and soles).
- Called “**Montgomery tubercles**“ in AREOLA
- Called “**Meibomian glands**“ in EYELIDS
- Called “**fordyce spots**“ when present in the mucous membrane as Ectopic glands
- Sebaceous glands are hormone responsive (under the control of androgens) and become active at puberty.
- They secrete sebum (squalene, cholesterol esters, wax esters and triglycerides) to moisturize the skin through a process called holocrine secretion through hair follicle opening.

Sometimes present in abnormal location such as the lips or the mucus membrane on the inside (we don't have hair in that area so the presentation of sebaceous glands is abnormal)

They appear as yellow particles

**Hair follicles: -**

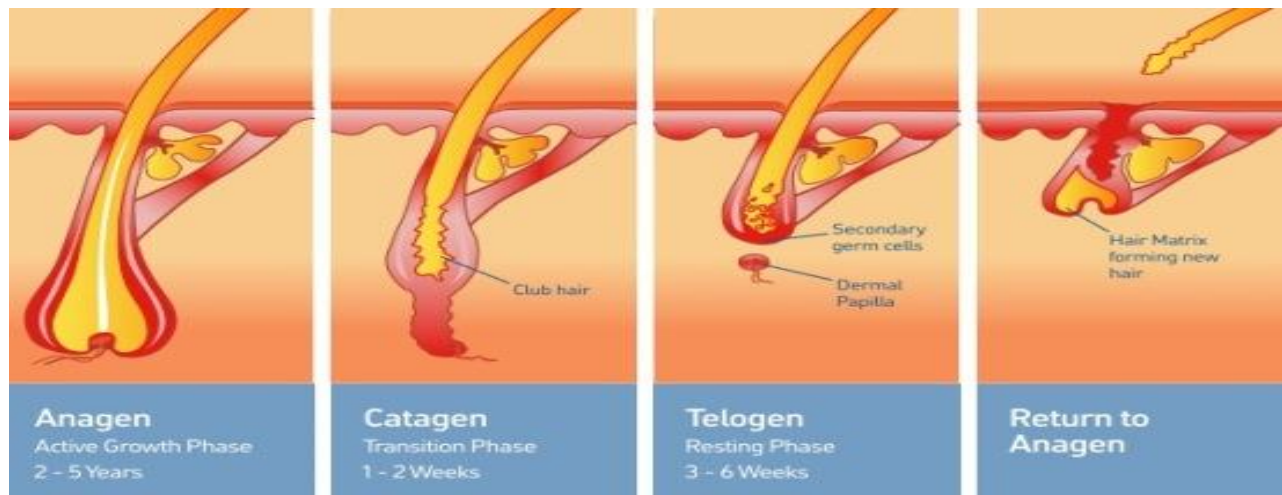
The hair follicle with its attached sebaceous gland form the **Pilosebaceous Unit**.

- Hair follicle has the hair shaft, hair bulb and the bulge.
- 3 types of hair: terminal coarse hair, vellus hair, and androgen dependent hair on beard, axilla and groin areas.

- Hair follicle cycle in anagen or growth phase 80%, catagen or resting phase and telogen or shedding phase both 20%.

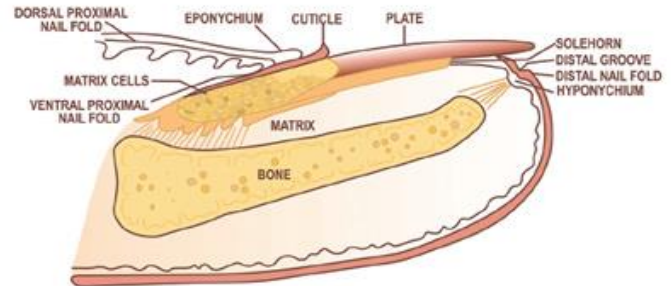
Phases of the hair follicle:

- Phase where the hair is dividing and elongating -> Anagen (growth phase 1cm/month, lasts for 2 years but in Indians it lasts for 6 years)
- Middle phase Catagen (lasts for 3 weeks)
- When the hair falls (dead hair follicle) -> Telogen (3 Months)
- Some people have something called Telogen effluvium where the period of Telogen exceeds 3 months



Nails: -

- Highly modified skin appendage.
- Consists of nail plate, proximal nail fold, nail matrix, nail bed, and hyponychium.
- Grows out of nail matrix.
- The matrix covers the mid-portion of the distal phalanx.
- The nail plate is formed of hard keratin.
- **THE LUNULA** is the visible part of the matrix.
- Proximal nail fold morphology can be altered in connective tissue disease
- Protected by the cuticle.
- Fingernails grow at 3 mm per month and need 6 months to be replaced after avulsion.
- Toenails grow at 1 mm per month and need 12-18 months to be replaced.
- Proximal nail fold morphology can be altered in connective tissue disease









Not that important just go over it, but know that it is affect in liver and kidney diseases, anemia, respiratory diseases, and other dermatological (Alopecia Areata, psoriasis, lichen planus)

NAIL DISORDERS

1- ABSENT PART: Anonychia congenita				
2- NAIL PITTING: Psoriasis				
3- CUTICLE INVASION: Lichen planus				
4- PIGMENTATION & RIDGING: Monilla				
5- DISTAL ONYCHOLYSIS: Tinea				
6- SPOON NAILS: Iron deficiency Anemia				
7- DISCOLORED & INVERTED EDGES: Ectodermal Dysplasia				
8- CLUBBING: Hypoxia, Malignancy or Toxins				
9- BITTEN NAILS (SHORT): Anxiety				
10- SPLINTER HAEMORRHAGE: Bac. Endocarditis				
11- YELLOW: Bronchiectasis, Lymphoma & Edema				
12- HALF & HALF: Hepatic Necrosis				
13- RIDGING: Rheumatoid arthritis				
14- LONGITUDNAL BROWN LINES: Addisons's, Breast cancer & Melanoma				
15- WHITE NAILS: Anemia				
16- RED NAILS: SLE, Polycythemia				
17- HORIZONTAL WHITE & PINK BANDS: Nephrotic Syndrome				
18- BRITTLE NAILS: Hypothyroidism				

Skin Types

TYPE I:	Pale white skin, blond/red hair	Always burns, does not tan
TYPE II	fair skin	burns easily
TYPE III	dark white skin	burns, then tans
TYPE IV	light brown skin	tans easily with minimum burns
TYPE V	medium brown skin	tans darkly with rarely burns
TYPE VI	dark brown skin	tans darkly, never burns

 <p>TYPE 1: Highly sensitive, always burns, never tans. <i>Example: Red hair with freckles</i></p>	 <p>TYPE 2: Very sun sensitive, burns easily, tans minimally. <i>Example: Fair skinned, fair haired Caucasians</i></p>	 <p>TYPE 3: Sun sensitive skin, sometimes burns, slowly tans to light brown. <i>Example: Darker Caucasians</i></p>
 <p>TYPE 4: Minimally sun sensitive, burns minimally, always tans to moderate brown. <i>Example: Mediterranean type Caucasians</i></p>	 <p>TYPE 5: Sun insensitive skin, rarely burns, tans well. <i>Example: Some Hispanics, some Blacks</i></p>	 <p>TYPE 6: Sun insensitive, never burns, deeply pigmented. <i>Example: Darker Blacks</i></p>

Classification of Dermatological Disorders

Inflammatory:

- Infectious: viral, bacterial, fungal, protozoal, and infestation.
- Non-infectious: eczematous, papulosquamous, urticaria and erythema, bullous diseases, autoimmune diseases.


Neoplastic:

- Benign, malignant.

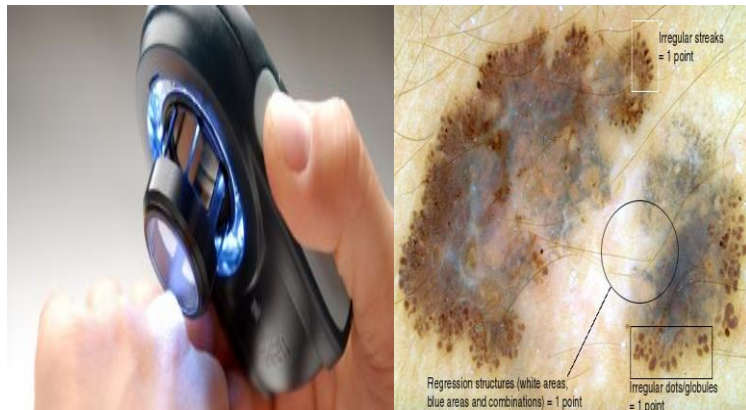
Other:

- Metabolic, toxic, genodermatosis.

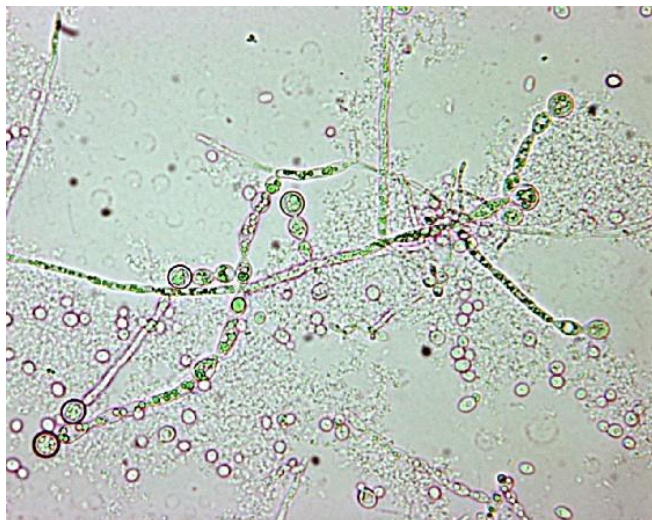Investigations



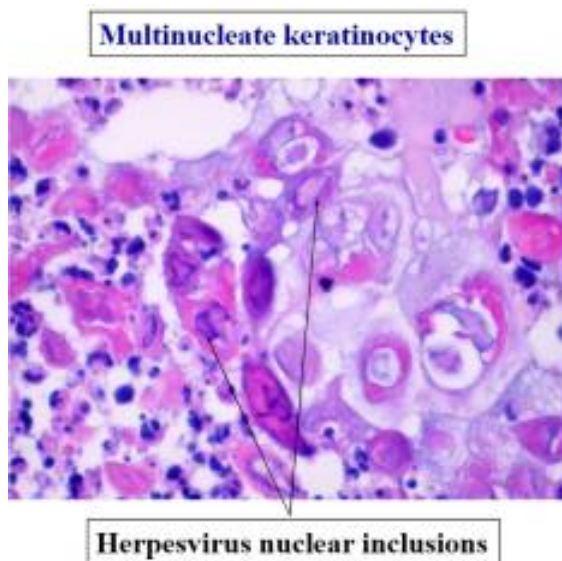
Wood's lamp: - to examine the skin color and some florescent organisms



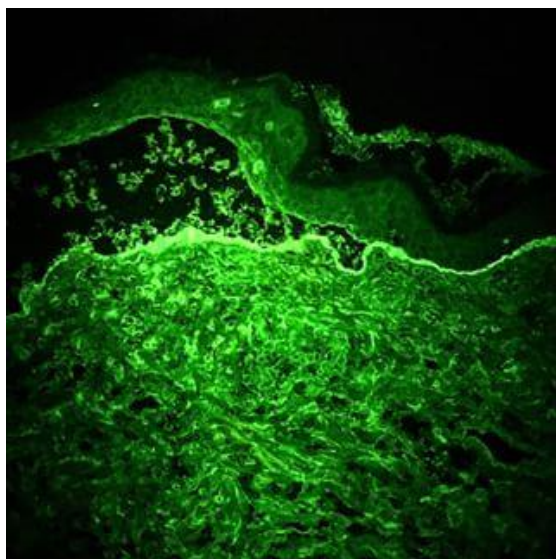
Dermoscopy: - for benign and malignant lesions.



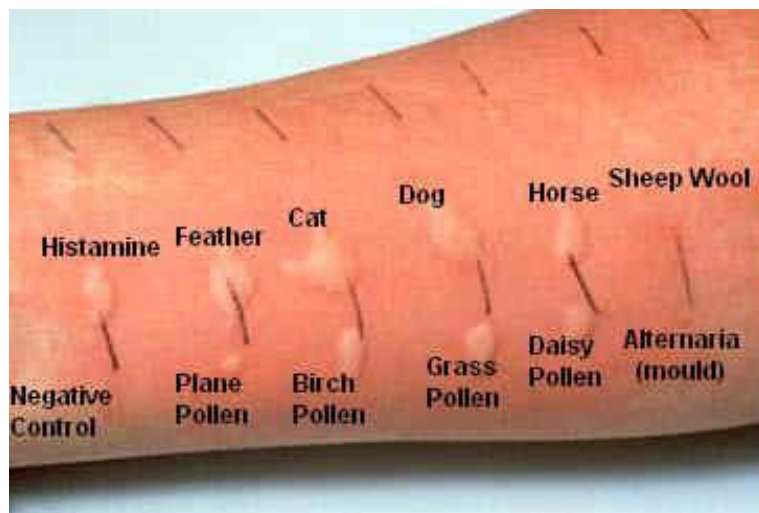
KOH for fungal infections.



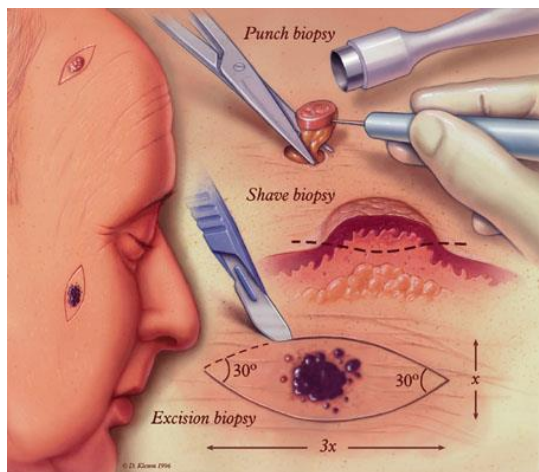
Tzanck smear for herpes.



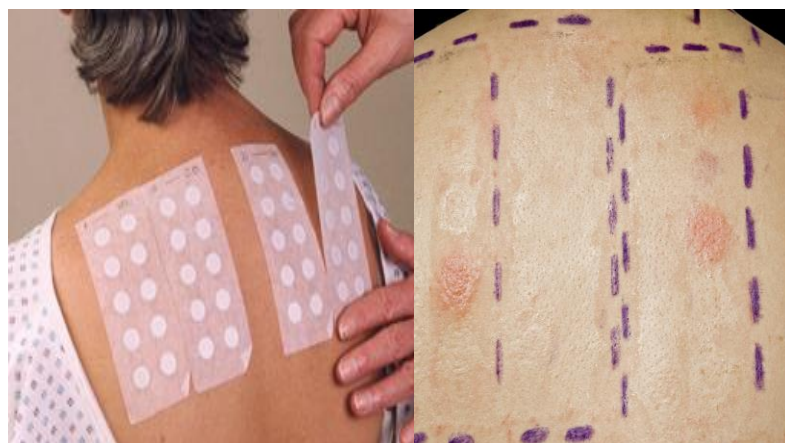Direct Immunofluorescence for bullous



Prick test for common allergens type 1 hypersensitivity.



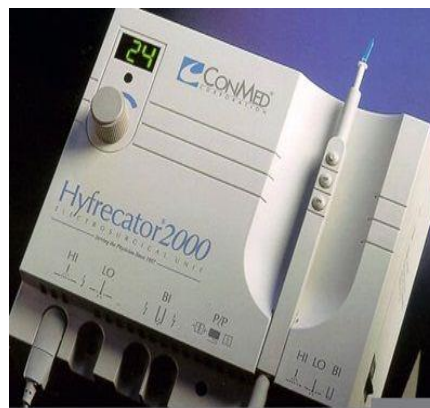Skin biopsy: shave, punch, incisional, excisional or curettage.



Patch testing for allergic contact dermatitis type 4 hypersensitivity.

Treatment Modalities

- Topical and systemic therapies.
- Cryotherapy.
- Electrocautery.
- Laser surgery.
- Cutaneous and nail surgery.
- Phototherapy.
- Immunomodulation for warts and alopecia areata.
- Cosmetic surgery and hair transplant.



Summary

The functions of the skin are briefly summarized in the following table.

Skin structure	Function
Keratinocytes – stratum corneum	Prevents the skin against external environment. Barrier for shearing forces acting on the skin Prevents the absorption of water from outside, and loss of water and electrolytes from the skin
Melanocytes	Protects against the damage by ultraviolet light
Langerhans cells	Acts as the first line of immunological defense for the skin
Collagen tissue	Prevents the body against mechanical forces
Elastic tissue	Provides the elastic recoil to the skin
Ground substance (glucosaminoglycans)	Remarkable capacity to absorb water, gives fullness to the skin Protects the body against compressive forces
Nerves	Provide sensations to and from the skin
Blood vessels	Nutritional and help in maintaining body temperature
Sweat glands	Helps in maintaining body temperature, in keeping the skin moist, and excretion of waste products such as urea
Sebaceous glands	Moisturizes the hair and skin, fungistatic and bacteriostatic
Apocrine glands	Responsible for body odor
Nails	Helps in fine movements such as grasping of objects
Hair	Improves body image, scalp hair protects against ultraviolet damage
Subcutaneous fat	Insulates the body from cold, reserve source of food, and cushions the body from blunt trauma

Questions

1. The number of layer in epidermis:

- A. 2.
- B. 3.
- C. 4.
- D. 6.
- E. 8.

2. Which of the epidermal cell layers provides protection against chemical and pathogens?

- A. Stratum corneum.
- B. Stratum granulosum
- C. Stratum spinosum.
- D. Stratum basale.

3. The main cell type in the epidermis is:

- A. Keratinocytes.
- B. Melanocytes.
- C. Langerhans cells.
- D. A and B

4. Thick skin differs from thin skin in:

- A. No different.
- B. Thick spinous layer.
- C. Thick basal layer.
- D. Thick stratum corneum

ANS :

1-C

2-A

3-A

4-D

GOOD LUCK