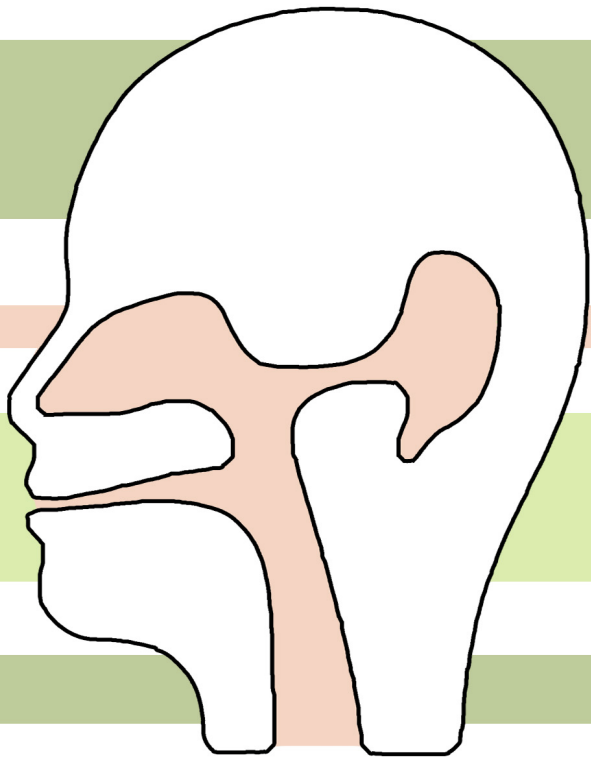

EAR, NOSE AND THROAT

(19) Trauma and Foreign Body I

Leader: Maha Allhaidan

Done by: Dana aldubaib

Revised by: Ghadah ALSuhaibani

Doctor's note **Team's note** Not important **Important** **431 teamwork**

(431 teamwork do not highlight it in yellow, but put it in a yellow “box”)

Objectives:

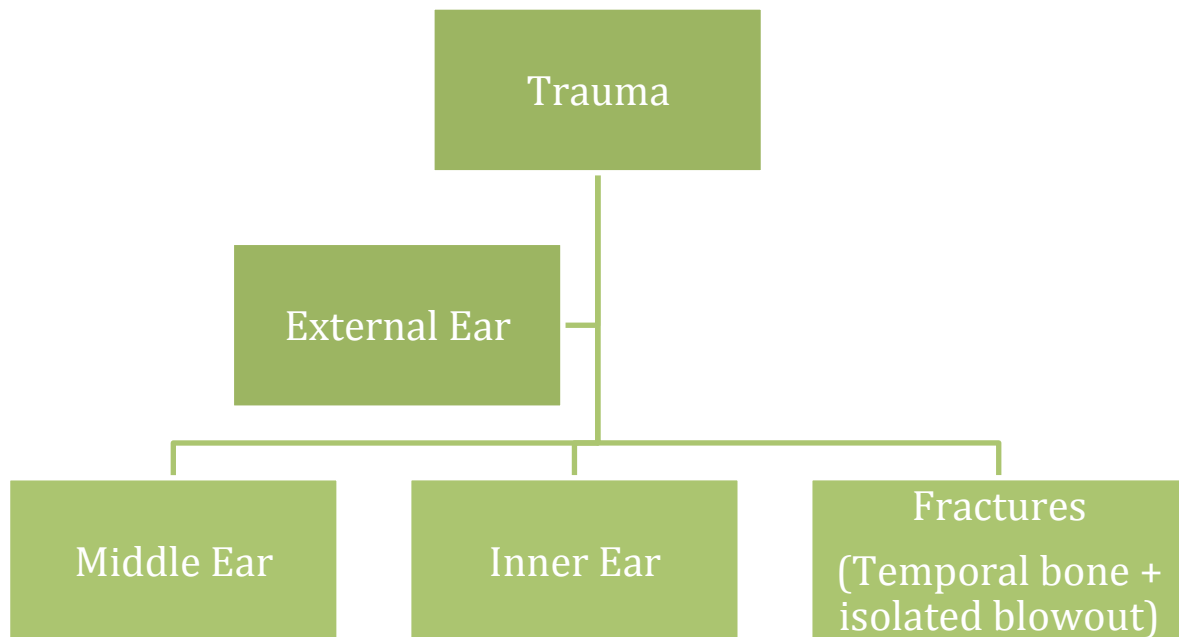
Team part I will talk about:

- Ear Trauma: inner, middle, & external
- Temporal Bone Fracture

Team part II will talk about:

- Facial Trauma
- Nasal Trauma
- Laryngeal Trauma
- Foreign Bodies
- Esophageal Perforation

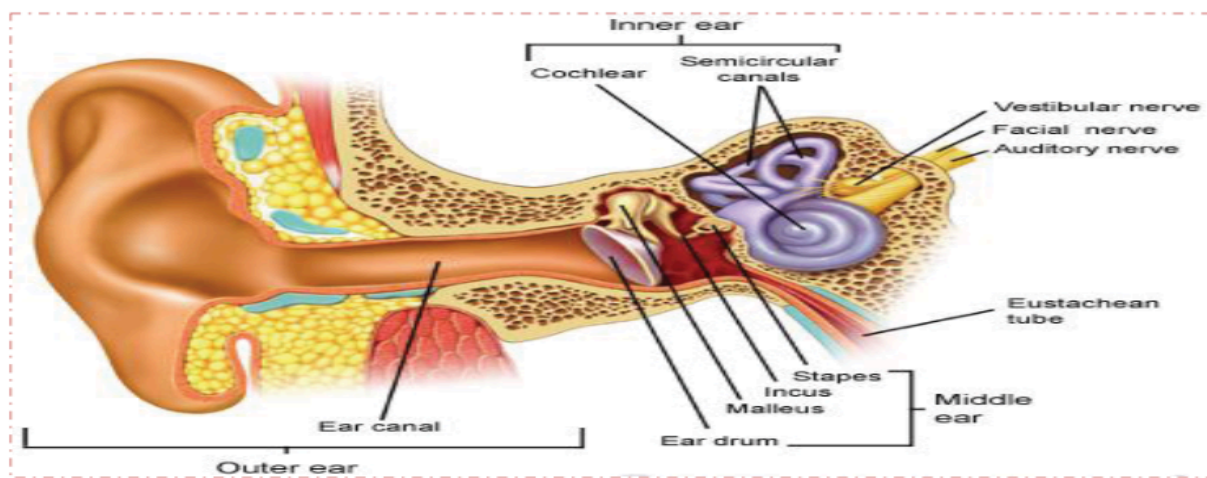
* The doctor did not provide the slides, so we took 430 teamwork and added the doctor notes.
(Any text underlined by red is important)
Special thanks for 430



Ear Trauma

****EAR TRAUMA**

Ear trauma can be divided to external(auricular), middle, or inner ear trauma. It could be a laceration, or avulsion (completely cut off). It could also be a burn, or radiation injury, or hematoma.



****EXTERNAL EAR:** (Auricle injuries)

1- Hematoma

Cartilage injuries in general cause hematoma. Very common, we see 2-3 cases per week. The child fell, adults were in a fight, ear got hit. Why hematoma is different in ear than in thigh? Cartilage.

Cartilage in general does not have blood vessels; therefore it takes its nutrition either from periosteum (Bone) or perichondrium (CT). If there hematoma then the cartilage will get separated from these structure and will not get nutrition.

If left untreated → **Necrosis** of the cartilage → permanent deformity (Cauliflower deformity) Therefore it needs to be diagnosed early.

Treatment: Drain it & apply pressure dressing (To reattach it together with the periosteum). Excise fibrous tissue. incision and drainage + AB

2-Avulsion:

Ear or part of ear is cut off.

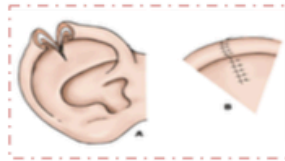
If patient presents within 3-4 hours to the ER we can re-implant it and re-vascularize it. **microvascular anastomosis**

If the patient presents late the surgeon can install a plastic ear.

3-Laceration:

From glass, knives, bite injuries

Treatment: Sutures



4-Cancer:

Ear is affected by cancer SCC (Squamous cell carcinoma) or BCC (Basal cell carcinoma)

5-Frostbite:

In cold countries the cartilage gets necrosis.

6-Burns

7-Split or Cauliflower Injuries From Ear Piercings or Earrings.

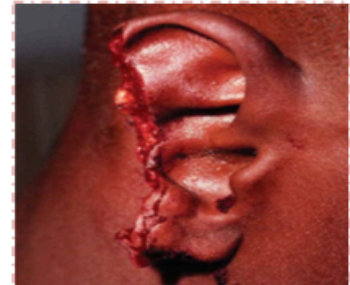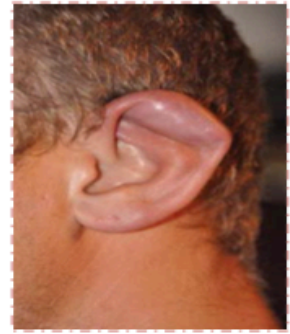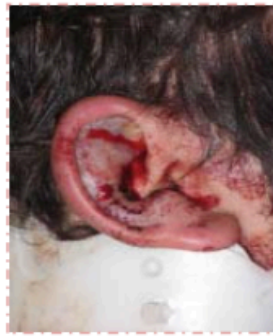-The lobule (where our ear pierced by our parents) is made of soft tissue and has no cartilage. It can get split in half.(if earring was pulled)

Treatment: Suture it in the clinic.

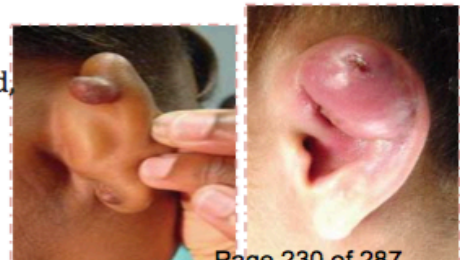-If the piercing is higher in the ear, in the cartilage it can get infected. Cause a deformity, hematoma, abscess and even keloid in dark skinned people. **non sterile can be Risk factor for keloid**

Treatment: Drain if abscess or hematoma.

Local steroids is the treatment for Keloid as it returns if removed



Copyright © 2010 by The McGraw-Hill Companies, Inc. All rights reserved.



Page 230 of 287

****MIDDLE EAR:**

. Trauma can happen to the tympanic membrane, ossicles, inner ear bone & structure (labyrinth), Incudostapedial joint...

1- Can Get Traumatic Perforation:

- Blast injuries. From pressure or small body inside the ear. Can also affect inner ear. انفجارات
- Insertion of foreign objects in the ear. By cleaning the ear and accidentally perforating it. Example ear cotton buds.
- Slap
- Skull base fracture (also affects facial nerve).

How to differentiate traumatic perforation of tympanic membrane from chronic infection perforation?
Onset from history, pain, hearing loss, and vertigo (all those are present in acute, possibly discharge in chronic).

Important for medico-legal cases.

Acute → the membrane will be irregular, and red (bleeding), and there will be blood collected in external canal. No healing process yet

Chronic → the membrane will be epithelialized (epithelium re-grow) with more rounded edges.

****Incudostapedial joint** is the most commonly affected area by trauma, as it is a small joint with very small blood vessels. Most affected by trauma patient comes with hearing loss.

Ossicular trauma alone has more hearing loss than tympanic membrane trauma alone. If combined more hearing loss.

Diagnosis by audiogram > conductive hearing loss > incudostapedial joint prosthesis

Treatment:

If small perforation → it can heal by itself in 6-8 months. But the patient must avoid infection because it prevents re-growth.

If large → requires Graft Tympanoplasty. If the ossicles are involved do an ossiculoplasty.

How to confirm if the ossicles are involved? Must do an audiogram
Displacement of the ossicles will cause conductive hearing loss.
Forcible displacement of the stapes into the inner ear can cause sensory neural hearing loss that can't be corrected even if the ossicles are put back into their proper position.

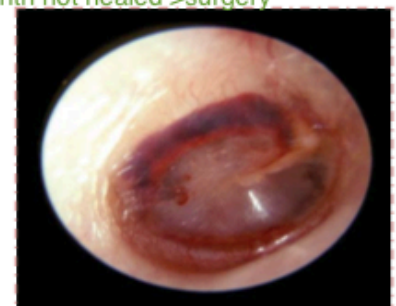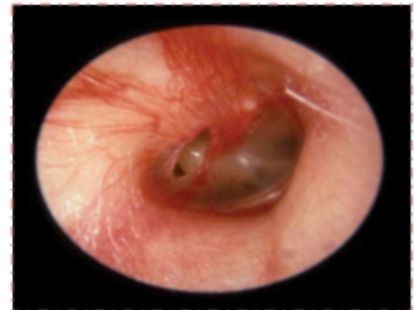90% will heal spontaneous, prevent water to enter, no swimming if after 6-8 month not healed > surgery

2-Hemotympanum: Behind tympanic membrane

When a blow, fracture, or blast is not severe enough to cause perforation but causes hematoma. A child inserted a pencil in his ear.

Symptoms: Pain. Hearing is affected (decreased).

Treatment: Do nothing it will resolve by itself in 1-2 weeks.



****Incudostapedial joint or articulatio incudostapedia** is a small synovial joint between the incus (anvil) and the stapes (stirrup). The joint's function is to transfer vibrations between the ossicles in the middle ear

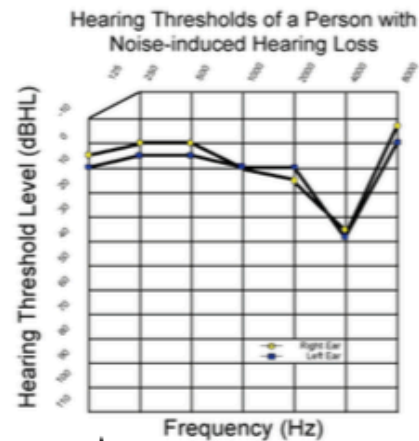
****INNER EAR:**

NIHL, Acoustic trauma, and Barotrauma.

1-NIHL(Noise Induced Hearing Loss): 1 of the commonest occupational induced disabilities

Noise induced Sensory neural hearing loss NISNHL

When hearing loss has occurred because of exposure to noise, the audiogram will show that the individual has lost the most hearing at the 4,000-Hertz frequency. This hearing loss will appear as a notch, or dip, in the audiogram at 4,000 Hertz frequency, as shown on the graph below. In addition to the occupational and personal history, this is how the doctor can determine from the audiogram that your hearing loss is related to noise.



frequency	exposure
90 db	8 hours
95 db	4 hours
100 db	2 hours
105 db	1 hour

- People who work in airports or in ambulances ^{في المطارات ، مصانع} are most affected if not wearing protective gear; however they do not notice it at first. Tinnitus is the first **warning sign**.

Not all people that work in areas with high frequencies suffer from NIHL; different people have different susceptibilities.

Some people are affected from the first encounter with high frequency Noise while others need recurrent exposure for longer periods.

It is not really dependent on age, race, or gender.

NIHL happens when a person is exposed to more than 90 db for an average of 8 hours.

Prevention: People who work at noisy places such as airports or ambulances should wear ear protective gear. Those who wear headphones with loud voices can also get it, as well as those who frequently attend bars, discos and weddings playing loud music.

Important: To have early identification either so that the company will compensate the worker or to change his place of work so he wouldn't be harmed if he couldn't hear the high frequencies.

2-Barotrauma ^{injury caused by a change in air pressure, affecting typically the ear or the lung.} is a physical damage to the body tissues caused by a significant ambient pressure change. Examples: such as when a scuba diver, a free-diver or in passengers of an old non pressurized airplane as well as in military pilots and pilots or passengers with T Q S H A T o o d q A d r o h q ` s n q x A q ` b s A h n e d b s h n n).

Causes: Injury to the tympanic membrane TM and middle ear ME, flying or underwater diving, ETD (Eustachian tube dysfunction) may predispose.

Signs & Symptoms: Ear pain, hearing loss, hyperemia and possible TM perforation, edema and ecchymosis of the ME membrane, conductive hearing loss and/or transudative middle ear perfusion.

The Eustachian Tube together with the external canal equalize the pressure in the 2 sides of tympanic membrane (middle & external ear pressure).

If someone's eustachian tube is not working he/she will have -ve pressure in the middle ear → **sucking of blood from blood vessels** to tympanic membrane or **accumulation** (Mostly) of blood or fluid in the middle ear. (hemotympanum)

Seen always in people with cold who get in airplane after it lands they have hearing loss, pain.

What other Symptoms? Vertigo and conductive hearing loss when doing audiogram (due to fluid). In extreme cases diving can get hemotympanum (accumulation of blood in the middle ear).

Page 232 of 287

Treatment: Important for airplane pilots with URTI to have it treated prior to flying the airplane. Give them Nasal decongestant before they fly so their ET will open. (Aviation medicine) atropin

If come afterward with the hearing loss and pain? Give decongestant nasal spray; most usually recover in 2 weeks.

Temporal Bone Fracture

Temporal bone area contains the Middle and Inner Ear.

Fractures can happen either from a hit to frontal, occipital or from a side injury.

Etiology:

-Blunt closed head trauma: Most are from RTA(road traffic accident) Can be due to a child falling, from a Motorcycle accident, etc... (blunt is the most Common)

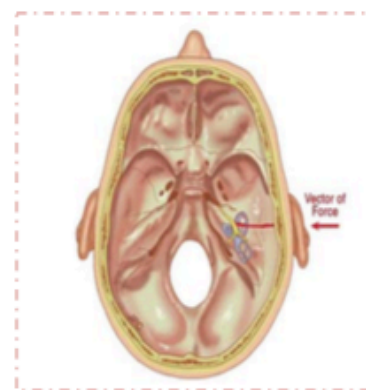
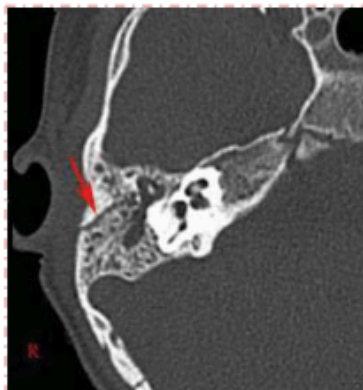
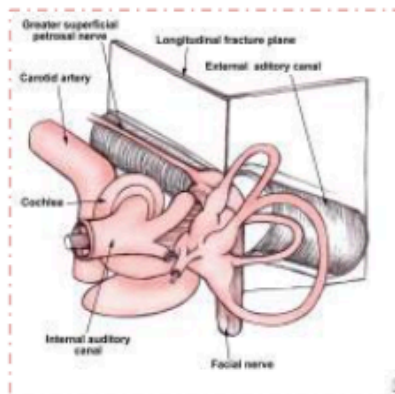
-Penetrating injuries. From glass, knives, blast, fights, laceration

Can affect facial nerve, semicircular canal (vestibule), ossicles.

Temporal bone axis is not straight

Blunt trauma: 5% of people who have head trauma will have temporal bone fracture. These are classified with respect to the axis of the Petrous Ridge and include:

- Longitudinal 70-80% of breaks but causes less damage
- Transverse 10-20% worse diagnosis. More facial nerve injury, as well as semicircular canal injury. However Less severe than mixed.
- Mixed 10% worst presentation and prognosis.



* longitudinal : along facial nerve preserve function of facial nerve , better prognosis

* Transverse : - Facial nerve paralysis ,more damage

Facial paralysis commonly occurs after transverse fractures of the temporal bone (50%). However it can also occur after longitudinal fractures (25%).

Inner Ear: the Vestibulocochlear Nerve (CN 8) & Vestibules (Semicircular canal) pass through it. Those are less involved in longitudinal fracture, and more with transverse.

(Therefore vertigo happens more with transverse)

Middle Ear has the facial nerve passing through it. It is more involved in transverse fractures, and less in longitudinal.

How to diagnose them?

If the patient comes with multisystemic trauma:

History: Do thorough evaluation. The mechanism and details of the traumatic forces involved.
Physical examination: ABCDE. Then after the patient is hemodynamically stable and the acute injuries are recognized and dealt with he/she should be re-evaluated again for other less significant injuries.
CT Scanning: high resolution CT scan of the temporal bone. The integrity of the ossicular chain may also be reevaluated with an optimal CT scan.
Usually in these cases the diagnosis of temporal bone trauma, facial nerve palsy and other internal injuries can be missed or diagnosed late especially in severe RTAs.

GOLD STANDARD for temporal bone fracture: high resolution **CT scan**.

Skull base fracture = temporal bone fracture.

Complications of temporal bone fracture: IMP

- Facial paralysis.
- Hearing loss (check if Tympanic membrane is punctured or cut.)
- CSF leakage from ear as discharge
- Tinnitis
- Carotid injury
- Vertigo

How to treat it? We treat it based on whether it is simple or complex.
Complex needs surgery with Neurosurgeon. If facial nerve is trapped release it.

Isolated Blowout Fracture

Fracture of orbital bony floor

Symptoms:

Enophthalmos, diplopia, limitation of eye movement.

Dx:

radiographs (tear drop), tomograms, and ophthalmology exam

Rx:

antral cavity must be explored.

Summary

*Ear trauma has 3 possible sites for injuries:

1- External ear: hematoma (Rx: drain+ pressure dressing+ excise fibrous tissue), laceration (Rx: sutures), avulsion (if present early 3-4hrs we can re-implant), cancer BCC/SCCC, burn, frostbit (cartilage necrosis due cold), split or cauliflower (Rx: sutures, if hematoma present : drain first).

2- Middle ear: traumatic perforation (acute perforation: irreg. membrane+ red with fresh bleeding, chronic perforation: epithelized memb. With round edges), incudostapedial joint injury is commonly affected area (Rx: if small perforation it's a self-limited with spontaneous healing in 8 mns, if large perforation needs tympanoplasty). Hemotympanum which is blood behind TM (Rx: spontaneous healing without intervention)

3-Internal ear: NIHL when exposed to 90db for more than 8 hrs, it's a SNHL, in audiogram detected at 4000 Hz as a notch, tinnitus is the first warning sign. Barotrauma which is an injury due significant pressure difference at external and middle ear as in scuba diving+ airplanes (Rx: decongestant nasal spray).

* Temporal bone fracture: = Skull base fracture

- Etiology: blunt trauma, mostly RTA, has 3 types: longitudinal fracture 80%, transverse 10%, mixed 10%.

- Dx: gold standard is HR CT scan,

- Complication: hearing loss, facial nerve paralysis, CCSF leak, tinnitus, vertigo, carotid injury.

-Rx: depends on type, collaborate with neurosurgeon, if facial n. involved release it.

* Isolated blowout Fracture: fracture of orbital bony floor

Symptoms: Enophthalmos, Diplopia, Limitation of eye movement.

Rx: antral cavity exploration.

For mistakes or feedback

ENTteam432@gmail.com