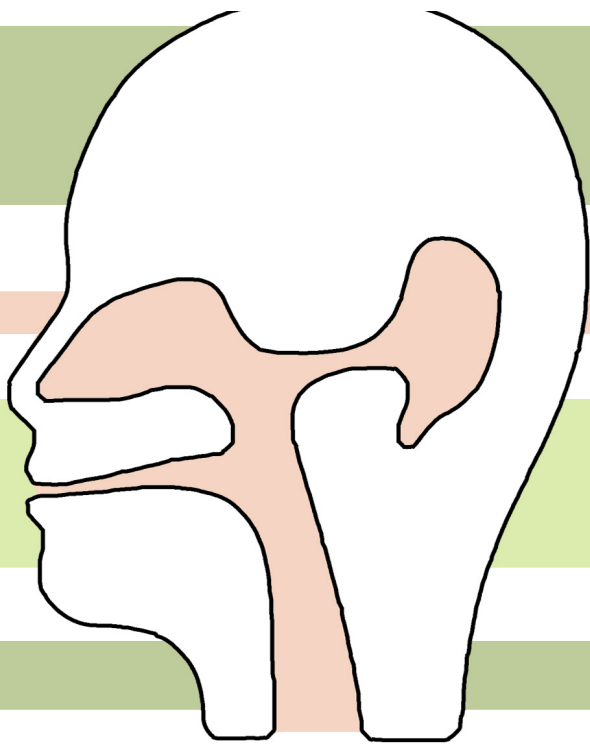



# EAR, NOSE AND THROAT

**(8&9&10) Head and Neck I & II & III**

**Leader: Maha Allhaidan**

**Done by: Ghada Alsuhaibani & Roqaih Aldueb &**

**Norah Alneghemish**

**Revised by: Shahad Alawwad & Ghaida Alabidi**

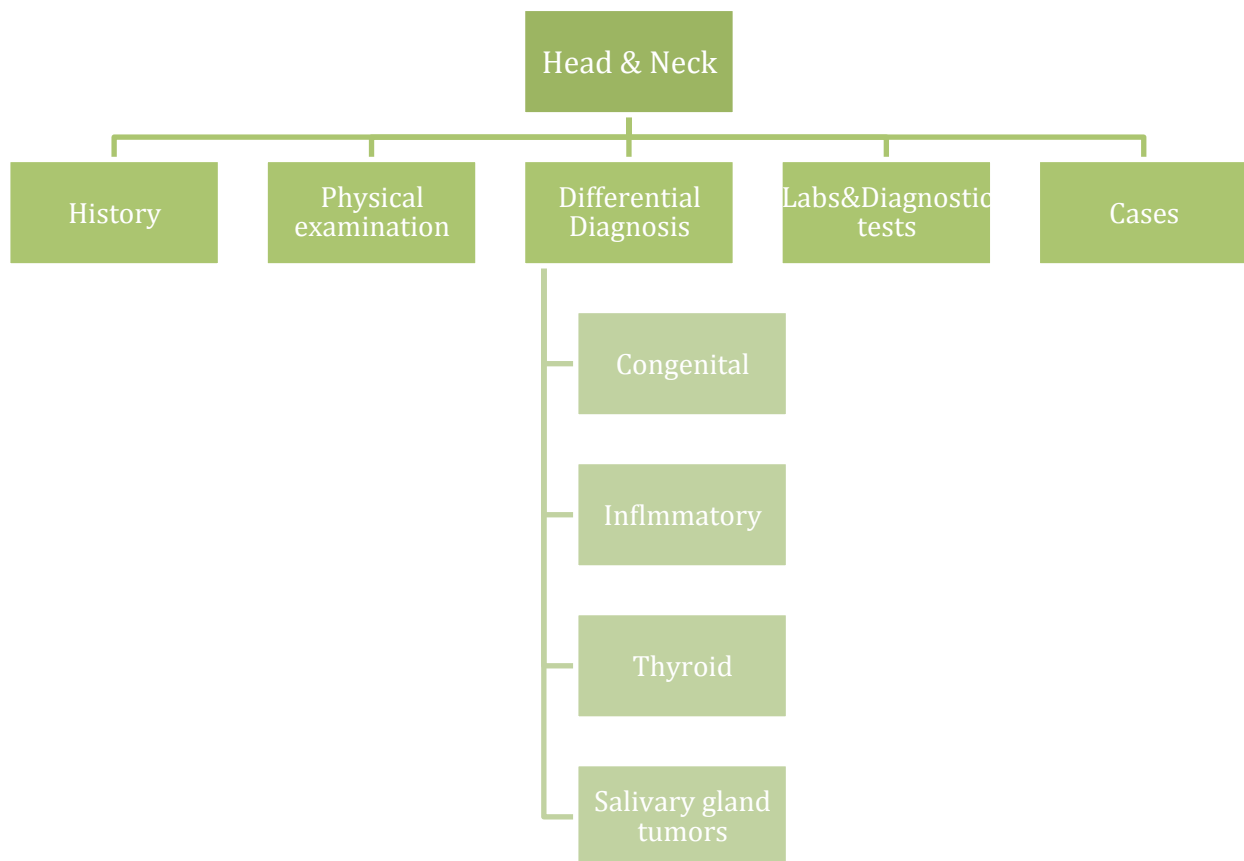
**Doctor's note**   **Team's note**   Not important   **Important**   **431 teamwork**

(431 teamwork do not highlight it in yellow, but put it in a yellow “box”)

## Objectives:

- 1- Neck-masses introduction: Anatomy, Diagnosis, DDx, Examples.
- 2- Thyroid Anatomy, nodule evaluation, cancer, surgery & complication.

Focus on thyroid disease and salivary glands



# History

**1. Duration and growth rate of mass:** malignant masses grow faster!

**Rule of 7's:** A mass that has been around:

7 days is **inflammatory**,

7 months is **malignant**,

7 years is **congenital and benign**

**2. Age Group:** Pediatric patients (up to 15) generally have inflammatory related neck masses and developmental more than neoplastic masses. Consider neoplasia first in older patients.

**3. Location:** **Especially important when considering congenital and developmental masses** because they occur in consistent locations. Spread of head and neck carcinoma is similar to an inflammatory disease and follows orderly lymphatic spread.

**4. Inflammatory Hx:** Ask about recent fever, pain and tenderness. Any recent illness, URTI, TB, sarcoidosis, fungal infection, dental problem, sinusitis or otitis. Thyroiditis can occur post URTI.

**5. Malignant Hx:** Ask about any previous head & neck malignancy. Also,

- Night Sweats
- Sun Exposure
- **Smoking**
- Alcohol (a consideration for Squamous Cell Carcinoma)
- Exposure to Radiation (Thyroid and Parathyroid Cancers) for medical/military workers
- Otalgia in elderly with normal ear exam suggestive of carcinoma
- Other Sx:
  - Nasal Obstruction,
  - Bleeding,
  - Otalgia,
  - Odynophagia, Dysphagia,
  - Hoarseness,
  - Sore Throat of > 3 Weeks,
  - Non Healing Ulcers,
  - Hemoptysis,
  - Weight Loss,
  - Cervical Adenopathy,
  - Hard Fixed Mass.
  - Hearing loss with blocked ear in adult and elderly – look for nasopharyngeal carcinoma



**Inflammatory vs. Neoplastic Neck Masses**

	Inflammatory	Neoplastic
<b>History</b>		
Painful	Y	N
H&N infection	Y	N
Fever	Y	N
Weight loss	N	Y
CA risk factors	N	Y
Age	Younger	Older
<b>Physical</b>		
Tender	Y	N
Rubbery	Y	Occ.
Rock hard	N	Y
Mobile	Y	± fixed

**6. Trauma:** Any recent history of trauma to the head or neck? **In neonate ask about Forceps delivery** (may cause hematoma mass in anterior neck or within the sternocleidomastoid muscle).

**7. Referred Pain:** Esp. to the ear because of referred pain via CN V, IX or XI can indicate an inflammatory or neoplastic process in any area in the upper aerodigestive tract mainly the oropharynx and hypopharynx.

**8. Speech Difficulties:** Voice Changes? Vocal cord paralysis suggests a thyroid carcinoma (b/c of involvement of recurrent laryngeal nerve) or primary laryngeal lesion

**9. Family Hx:** Any history of head or neck malignancies? Medullary Thyroid Cancer runs in families. Consider MEN (rare).

**10. Past Medical History:** Diabetes, HIV, Malignancies? Cervical lymph node hyperplasia very common in HIV. Smoker? Alcohol?

**11. Past Surgical History**

**12. Nutritional Status:** Any history of iodine deficiency? Suggested by residence in a geographic area of endemic goiter.

**13. Hypo/Hyper-Thyroidism Sx:**

<b>Hypothyroid Sx</b>	<b>Hyperthyroid Sx</b>
Complaints of fatigue, cold intolerance, weakness, lethargy, wt gain, constipation, dry & coarse skin, thin hair	Complaints of unexplained nervousness and sweating, heat intolerance, weight loss, palpitations, an enlarging neck mass, and ocular prominence (exophthalmos).

**14. Hyperparathyroidism Sx:**

"Bones, Stones, Abdominal Groans, Psychic Moans and Fatigue Overtones."

**Bones:** aches and arthralgias result from fractures and structural changes.

**Stones:** because of hypercalcemia.

**Abdominal Groans:** also b/c of hypercalcemia. Dehydration and constipation. Pancreatitis. PUD may worsen.

**Psychic Moans:** hypercalcemia can cause anorexia, N/V, thirst and polydipsia, mood swings, psychosis.

**Fatigue:** lassitude and muscular fatigability.

**Risk Factors:**

- Smoking (+ شيشم use in Southern areas which is a chewable tobacco therefore approximately 90% of oral CA in Saudi)
- Previous burn or scar
- Family history
- Sun exposure
- Immune deficiency
- Wood dust exposure
- History of other cancer
- Alcohol

# Physical Examination

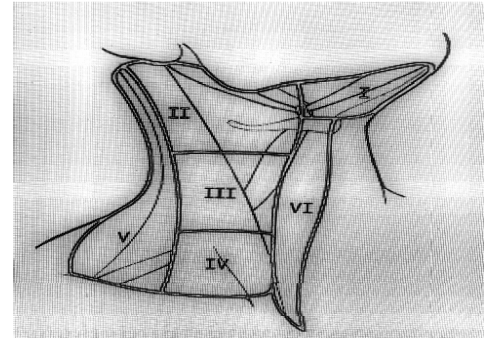
1. **Survey:** Inspect neck, noting its symmetry, any masses or scars. Look for enlargement of parotid or submandibular glands, and note any visible lymph nodes

2. **Lymph nodes:** Palpate the lymph nodes;

- Describe the location by lymphatic levels ( I, II , III , IV, V, VI) or by triangle
- Enlargement of a supraclavicular node, especially on the left, suggests possible metastasis from a thoracic or an abdominal malignancy.
- Tender nodes may suggest inflammation; **hard/fixed nodes suggest malignancy.**

## Lymphatic levels:

- 1- **Level one** - submental and submandibular triangles, : from hyoid bone to mandible.
- 2- **Level two** - between base of skull and hyoid bone.
- 3- **Level three** - between hyoid bone and omohyoid muscle.
- 4- **Level four** - between omohyoid muscle and clavicle.
- 5- **Level five** - posterior triangle lymph node.
- 6- **Level six** - tracheal and paratracheal lymph node. **(Central area)**



3. **Trachea and thyroid gland:** Inspect the trachea for any deviation from its midline position, and then feel for deviation. **Masses in the neck may push the trachea to one side.** Inspect the neck for the thyroid gland, then palpate. **Notes: size and shape of thyroid gland tells very little about thyroid function.**

4. **Full and details examination of the head and neck and the upper aerodigestive tract**

I-oral cavity & oropharynx	ii- Nasal cavity	iii- Ear	iv- Scalp	v- Cranial nerves
1- Make note of any trismus 2- notice any ulcer, leukoplakia- whit none removable discoloration- 3- asymmtry of tensiles 4- fallen or lose teeth 5- don't forget to eXamine the floor of mouth and the gingivobuccal sulcus 6- bimanual palpation is a must	1- notice any bleeding, ulcers or masses 2- look for nasal blockage 3- any nasal deformity 4- don't forget the eye	1- look for masses or lesions in the pinna or the canal 2- look for middle ear effusion- may suggest nasopharyngeal carcinoma	1- don't forget to eXamine the scalp for any lesions – look for BCC, or SCCA and chronic infection	1- look for any facial paraesthesia or numbness and any facial weakness 2- look for all the other cranial nerves

Oral cavity, Buccal, tongue, floor of mouth, lips, hard palate, gingival area... **Also Nasopharynx examination is very IMP** because it is the commonest site and type of cancer in Saudia Arabia. No excuse for not examining it when dealing with a neck mass because neck mass (or decreased hearing because of middle ear effusion) is the commonest presentations for nasopharyngeal CA)

**Case:** a patient with a neck mass and decreased hearing in left ear, your next step? **Nasopharyngeal examination with fiberoptic scope (or biopsy).**

# Labs and Diagnostic Tests

1. **Labs** to be Considered as dictated by the DDX: CBC (infecton vs. lymphoma), TB test, TFT.

## 2. **Radiographs:**

- **US:** Pulsatile neck masses require US prior to FNA. Helps differentiate solid masses from cystic masses (especially useful for congenital and developmental cysts). Would help you distinguish a congenital branchial or thyroglossal cyst from solid lymph nodes, neurogenic tumors or ectopic thyroid tissue. U/S pretty accurate (90-95% differentiation success). Also helps assess size of a nodule and helps identify impalpable nodules. It is very helpful (best) diagnostic tool in evaluating a thyroid and parathyroid tumors (you can't depend on PET scan for making the diagnosis even in lymphoma you need to have a tissue diagnosis)

-**CT:** Single most informative radiologic test. Helps differentiate cysts from solid lesions, localizes masses inside or outside a gland or nodal chain and differentiates a vascular mass. Cost limits its use. Clinical judgment plus needle biopsy generally makes use of CT in diagnosing neck masses infrequent. Consider for deep suspicious masses.

-**MRI:** Gives similar info as CT. Better for upper neck and skull base, Vascular delineation with infusion.

### Radionucleotide Scanning:

- Salivary and thyroid masses
- Location –glandular versus extraglandular
- Functional information
- Types used in H&N: Tx of oral CA, Tx of thyroid CA, PET-scan

3. **Abx Trial:** If diagnosis after examination in younger patient remains uncertain but inflammatory adenopathy is suspected then give a trial of abx. therapy and observation for 2 weeks. If mass still persists or has gotten larger, do a FNA biopsy with pathologic examination. (If doesn't improve>> do FNAB, never give another course of antibiotics) (IMP MCQ case)

## 4. **Fine Needle Biopsy:** (standard for diagnosis)

- *Most important* as the initial diagnostic procedure.
- This is the current standard of care for initial biopsy. Small gauge aspiration needle is used (25 gauge) for multiple aspirations.
- FNA biopsy is performed before surgical endoscopy but after a thorough head and neck exam and most of the time before any other studies done – unless the mass is vascular.
- *Single most important* study for diagnosing neck masses and thyroid cancer.
- **For thyroid:**
  - 5% false negative rate for FNA and thyroid nodules.
  - Good for papillary, medullary and anaplastic thyroid carcinomas
  - But FNA cannot accurately distinguish b/t benign and malignant follicular thyroid tumors or Hürthle cell tumors.

### • Indications:

- 1- Any neck mass that is not an obvious abscess
- 2- Persistence after a 2 week course of antibiotics

### • contraindications:

- 1-No contraindications (even in vascular or hematological diseases) **Only Carotid body tumor.**

- **Special Considerations:**

- FNA biopsy readily differentiates a cystic lesion from inflammatory lesion
- FNA helpful in differentiating lymphoma from carcinoma. Helps avoid endoscopic exam, guided biopsies and general anesthesia for a diagnosis of lymphoma. Would just need to do a simple nodal excision under local for histologic confirmation of lymphoma (after the FNA).
- High risk pt with pos hx of chronic tobacco and/or alcohol who have a solid neck mass that is not obviously a mucosal tumor may have inconclusive or negative FNA. Endoscopy and open biopsy are still required in this group b/c you should have high index of suspicion.
- If I took FNA and showed SSC but you can't find the tumor, don't go for open biopsy (because you lower the survival rate by disturbing the lymphatics), you go for panendoscopy searching for the primary tumor. Still can't find the dx then at that stage you do an open biopsy.

5. **Endoscopy and Guided Biopsy:** Helps identify primary tumor as source of a metastatic node.

6. **Open Excisional Biopsy:** (for lymphoma- Toronto notes)

Done after work-up is complete and if diagnosis is still not evident. Provide immediate specimen for histologic frozen section. Simultaneous radical neck dissection may be necessary if diagnosis supports squamous cell carcinoma, melanoma, or adenocarcinoma (unless mass is supraclavicular).

7. **Culture with Sensitivity Tests:** for inflammatory lesions after biopsy.

### So what to do when patient presents with a neck mass?

**There are many algorithms and what follows is very simplified.**

1. History
  2. Initial Physical Exam
  3. Any Pertinent Non-Invasive Lab and Radiographic Studies? And how useful they are in getting me the diagnosis
    - For example, CBC-P, TFT's, US, Thyroid Radionuclide Scan, Esophagrams, Abx Trial Therapy in younger patients, etc.
  4. Update History and Repeat Physical Exam
  5. More Invasive Tests as Warranted
    - For example, FNA biopsy of cervical lymph node or mass then endoscopy (direct laryngoscopy, esophagogastroscope or bronchoscopy) with guided biopsy if FNA reveals SCCa (to look for primary site).
  6. Consider CT at this point if FNA biopsy is non-confirmatory or for a suspicious lesion in a high-risk patient whose FNA is negative.
  7. Open Biopsy of Mass if primary site still unknown. *Follow immediately w frozen section and removal of mass or radical neck dissection if the frozen show scca*
- Note: open biopsy is not the initial diagnostic test, if done for pt with SCCA the pt survival get compromise due to alteration of the lymphatic drainage

**Case:** a common malpractice is doing an open (excisional) biopsy on a neck mass, because if the pt has malignancy by this you're reducing the survival by 20%. Do FNAB only. If you do FNAB and it was NOT diagnostic (only happens in 5% of pts), go for the open biopsy. If you open do frozen section, if inflammatory or adenocarcinoma or lymphoma there's nothing to do more, if SCC do a radical neck dissection (remove the SCM, jugular vein, lymphatic, accessory nerve)

## Congenital Differential Diagnosis of Neck Mass

### **Epidermal and sebaceous cysts:**

- In older age groups
- SSx: elevation and movement of overlying skin, skin dimple or pore
- Excisional biopsy confirms the diagnosis

### **Thyroglossal duct cyst:**

- **Most common congenital neck mass (70%) Present before age 20 (50%)**
- Occurs when parts of the thyroglossal duct persist and form a cyst.
- Most commonly located **in the midline** near (inferior to) the hyoid bone
- **Movies with tongue protrusion and swallowing.**
- Tx: with Sistrunk procedure after treat the infection. (excision of the cyst with its tract and the body of the hyoid bone to prevent recurrence)

### **Bronchial cleft cyst:**

- 1st cleft: less common and association with facial nerve
- **2nd cleft is most common**, tract medial to XII nerve and **between internal and external carotid.**
- 3rd and 4th cleft are rarely reported.
- Present in older children and young adults, usually following URI
- It is smooth, fluctuant mass with underlying sternocleidomastoid muscle.
- Skin erythema and tenderness if infected
- Tx: Initial control of infection then surgical excision, including tract (may necessitate parotidectomy (1st cleft )

### **Vascular tumor:**

- Lymphangiomas and Hemangiomas
- Usually they present in the first year of life
- Hemangioma usually resolves spontaneously while lymphangiomas remain unchanged
- CT/MRI may help define the extent of the disease.
- Tx:
- Lymphangioma: surgical excision for easy accessible on lesions affecting vital functions, recurrence is common
- Hemangiomas: surgical excision reserved for those with rapid growth involving vital structures or associated thrombocytopenia that fails medical therapy (steroids, interferon)



# Differential Diagnosis of Neck Mass

## Inflammatory Causes

1. Lymphadenitis
  - Very common in **first 10 years of life**
  - Tender node with sign of systemic infection
  - Tx: Antibiotics with follow up
  - **FNAB indications (pediatrics):**
    - Actively infectious condition with no response
    - Progressively enlarging
    - Solitary and asymmetric nodal mass
    - Supraclavicular mass (60% malignant)
    - Persistent nodal mass without active infection

(Leukemia and lymphoma can present as acute infection)
2. Inflammation of a lymph node (nodes) due to a variety of infectious causes  
(Equivocal or suspicious FNAB in pediatric nodal mass requires open excisional biopsy to rule out malignant granulomatous disease)
3. Deep neck infection
4. Thyroiditis
5. Acute and subacute thyroiditis

## Diffuse Thyroid Enlargement

- A goiter is diffuse enlargement of the thyroid gland seen in Graves Disease, Plummer's Disease, Iodine Deficiency, Acute Thyroiditis, Subacute Thyroiditis, and Chronic Thyroiditis (Hashimoto's and Riedel's Diseases). Also, goiters are seen in Diffuse Multinodular Goiter. **So patient with a goiter can be clinically euthyroid, hyperthyroid or hypothyroid. (Most important test is TSH)**

### 1- Iodine Deficiency

- Rarely a cause of goiter in the USA.
- It is usually treated medically and only rarely surgically for compressive symptoms.

### 2- Grave's Disease

- Diffuse goiter with hyperthyroidism, exophthalmos, and pretibial myxedema. Caused by circulating antibodies that stimulate TSH receptors on follicular cells of the thyroid and cause deregulated production of thyroid hormones.
- Diagnosed by Increased T3 and T4 and very low TSH and global uptake of radioiodine.
- **Treated in 3 ways: medical blockade (methimazole, PTU, propranolol, iodide), radioiodide ablation, surgical resection.**

### 3- Acute Thyroiditis

- Rare complication of septicemia. High fever, redness of overlying skin, tenderness.
- **Needle aspiration to identify organism.**
- **Intensive Abx therapy. Occasionally, incision and drainage.**

#### 4- Subacute Thyroiditis

- Secondary to viral infection and usually there is complete resolution within months.
- Fever, goiter and anterior neck pain. Possible sx and signs of hyperthyroidism w exquisitely tender thyroid gland on palpation.
- "Cold" uptake on scan distinguishes it from Graves b/c later in the course of the disease, pt becomes euthyroid and then hypothyroid.
- Treat with NSAIDS usually or prednisone if sx are bad.

#### 5- Chronic Thyroiditis

- Hashimoto's Thyroiditis: lymphocytic infiltration and destruction of gland resulting in hypothyroidism and a diffuse goiter.
- Hashimoto's common in women.
- Most common cause of goiter and hypothyroidism in USA.
- T3 and T4 either normal or low. TSH is elevated.
- Tx: thyroxine but then surgery if dominant mass is not suppressed by this therapy.

#### 6- Diffuse Multinodular Goiter

- This is adenomatous hyperplasia of the thyroid gland that is asymptomatic (non-toxic/euthyroid).
- R/O malignancy w FNA.
- Multiple nodules suggest a metabolic rather than a neoplastic process, but irradiation during childhood, a positive family history, enlarged cervical nodes, or continuing enlargement of one of the nodules raises the suspicion of malignancy.

#### 7- Thyroid Neoplasms

- Palpable nodules of thyroid occur in 5% of population. 15-30% of these prove to be malignant.

##### A. Benign Thyroid Nodule

- Usually benign nodules are solitary follicular adenomas, colloid nodules, benign cysts, or uni-nodular thyroiditis.
- Solitary toxic adenomas occur in older patients and are usually benign. These toxic adenomas reveal decreased TSH w increased T3 and T4.
- Thyroid scan show "hot nodule" and complete suppression of unaffected lobe.
- Usually managed w radioactive iodine or a unilateral lobectomy if the nodule is large.

##### B. Thyroid Cancer

- Risk Factors: Hx of radiation therapy to neck, young>old, cold nodule, History of rapid development of nodule, solitary>multiple nodules, vocal cord paralysis, and cervical adenopathy, hard fixed mass, elevated serum calcitonin
- Signs and Sx: Mass/nodule, lymphadenopathy, most are euthyroid and usually asymptomatic masses in low midline ant. Neck.
- Workup: FNA and U/S, thyroid function test if there are symptoms or signs of hypo-or-hyperthyroidism
- After thyroidectomy, you MUST follow Ca levels post-op (even give them supplemental Ca for awhile to be on safe side): can be decreased 2ndary to parathyroid damage.

### 1- Papillary carcinoma

- Constitutes 80% of thyroid carcinomas.
- Spreads lymphatically and slowly.
- 10 yr. survival rate is 95%. Good 131 I uptake.
- Tx:
  - hemithyroidectomy (usually not enough)
  - **Total Thyroidectomy most appropriate**
  - Post-Op need to give thyroid hormone replacement. Post-Op 131 I scan can diagnose and treat mets.

### 2- Follicular Adenocarcinoma

- 10% of thyroid cancers.
- Hematogenous spread (commonly to bone).
- More aggressive.
- Good 131 I uptake.
- 10 yr. survival is 90%.
- **Dx cannot be made w FNA.** Tissue structure (capsule) needed for diagnosis. (Malignancy if there is capsular or blood vessel invasion.)
- Tx same as in papillary ca

### 3- Medullary Carcinoma

- 5% of thyroid cancers.
- Associated with **MEN type II**
- Secretes calcitonin.
- Diagnosis made w FNA.
- Poor 131 I uptake.
- Lymph and hematogenous spread.
- 10 yr. survival is 50%.
- Treat w total thyroidectomy and lymph node dissection.
- Hürthle Cell Thyroid Cancer sub type of follicular ca

### 4- Anaplastic Carcinoma

- Undifferentiated carcinoma arising in 75% of previously differentiated thyroid cancers.
- 1-2% of all thyroid cancers.
- FNA helps diagnose.
- Major DDx includes lymphoma (much better prognosis).
- Treat small tumors: Total Thyroidectomy (possibly w external beam radiation). If there is airway obstruction then do a debulking surgery and tracheostomy
- Dismal prognosis. Most pt have stage IV (distant mets) at presentation.

## **Non-Thyroid Neoplasms**

- Primary cervical neoplasms are rare.
- Metastatic lesions represent up to 80% of all non-thyroid neoplastic neck masses.
- The initial management objective in these cases is always disclosure of site of origin of primary tumor (aerodigestive endoscopy.).
- The other 20% represent lymphomas or salivary gland tumors.
- Of the metastatic lesions, up to 90% arise from clinically obvious primary neoplasms located above the clavicle.

### **1- Metastatic Lesions**

- Be aware that the immediate removal of enlarged lymph node for diagnostic purposes is NOT GOOD for pt with metastatic cervical carcinoma.
- Disruption of lymphatic drainage and manipulation of the mets decrease chance for clean excision and cure.
- Enlarged nodes high in neck or in posterior triangle suggest nasopharyngeal lesion.
- Enlarged jugulodigastric nodes suggest tonsils, base of tongue or supraglottic larynx. If nodes are in supraclavicular area or lower 1/3 of neck then consider the whole digestive tract, lungs, breast, GU tract, and thyroid gland.
- Mets spread from chest or abdomen via thoracic duct (left side mets more common than right).

### **2- Epidermoid (Squamous Cell) Carcinoma**

- Tumor of middle and late adulthood.
- Associated with smokers and ETOH (alcohol).
- Primary tumor usually on a mucosal surface of upper aerodigestive tract.
- Neck mass represents mets. You must find primary site to treat successfully.
- Neck mass (es) can be unilateral, bilateral or multiple in number.
- HARD to palpation and may be fixed due to invasion of adjoining structures. Treatment: may include radical neck dissection Also, treat the primary site as warranted. Radiotherapy may be used.

### **3- Lymphomas**

- Commonest in early and middle adulthood.
- Masses are usually multiple but can be bilateral and/or unilateral.
- Range in size from one to ten centimeters.
- SOFT and MOBILE. Can be in anterior or posterior neck.
- Patient may be asymptomatic or possibly has low-grade fever, malaise, weight loss, night sweats.
- Diagnosis is made via cervical node excisional biopsy and histopath exam. Reed-Sternberg cells are associated with Hodgkin's.
- Treatment for lymphoma is medical

## **Salivary Gland Tumors**

- **Benign tumors are a mobile and non-tender while malignant tumors are painful and fixed.**
- **Malignant tumors may involve lymph nodes (evidence of local metastasis) and/or facial paresis/paralysis.(fast growing tumor and pressure symptoms depends on the site)**
- Diagnose w FNA.
- Treatment is generally via adequate surgical resection with neck dissection for node-positive necks and radiation

### 1. Parotid :

- a. 90% of all salivary glands tumors
- b. 90% is benign
- c. 90% is pleomorphic adenoma (mixed tumor)
- d. most common malignant tumor is mucoepidermoid carcinoma
- e. Characteristic of pleomorphic: high rate of malignant changes that why it is advisable to do the surgical resection quickly. Grow larger than warthins tumor. Higher rate of recurrence because microscopically it has pseudopodia which penetrate the capsule leading to the recurrence

### 2. Submandibular glands :

- a. Involved in 10% of salivary gland tumors.
- b. 60%are benign, 40% are malignant
- c. most common benign is pleomorphic adenoma
- d. Most common malignancy in submandibular, sublingual and minor salivary glands is the Adenoid Cystic Carcinoma (Mucoepidermoid Carcinoma is 2nd).

### 3. Sublingual gland

- a. rarely involved
- b. 60-70 %is malignant
- c. most common benign is pleomorphic adenoma

### 4. Minor salivary gland

- a. 90% is malignant
- b. commonly involve the palatal region

## Malignant Lesions of Larynx

- More common in men.
- Most common site is glottis. 90% are Squamous Cell Carcinoma.
- Risk factors: tobacco and alcohol. Sx: hoarseness, throat pain, dysphagia, odynophagia, neck mass, referred ear pain.
- Treatment: Total or supraglottic laryngectomy with neck dissection if there is nodal involvement. Radiation therapy or surgery for early lesions. Combination therapy for advanced disease.

## Parathyroid Masses

- After parathyroidectomy, watch out for recurrent nerve injury, neck hematoma and hypocalcemia.
- "Hungry Bone Syndrome" is severe hypocalcemia after surgery correction of hyperparathyroidism as bone aggressively absorbs Ca. Sx of this syndrome: perioral tingling, paresthesias, positive Chvostek's sign, carpal pedal syndrome.

### A. Primary Hyperparathyroidism: Adenoma

- Primary hyperparathyroidism is usually due to an adenoma (85%) which is NOT usually palpable.
- Labs show elevated PTH and hypercalcemia. Check urine to R/O Familial Hypocalciuric Hypercalcemia.

### B. Primary Hyperparathyroidism: Hyperplasia

- All 4 glands affected. Seen in MEN type I and IIa (must R/O MEN if pt has hyperplasia). Do a neck exploration and remove all of the parathyroid glands (leave 30 mg of parathyroid tissue behind placed in nondominant forearm).

## Nasopharyngeal carcinoma

- The incidence of nasopharyngeal carcinoma is two- to threefold higher in males compared with females.
- The incidence peaks around 50 to 59 years of age and declines thereafter.

### Risk factors:

- 1- Epstein-Barr virus
- 2- Smoking

### Histology & Staging:

- Nasopharyngeal carcinoma arises from the epithelial lining of the nasopharynx.
- The current TNM staging system classifies nodal stage of nasopharyngeal carcinoma according to laterality, size and location of lymph node, and whether unilateral (N1), bilateral (N2), >6 cm (N3a), or extend to the supraclavicular fossa (N3b).

### Diagnostic Evaluation:

- A definitive diagnosis is made by endoscope-guided
- Biopsy of the primary tumor. (Incisional neck biopsy or nodal dissection should be avoided as this procedure will negatively impact subsequent treatment.)
- Routine evaluation should include history and physical examination, including the cranial nerves, complete blood counts, and serum biochemistry, including liver function tests and alkaline phosphatase.
- Other studies should include chest radiograph, nasopharyngoscopy, and computed tomography (CT) or magnetic resonance imaging (MRI) of the nasopharynx, skull base, and neck.

### Management:

- Nasopharyngeal cancer has a propensity for early, bilateral spread to regional lymph nodes in the neck. Thus, all patients, including those with a clinically negative neck, are treated with bilateral neck irradiation.
- For patients without lymph node involvement (N0), it may be safe to omit RT to the lower neck,
- For patients with lymph node involvement, RT should encompass the whole neck.

### Prognosis:

The five-year overall survival for nasopharyngeal carcinoma according to disease stage in a contemporary case series was 90, 84, 75, and 58 percent for stage I through IV, respectively

# Head & Neck Cases

Pictures were not provided, the pictures below were taken from websites.

## Case 1:

Child presented with rapid growing neck mass, low oral intake, irritability, fever, and history of sore throat 5 days ago.

**Dx:** abscess formation

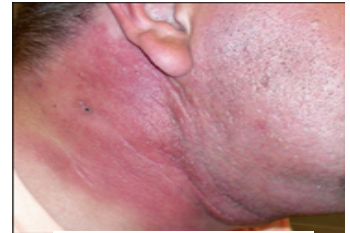**TX:** Incision and drainage with antibiotics

## Case 2:

Adult with neck swelling in the submandibular area for 5 days, low grade fever, pain and he never had like this swelling before

**Dx:** Cellulitis (Presents like mass under skin and tender.)

**Tx:** Antibiotics



Case 2

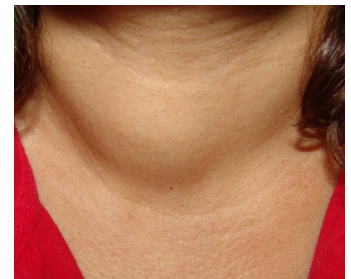
## Case 3:

Patient presents with bilateral neck mass for 5 months and he is asymptomatic.

**Dx:** Benign thyroid nodule

**Investigation:** Neck examination, FNAB, TSH

**Tx:** surgical excision.



Case 3

## Case 4:

Patient presents with lesion on his cheek that is growing slowly for the past 7 years

**Dx:** Basal cell carcinoma (Even if it is growing for the past 2 years it considered basal because it is the commonest.)

**Investigation:** Biopsy (we took the biopsy from the corner because the center is usually necrotic.)

**Tx:** Surgical excision.

Basal cell carcinoma is local and slowly growing tumor. With parotid or LN involvement, SCC (shorter duration compared with basal). If the patient present with lesion for 2 months, think melanoma or subcutaneous lymphoma.

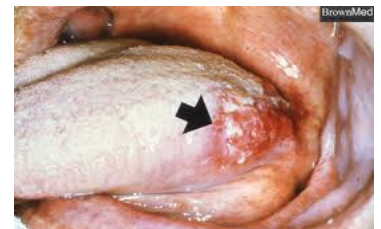
## Case 5:

Heavy smoker patient presents with painful mass in his right side of his neck

**Dx:** Squamous cell carcinoma of the tongue

**Investigation:** Biopsy and CT scan or MRI for metastasis

**Tx:** Surgical excision



Case 5

**Case 6:**

Smoker patient otherwise healthy, he started having painful swallowing and pain in his ear for 2 months. (the tumor located on the tonsils)

**Dx:** unilateral tumor of tonsils (either squamous cell carcinoma or lymphoma)

**Investigation:** Biopsy

**Case 7:**

50 year old male smoker patient presented with stridor and hoarseness for 10 months, dysphagia, weight loss and he sleeps on a chair. And on examination there is neck mass about 4 cm.

**Dx:** Laryngeal cancer

**Tx:** Laryngectomy

Stridor indicates airway obstruction and weight loss indicates severe cases

**Case 8:**

Lady patient neck mass but she is asymptomatic.

**Dx:** Deploy parotid tumor

**Tx:** Surgical excision

**Case 9:**

Elderly lady started rapid growing mass in the left side of her neck for the past 2 months, low grade fever, weakness, malaise

**Dx:** Lymphoma

But if the same lady has the neck mass for 7 years and it is asymptomatic she is most likely has pleomorphic adenoma or if her neck mass is growing for the last 6 months and it is painful, and known she has facial nerve palsy, most likely is malignant parotid tumor

- The most common benign tumor of the salivary gland is pleomorphic adenoma
- Second most common benign is warthin's tumor (papillary cystadenoma lymphomatosum)
- 80-90% of parotid masses are benign
- Most common malignant in all salivary glands: mucoepidermoid then adenoid cystic carcinoma.
- Most Common tumor in all salivary glands: Pleomorphic Adenoma
- 40-60% submandibular tumors are benign
- In minor salivary glands most likely is malignant tumors
- In sublingual tumor is 40-70% malignant
- Pain, nerve palsy, rapid growing tumor, LN, invasion of skin. (all these symptoms are indications of malignancy)

**Investigations:** FNA, CT/ MRI.

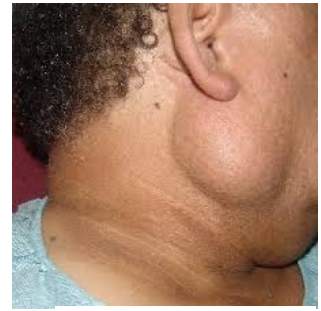

**Case 10:**

3 years history of left parotid mass,

**Dx:** warthin's tumor

**Investigation:** FNA



Case 10

**Case 11:**

Lady with rapidly growing mass on her neck, tiredness, weakness, fever, weight loss over 4-5 months, **pale**, WBC 150, platelets 15-16. Hb 6-7.

**Dx:** Leukemia.

If the patient normal parameters but multiple lymphadenopathy and Hepatosplenomegaly, think lymphoma.

**Case 12:**

submandibular pleomorphic adenoma.

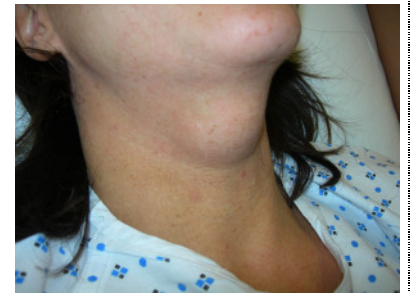**Case 13:**

**Dx:** thyroglossal cyst. Midline

**Case 14:**

Old lady is using dentures

**Dx:** Squamous cell carcinoma



Case 13

**Case 15:**

Male patient working as carpenter, complains of not being able to see the sides (big nose).

**Dx:** Sinonasal tumor (SCC and adenocarcinoma), **wood dust association.**

**Investigation:** Biopsy

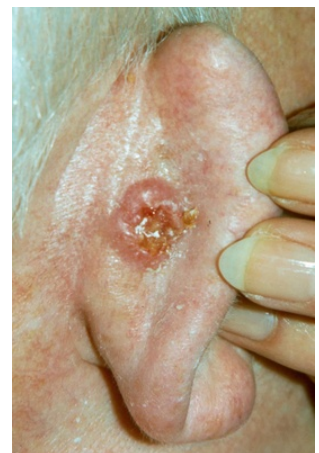**Tx:** No chemo or radiation, just resection.

**Case 16:**

Post liver and kidney transplant patient, presenting with post auricular discharge for the last 6 months. Ear examination is normal, however, you find a small ulceration in the skin.

**Dx.** In immunocompromised patients, don't consider infected sebaceous cyst. This is a case of squamous cell carcinoma.

**Investigations:** MRI shows air from the skin track. The carcinoma is invading the parotid and temporal bone. Biopsy reveals squamous cell carcinoma of the skin.

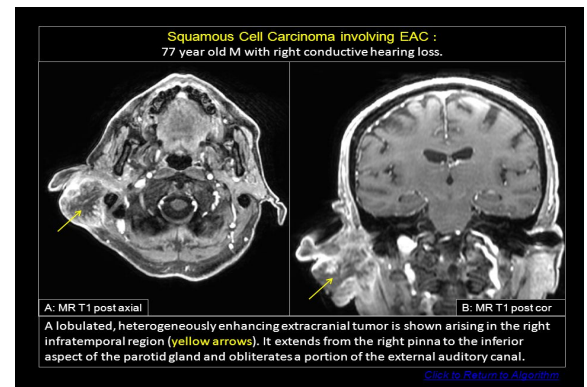


Case 16 A

Head and Neck

ENT Teamwork 432

**Treatment:** **SCC is aggressive so you have to resect the tumor completely with good margins.** When you have auricular squamous cell carcinoma, you must resect the auricle. In this patient, the parotid, facial nerve, and mastoid process were also resected due to involvement.



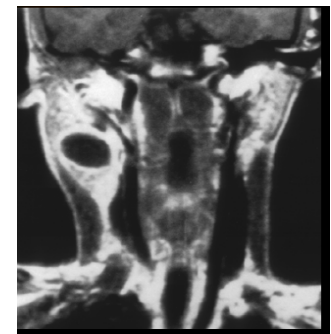
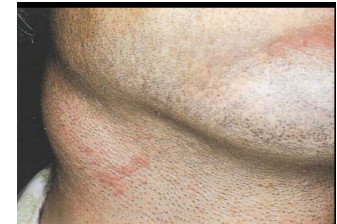Case 16 B

**Case 17:** 65 year old with 11 year history of left neck mass, scan shows cystic lesion, location is at the level of SCM, mid neck, no enlargement of the lymph nodes.

**Dx:** This is a case of branchial cyst. What is against branchial in this patient? Age. However, while congenital disease is rare in elderly, they may occur.

**Investigations:** We are not worried because it is been there for 11 years, however, we did FNA to confirm it's branchial cyst.

**Treatment:** surgical excision including the tract which extends to the tonsils.

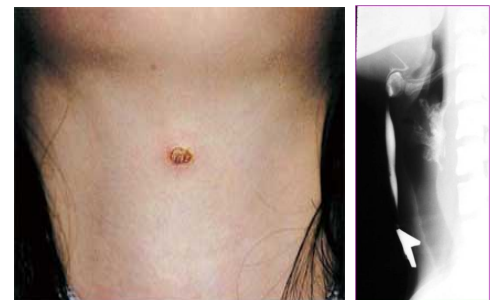

Case 17 Branchial Cyst

**Case 18:** 80 year old lady presents with midline swelling for the past 25 years. The swelling is elevated on tongue protrusion.

**Dx:** This is an unusual case of thyroglossal cyst.

**Treatment:** **Sis-trunk** procedure where you remove the cyst and any attached skin, the complete track (which starts at the foramen cecum ie. base of tongue), and the body of the hyoid bone (the track goes through or deep to the body of hyoid). **If you remove the cyst alone, the patient may suffer from recurrence (50%) or a draining fistula. With recurrence, the rate of cure is decreased.**

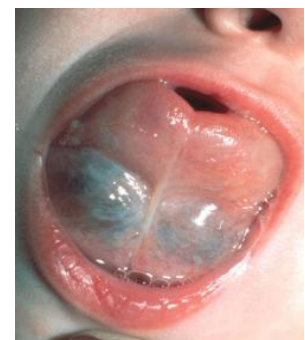

Case 18: Thyroglossal fistulography which shows extension of track to base of tongue.

**Case 19:** patient with fungating mass of the neck. Biopsy shows squamous cell carcinoma. Biopsy from floor of the mouth shows squamous cell carcinoma.

**Case 20:** Benign sublingual cystic lesion in a young patient.

**Dx:** Ranula. Ranulas are mucoceles that occur in the floor of the mouth and usually involve the major salivary glands. Specifically, the ranula originates in the body of the **sublingual gland**, and, infrequently from the minor salivary glands at this location.

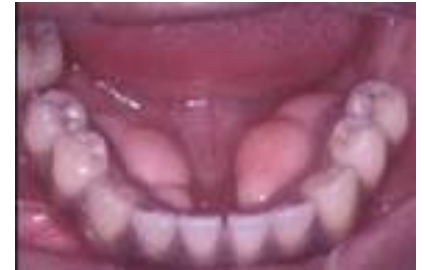

Case 20: Ranula

**Treatment:** marsupialization of the ranula with packing. The more traditional method of surgery for an oral ranula is complete excision of the ranula and associated major salivary gland.

The term ranula is derived from the Latin word *rana*, meaning frog, and describes a blue translucent swelling in the floor of the mouth reminiscent of the underbelly of a frog.

**Case 21:** This is another example of a benign disease. Torus mandibularis. This is normal variation and is nothing to worry about. “not important”

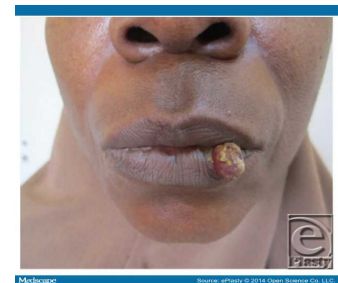

Case 21

**Case 22:** This man has a fungating mass of his lip for the past 8 months. He is afraid of doctors and so he tried removing the mass himself by tying a band around it and excising it using a knife.

**Dx:** simple granuloma “pyogenic granuloma”.

**Treatment:** Under local spray of lidocaine, you snip it.



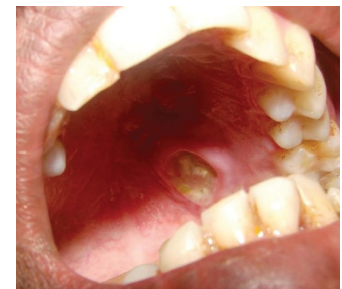Case 22

**Case 23:** patient on the list for liver transplant develops a painful ulcer of the left side of his tongue.

**Dx:** We are worried about cancer in such patients since they suffer from liver failure and are immunocompromised.

**Investigations:** Biopsy reveals necrotizing sialometaplasia (ulcer of the palate is the typical presentation) which is necrosis of the salivary glands associated sometimes with liver disease. It may mimic cancer of the tongue, which needs to be ruled out.

**Treatment:** Resolves spontaneously.



Case 23

**Case 24:** Smoker, drinker presents with 3 month history of a painful sore throat. He has been on multiple courses of antibiotics. He is frustrated from his primary care physician and has come to you for evaluation. On examination, there is a fungating mass on his soft palate.

**Dx:** This is not tonsillitis; tonsillitis doesn't persist for 3 months. Instead of prescribing antibiotics for a prolonged period, a biopsy should have been taken.

**Investigations:** Biopsy reveals squamous cell carcinoma of the palate.

**Case 25:** Auricular tumor in an elderly patient who is exposed to the sun frequently. Examination reveals **rodent ulcer typical of basal cell carcinoma.**

**Investigations:** Biopsy reveals basal cell carcinoma.

**Treatment:** wedge resection

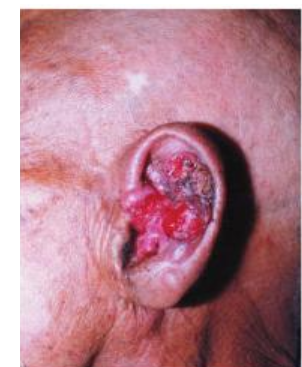

Fig. 16.2: Malignancy of left external auditory canal and pinna

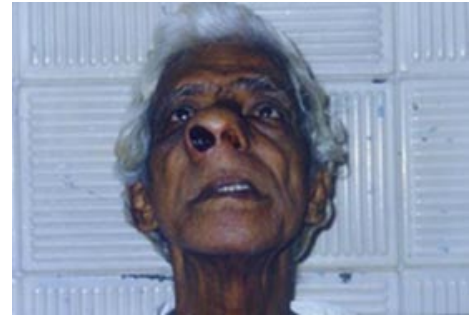
Case 25



**Case 26:** This is a rare case of an elderly lady who present with a fungating mass through her nose.

**Investigations and Dx:** Biopsy reveals sinonasal melanoma. Melanoma doesn't always happen in the skin, mucosal membranes can give rise to melanomas as well.

**Treatment:** **There is no treatment for melanoma except for surgical resection.** Skin melanoma has a bad prognosis. Mucosal melanoma has an even worse prognosis,



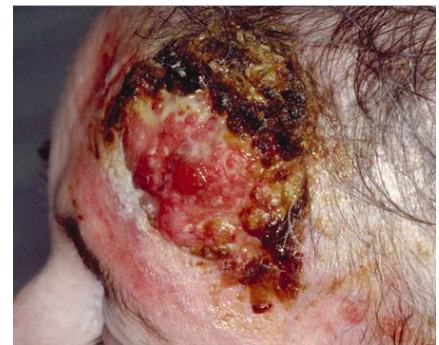Case 26

**Case 27:** A neglected elderly lady in a nursing home presents with a growing mass on the left side of her neck. Society often believes that these homes are well organized and take good care of their residents.

**Investigations:** Biopsy reveals squamous cell carcinoma. It was a local disease with no metastasis.

**Treatment:** Patient underwent wide local excision with neck dissection.

**Case 28:** This is a patient with basal cell carcinoma of the temporal area. Treated with radiation 20 years earlier. The patient ignored himself completely and disappeared from followup. He presented 20 years later with a massive tumor eating half of his face.



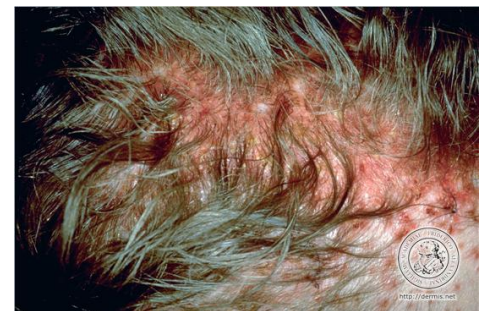Case 28

**Investigations and Dx:** Biopsy reveals squamo-basal cell carcinoma i.e. transformation from basal to squamous cell carcinoma.

**Treatment:** He underwent massive resection of the whole area. Keep in mind that in patient who received radiation cannot be given radiation again as the tissue would not be able to tolerate it. Reconstruction is usually done with anterolateral thigh flap; we take a free flap from the leg with its vessels and plug it into the area and reanastomose the skin.

**Case 29:** This is another example of ignorance. The patient has malignant histiocytosis of the skull. The patient is demented and refuses any kind of treatment. Finally, his family brought him because they couldn't tolerate his smell.

**Treatment:** complete resection with radical neck dissection (carotid, internal jugular, vagus nerve, sternocleidomastoid, lymph nodes..etc). This is the tumor in the dura, which was resected and grafted. The patient left before the skull defect was grafted with dorsalis free flap.

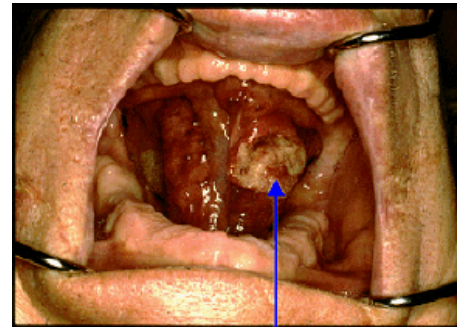


Case 29

**Case 30:** 80 year old lady who is a heavy smoker since childhood presents with severe dysphagia, pain, weight loss, and otalgia (the highest area of smokers is in the north and in the eastern province). In the north, they believe that smoking treats cough symptoms.

**Investigations and Dx:** Scan reveals base of tongue destructive tumor extending all the way to the larynx. This the picture you get with heavy smoking: huge tumor, extending to the larynx, in more than one site.

**Treatment:** She underwent total laryngectomy and base of tongue resection. We created a new pharynx so that she can eat and swallow. She can speak by using special reconstruction.



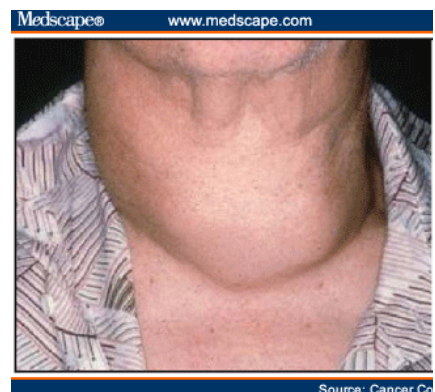
Case 30

**Case 31:** This is an unfortunate 36 year old lady who had parotid myoepithelial carcinoma which is not that common of a tumor in the parotid. She was treated with resection previously but had declined radiation therapy. She came with a massive recurrence of her parotid tumor. Her MRI shows that her tumor has reached her larynx and has replaced most of the neck. She underwent surgery and reconstruction, and had done quite well from a surgical point of view. However, she disappeared after surgery without undergoing radiotherapy. She has been seen 6 years ago. She was blind at that time because the tumor recurred at the skull base and destroyed her optic canal. She remained in the hospital for 6 months for pain management before passing away. People don't always help themselves. When you deal with cancer, you have to understand that the people have the will to choose how they die. You cannot force treatment on patients. You can only counsel them about the consequences of refusing treatment.

**Case 32:** Elderly lady presented with massive thyroid mass.

**Investigations and Dx:** MRI shows huge thyroid mass, huge cervical lymph nodes compressing the airway. Biopsy from the trachea showed anaplastic thyroid carcinoma. The rest of the tumor is papillary.

Anaplastic thyroid carcinoma is worse than any type of cancer. 1-year survival rate is less than 2%. In contrast, papillary thyroid carcinoma is curable in more than 90%. The average survival even with metastasis is 22 years. This shows that with thyroid, you could have the best prognostic cancer (papillary) and the worst prognostic cancer (anaplastic).



Source: Cancer Co

Case 32

**Treatment:** She underwent radical neck dissection (carotid, internal jugular, sternocleidomastoid, ..etc)..

## Summary

1- History is a critical part where it guides you toward the DDX and investigations, where you have to ask about the mass duration and growth rate, age, RFs, family Hx, inflammatory mass RFs, malignancy RFs+ symptoms.

2- PE: start by general survey where you inspect for any abnormality, lymph node level identification, trachea and thyroid gland exam and end with a detailed head and neck examination of (oral cavity & oropharynx, nasal cavity, ear, scalp, cranial nerves)

3- labs +investigation: start with labs (CBC, TFT, TB), imaging (US for thyroid, MRI Better for upper neck and skull base,)for the mass and lymphatic metastases assessment, FNA is the initial and standard for diagnosis, Abx Trial for highly suspected infection masses for 2 wks if no improvement then go for next step.

4- In congenital neck masses, the course of the mass is benign where it is slowly growing masses. Thyroglossal duct cyst is by far is the commonest and in the midline of the neck.

5- Inflammatory causes of neck mass treated by antibiotics, FNAB only done for cetrian indications

6- In thyroid masses we do TSH to know if it is hyper or hypothyroidism. FNAB is done if malignancy is suspected

7- The most common benign tumor of the salivary gland is pleimorphic adenoma  
Second most common benign is warthins

8- Most common malignant in all salivary glands: mucoepidermoid then adenoid cystic carcinoma.

9- Most Common tumor in all salivary glands: Pleimorphic Adenoma

10- The most important risk factor of nasopharyngeal carcinoma is smoking were you do endoscopic guided biopsy to confirm the diagnosis.

## MCQ's:

**1- A 56 year old presented with a midline neck mass occurs with swallowing. no dysphagia no weight loss.**

Dx: thyroglossal duct cyst o Most IMP **radiological investigation:** U/S o Most IMP **tool for investigation:** FNAB o FNAB Result: follicular lesion underwent surgery for the large obstructive lesion. , Tx: total thyroidectomy

**2- A lady with an ulcer in the temporal area for 8m.**

DDx? BCC, SCC, Melanoma Signs of malignancy: Invading edges, Non healing ulcer, Age, **Dx by:** biopsy of the margins (the base is usually necrotic and not useful for Dx) What areas you wanna examine? Eye (if deep invasion it will be affected), Facial nerve, lymph node examination. **Investigations?** CT.

**3- Patient presented with parotid mass, what is the most common benign tumor of the parotid?**

- A. Warthins tumor
- B. Pleomorphic adenoma
- C. Mucoepidermoid
- D. Adenoid cystic carcinoma

**4- What is the diagnostic test for nasopharyngeal carcinoma?**

- A. Endoscopic biopsy
- B. MRI
- C. Open biopsy

**5- 20 year old patient presents with midline neck mass for 6 year, what is the most likely diagnosis?**

- A. Thyroglossal duct
- B. Bronchial cleft cyst
- C. Thyroid tumor
- D. Lymphoma

**For mistakes or feedback**

**ENTteam432@gmail.com**

**Answers**

**3- B**

**4- A**

**5- A**