
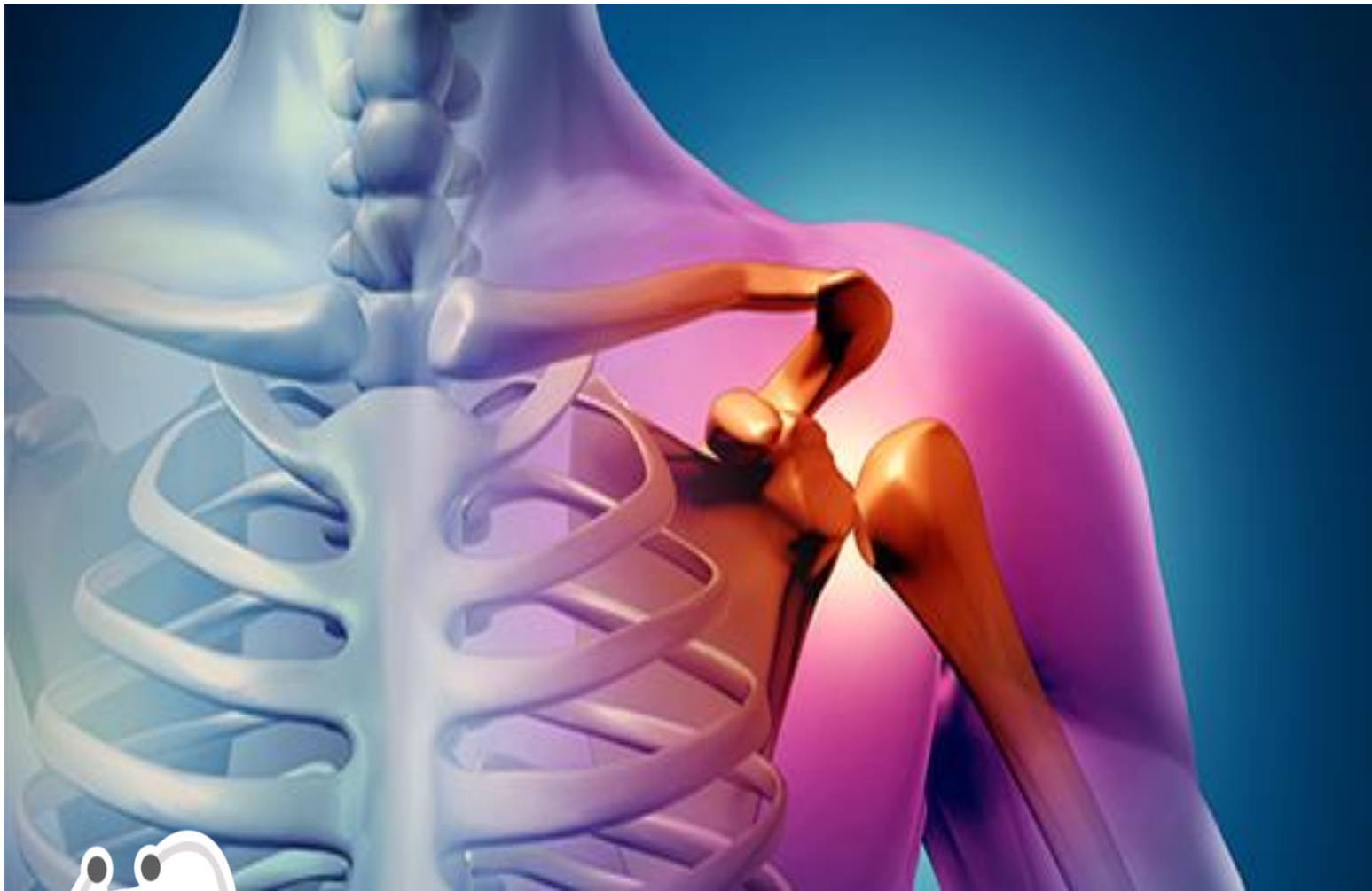


# Orthopedics

432 Team

## 14 Bone Tumors



Done By: Moudhi Aldegether & Samma Albukhayyet

Revised by: Lama AlHomayin

Team Leader: KhuloodAlRaddadi (F1)

[Khulood.ALRaddadi@gmail.com](mailto:Khulood.ALRaddadi@gmail.com)

جامعة  
الملك سعود  
King Saud University



Color Code:

Slides

431 team work

Doctor's Notes  
Arabic Words

Team Notes  
Books' notes

Important  
Other Sources

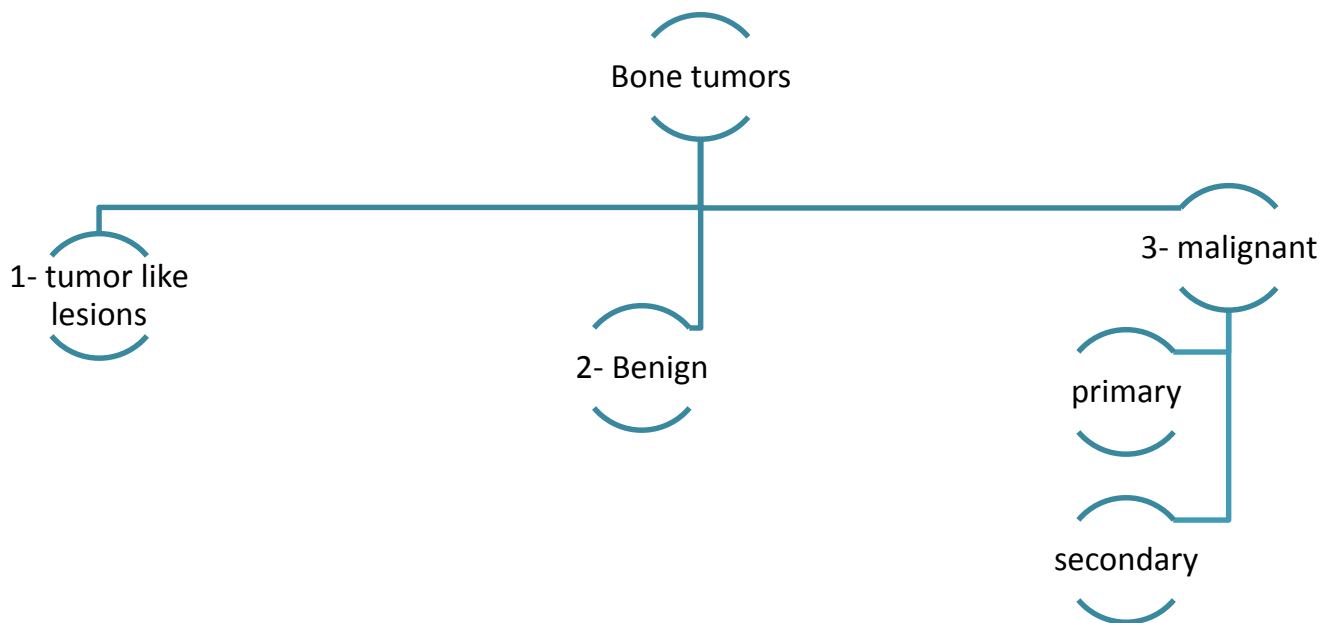
**Note:** All the information was copied from 431 team work and doctor's notes were added

## Objectives

By the end of this lecture you should know:

- How to reach a diagnosis by history, physical examination and investigations.
- How to manage cases of bone tumors.

## MIND MAP



**OSCE:****History :**

Cc :swelling or Pain (where, when , how, for how long, associated symptoms )

(Site,Onset, Character,Radiation,Associations,Time course,Exacerbating/Relieving factors,Severity)

Family history

Predisposing factors

**PE:**

General examination ( unwell ) E.g.female presented with bony pain and swelling in her leg and she has history of cancer )

Local examination

Examine joint bellow joint above and if it is in the lower limp lymph and inguinal lymph nodes

**Investigations :**

X-ray( ap ,lateral) , MRI ,blood investigations

each sample you take, take it for both histopathology and culture

**Diagnoses:**

1- Site: Epiphysis, Diaphysis or Metaphysis which most of the tumor arises from metaphysis.

2- Centric (away from the border) or eccentric (in the bone border).

3- Border of the tumor:

a) Well define & sharp border → usually in benign tumors.

b) Ill-defined → usually in malignant.

c) Sclerotic margin: sign of benign tumors.

4- Matrix of the tumor:

a) Sclerotic: it means forming bone .so on x-ray →opaque.

b) Lytic: it means forming tissue other than bone (it may be cartilage, fibrous tissue or cyst)

on X-ray →translucent.

N.B. this calcification (lytic and sclerotic) helps in the differentiation b/w the tumors .i.e. you can't say from this calcification that this tumor is benign or malignant.

5- Periosteal reaction: -occur in some bone tumors:

a) Characteristic periosteal reaction: mostly occur with malignant tumors (teeth like)

b) Smooth periosteal reaction: with benign tumor.

6- Geographic appearance:

Describe the tumor: e.g. oval shape, surface tumor, multiple tumor, etc.

7- Soft tissue extension: occurs mostly with malignant tumors or aggressive benign

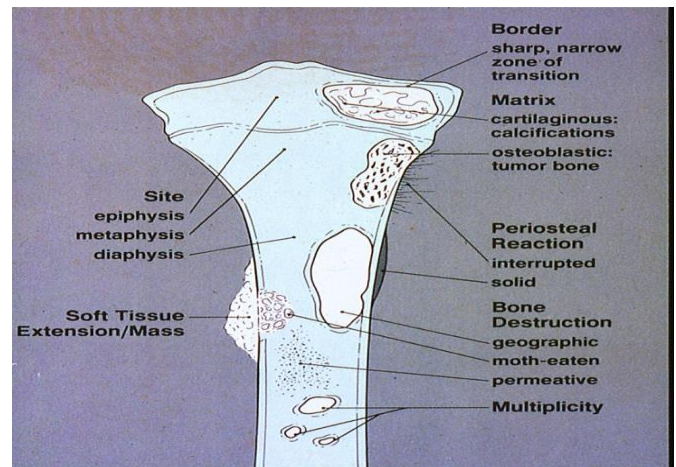
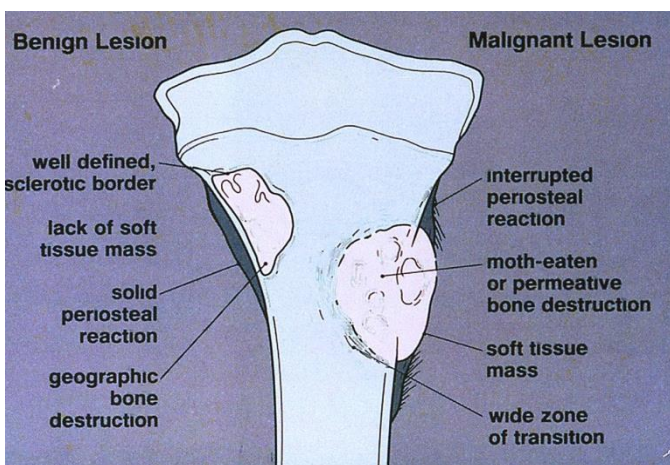




FIG. 13.2 CLASSIFICATION OF TUMORS AND TUMORLIKE LESIONS BY TISSUE OF ORIGIN

Tissue of Origin	Benign Lesion	Malignant Lesion
Bone-forming (osteogenic)	Osteoma Osteoid osteoma Osteoblastoma	Osteosarcoma (and variants) Juxtacortical osteosarcoma (and variants)
Cartilage-forming (chondrogenic)	Enchondroma (chondroma) Periosteal (juxtacortical) chondroma Enchondromatosis (Ollier's disease) Osteochondroma (osteocartilaginous exostosis, single or multiple) Chondroblastoma Chondromyxoid fibroma	Chondrosarcoma (central) Conventional Mesenchymal Clear cell Dedifferentiated Chondrosarcoma (peripheral) Periosteal (juxtacortical)
Fibrous and fibrohistiocytic (fibrogenic)	Fibrous cortical defect (metaphyseal fibrous defect) Nonossifying fibroma Benign fibrous histiocytoma Fibrous dysplasia (mono- and polyostotic) Periosteal desmoid Desmoplastic fibroma Osteofibrous dysplasia (Kempson-Campanacci lesion) Ossifying fibroma (Sissons' lesion)	Fibrosarcoma Malignant fibrous histiocytoma
Vascular	Hemangioma Glomus tumor Cystic angiomas	Angiosarcoma Hemangioendothelioma Hemangiopericytoma
Bone-marrow (hematopoietic) and lymphatic	Giant cell tumor (osteoclastoma) Eosinophilic granuloma Lymphangioma	Malignant giant cell tumor Histiocytic lymphoma Hodgkin's disease Leukemia Myeloma (plasmacytoma) Ewing's sarcoma
Neural (neurogenic) Notochordal	Neurofibroma Neurilemoma	Malignant schwannoma Chordoma
Fat (lipogenic)	Lipoma	Liposarcoma
Unknown	Simple bone cyst Aneurysmal bone cyst Intraosseous ganglion	Adamantinoma

# Tumor like lesions

## 1) Simple bone cyst (unicameral cyst):

Most commonly incidental finding. (Most resolve within 2 years.)

But the patient may present with pathological fracture →

Cause pain ( after trauma , & cyst may correct after fracture )

The most common tumor like lesion

Usually in children age group up to 20 years old ,Male > Female

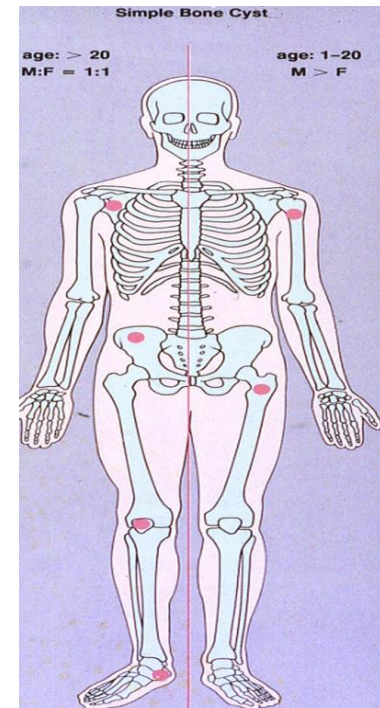
After 20 Male=Female

### Sites:

Common in the end of long bones (e.g. proximal humerus).

Upper & lower parts of the femur

Pelvic (iliac crest) ,Calcaneus, Scapula ,Patella



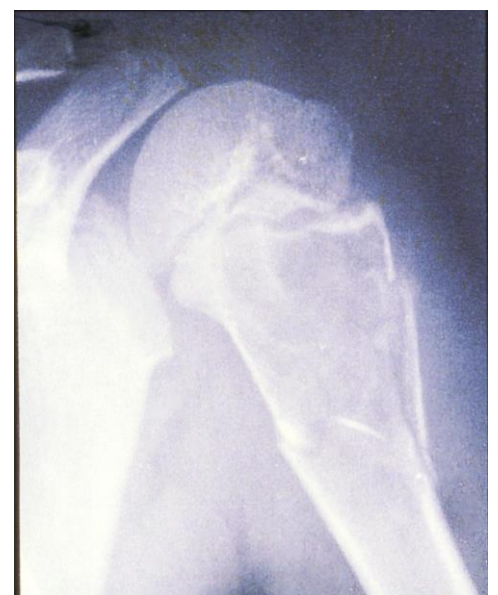
### Radiological feature :

( x-ray is the main essential investigation in benign tumors ) 1) Metaphysic lytic lesion.

2) Sclerotic margin, well define.

### Treatment :

- X-ray of pathological fracture in child age group
- Nothing to do it except conservative treatment for the fracture ,& till the patient that you may have fracture in this area
- The same fracture in older age with displacement & angulation
- ORIF (Open Reduction and Internal Fixation) + Bone graft to fill the space





## 2) Aneurysmal bone cyst:

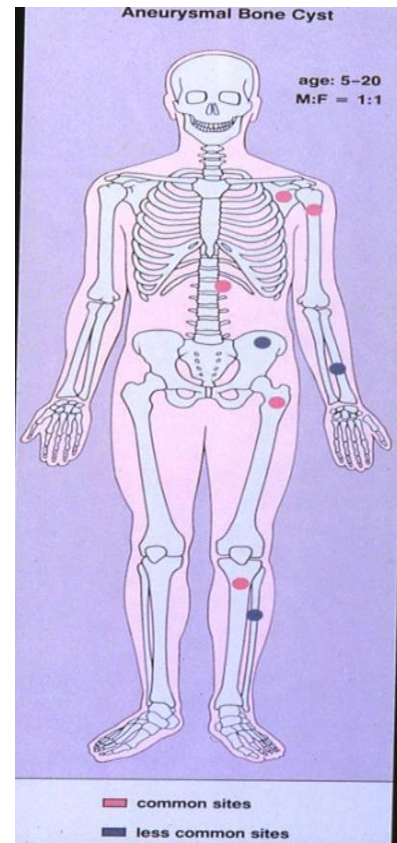
- "Aggressive" and balloon-like"
  - Progressive tumor like lesion.
  - Recurrence rate is high.
  - "Fusiform cyst and Arteriovenous formation"
  - Aneurysmal cysts have bloody content, while simple cysts have Orange contents
- colored fluid. Similar to sun top juice color

### Site (common site):

- Upper humerus.
- Upper femur.
- Spine (neural arch: lamina & pedicle) may give pressure effect.
- Proximal tibia.
- Scapula.

### Presentation:

- The usual presentation is swelling.
- Patient may present with pathological fracture → pain."

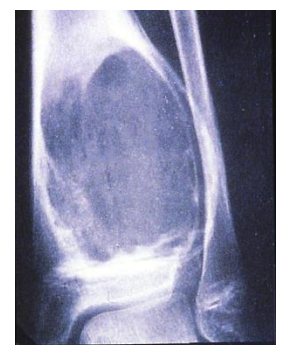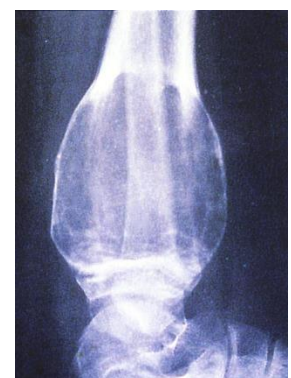


### Radiological feature:

- clear margin
- X-ray shows different content inside aneurysmal cyst unlike simple cysts.
- Metaphyseal lytic lesion.
- Well- defined, sclerotic margin.
- Expansile → thin cortex (like egg shell

### Treatment:

- ORIF + BONE graft ( from fibula as support BCZ lesion is very big)
- Sequestration = divide it to small champers
- Aspiration with alcohol ,phenol & steroid



# Benign tumors

## 1) Fibrous Cortical Defect (Non Ossifying Fibroma)

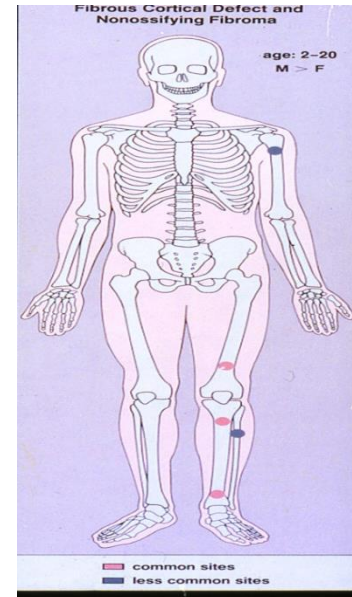
- Benign lesion since birth
- Not site for fracture.
- Never transfer to malignant.
- Ec-centric lesion

### Site:

- Around knee: (lower femur, upper tibia).
- Lower tibia.

### Presentation :

- Asymptomatic (no pain, no swelling & no pathological fracture) → discovered incidentally



### RADIOLOGICAL FEATURE :

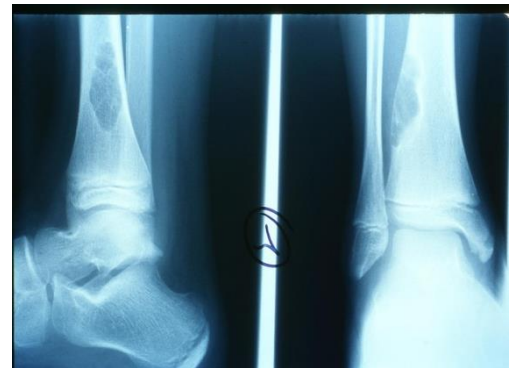- I am looking at x ray of the right ankle of a child
- I can see a lesion in the metaphyseal diaphyseal junction
- Margin : clear
- Matrix : fibrous
- Cortex : intact
- Most likely benign
- Can't be simple bone cyst because of the site

Metaphyseal lytic lesion ( inside the cortex)

- Well defined, sclerotic margin.

### Treatment :

- Self-limited, healed by itself.
- Reassurance. If pain-full → curettage +bone graft.





## 2) Osteoid osteoma:

ورم عظمي عظماني

Benign tumor which has different behavior → main presentation is pain.

Usually affects young patients 10-35 and more common in males.

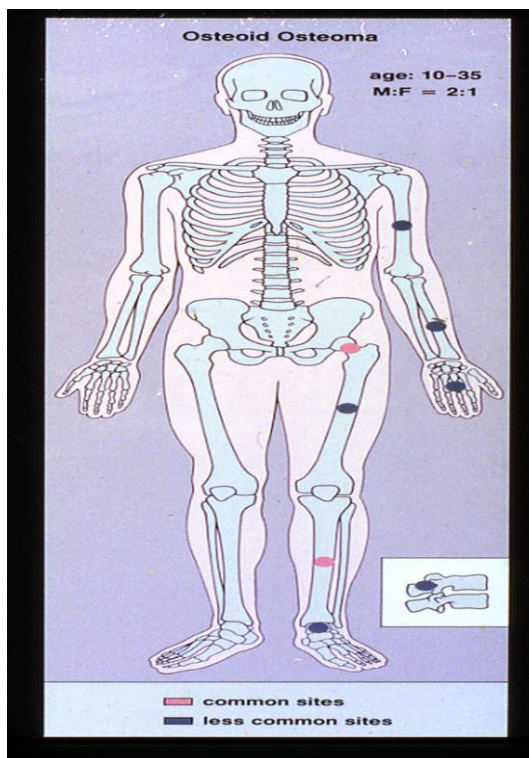
May arise in the cortex of long bones, or occasionally in the cancellous bone of the spine and less commonly talus

### Presentation:

Usually well localized pain that is worse at night and prevents patients from sleep. Night pain is important sign to think about tumor

### Character of pain :

1. Pain at the site of tumor.
2. Aggravated by activity.
3. Relieved by aspirin & NSAID.

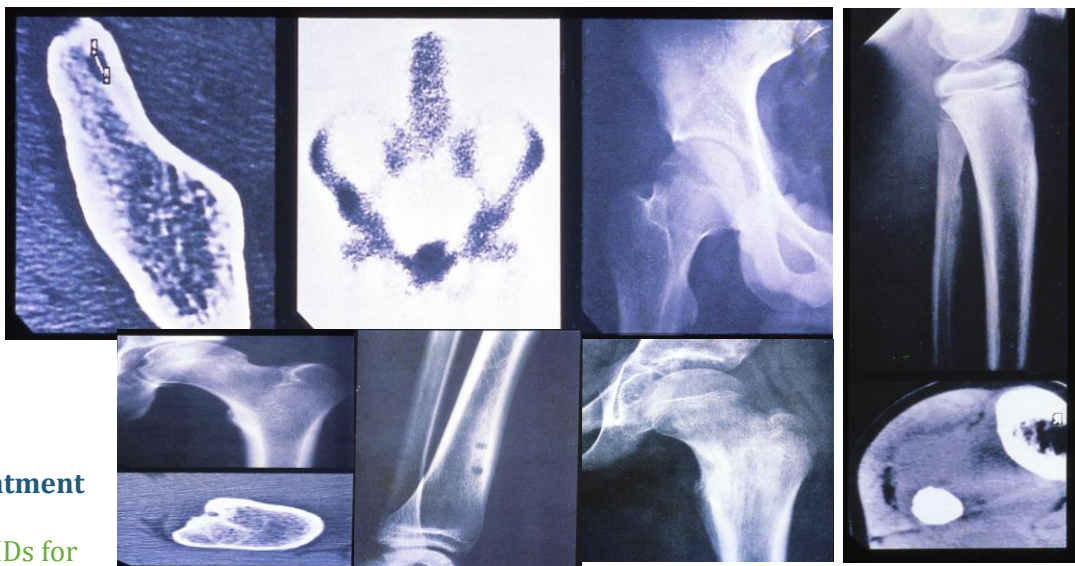


**Radiological features :**

- make sure it is not acute vascular necrosis
- Metaphyseal or diaphyseal lesion.
- Lytic lesion inside patch of sclerosis.
- The lytic lesion called (( nidus )) , nidus is the part which surrounded by a reactive zone
- of dense sclerotic new bone formation, therefore in the treatment →we remove nidus only.

**Investigation:**

- 1) X-ray→ a nidus surrounded by a thick cortex(sclerosis).
- 2) CT scan →nidus
- 3)"Bone scan used sometimes.→↑uptake.

**Treatment**

- NSAIDs for weeks
- If not relived A CT-guided needle can be inserted in to the nidus and the lesion ablated
- with radiofrequency coagulation (also called radiofrequency ablation).
- If it easy to access > excise it label it then send it to histopathology to make sure all
- The lesion was excised"

3-6

### 3) Endochondroma:

15-50 age group

Tumor grows within the bone and expands it (ballooning)

It composed of translucent hyaline cartilage and content inside is chondroid

The affected bone is expanded by the tumor and its cortex is thinned

#### Sites

Mainly small bone e.g. phalanges in hand & foot ...etc.

Fairly common in Femur, humerus and less commonly tibia & fibula

#### Presentation:

Usually found incidentally Swelling. Females might notice it because they might feel that their ring became tight due to the swelling

Pathological fracture which may cause pain. Affect one side and prolonged healing

Metaphyseal or diaphyseal lytic lesion. Well defined.

Sclerotic margin.

Multicentric

#### Radiological features:

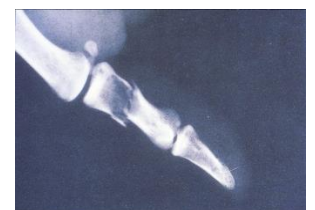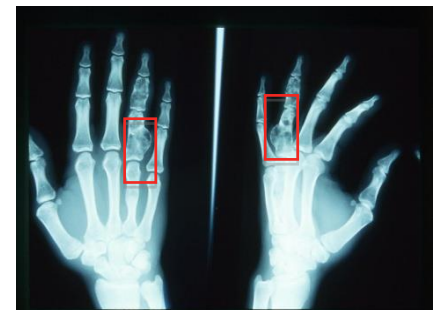
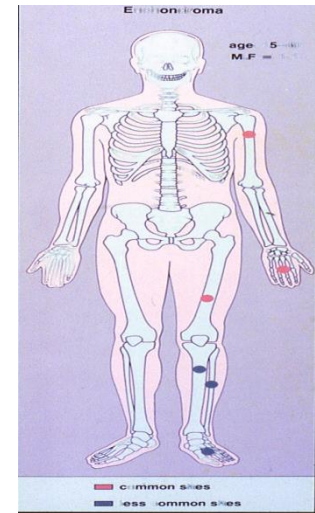
Location and contents is different than aneurismal bone cysts.

- Enchondroma usually in digits, different from aneurysmal which happens in long bones
- Ground sub here contains fibrous tissue unlike aneurysmal which appears like glass

X- RAY of enchondroma is more hyperdense due to the chondroid.

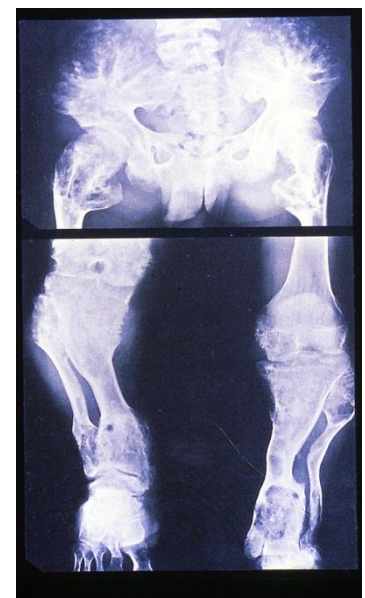
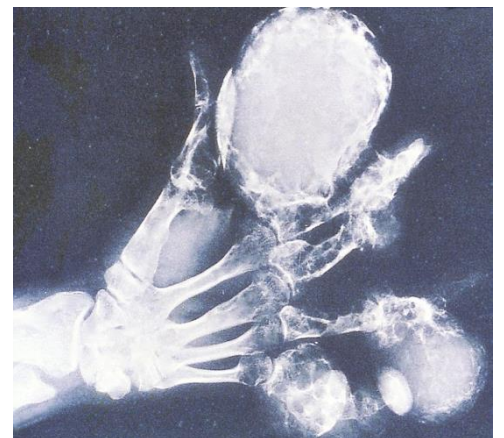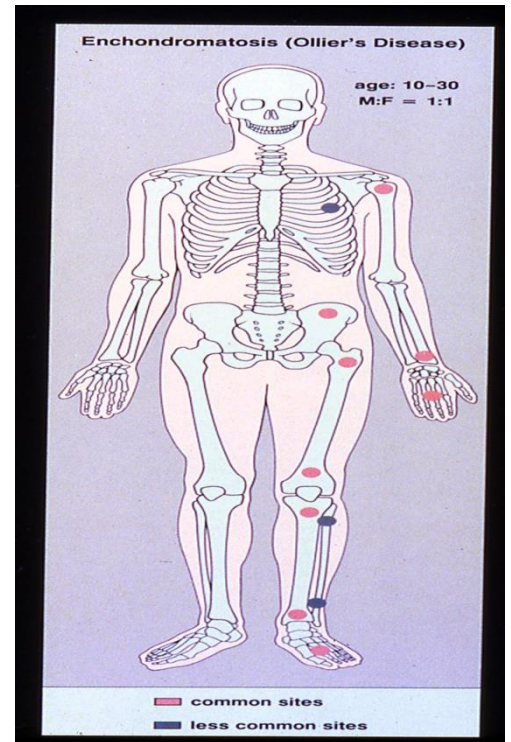
#### Treatment :

If it symptomatic (pain , become bulky ) >> surgery (curettage + bone graft) and fixation. N.B. any pathological, you must take a biopsy.



4) Endochondromatosis:

Multiple enchondroma of the major long bones occur mainly in the rare condition called multiple enchondromatosis.  
 Benign ,affect both sides ,low grade destructive lesion  
 Usually starts in children, and carries a high risk of becoming a secondary tumor (malignant transformation).





## Osteochondroma الزيادة العظمية

- Commonest benign tumor of bone.
- The only surface tumor, (outside the bone), therefore, it's called **exostosis**.
- It is a combination of both bone & cartilage.
- Usually in 10-20 age group and Male > Female.
- Painful in children due to growth plate compression and pressure effects on adjacent nerve or vascular structures.

### Sites:

- The commonest are (around knee) distal femur + proximal tibia + proximal humerus, Scapula, neck of femur.

### Presentation:

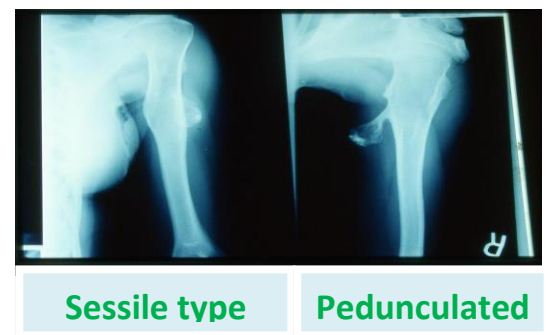
- Swelling, it can reach huge size (**keeps on growing**), **commonest patient's symptom is cosmetic**

### Symptoms of complications:

1. Pressure symptom:
  - Pseudo-aneurysm. → artery.
  - Hypothesis or parasthesia → nerve.
  - Rendering the movement → tendon.
  - Restrict the movement of the movement nearby the joint
  - Adventitia bursea.
2. Fracture especially with pedunculated type.
3. If transfer to malignant

### Radiological features:

- Metaphyseal lesion.
- Mushroom-like stalk of the bony tumor. (connected to the bone)
- On x-ray the cartilaginous cap: which is the cartilaginous part of the tumor not seen (translucent). it is located around the bony part.
- Direction of the tumor → away from the bone.
- Start from the growth plate and Stops growing when patient stop to growth usually at 18 yrs.
- According to the shape of the neck of the tumor, we divide it into:



1. Pedunculated type: has long & thin neck.
2. Sessile type: has short & thick neck.

**Treatment:**

- Usually we do nothing, just reassure the patient.
- Surgery (just excision, no need for bone graft b/c it is surface tumor) & the surgery is indicated:
  1. pain associated with osteochondroma
  2. Presence of any complication (compression on nerves, vessels or tendons)
  3. Transforming to malignant "chondrosarcoma" (rare only 1%)
- **COSMESIS is NOT AN INDICATION FOR SURGERY**

Most common site for excision of osteochondroma is the knee because of the effect on ligaments and compression on vessels

How to know it transformed to malignant? By two things

1. sudden increase in the size of tumor (the patient will notice)
2. increase in the cartilage cup in X-ray

**Giant cell tumor**

- From bone marrow
- Occurs most commonly in young adults, 20-40 age groups.
- **BENIGN AGGRESSIVE TUMOR.** So, The patient must be followed every 3 months in the first year, every six months in the second year and once in a year after that.
- **It's can metastases to the lung. So it's important to get chest x-ray.**
- Origin: osteoclast, therefore it is sometimes called osteoclastoma.
- Very destructive tumor
- DD: bone cyst, aneurysmal cyst.

Giant cell tumor : can be a soft tissue tumor example : tendons or nerve sheaths and can be a bone tumor , so we say giant cell tumor of the bone b/c it's not specified to the bone only

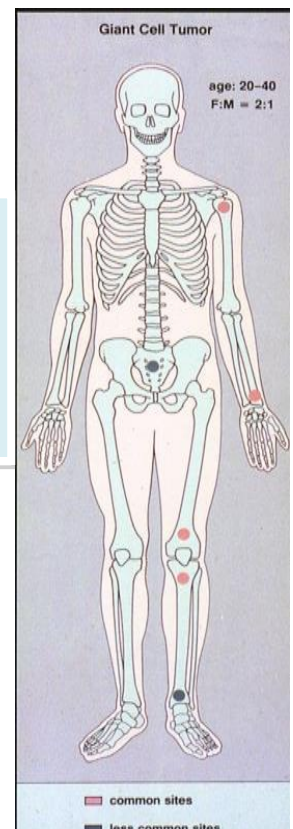
**Sites:**

1. Most common distal epiphysis of radius
2. Less common are distal tibia ,sacrum
3. Very bad one in sacrum because it will affect nerve roots

Most of GCT are located within the epiphyses of long bones, but they often extend into the metaphysis

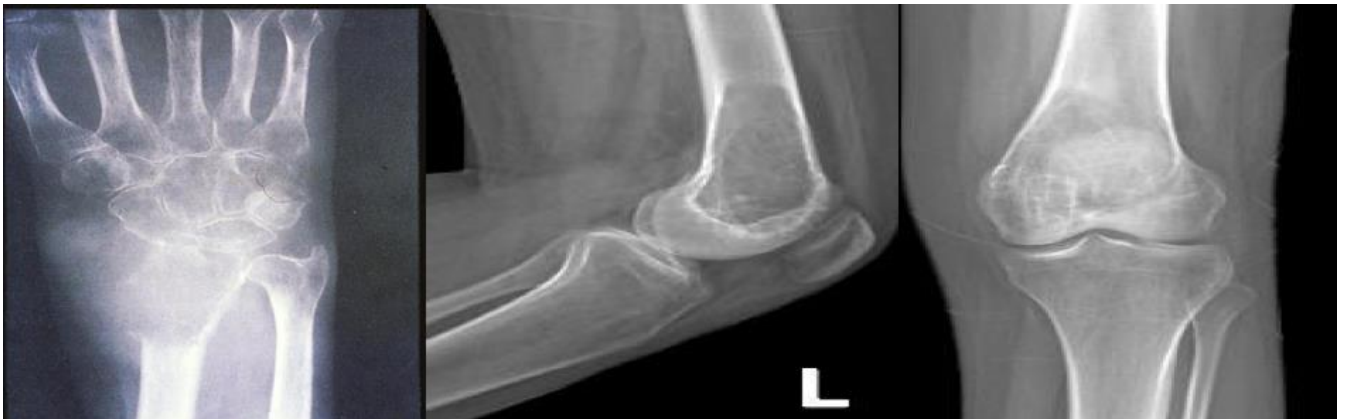**Presentations:**

1. Mostly patient present first with: pain, then swelling & later on pathological fracture.
2. Not clear
3. Osteopenia.



### Radiological features:

- Epiphyseal lytic lesion.
- No new bone formation b/c this new bone will be eaten by the osteoclast.
- Ill define margin.
- Radiograph shows lucent regions, lytic destruction of the bone with expansion of the cortex, without a sclerotic rim.
- Ill-defined borders when aggressive or pre-malignant
- Usually looks like a bone cyst, definite diagnosis made by biopsy.
- No marginal sclerosis.
- Soft tissue extension.



### Investigations:

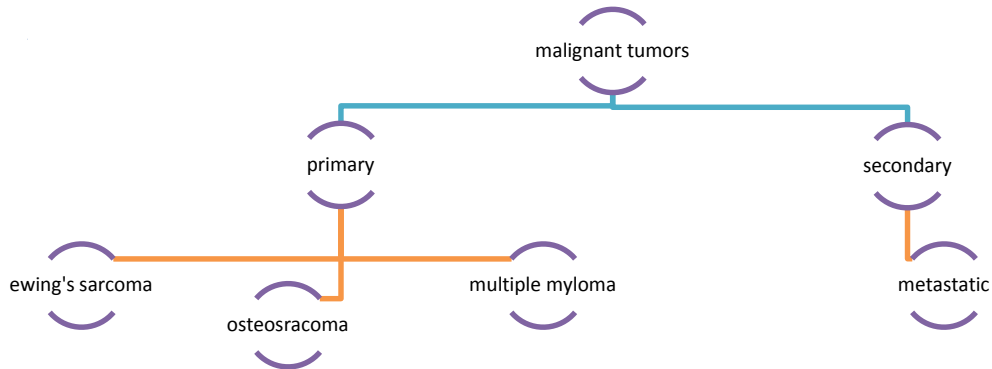
The assessment depends on :

1. Soft tissue extension: by MRI.
2. Joint extension: the articular cartilage is a very resistant against progression of the tumor from going to the joint.
3. Bone extension: by CT scan.
4. Further investigation:
  - Bone scan: for metastasis.
  - CBC: FOR ASSESSMENT of general condition of patient.
  - Biopsy: for confirmation it doesn't convert to malignant tumor.

### Treatment:

- **Generally, we do curettage and bone grafting**
- More details:
  - No place for conservative treatment
  - Excision followed by either bone graft or prosthesis (depending on site of tumor)
    1. If tumor in non weight bearing area (e.g. lower radius): radical excision, bone graft and arthrodesis for nearby joint
    2. If the tumor in weight bearing area (e.g. lower femur): excision and prosthesis (N.B. no bone graft here)

- Radiotherapy & chemotherapy are indicated in:
  - A. Frank malignancy.
  - B. Recurrence of the tumor: Recurrence rate is 50% ,it will be more aggressive with metastasis



**Ewing's sarcoma**

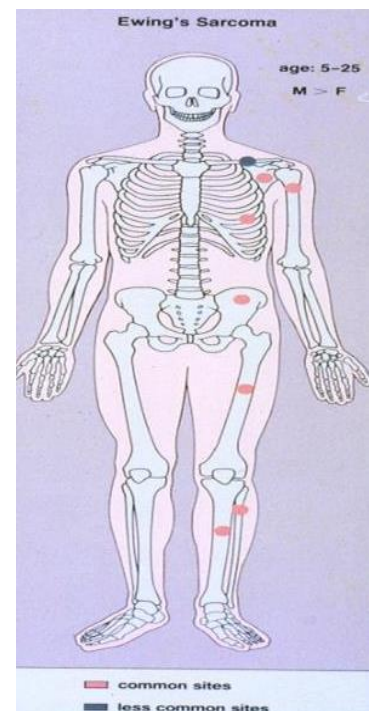
- Origin: from the endothelial lining of the bone marrow canal.
- Most of the Ewing's sarcoma is miss-diagnosed firstly as acute osteomyelitis. (Mimic the OM) because of systemic symptoms and elevated ESR and elevated c-reactive protein
- Young age group 5-25
- Pulmonary metastasis can occur.

**Sites:**

- It is the only bone tumor which takes it origin from diaphysis > so we will find a diaphyseal lesion
- The diaphysis of the femur are the most common sites followed by the tibia and humerus

**Presentations:**

- Very characteristic:
  - 1- Febrile patient.
  - 2- High WBC's.
  - 3- Local Pain & redness
  - 4- Ulceration of skin.
  - 5- swelling
- + Scapula, less commonly clavicle



Like the presentation of infection



**Radiological features:**

- X-ray: peel onion reaction
- You think it is osteomyelitis :
  - You do aspiration for drainage of pus > there will be no pus and you will find tumor tissue
  - You do biopsy > ewing's sarcoma
- So, it is a diaphysial lytic lesion ( not sclerotic)
- Ill defined
- Sometimes > soft tissue extension
- N.B. you can't differentiate it from osteo sarcoma unless you do biopsy

**Investigations:**

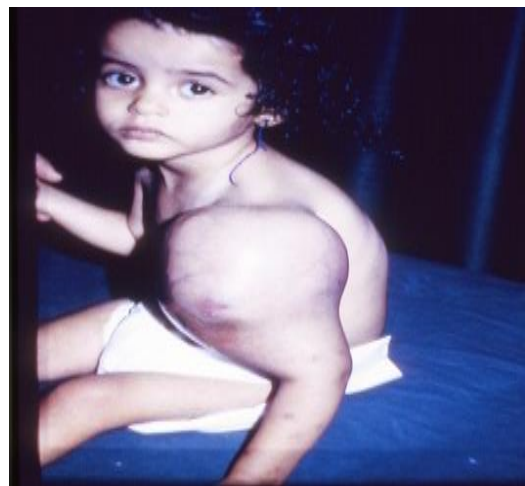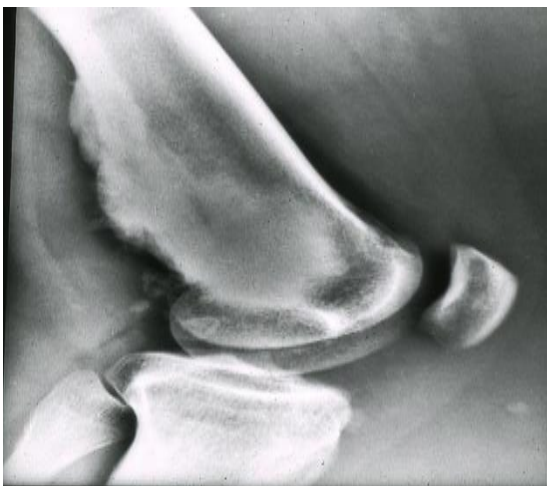- Definitive diagnosis is made by **MRI and biopsy**

**Management: timing is important**

- In history usually asymptomatic unless it cause pressure in vital structures or in late stage
- Blood investigations , ESR
- Radiology ( X-ray, bone scan, CT, MRI)
- Biopsy – same surgeon who will do surgery should take the biopsy- to avoid contamination then spreading the tumor

**Treatment:**

- It is sensitive to chemotherapy
- So start with chemotherapy to decrease the tumor in size so it will be easy to ecise it and control metastasis ( microcell) everywhere in the body as in bacteremia
- Tumor treated by operative excision and disarticulation and you may need amputation



## Osteosarcoma

- Most common primary malignant tumor.
- {remember the most common malignant tumor is metastatic}
- More common than Ewing's sarcoma
- 10- 25-year-old and Male > Female

### Sites:

- Arises from primitive bone-forming cells
- found in metaphysis unlike the Ewing which is in the diaphysis
- Around the knee.
- Common in the lower femur, upper tibia, and upper humerus.
- Less commonly clavicle

### Presentation:

- Patient present firstly with pain, then swelling, lastly pathological fracture (typical presentation of malignant tumor).
- Overlying skin is warm due to high vascularity.
- May present as cachectic ( in late and advanced cases)

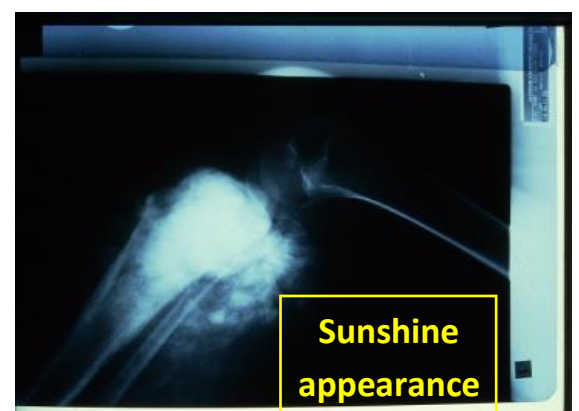
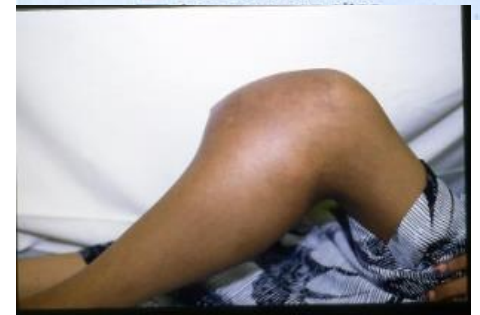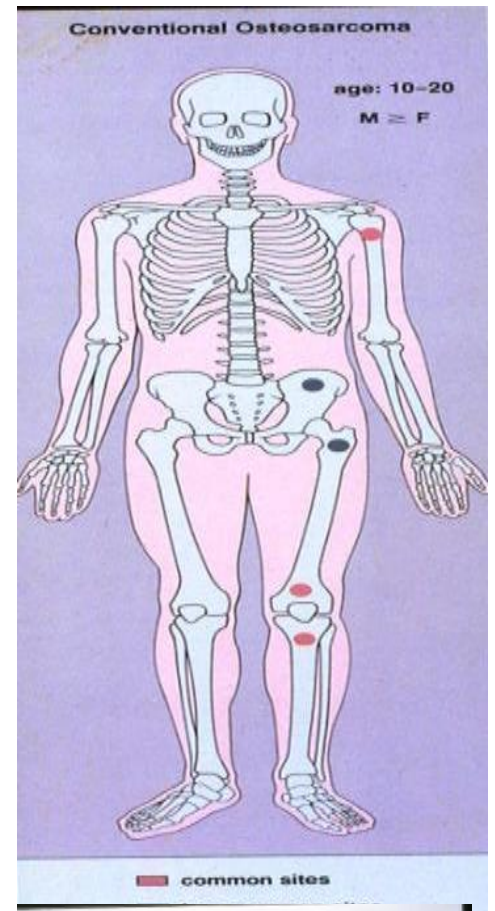
### Radiological features:

- Very dense
- Irregular medullary and cortical destruction of the metaphysis.
- Sun rise periosteal reaction (surrounded by low dense)
- Could be lytic or sclerotic."mixed"
- Ill defines no sclerotic margin.
- Metaphyseal lesion.
- Definite diagnosis made by biopsy

### Investigations:

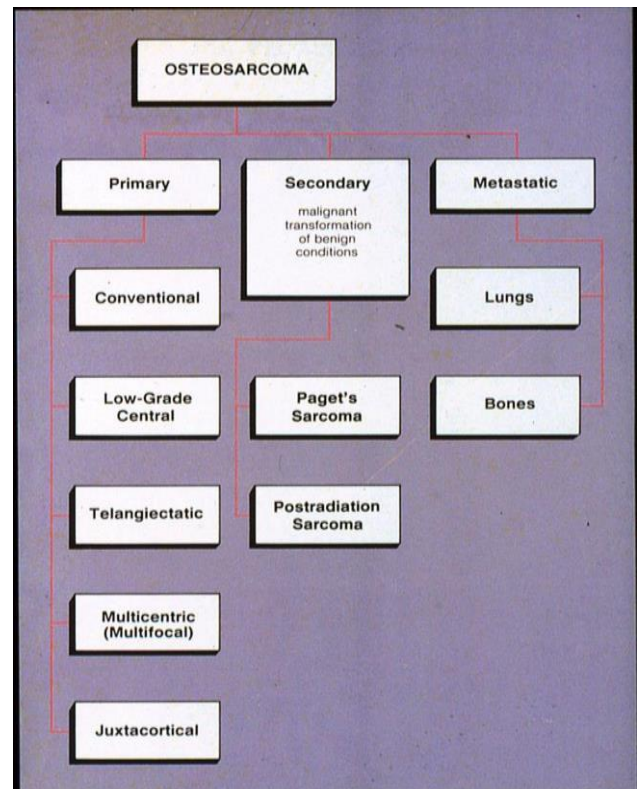
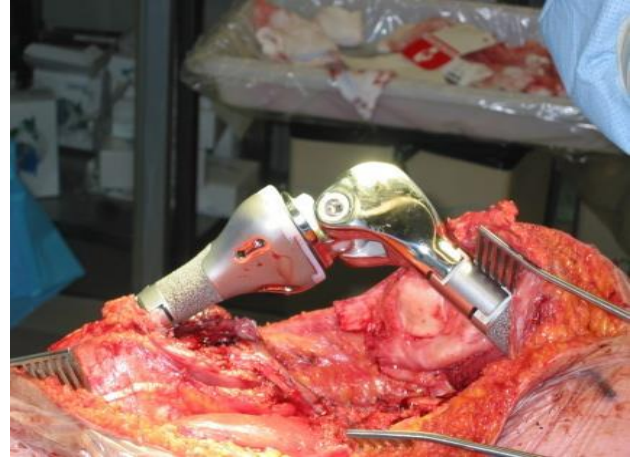- CT scan = bone extension
- MRI = soft tissue extension
- Bone scan = metastasis
- Search for metastasis

### Treatment:



### 1- Surgical intervention :

- **Limb salvage procedure:** which is radical excision of the affected bone & the affected compartments (e.g. flexor compartment of thigh , adductor compartment of the thigh ... etc )around the bone + followed by reconstruction (reconstruction may be :prosthesis , bone graft , or bone cement ) + lastly we do radiotherapy & chemotherapy
- Amputation : is indicated when the whole compartment around the bone is involved (e.g. the flexor, adductor & extensor compartment of the thigh). If there the Vessels involved you can do bypass graft. The presence of Pathological fracture.



2- in all stages: **chemotherapy**  
>surgery >chemotherapy

3- survival rate is 80 %

4- N.B. CHEMOTHERAPY TO AT LEAST  
↓ED SIZE OF THE MASS.



## Multiple myeloma

- Arise from plasma cells in the bone marrow. Plasma cells are responsible for antibodies production (gamma globulins).
- The most common primary malignant tumor.
- Arises from the plasma cells of the bone marrow
- Tumor of bone marrow, occurring in older adults > 50 and predominantly Males.
- **BENCE JONES PROTEINS test found in 24-hour urine collection. (highly suggest diagnosis)**
- Disseminates too many parts of the skeleton through the blood stream, thus usually multiple.

### Sites:

- Central bones (axial skeleton): skull, ribs, pelvic girdle. & spine.
- It may be solitary, multiple (commonest) or generalized osteoporosis (myelometosis: multiple myeloma + only generalized osteoporosis).

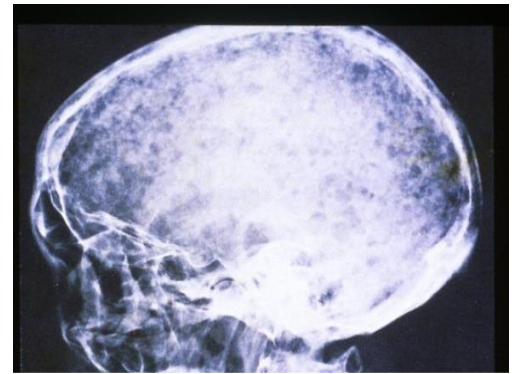
### Presentation:

- Pt ill (decreased immunity)
- Sclerotic (no more elasticity) so more prone to fractures
- In skull there will be pepper (lytic) & salt (sclerotic)... {if sclerotic → un flexible → easy to fracture) mottled appearance).
- P.t came with bone ach (backache) + osteopenia.
- More common in periphery than center
- **The only definitive diagnosis is bone marrow aspiration**

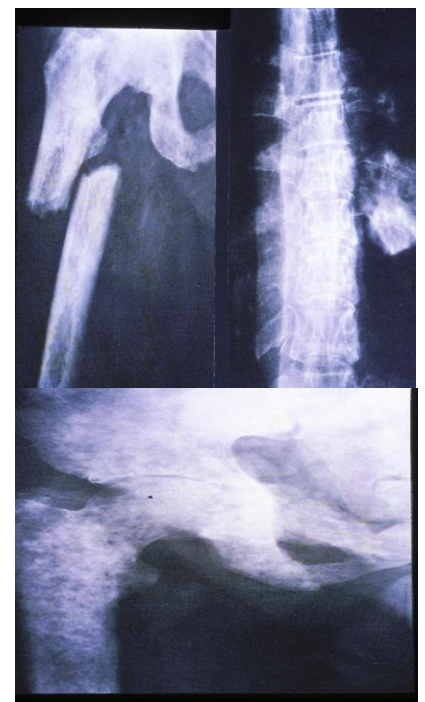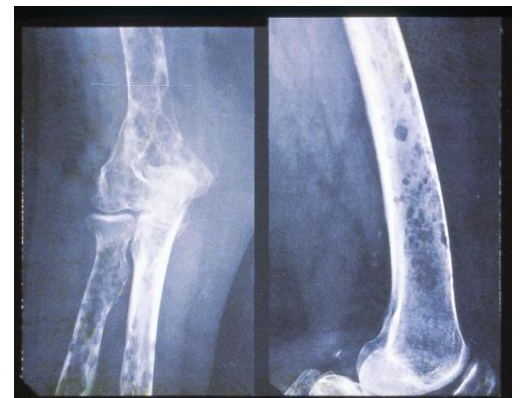### Treatment:

- Bone marrow transplant: Success rate is 30% and it Costs millions.
- Radiotherapy.
- Chemotherapy.

Done by  
oncologist



Salt and pepper appearance

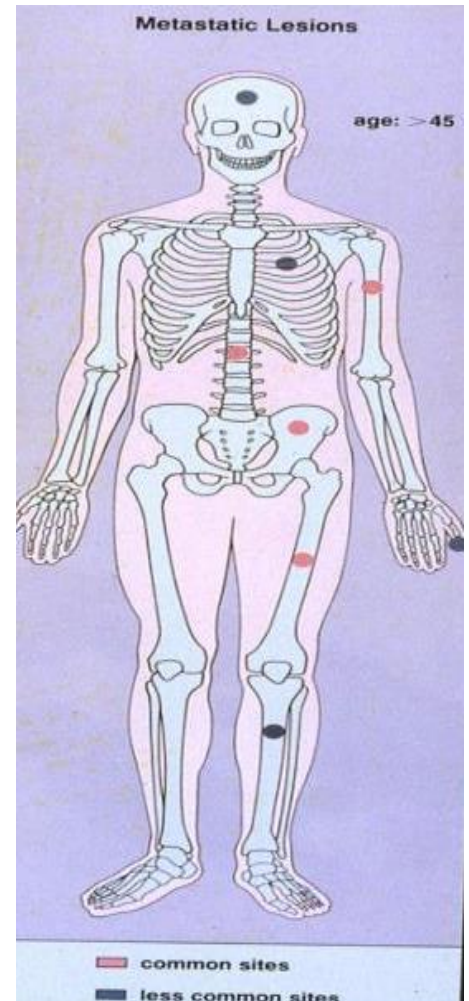


The rule of orthopedic surgeon is only when you have pathological fracture, do internal fixation.



## Metastatic lesions

- Tumor outside the bone. The most common tumors are: prostate, thyroid, breast, lung and kidney. if female patient, think about breast cancer
- More than 45 in age, F<M.
- More common than primary tumors in later adult life.
- Affect SAME SITE which affected by multiple myeloma.
- Take biopsy to know where is the primary
- If there is fracture do curettage first, then fixation.

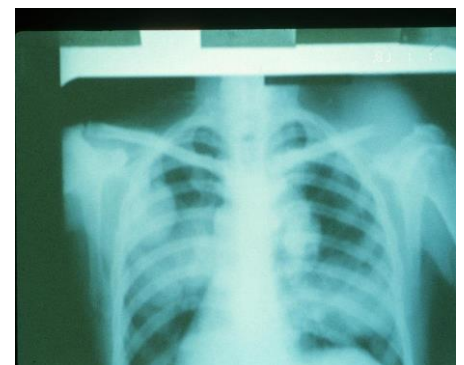


### Presentations:

- Patient present & primary tumor is known & the patient is treating from it.
- May present with secondary metastasis. So, we have to search for the primary and try to treat it.
- Usually metastasis occurs in the highly vascular bones e.g. vertebral body, ribs, pelvis, upper end of femur, and humerus.

### Radiological features:

- It may be solitary or multiple (common) or just osteoporosis (called carcinomatosis).
- It differs from multiple myeloma because it may present with lytic or sclerotic lesion while the M.M only present with lytic lesion.
- If the primary tumor is from the prostate → the lesion will be sclerotic.
- If the primary tumor is from the breast → the lesion will be lytic.

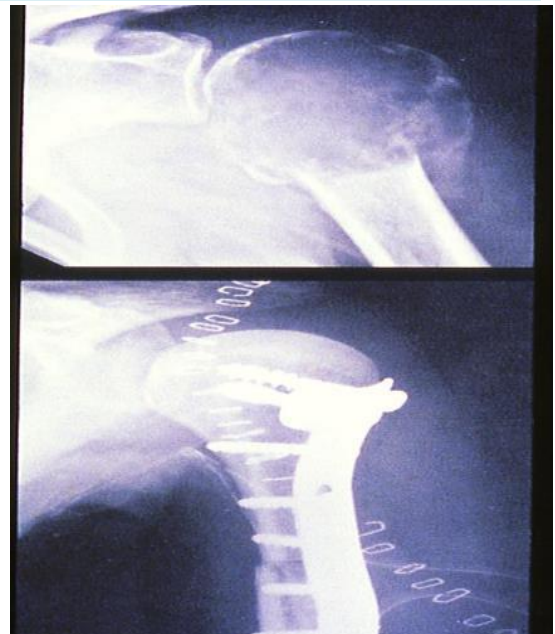


### Investigations:

- Same as Multiple myeloma
- X-ray shows decreased bone density (bone eaten away) with thinning of the cortex. Resembles bone cysts but the age group directs the diagnosis.
- Metastasis usually of the lung sarcoma
- CT- scan of the chest performed for definite diagnosis.

### Treatment:

- Same as multiple myeloma



you might think this is bone cyst but after biopsy it appears adenocarcinoma because of renal cell carcinoma, he undergone nephrectomy and after that the humerus was treated

## Summary

- Most common **bone Tumors** → BENIGN.
- Most common **benign** tumors → OSTEOPHYTOMA.
- Majority of **Malignant tumors** → METASTATIC of other tumors elsewhere in the body.
- Most common **primary malignant** tumors → M. MYELOMA THEN OSTEOSARCOMA.
- **Malignant Bone tumors** are called SARCOMA
- **Primary Malignant bone tumors** is minority
- **Benign bone tumors** do not invade the soft tissue nor do they affect the cortex
- Certain tumors have predilection for some bones (favorite places) it can be recognized by X-ray. E.g.: **Ewing's sarcoma** most commonly in the DIAPHYSIS. **Giant cell tumors** are almost always found in a subarticular position, i.e. METAPHYSIC location.

<b>Tissue of origin</b>	<b>Benign</b>	<b>Malignant</b>
<b>Bone ( osteogenic )</b>	Osteodostema Osteoblastoma	Osteosarcoma ( most common in epiphysis )
<b>Cartilage ( chondrogenic )</b>	Enchodroma Chondroblastoma	Chondrosarcoma
<b>Bone and cartilage</b>	Osteochondroma	
<b>Fibrous ( fibrogenic )</b>	Fibrous cortical defect	
<b>Bone marrow ( hematopoietic )</b>	Giant cell tumor	Multiple myeloma Ewing's sarcoma ( most common in diaphysis)
<b>Unknown ( lesion like tumor)</b>	Single cyst Aneurysmal bone cyst ( ABC )	
<b>Metastasize</b>		Metastasis

### MCQ

**1) Which one of the following tumors behave similar to acute osteomyelitis?**

- A) Multiple myeloma
- B) Ewing's sarcoma
- C) Metastasis tumor

**2) Which one of the following is the most common benign tumors?**

- A) Osteoid osteoma
- B) Endochondroma
- C) Osteochondroma

**Answers:  
1- B 2- C**