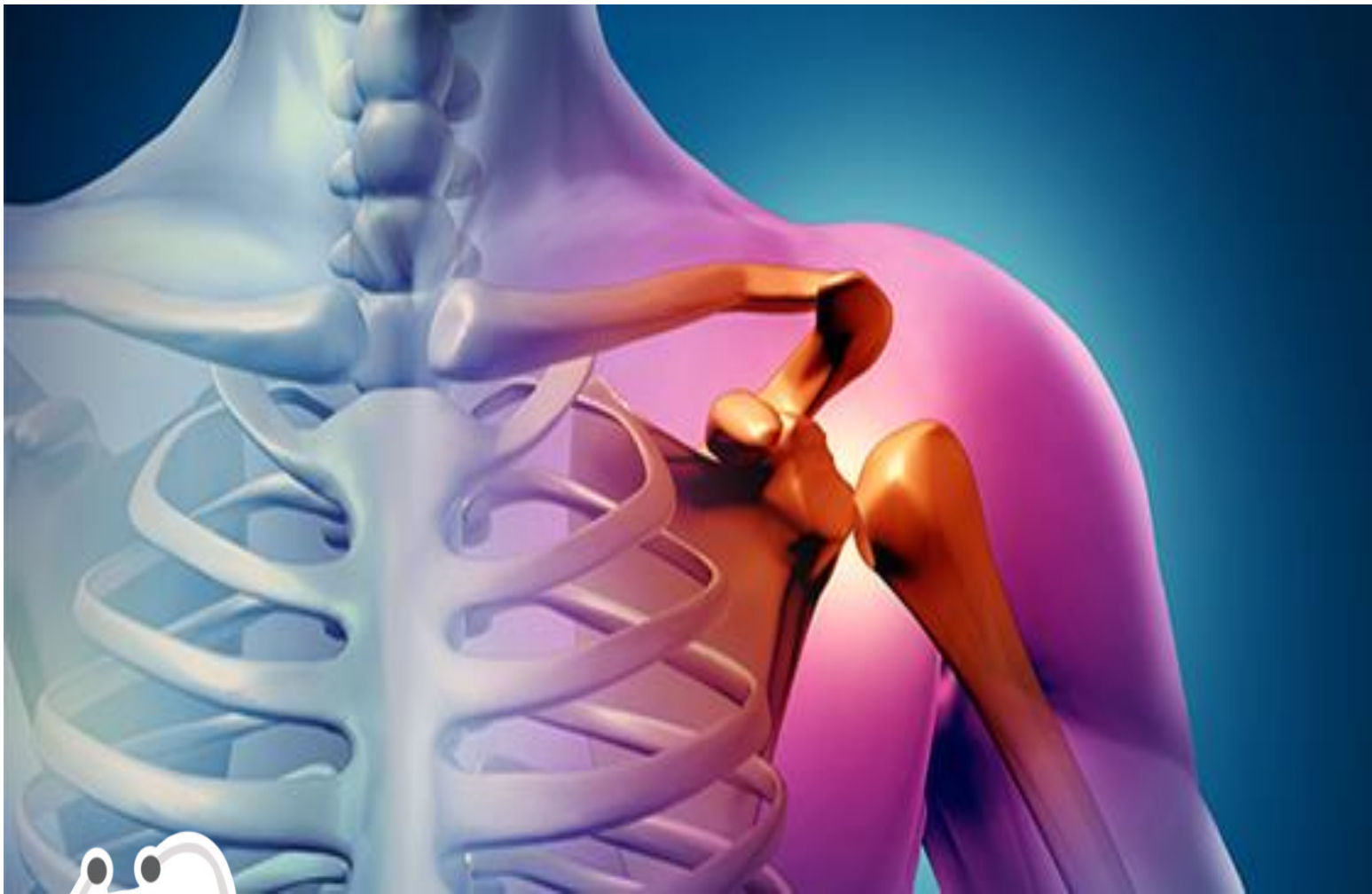


Orthopedics

15 Metabolic Bone Disorders



1st Edition:

Done By: Abdullah Bawazir (A1)

Revised by: Bader Alabdkarim (A1)

2nd Edition: Heba AlSharif (F1)

جامعة
الملك سعود
King Saud University



Color Code:

Slides

431 team work

Doctor's Notes

Arabic Words

Team Notes

Books' notes

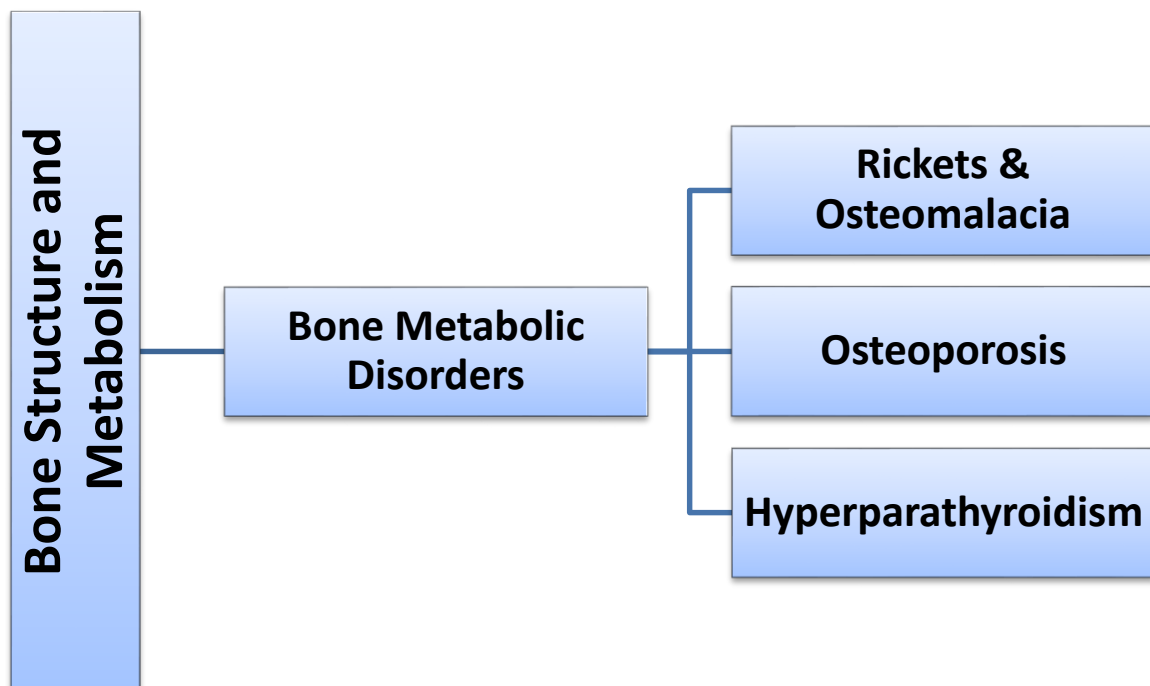
Important

Other Sources

Objectives

NOT GIVEN

MIND MAP



Orthopedic Surgeons and Bone:

- Orthopedic surgeons have to deal with all types of bone: healthy or diseased; and that's why they have to know about bone metabolism.
- Bones in the body protect vital organs.
- Bones give support to muscles and tendons.
- Bone may become weak in certain conditions.

Bone is a Living structure:

- There is a continuous activity in bone during all stages of life.
- There is continuous bone resorption and bone formation as well as remodeling. **The bone is an active organ just like the heart like the kidney in that there is a continuous metabolism.**
- **While osteoblasts are forming new bones, osteoclasts are removing the dead or aged ones. This process accelerates with aging and when estrogen levels drop (Ex, menopause) the rate of formation decrease and the rate of loss increase. Opposite happens in the childhood where bone formation is higher than resorption.**
- That means bone is not only for protection and support but its contents play an important part in blood homeostasis.

Bone metabolism is controlled by many factors:

- Calcium.
- Phosphorus.
- Parathyroid gland.
- Thyroid gland.
- Estrogen.
- Glucocorticoid hormones.
- Intestinal absorption (**patient with malabsorption such as celiac can't absorb calcium**).
- Renal excretion (**because all components of blood gets filtered by the kidney including the calcium, e.g. tubular necrosis, or glomerular nephropathy they will not benefit from the dietary or supplemental calcium or Vitamin D intake until this condition is corrected**)
- Diet (**inadequate food intake affects the calcium level**)
- Vitamin D (**nowadays VD is very important for adrenal glands, brain, muscles, more likely it affects everything in our body**)
- Sun exposure.

Bone Structure

Bone is formed by:

Bone matrix:

- 40% organic: collagen type1 (responsible for tensile strength).
- 60% Minerals: mainly Calcium hydroxyapatite, Phosphorus, and traces of other minerals like zinc.

Cells in bone: osteoblasts, osteoclasts, osteocytes. (Osteoblast daily form 10000 new cells while osteoclast removes 11000 in adults).

Plasma levels

- **Calcium:** 2.2-2.6 mmol/l
- **Phosphorus:** 0.9-1.3 mmol/l
- **Alkaline phosphatase:** 30-180 units/l is elevated in bone increased activity like during growth or in metabolic bone disease or destruction (it shows how much activity in the bones, when increased it means increased turnover).
- **Vitamin D level:** 70-150 nmol/l

(Both absorbed by intestine and secreted by kidney in urine)

Parathyroid Hormone (PTH)

- Production levels are related to serum calcium levels.
- PTH secretion is increased when serum calcium is low.
- **Action of PTH:** it increases calcium levels in the blood by increasing its release from bone & increase absorption from the intestine & and increase reabsorption from the kidney (also increase secretion of phosphorus).

Hyperparathyroidism:

- Primary: Adenoma of the gland
- Secondary: as a result of low calcium
- Tertiary: as a result of prolonged or sustained stimulation = hyperactive nodule or hyperplasia.

Calcitonin

- Is secreted by C cells of thyroid gland.
- Its secretion is regulated by serum calcium.

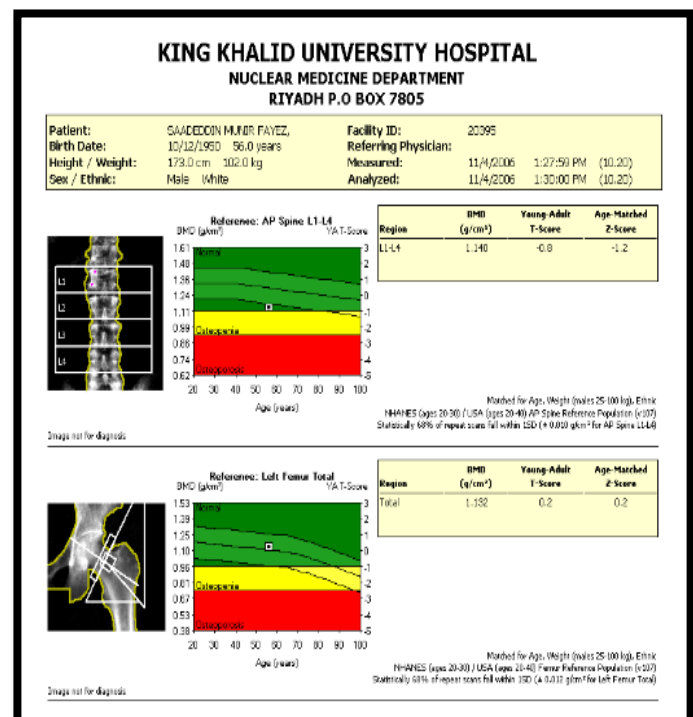
- Its action is to cause inhibition of bone resorption and increasing calcium excretion by this it causes lowering of serum calcium.

Bone Strength

- Bone strength is affected by mechanical stress which means exercise and weight bearing.
- Bone strength gets reduced with menopause and advancing age.
- Reduced bone density on X rays is called **Osteopenia**. (The opposite is **osteosclerosis**).
- Osteopenia is also a term used to describe a degree of reduced bone density, which if advanced becomes **Osteoporosis**.
- X-ray is not accurate because sometimes the technician put overexposure or underexposure.

Bone Density

- Bone density is diagnosed at current time by a test done at radiology department called: **DEXA scan** (they do it in three areas: vertebrae, wrist, and neck of femur).
- DEXA is (Dual Energy X ray Absorbtiometry)
- However: increased bone density does not always mean increased bone strength, as sometimes in Brittle bone disease (which is a dense bone) is not a strong bone but fragile bone, which may break easily.
- Green area is normal Density, range is (0-1) or (0 to -1).
- Yellow area is osteopenia Range from -1.5 to -0.2.
- Red area is osteoporotic Less than -2.5.



Rickets & Osteomalacia

- Different expressions of the same disease, which is: **Inadequate mineralization.**
- **Rickets:** affects Areas of endochondral growth in **children.**
- **Osteomalacia:** All skeleton is incompletely calcified in **adults.**

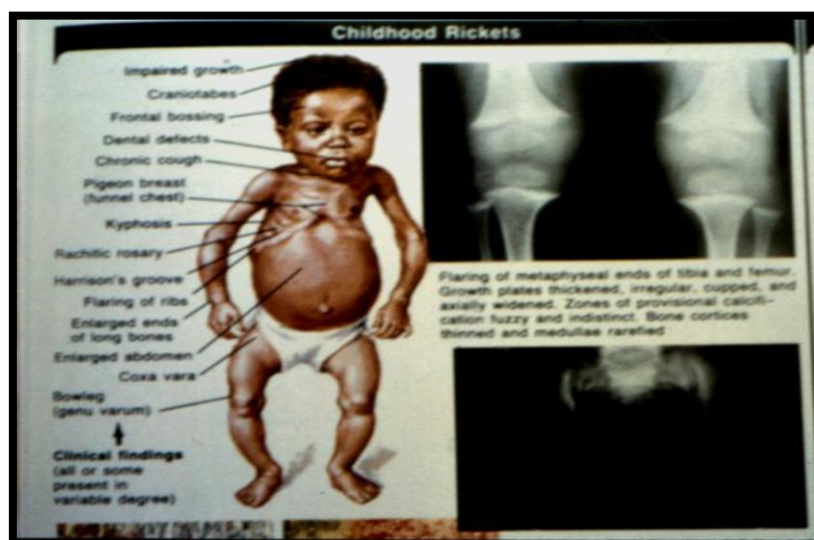
Rickets:

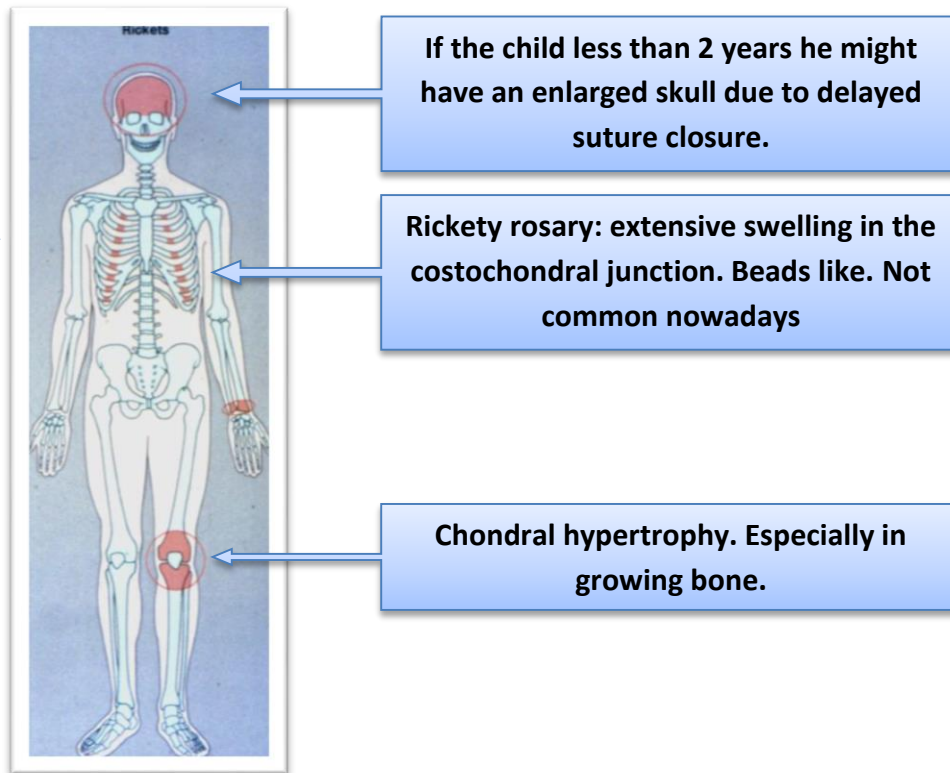
Causes: “for both Rickets & Osteomalacia”

- Calcium deficiency.
- Hypophosphataemia.
- Defect in Vitamin D metabolism (nutritional, underexposure to sunlight, intestinal malabsorption, liver & kidney diseases).

Signs & Symptoms:

- Child is restless, babies cry without obvious reason. (e.g. when changing diaper).
- Failure to thrive.
- Muscle weakness.
- In severe cases with very low calcium: tetany or convulsions.
- Joint thickening (**hypertrophy**) especially around wrists and knees.
- Deformity of limbs, mostly Genu varum or Genu Valgum.
- Pigeon chest deformity, Rickety Rosary, craniotabes.



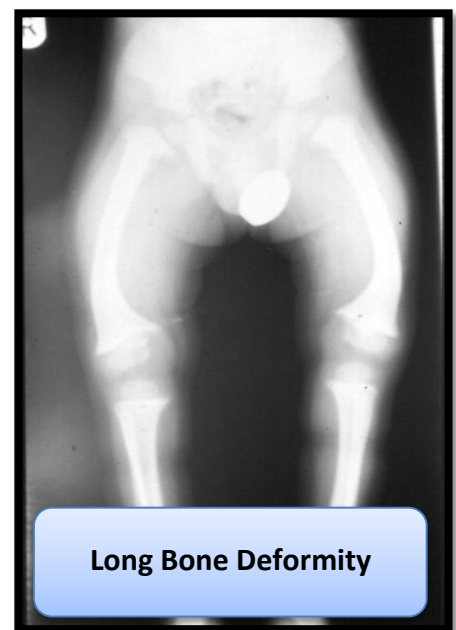
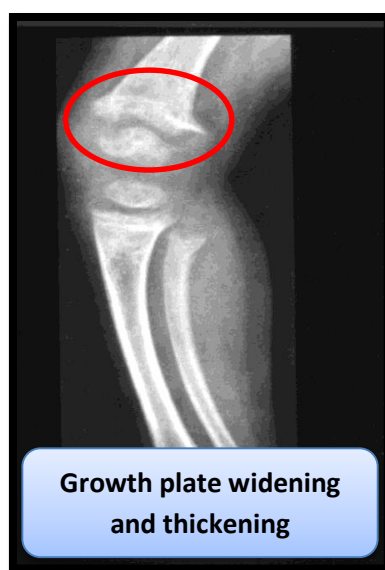
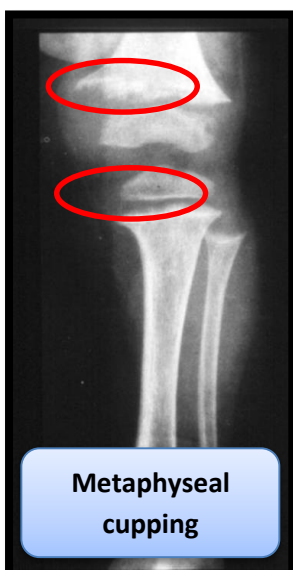Biochemistry (most important investigation):

- **Hypocalcaemia, Hypocalciuria, High alkaline phosphatase.** (If alkaline phosphatase is normal, it is most likely not metabolic bone disease).

X-Ray Findings:

1. Growth plate widening and thickening.
2. Metaphyseal cupping.
3. Long bones deformities.

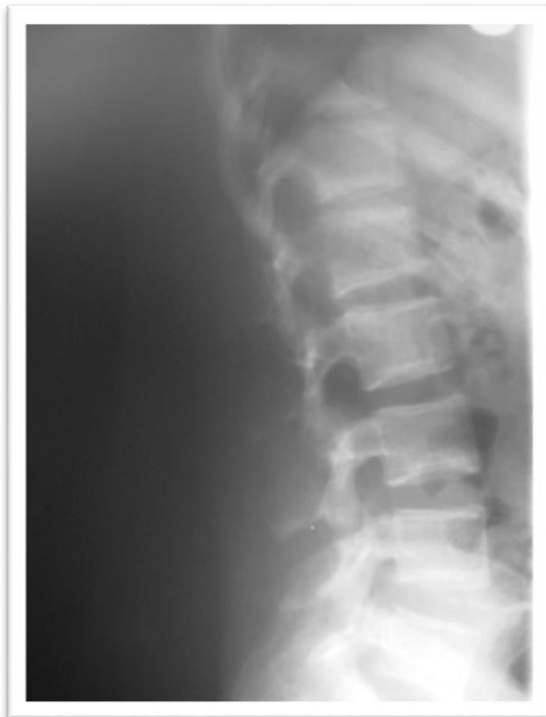

Osteomalacia: Metabolic Bone Disorder in **Adults**

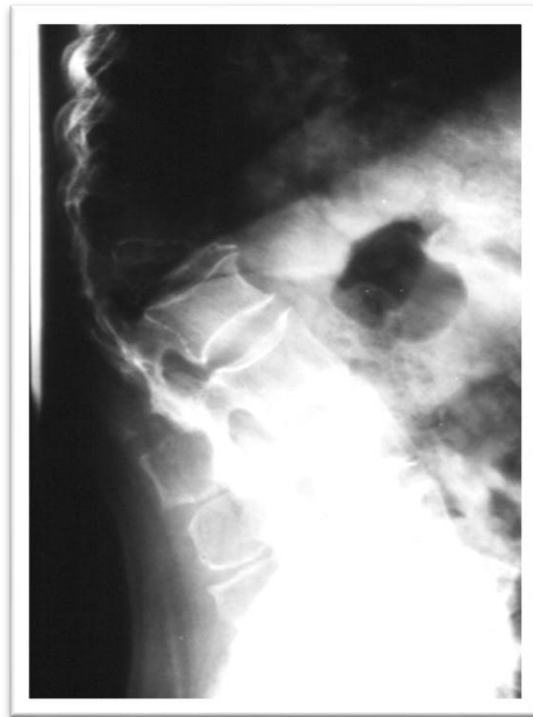Signs & Symptoms:

The difference here is that the growth is stopped in Adults unlike children so no growth related symptoms here.

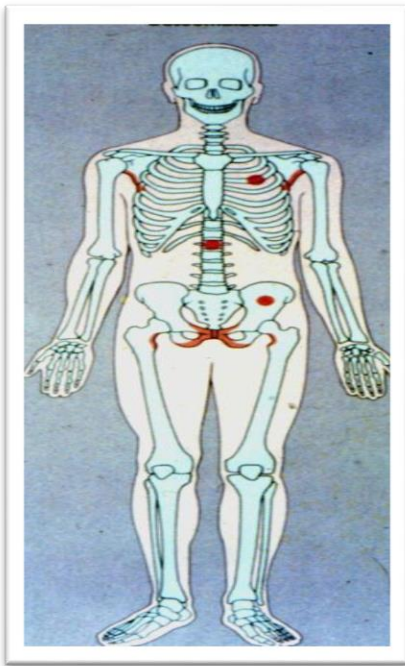
- Generalized bone pain, mainly backache (because the back bears body during walking).
- Muscle weakness.
- Reduced bone density.
- Vertebral changes: Bi-concave vertebra, vertebral collapse, kyphosis (when bone become soft the convex shape of intervertebral disc will be concave then any press on vertebrae with this shape will cause fracture).
- Stress fractures (in children with stress the bone will bend but in adult with much stress it won't bend it will fracture): Loosers zones in scapula, ribs, pelvis, and proximal femur.



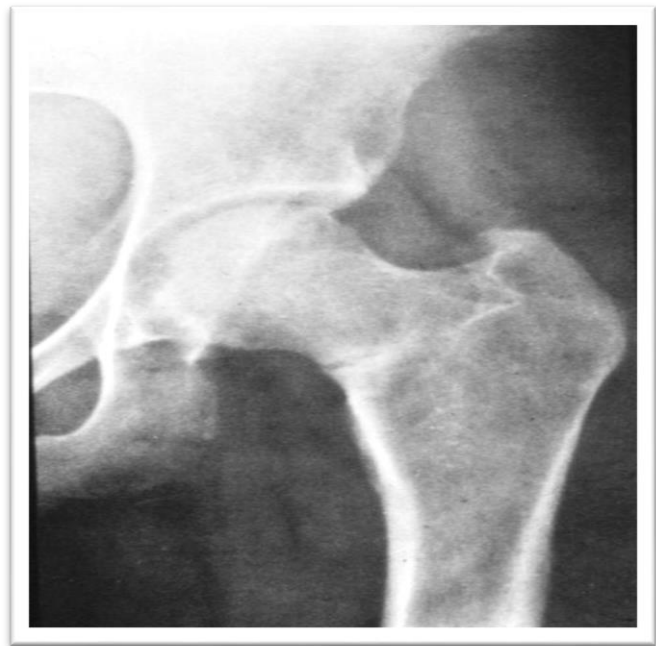**Bi-concave vertebra from above and below, any fall can cause compression fracture
(Looser zone)**



Kyphosis
"In advanced stages "



No changes in skull, no changes in costochondral junction.
Might be stress fracture in ribs, neck of femur.



Femoral head stress fracture
"MCQ"

Treatment:

You have to make sure first that the patient does not have systemic disease like malabsorption in intestine or kidney disease (Because there is no point of treatment without treating the primary cause).

Rickets:

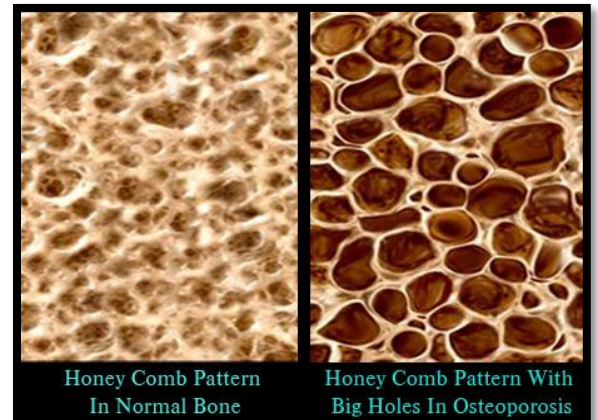
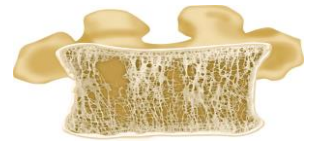- Adequate Vitamin D replacement
- Sun exposure
- Correct residual deformities (if there is Genu varum or Genu Valgum and did not improve after the treatment we do corrective osteotomy).

Osteomalacia:

- Vitamin D + Ca
- Fracture management
- Correct deformity if needed
- Exclusion of other diseases

Osteoporosis

- **Decreased bone mass:** decreased amount of bone per unit volume and this causes reduced density (Loss of bone unite unlike osteomalacia which affects bone mineralization).
- **Mineralization is not affected.**
- Mainly post-menopausal (drop in Estrogen levels) and age related
- The danger is not in osteoporosis itself but in the complications that it might cause.
- Osteoporosis is painless disease unless it causes fracture.
- Osteoporotic fracture nowadays is called fragility fracture.



Primary Osteoporosis:

Post-Menopausal Osteoporosis

- Due to **rapid decline in estrogen level.**
- This results in increased osteoclastic activity.
- Normal bone loss usually 0.3% per year.
- Post-menopausal bone loss 3% per year.

❖ Risk Factors:

- Race (Caucasian)
- Hereditary
- Body build (thin people)
- Early menopause
- Smoking/ alcohol intake/ drug abuse
- Calcium intake (low Ca)

Senile osteoporosis

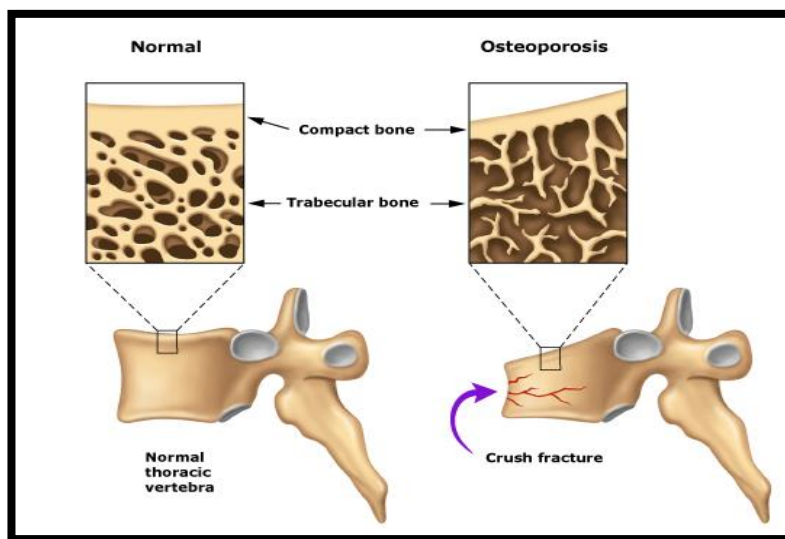
- Usually by 7th to 8th decades there is steady loss of at least 0.5% per year.
- It is part of physiological manifestation of aging.

❖ Risk factors:

- Male menopause (Decreased Testosterone)
- Dietary: less calcium and vitamin D and protein.
- Muscle weakness.
- Reduced activity.

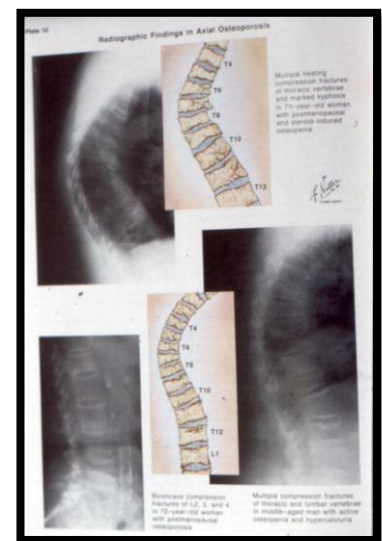
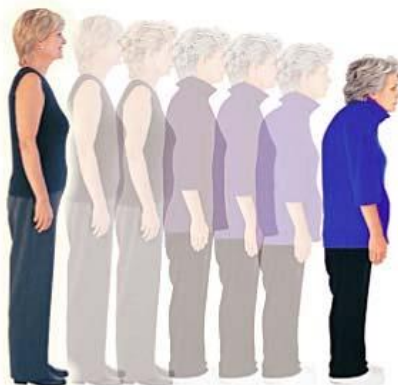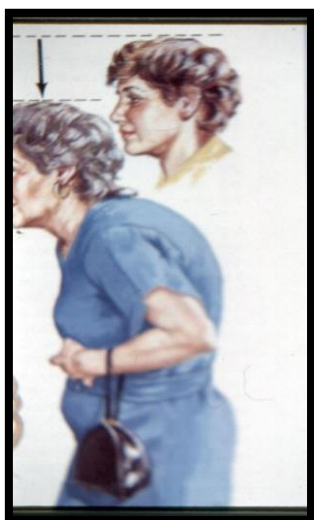Clinical Features of Osteoporosis:

- Osteoporosis is a Silent disease.
- Osteoporosis is Serious due to possible **complications mainly fractures** (common sites are dorsal spine, wrist, and neck of femur).
- Osteoporosis does not cause pain usually.
- Osteoporosis causes gradual increase in dorsal kyphosis.
- Osteoporosis leads to loss of height.
- **Osteoporosis is not osteoarthritis**; but the two conditions may co-exist.



How does kyphosis and loss of height occurs?

With osteoporosis the anterior part of the vertebra narrows which leads to kyphosis and loss of height.



Osteoporotic Fractures (Fragility fractures):

- They are Pathological fractures.
- Most common is osteoporotic compression fracture (OVC #s).
- Vertebral micro fractures occur unnoticed (dull ache).
- **Most serious is hip fractures** (increased vascularity → bleeding might cause death) (Present to the ER unable to walk).
- Also common is wrist fractures (Colles fracture).

Secondary Osteoporosis:

It happens most of the time in younger patient e.g. 45 years old, so in younger patient with osteoporosis suspect a secondary cause.

- **Drug induced:** steroids, alcohol, smoking, phenytoin, heparin.
- Hyperparathyroidism, hyperthyroidism, Cushing's syndrome, gonadal disorders, malabsorption, mal nutrition.
- **Chronic diseases:** RA, renal failure, tuberculosis.
- **Malignancy:** multiple myeloma, leukemia, metastasis.

Disuse Osteoporosis:

- Occurs locally adjacent to immobilized bone or joint.
- May be generalized in in bed ridden patients.
- Awareness of and attempts for prevention are helpful (by moving the limb from time to time).

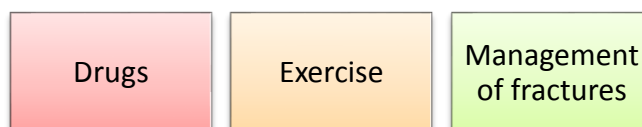
Osteomalacia vs. Osteoporosis

Osteomalacia	Osteoporosis
Any Age	Post-Menopausal, old age
Patient is ill	Not ill
General ache	Asymptomatic until fracture
Weak muscles	Normal
Looser zones	Nil
Alkaline Ph increased	Normal
PO\$ decreased	Normal

Prevention of Osteoporosis:

- Prevention of osteoporosis should start from **childhood**
- Healthy diet, adequate sunshine, regular exercise, avoidance of smoking or alcohol, caution in steroid use
- At some time in the past there was a recommendation of HRT (Hormone replacement Therapy) for post-menopausal women? And men; but now this is discontinued (**because of the side effect**).

Management:



Drug Therapy:

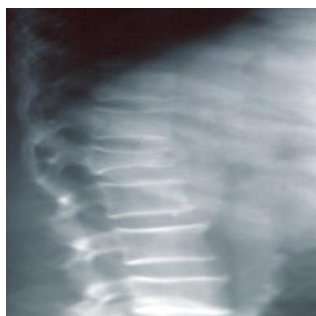- **Estrogen** has a definite therapeutic effect and was used extensively as HRT but cannot be recommended now due to serious possible side effects (**such as tumors**).
- Adequate intake of **calcium and vitamin D** is mandatory
- Drugs which **inhibit osteoclast activities**: e.g. Bisphosphonates like sodium alendronate FOSAMAX , BONVIVA
- Drugs that **enhance osteoblast activities**: bone stimulating agents like PROTELOS, FORTEO. The problem in this type of medication is the risk of malignancies.
(**New guidelines state that they should receive both which inhibit osteoclast and stimulate osteoblast activity**)

Exercise in Osteoporosis:

- Resistive exercises
- Weight bearing exercises
- Exercise should be intelligent to avoid injury which may lead to fracture

Management of fractures in Osteoporosis:

Use load shearing implants in fracture internal fixation instead of plating. (**We don't depend on the metal alone because with time the metal may get out of the bone or break**)



Vertebral Osteoporotic Compression Fracture (OVC)

Management of OVC:

Pain relief

Prevention of further fractures

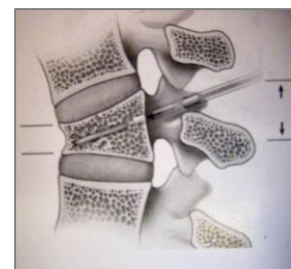
Prevention of instability

Vertebroplasty

Kyphoplasty

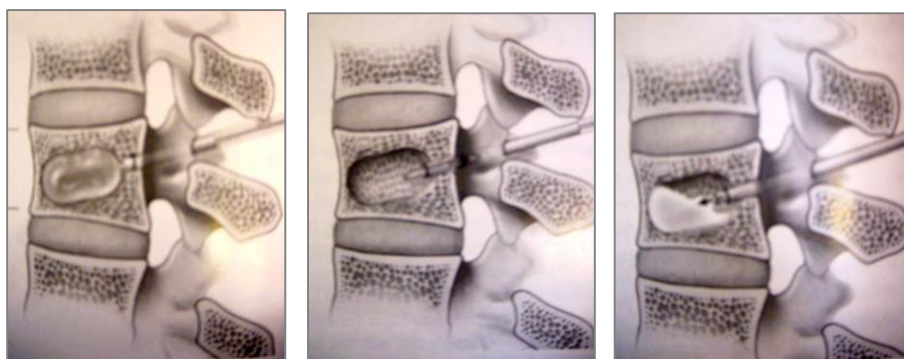
Vertebroplasty:

- Is the injection of bone cement into the collapsed vertebra.
- The injection is done under X ray control (image intensifier) by experienced orthopedist or interventional radiologist.
- It results in immediate pain relief.
- It helps to prevent further OVF.
- Possible complication is leakage of cement into spinal canal (nerve injury) or venous blood (cement PE).



Kyphoplasty:

- Is the injection of bone cement into the collapsed vertebra AFTER inflating a balloon in it to correct collapse and make a void (empty space) into which cement is injected.
- It is possible that some correction of kyphosis is achieved.
- It is safer because cement is injected into a safe void.

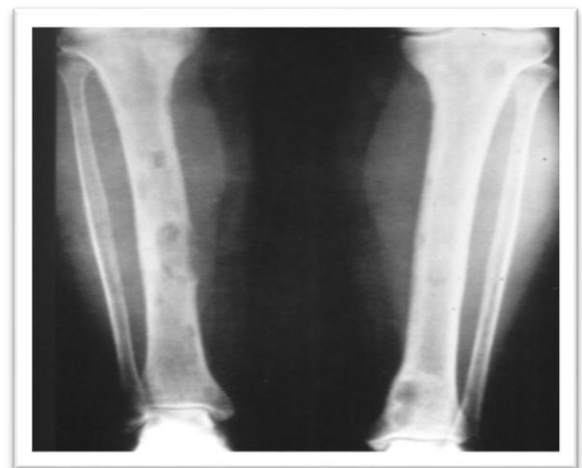
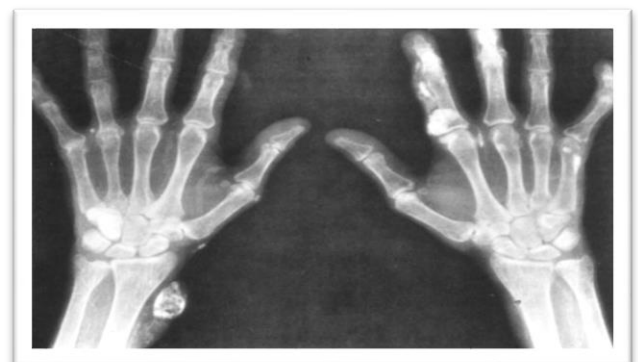
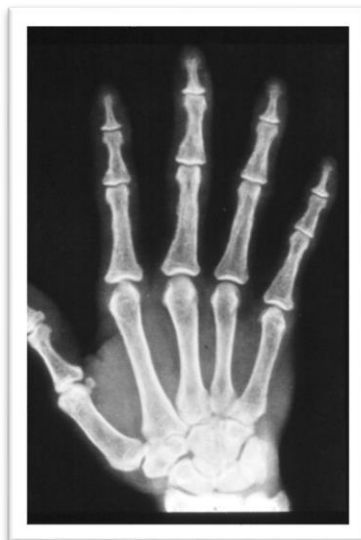
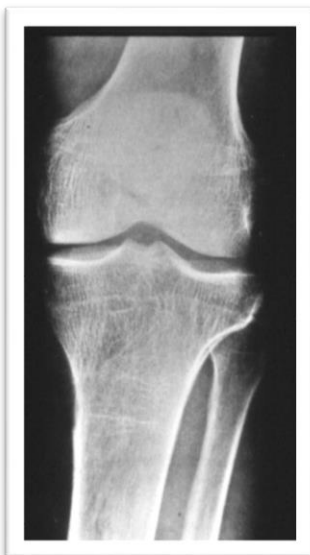Hyperparathyroidism

- Excessive PTH secretion: primary, secondary or tertiary.
- Leads to increased bone resorption, sub periosteal erosions, osteitis manifested by fibrous replacement of bone.
- Significant feature is hypercalcemia.
- In severe cases: osteitis fibrosa cystica and formation of Brown tumors.

Radiological Changes:

- Generalized decrease in bone density.
- **Sub-periosteal bone resorption** (scalloping of metacarpals and phalanges).
- Brown tumors (too much bone reuptake causing areas of empty bone with bleeding, this blood will accumulate like paste forming what calls brown tumors).
- Chondrocalcinosis (wrist, knee, shoulder).



Management of Hyperparathyroidism:

By management of the cause:

- Primary hyperparathyroidism due to neoplasm (adenoma or carcinoma) by excision.
- Secondary hyperparathyroidism by correcting the cause of hypocalcaemia.
- Tertiary hyperparathyroidism by excision of hyperactive (autonomous) nodule.
- Extreme care should be applied after surgery to avoid hypocalcaemia due hungry bones syndrome.

MCQ's

1. A child comes to your clinic presenting with Rickets, X-ray shown. Identify the sign present on the X-ray?

- A) Widened epiphysis
- B) Looser's zone
- C) Rickets Rosary

Q1=A

2. Old pt. falls in bathroom, turns out he fractured his hip. What is the most likely cause?

Osteoporosis

