

OCULAR EMERGENCIES

BY

PROF. MUBARAK F. AL-FARAN, MD

Sudden Loss of Vision

No Redness or Pain

1. Unilateral Blindness

- CRA embolus
- Traumatic damage to optic nerve

2. Unilateral decrease in vision

- CRV thrombosis
- Vitreous hemorrhage
- Acute keratoconus

Sudden Loss of Vision

No Redness or Pain

3. Unilateral visual field loss

- BRA embolus
- BRV thrombosis
- RD

4. Bilateral visual decrease in vision

- Stroke
- Hemorrhage
- Trauma of optic radiation, optic tract
- ↑ I.C.P.
- Potential CO

Progressive Visual Loss

Without Redness or Pain

1. Cloudy vision
 - Corneal opacity
 - Corneal dystrophy
 - Cataract
 - Vitreous opacities

Visual Loss

With Redness or Ocular Complaint

- Keratitis
- Iritis
- Cyclitis

Cloudy Vision

With Eye Pain and Headache

- CACG, secondary glaucoma to rubeosis, etc
- Optic neuritis
- Endophthalmitis

Visual Loss

With Hyperemia, Hypotony

- Choroidal detachment
- Phthisis bulbi following inflammations,
perforating injury

Visual Loss

With Hyperemia and Exophthalmos

- Orbital cellulitis
- Pulsating exophthalmos
- Cavernous sinus thrombosis

Symptoms

1. Disturbance of vision

- ↓ V.A

⇒ Sudden ⇒ Gradual

- Unilateral

- Unilateral

- Bilateral

- Bilateral

Symptoms

1. Disturbance of vision

- Abnormal V. Field
 - Unil., in retinal, optic nerve disease
 - Bilateral in symmetric defects or post. to chiasm

Symptoms

1. Disturbance of vision

- Floaters, R/O RD
- Cortical blindness, bilateral lesions of occipital lobe
- Diplopia - Physiologic
 - Ocular muscle weakness

Symptoms

2. Pain in one or both eyes or in the head

- Superficial FB
- Deep pain in the eye
- Headache
- Photophobia

Symptoms

3. Abnormal secretion from eye

- Lacrimation
- Mucus
- Pus
- Dry eyes

Physical Signs described by Pt. As Symptoms

1. Red eye - Serious

- Conj. injection
- Ciliary injection
- Subconj. hemorrhage

Physical Signs described by Pt. As Symptoms

2. New growth
3. Abnormal position of eyes or eyelids
4. Protrusion of globe
5. Widened palpebral fissures
6. Pupillary abnormality

Causes of sudden persistent Unilateral ↓ of vision (serious)

1. Angle closure glaucoma
2. Iridocyclitis
3. Vitreous hemorrhage
4. Retinal artery or vein closure
5. Optic neuritis

Causes of gradual unilateral loss of vision

1. Corneal opacity
2. Glaucoma
3. Cataract
4. Vitreous opacity
5. R.D
6. Macular degeneration

Sudden bilateral loss of vision- Uncommon

1. Usually after inquiry starts
one eye followed by other
2. Suggestive of -
 - Hysteria
 - Toxic effects of drugs

Gradual bilateral loss of vision

1. Any ophthalmic disorder
 - If V.A. ↓ Peripheral vision is intact - Disorder is ant. to chiasm
 - If peripheral vision ↓ - Disorder may be at or post. to chiasm

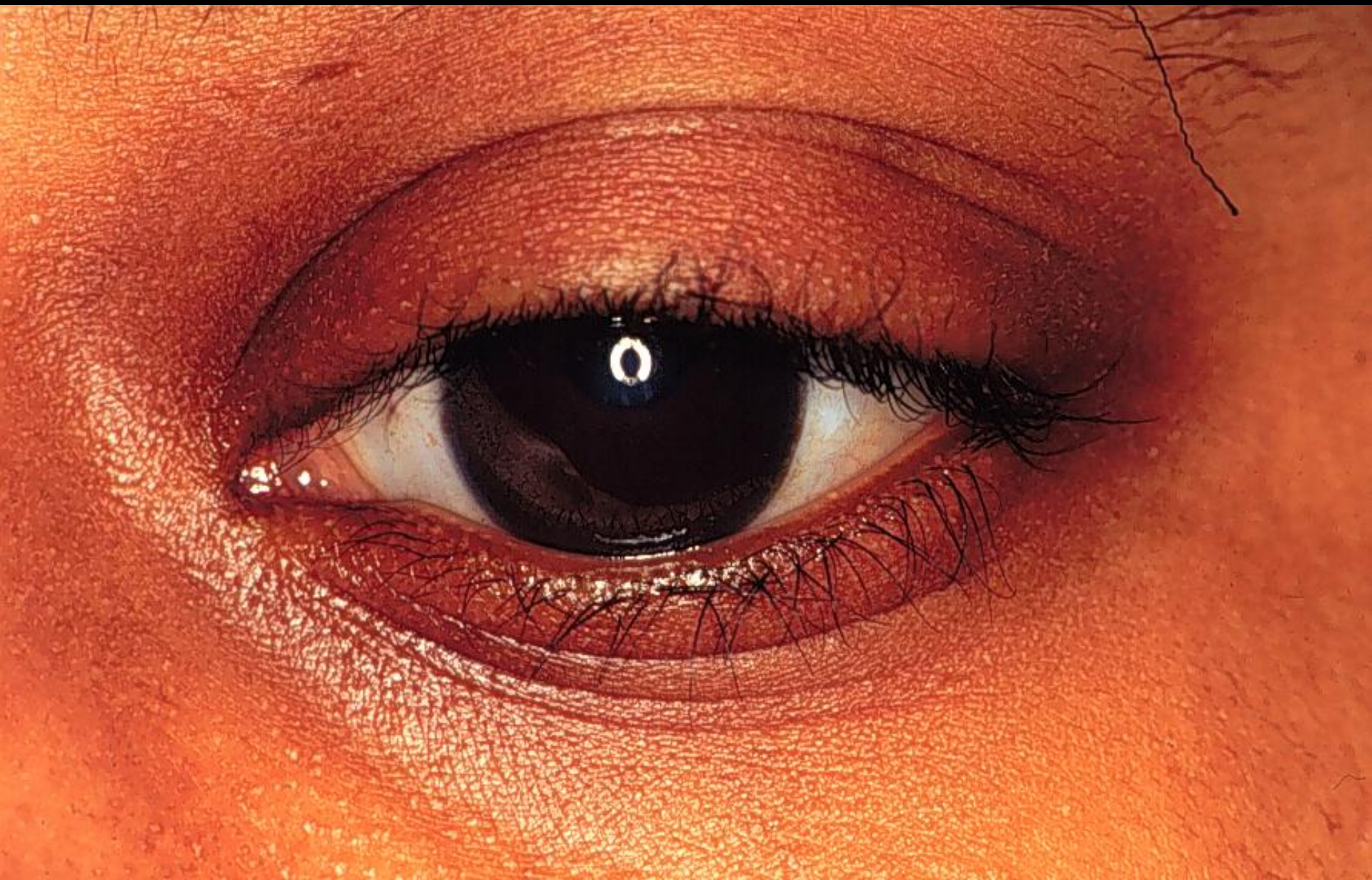Pain - Superficial F.B.

Deep severe pain: (most important)

1. Inflammation of ciliary body
2. Rapid in ↑ IOP (ACG)

Abnormal Secretion

1. Pus - M.P.C.
2. Tearing - ? Epiphora
3. Dry eye, keratoconj. Sicca, etc.





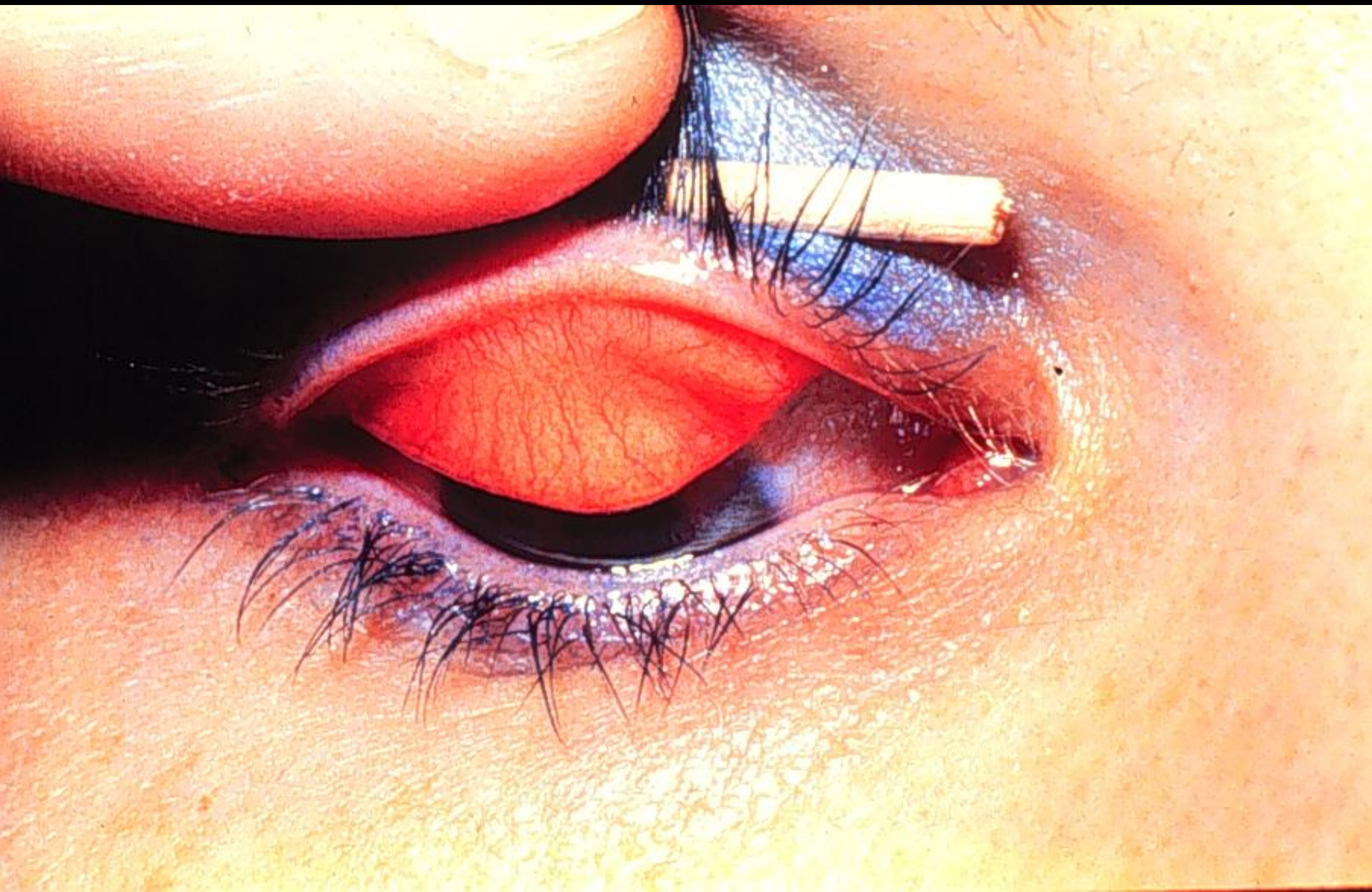
The Red Eye

NONTRAUMATIC RED EYE: POSSIBLE CAUSES

- Conjunctivitis
- Iritis (uveitis)
- Corneal inflammation
- Acute glaucoma

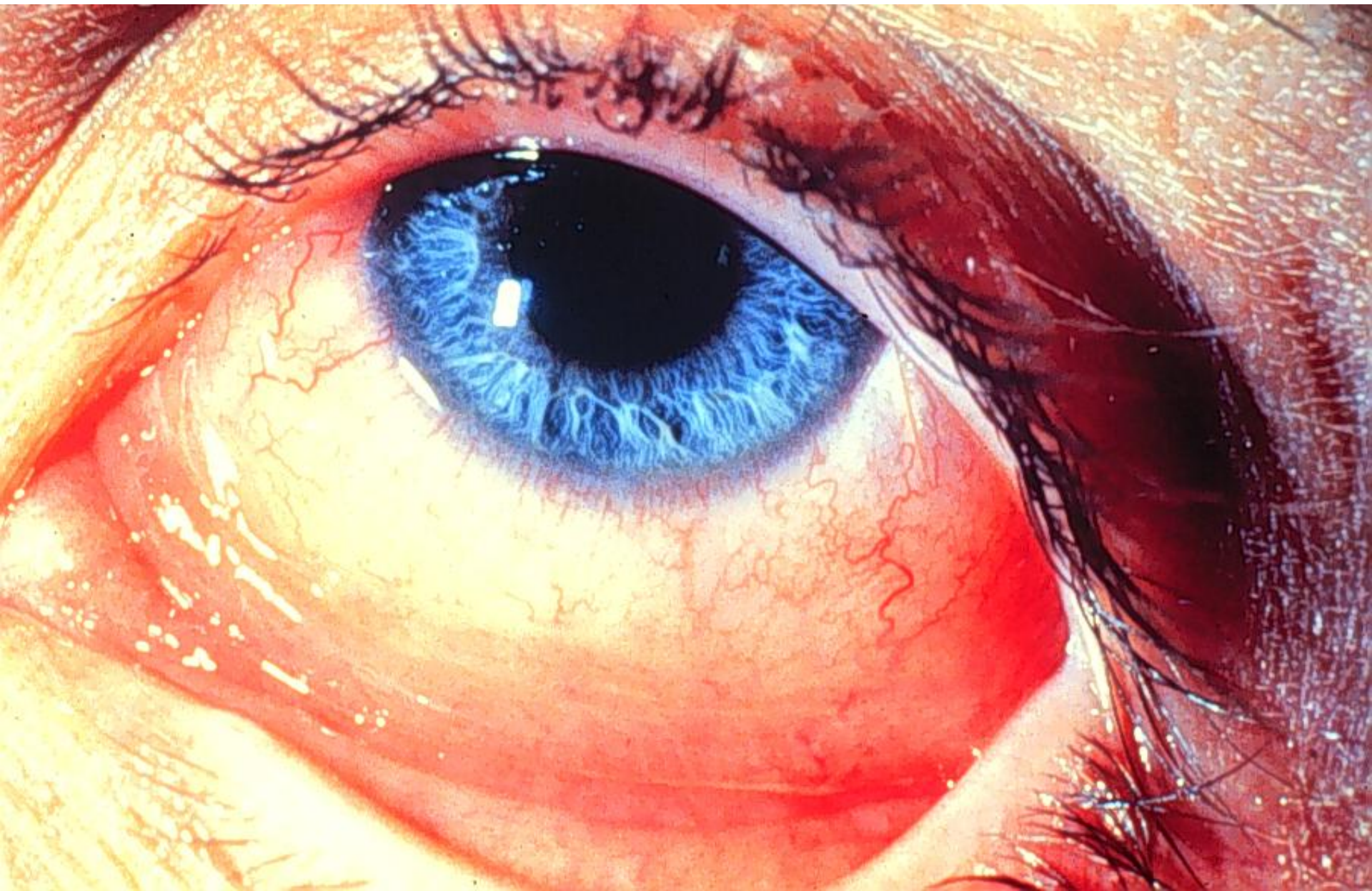
BACTERIAL CONJUNCTIVITIS: CLINICAL SIGNS

- Conjunctivitis often bilateral
- Mucopurulent discharge
- Lid crusting



VIRAL CONJUNCTIVITIS: CLINICAL SIGNS

- Usually bilateral
- Preauricular lymphadenopathy
- Conjunctival inflammation
- Watery discharge



DIFFERENTIATION OF THE COMMON TYPES OF CONJUNCTIVITIS

Clinical Findings and Cytology	Viral	Bacterial
Itching	Minimal	Minimal
Hyperemia	Generalized	Generalized
Tearing	Profuse	Moderate
Exudation	Minimal	Profuse
Preauricular adenopathy	Common	Uncommon
In stained scrapings and exudates	Monocytes	Bacteria, PMNs*
Associated sore throat and fever	Occasionally	Occasionally

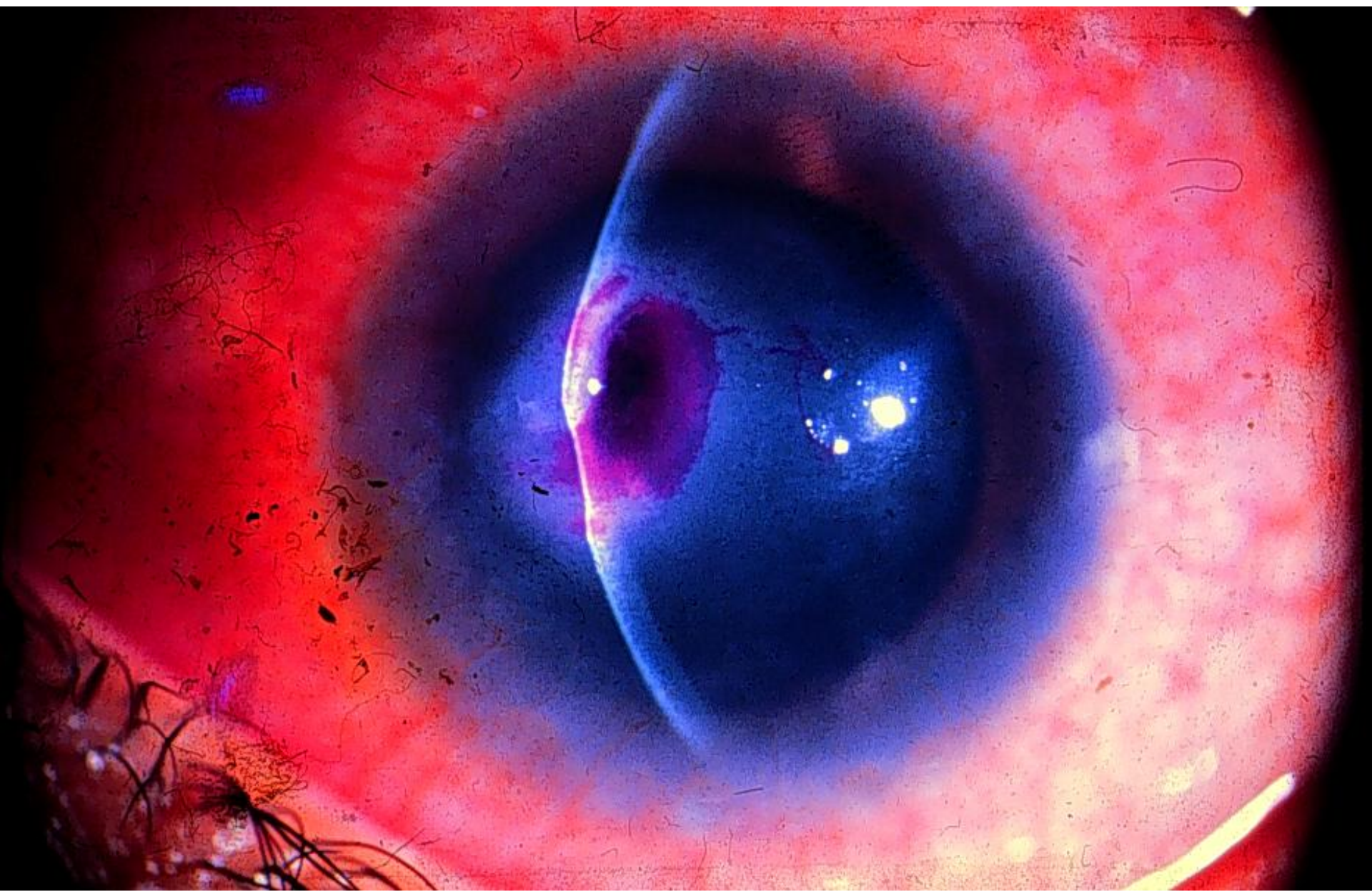* Poly morphonuclear cells

DIFFERENTIATION OF THE COMMON TYPES OF CONJUNCTIVITIS

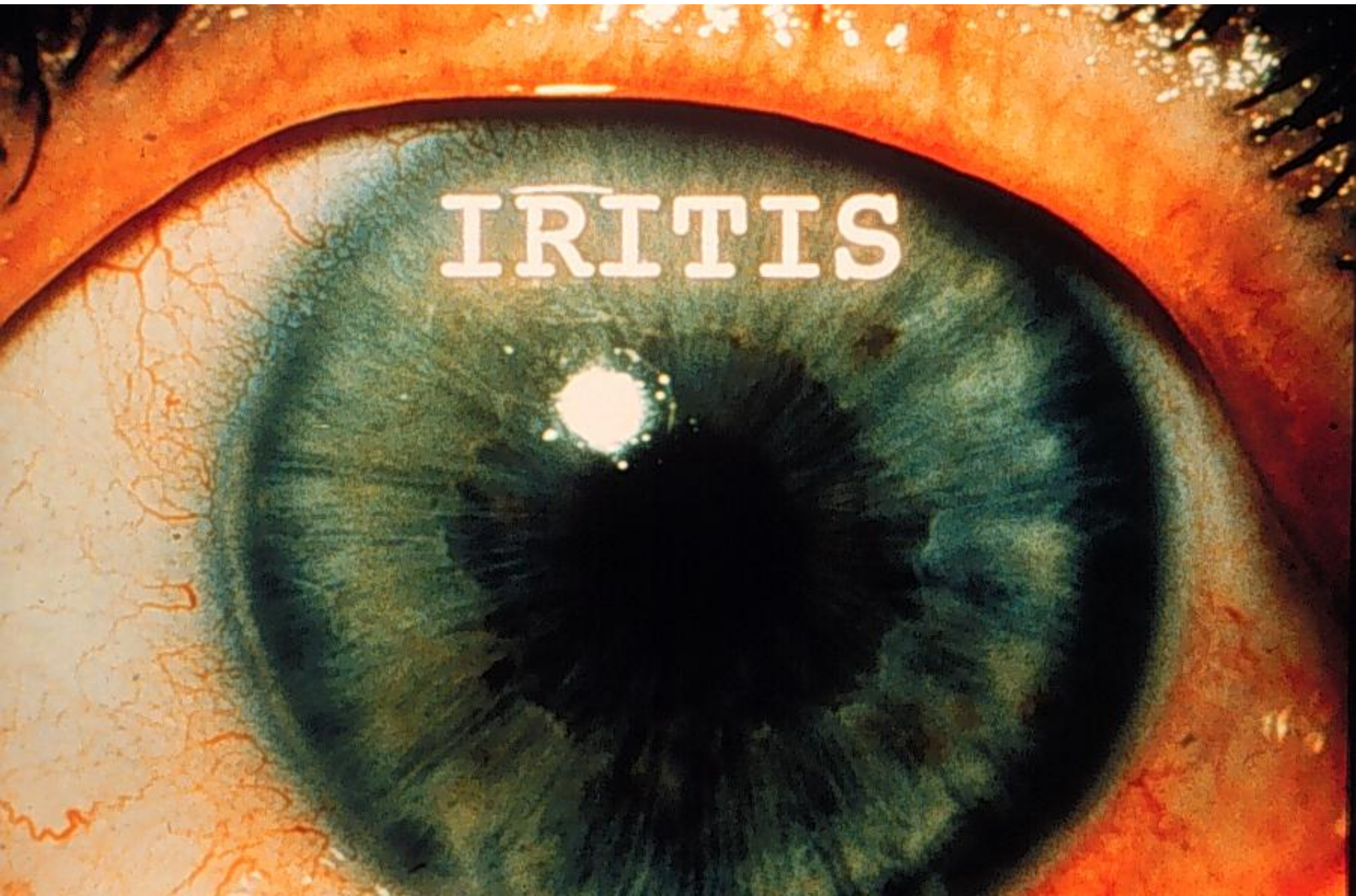
Chlamydial	Atopic (Allergies)
Minimal	Severe
Generalized	Generalized
Moderate	Moderate
Mild to moderate	Minimal
Common only in inclusion conjunctivitis	None
PMNs*, plasma cells inclusion bodies	Eosinophils
Never	Never

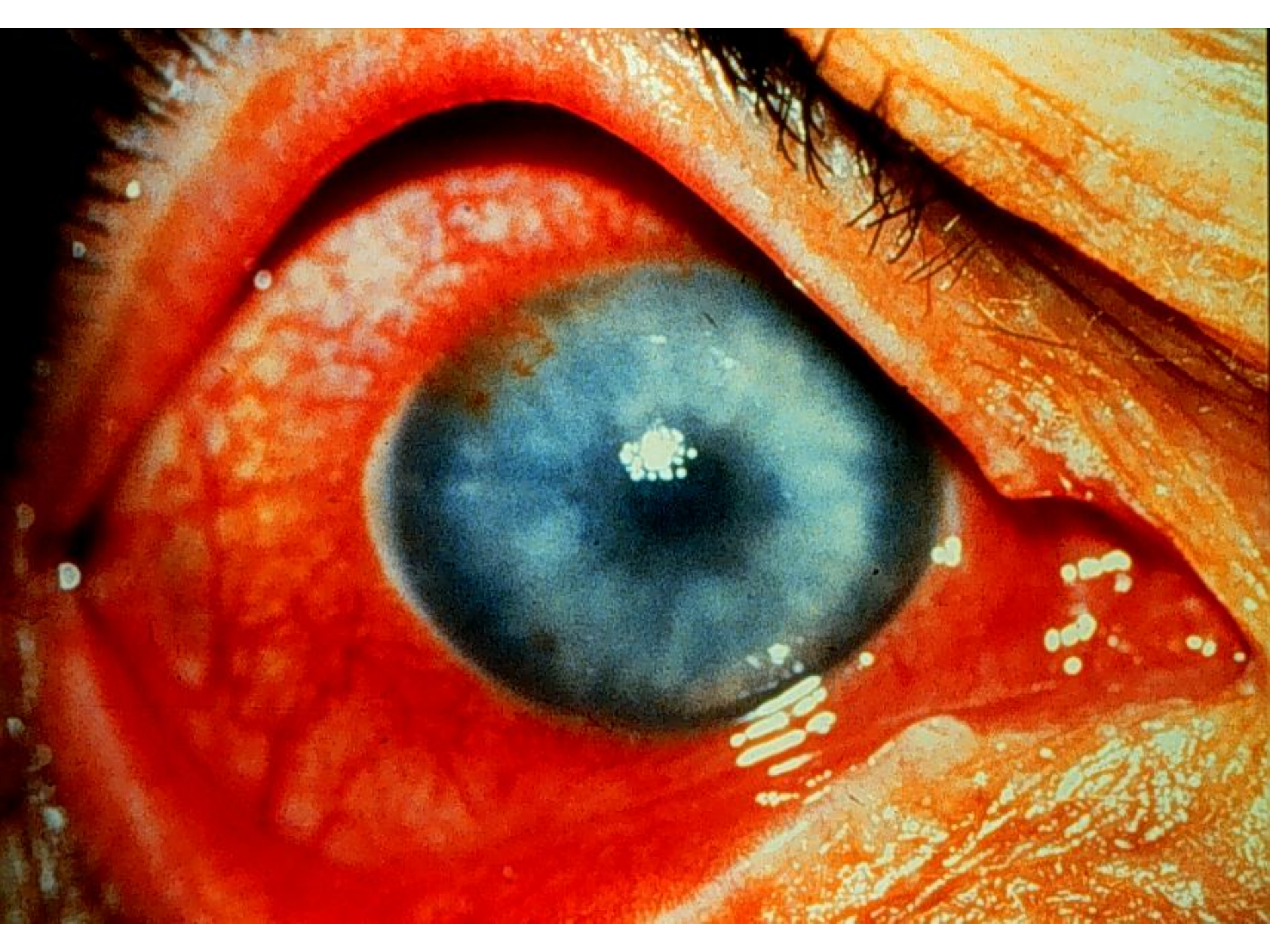
* Poly morphonuclear cells





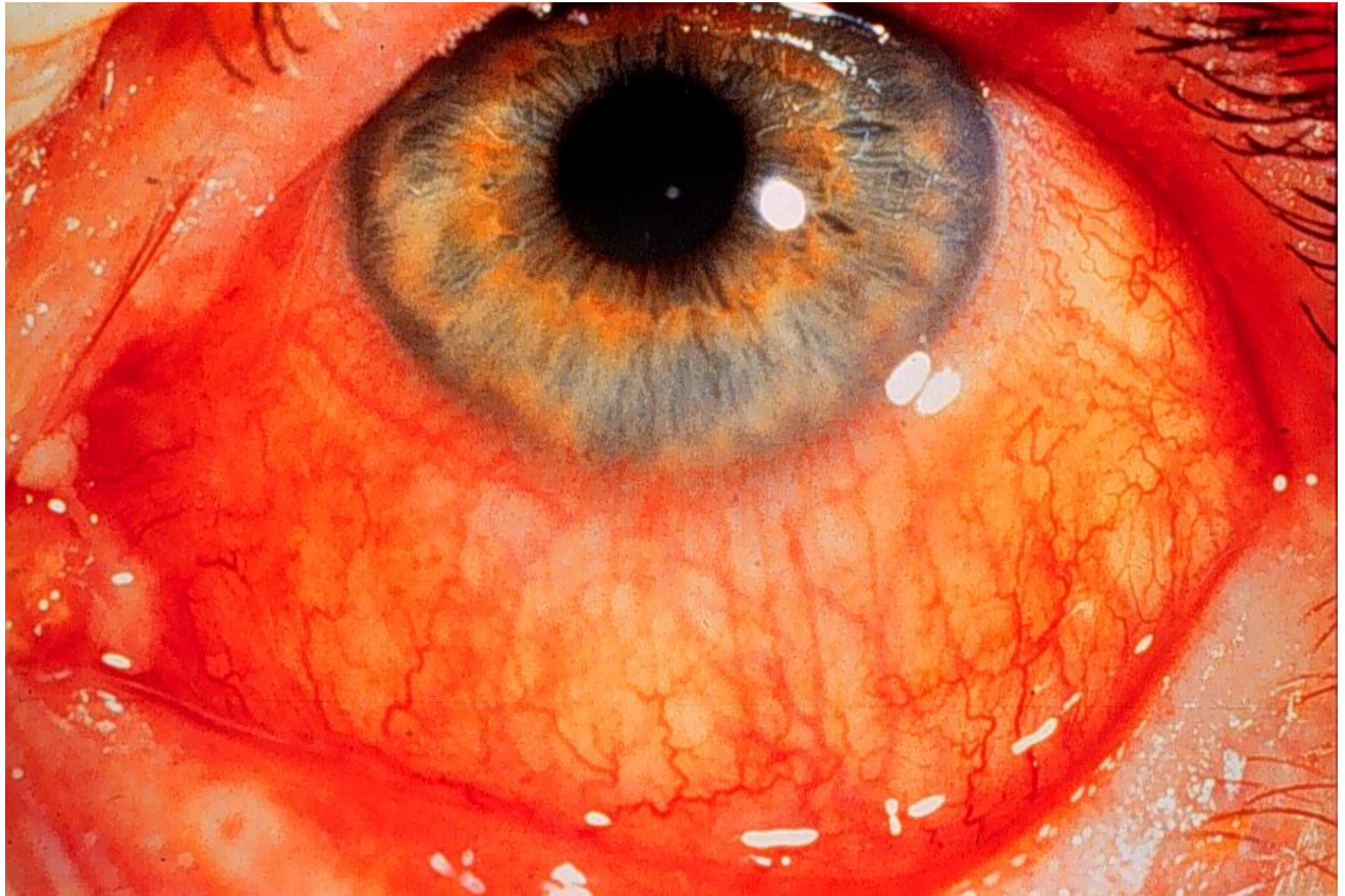IRITIS

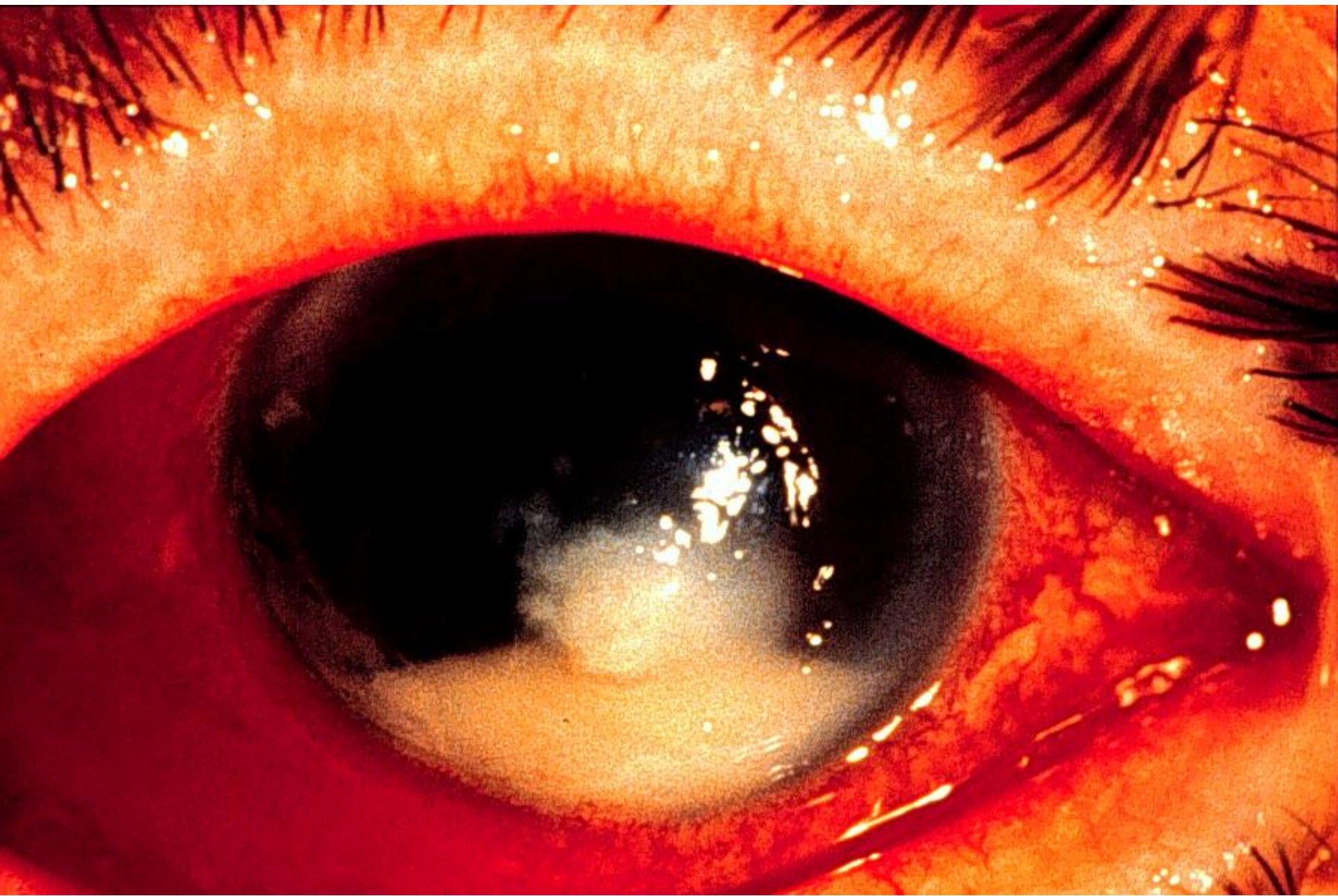



ACUTE GLAUCOMA: SYMPTOMS

- Severe ocular pain
- Decreased vision
- Headache, nausea/vomiting
- Abdominal pain



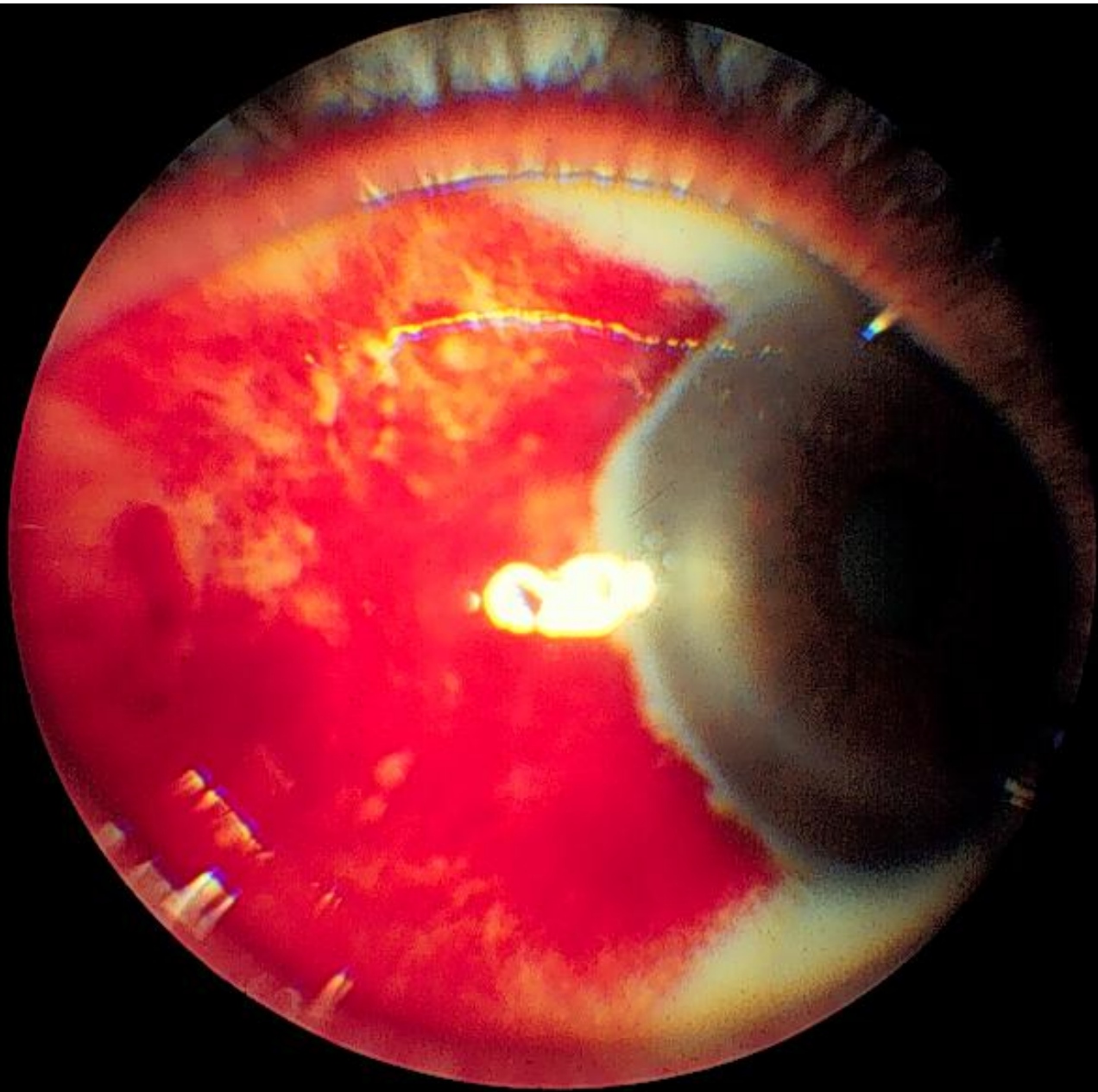


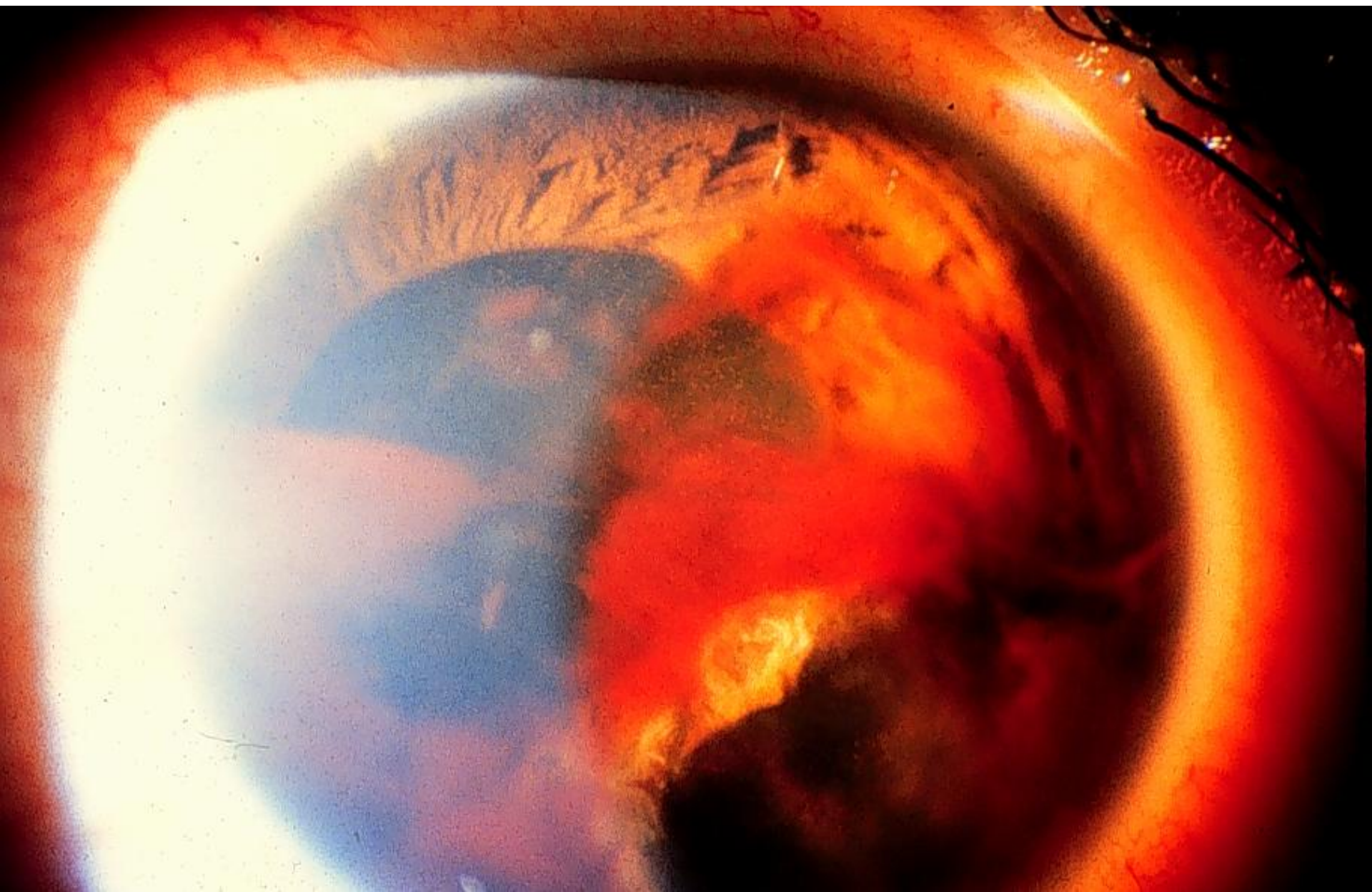
ANY NOXIOUS AGENT TO THE EYE CAN CAUSE ITS
REDNESS. THERE ARE ONLY THREE MAJOR CAUSES
THAT CAN BE CALLED SERIOUS. THEY ARE:

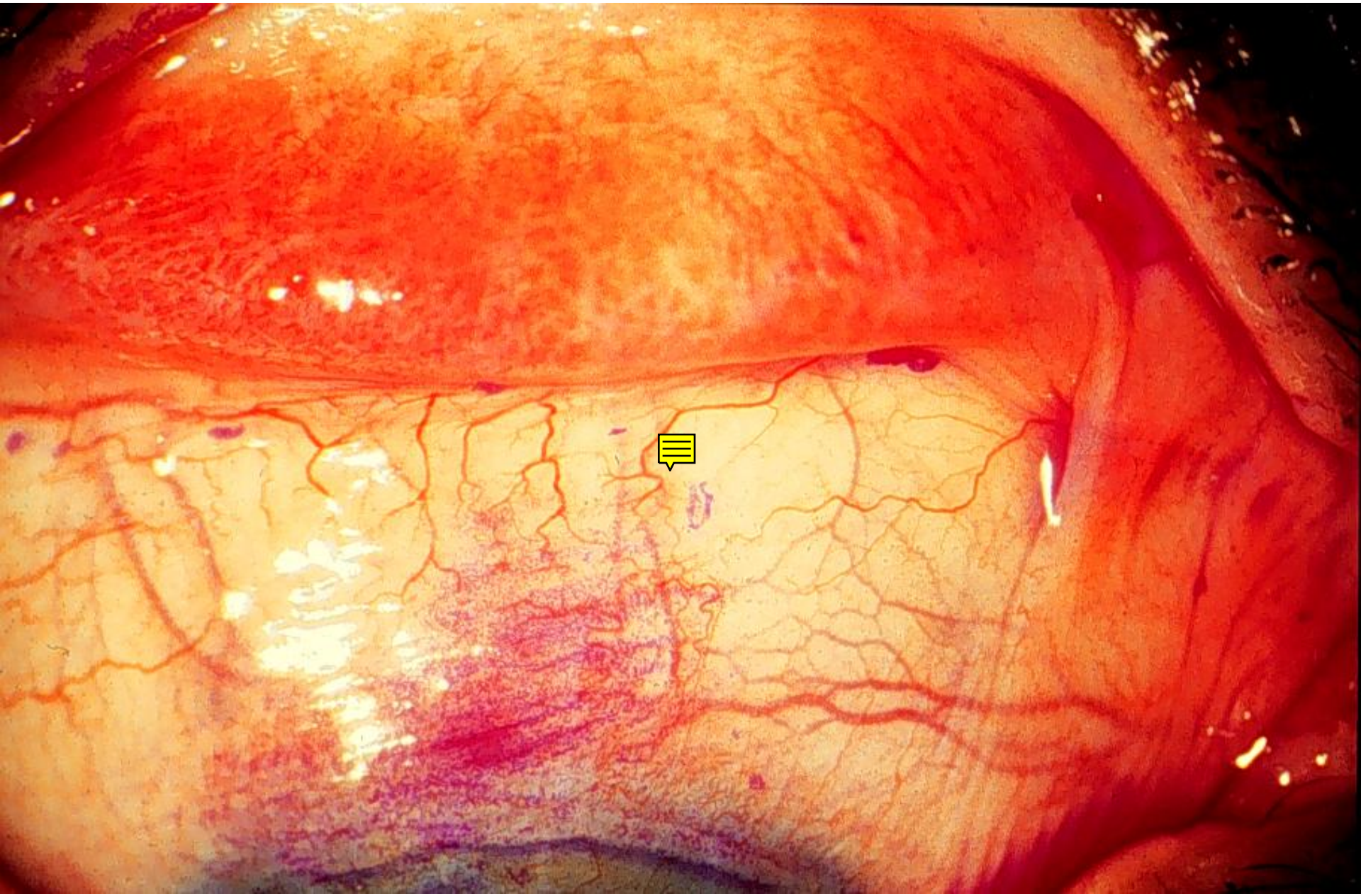
- I. KERATITIS
- II. IRITIS
- III. ACUTE GLAUCOMA

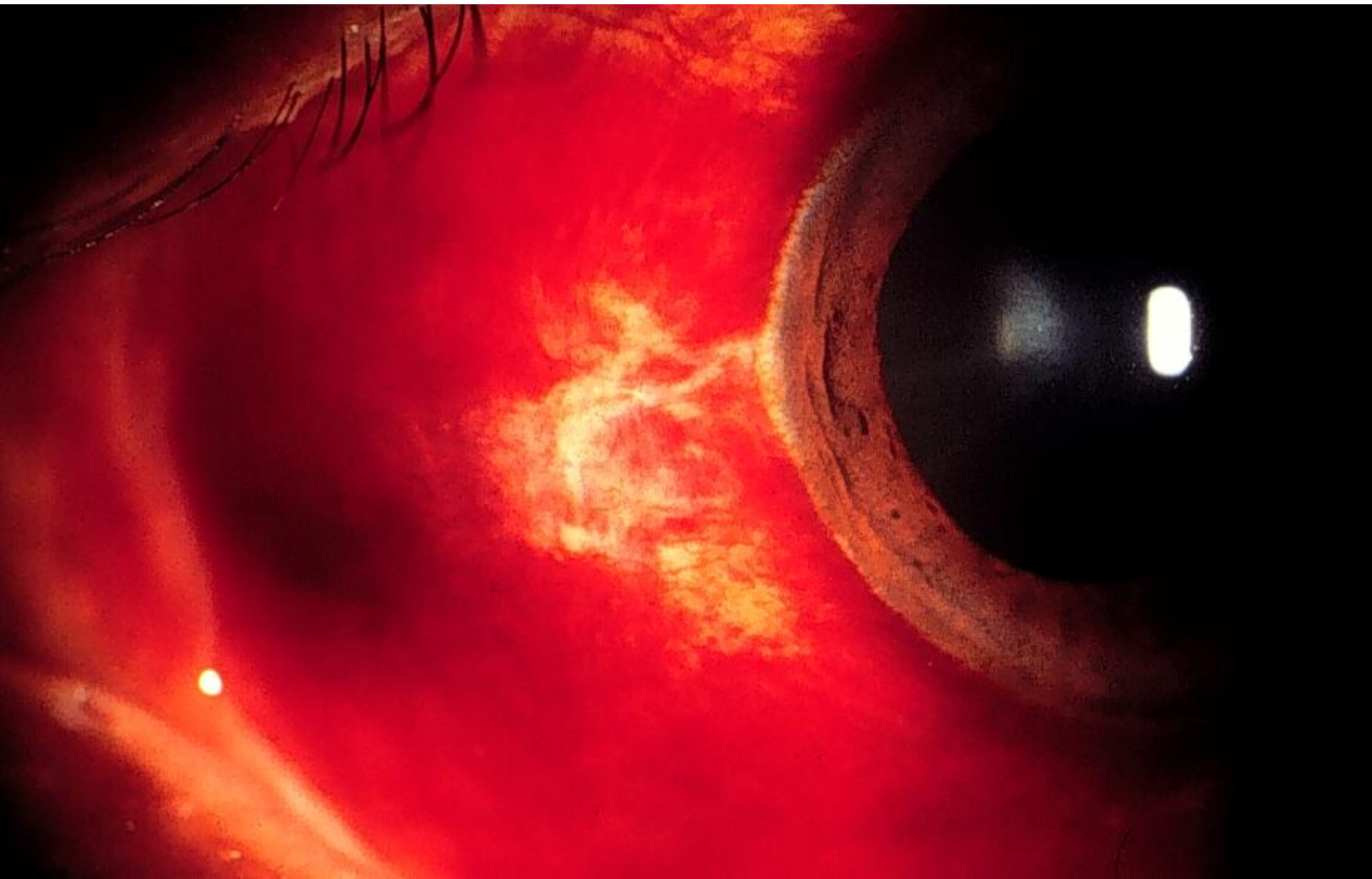
CONJECTIVITIS

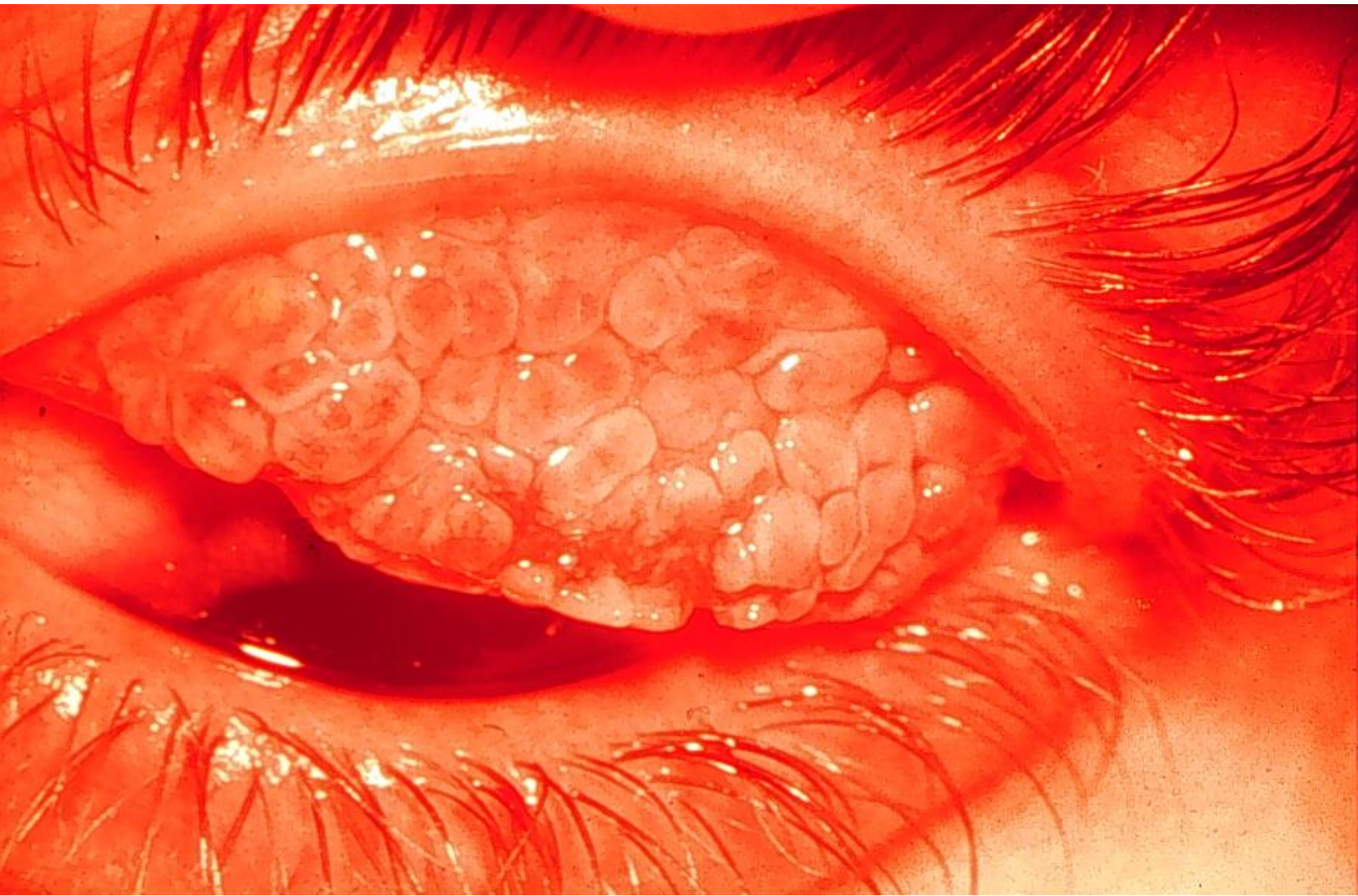
THERE IS ONLY ONE DECISION TO MAKE ABOUT A
RED EYE. IS IT ONE OF THE MAJOR THREE OR IS
IT NOT? IF IT IS, THEN EXAMINATION OF THE
EYE CARRIED OUT IN THE SAME WAY EVERY TIME
WILL INDICATE WHICH OF THE MAJOR THREE IT IS.

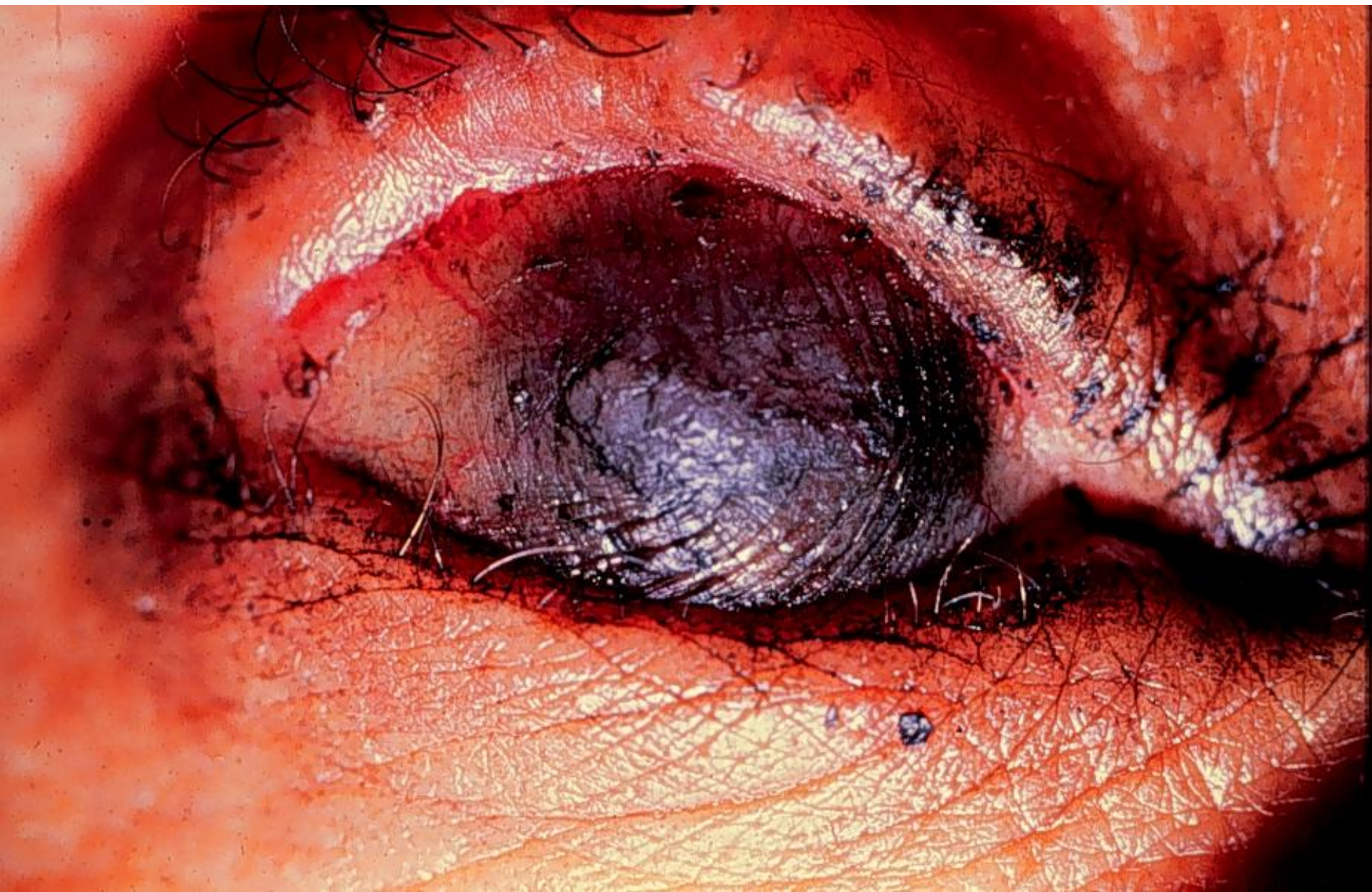











?

STEROIDS

