

BASIC ANATOMY & PHYSIOLOGY OF THE EYE



Essam Osman, M.D.
Professor & Consultant ophthalmologist
Glaucoma unit

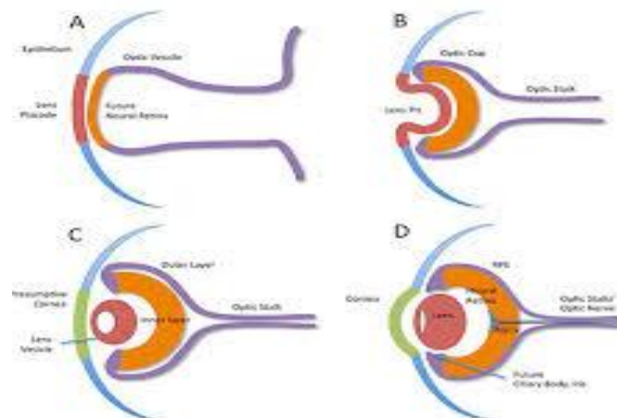
ANATOMY

ANATOMY



EMBRYOLOGY OF THE EYE

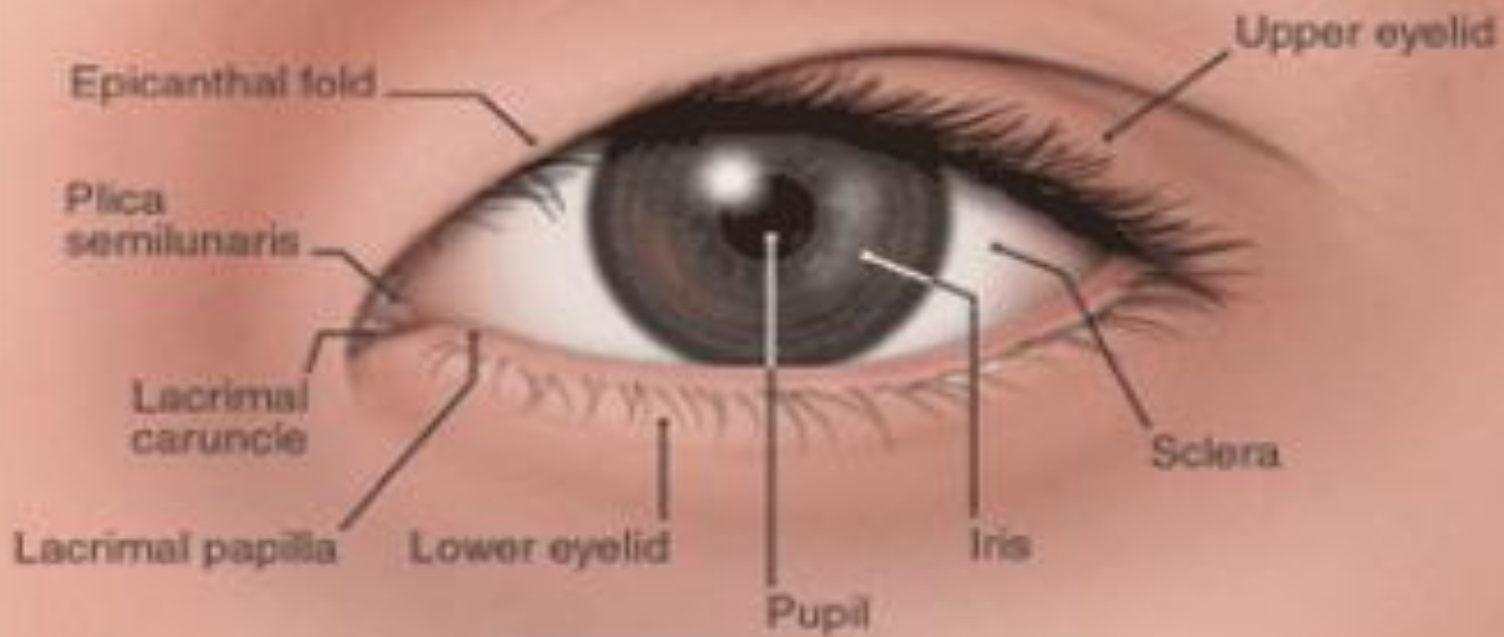
- ✧ This highly specialized sensory organ is derived from neural ectoderm, mesoderm and surface ectoderm.
- ✧ The eye is essentially an outgrowth from the brain (neural ectoderm).
- ✧ Started as *Optic vesicle* connected to the forebrain by *Optic stalk*.



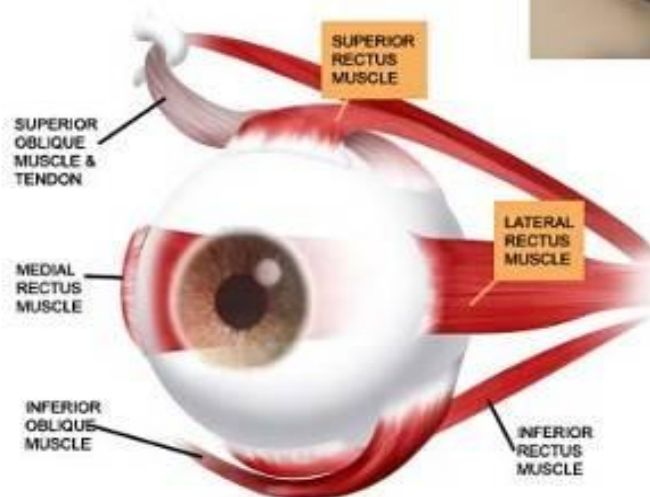
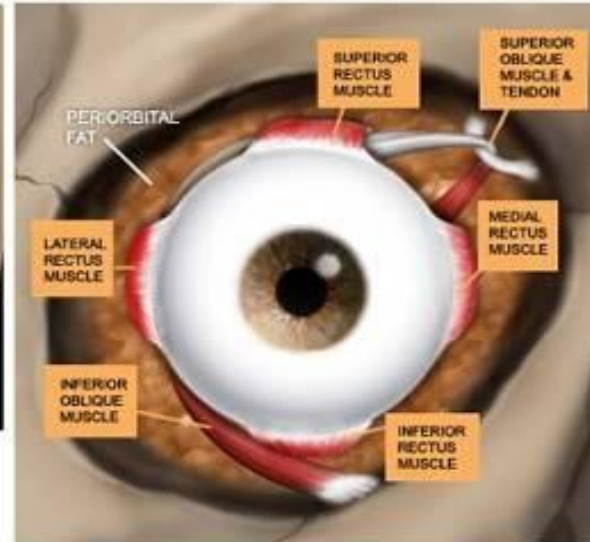
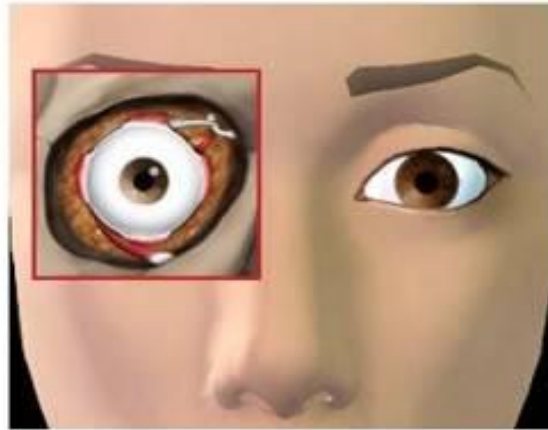
DEVELOPMENT OF THE EYE AFTER BIRTH

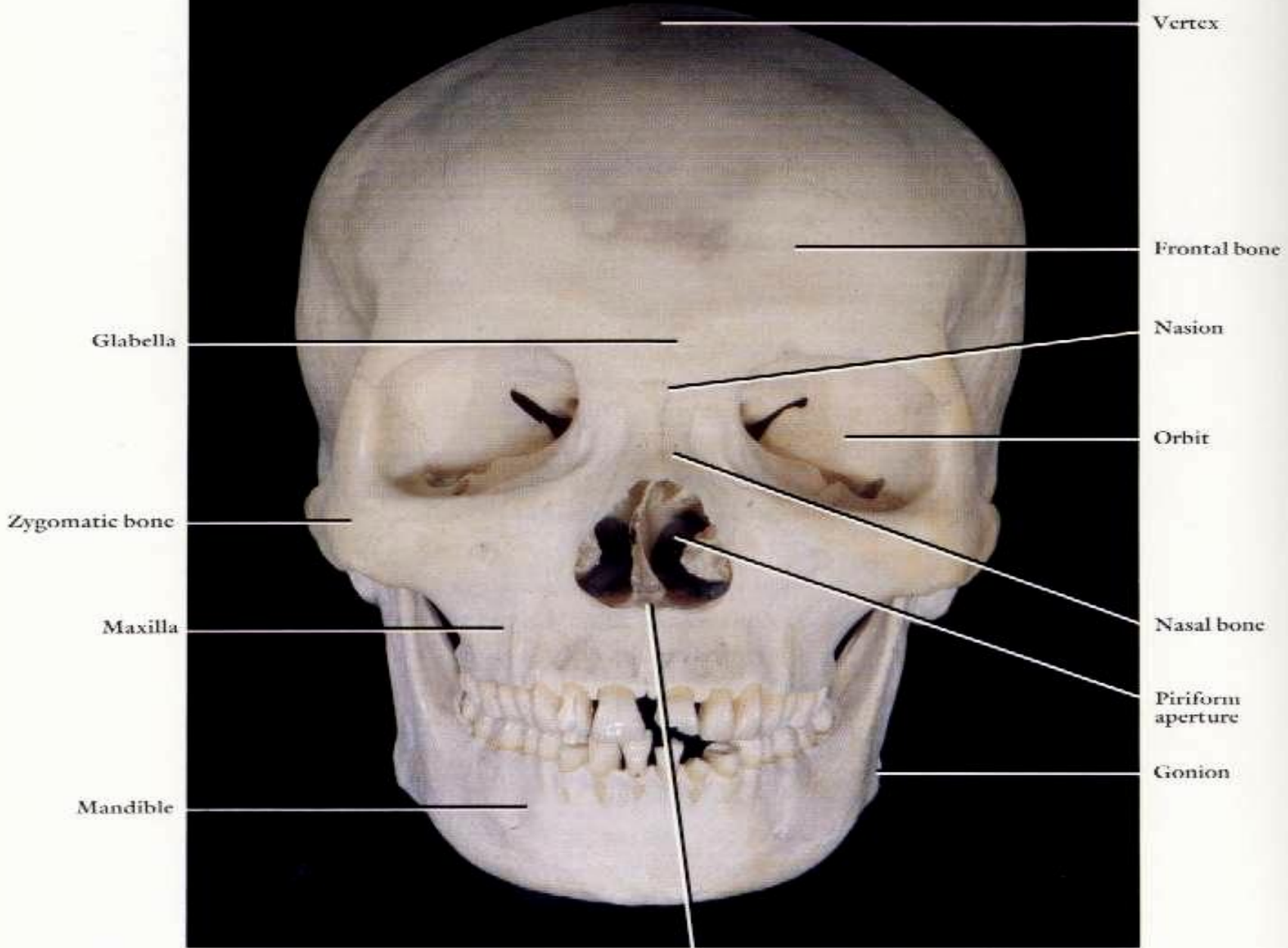


- At birth, the eye is relatively large in relation to the rest of the body.
- The eye reaches full size by the age of 8-13 years.
- The lens continues to enlarge throughout the life.
- The iris has a bluish color due to little or no pigment on the anterior surface.
- During early infant life, the cornea & sclera can be stretched by raised IOP → enlargement of the eye.



Where is the eye located ?





Vertex

Frontal bone

Glabella

Nasion

Orbit

Zygomatic bone

Nasal bone

Maxilla

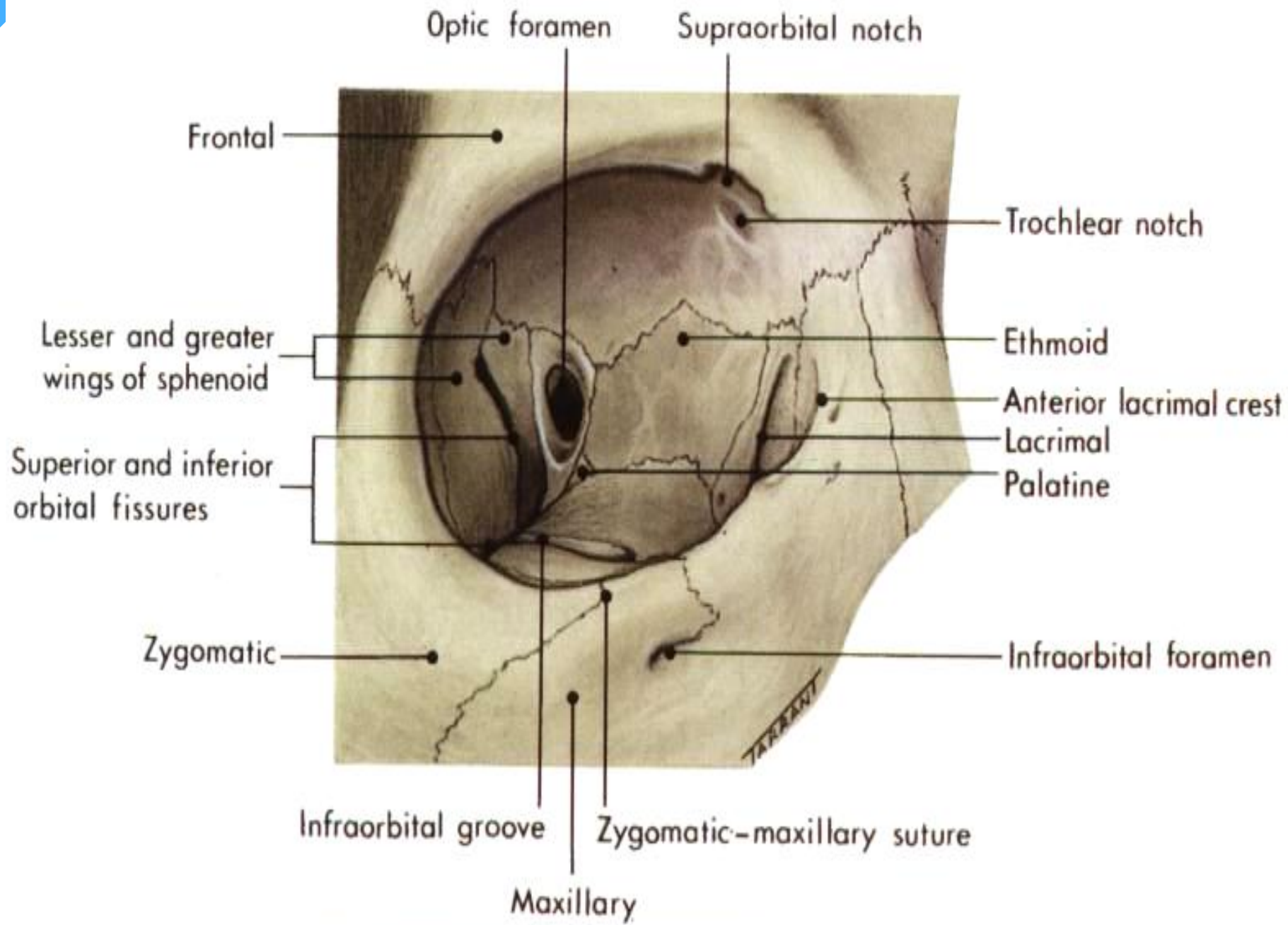
Piriform aperture

Mandible

Gonion

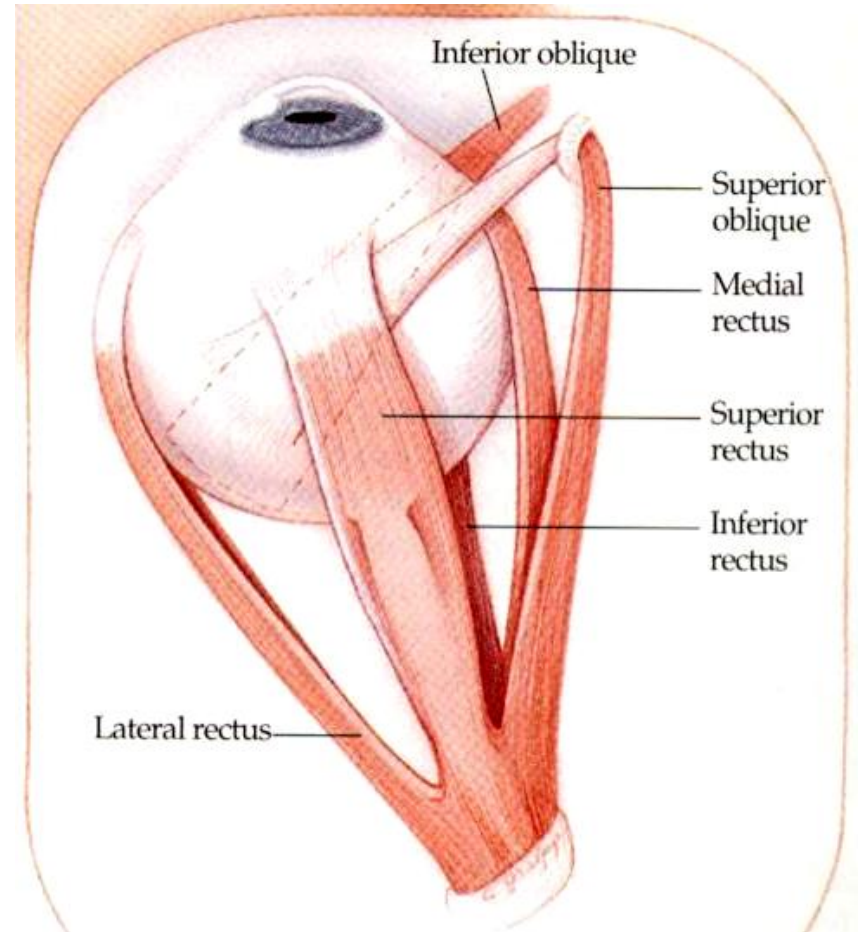
THE ORBIT

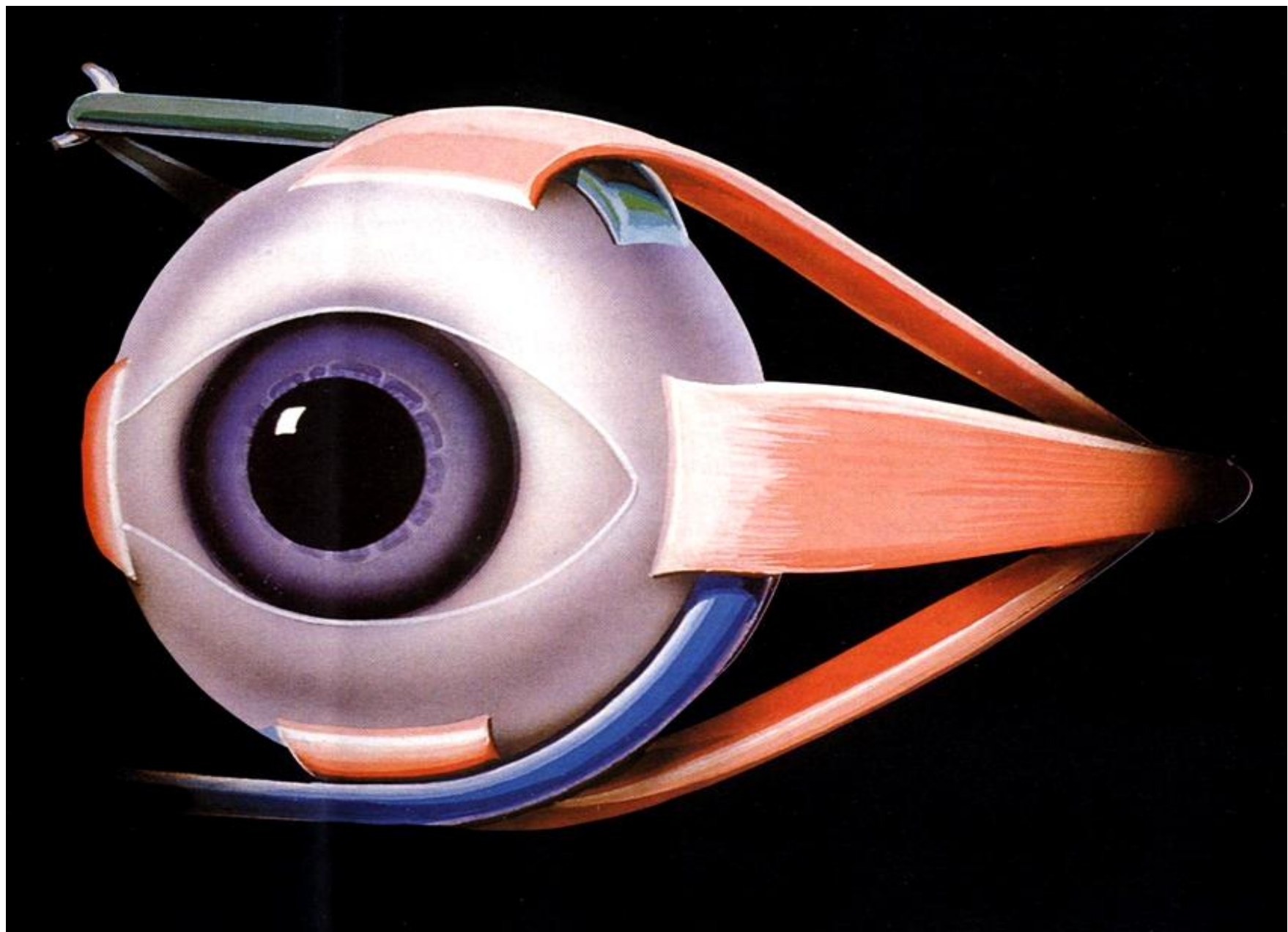
- ✓ As a socket, contains & protect the eye.
- ✓ The weakest parts are the floor & the medial wall.
- ✓ Seven bones contribute the bony orbit.
- ✓ Surrounded by nasal sinuses.
- ✓ Important openings are:
 - ✓ Optic foramen.
 - ✓ Superior orbital fissure.
 - ✓ Inferior orbital fissure.

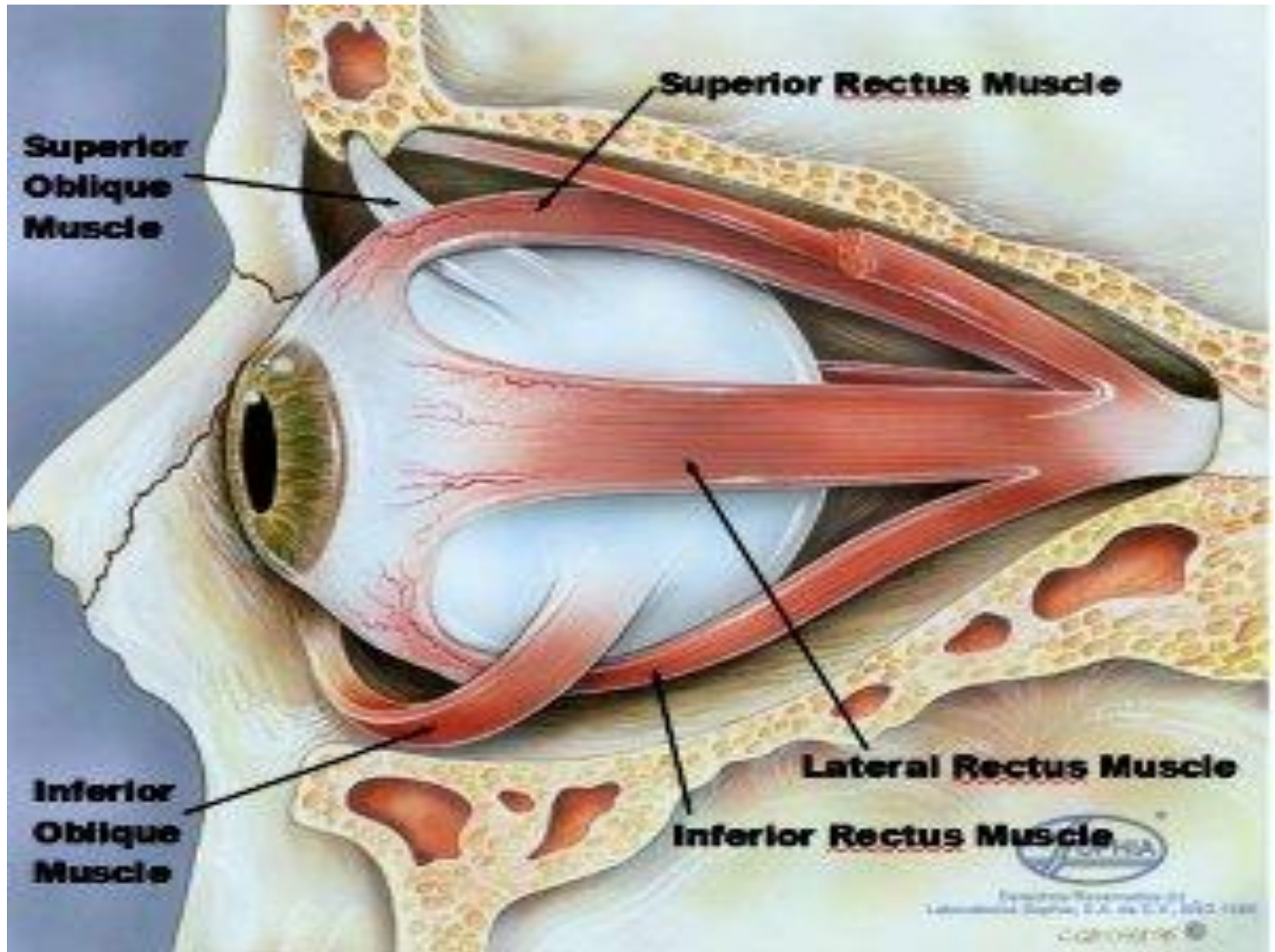


THE EXTRAOCULAR MUSCLES

- Four recti & two oblique muscles.
- All are supplied by Oculomotor n. except superior oblique (Trochlear n.) & lateral rectus (Abducent n.).







Superior Rectus Muscle

Superior Oblique Muscle

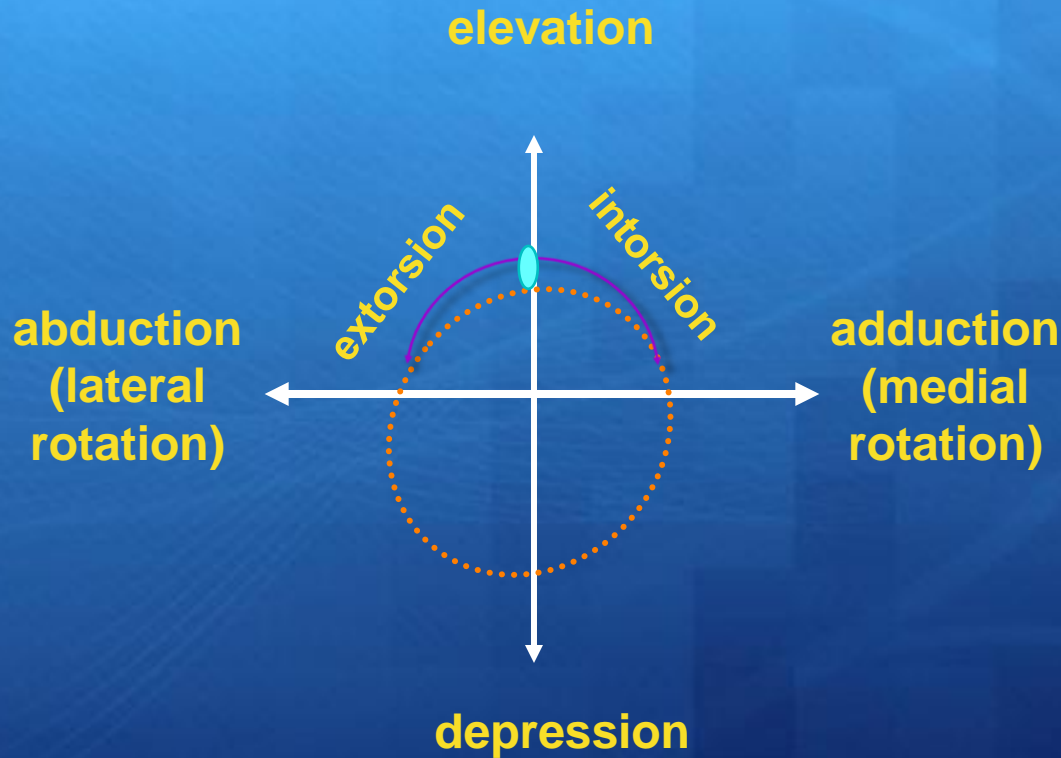
Lateral Rectus Muscle

Inferior Rectus Muscle


Inferior Oblique Muscle

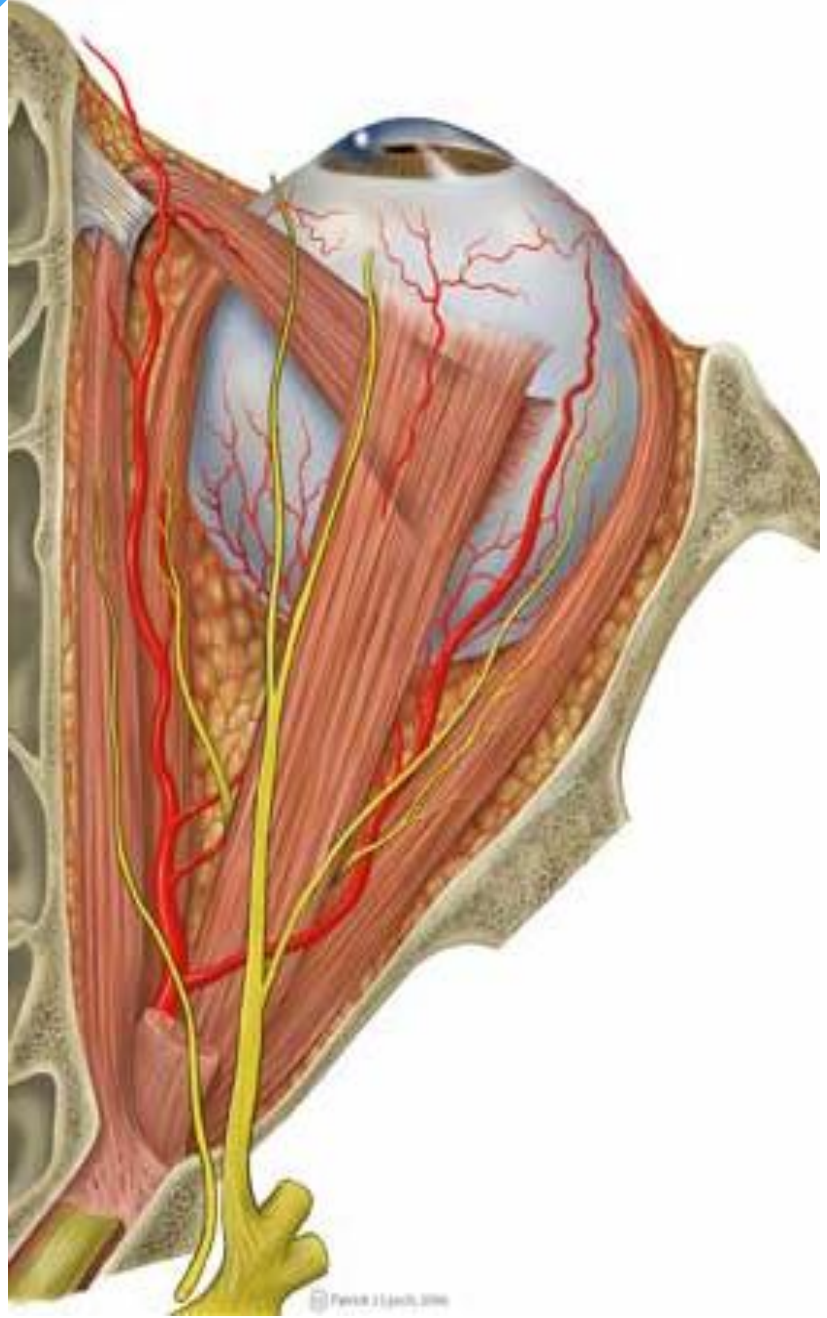
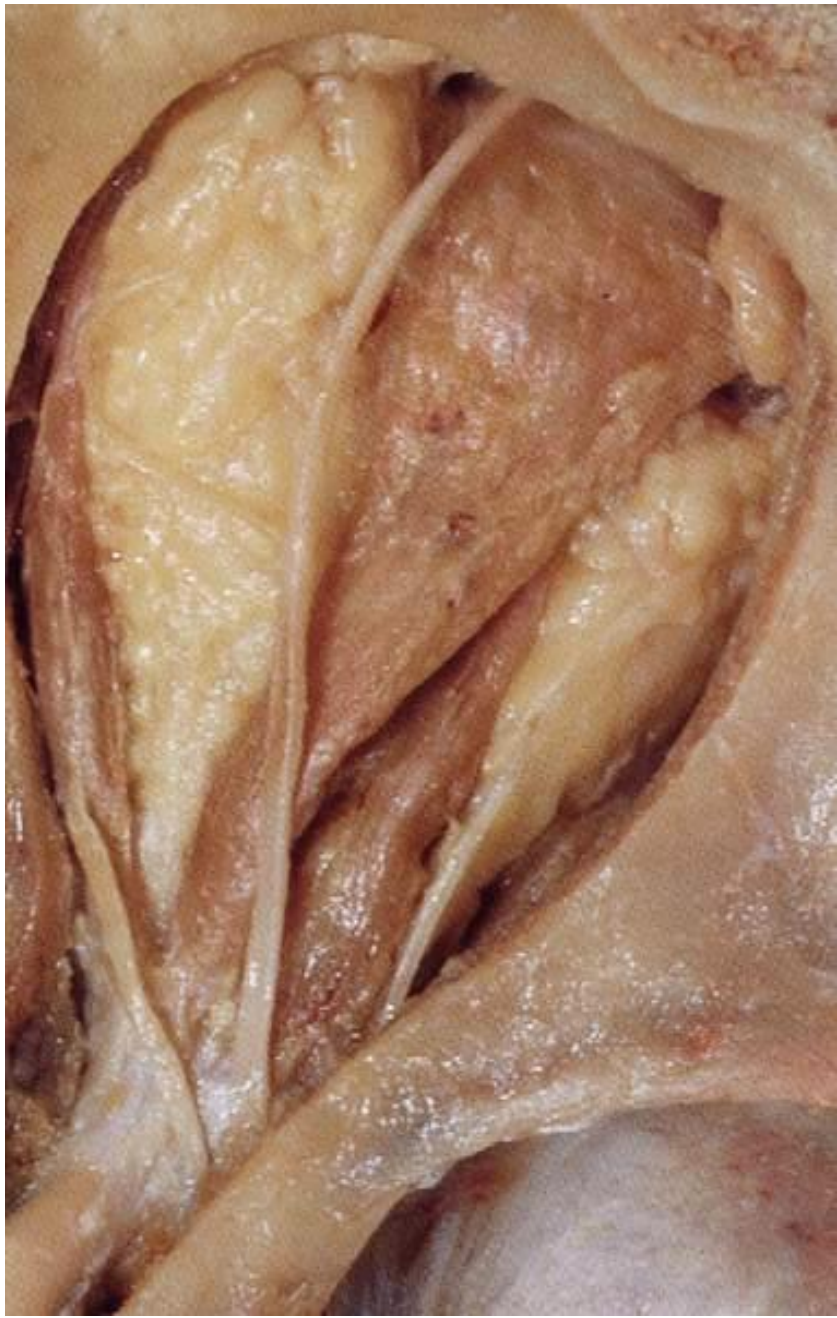Anatomical Education
Anatomical Education of the Eye, U.S. & U.K. 1982-1988
© 1988

Innervation & action of eye muscles:



midline

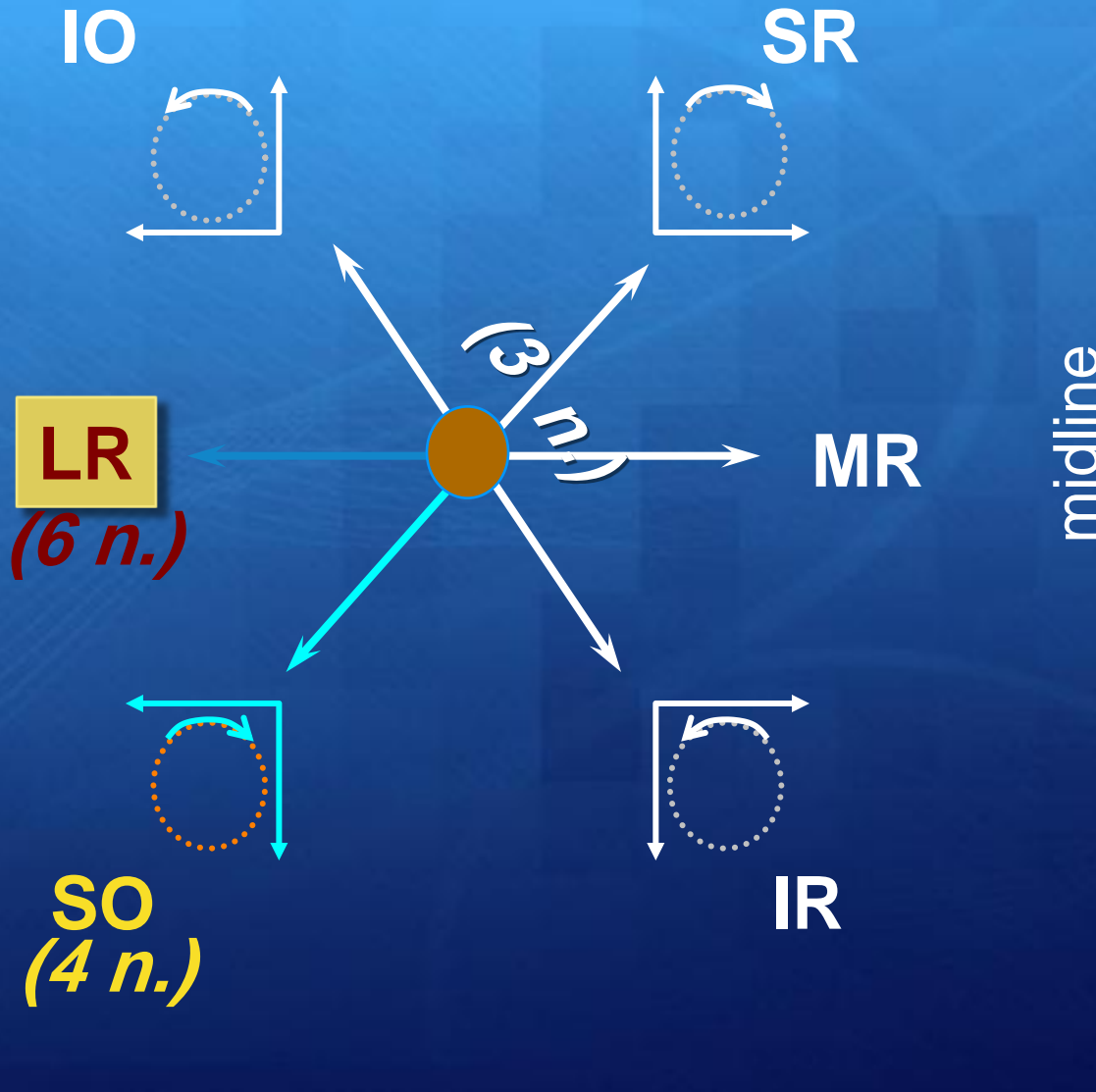




MUSCLES ACTIONS

Muscle	Primary Action	Secondary Action	Tertiary Action
Superior rectus	Elevation (transverse axis)	Medial rotation or adduction (vertical axis)	Intorsion or incycloduction (sagittal axis)
Inferior rectus	Depression (transverse axis)	Medial rotation or adduction (vertical axis)	Extorsion or excycloduction (sagittal axis)
Lateral rectus	Lateral rotation or abduction (vertical axis)	—	—
Medial rectus	Medial rotation or adduction (vertical axis)	—	—
Superior oblique	Depression (transverse axis)	Lateral rotation or abduction (vertical axis)	Intorsion or incycloduction (sagittal axis)
Inferior oblique	Elevation (transverse axis)	Lateral rotation or abduction (vertical axis)	Extorsion or excycloduction (sagittal axis)

Innervation & action of eye muscles:



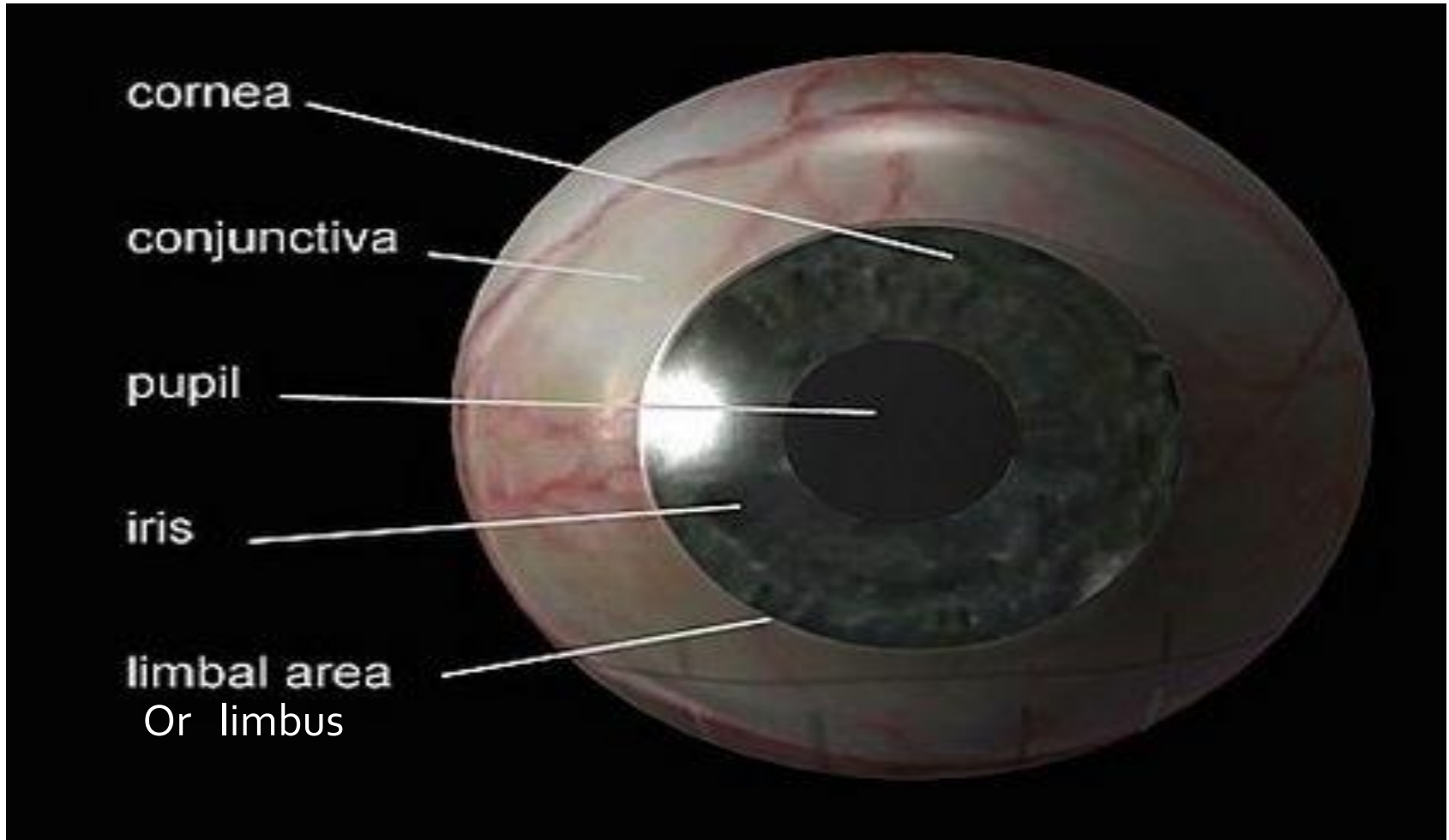
Hence for clinical test:

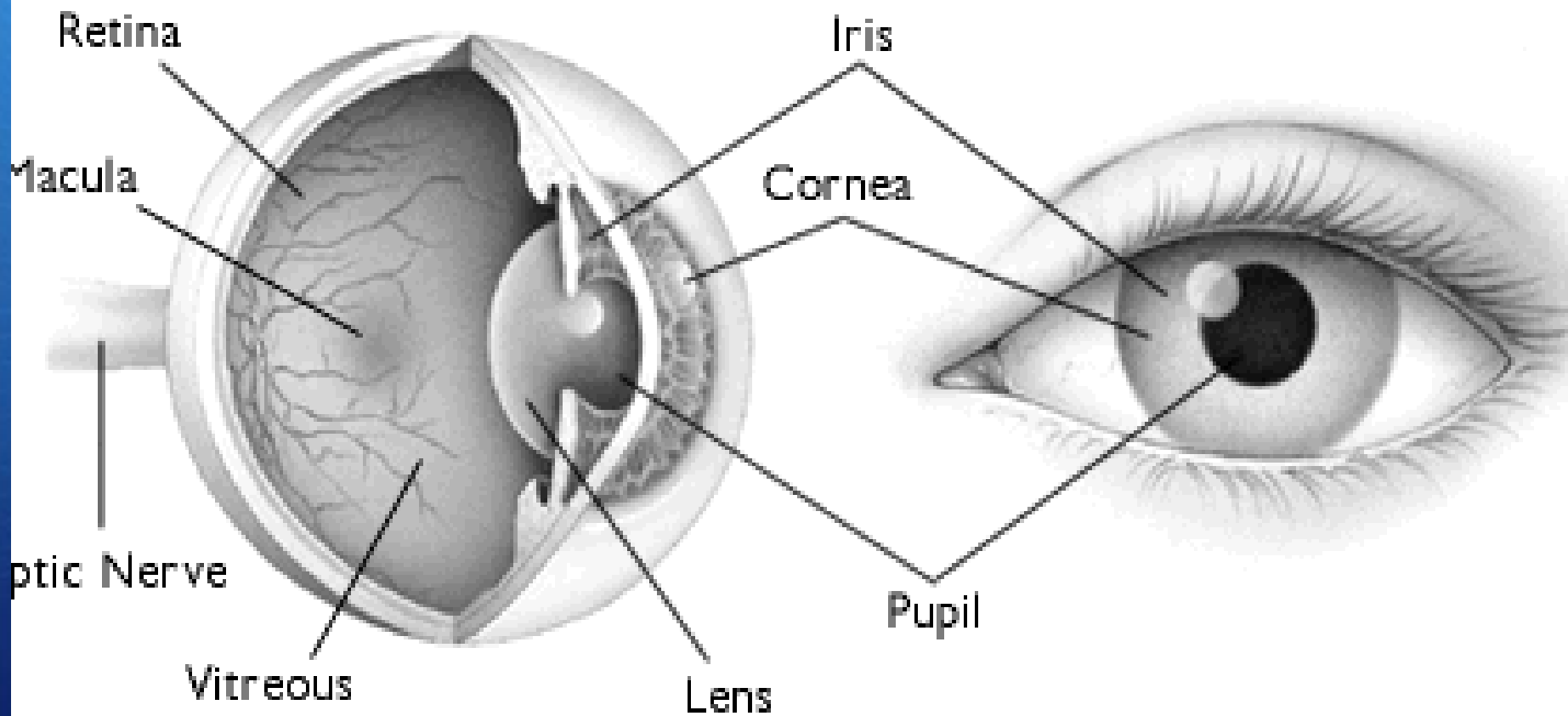
(Field of Action)

Direction to look

- **SO** **Down and in**
- **IO** **Up and in**
- **SR** **Up +/- out**
- **IR** **Down +/- out**

Globe Anatomy





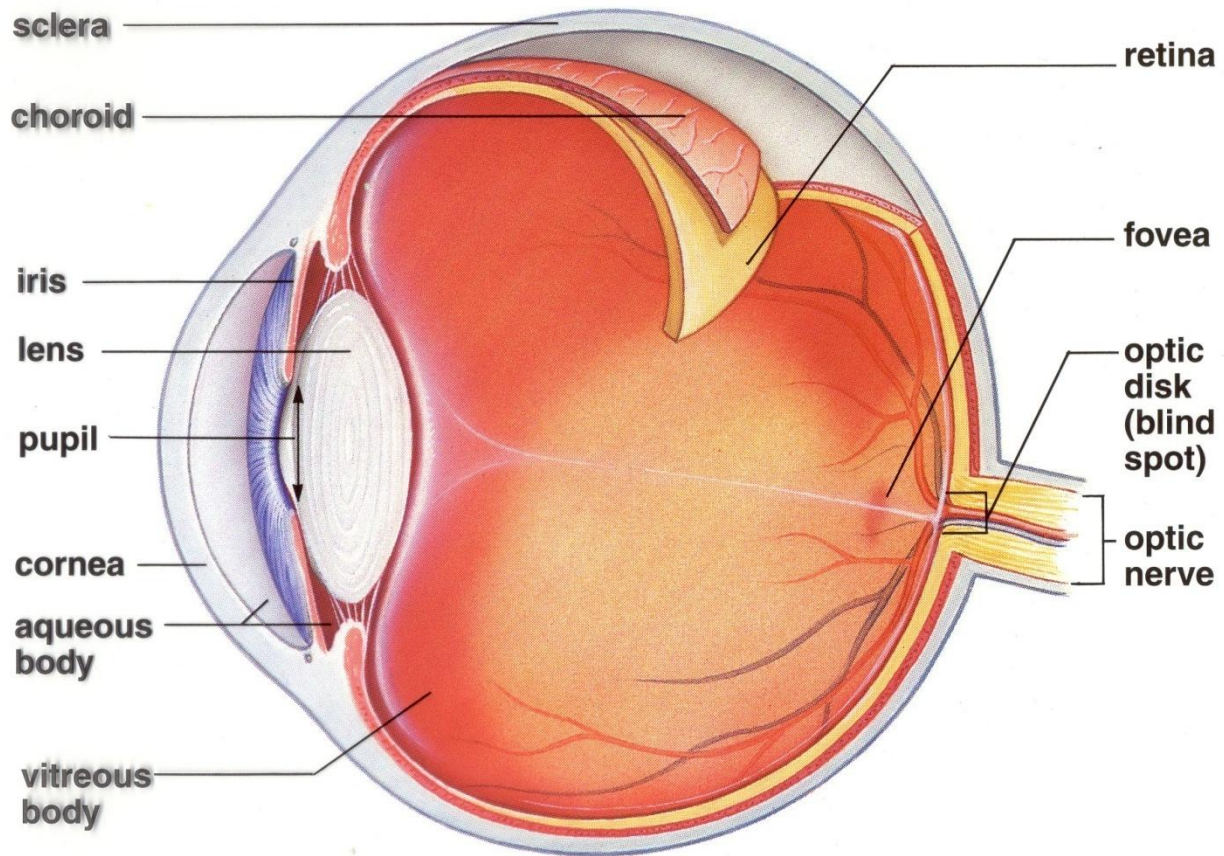
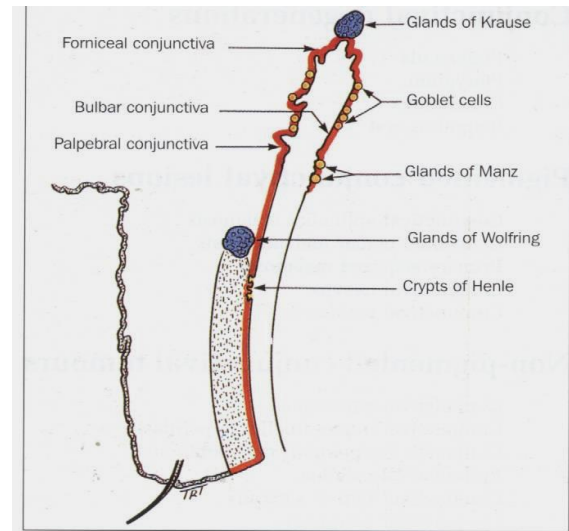
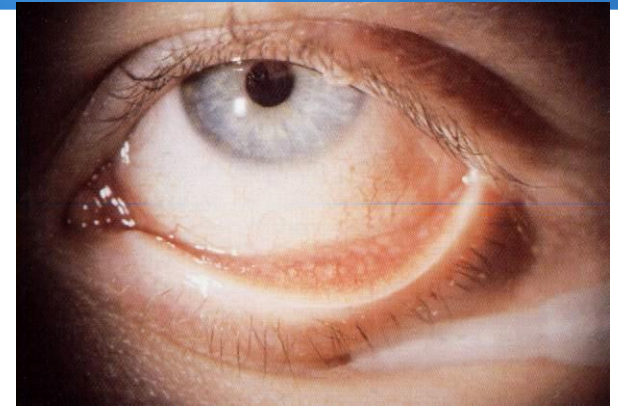


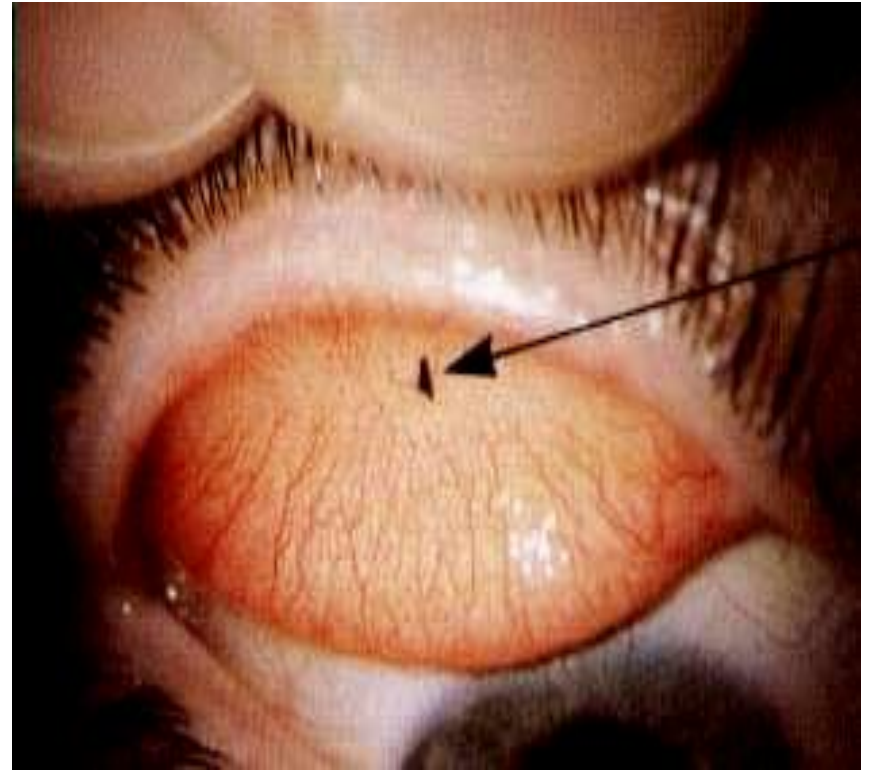
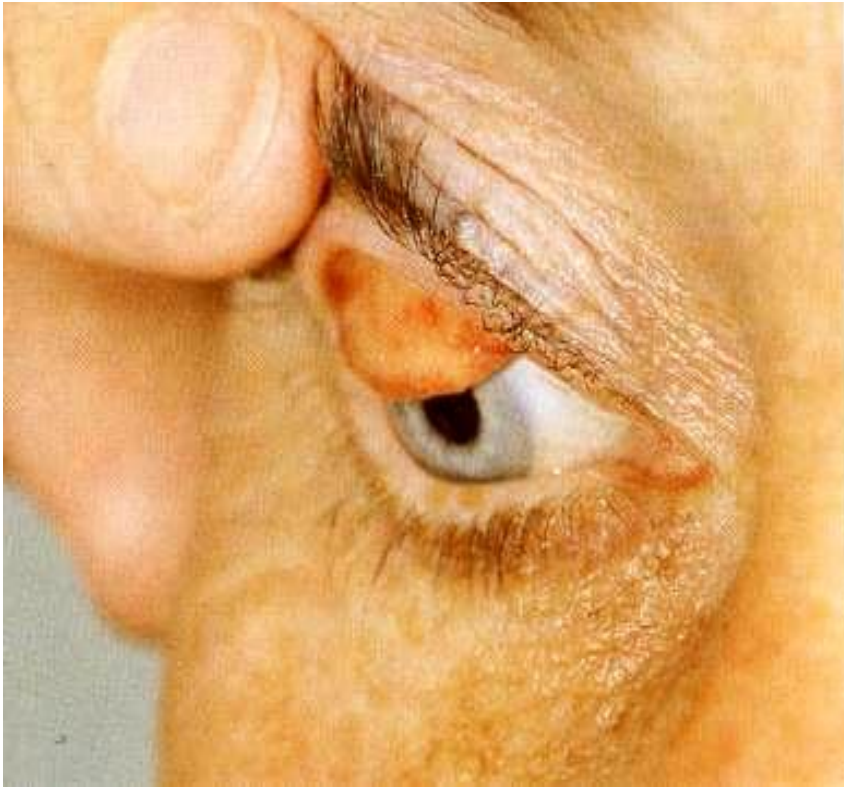Fig. 32.30 Structure of the human eye.

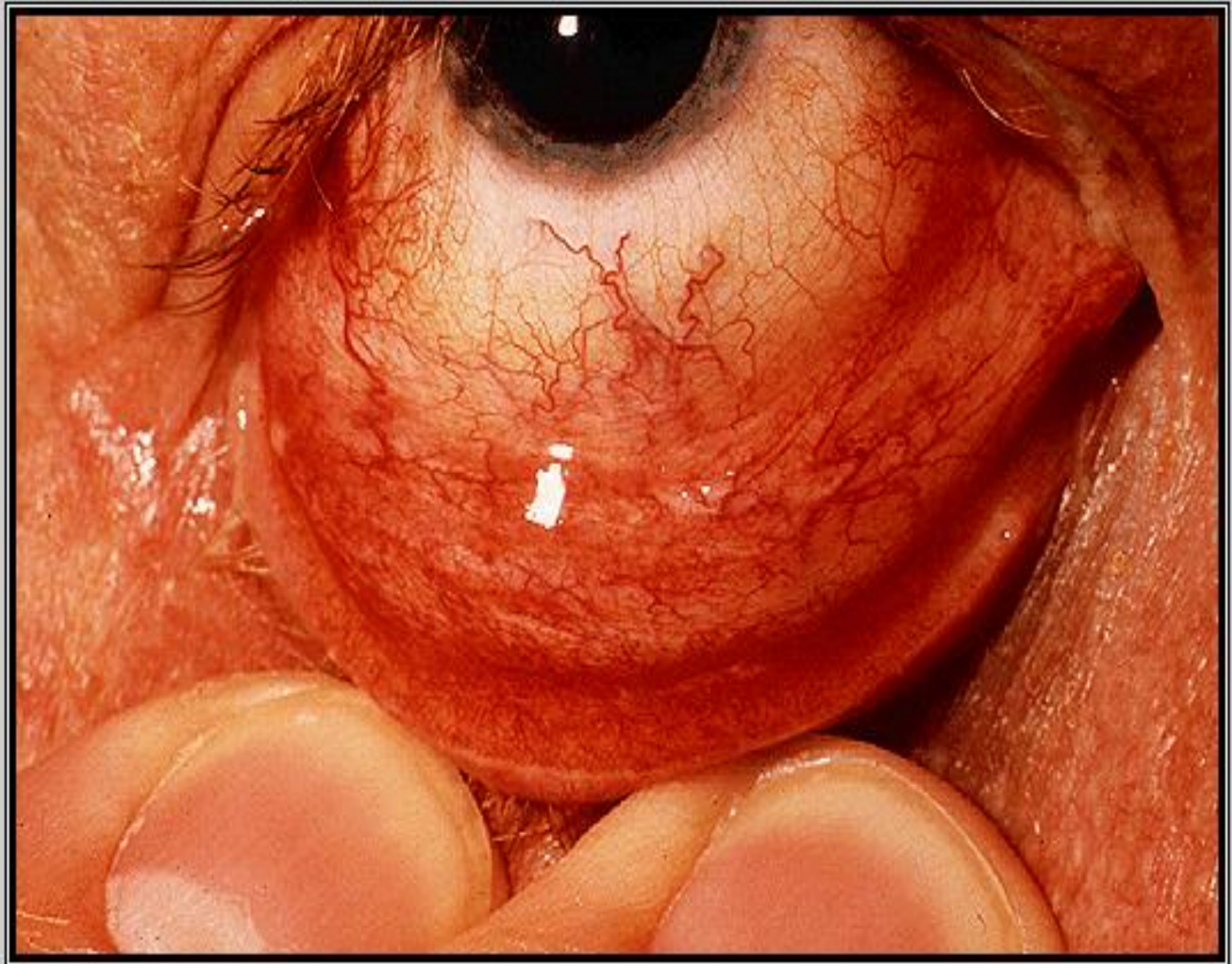
CONJUNCTIVA

- + **Three parts:**
 1. Bulbar conjunctiva.
 2. Palpebral conjunctiva.
 3. Forniceal conjunctiva.
- + **The stroma (no adenoid tissues until 3 months after birth).**
- + **Follicles & Papillae.**
- + **Injection and chemosis.**



Palpebral conjunctiva





THE EYE (GLOBE)

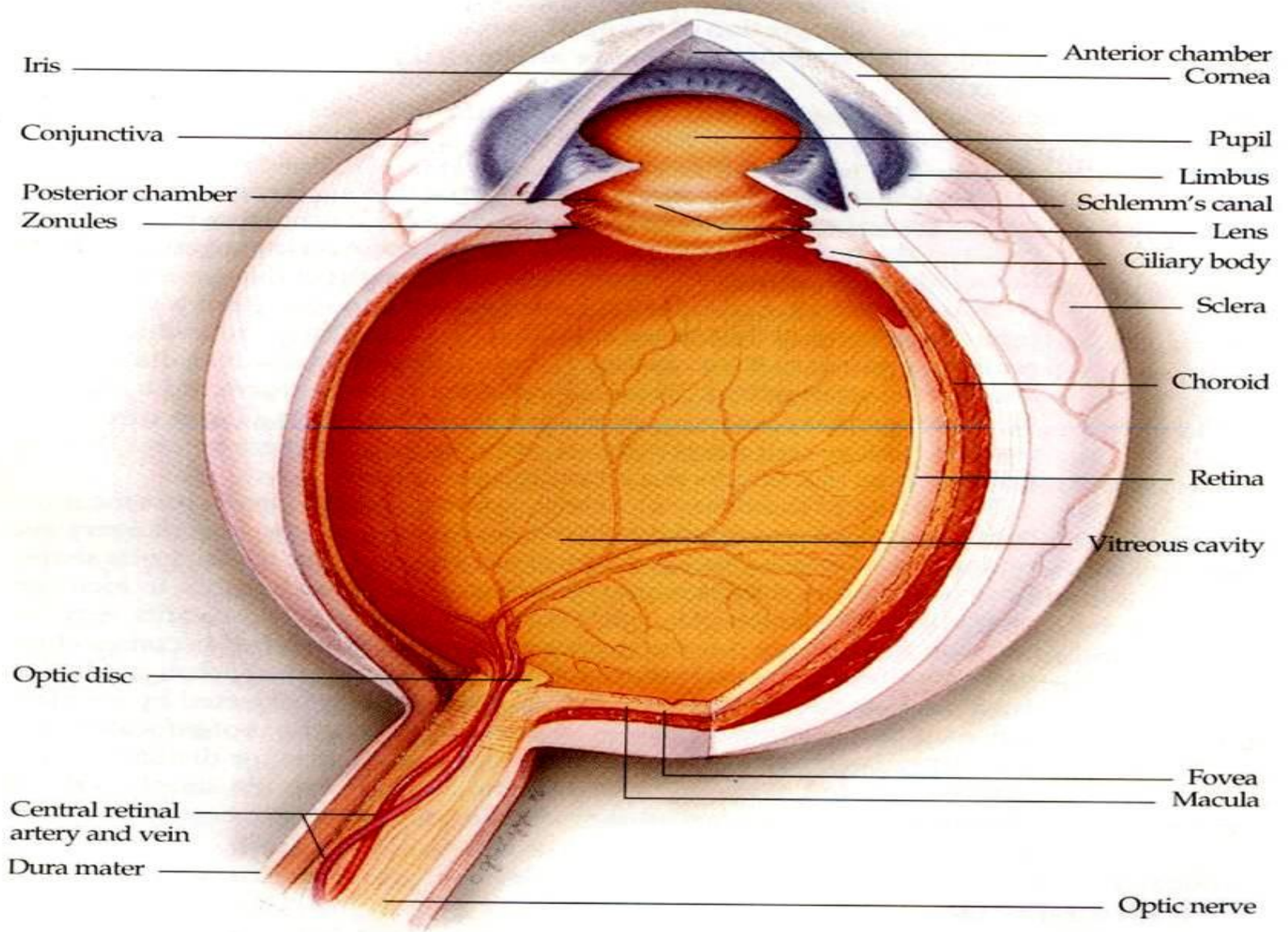
- ✓ Two spheres with different radii:
 - Cornea, window of the eye.
 - Sclera, opaque shell.

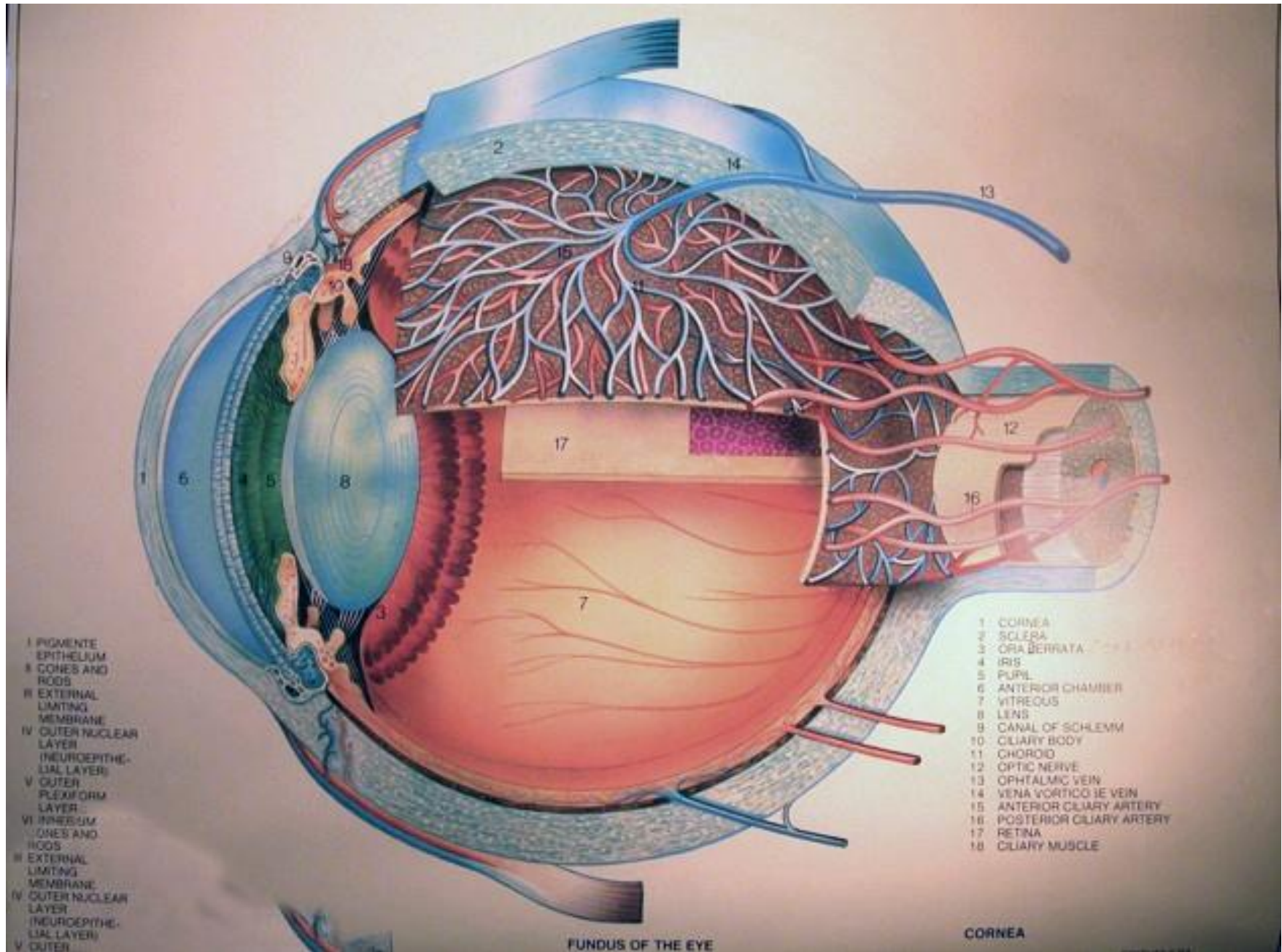
*** The eye measures approximately 21-24 mm in all its main diameters.

The coats of the eye

*** Three layers:

- ❑ The outer: inelastic coat, transparent cornea and opaque sclera.
- ❑ The middle, vascular coat, The Uvea: choroid, ciliary body and iris.
- ❑ The inner: The Retina, extends forwards to within 6 mm of the limbus.



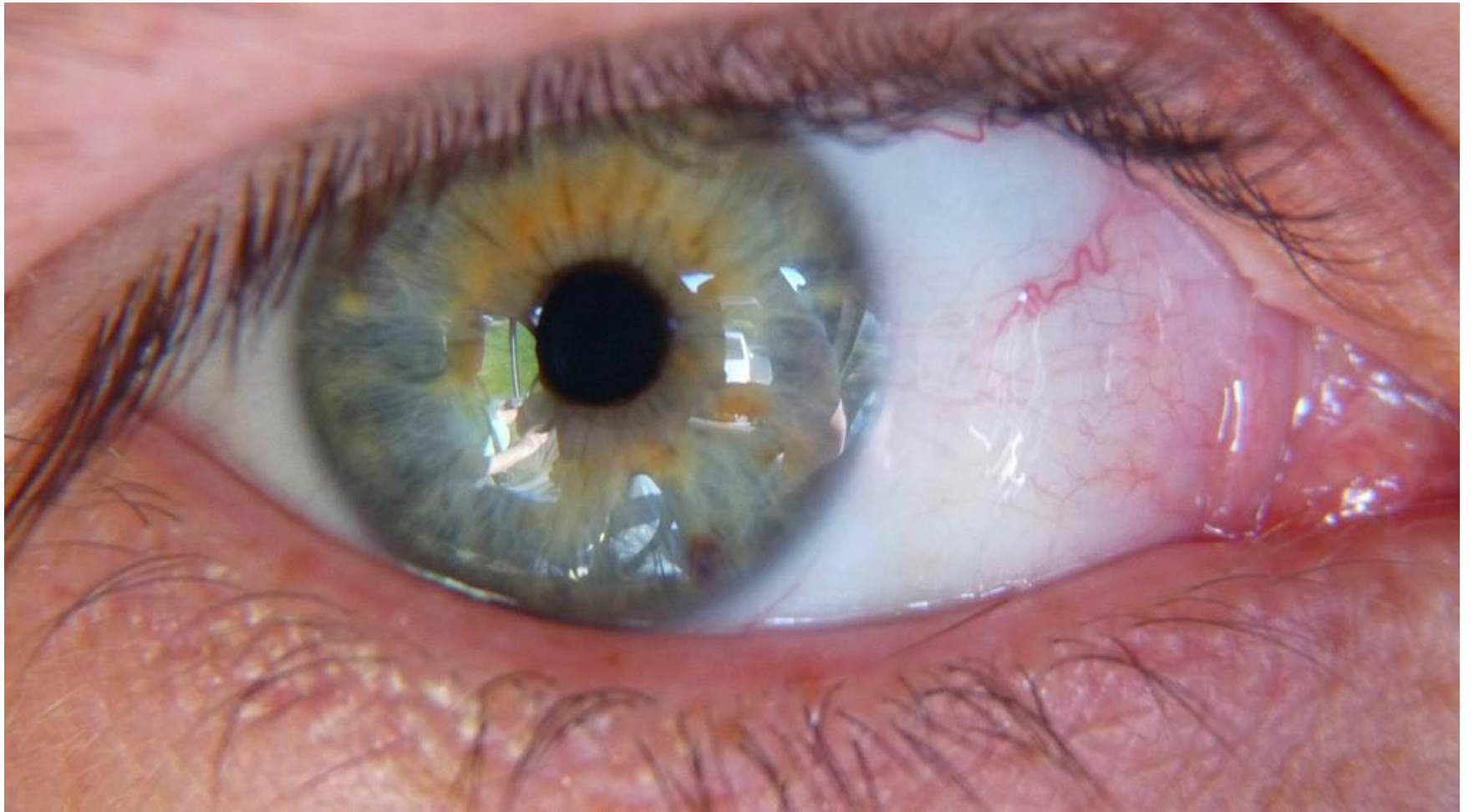

- I PIGMENTE EPITHELIUM
- II CONES AND RODS
- III EXTERNAL LIMITING MEMBRANE
- IV OUTER NUCLEAR LAYER (NEUROEPITHELIAL LAYER)
- V OUTER PLEXIFORM LAYER
- VI INNER PLEXIFORM LAYER
- VII CONES AND RODS
- VIII EXTERNAL LIMITING MEMBRANE
- IX OUTER NUCLEAR LAYER (NEUROEPITHELIAL LAYER)
- X OUTER

- 1 CORNEA
- 2 SCLERA
- 3 ORA BERRATA
- 4 IRIS
- 5 PUPIL
- 6 ANTERIOR CHAMBER
- 7 VITREOUS
- 8 LENS
- 9 CANAL OF SCHLEMM
- 10 CILIARY BODY
- 11 CHOROID
- 12 OPTIC NERVE
- 13 OPHTHALMIC VEIN
- 14 VENA VORTICOSA VEIN
- 15 ANTERIOR CILIARY ARTERY
- 16 POSTERIOR CILIARY ARTERY
- 17 RETINA
- 18 CILIARY MUSCLE

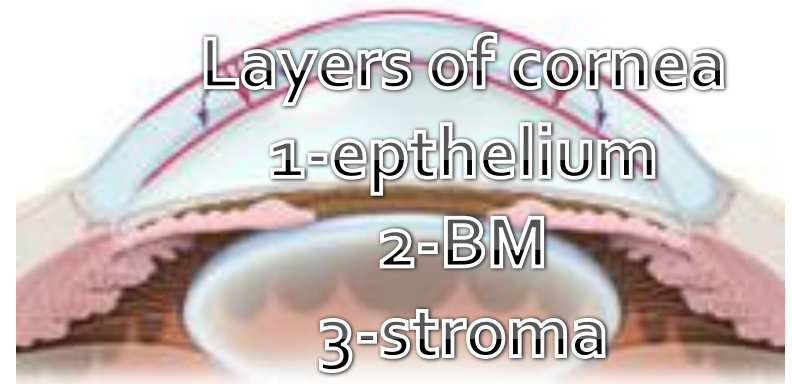FUNDUS OF THE EYE

CORNEA



Cornea

- ✓ It has 5 layers.
- ✓ 500 -530 micron in thickness.
- ✓ Transparent
- ① Avascular
- ② Regularly arranged collagen fibers.



Layers of cornea

1-epithelium

2-BM

3-stroma

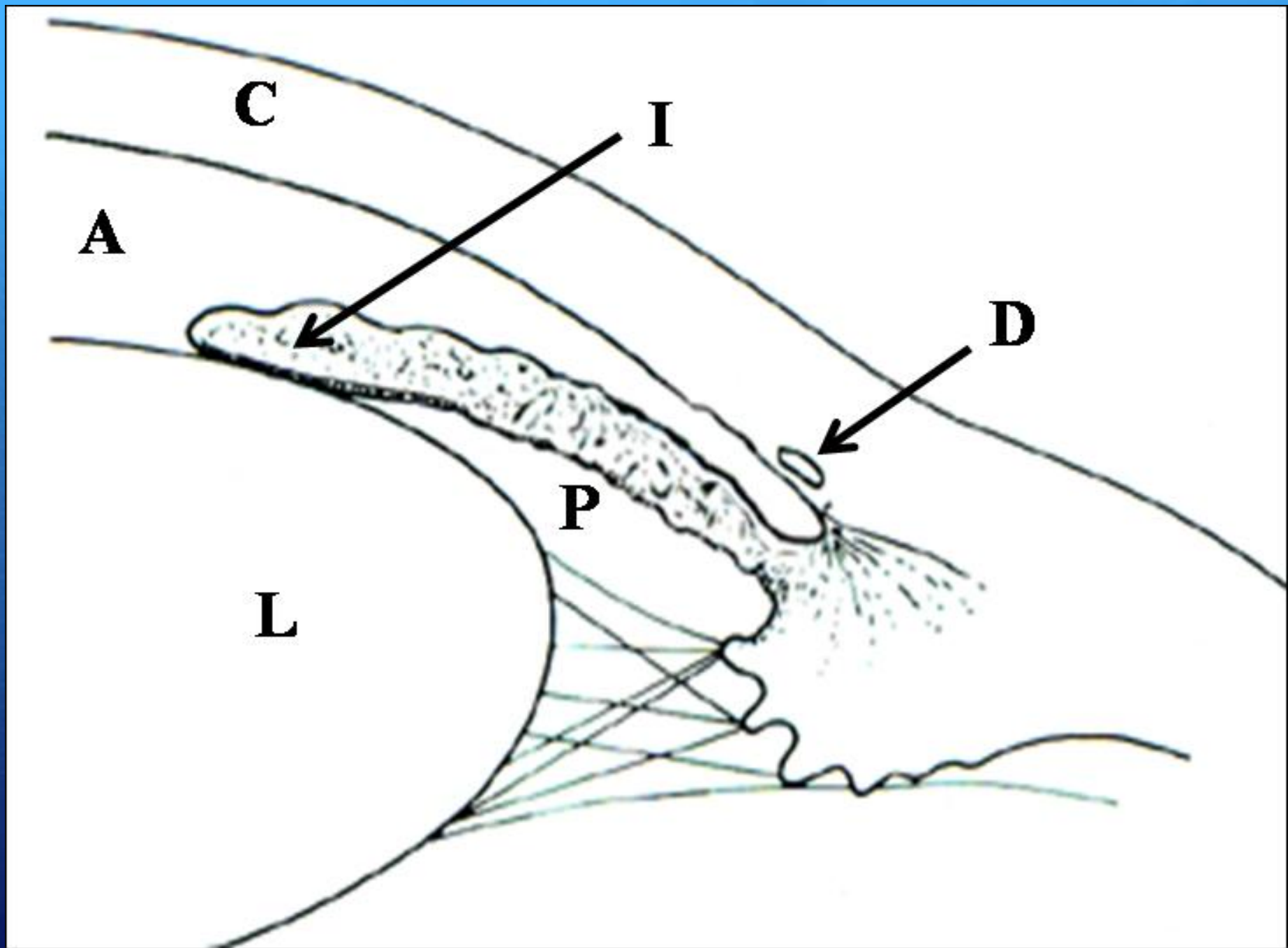
4-DM

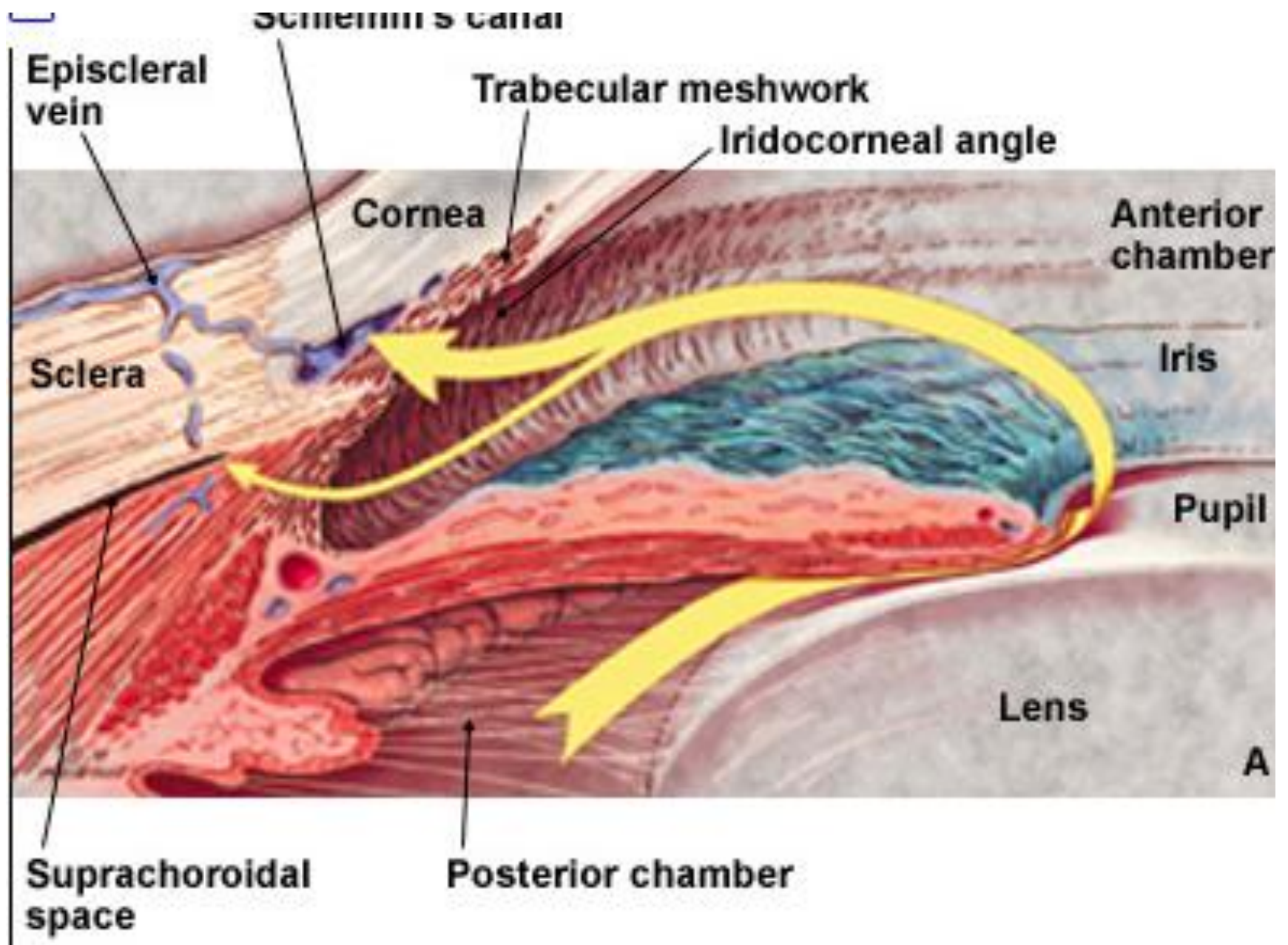
5-endothelium

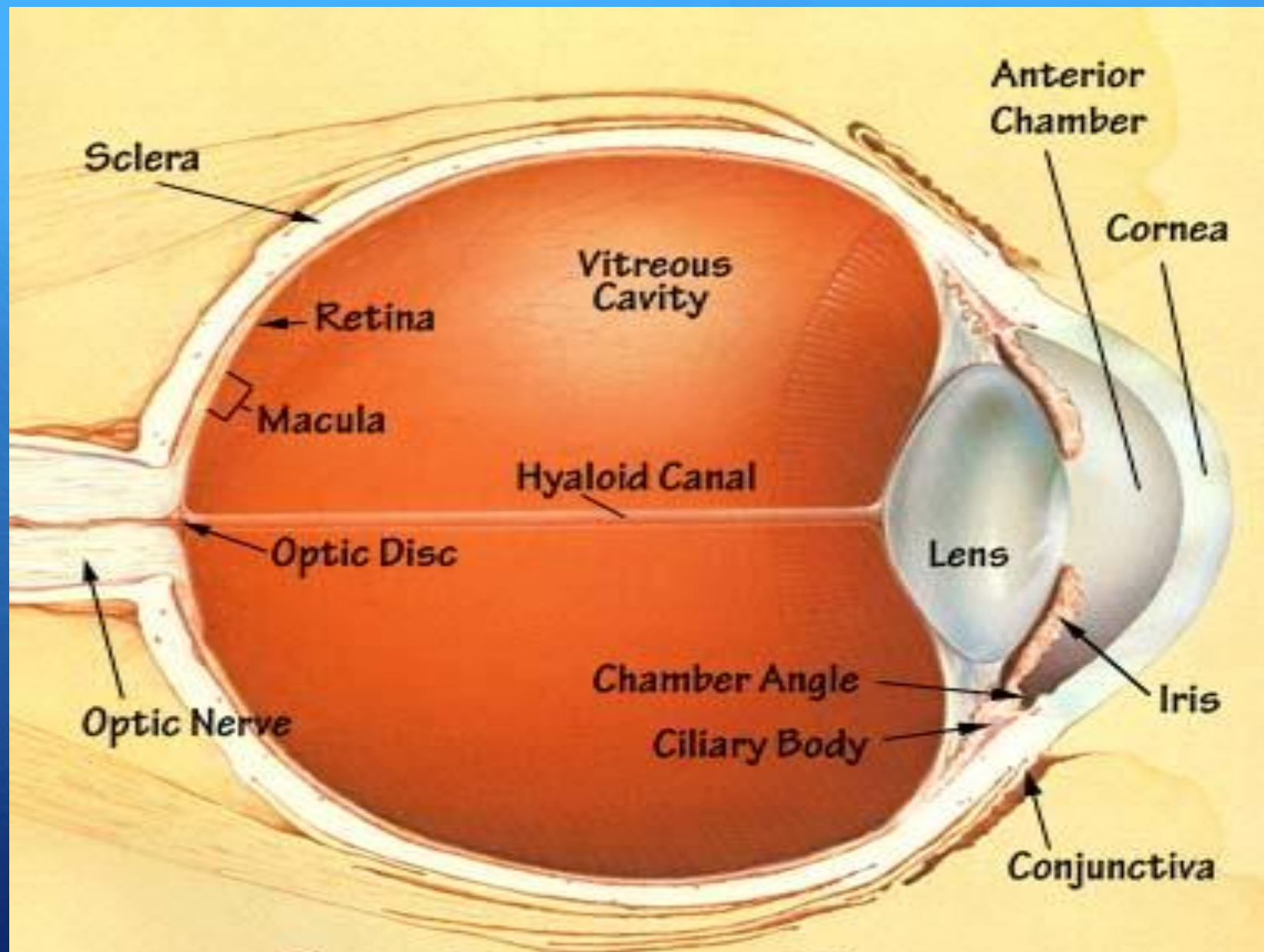
The Chambers of The Eye

*****Three optically clear spaces:**

- ◆ The anterior chamber, in front of the iris
- ◆ The posterior chamber, immediately behind the iris. These two chambers which communicate through the pupil are filled with clear aqueous humour.
- ◆ The vitreous cavity: filled by gel-like structure, The Vitreous.
- ◆ ANTERIOR AND POSTERIOR SEGMENT

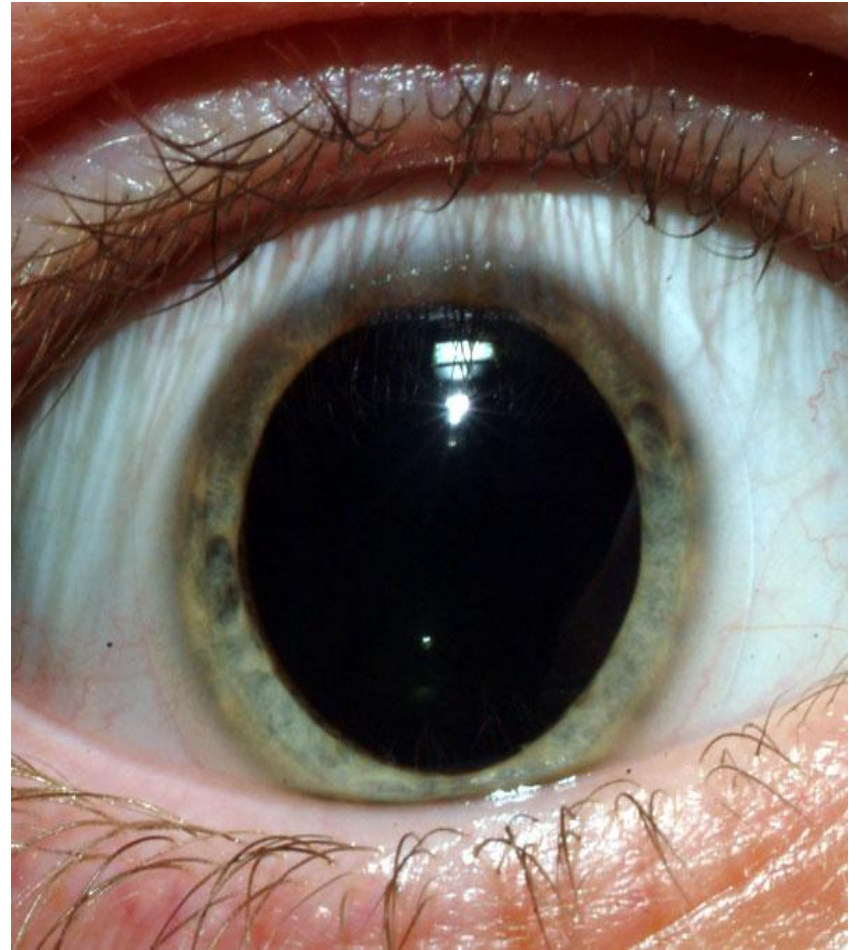
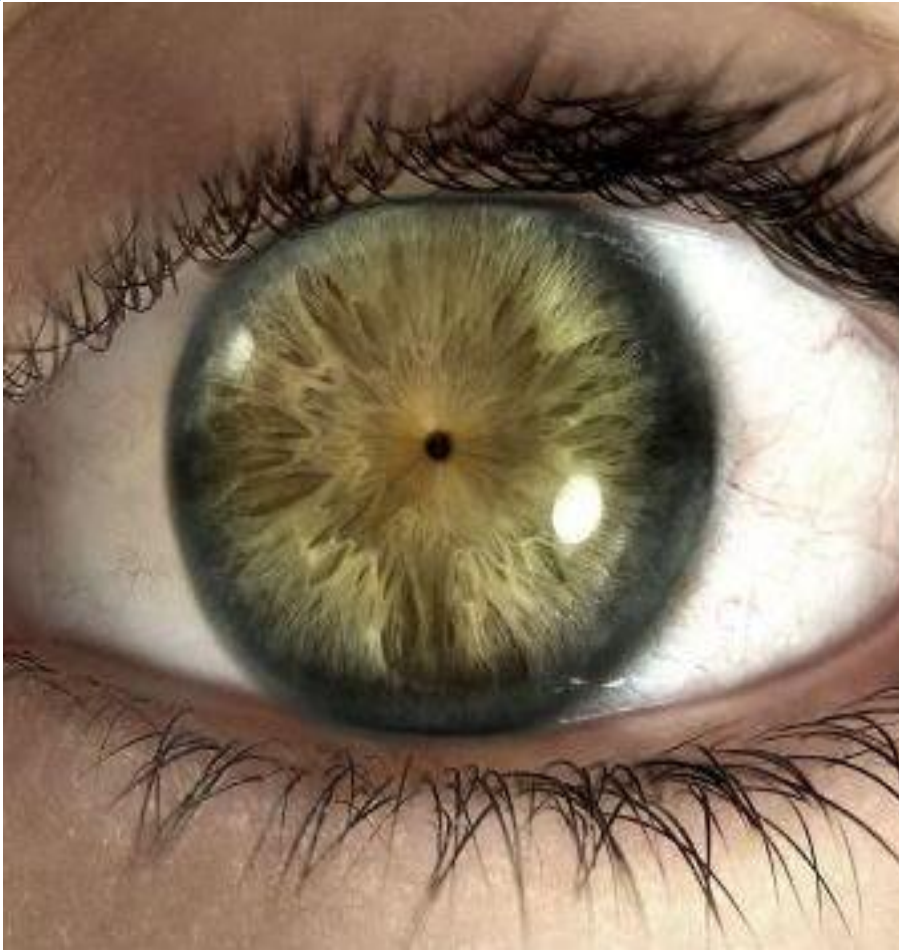

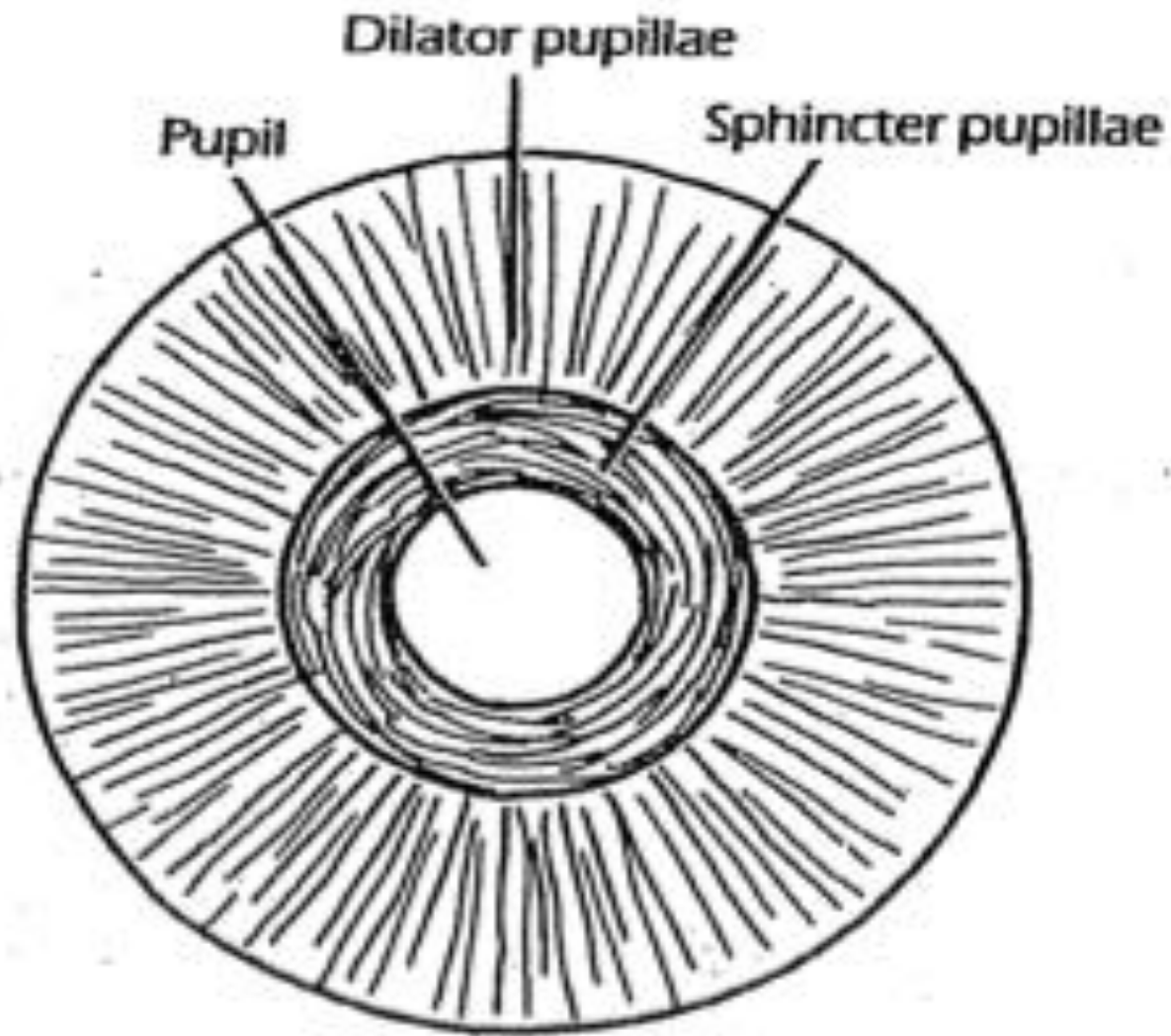




The Human Eye

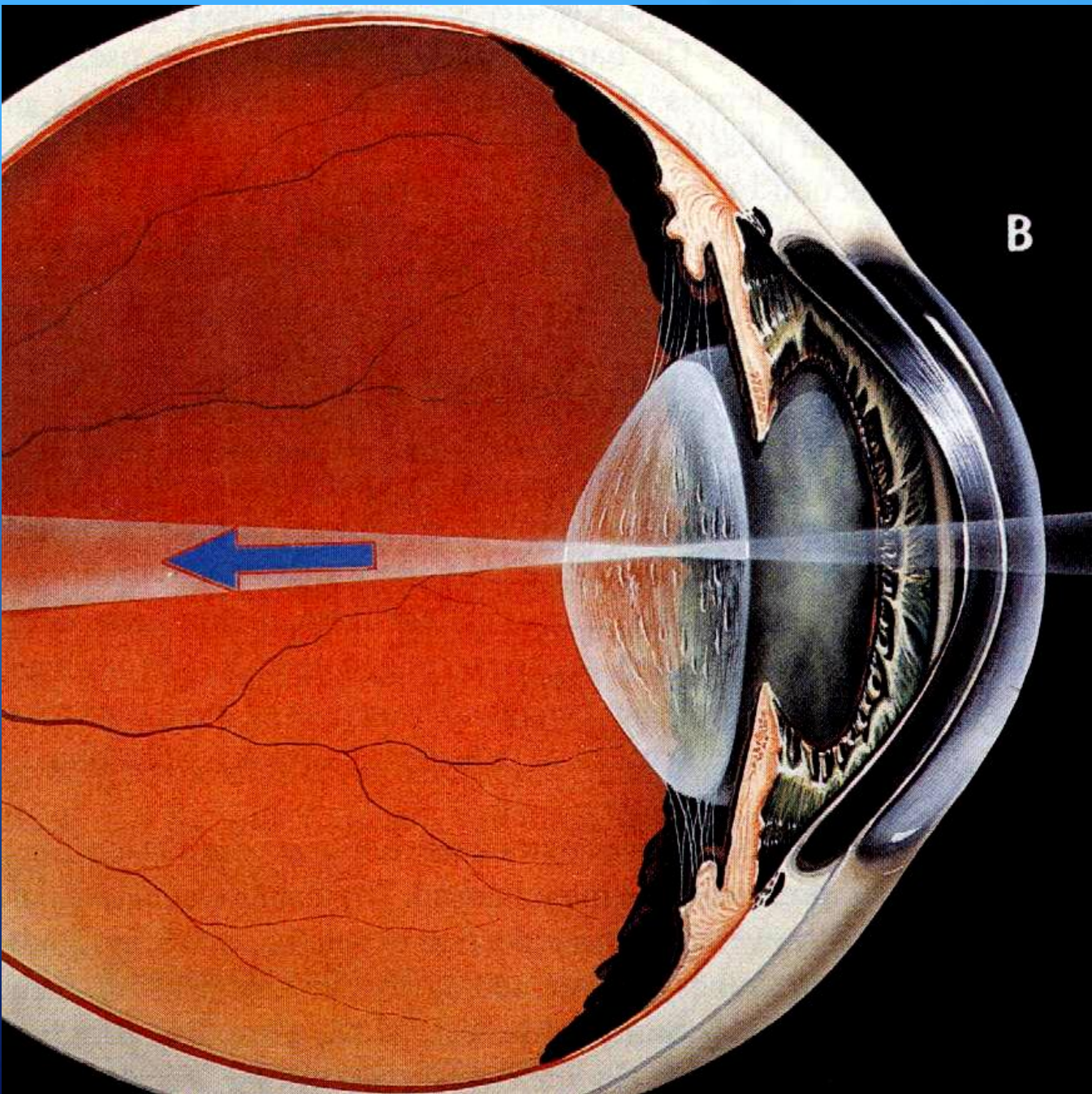
Iris & Pupil

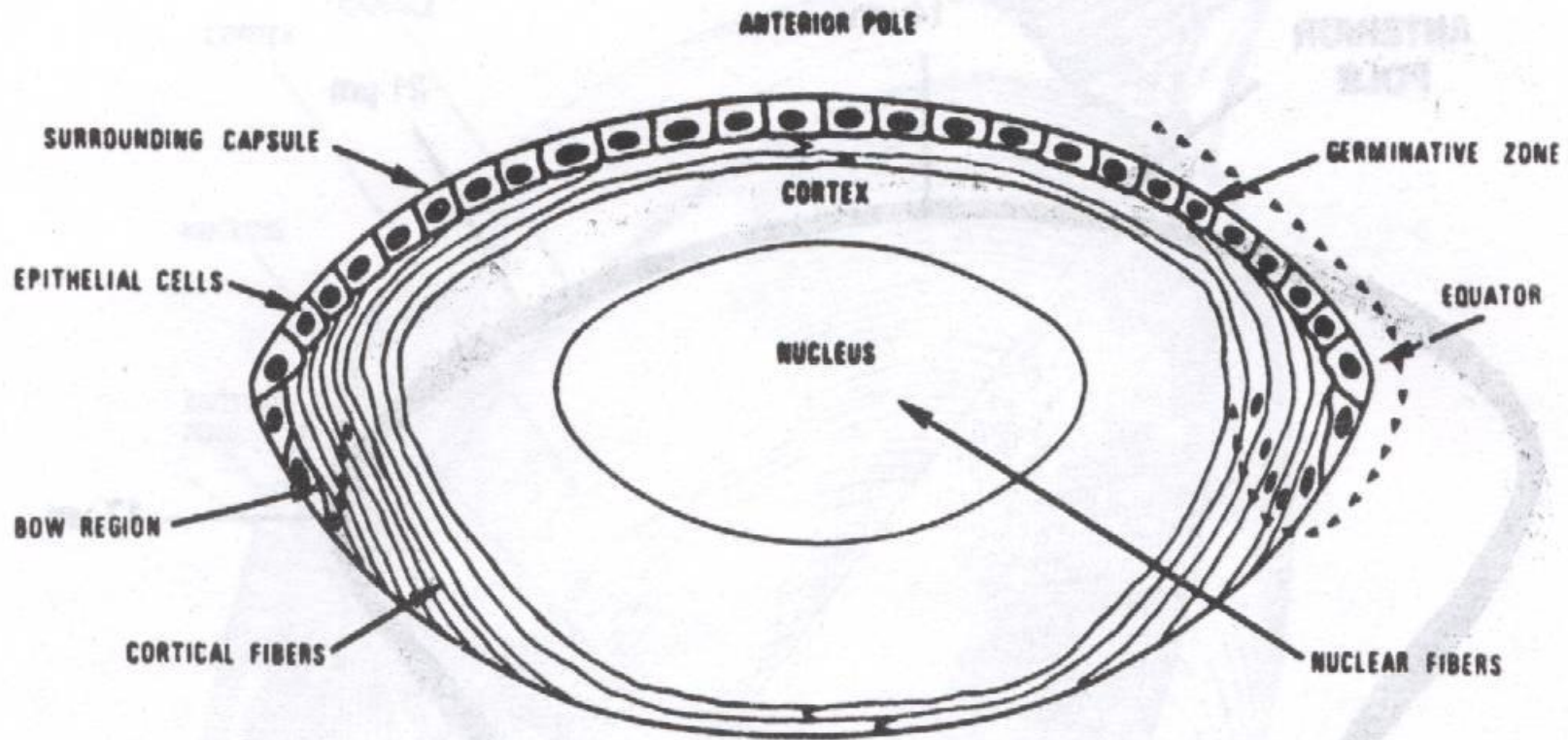


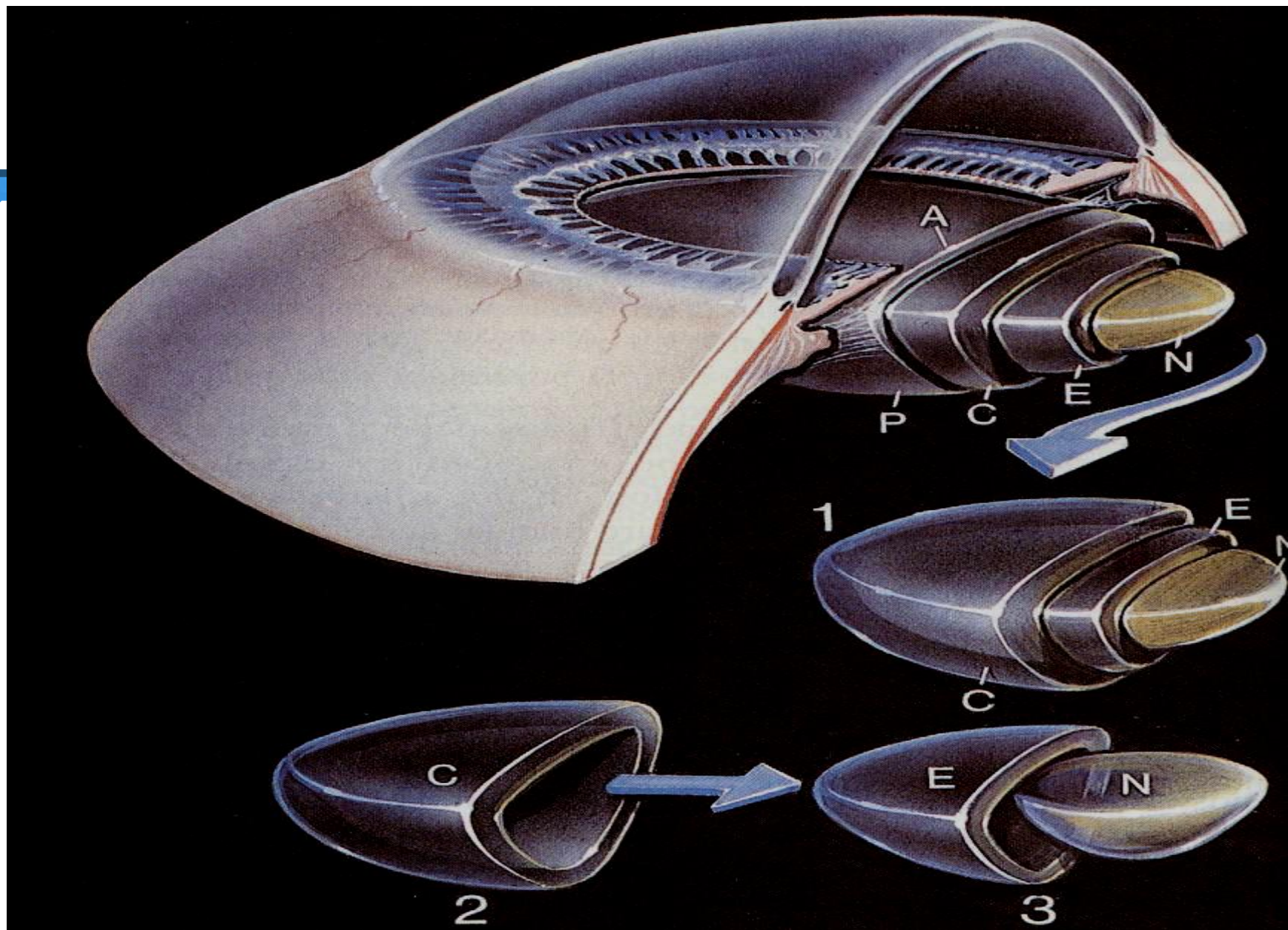


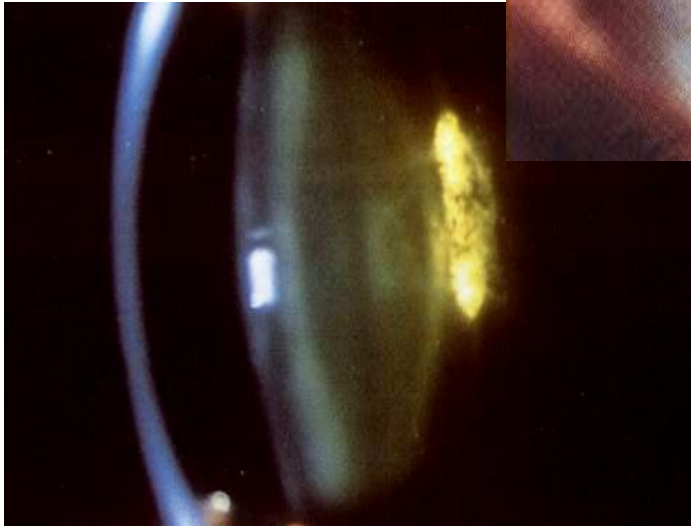
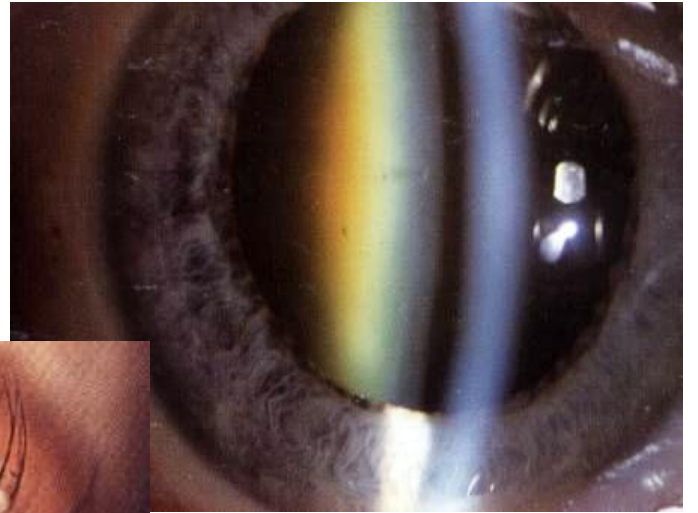
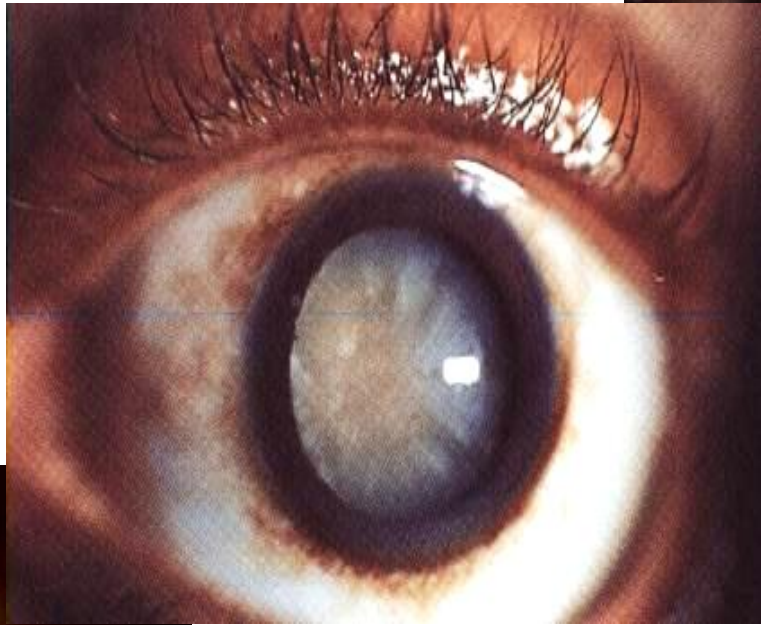
The Lens

- ❑ The crystalline lens is the only structure continuously growing throughout the life.
- ❑ Changeable refractive media.
- ❑ Capsule, epithelium and lens fibers.
- ❑ Congenital anomalies and effect of systemic diseases.
- ❑ Cataract.





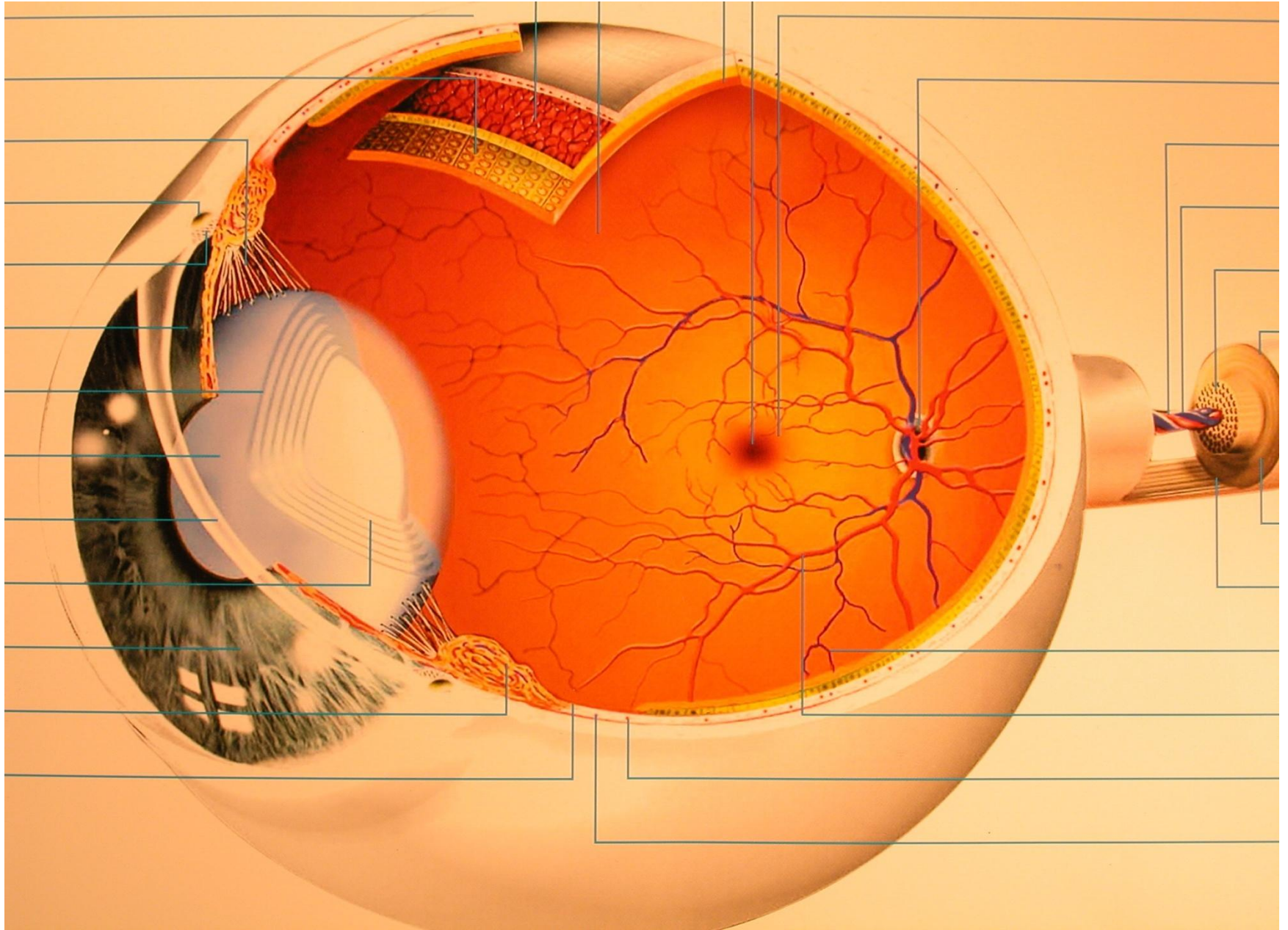


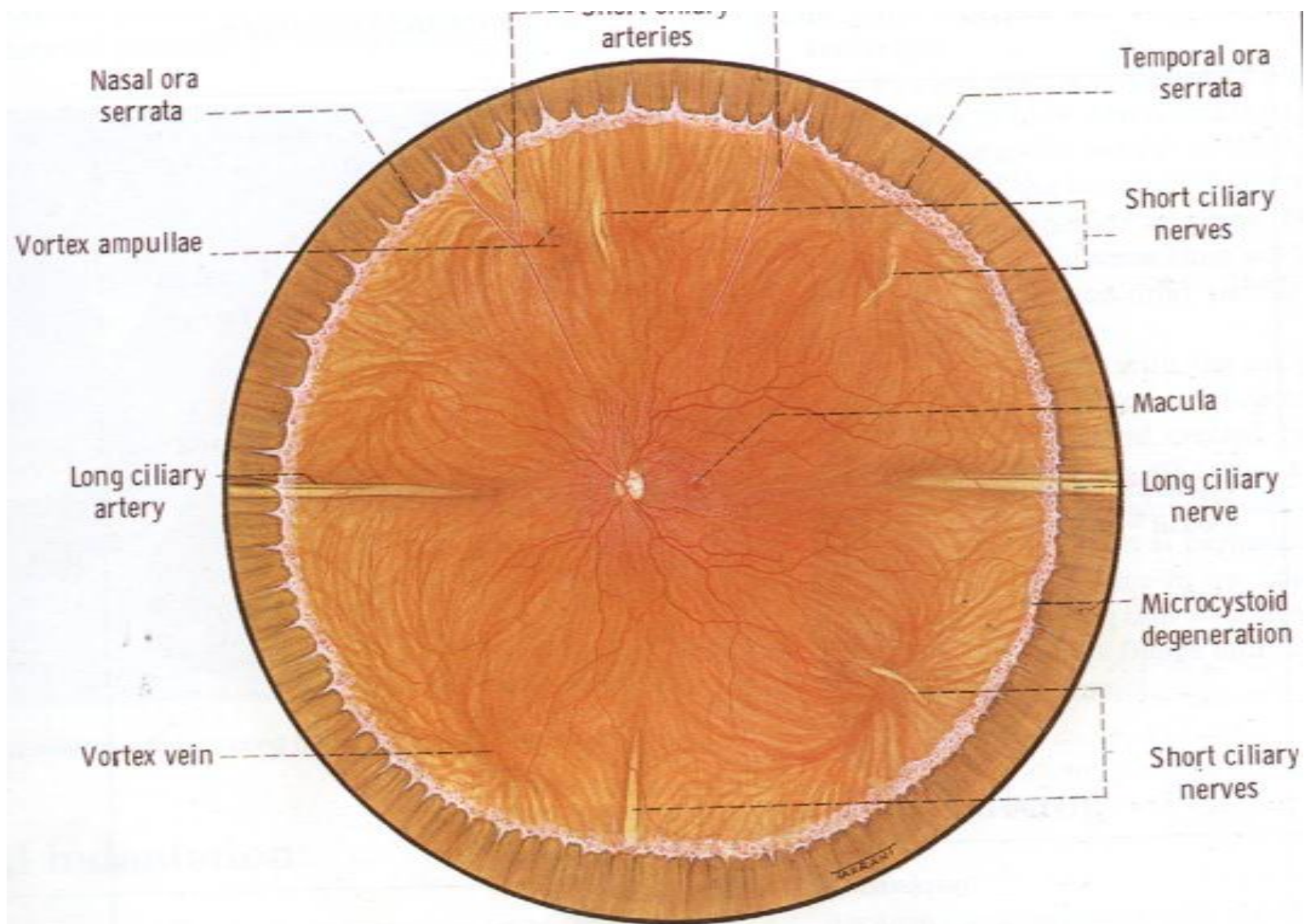


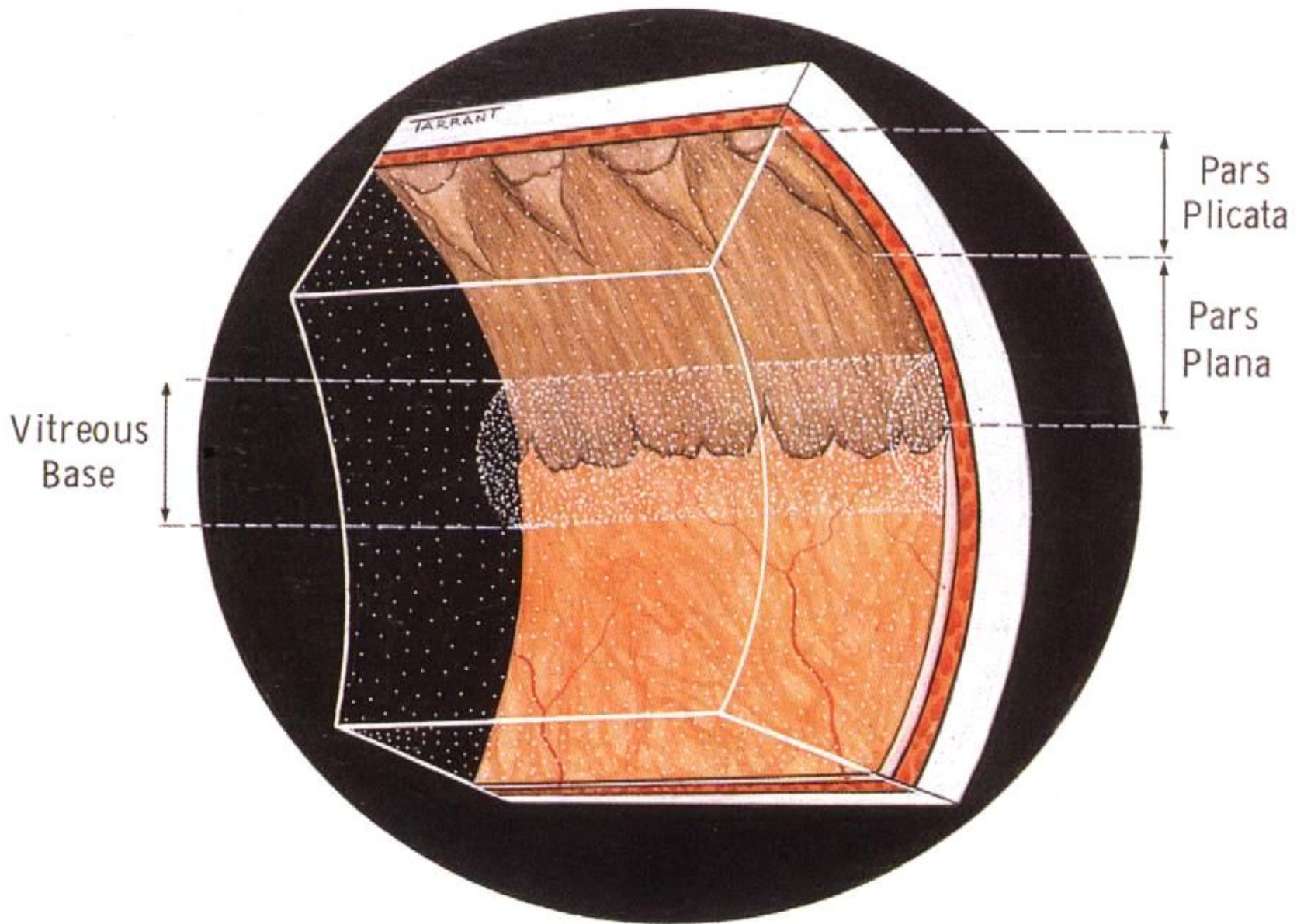
cataract

Retina and Vitreous

- ❑ Vitreous attachment.
- ❑ Optic nerve head, macula, fovea, retinal background, Ora serrata, and retinal vasculature.
- ❑ Effect of systemic diseases.
- ❑ Retinal detachment.







FUNDUS OF THE EYE

NASAL

TEMPORAL

PILLA

TIC NERVE

ERIOR
SAL
TERY

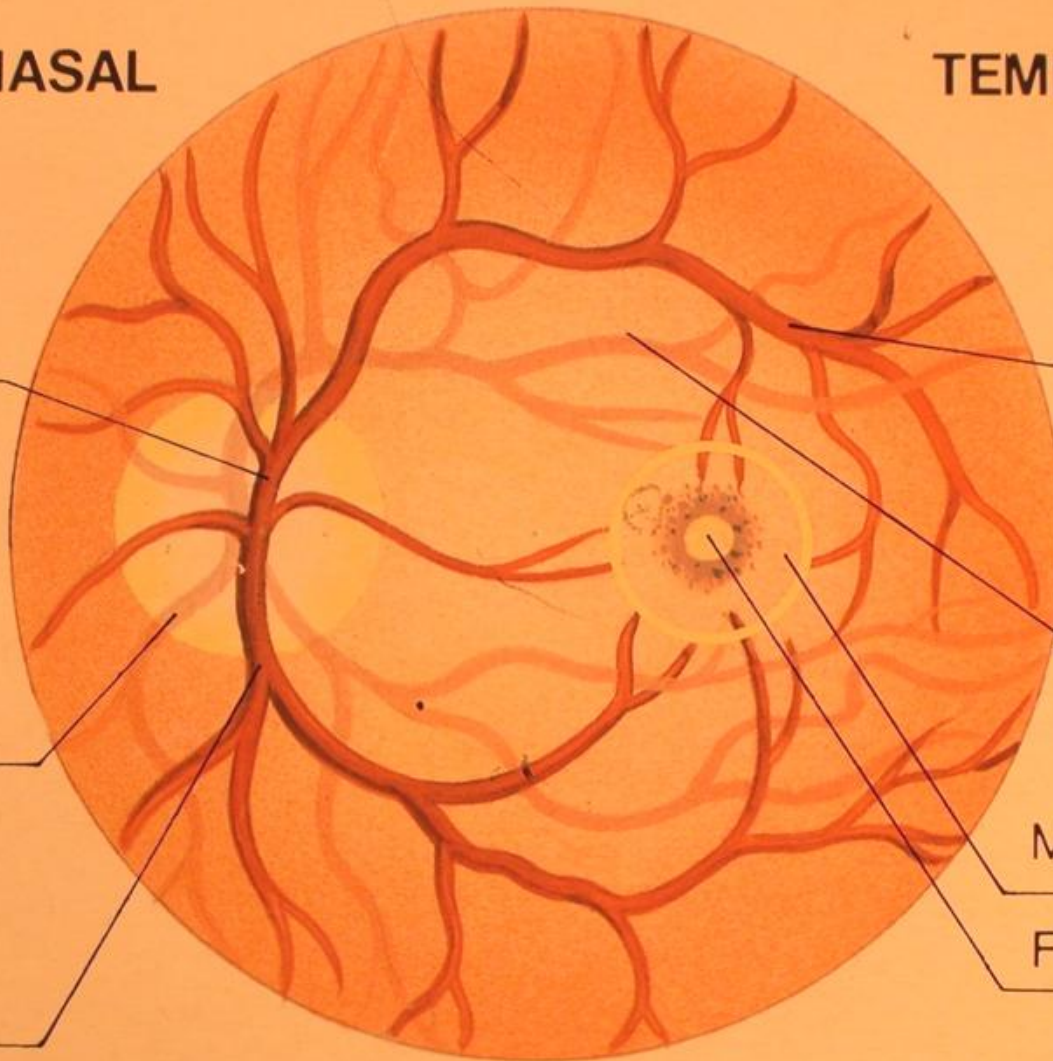
ERIOR
MPORAL
N

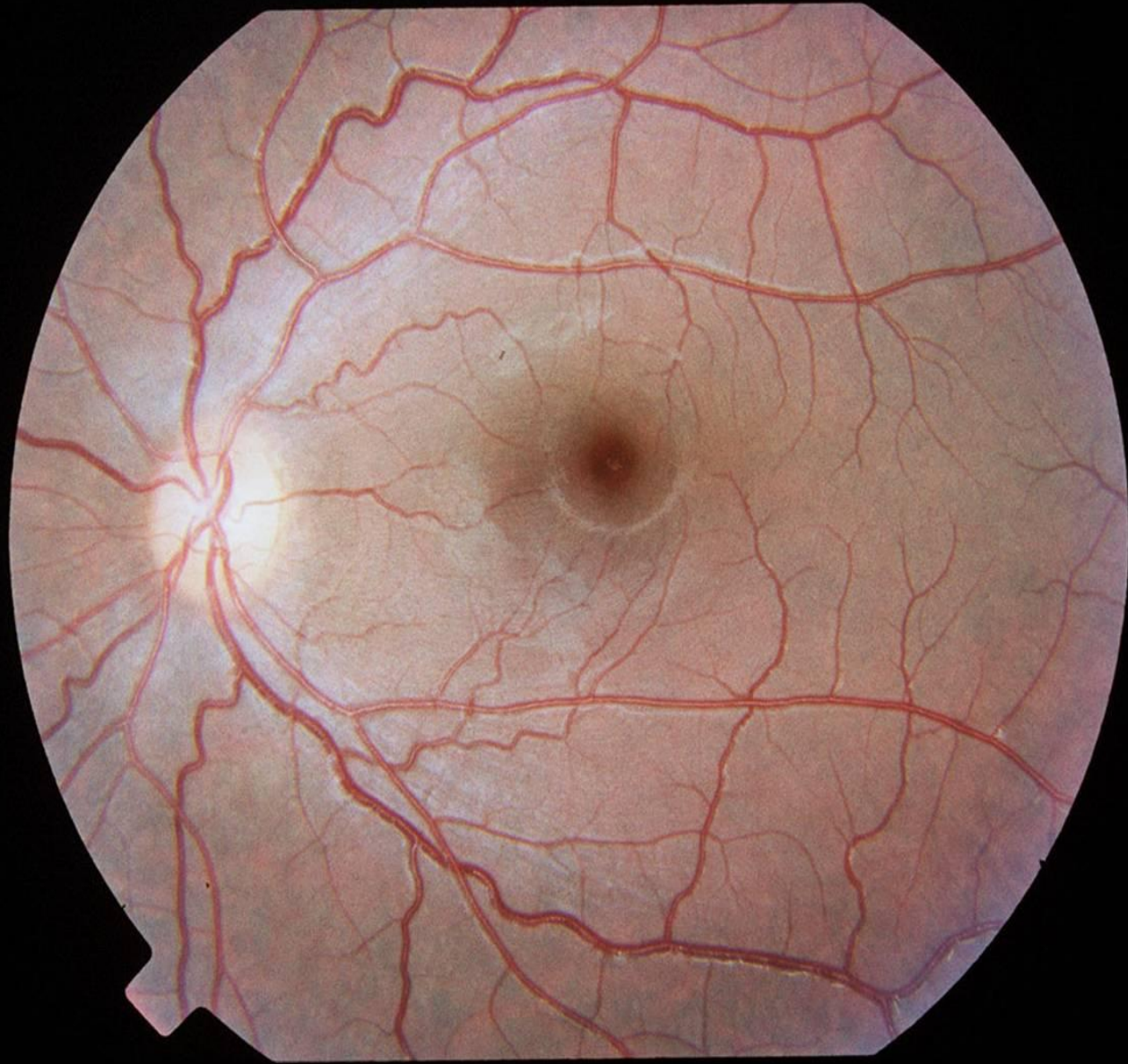
SUPERIOR
TEMPORAL
VEIN

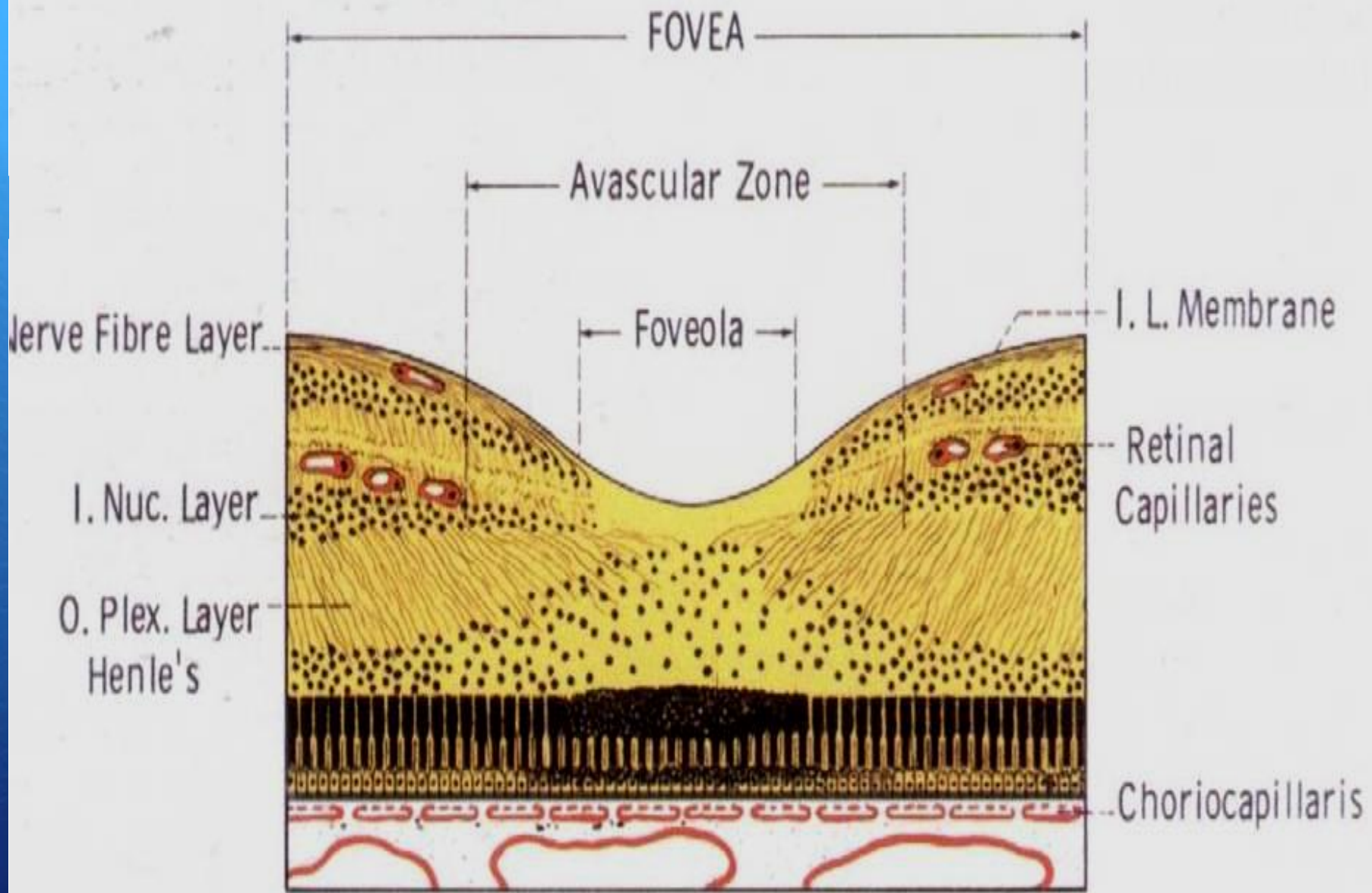
SUPERIOR
TEMPORAL
ARTERY

MACULA LUTEA

FOVEA CENTRA



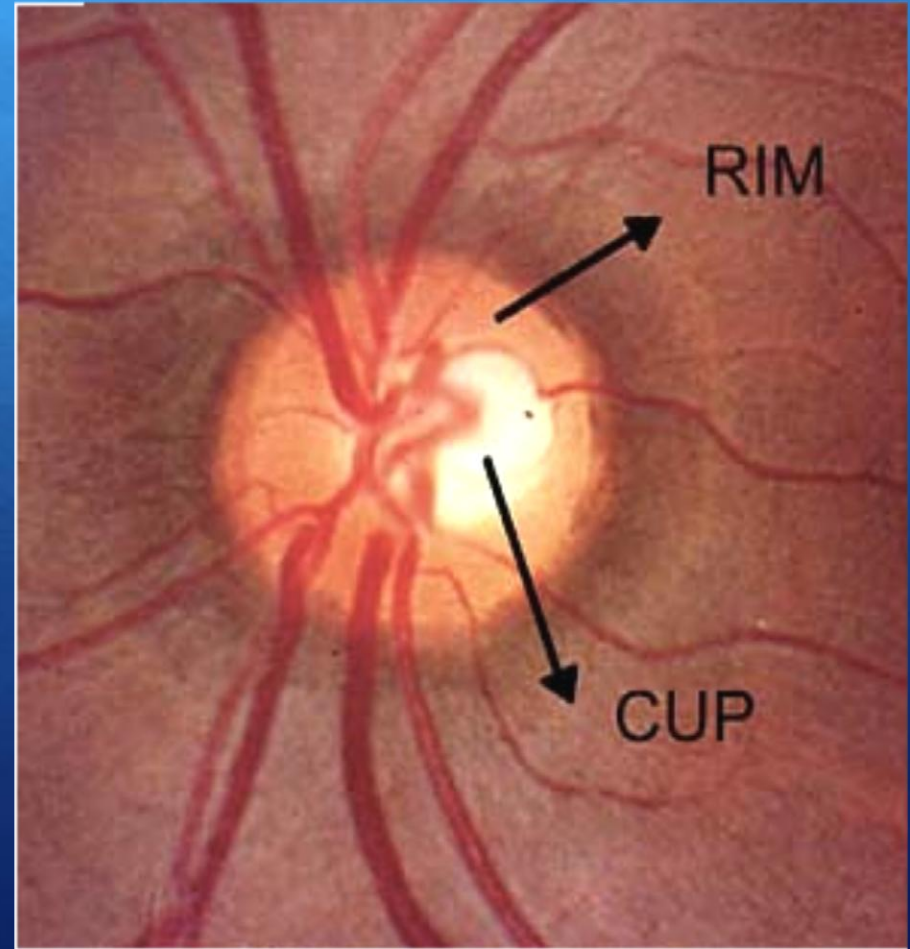


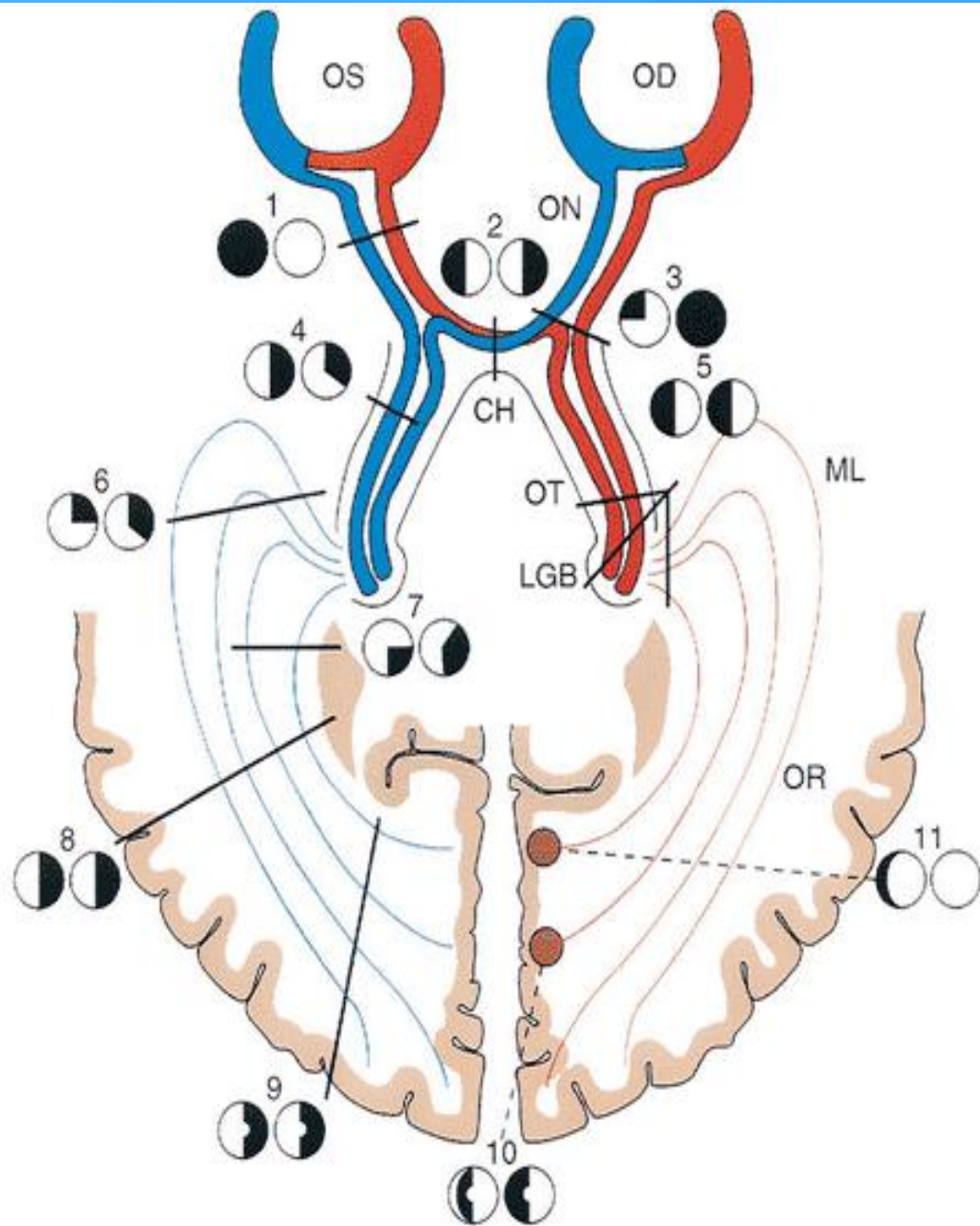


ZEISS

Optic Nerve

- ◆ contains around 1.2 million nerve fibers, which are axons of the retinal ganglion cells.
- ◆ 1 mm in the globe.
- ◆ 25 mm in the orbit.
- ◆ 9 mm in the optic canal.
- ◆ 16 mm in the cranial space
- ◆ Partial decussation occurs and about 53% of the fibers cross to form the optic tracts.

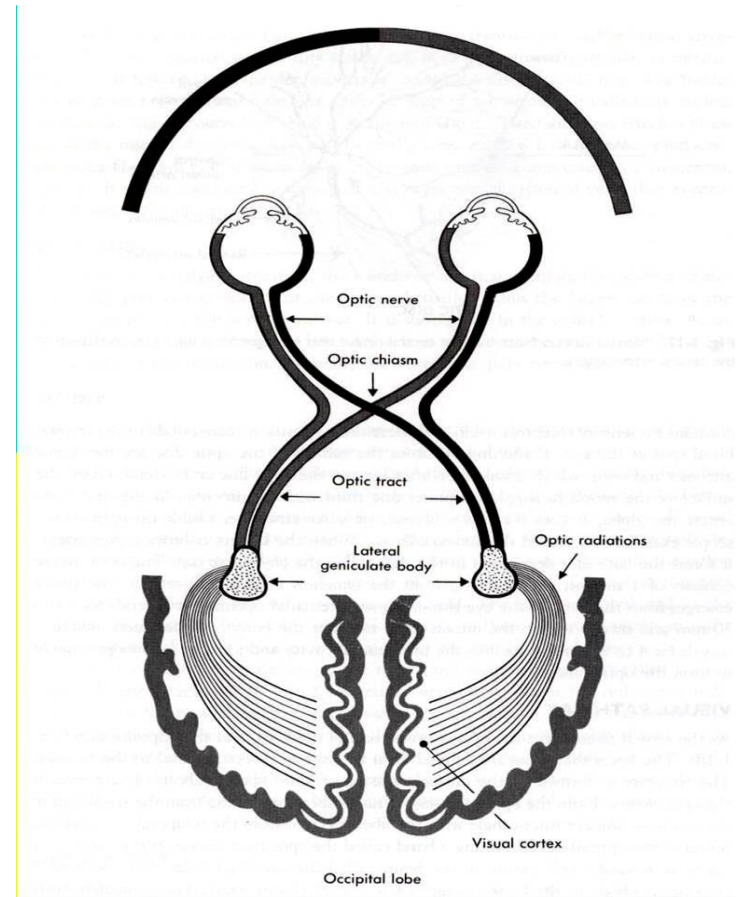


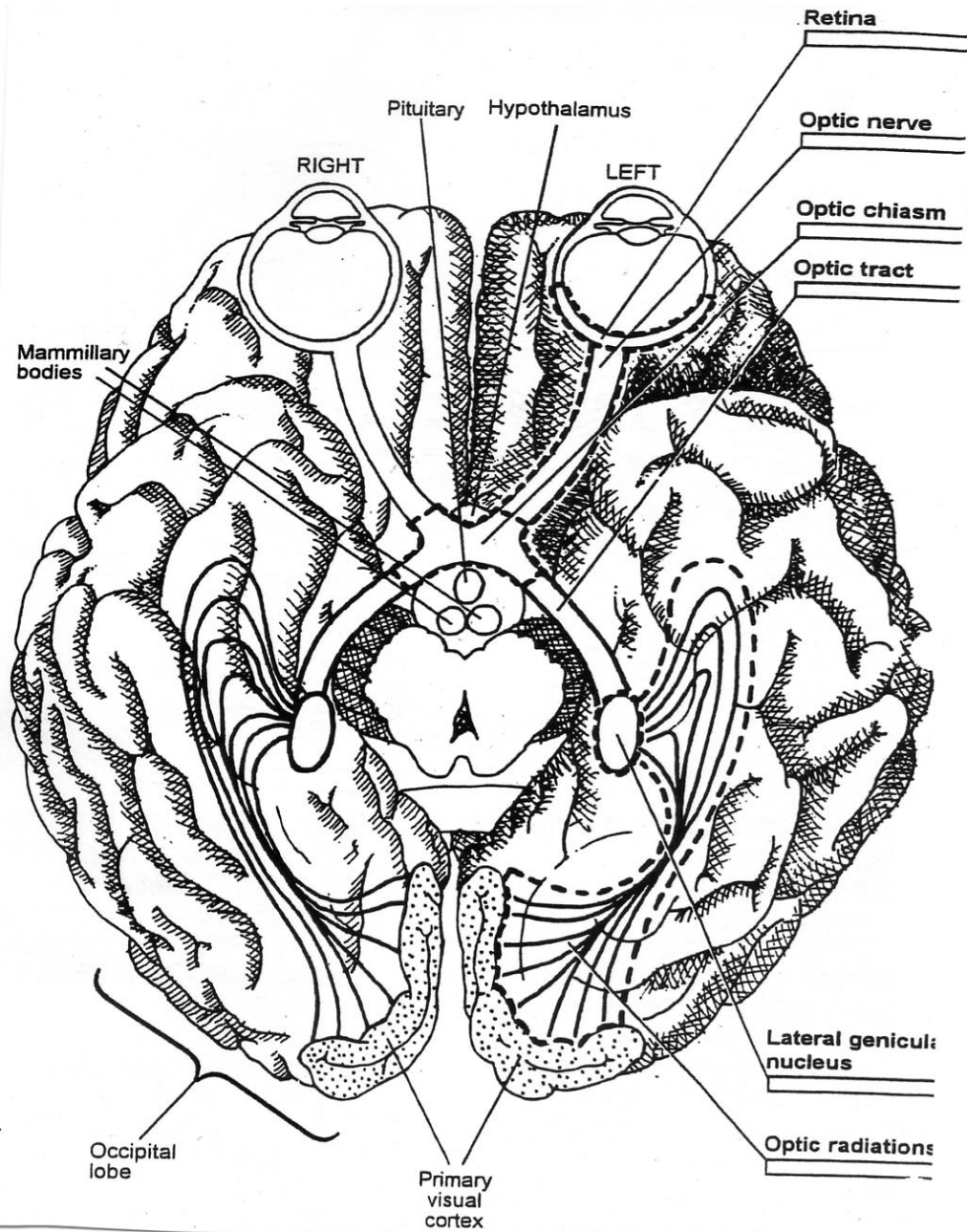


The Visual Pathway

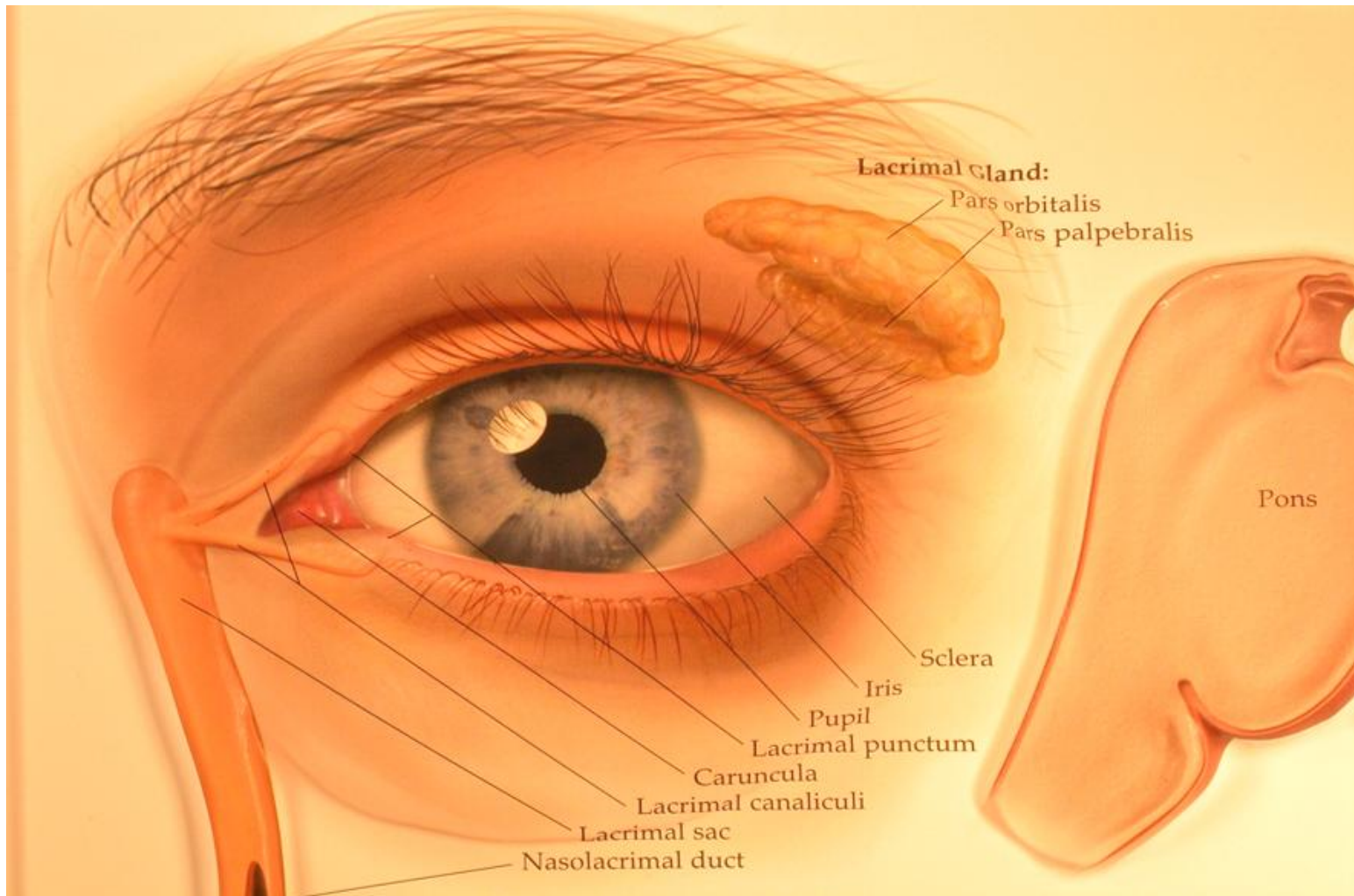
Visual Pathway: Three neurons

1. Bipolar cell, lies within the retina.
2. Ganglion cell, synapse in lateral geniculate body.
3. Third neuron terminates in visual cortex.



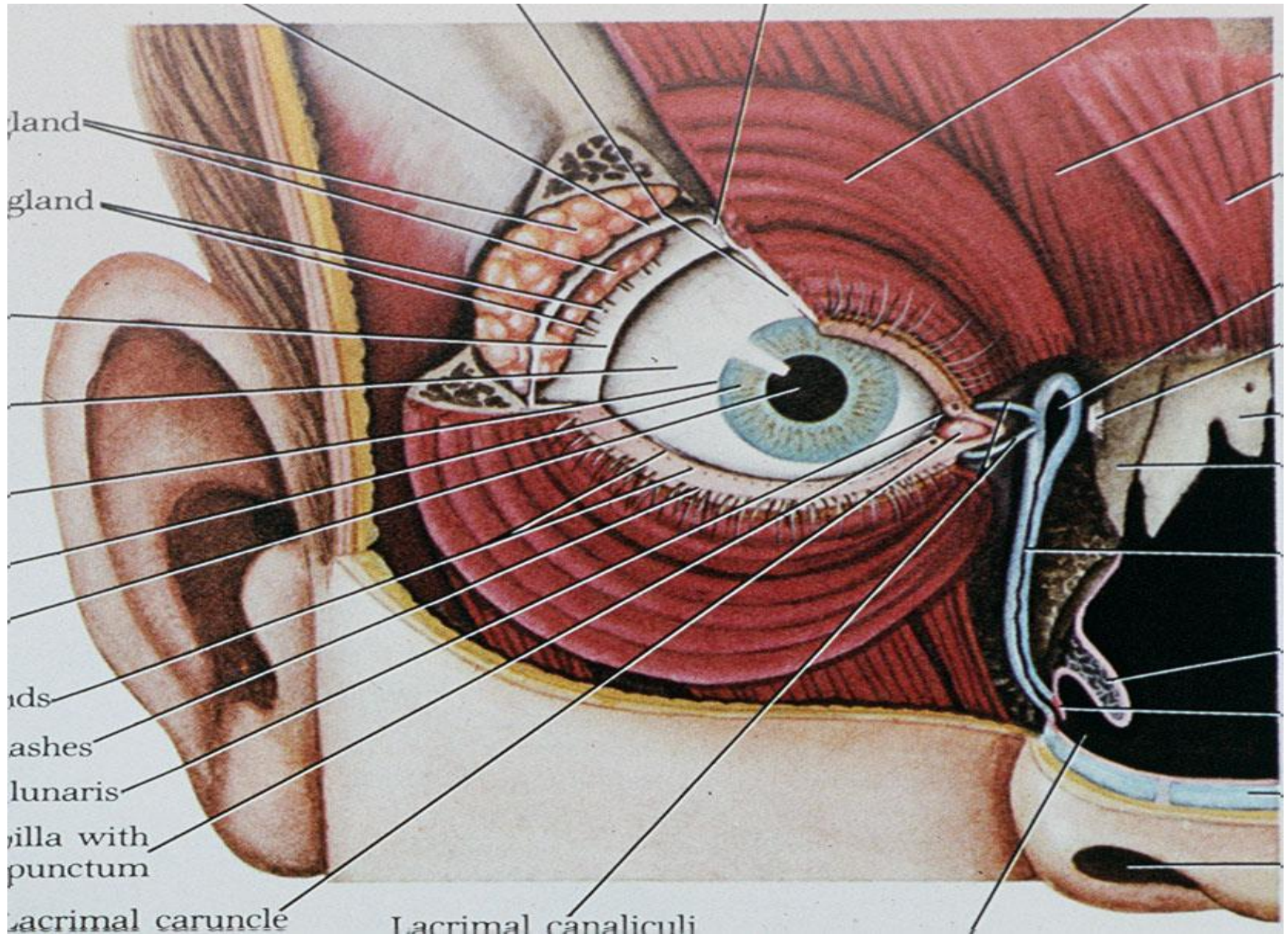


THE LACRIMAL APPARATUS



THE LACRIMAL APPARATUS

- ❑ Lacrimal gland secretes tears into the upper fornix of the conjunctival sac which are spread over the surface of the cornea as a tear film by blinking of the lids.
- ❑ Tears accumulate at the inner canthus and drain into the lacrimal sac via the puncta & canaliculi.
- ❑ The sac is continuous inferiorly with the nasolacrimal duct which opens into the nasal cavity just beneath the inferior turbinate.



gland

gland

ids

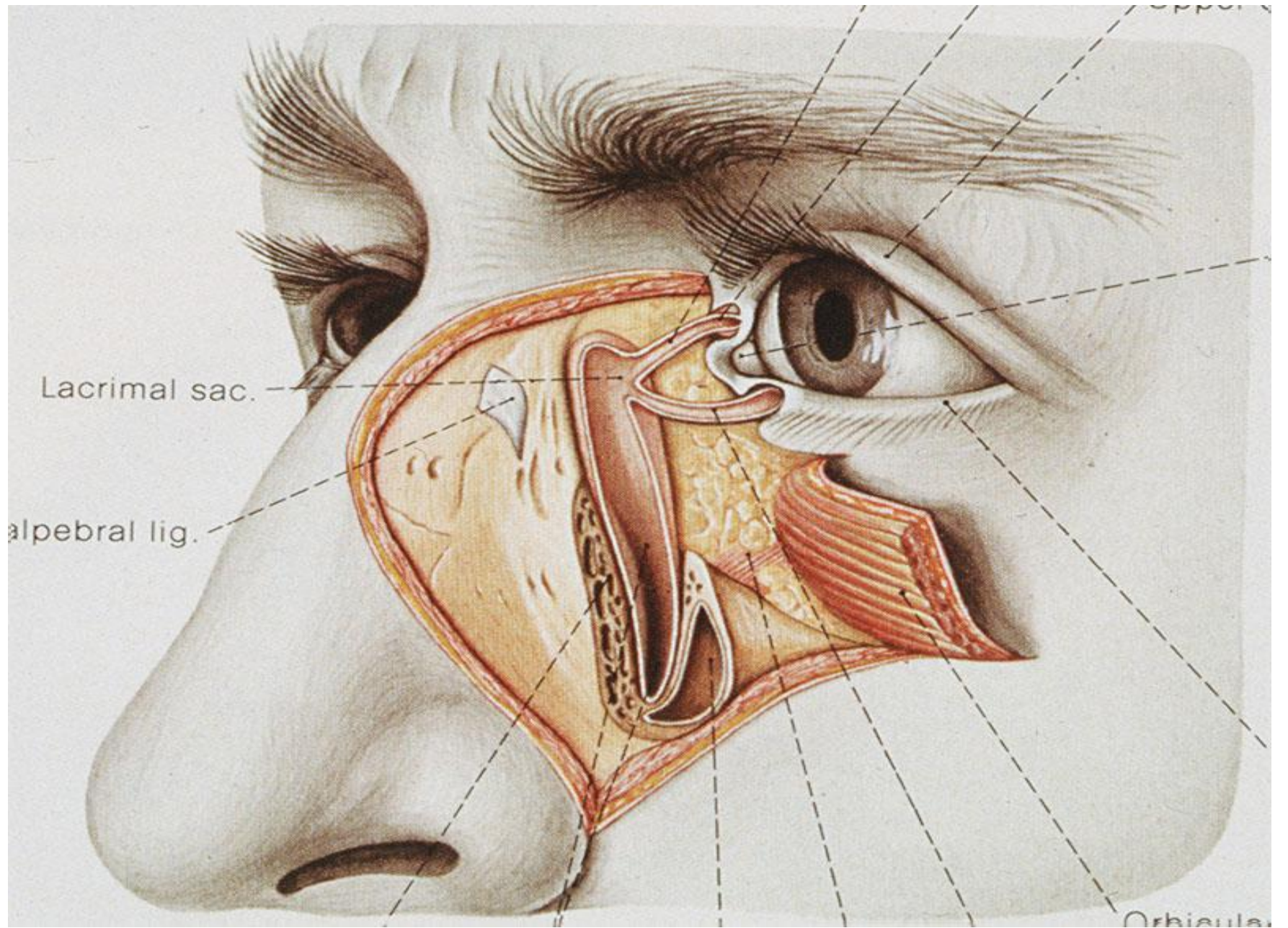
ashes

lunaris

villa with
punctum

lacrimal caruncle

Lacrimal canaliculi

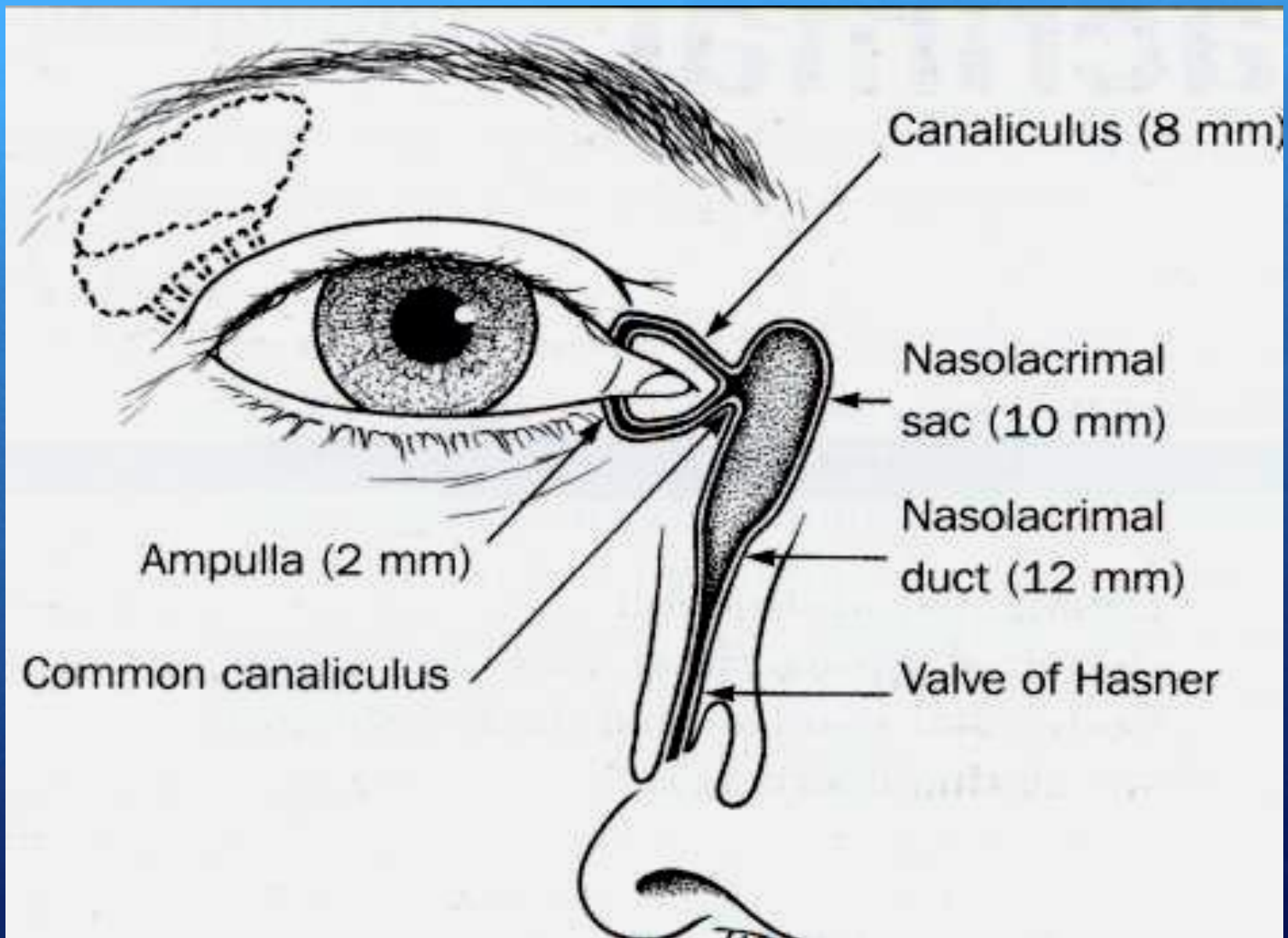


Lacrimal sac.

Alpebral lig.

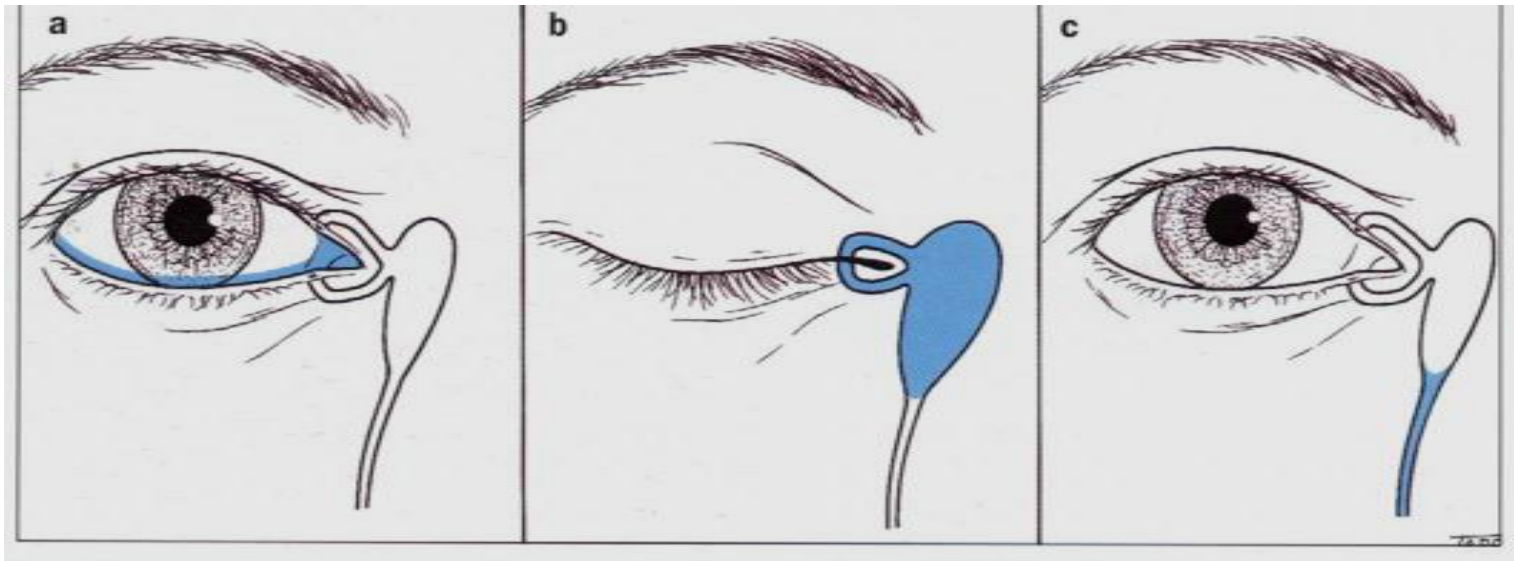
Orbicle

Upper



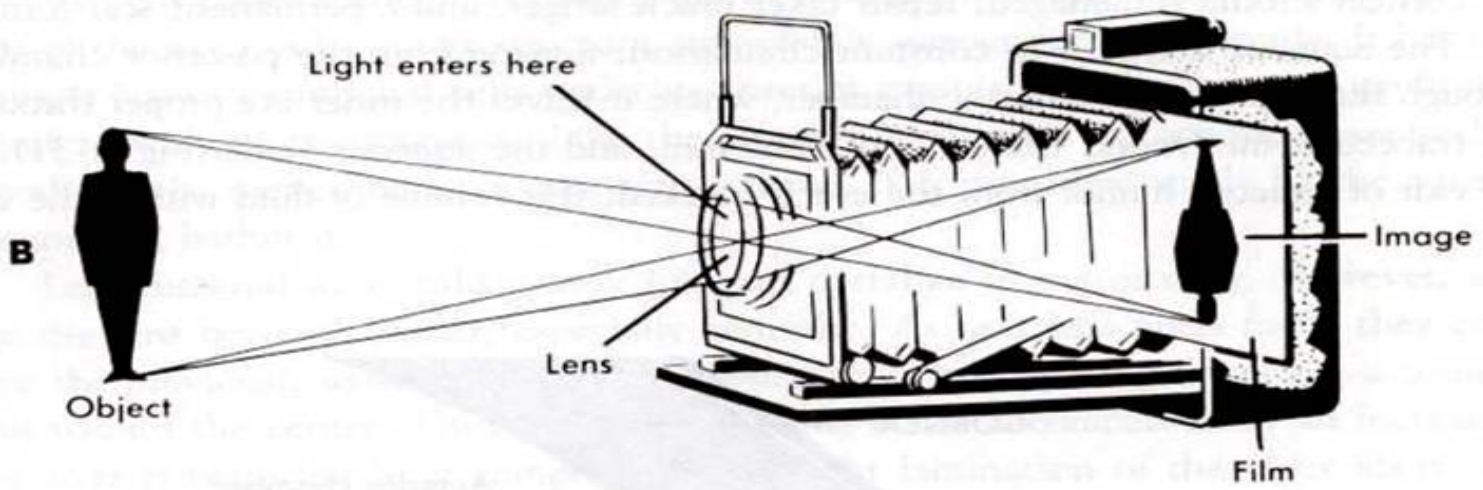
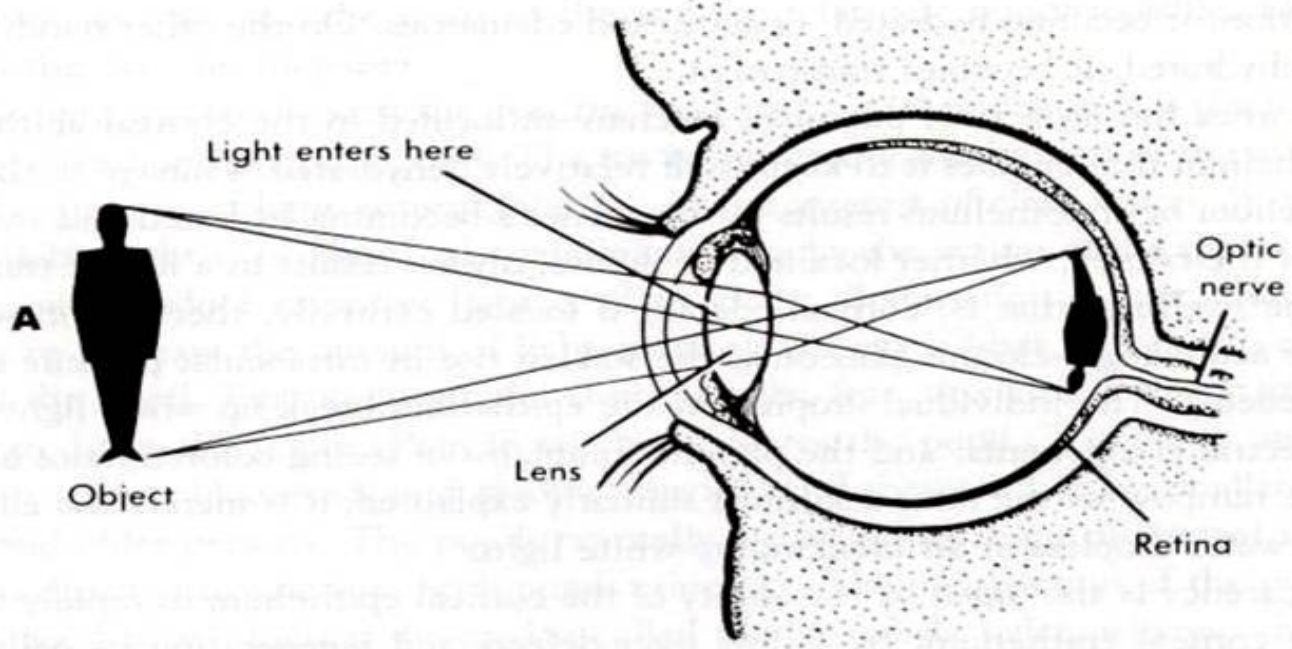
Lacrimal Apparatus

- ❑ Tear secretion.
- ❑ Layers of precorneal tear film.
- ❑ Drainage of tear.



Optics of the Eye

- ❑ The eye is like a camera. Light must have a clearly pathway to be clearly focused on the sensory receptors of the retina, i.e., Clear cornea, anterior chamber, lens and vitreous cavity.
- ❑ The Refractive power of the eye is about 58 - 62 diopters.



Optics of the Eye (cont.)

- ◆ The cornea is the major refracting element of the eye with a power of approximately 40 diopters. If the curvature is greater in one meridian than the other→ Astigmatism.
- ◆ The refractive power of the lens is about 17-21 diopters at rest. Accommodation able to change the power of the lens markedly depends on age.

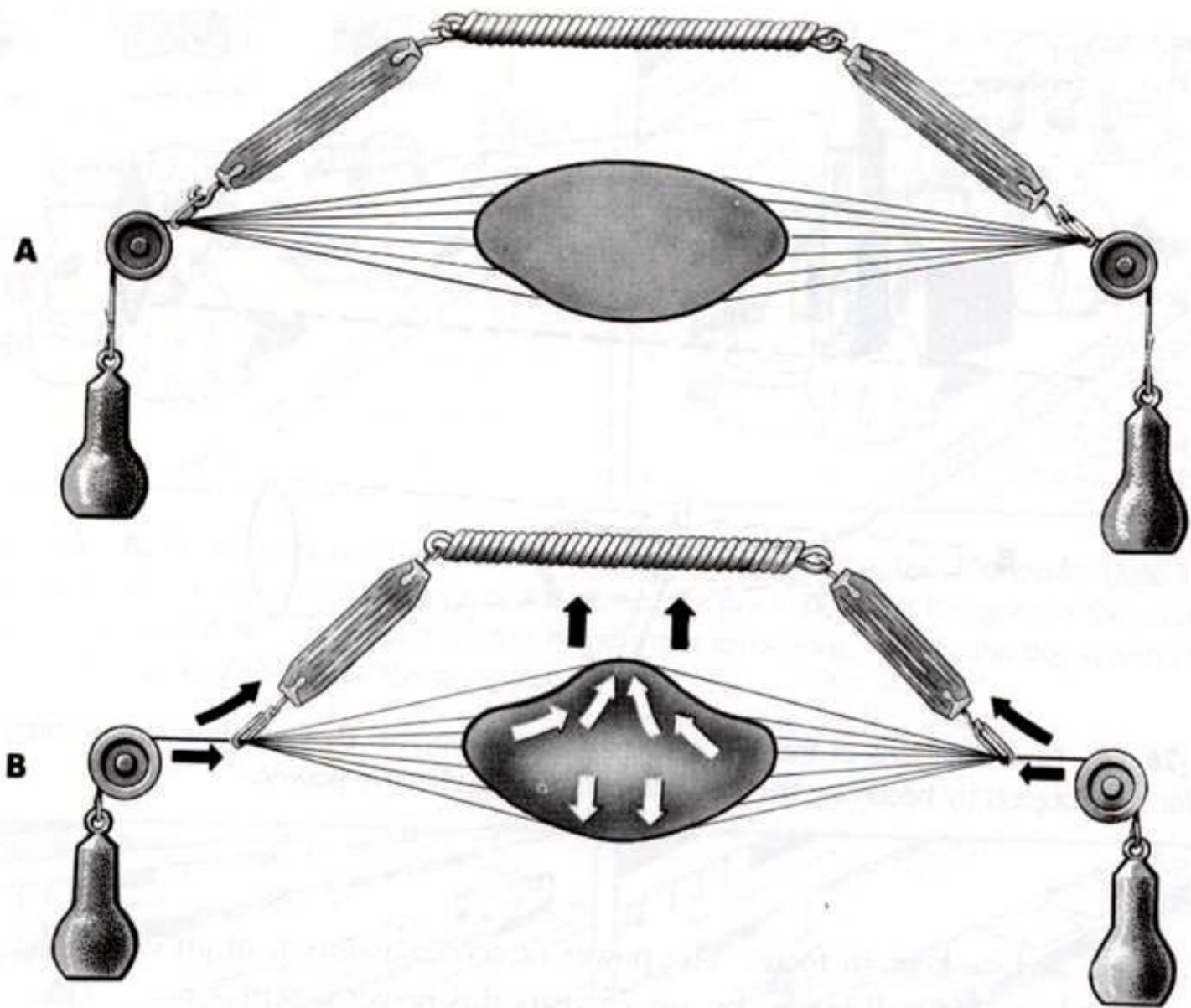


Fig. 1.29. (A)

The Intraocular Pressure

- ❑ The pressure within the eye is maintained at a steady level by continuous formation & drainage of aqueous.
- ❑ Aqueous is secreted by the ciliary epithelium → posterior chamber → anterior chamber (through the pupil) → drained through the anterior chamber angle.
- ❑ The intraocular pressure, (IOP), is normally 10 – 21 mmHg; increased IOP ocular hypertension .
- ❑ High IOP almost always due to an obstruction of aqueous outflow.

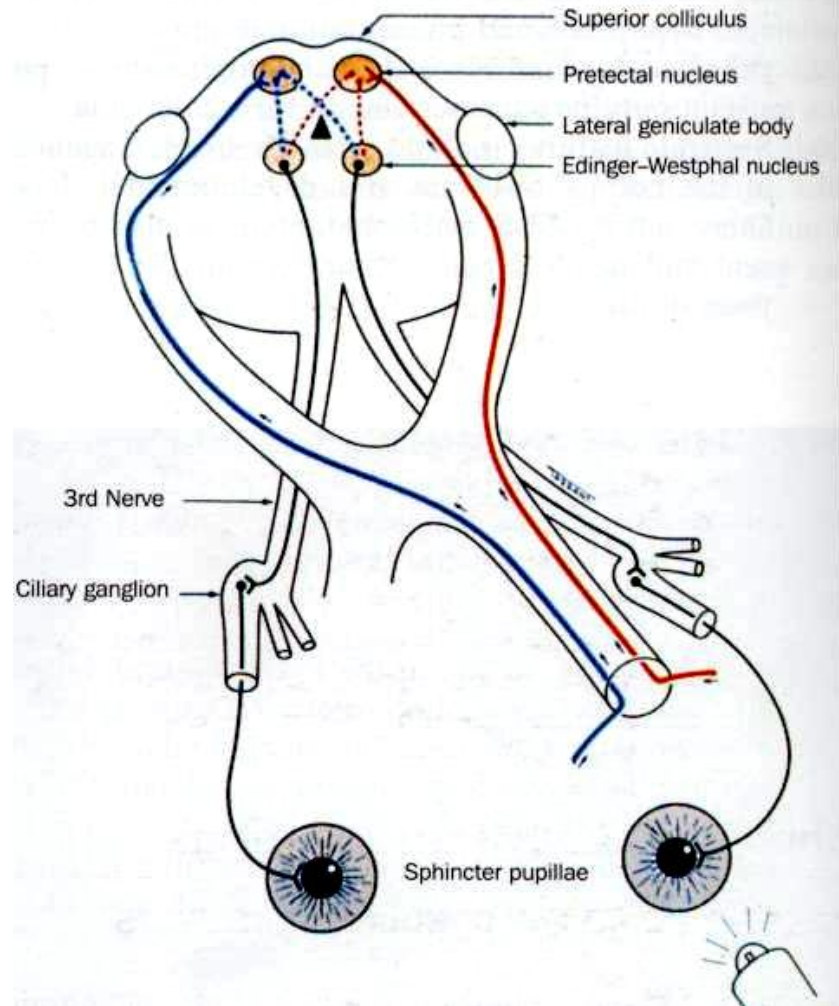
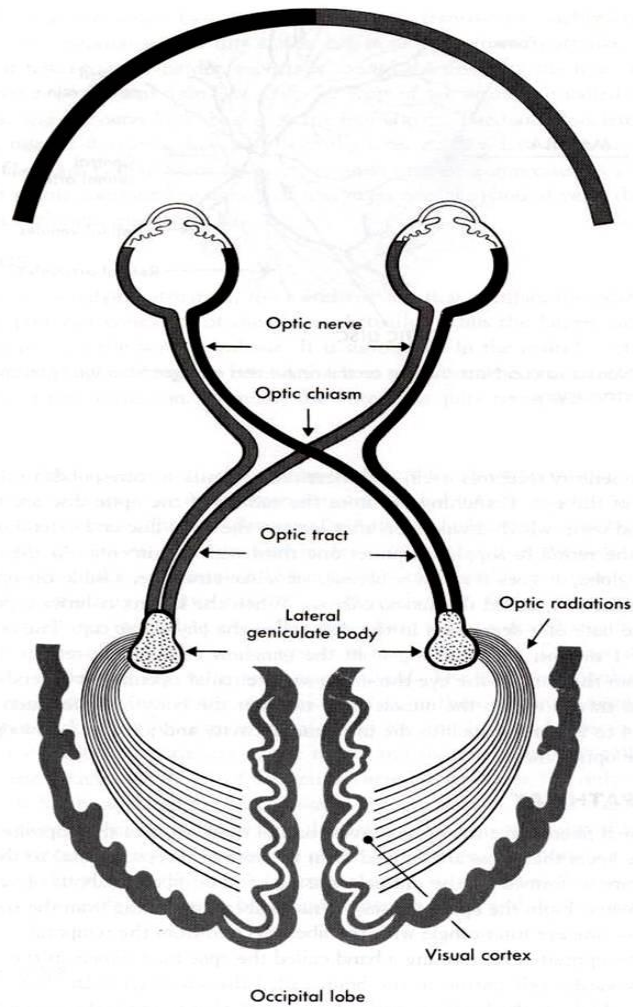
VISION

✓ *The retina:*

- The central retina contains yellow pigment, Xanthophyll, the so called macula lutea (yellow spot).
- It is divided into retinal pigment epithelium & neurosensory retina.
- Photoreceptors contains visual pigment which consists of a large protein (opsin) attached to retinal (vitamin A aldehyde).

VISION (cont.)

- + Light splits the opsin from the retinal with initiation of a graded electrical potential → Transmitted through the visual pathway to be processed in the visual cortex (occipital lobe) → vision sense.
- + Visual Pathway: Three neurons
 1. Bipolar cell, lies within the retina.
 2. Ganglion cell, synapse in lateral geniculate body.
 3. Third neuron terminates in visual cortex.



Summery

The socket that contains the eye called -----

ORBIT

the orbit is formed by Bones.

Seven

The optic nerve pass through

Optic foramen or canal

Summery

The eye has Extraocular muscles

Six

..... Recti and obliques.

4

2

All extraocular muscles are supplied byexcept

Oculomotor nerve except SO₄ and LR6

When we test a patient 4th nerve we should ask him to look

Down and in

Summery

The space that lies behind the cornea & in front of the iris called.....

Anterior chamber.

The fluid that fills the chambers of the eye called.....

Aqueous humors

The cavity that lies behind the lens called.....

Vitreous cavity

Summery

The main refractive structure in the eye is

The cornea

The second refractive structure in the that can change its power

The lens

The structure that determines the color of the eye is

The iris

when the lens get opacified this condition called

cataract

Summery

The central part of the retina called

The macula

The central part of the macula called

Fovea

The central part of the fovea called

foveola

Summery

The optic nerve lies in part of the retina


Nasal

The percentage of the decussating fibers is

53%

Thank you





Palpebral
fissure

Supraorbital
notch

Eyelids

Dorsum nasi

Zygomatic bone

Ala nasi

Infraorbital
foramen

Lips

Mental
protuberance

Mental foramen