

# Orthopedic Emergencies 2

SULTAN ALDOSARI, MBBS, FRCSC

Ass. Professor

Course 452

College of Medicine

KSU

- Open Fractures
- Fractures with neurovascular Injuries
- Unstable Polytrauma Patients With A Pelvic Fracture

# Objectives

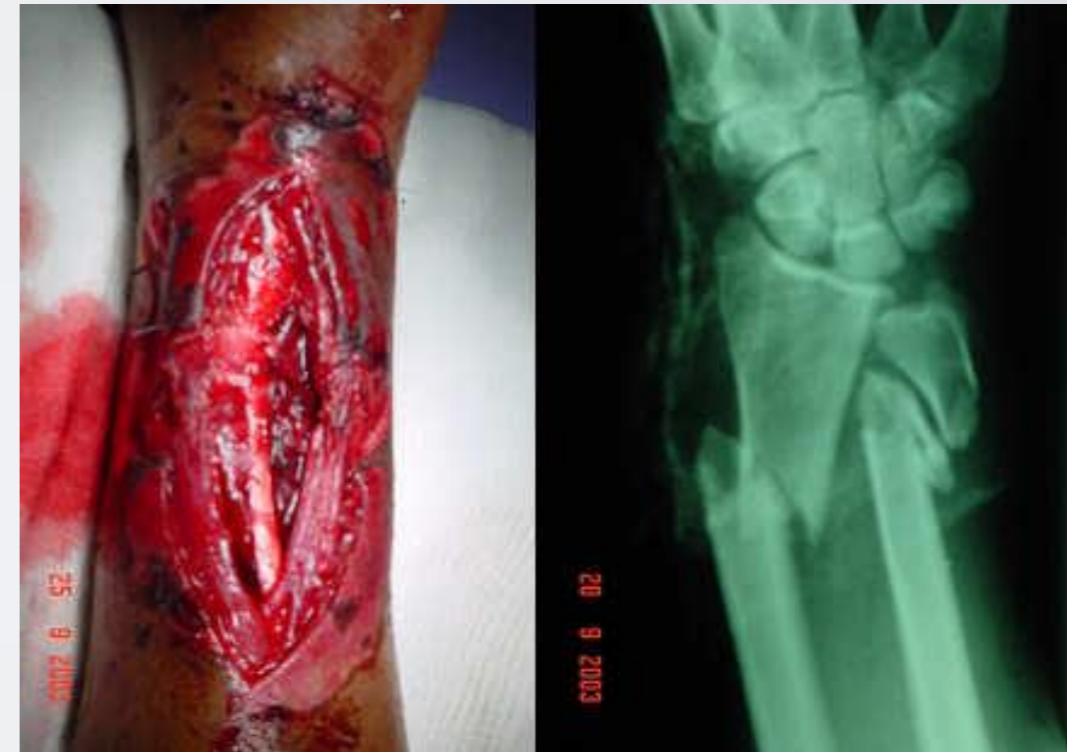- To be able to **identify and diagnose** patients with an open fracture, a fracture with nerve or vascular injury and poly-trauma patients with pelvic injuries
- To be **knowledgeable** about the **pathophysiology and morbidity** associated with these injuries
- To be able to **apply the principles of management** of these injuries at the site of accident and in the emergency room

# Open Fractures

- Definition:

- ☰ A fracture that at some point communicated with the environment

- ☰ An open joint is managed similarly

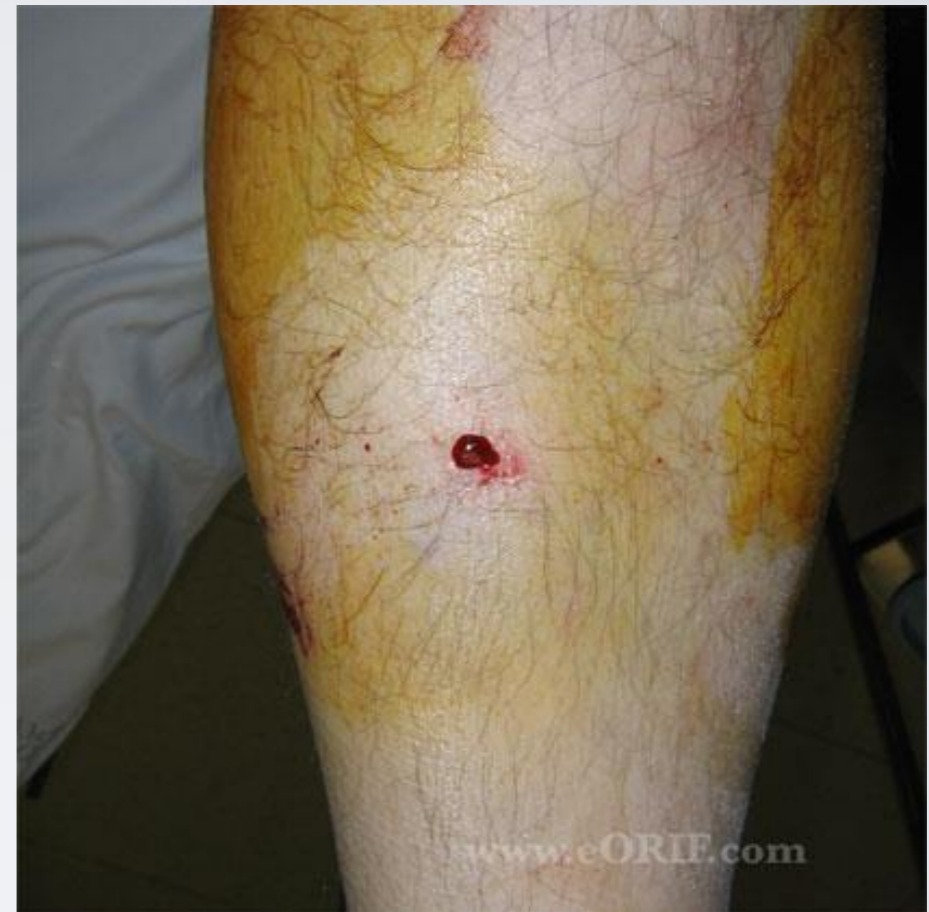

# Open fracture

- Usually requires higher injury

📄 Not always!

- Sometimes can be missed



# Open fractures

- Commonly occurs in bones with minimal soft tissue coverage
- Usually higher energy is required in deep bones

# Open fractures

- Pathology:
  - Traumatic energy to the soft tissue and bone
    - Inoculation of organisms
    - Necrotic tissue
    - Injury to vessels and microvasculature
    - Raised compartment pressure
    - Ischemia and lack of immune response
    - INFECTION

# OPEN fractures

- Infection in the presence of a fracture
  - Difficult to eradicate
  - Prolonged antibiotics
  - Multiple surgeries
  - Significant morbidity
  - Significant costs



# Open fractures

- An open fracture is usually a “red flag” warning of significant trauma
  - Detailed assessment of the patient is necessary
- An open fracture is associated with significant morbidity
  - Must act quickly

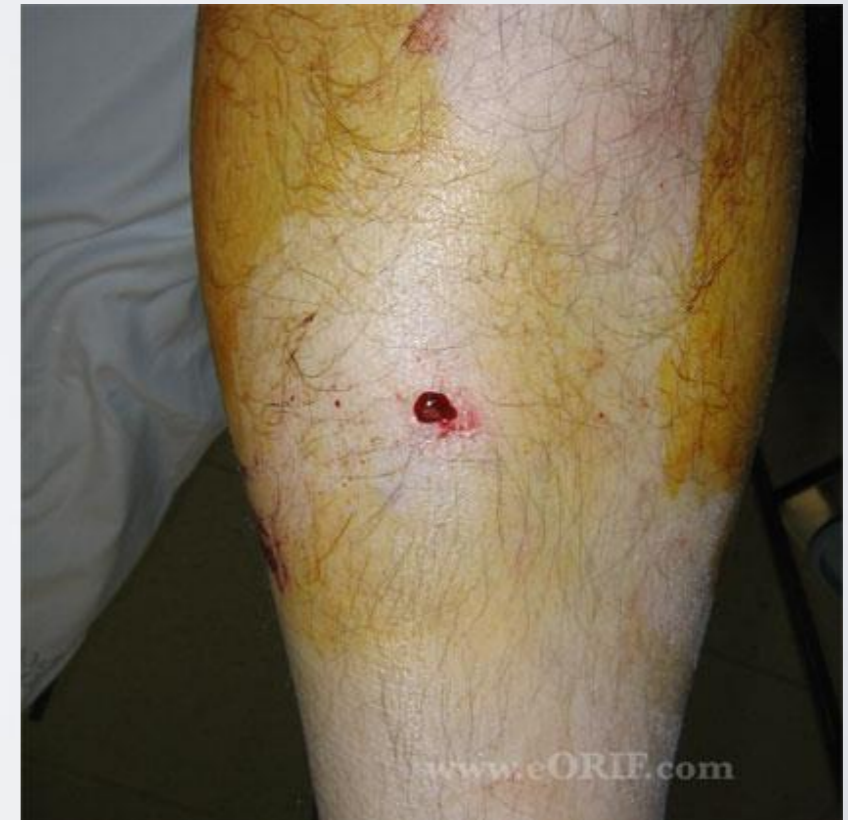# Open fractures

- A delay in management is proven to increase the likelihood of complications
  - Give urgent priority while triaging, provide initial management and consult urgently

# •Open fractures

## Diagnosis

- Some times obvious!
- Other times, settle,,, be observant
- A wound close to a fracture is an open fracture until proven otherwise!
- Whenever a fracture is diagnosed, go back and check the skin



# •Open fractures

## Diagnosis

- A small wound continuously oozing blood, especially, if you see fat droplets within the blood, is an open fracture!
- Not always close to the fracture
- Don't probe!!
- If in doubt, use good light, if there is a break in the dermis or fat is seen, call it an open fracture
- Better to overcall than miss it !

# •Open fractures

## Algorithm

- Assess and stabilize the patient, ATLS principles
- Assess the condition of the soft tissue and bone to help grade the open fracture
- Manage the wound locally
- Stabilize the fracture
- IV antibiotics
- Tetanus status

# •Open fractures

## Algorithm

- Assess and stabilize the patient, ATLS principles
- Assess the condition of the soft tissue and bone to help grade the open fracture
- Manage the wound locally
- Stabilize the fracture
- IV antibiotics
- Tetanus status

# • Open fractures

## Assessment

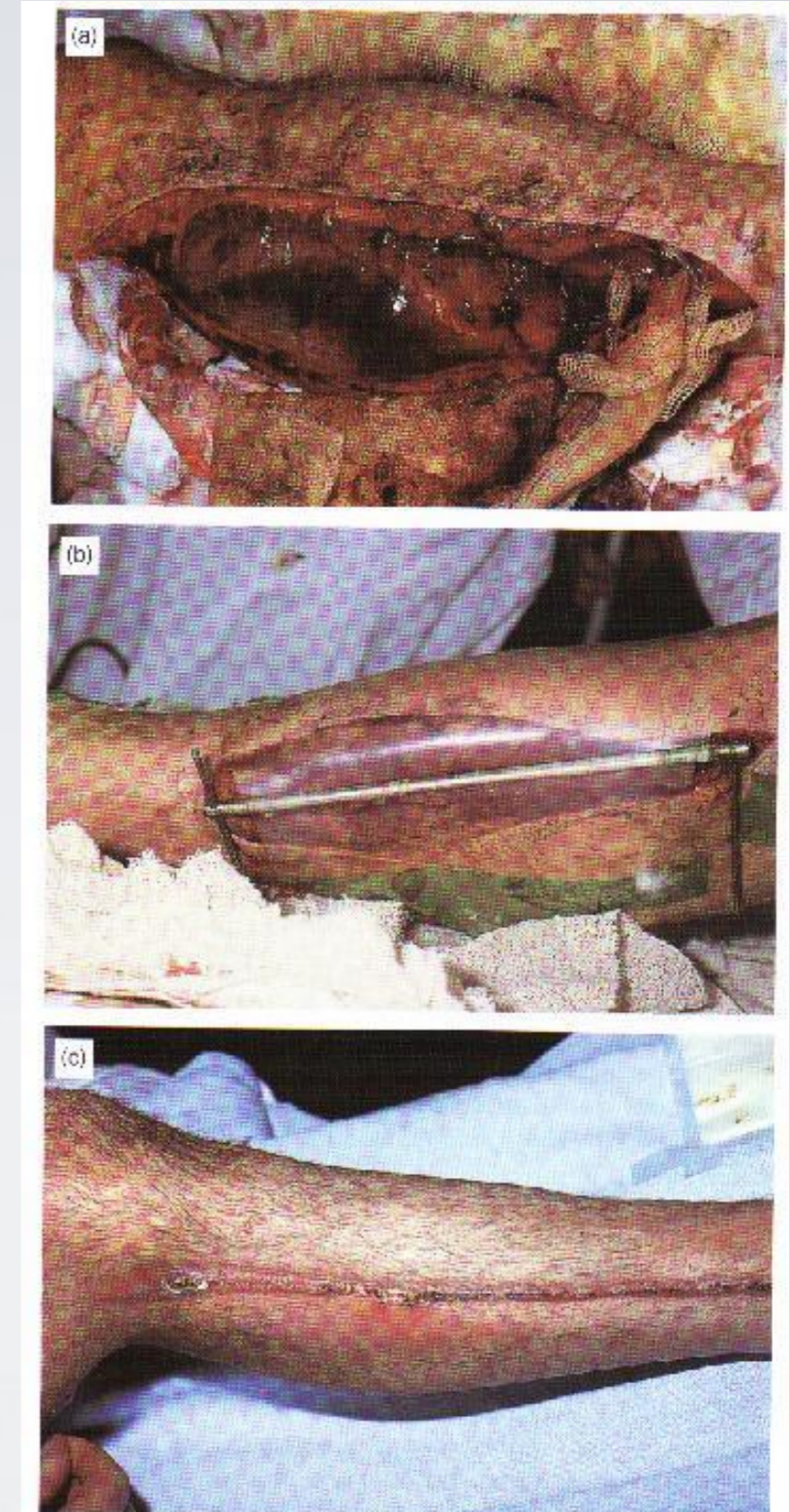
- If polytrauma, apply ATLS principles
- If isolated injury:
  - Mechanism and circumstances of injury
  - Time since injury
  - PMH/PSH/Allergy/Drugs/Smoking
  - Tetanus vaccination status



# • Open fractures

## Assessment

- Examine the affected region for:
  - Soft tissue:
    - Degree of contamination
    - Necrotic and devitalized tissue
    - Size of wound
    - Coverage loss
    - Compartment syndrome



**Fig. 23.40** Fasciotomy closure device being used to close a large fasciotomy over a period of 1 week: (a) immediately postfasciotomy; (b) 4 days later; and (c) after healing.



# • Open fractures

## Assessment

- Bone:
  - Comminution
  - Stripping of bone periosteum
  - Away from injury to joint above and below
  - X-rays to joint above and below

# • Open fractures

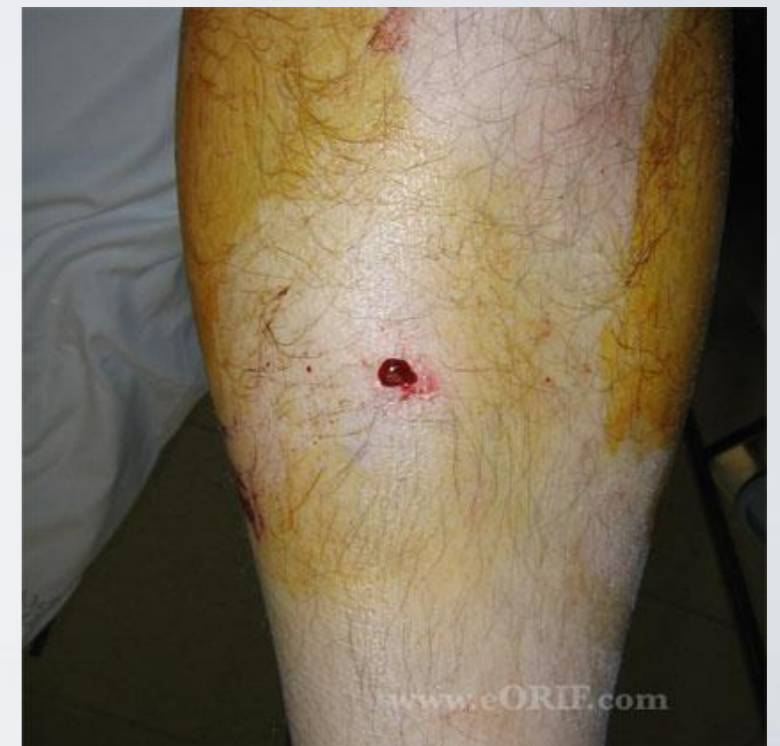## Assessment

- Neurovascular status distally:
  - On arrival and post reduction and splinting later

# • Open fractures

## Assessment

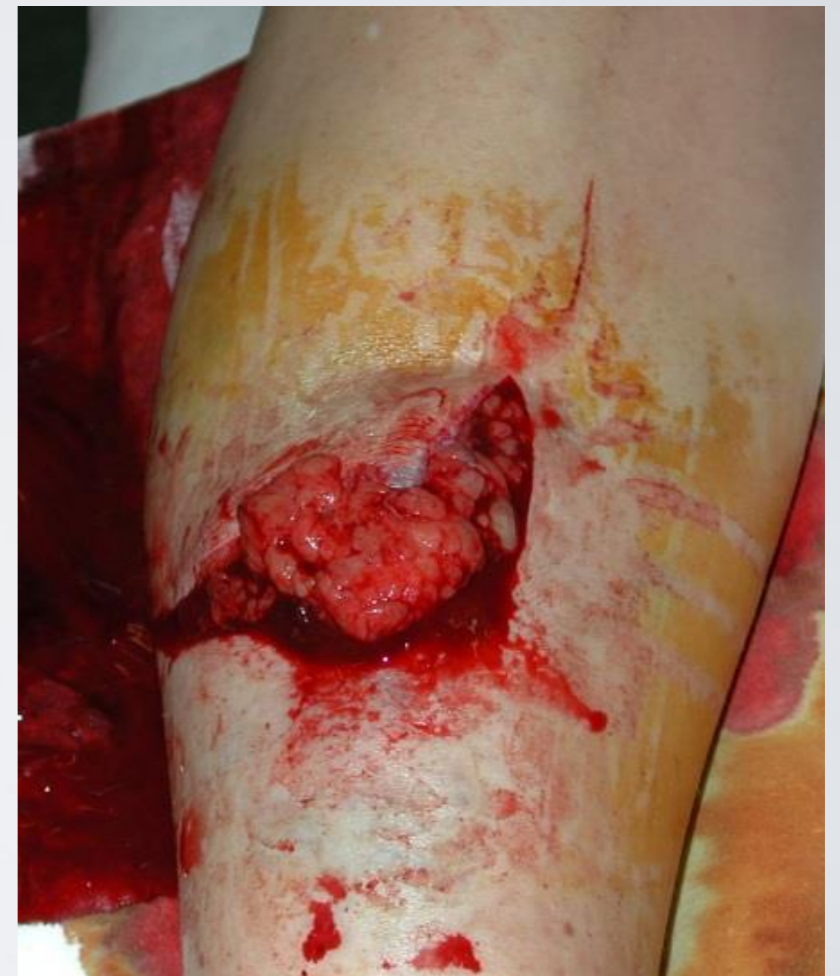- Open fracture grade:
  - Grade 1:
    - Less or equal to 1 cm, clean, non segmental nor severely comminuted fracture, less than 6 hours since injury



# • Open fractures

## Assessment

- Grade 2 open fracture:
  - >1cm wound, not extensive soft tissue injury or contamination, non segmental nor severely comminuted fracture, no bone stripping and with adequate soft tissue coverage



# • Open fractures

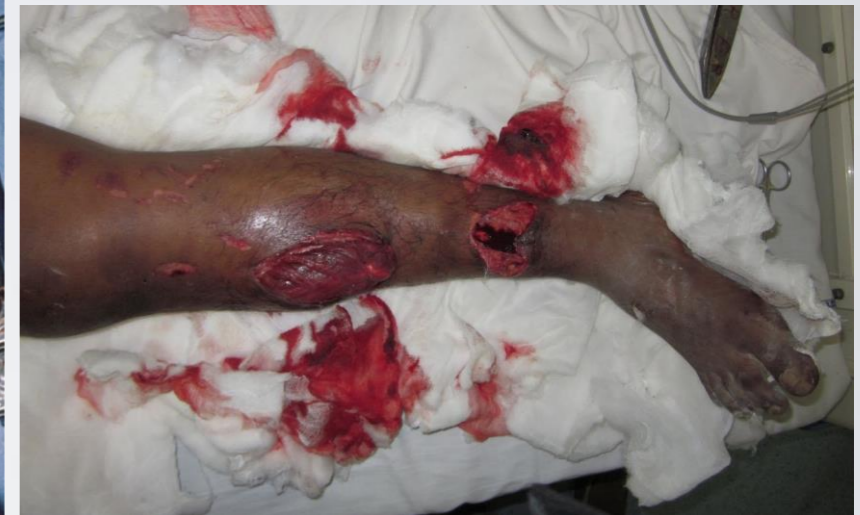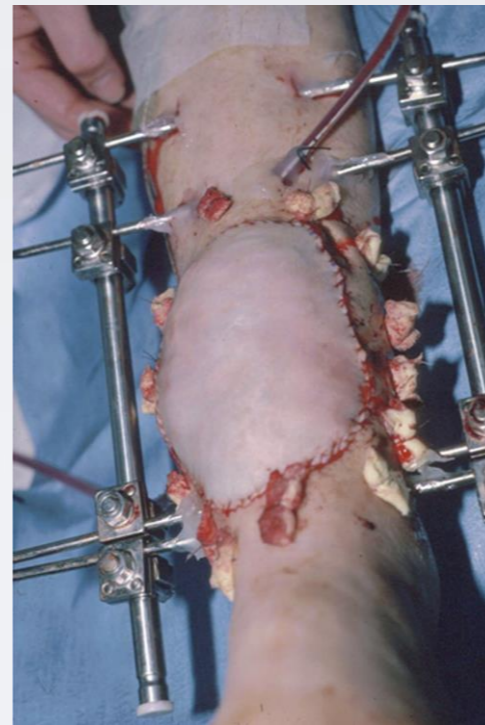
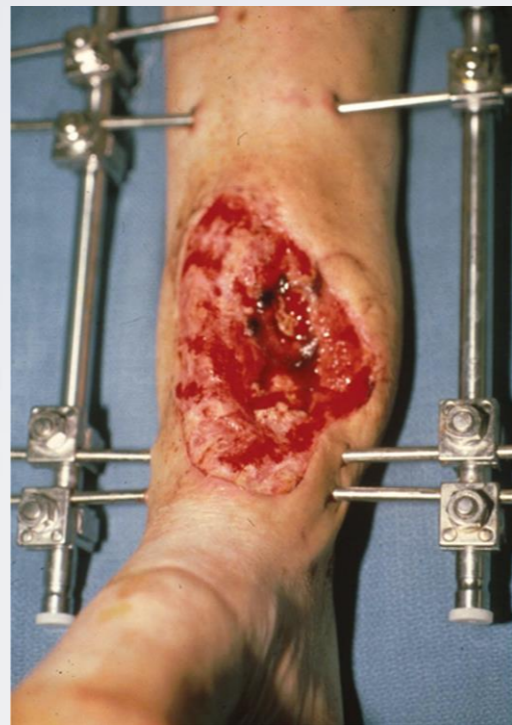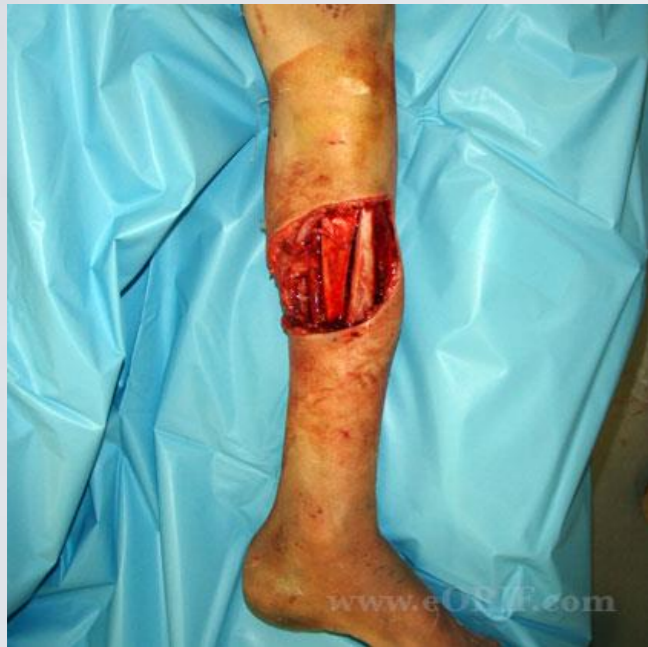## Assessment

- Grade 3 open fracture:
  - 3A: Any size with extensive soft tissue contamination or injury but not requiring soft tissue coverage procedure, or with a segmental or severely comminuted fracture, or late presentation more than 6 hours
  - 3B: Any open fracture that requires soft tissue coverage procedure
  - 3C: Any open fracture that requires vascular repair



# • Open fractures

## Assessment

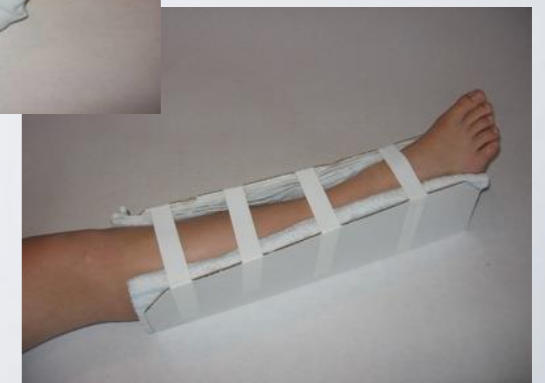
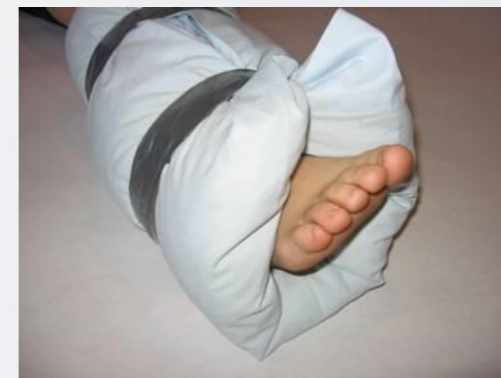
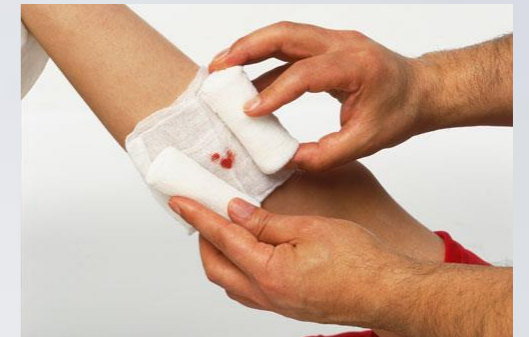
# • Open fractures

## Management

- Local:

- Take a picture!
- If dirty, irrigate with normal saline to remove gross contamination
- If bone sticking out try to reduce gently then immobilize and re-check neurovascular status
- Cover with sterile wet gauze
- If bleeding apply direct pressure on wound
- No culture swabs in ER



# • Open fractures

## Management

- Antibiotics:

- First generation Cephalosporin for gram positives (Ex: Cefazolin) in all open fractures
- Aminoglycoside to cover gram negatives ( Ex: Gentamicin) sometimes not required in grade 1 but in general it is safer to give in all grades
- Add penicillin or ampicillin or metronidazole for clostridium in grade 3 open fractures and all farm and soaked wounds



# • Open fractures

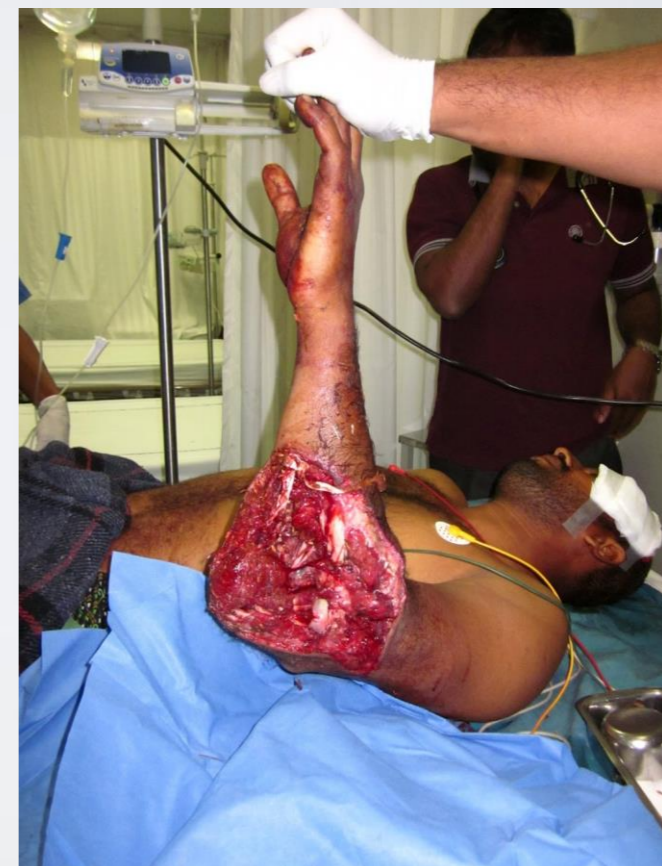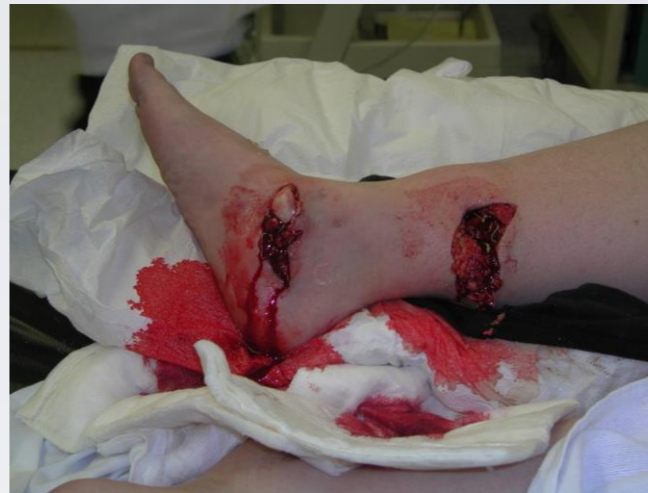## Management

- Tetanus prevention:
- Wound types:

### 1. Clean wounds:

- <6 hours from injury
- Not a farm injury
- No significant devitalized tissue
- Non immersed wound
- Non contaminated wound

### 2. Other wounds



# • Open fractures

## Management

### • Tetanus prevention:

Clean wounds		Other wounds					
Completed vaccination		Not completed or unknown		Completed vaccination		Not completed or unknown	
Booster < 10 years	Booster >10 years	Td 0.5ml IM		Booster < 5years	Booster > 5 years	TIG 250U And Td 0.5ml IM	
nothing	Td 0.5 ml IM			nothing	Td 0.5ml IM		

# • Open fractures

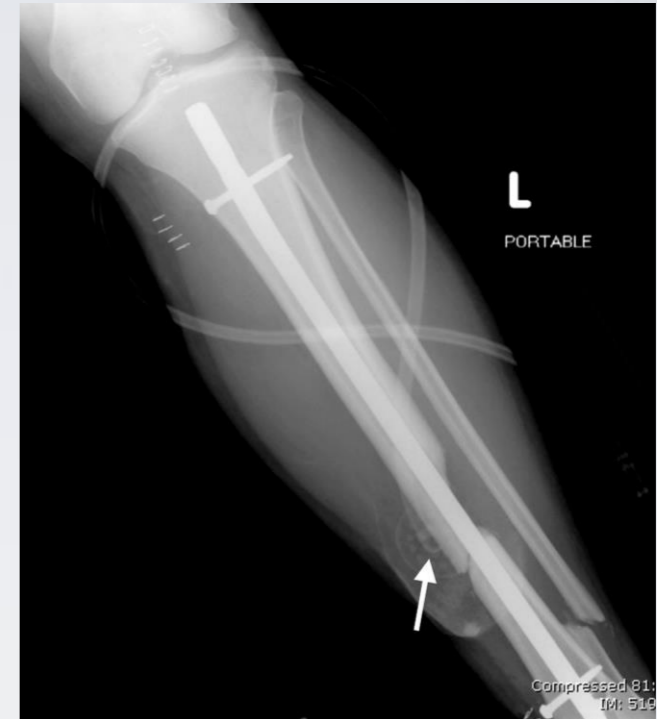## Management

- As soon as patient is stable and ready, alert the OR, and consent for surgery
- Plan: Irrigation, debridement and fracture stabilization
- The sooner the less risk of further morbidity

# • Open fractures

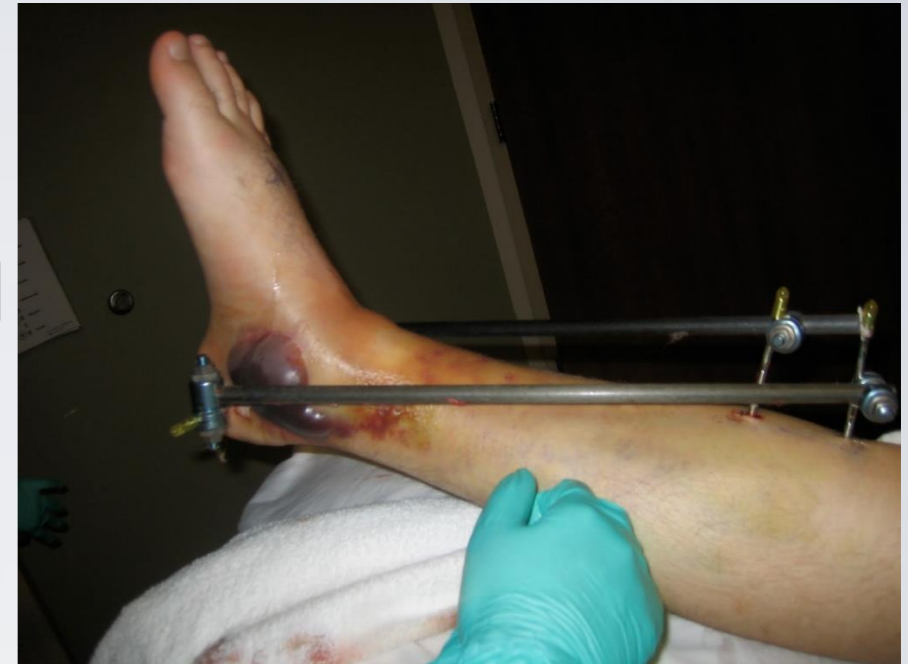## Management

- In the OR:
  - Extend wound if necessary
  - Thorough irrigation
  - Debride all necrotic tissue
  - Remove bone fragments without soft tissue attachment except articular fragments
  - Usually requires second look or more every 48-72 hours
  - Generally do not close open wounds on first look



# • Open fractures Management

- Fracture management:
  - Generally avoid internal fixation (plate and screw)
  - Generally external fixator is used.
  - Femur and tibia fractures can usually be treated immediately with IM nail except severe injuries and contamination
  - Observe for compartment syndrome post-operatively



# • Open fractures

## Results

- If all principles applied:
  - 2% complication rate in grade 1
  - 10% complication rate in grade 2
  - Up to 50% complication rate in grade 3

# Fractures with nerve or vascular injuries

- Don't miss it !!!!
- Always perform an accurate assessment at presentation, post manipulation and reduction, post surgical fixation, serially until condition stabilizes
- Serial examination helpful in deciding line of treatment
- Serial examination helps avoid confusion



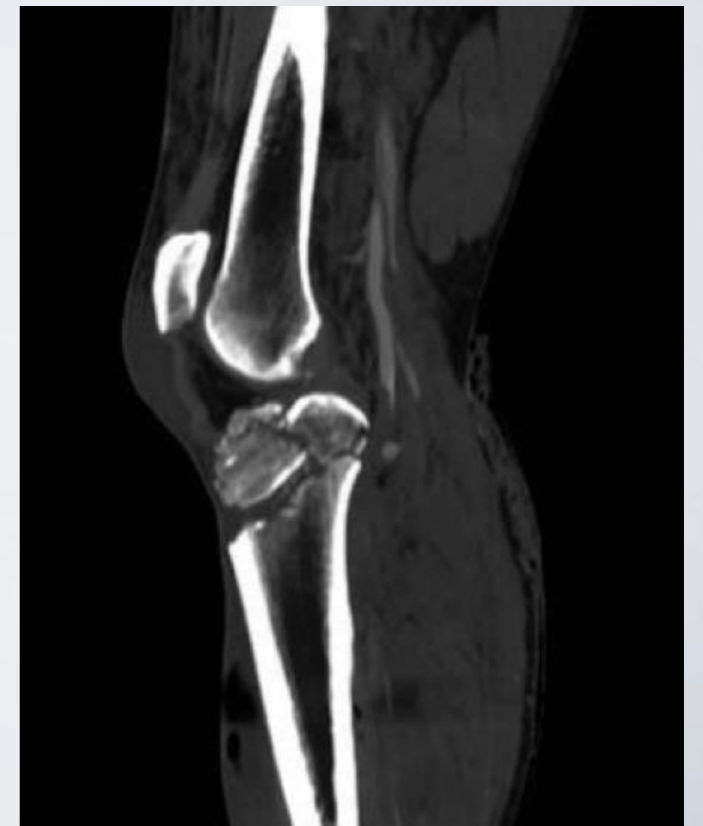# Fractures with nerve or vascular injuries

- High correlation between vascular injury and nerve injury
  - Proximity



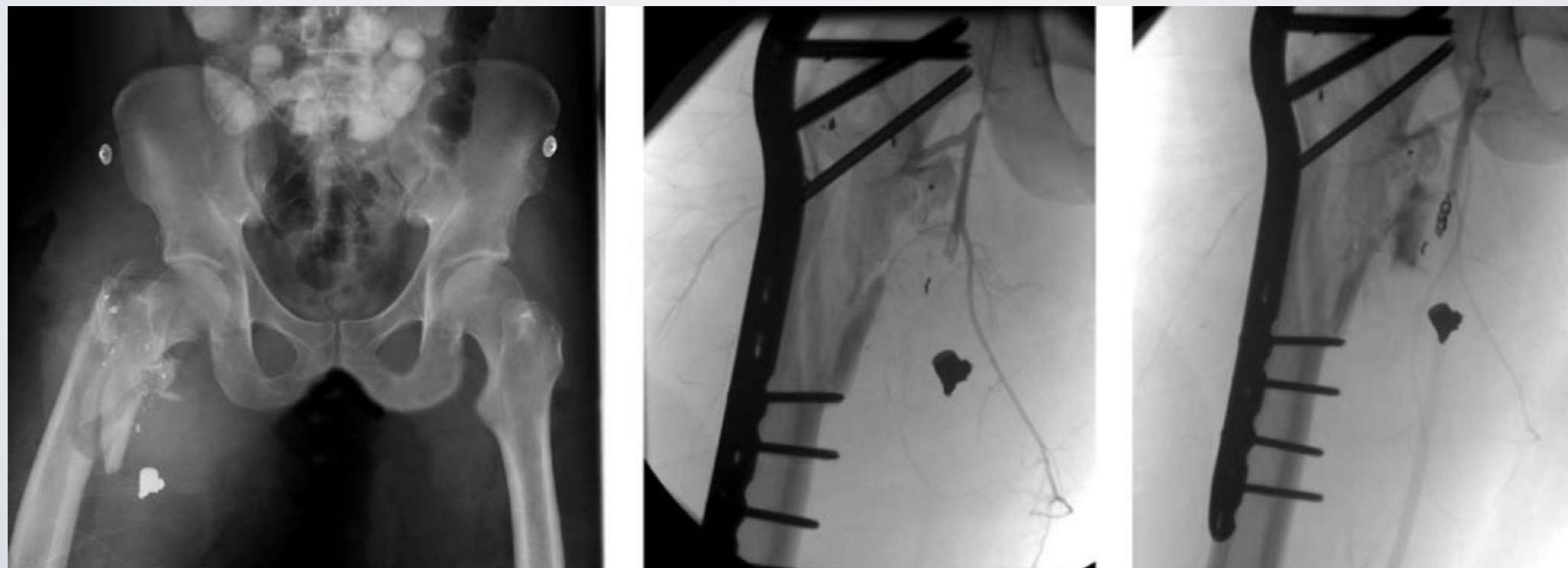
# Fractures with nerve or vascular injuries

- Mechanisms:
  - Penetrating trauma
  - High energy blunt trauma
  - Significant fracture displacement
  - Keep in mind tissue recoil at presentation



# Vascular injuries

- Direct laceration
- Traction and shearing



# Vascular injuries

## Assessment

- Always check:
  - Pulse, Color, Capillary refill, Temperature, compartment pressure
- Keep high index of suspicion:
  - High energy trauma
  - Associated nerve injuries
  - Fractures/ Dislocations around the knee

# Vascular injuries

## Assessment

**Table 1**

**Hard and Soft Signs of Vascular Injury Associated With Extremity Trauma**

---

**Hard signs**

Pulselessness

Pallor

Paresthesia

Pain

Paralysis

Rapidly expanding hematoma

Massive bleeding

Palpable or audible bruit

**Soft signs**

History of bleeding in transit

Proximity-related injury

Neurologic finding from a nerve adjacent to a named artery

Hematoma over a named artery

# Vascular injuries

## Assessment

- Hard signs > realignment of limb > if persistent >
  - vascular intervention
- Hard signs > realignment of limb > improved >
  - Close observation
  - Realignment can result in unkincking of vessels, lowering compartment pressure, relaxation of arterial spasm

# Vascular injuries

## Assessment

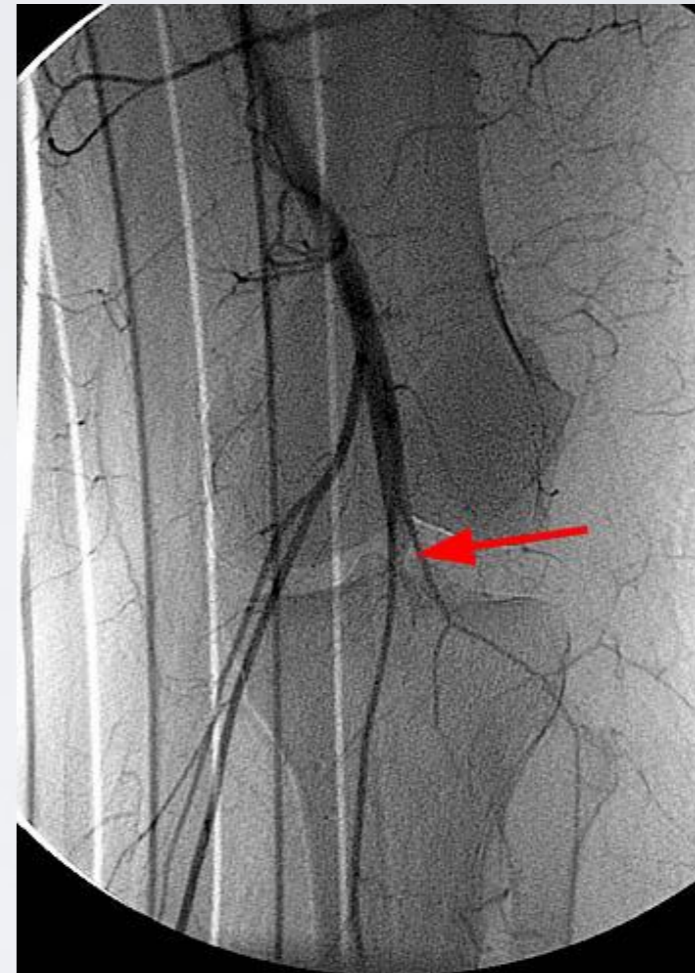- ABI
  - $< 0.9$  associated with vascular pathology
  - Rarely can give false negative result (Ex. Profunda femoris)
  - Always used in high risk fractures (knee)
  - If positive  $>$  Urgent vascular intervention



# Vascular injuries

## Assessment

- Angiography, CT angiography
- Gold standard
- Not without risks
- Vascular surgeon to arrange with interventional radiologist



# Vascular injuries

## Management

- Once vascular injury is confirmed:
  - Coordination between:
    - Vascular surgeon
    - Orthopedic surgeon
- To emergently re-establish perfusion and protect repair with skeletal stabilization

# Vascular injuries

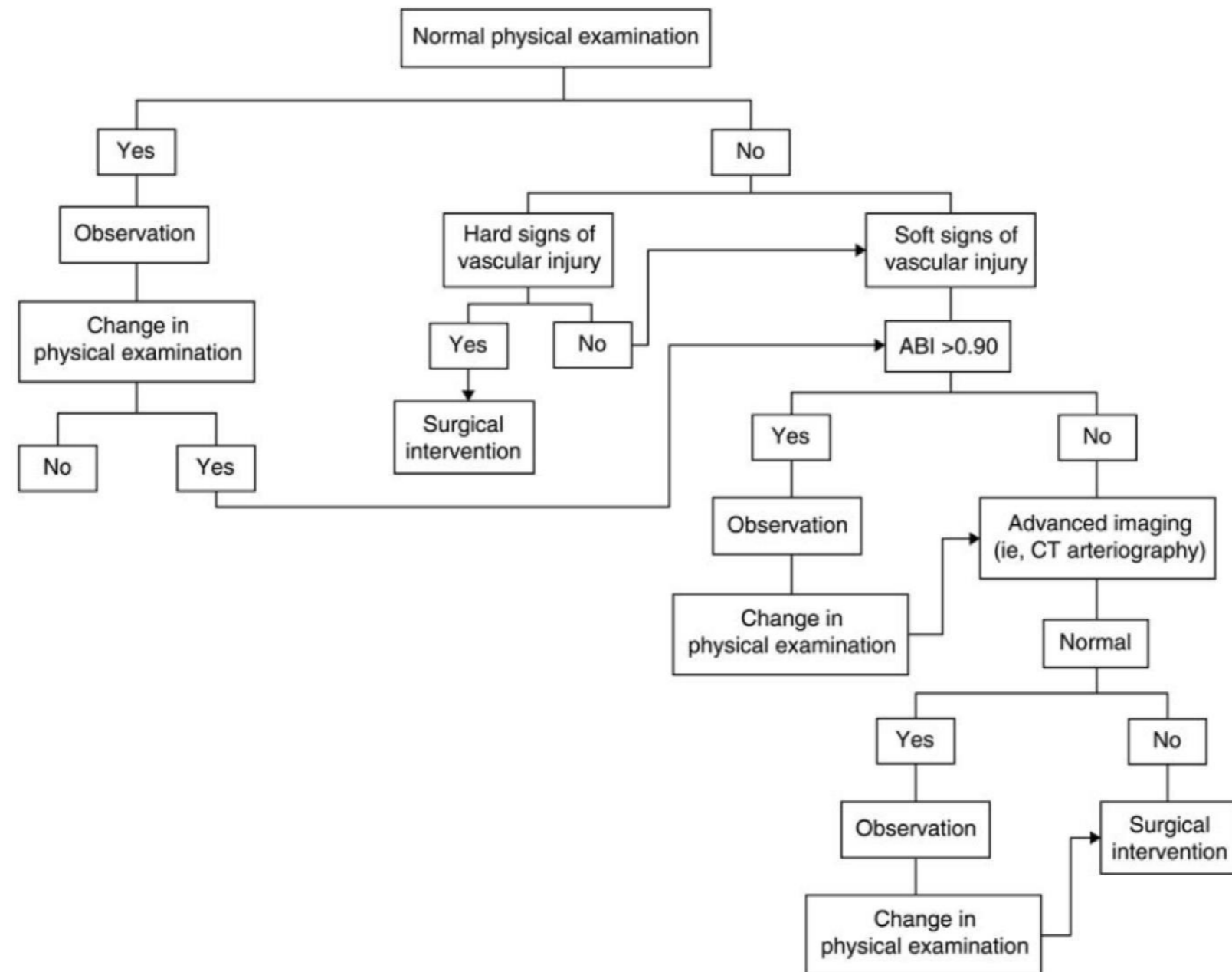
## Management

- Warm ischemia time dictates treatment
- Most times, a quick external fixator is applied, followed by vascular repair
- Avoid prolonging warm ischemia.

# Vascular injuries

## Management

Figure 3



# Vascular injuries

## Management

- Prolonged warm ischemia >6 hours
  - Prophylactic fasciotomy
- Grade 3C open fractures have the worst outcome
- Amputation may be necessary in severe cases

# Nerve injuries

- Cause of medico-legal concern
- Accurate assessment and documentation at presentation, post reduction, post surgery is essential
- Remember to examine for motor and sensation prior to sedation

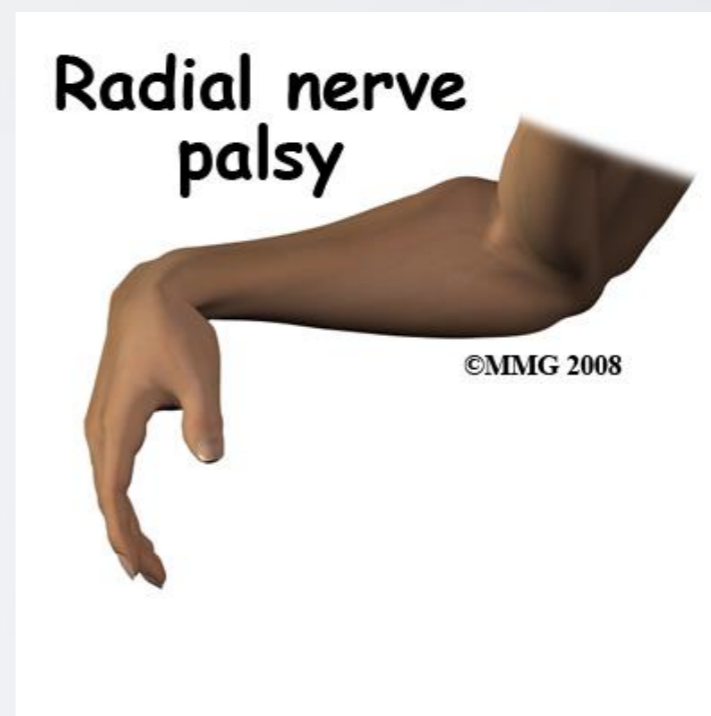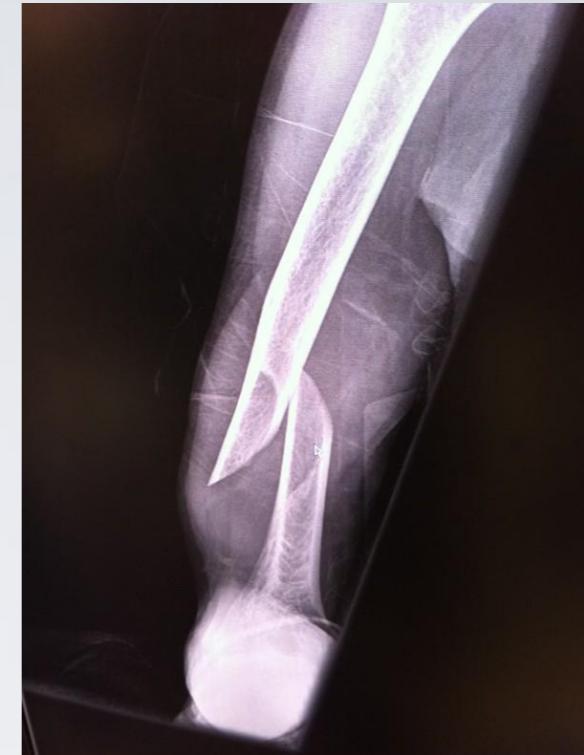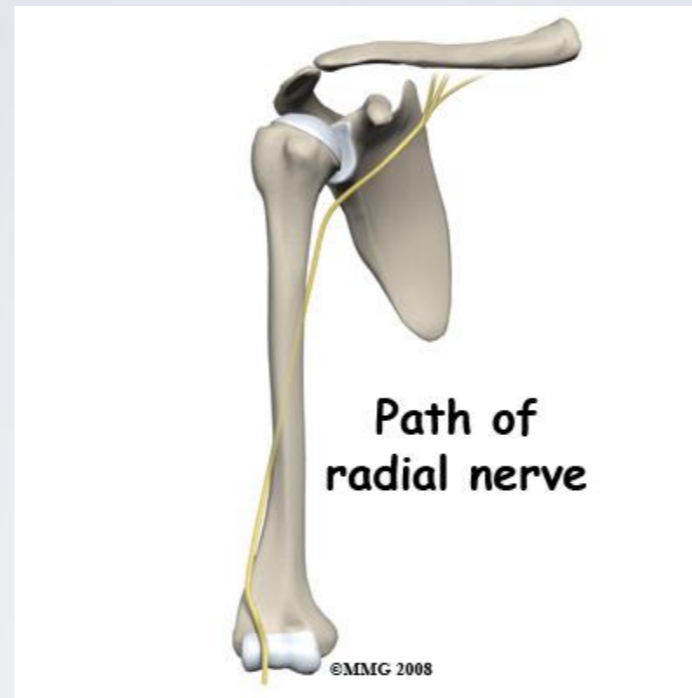
# Nerve injuries

- Closed fractures not requiring surgery with nerve injuries:
  - Usually good outcome >80%
  - Usually managed conservatively in the early stages
  - Recovery may take more than 6 months



# Nerve injuries

- Intact nerve before reduction, absent after reduction:
- Controversial management
- Usually observe

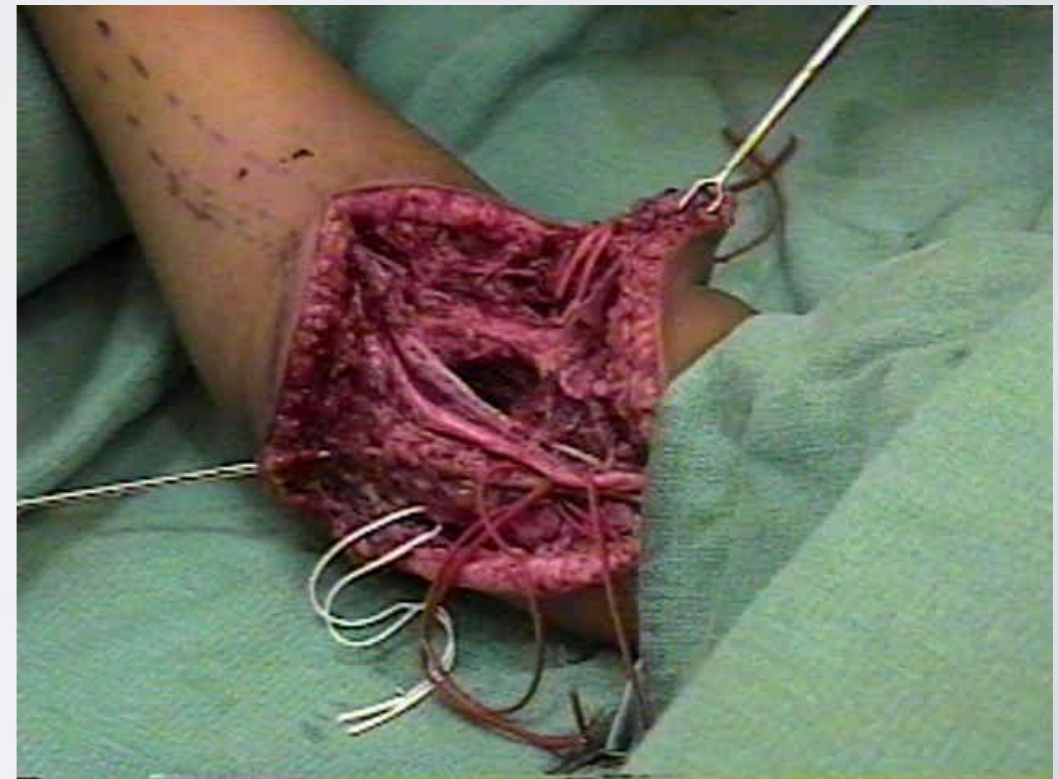


# Nerve injuries

- Fracture requiring surgery with nerve injury:
  - Limited exploration

# Nerve injuries

- Open fracture with nerve injury:
  - Explore, tag nerve ends for later repair



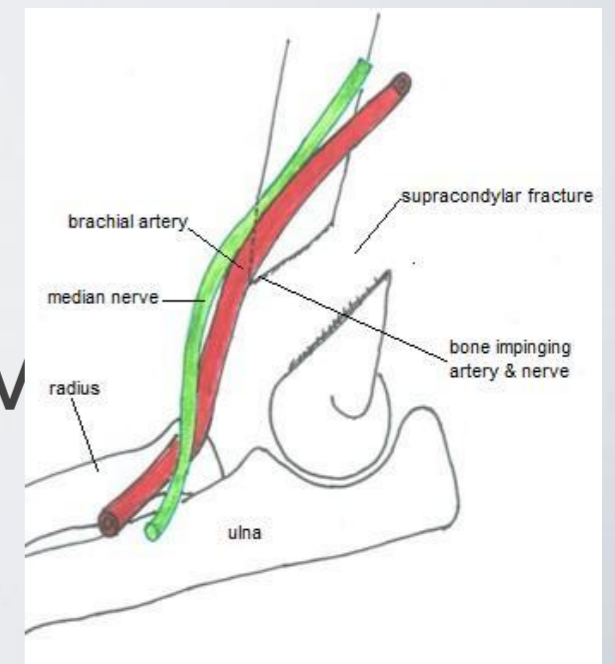
# Nerve injuries

- Follow up:
  - Clinically
  - Electrodiagnostic assessment start at 6 weeks then serially every 6 weeks
  - If no improvement:
    - Nerve exploration: neurolysis / repair / grafting
    - Tendon transfers to preserve function

# Nerve injuries

## Common sites

- Shoulder fracture / dislocation > Axillary nerve
- Distal humeral shaft fracture > Radial nerve
- Elbow fracture / dislocation > Median>>radial>>ulnar
- Hip fracture / dislocation > Sciatic nerve
- Knee fracture / dislocation > Peroneal nerve

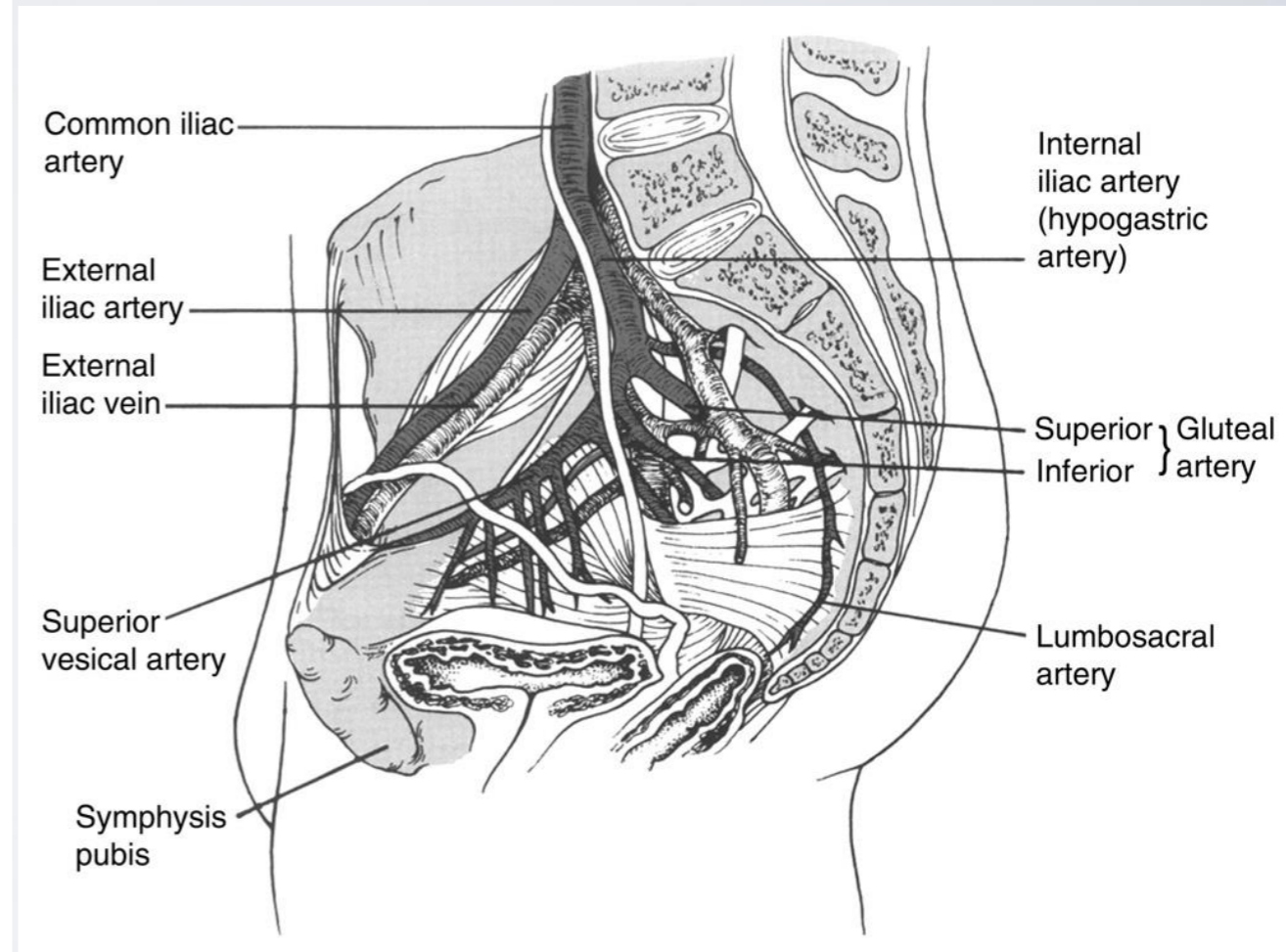
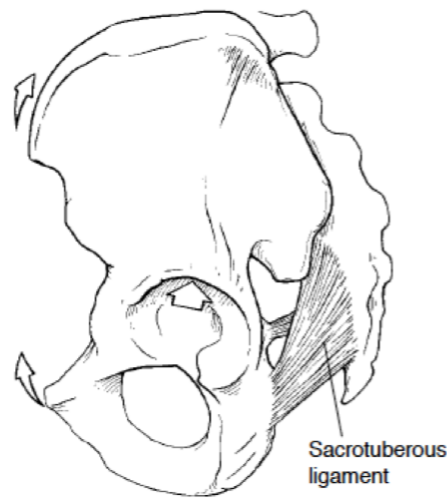
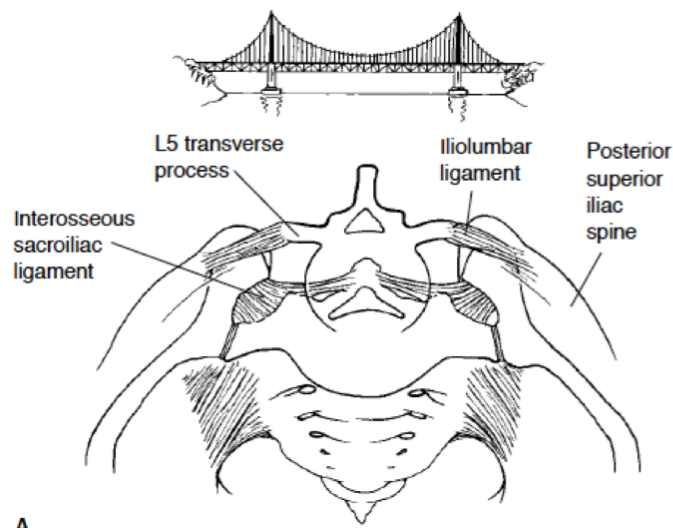
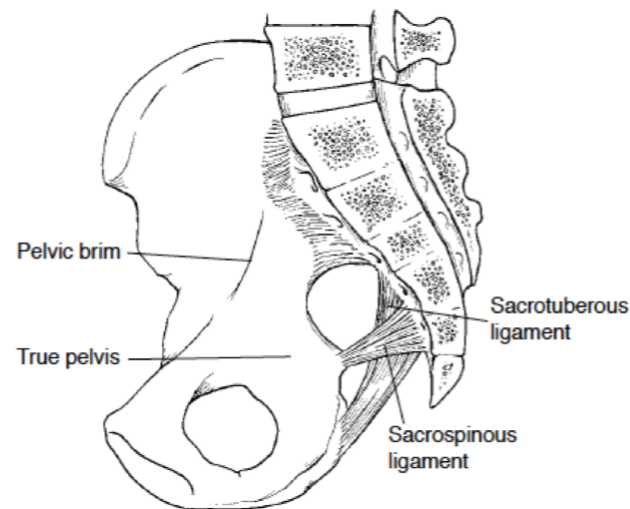
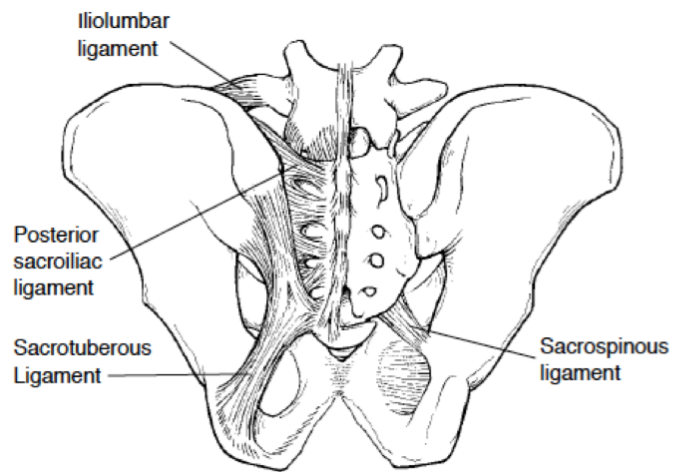




# Pelvic trauma

## In the poly trauma patient

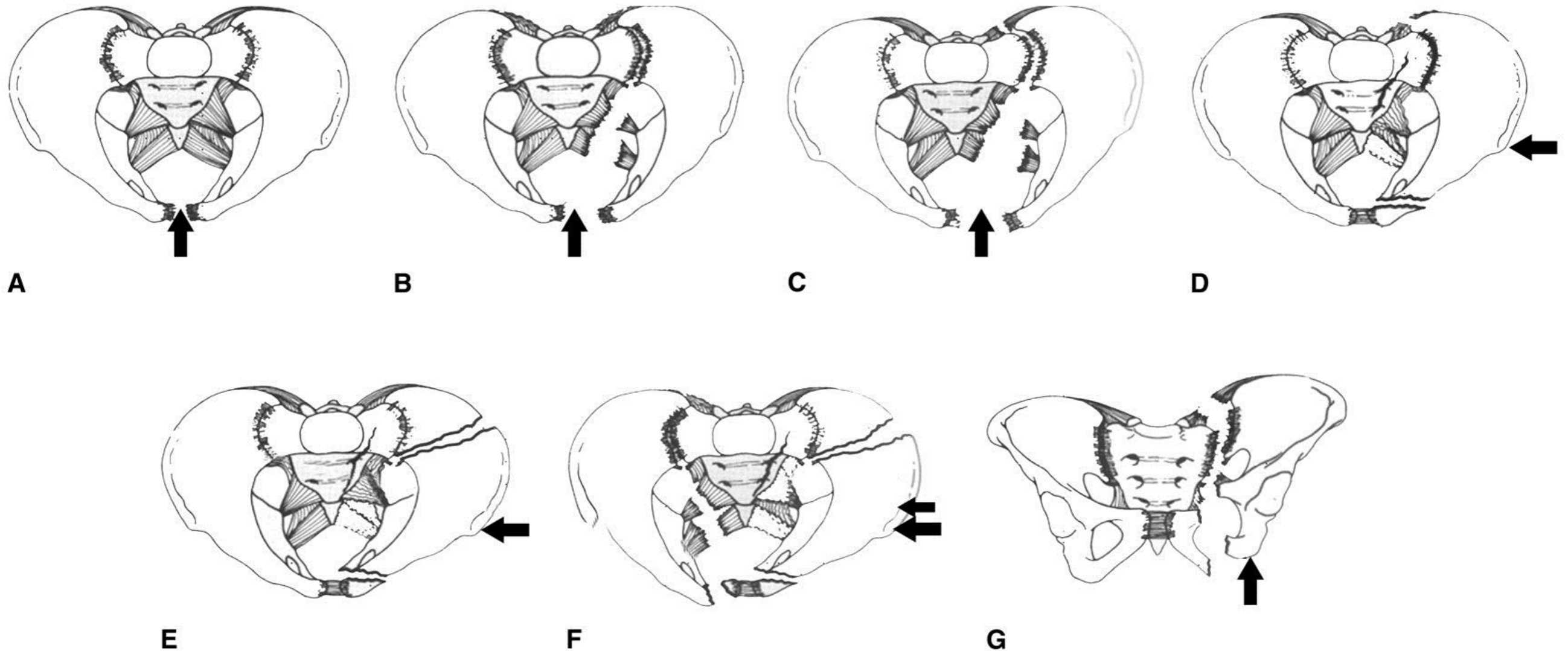
- PELVIS ANATOMY



# Pelvic trauma

In the poly trauma patient

- Pathology

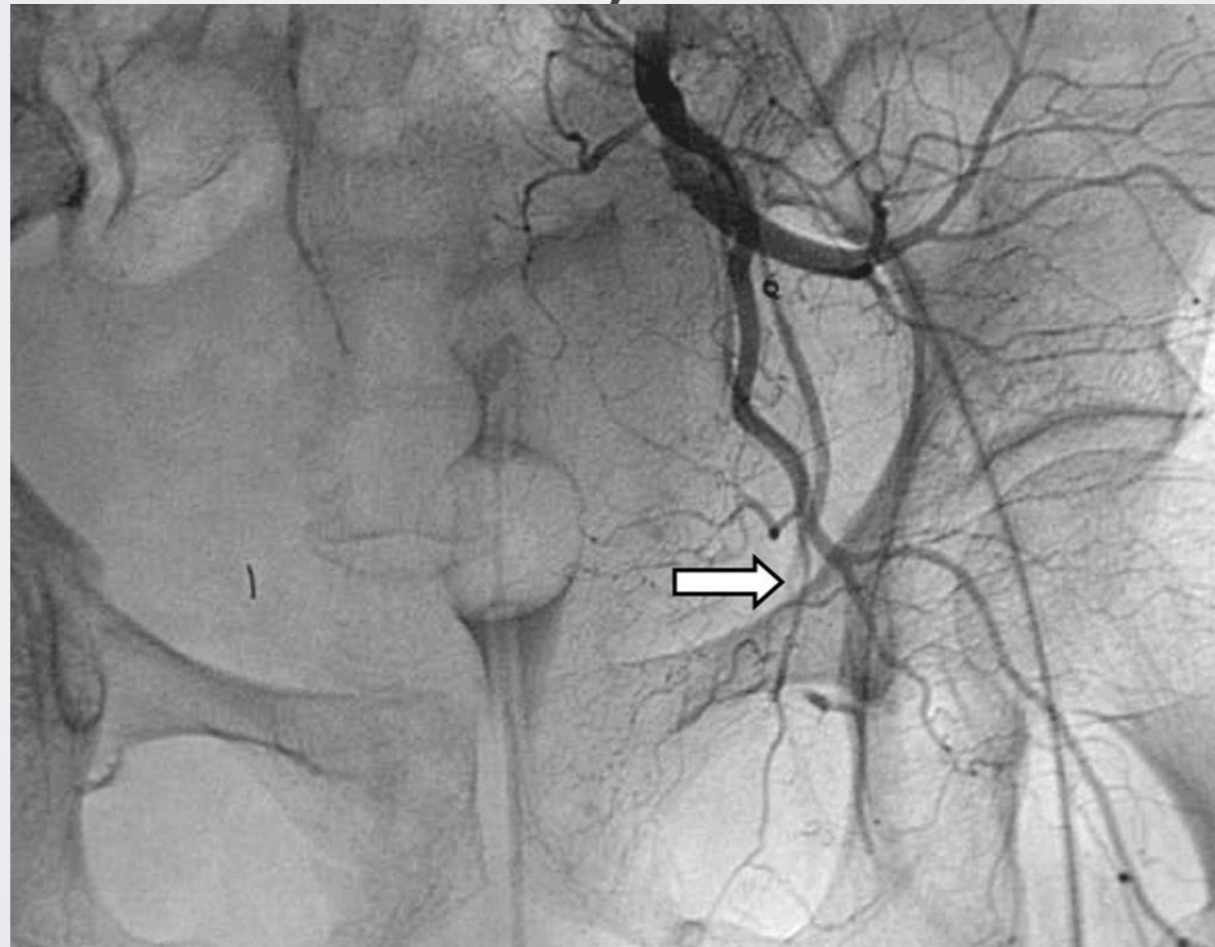




# Pelvic trauma

In the poly trauma patient

- Pelvic fractures / instability may cause life threatening bleeding
- Diagnosing pelvic instability can save lives



# Pelvic trauma

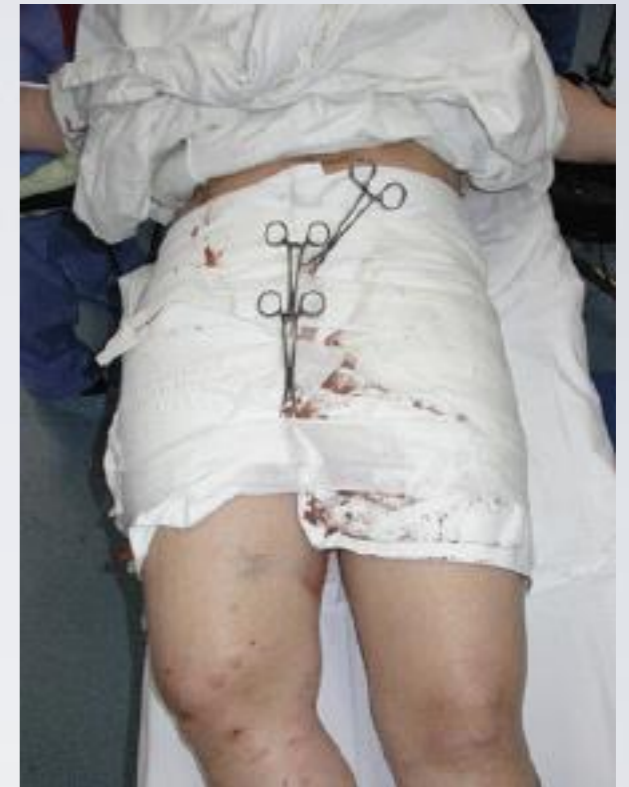## In the poly trauma patient

- Diagnosis:
  - History: High vs. Low energy trauma
  - Mechanism of injury: Anterior vs. Lateral vs. Axial force
  - Pelvic skin contusion, bruising
  - Short extremity
  - Careful neurologic assessment

# Pelvic trauma

## In the poly trauma patient

- Diagnosis:
  - Primary survey : part of “C”
    - Assess stability by gentle compression on the ASIS
    - Traction on the leg and assess pelvic instability
      - If unstable or painful:
        - Apply sheet around hips and close the pelvis gently
        - This results in decreased intra-pelvic volume leading to tamponading the bleeding
        - Traction on the leg to stabilize vertical instability
        - This minimizes ongoing vasculature injury and bleeding



# Pelvic trauma

## In the poly trauma patient

- Diagnosis:
  - Rectal exam:
    - Bone fragments ( be careful)
    - High riding prostate
    - bleeding
  - Blood at the meatus
  - Labial or scrotal echymosis
  - Vaginal exam

# Pelvic trauma

In the poly trauma patient

- Management:
  - Stabilize pelvis with binder
  - If vertically unstable apply traction
  - IV resuscitation
  - Look for other injuries
  - Check response

# Pelvic trauma

In the poly trauma patient

- Management:
  - If partial response, may require angiography for embolization of bleeders
  - May require external fixator and/or pelvic clamp

# Pelvic trauma

In the poly trauma patient

- Early diagnosis
- Aggressive resuscitation
- Coordinated team effort
  - Save lives