

COMMON ADULT'S FRACTURES

Dr. Sultan Aldosari, MBBS, FRCS.




OBJECTIVES

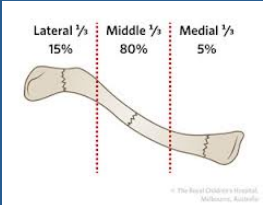
- CLAVICAL FRACTURE
- HUMERUS (PROXIMAL & SHAFT)
- BOTH BONE FOREARM FRACTURES
- DISTAL RADIUS FRACTURE
- HIP FRACTURE
- FEMUR SHAFT FRACTURE
- TIBIAL SHAFT FRACTURE
- ANKLE FRACTURE

CLAVICLE FRACTURE

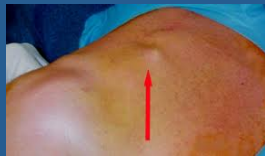- Clavicle is S shape bone
- It is anchored to scapula via ACJ.
- It is anchored to trunk via SCJ
- Most of fracture occurs as result from fall onto shoulder.



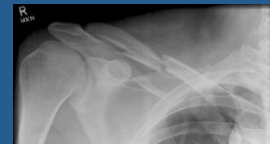- Fracture is classified into: proximal, middle and lateral third fractures.
- Most of fractures are of middle third.



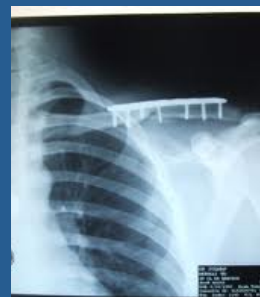- Clinical findings:
 - Check the skin
- Injury to brachial plexus and subclavian artery/vein may be present
- Rarely, Pneumothorax can occur.



- X-rays:
 - AP chest
 - Clavicle special view.



- Treatment:
 - Most of clavicle fractures are treated with a sling.

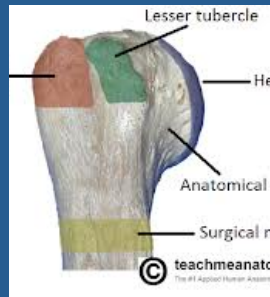


Few fractures should be treated surgically with open reduction and internal fixation

- Skin is tented
- Severe displacement:
 - 100% displacement
 - > 2 cm overlap

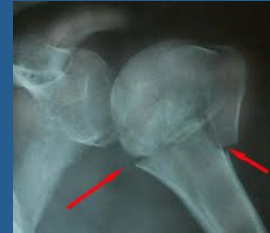PROXIMAL HUMERUS ANATOMY

- Proximal humerus has four anatomic parts:
 - Head
 - Greater tuberosity
 - Lesser tuberosity
 - Shaft
- Anatomic neck v.s surgical neck.



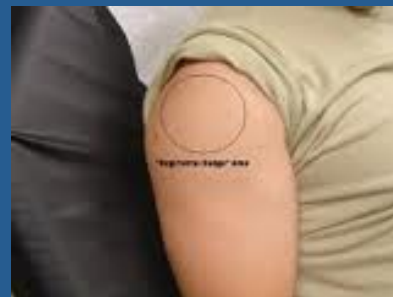PROXIMAL HUMERUS FRACTURE

- In younger patients: violent trauma.
- In older patients: minor trauma.
- Most fractures are minimally displaced.



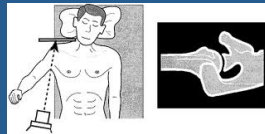
PHYSICAL EXAM

- Expose the shoulder very well.
- Look for fracture signs
- Check the skin.
- Peripheral N/V exam.
- Axillary nerve: lateral skin patch.
- Examine cervical spine.



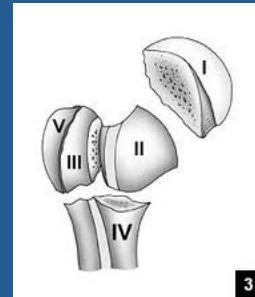
X-rays

- AP
- Lateral
- Axillary views.
- CT scan for displaced fractures.

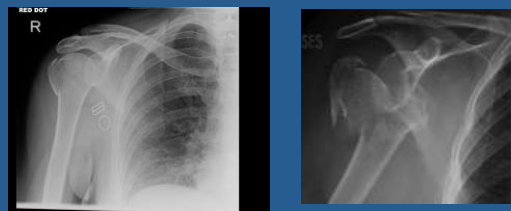
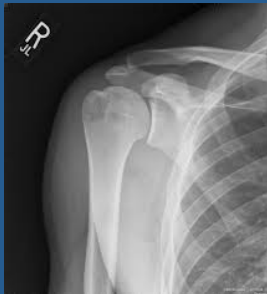
X-rays

- Fracture is defined by the fragments displaced.
- Displacement: more than 1 cm.

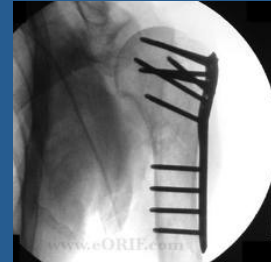

Normal AP shoulder



- If fracture is not displaced:
 - Treatment with sling and NWB of UE for 6-8 weeks.
 - Early ROM exercises after 2-4 weeks.
 - Normal function can be resumed after 3-4 months.

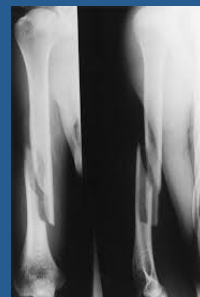
- If the fracture is displaced:
 - Surgery is indicated.
 - ORIF is indicated (plate and screws).
 - Shoulder hemiarthroplasty is indicated in some cases.



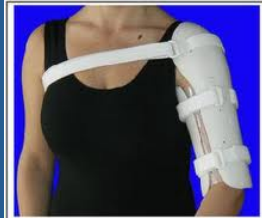HUMERUS SHAFT FRACTURE

- It can be classified based on location of fracture. (proximal, middle and distal)
- Fracture symptoms.
- On exam:
 - Skin
 - N/V
 - Compartment
- Watch for radial nerve palsy.

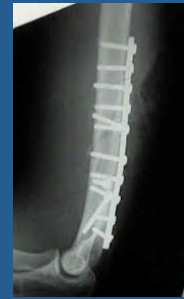X-rays



- Almost all humerus shaft fracture can be treated non-surgically.
 - Close reduction
 - Functional brace x 4-6 weeks + NWB
 - Early ROM of elbow and shoulder.



- Surgery is indicated for specific conditions like:
 - Segmental fracture
 - Open fracture
 - Obese patient
 - Bilateral fracture
 - Floating elbow (forearm and humerus)
- Surgery: ORIF with plate and screws.

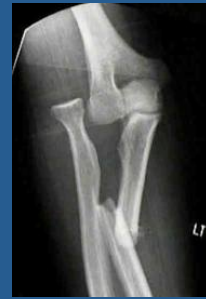
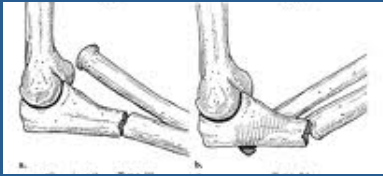
BOTH BONES FOREARM FRACTURE

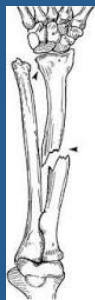- Forearm is complex with two mobile parallel bones.
- Radius and ulna articulate proximally and distally.
- It very unlikely to fracture only one bone without disruption of their articulation:
 - Both bone fracture
 - Monteggia fracture
 - Galeazzi fracture.

- Fractures are often from fall or direct blow.
- Both bones fracture:
 - Means radius and ulna are broken.
- Monteggia fracture:
 - Means proximal or middle third ulna shaft fracture with dislocation of radius proximally (at elbow)
- Galeazzi fracture:
 - Means distal third shaft radius fracture with disruption of DRUJ.

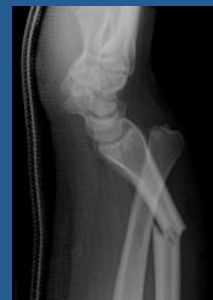Monteggia



Galeazzi



Galeazzi

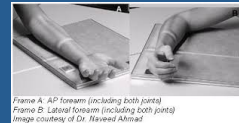

CLINICAL

- Symptoms and signs of fracture
- Check the skin
- Check the compartments of forearm
- Check Ulnar, median and radial nerve (PIN,AIN)
- Check vascularity: color, temperature, capillary refill and pulse.

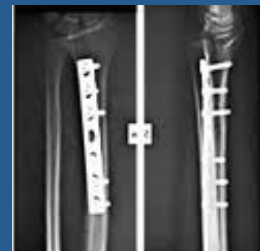Investigations

- 2 orthogonal views
- CT scan if fracture extends into joint.



Treatment

- Both bone fracture:
 - Reduce and splint at ER/clinic (temporary)
 - Are treated almost always with ORIF: (plate and screws)
- Monteggia fracture:
 - ORIF ulna and close reduction of radial head
- Galeazzi fracture:
 - ORIF radius and close reduction of DRUJ.



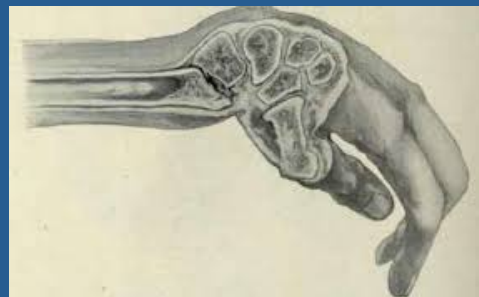DISTAL RADIUS FRACTURE

- Most common fracture of upper extremity.
- Most frequently are seen in older women.
- Young adults fractures are most commonly secondary to high energy trauma.

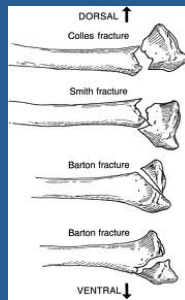
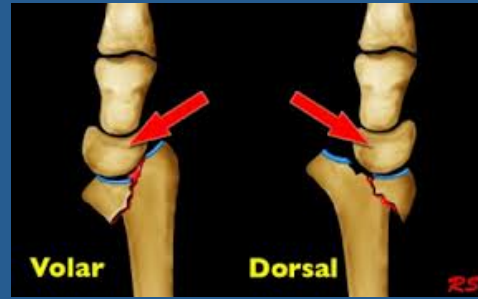
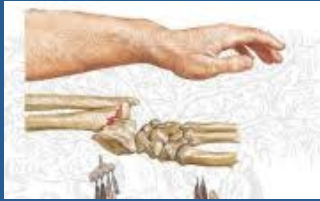

- Extra-articular:
 - Colles' Fracture: dorsal angulation, shortening and radial deviation
 - Smith's fracture: shortening and volar angulation. (reverse Colles')
- Intra-articular:
 - Barton's fracture: volar or dorsal
 - others

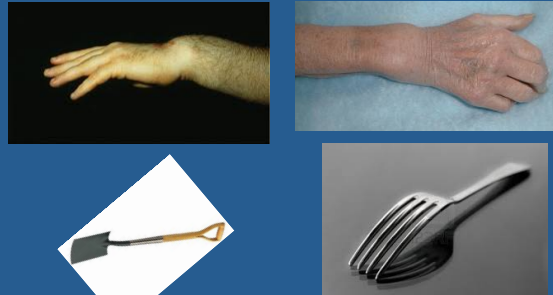
Colles'



Smith's

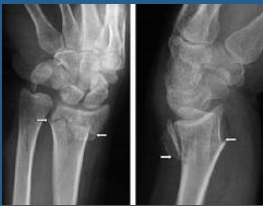

Clinical

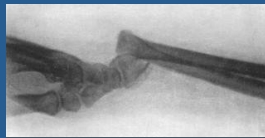


X-rays

Colles'

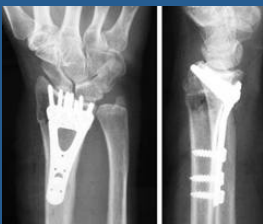

Smith's



CT scan if fracture extends into joint

- Extra-articular fractures:
 - Close reduction and cast application.
 - Immobilization for 6-8 weeks.
 - ROM exercises after cast removal.
 - Surgery: if reduction is not accepted
- Intra-articular fracture:
 - a step more than 2 mm is an indication for surgery.
 - ORIF with plate and screws.



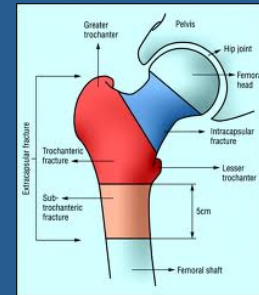
LOWER EXTREMITY

HIP FRACTURE

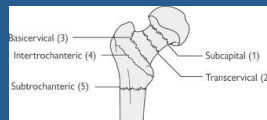
(Old Patients: > 60 yrs)

- It is the most common fracture of LL.
- It is associated with osteoporosis.
- Most common mechanism is a fall from standing height.
- Other causes of fall (stroke, MI) should be rolled out during clinical evaluation.
- It is a life changing event.

- Fractures can be classified
 - Intra-capsular
 - Extra-capsular
 - Displaced vs not displaced



- Intra-capsular:
 - Subcapital
 - Trans-cervical
- Extra-capsular:
 - Basicervical
 - Intertrochanteric
- AVN risk is higher with intra-capsular fracture.



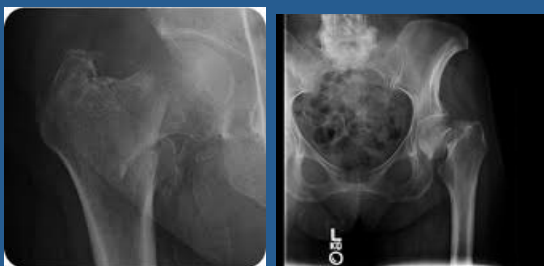
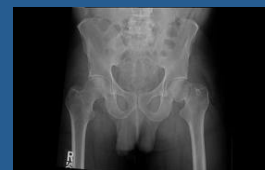Clinical

- Full detailed history of mechanism of injury.
- R/O syncope, chest pain, weakness etc.
- A detailed systemic review.
- Deformity: Abduction, External rotation and shortening.
- Assess distal N/V status
- Avoid ROM if fracture is expected.

- Common associated injuries:
 1. Distal radius fracture
 2. Proximal humerus fracture
 3. Subdural hematoma

- R/O:
 - ACS
 - Stroke

- 3 views are needed:
 - AP pelvis
 - AP hip
 - Lateral hip
- MRI is sensitive for occult fracture.

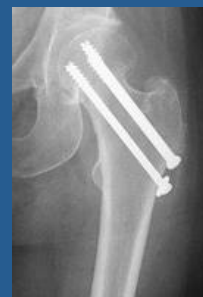
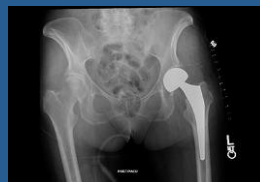
Treatment

- No close reduction is needed.
- No traction is needed.
- Patient needs surgery ideally within 48 hrs.
- The goal is to ambulate patient as soon as possible.
- Be sure that DVT prophylaxis is started.
- Be sure that patient will be evaluated for osteoporosis after discharge.

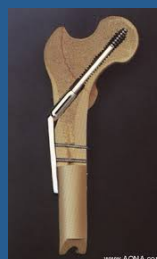Treatment

- If fracture is intra-capsular:
 - **Displaced:** hemiarthroplasty
 - **Not displaced:** percutaneous in situ Screws fixation.

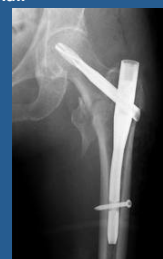

- If fracture is Extra-capsular:
 - Stable: Close reduction and DHS
 - Unstable: Intra-medullary devise
- Fracture instabilities signs:
 1. Large LT fragment
 2. Extension to subtrochantric region
 3. 4 parts fracture.

DHS



IM nail



Complications

- Nonunion
 - 2% (IT fractures)
 - 5% (non displaced neck fracture)
 - 30% (displaced neck fracture)
- AVN (femoral neck fracture) :
 - 10% (non displaced)
 - 30% (displaced)
- Death: early 4 %. At 1 year: 20-40 %
- VTE

Femoral Neck FRACTURE (Young Patients)

- It is a completely different entity from similar fractures in elders (>60 years).
- High energy mechanism.
- ATLS protocol.
- 2.5%: associated femoral shaft fracture. (long femur X-ray)
- Patient should be taken to operative room for ORIF within 6 hours.
- Nonunion: 30% (most common complication)
- AVN: 25-30%

Femur Shaft Fracture

- Most common:
 - high energy mechanisms
 - Young patients (male, < 30 years).
 - ATLS protocol.
- Less common:
 - low energy mechanism (torsional forces)
 - Old patients.
 - Spiral type fracture.
- R/O pathological fracture in Young + low energy mechanisms.

- Associated musculoskeletal injuries:
 - Ipsilateral femoral neck fracture (10%. Missed in 30-50%)
 - Knee ligaments injuries: 50%
 - Meniscal tear 30%
 - Floating knee injury: less common
 - Vascular/nerve injuries: rare
 - Contralateral femur shaft fracture (worse prognosis among above)

- Associated non-MS injuries:
 - Fat embolism
 - ARDS
 - Head injuries.
 - Abdominal injuries

Clinical

- ATLS
- Fracture symptoms and signs
- Skin integrity
- N/V exam.
- Compartment assessment
- Knee swelling or ecchymosis.

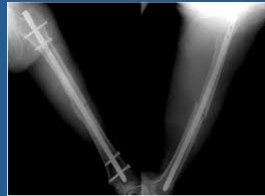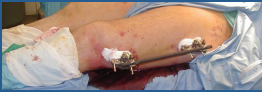Investigations

- AP and lateral views femur
- 15° Internal rotation AP view ipsilateral hip.
- Lateral view ipsilateral view
- If femoral neck fracture is suspected: CT scan hip.
- Knee AP and lateral views

Management

- ATLS: ABC resuscitation.
- Skeletal traction (proximal tibial pin)
- Early surgical fixation:
 - Proven to reduce Pulmonary complications.
 - Must be within 24 hrs (ideally < 6 hrs)
 - If patient is unstable: External fixation.
 - If Patient is stable IM nailing

FEMUR SHAFT FRACTURE



Complications

- Malunion:
 - most common.
 - More common with proximal fracture (subtrochantric fracture)
 - Rotational, angulation and shortening
- Nonunion: rare
- Infection.
- VTE.

TIBIA SHAFT FRACTURE

- It is a subcutaneous bone (high suspicion for skin injury).
- Most common large long bone fracture.
- It can be secondary to low or high energy mechanism.
- It carries the highest risk of compartment syndrome.
- 20 % of tibial fracture can be associated with ankle intra-articular fracture.

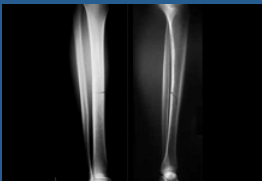- It can be classified based on location and morphology:
 - Proximal third
 - Middle third
 - Distal third
- Displaced vs. Non-displaced:

- Clinical:
 - Skin integrity.
 - Assess compartments of leg : needs serial exam.
 - Serial N/V exam.

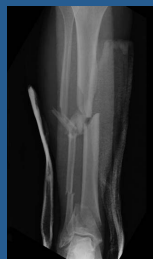INVESTIGATIONS

- X-rays:
 - AP and lateral tib/fib .
 - AP/lateral knee
 - AP/ Lateral ankle
- CT SCAN IF FRACTURE EXTENDS INTO JOINTS ABOVE OR BELOW.

NOT DISPLACED



DISPLACED



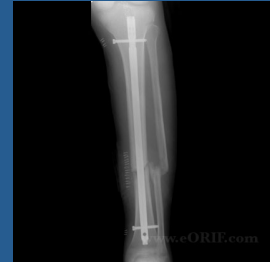MANAGEMENT

- Indications for non-surgical treatment:
 - NO displacement : < 10° angulation on AP/lateral x rays.
 - < 1 cm shortening.
 - Not comminuted.
- C/I:
 - Displacement.
 - Open fracture.
 - Compartment syndrome.
 - Floating knee.

MANAGEMENT

- Close reduction and cast immobilization:
 - Above knee back slab and U slab if surgical treatment is chosen.
 - Above knee full cast if non-surgical treatment is chosen: it must be bivalved to minimize compartment syndrome.
 - Always provide patient with Compartment Syndrome checklist if patient is discharged home with cast.
 - NWB for 8 weeks with cast immobilization.

- Surgical treatment:
 - Most common modality of treatment.
 - Most commonly IM nail fixation.

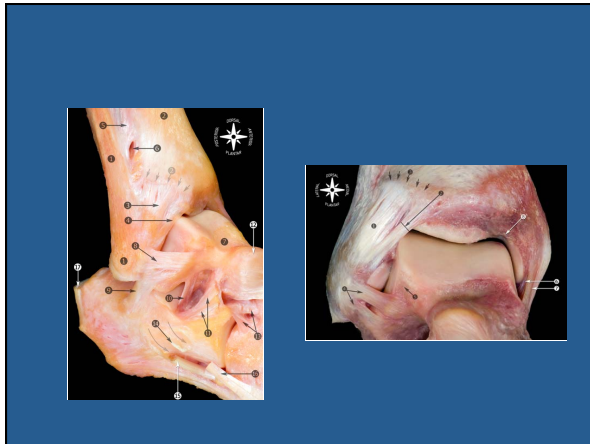

COMPLICATIONS

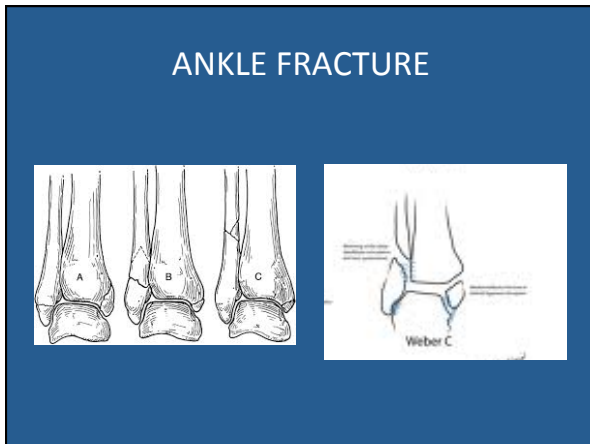
- Non-union: most common complication.
- Delayed union
- Infection: open fracture
- DVT/PE

ANKLE FRACTURE

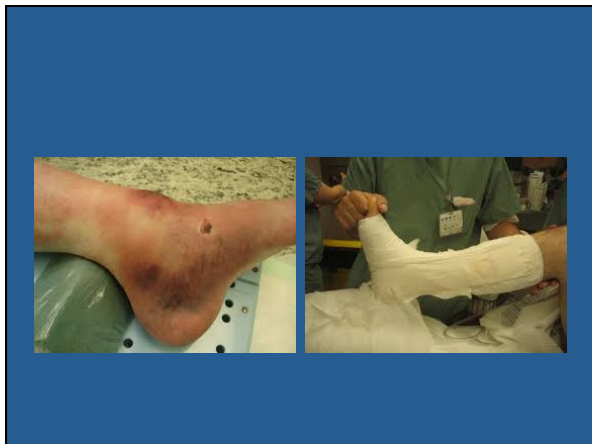- Ankle anatomy:
 - Medial and lateral malleoli, distal tibia and talus.
 - Highly congruent joint
 - Fibula is held to distal tibia by syndesmotic ligament.
 - Medial malleolus is held to talus by deltoid ligament.
 - Lateral malleolus is held to talus by LCL.



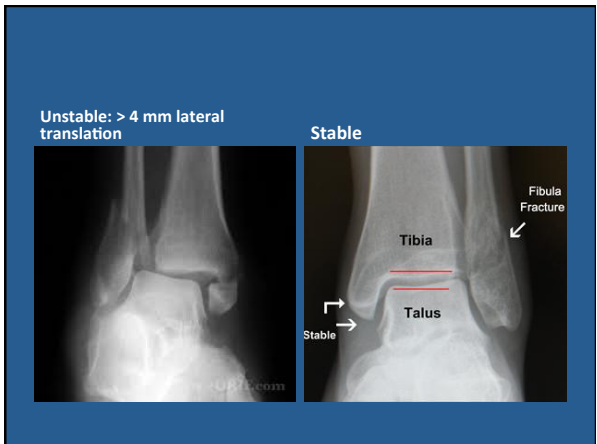
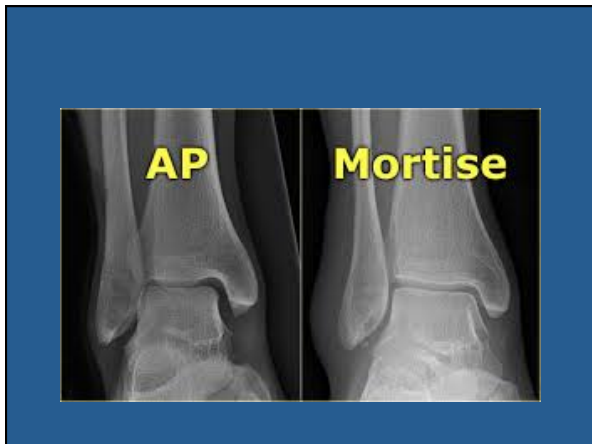
- Low energy (torsional): malleoli fracture.
- Classification:
 - Stable v.s Unstable fracture:
 - lateral displacement of talus
 - Medial, lateral or bimalleolar fracture
 - Lateral malleolus: Weber A, B, C

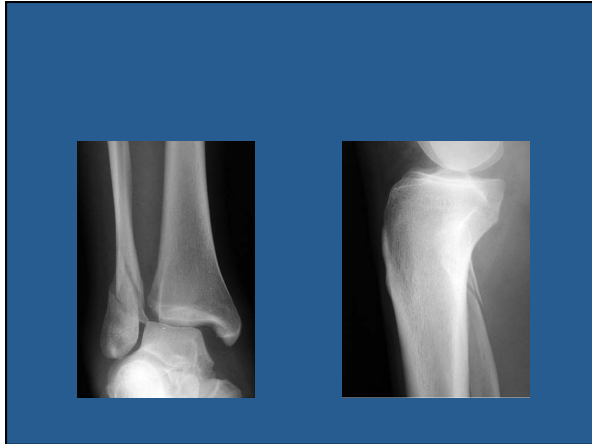

- ### CLINICAL
- Look for Fracture symptoms and signs.
 - Assess medial joint ecchymosis or tenderness to assess medial malleolus and deltoid ligament integrity.
 - Assess N/V status (before and after reduction).




- X-rays:
 - AP
 - Lateral
 - Mortise view
 - Long leg x-rays: if only medial malleolus is broken.
- CT SCAN IF FRACTURE EXTENDS TO ARTICULAR SURFACE OF DISTAL TIBIA.





- Intact medial malleolus:
 - Weber A:
 - splint + NWB X 6 weeks.
 - Early ROM.
 - Weber B/C:
 - If medial joint line widen (unstable): ORIF.
 - If not: Call Orthopedic for stress film x-rays.
 - If both malleoli are broken:
 - ORIF



The right image shows two X-ray views of a knee joint. The left view is a lateral view, and the right view is an anterior view. The right view shows surgical hardware (screws and plates) on the medial malleolus, indicating an ORIF procedure. A small 'B' is visible in the bottom right corner of the right image.

THANKS