



433 Teams
ENT

16

Larynx I

Color index:

432 Team – **Important** – 433 Notes – Not important

ent433team@gmail.com



جامعة
الملك سعود
King Saud University

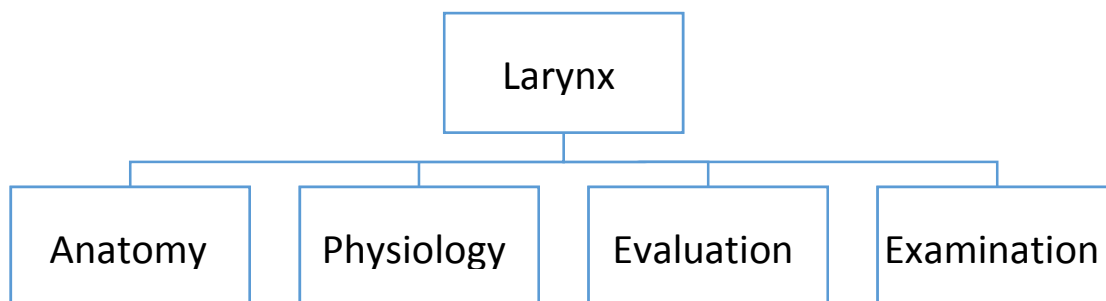


Objectives for Larynx I & II:

- To know the basic larynx anatomy and physiology.
- To recognize assessment and management of common laryngeal diseases, include ability to obtain patients' history, perform comprehensive physical and mental status assessment, interprets findings
- To know how to handle common laryngeal emergencies.
- To be aware of common laryngeal operations.

Specific Objectives for Larynx I:

- Anatomy and physiology of the larynx
- Gross anatomy, blood and nerve supply



History and Examination

Case: 35 years old female has dysphonia (hoarseness)?

- You should ask about:

Duration, Onset (sudden, gradual), progression. Associated symptoms:

1) Difficulty in breathing (In larynx we have two vocal cords which get adducted when talking – phonation– by the help of four muscles and abducted when breathing by the help of one muscle). If pt vocal cord isn't opening while breathing she'll have stridor.

2) Difficulty in swallowing: posterior to the larynx is the esophagus if there's any problem there it might cause dysphagia.

3) Neck swellings: if pt has dysphonia and we examined the neck (neck mass: goiter) remember the course of the recurrent laryngeal nerve which passes through the neck suspecting a mass compressing the nerve.

4) Aspiration and choking: when talking or eating what normally happens cessation of breathing, vocal cords are attached adducted and epiglottis come anteriorly to close the airway (If pt has vocal cord paralysis, no sensation and choking might happen).

5) Trauma: ask about surgeries required intubation (the ETT is passing through the vocal cords posteriorly if the anesthetist was very aggressive he can dislocate arytenoid distorting the pt voice (it's not nerve problem but mechanical), blunt trauma, iatrogenic –most common cause for dysphonia here is thyroid surgery.

6) Social life: coffee and tea (foreign body sensation: throat clearance, feeling of something is stick to the throat.

There are two types of reflux: GERD (heart burn)

LPR laryngopharyngeal reflux: sometimes acidity go up to the larynx, in larynx it doesn't accept the acidity there so you start clearing your throat to wash it away. When examining the cords here they will be edematous red congested. Here you should ask about the habits which increase the reflux: coffee, tea, lying flat when sleeping, eat before going to bed..etc

7) Medication

8) Fever, weight loss, change in appetite to exclude cancer also URTI in winter causing laryngitis and that will cause some changes to the vocal cords (red, congested) leave it for few days it will resolve by it's on but in voice abusers like teachers, lawyers ..etc you must give them ten days rest or else their vocal cords will be damaged.

- Examination: If the patient has no history of any surgeries, trauma or anything just dysphonia and one of the vocal cord is immobile by examination(nose, throat and vocal cords) you must do CT scan chest and neck and follow the nerve the course of the recurrent laryngeal nerve passing from the chest up to the neck to exclude any masses compressing it causing his problem. if nothing was detected you label him as idiopathic.

Definitions

- Dysphonia: is a **descriptive medical term** meaning **disorder of voice**.
- Hoarseness: is a **subjective term**, and usually refers to a **weak or altered voice**.
- Voice changes are: **breathy (vocal cords aren't closing well so the air is escaping this could be due to vocal cord paralysis)** **harsh (a mass compressing on vocal cord)**, **tremulous, weak, reduced to a whisper, or vocal fatigue like in teachers where voice deteriorates with use.**

Team 430:

Normally person talks at end of respiration.

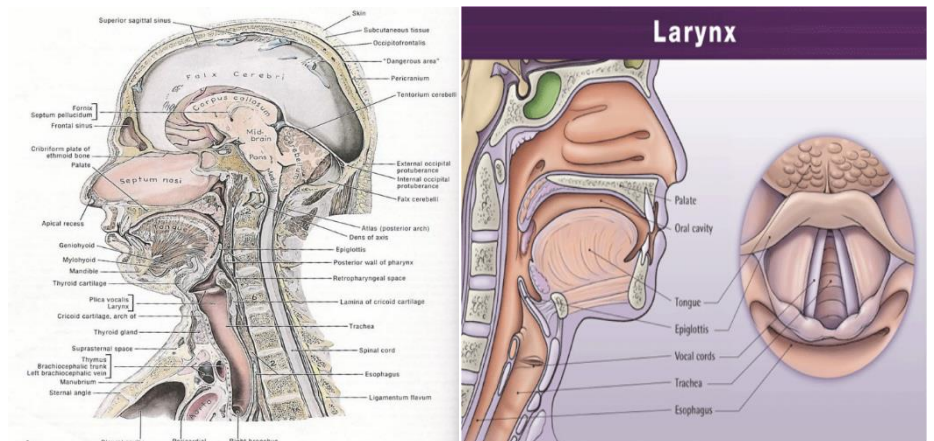
-- You breathe then talk and never breath in while talking without stopping, therefore while talking you are building up pressure causing the vocal cords to move and close during phonation

-- In breathy voice 1 of the vocal cords is not moving, so instead of saying 10 words in 1 sentence someone with a breathy voice will say around 3 words and stop for a breath

Anatomy

--The larynx extends from the epiglottis to the cricoid.

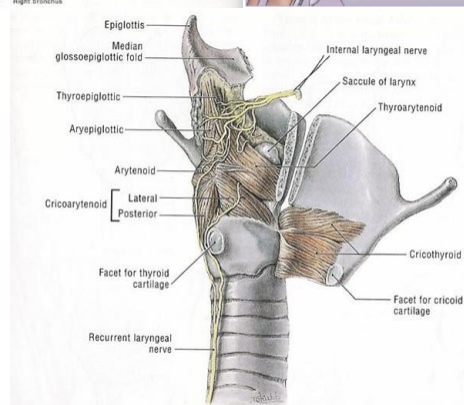
--The epiglottis is located on top, behind it two cartilages called arytenoid and hyoid cartilage.



Skeletomembranous

Framework of Larynx:

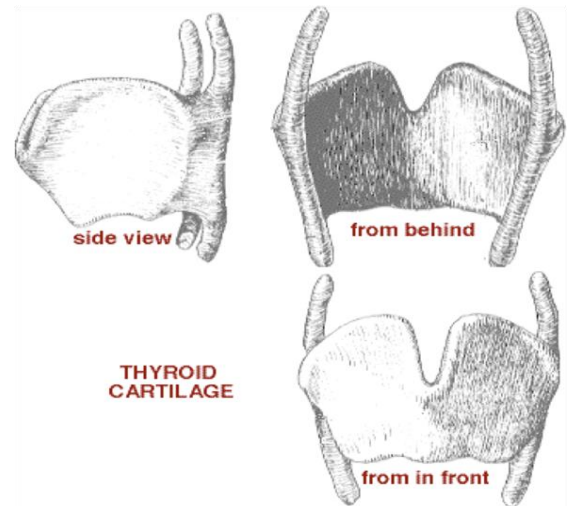
- 1) Thyroid cartilage
- 2) Cricoid cartilage
- 3) paired arytenoids cartilage
- 4) Epiglottis
- 5) Hyoid bone



When you feel your neck there are two cartilages first is the thyroid (shield like) open posteriorly and below it the cricoid (complete ring) both are hyaline cartilages so it will be calcified with time in elderly people (if x-ray was done on a 45 years old patient and found opacity it is normal) and the joint between them is synovial joint allowing some movement between the cricoid and the thyroid cartilages

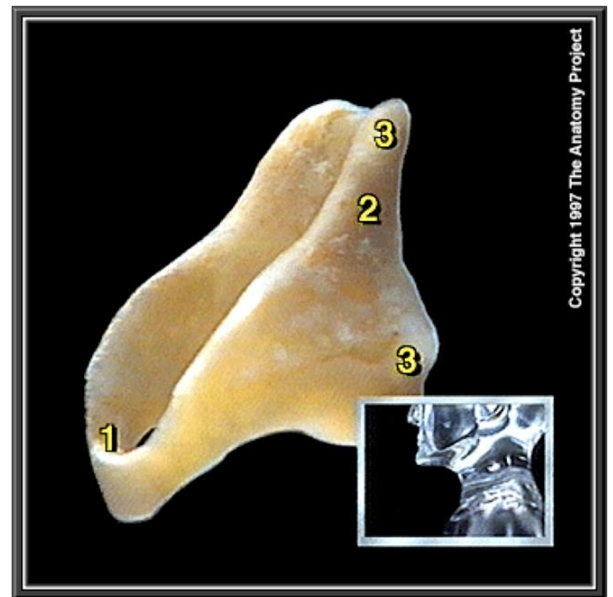
1) Thyroid Cartilage:

- Shield like
- Thyroid cartilage is opened posteriorly.
- In men it is noted as Adam’s apple.
- It is attached to the cricoid.



2) Cricoid Cartilage:

- Signet ring shaped.
- the only **complete skeletal ring** for the air way.
- Both thyroid and cricoid cartilage ► hyaline ► calcification
- Cricothyroid joint is a Synovial joint ► hinge motion
- Cricoid Cartilage is the narrowest area where the airway obstruction usually happens because it is a complete ring.
- Thyroid and cricoid might be seen as bones (calcified) in an X-Ray of a 40-year old patient.

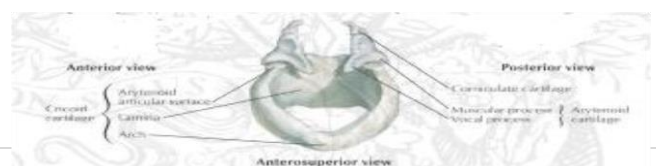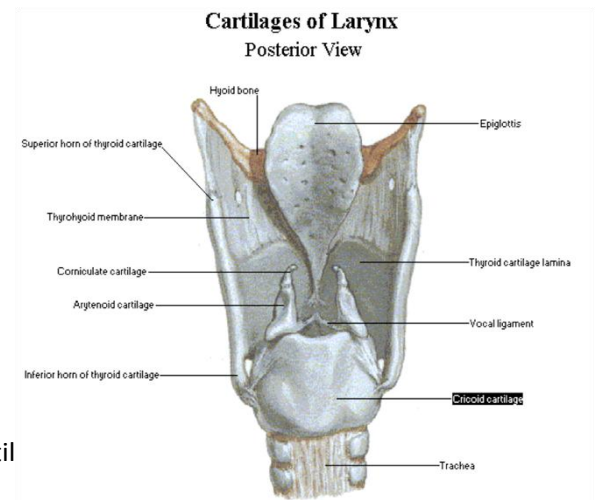


3) Arytenoid Cartilage:

- Pyramidal shaped
- Apex , vocal & muscular process.
- Cricoarytenoid joint: Synovial Rocking motion

4) Corniculate and Cuneiform Cartilage:

Two small cartilages (arytenoid) lay over the cricoid cartil pyramidal in shape has anterior process called vocal process and another muscular process posteriorly. it has an apex and above it another small cartilage called corniculate cartilag



5) Epiglottic Cartilage:

-Leaf like structure

-Elastic cartilage

-Its ligaments and fold: Thyroepiglottic

ligament (to thyroid)

Hyoepiglottic ligament (to hyoid bone)

glossoepiglottic fold ► valleculae
(Valleculae is the base of the tongue where the tongue is attached to the epiglottis)

-The epiglottis on top is attached to the thyroid cartilage midline, inner margin of thyroid, it's an elastic cartilage while swallowing it covers the airway and directs the food to cricopharynx.

-Thyroid, cricoid and epiglottis are all single cartilages unlike the others paired

- **Laryngeal Membranes:**

The cartilages are covered by membranes that form folds and ligaments

1) Quadrangular membrane.

-Upper and lower border ► thickened

-aryepiglottic fold (it goes up covering the epiglottis)

-Vestibular fold (or ventricular fold inferiorly also called false vocal cord)

2) Triangular membrane (conus elasticus).

Medial and lateral border is free ► thickened

► vocal ligament

--- Covers the trachea going up and ends at the level of vocal ligaments or fold

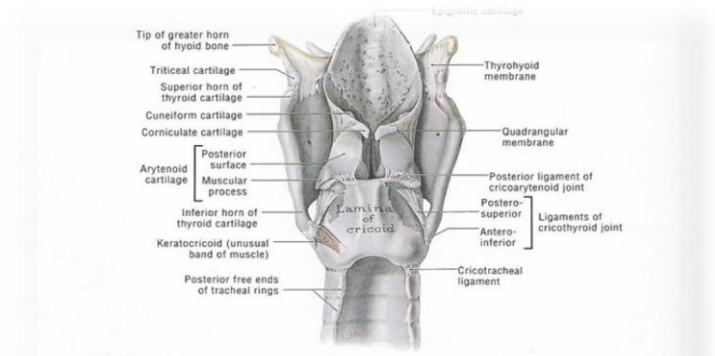


Figure 8-55. Posterior view of the skeleton of the larynx. Observe that the thyroid cartilage shields the smaller cartilages of the larynx. The hyoid bone, although not a part of the larynx, shields the upper part of the epiglottic cartilage.

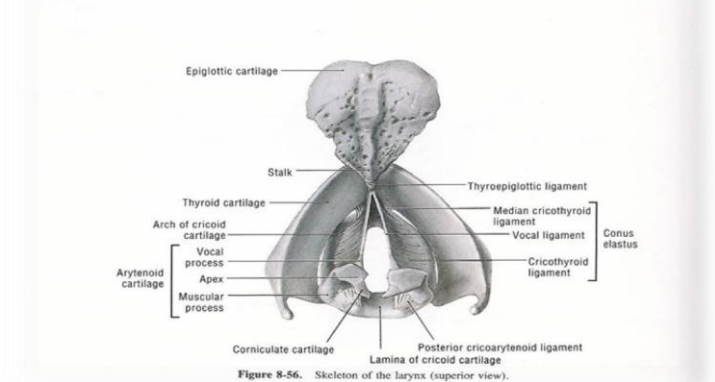
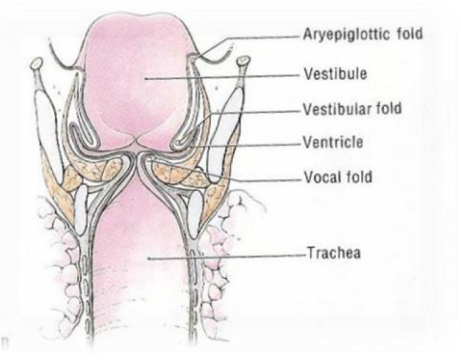
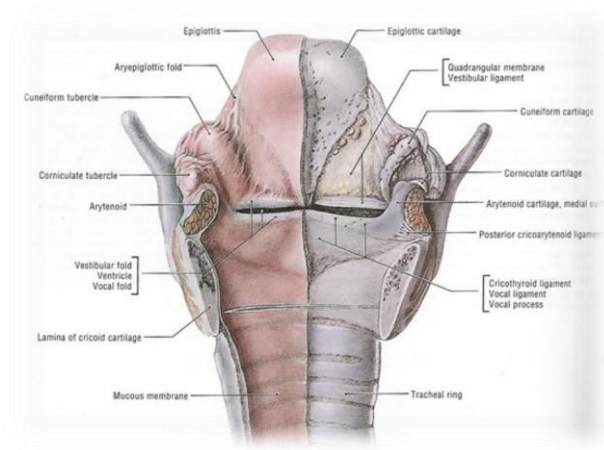


Figure 8-56. Skeleton of the larynx (superior view).



- Between the upper membrane (quadrangular m) and the lower membrane (triangular m) there is a very weak area (in the larynx) which is not covered by any membrane we call it the ventricle or vestibule or saccule.

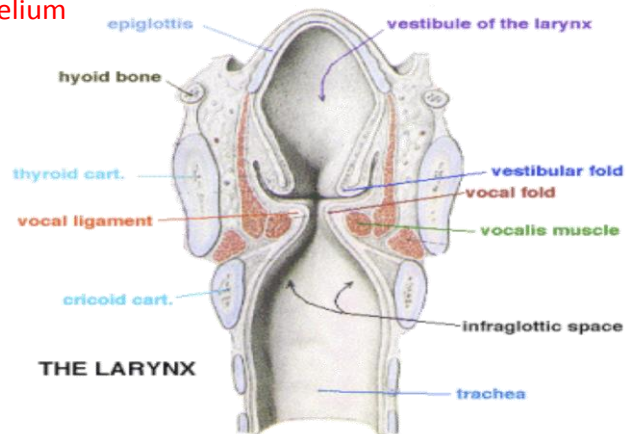
- **Laryngeal Mucosa:**

All mucosa from trachea to aryepiglottic fold ► **ciliated columnar epithelium.**

- Except vocal cord and aryepiglottic fold ► **squamous epithelium.**

- Commonest tumor in larynx: **Squamous Cell Epithelium**

Most common tumor of vocal cords is squamous cell carcinoma



- **Cavity of Larynx:**

-The area between the Vocal Cords is Glottis -The area above the Vocal Cords is Supraglottis or Epiglottis

-The area below the vocal Cords is Subglottis

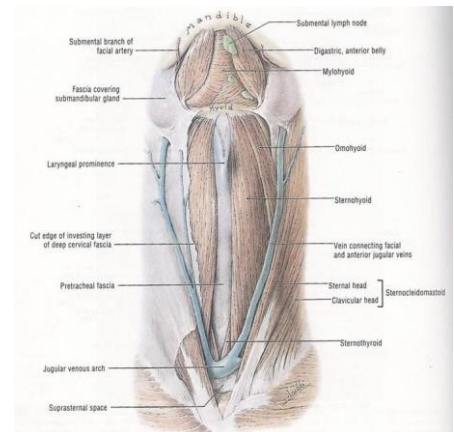
- **Laryngeal Musculature:**

Extrinsic depressors: (C1-C3)

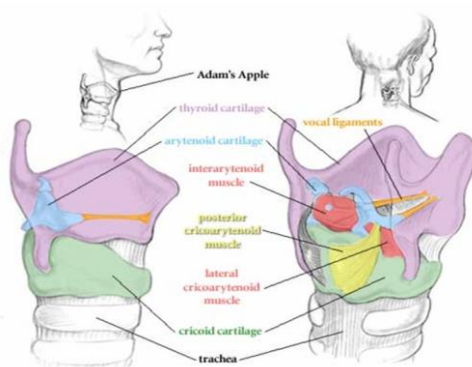
Sternohyoid, sternothyroid, thyrohyoid, omhyoid.

Extrensic elevators:

Genohyoid (C1), diagastric (CNV-CN VII)
mylohyoid (v) stylohyoid (VII) **Used in swallowing.**



All elevators attachments are above and all the depressors attachments are below to suit their function (Dr: the extrinsic muscles are not so important focus on the intrinsic ones)



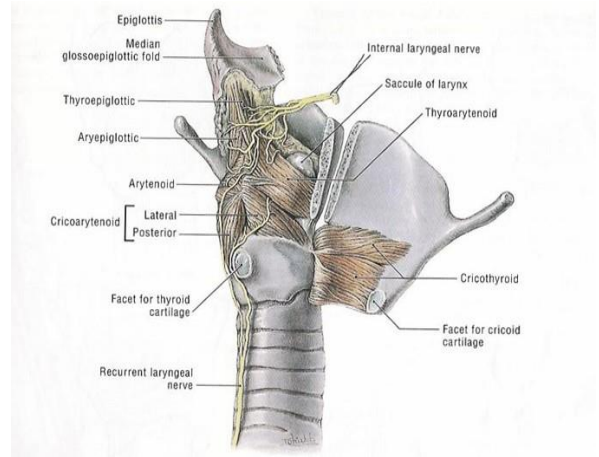
• **Intrinsic Musculature:**

Abductors: (breathing)

posterior cricoarytenoid (PCA)

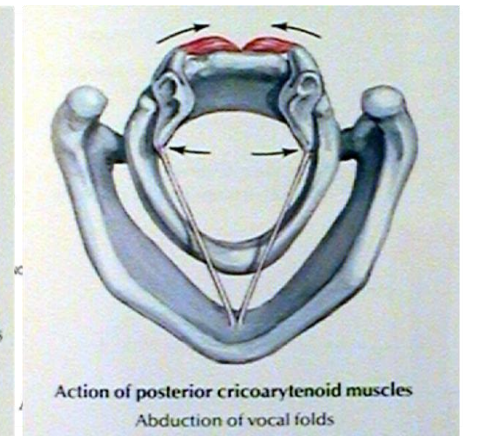
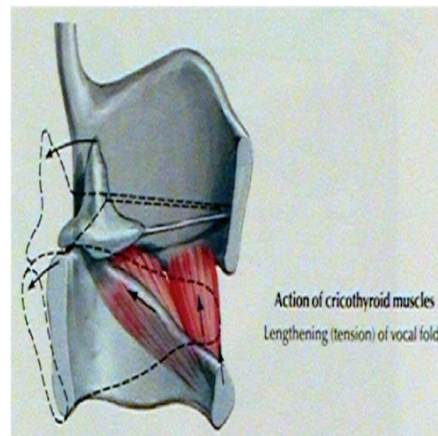
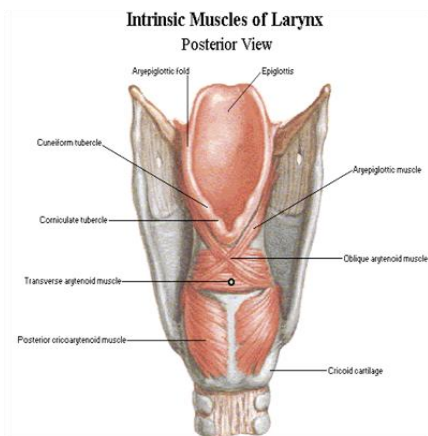
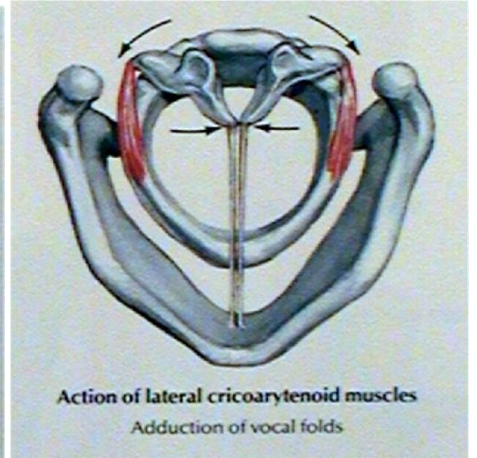
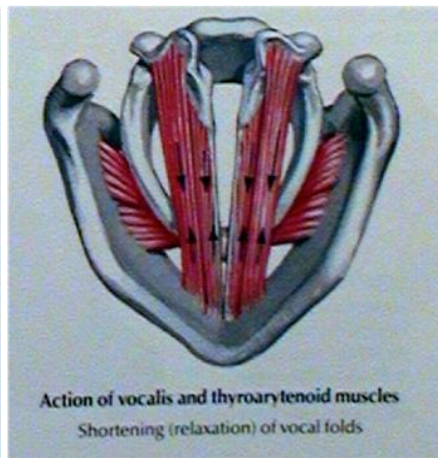
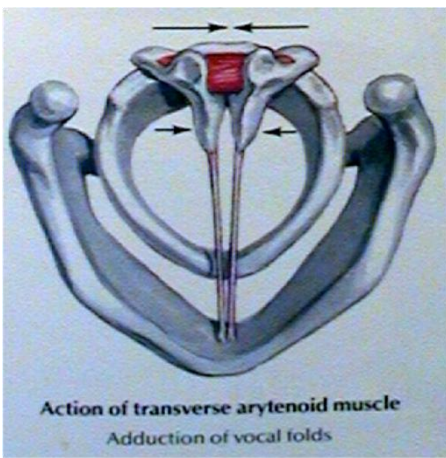
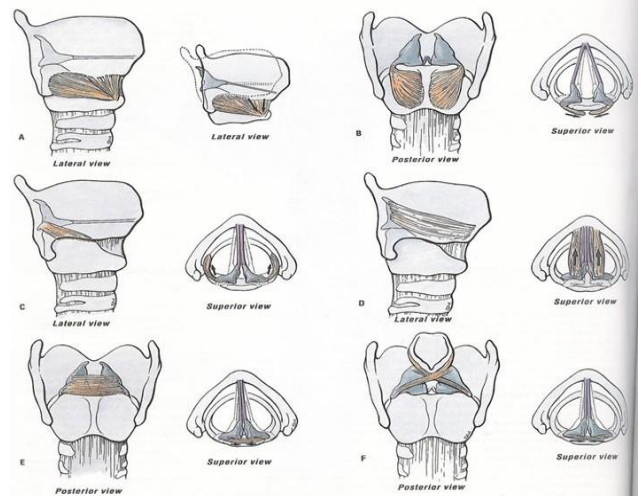
Adductors: (talking)

thyroarytenoid (TA), lateral cricoarytenoid (LCA), cricothyroid, interarytenoid .



Vocal cords have 2 movements: Adductors (4 muscles) are used for speaking, Abductor (1 muscle) used for breathing and located Posteriorly. **(Important for MCQs)**

Cricoidthyroid is an adductor muscle. But mainly it is responsible for the **Vocal Cord tension** of the vocal cords and supplied by the Superior Laryngeal Nerve (SLN). **(Important for MCQs)**

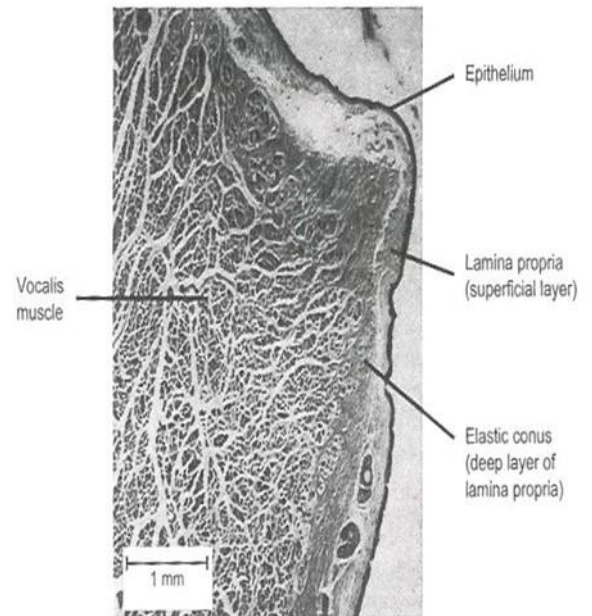


- **Histology:**

Vocal cord layers:

- 1) Squamous epithelium
- 2) Lamina propria
 - 1- superficial layer Reink's space
 - 2-Intermediate layer. 3- Deep layer .

-Intermediate + deep layers =vocal ligament (the two layers are attached to each other)
- 3) Vocalis (thyroarytenoid muscle)



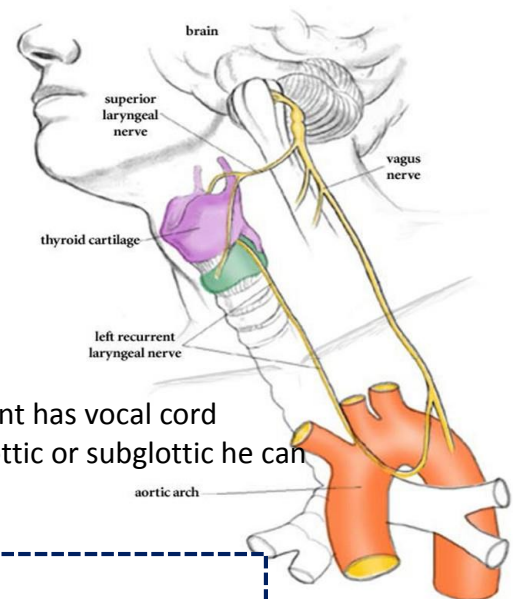
- **Blood Supply:**

Superior and inferior laryngeal artery and veins.

- **Lymphatic Drainage:**

Above vocal cord ► up deep cervical lymph node. Below vocal cord lower ► deep cervical node

Vocal Cords have no lymphatic drainage, So when the patient has vocal cord carcinoma he won't have metastasis unless it goes supraglottic or subglottic he can start to have metastasis from there.



430 Team:

-Any smoker should undergo vocal cord carcinoma screening.

- Lymph nodes drain into cervical lymph nodes so any patient that comes with neck mass especially painless you should consider lymphoma. History: onset and duration, URTI, complete head and neck examination.

- **Nerve supply:**

Vagus gives 2 branches:

1. Superior laryngeal nerve (SLN)
 - o Internal branch (sensory) + superior laryngeal artery.
 - o External branch (motor) ► cricothyroid muscle only

2. Recurrent laryngeal nerve (RLN)

o RT side: crosses the subclavian artery

o LT side: arises on the arch of the aorta deep to ligamentum arteriosum (left is longer)

It is divided behind the cricothyroid joint

o Motor ► all the intrinsic muscles except the cricothyroid

o Sensory

SLN: sensation above the vocal cords, chocking means (they are working well, good sensation).

RLN: sensation of vocal cords and below. Left course is longer than the right course. However, vocal cord paralysis might be caused by: (thyroidectomy is the most common), brain tumor, vocal cord tumor, thyroid tumor, esophageal, mediastinal. tumors compressing the nerve, iatrogenic causes: cardiac thoracic surgery or idiopathic: waking up in the morning sounding weird.)

Most common is to have left vocal cord paralysis due to the long course of the left recurrent laryngeal nerve.

The neonates are obligate nasal breathers until 2 months

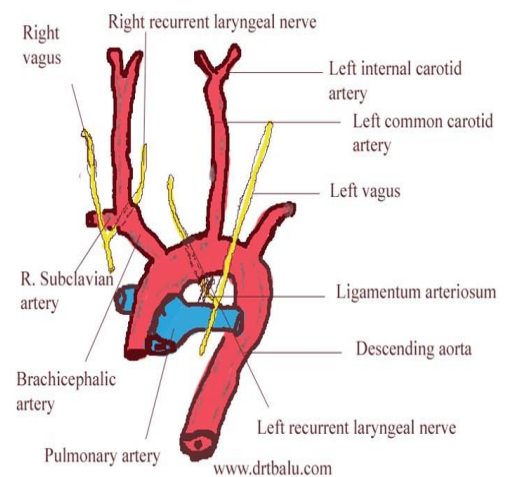
How to manage vocal cord paralysis? Wait for 6 months it might resolve by its own. If it didn't or the patient count on his voice for living, you interfere earlier. by injecting materials absorbable within six months to close the vocal cord temporary.

- Pediatric Airway Anatomy:

-- The neonates are obligate nasal breathers until 2 months. They can't breathe from their mouth first when they are born

-- The epiglottis at birth is omega Ω shaped

-- The infants have high larynx C1-C4



Applied Physiology of the Larynx

1. Protection of the lower air passages
2. Respiration
3. Phonation

1) Protection of the lower air passages:

- Closure of the laryngeal inlet
- Closure of the glottis
- Cessation of respiration
- Cough reflex (forced expiration is made against a closed larynx)
- Closure of the airways during swallowing the bolus.

Patient with CVA or neurological problem have loss of sensation so all the time they aspirate or choke.

2) Phonation:

- Voice is produced by vibration of the vocal cord
- Source of energy is the airflow (good lung → good voice)
- Normal vocal fold vibration occurs vertically from inferior to superior
- The mouth ,pharynx ,nose ,chest (are resonating chambers)

We talk during expiration (we take deep breath feel pressure in subglottic area this pressure help in pushing the air between the vocal cords and start vibrating them)

If I have bronchial asthma it means that the amount of air is little, I won't be able to talk for long time because the pressure was so little.

COPD , Smoker >> low air amount>> low vocal vibration>> dysphonia

430 Team:

- We speak at the end of expiration so that air comes out of the lungs, through the trachea, and into the larynx.
- The air makes the vocal folds vibrate. So we need normal mobile vocal cords and mucosa not thick secretions or masses or infections or allergic rhinitis closing the resonating chambers.
- When the vocal folds vibrate, they alternately trap air and release it. Each release sends a little puff of air into the pharynx; each puff of air is the beginning of a sound wave.
- The sound wave is enhanced as it travels through the pharynx; by the time it leaves the mouth, it sounds like a voice.
- The mouth, pharynx, nose, and chest which all should also be normal.
- Tongue is important for articulation of the voice.

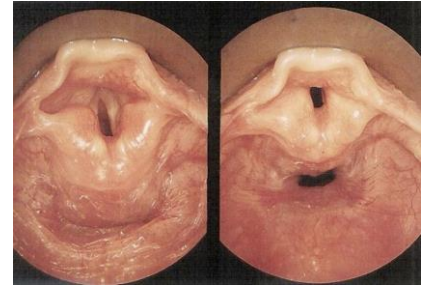
3) Respiration

Vocal cord in abduction position

Voice Mechanism

Speaking involves a voice mechanism that is composed of three subsystems:

- Air pressure system
- Vibratory system
- Resonating system



The “spoken word” result from three components of voice production: Voiced sound, resonance, and articulation

- Voiced sound: the basic sound produced by vocal fold vibration “buzzy sound”
- Resonance: voiced sound is amplified and modified by the vocal tract resonators (throat, mouth cavity, and nasal passages)
- Articulation: the vocal tract articulators (the tongue, soft palate, and lip) modify the voiced sound.

-- Vocal fold vibrate rapidly in sequence of vibratory cycles with a speed of about:

- 110 cycles per second (men)= lower pitch
- 180 to 220 cycles per second (women)=medium pitch
- 300 cycles per second (children)= higher pitch
- Louder voice: increase in amplitude of vocal fold vibration

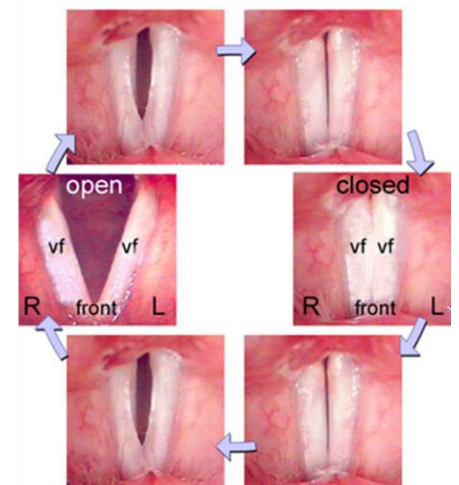
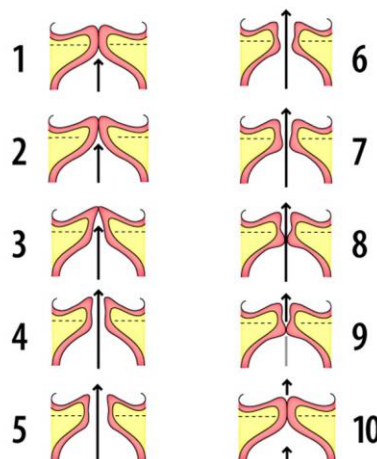
- Vocal cord vibration: **Bernoulli Effect**

Air comes from the lung opens the lower lip then the middle then the upper lip. Cannot be seen by direct visualization (very fast ~300 cycle). Can be seen by stroboscope.

- Laryngeal sphincters:

- True vocal cord
- false vocal cord
- Aryepiglottic sphincter

Aryepiglottic fold is between the epiglottis and arytenoid. If it is short then the epiglottis will always be covering the airway (air obstruction)



Evaluation of the Dysphonic Patient

History of Dysphonia (hoarseness):

Onset, duration, severity, URTI, fever, cough, voice abuse (job), tobacco or alcohol, dysphagia, aspiration, breathing difficulty (stridor), weight lost, GERD, trauma, previous surgery, neck mass, Laryngopharyngeal reflux (throat clearance) (Occupation and medication are important)

Examination

- Complete ENT examination
- Laryngeal examination and voice assessments:

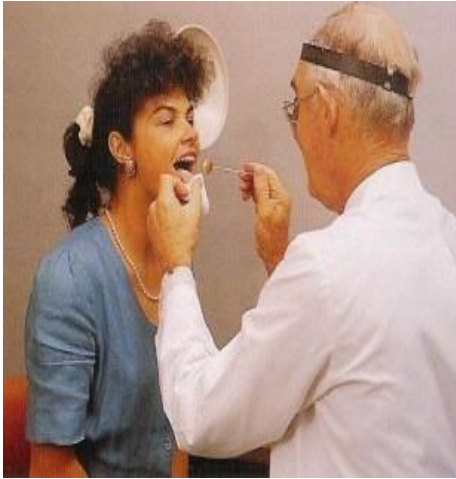Indirect laryngoscope (using mirror in old days) Direct laryngoscope

Fibreoptic flexible scope (MCQ: indications are examination of nose, nasopharynx) Stroboscopy (for vocal cord vibration assessment)

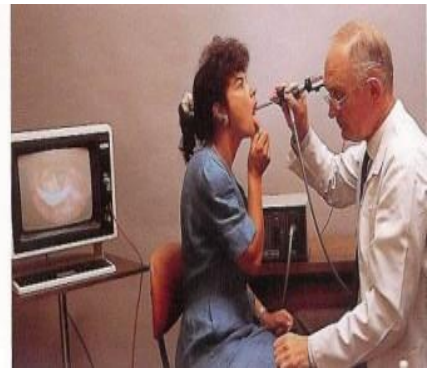
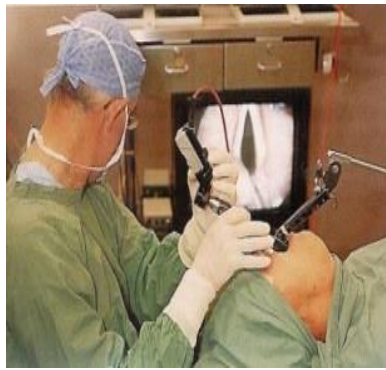Acoustic analysis

Cranial nerves (tumors might be compressing the involved nerves) Neck examination

You always have to examine the patient nose, throat and vocal cords and always mention in OSCE you need to examine the cranial nerves



Indirect Laryngoscope



Direct Laryngoscope

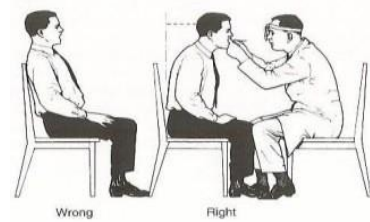
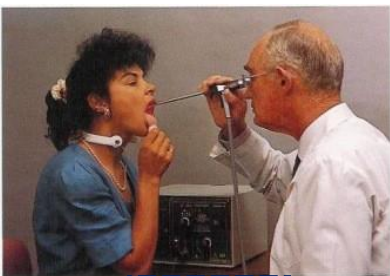
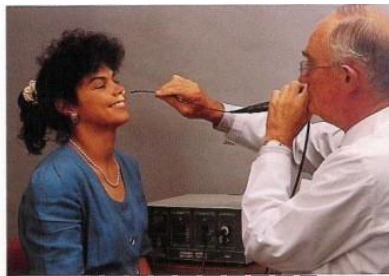


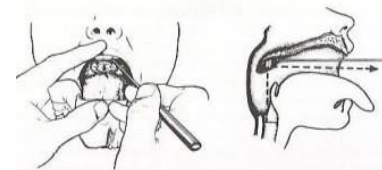
Figure 1.3 Position of the patient's head and neck for indirect laryngoscopy to create the best angle for a comprehensive view of the laryngeal structures.



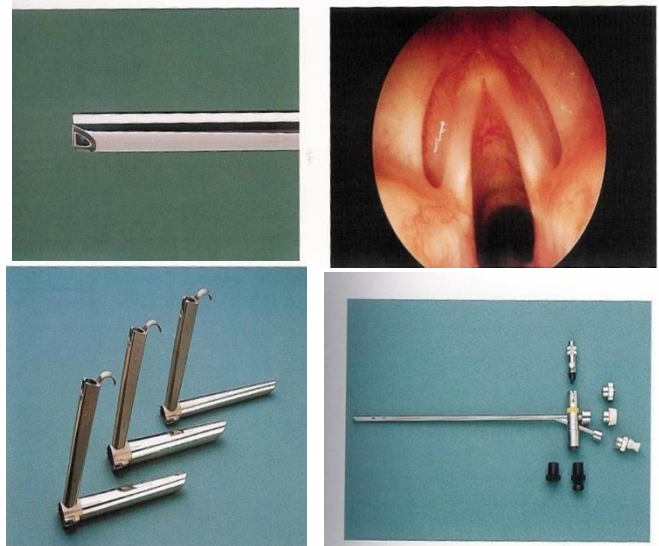
Rigid



Flexible



-Long-horn is called bronchoscopy
 Indications: foreign body removal, biopsy, washing trachea and visualization.
 -In the rigid nasopharyngoscope: Nose use the angle of (0-30) degrees.
 Looking down use (70-90) degrees for vocal cords



430 Team:

- In Exam: Mention 2 indications of the flexible fibre optic?
- Always: Children and Gag reflex (GERD)
- Nasal polyp surgery >> FESS
- Vocal Cord polyp nodule >> Microlaryngoscopy

Summary

- Dysphonia: is a descriptive medical term
Hoarseness: is a subjective term
- Thyroid cartilage: Shield like
Cricoid cartilage: Signet ring shaped, the only complete skeletal ring
Arytenoid cartilage: Pyramidal shaped
Epiglottic cartilage: Leaf like structure, elastic cartilage
- Glossoepiglottic fold: valleculae (Valleculae is the base of the tongue where the tongue is attached to the epiglottis)
- Recurrent laryngeal nerve supplies all the intrinsic muscles except the cricothyroid by superior laryngeal nerve
- The neonates are obligate nasal breathers until 2 months
- Vocal cords have 2 movements:
Adductors (4muscles) are used for speaking, Abductor (1muscle) used for breathing and located Posteriorly
- Cricoidthyroid is an adductor ms. but mainly it is responsible for the Vocal Cord tension of the vocal cords and supplied by the Superior Laryngeal Nerve.
- Cricothyroid membrane is important for emergency cricothyroidotomy

MCQs

1- A 5-year-old girl presented to pediatric hospital with biphasic stridor. Her mother mentioned that she was presented with the same condition 5 times. She was diagnosed to have croup.

What is the most likely cause of the recurrence?

- A- The treatment by steroids
- B- Bacterial infection
- C- Associated immune deficiency
- D- Underlying subglottic pathology

2- 30 years old lady underwent total thyroidectomy, after she woke up from the surgery and started to talk she noticed changing in her voice.

What is the most likely cause of her hoarseness?

- A- Infection
- B- Thyrotoxicosis
- C- Hypothyroidism
- D- Vocal cord paralysis

Answers:

- 1- D
- 2- D

Done By:

Othman Abid

