



433 Teams  
**ENT**

20

**Communication and Swallowing Disorders I**

Color index:

432 Team – **Important** – 433 Notes – Not important

ent433team@gmail.com



جامعة  
الملك سعود  
King Saud University



# Physiology of communication

## Language:

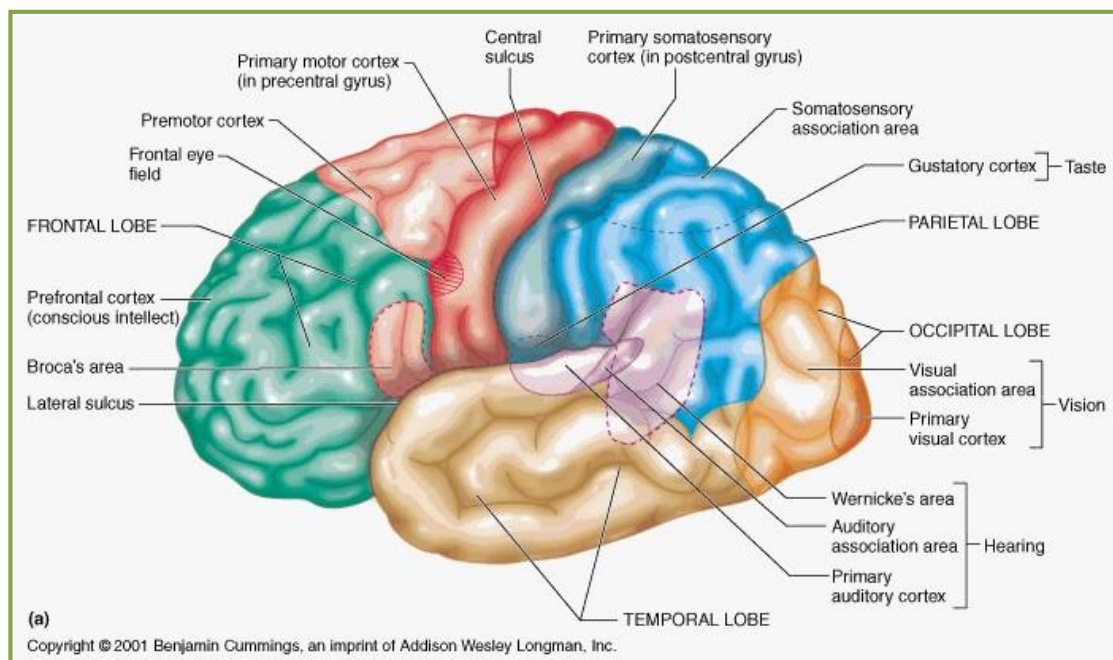
An arbitrary symbolic system relating sounds to meaning.

The major area of language comprehension called **Wernicke's** area. This area lies behind the primary auditory cortex in the posterior part of the superior gyrus of the temporal lobe. (problem will cause fluent aphasia but have no meaning)

The visual association area that feeds visual information conveyed by words read from a book into Wernicke's area is the language comprehension area "**angular gyrus area**", lying in the anterolateral region of the occipital lobe.

## Speech:

A neuro---muscular process whereby language is uttered. It includes the coordination of respiration, phonation, articulation, resonance and prosody. Broca's area (problem will cause expressive aphasia understand but can't express), located partly in the posterior lateral prefrontal cortex and partly in the premotor area, is responsible for expressing individual's words and short phrases. It works in association with Wernicke's area.



## Voice:

The result of vibration of the **true vocal folds** using the expired air.

- Voiced sound: The basic sound produced by vocal fold vibration is called “voiced sound.” This is frequently described as a “buzzy” sound. Voiced sound for singing differs significantly from voiced sound for speech.
- Resonance: Voice sound is amplified and modified by the vocal tract resonators (the throat, mouth cavity, and nasal passages). The resonators produce a person’s recognizable voice.
- Articulation: The vocal tract articulators (the tongue, soft palate, and lips) modify the voiced sound. The articulators produce recognizable words.

Subsystem	Voice Organs	Role in Sound Production
Air pressure system	Diaphragm, chest muscles, ribs, abdominal muscles, Lungs	Provides and regulates air pressure to cause vocal folds to vibrate
Vibratory system	Voice box (larynx)Vocal folds	Vocal folds vibrate, changing air pressure to sound waves producing “voiced sound,” frequently described as a “buzzy sound” Varies pitch of sound
Resonating system	Vocal tract: throat (pharynx), oral cavity, nasal passages	Changes the “buzzy sound” into a person’s recognizable voice

-- **Three voice subsystems:**

## Swallowing:

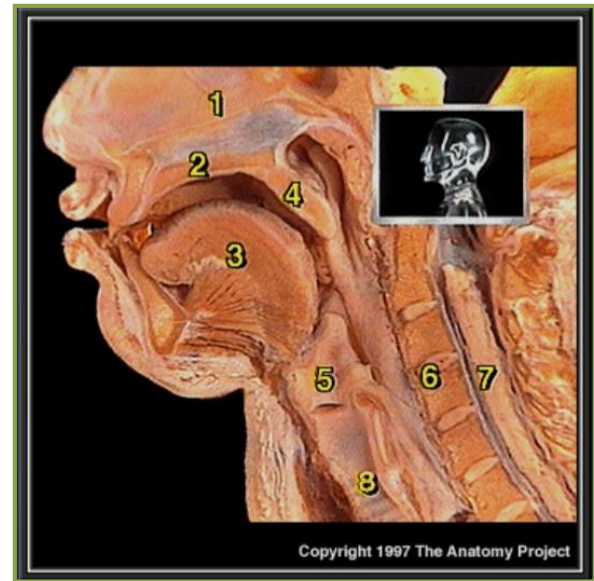
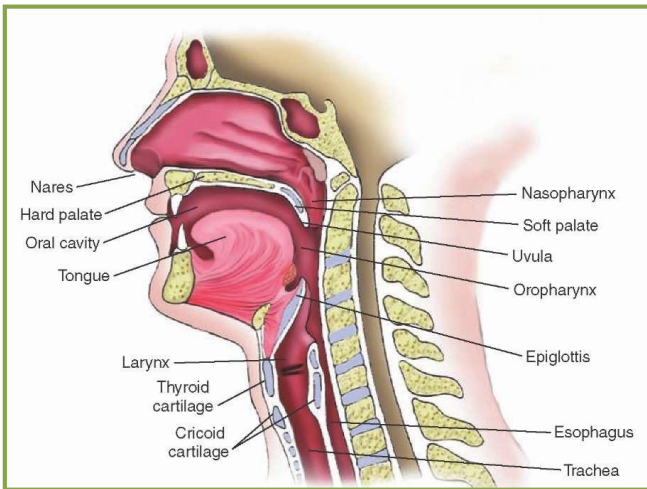
The process of successful passage of food and drinks from the mouth through pharynx and esophagus into the stomach.

**Check out this two-minute video:**

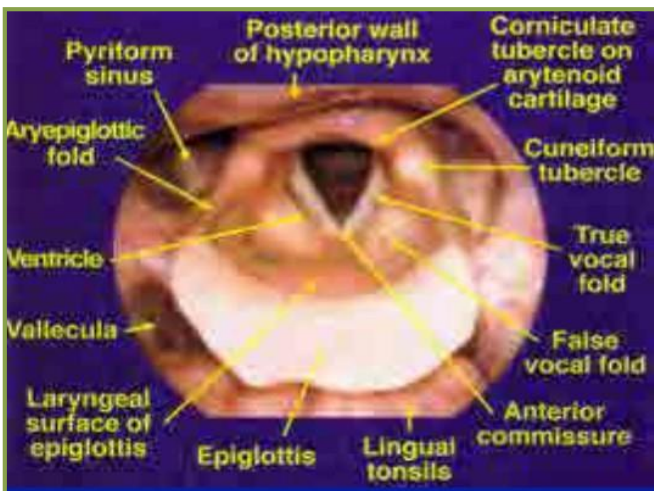
<https://www.youtube.com/watch?v=wqMCzuliPaM>

- Voice “phonation” is produced by the vibration of the true vocal folds not the cords.
- The vocal cords meet anteriorly at the anterior commissure.
- The vocal cords abduct during breathing and adduct during phonation “open vocal cords during speaking = whispering”.
- Male vocal folds vibrate 100-120 times per seconds, and female vocal folds’ vibration rate is 200 times per seconds.

# Voice Disorders

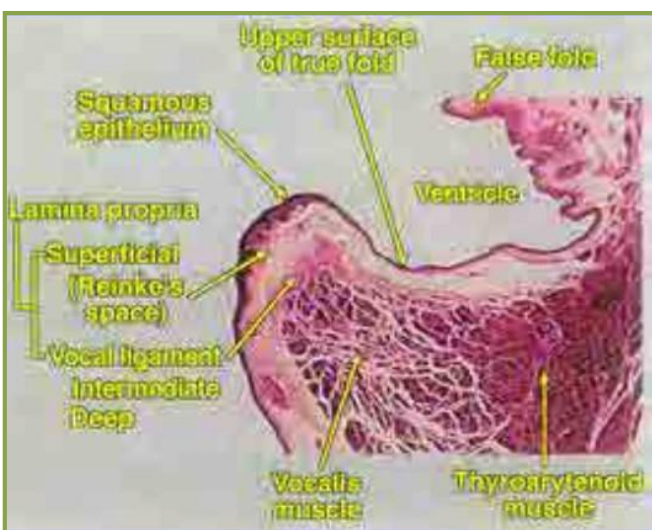


1. Nose, 2. Hard palate, 3. Tongue, 4. Soft palate, 5. Larynx, 6. Vertebral column, 7. Spinal cord, 8. Trachea



**-IMP PICTURE (430 note):** to decide the side of any part of the larynx lesion (eg: vocal cord lesions ) whether it's right or left side lesion(consider the land mark anteriorly is

: anterior commissure and epiglottis and **your posterior land mark is** : arytenoid cartilage and hypopharynx ) because in the EXAM some picture will be inverted , so it's very important to know the correct site of the lesion



**Cross section of the vocal cords which contains:**

**Mucosa:**

1-Squamous epithelium

2-lamina propria which contains: - the superficial layer - the intermediate and deep layers which form the vocal ligament

## Prerequisites of “normal” voice production:

1. Normal range of movement of vocal folds.
2. Normal mobility of mucosa on deep layers.
3. Optimal coaptation of vocal folds' edges.
4. Optimal motor force.
5. Optimal pulmonary support.
6. Optimal timing between vocal fold closure and pulmonary exhalation.
7. Optimal tuning of vocal fold musculature (int. and ext.).

## Definition of Dysphonia:

--- “Difficulty in phonation”.

--- “Change of voice from his/her habitual”.

--- “Hoarseness = roughness and harshness of voice”.

## Etiological classification of dysphonia:

### **A. Organic causes:**

- Congenital
- Inflammatory
- Traumatic
- Neurological
- Neoplastic
- Hormonal
- Status post---laryngectomy

### **B. Non-organic causes:**

- Habitual:
  1. Hyperfunctional childhood dysphonia
  2. Incomplete mutation
  3. Phonasthenia (Voice fatigue)
  4. Hyperfunctional dysphonia



5. Hypofunctional dysphonia
6. Ventricular dysphonia

- Psychogenic:

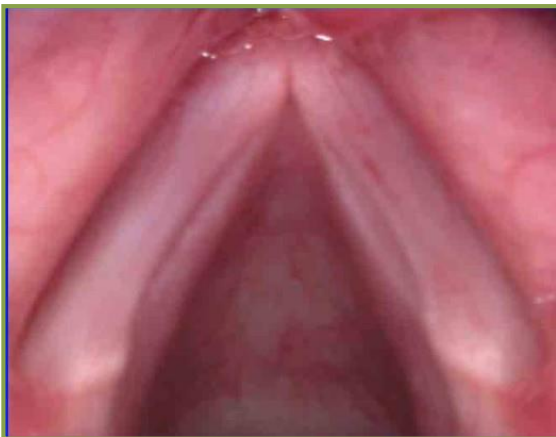1. Psychogenic dysphonia
2. Psychogenic aphonia

### **C. Benign vocal fold lesions:**

1. Vocal fold nodules
2. Vocal fold polyps
3. Vocal fold cysts
4. Reinke's edema
5. Contact granuloma

### **D. Accompaniment of neuro---psychiatric ailments**

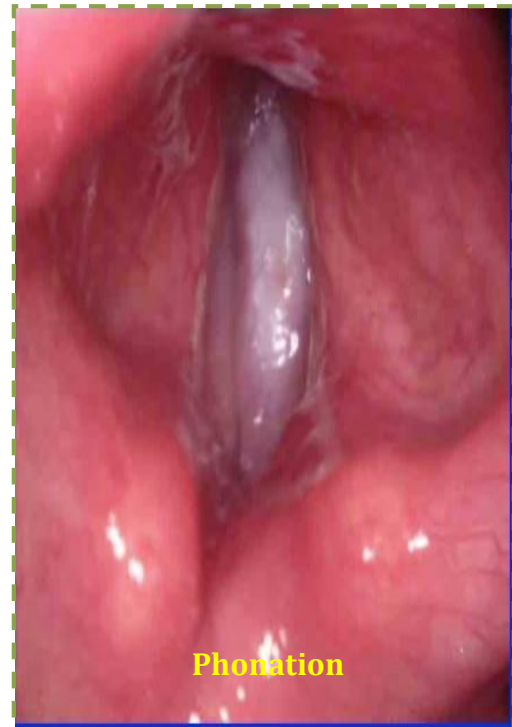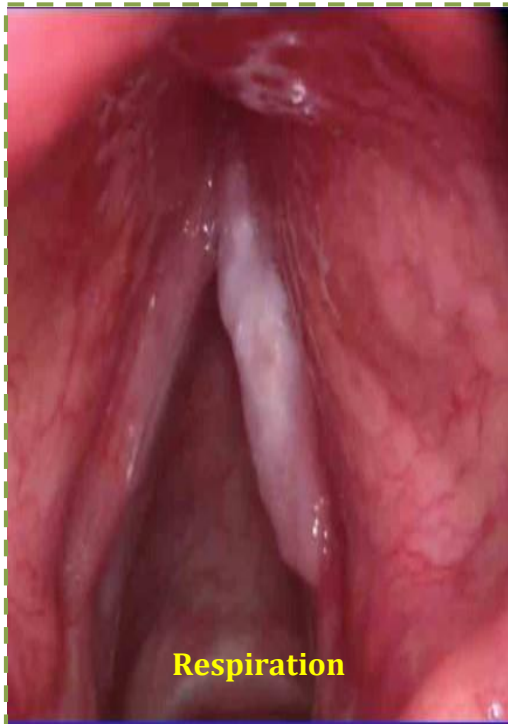#### **1-Sulcus vocalis (Congintal)**



Difficult case with difficult management, mostly no one will ask about it. T: Surgery P: Sever dysphonia

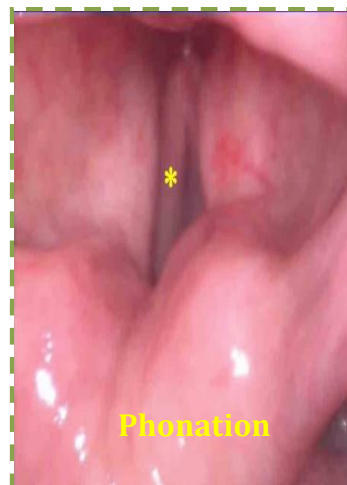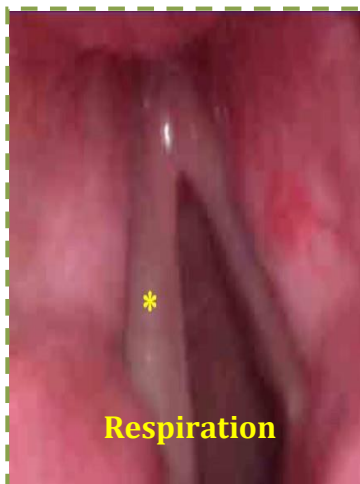P: presentation, T: treatment.

## 2-Laryngeal Carcinoma



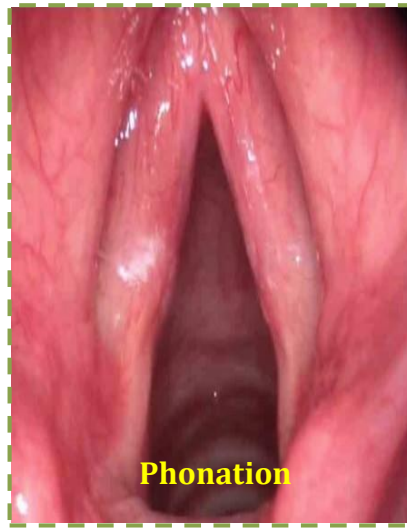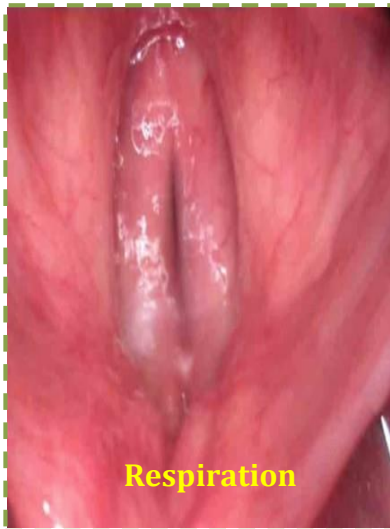--- Any ugly looking whitish mass on the vocal folds in smoker = think about cancer. P: dysphonia, T: surgical  
 --- Whitish layer over the vocal folds (leukoplakia) could be metaplasia.

## 3-Left vocal cord paralysis



dysfunction of recurrent laryngeal /vagus nerve. It causes a characteristic breathy sound, swallowing disability, weak cough, and sensation of shortness of breath. P: dysphonia, aspiration. T: medicalization

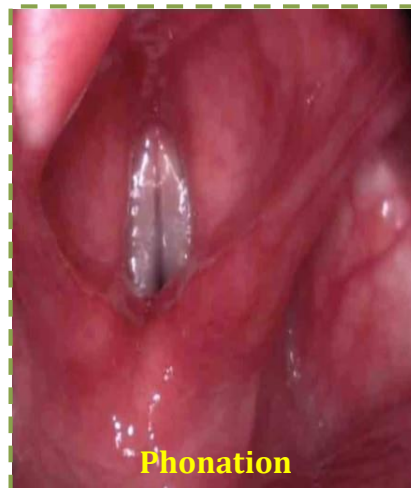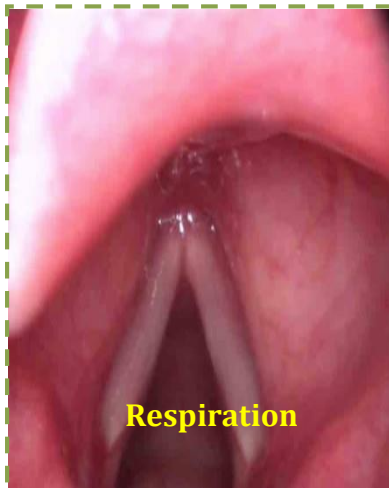#### 4-Hyperfunctional dysphonia



Hyperfunctional childhood dysphonia = muscle tension dysphonia.

Incomplete adduction gap (phonatory gap) sign of exhausted muscle Voice thereby

#### 5-Phonasthenia

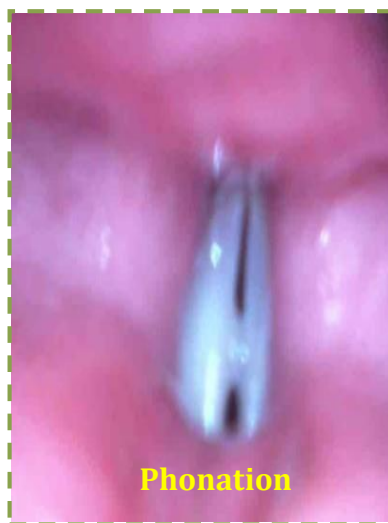
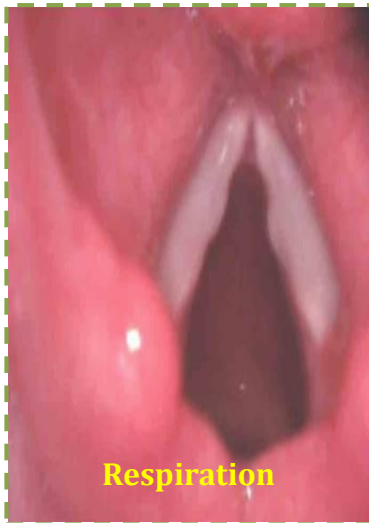
Phonasthenia is the most common one, could be due to voice problem or reflux. Treated by voice therapy. With voice fatigue. also phonatory gap . T: voice thereby



## Benign vocal folds' lesions:

### 1. Vocal fold nodules: Adult type (usually bilateral + affecting females)



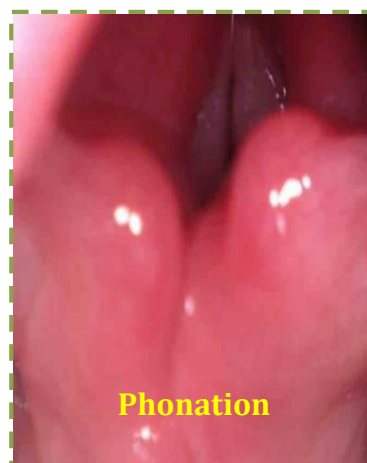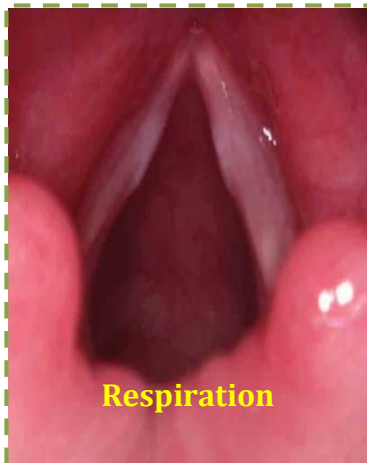**Bilateral** nearly small symmetrical lesions at the junction of anterior and **middle two-thirds** of membranous vocal folds. P: dysphonia

--- **Causes:** vocal misuse and abuse, and chronic repetitive phonotrauma.

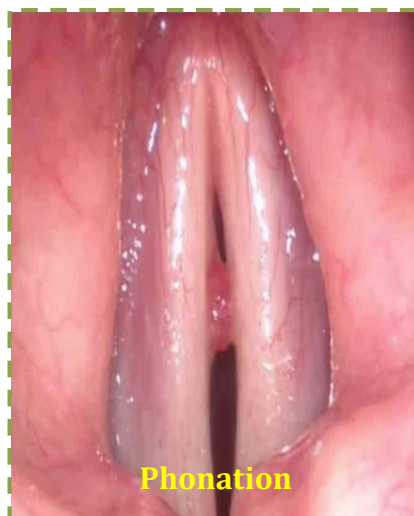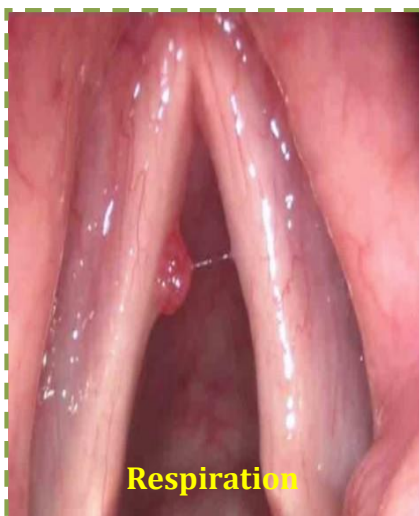--- **Treatment:** **voice therapy** , **voice arrest** .with vocal hygiene advice)

Surgery (rarely!) is indicated if case of asymmetrical lesions, fibrotic lesions, or failed

### Vocal fold nodules: Juvenile type (softer)



### 2. Left vocal fold polyp with a reaction

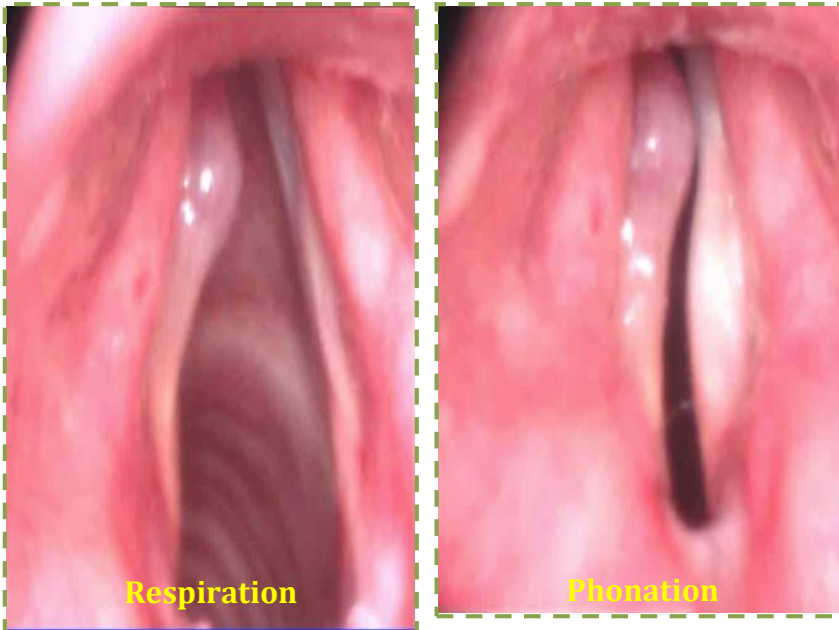


**Etiology:** by acute phonotrauma.

**Describe:** usually **Unilateral**  
Can be bilateral and nearly in the same area with **well-defined edges**

--- Red polyp = hemorrhagic wait and reevaluate

### 3. Left vocal fold cyst



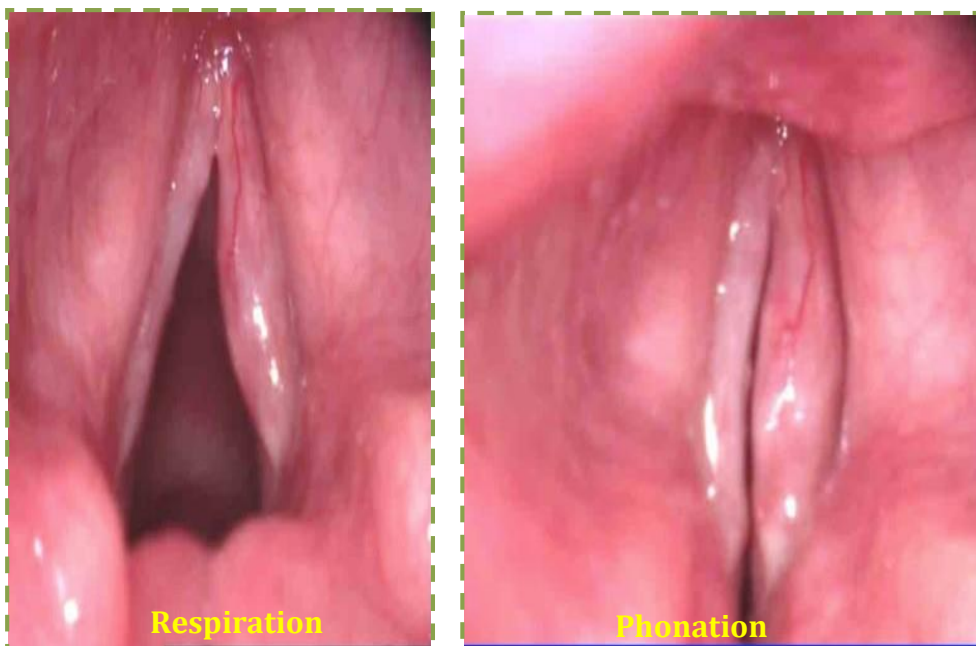
**D: Localized intra-foldal lesion**

**Etiology** : phonotrauma and could be congenital.

The mucosal waves on digital laryngostroboscopy are missed because they can't cross the dense mass.

**Treatment**: surgical excision followed by post-op voice therapy with voice hygiene advice.

### 4. Right-sided Reinke's edema



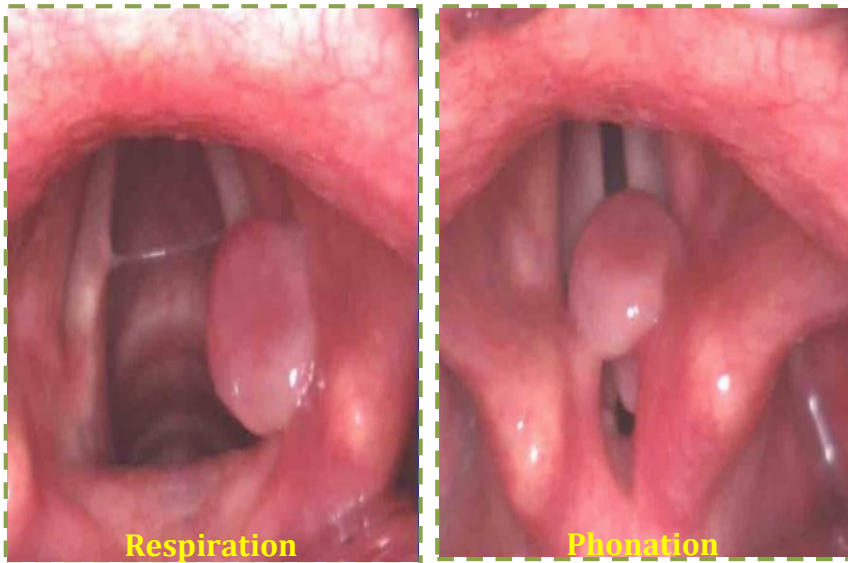
-- D: bilateral Reinke's edema is usually bilateral and could be unilateral.

-- Etiology : phonotrauma, smoking and reflux (GERD).

- It is common among middle-aged smoker active women.

-- Treated: smoking cessation, reflux medications and surgery.

## 5. Right-sided contact granuloma (This is the description + location)



**D: Contact granuloma grows on the posterior glottis. Etiology**

**: intubation – phonotrauma --- severe laryngopharyngeal reflux.**

Treat: the cause, and avoid surgery because of risk of recurrence, unless the lesion was big enough to obstruct the airway.

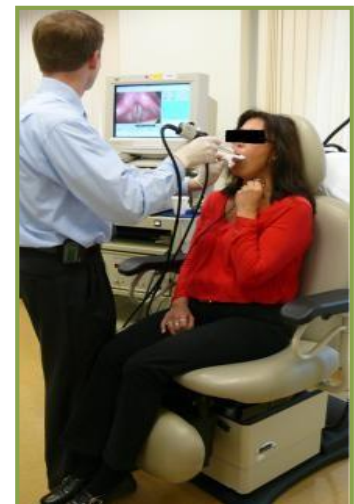
### Assessment of dysphonia:

#### I. History taking

#### II. Physical examination: APA “Auditory Perceptual Assessment”.

#### III. Investigations:

- Audio recording
- **Digital laryngostroboscopy**
- Digital laryngokymography
- Acoustic analysis (MDVP)
- Aerodynamic analysis (Aerophone II)
- GERD (LPR) work---up
- CT neck



### APA of Voice Disorders

- |   | 0        | 1                 | 2                          | 3                |
|---|----------|-------------------|----------------------------|------------------|
|   | (normal) | (mild)            | (moderate)                 | (severe)         |
| - Dysphonia grade (G) :                                   |          |                   |                            |                  |
| - Character :   |          | <b>S</b> Strained | <b>L</b> Leaky             | <b>B</b> Breathy |
|   |          |                   | <b>I</b> Irregular (rough) |                  |
| - Pitch : ( increased / decreased / diplophonia).         |          |                   |                            |                  |
| - Register : Habitual register: modal/ falsetto.          |          |                   |                            |                  |
|   |          |                   | vocal fry ( Y / N )        |                  |
|   |          |                   | Register breaks ( Y / N ). |                  |
| - Loudness: ( excessive – soft – fluctuating )            |          |                   |                            |                  |
| - Glottal attack: ( normal – soft – hard ).               |          |                   |                            |                  |
| - Associated laryngeal function (cough/laughter/whisper). |          |                   |                            |                  |

Stroboscopy is a special method used to visualize vocal fold vibration. It uses a synchronized, flashing light passed through a flexible or rigid telescope. The flashes of light from the stroboscope are synchronized to the vocal fold vibration at a slightly slower speed, allowing the examiner to observe vocal fold vibration during sound production in what appears to be slow motion <sup>(4)</sup>.

## Management of voice disorders:

1. Pharmacological agents “given to treat GERD”
  2. Surgical procedures (Phonosurgery)
  3. Technical aid devices
  4. Voice therapy
- Dysaudia : change in the singing voice-

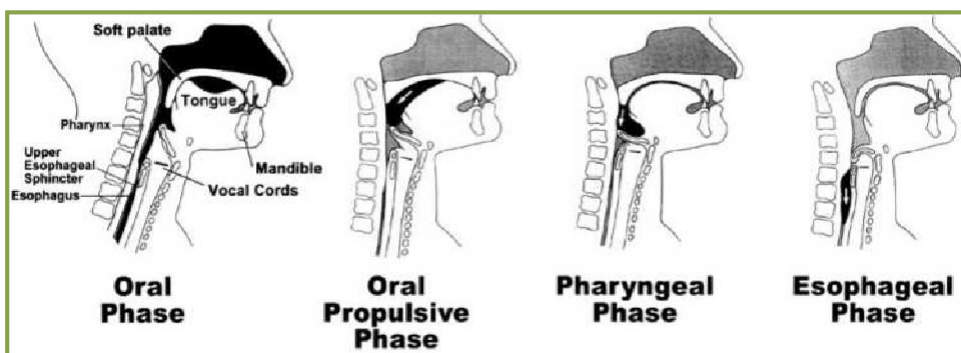
GERD can cause cough, dryness, swallowing problems, and choking.

--- It has a variant called “laryngopharyngeal reflux disease”.

--- The patient should avoid coffee, tea, soft drinks, ginger, lemon and

## Swallowing Disorders

### Phases of normal swallowing:



-- Normal swallowing rate per day = **2000-2500**.

--- The oral preparation phase and oral propulsive phase are **voluntary**, and the rest are **involuntary**.

--- **Most of swallowing problems are in the pharyngeal phase.**

### Definitions:

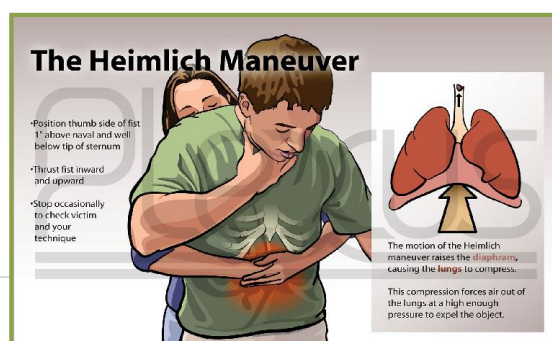--- **Swallowing**: is the successful passage of food and drinks from the mouth to the stomach.

--- **Dysphagia**: pain, discomfort, and/or difficulty in initiating or completing the act of swallowing.

### Consequences of dysphagia:

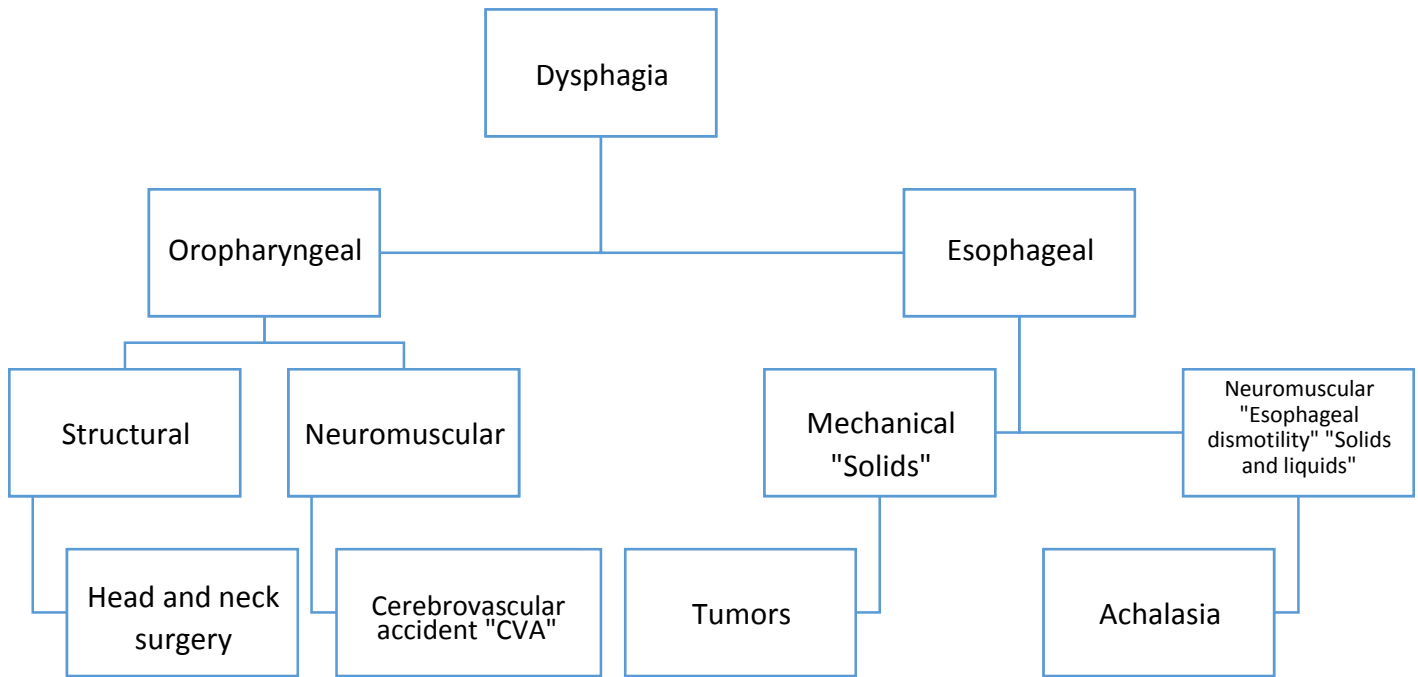
1. Dehydration
2. Weight loss
3. Aspiration pneumonia
4. Airway obstruction
5. Loss of joy of food

--- The best way to manage airway obstruction is **Heimlich maneuver**.





## Causes of dysphagia:



## Assessment of dysphagia:

I. History taking

II. Physical examination:

- General examination
- Language and speech assessment
- Vocal tract examination
- Neck examination
- Trial feeding

III. Investigations:

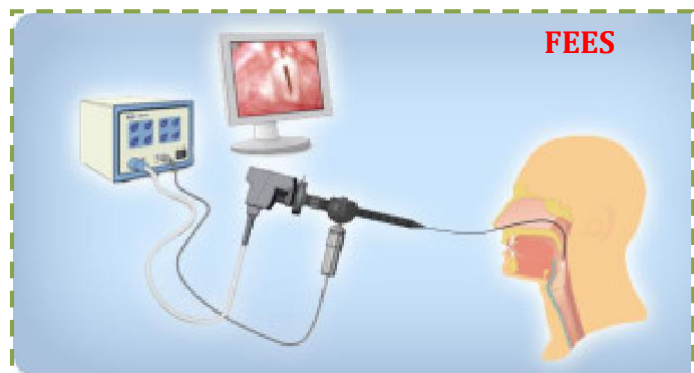- **FEES "Fiberoptic endoscopic evaluation of swallowing"**
- **VFES (MBS) "Video fluoroscopic swallowing exam"**  
(Modified barium swallow)

--- GERD (LPR) work-up

**FEES protocol of evaluation**

**(Langmore, 2003):**

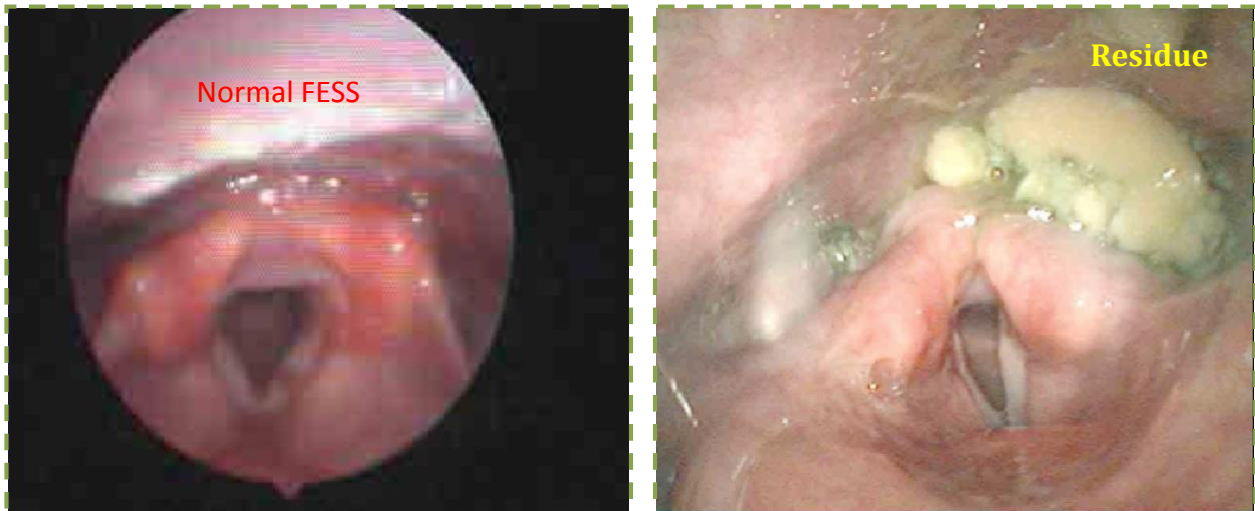
- Anatomic and physiologic assessment.
- Assessment of food and liquid swallowing.
- Assessment of therapeutic interventions.





During FEES, we give the patient colored fluid, colored solid and semi solid food and visualize the pharynx during swallowing. **There are two positions: near and away from the vocal folds.**

FEES can be done anywhere, can be done for pregnant women and patients with neck injuries and there is no risk of radiation.



- The pharynx squeezes to get rid of food remnants.
- When we evaluate the swallowing in any patient and we heard a wet voice after the patient drank water = **this is a sign of aspiration.**
- Weakness in the mouth (or the tongue) **could cause pre-swallowing aspiration.**
- Whenever there is no good closure during swallowing, there will be a risk of aspiration during swallowing.
- Post-swallowing aspiration caused by post-swallowing residue.
- **We can assess the oral phase (or esophageal phase) of swallowing using VFES.**
  - **The most common view is lateral.** Used to assess aspiration of small amounts of food.
  - **Disadvantages:** exposure to radiation and should be done in the radiology department.
  - To see the exam: <https://www.youtube.com/watch?v=sM6uxd1uS6M>

### Management of dysphagia:

1. Oral vs. Nonoral feeding: Nonoral feeding when:
  - Aspiration > 10%
  - Oral and pharyngeal transit time > 10 seconds
2. Direct vs. Indirect therapy:
  - Direct: food or liquid is given to the patient
  - Indirect: no food or liquid is given (only saliva)
3. Compensatory vs. Therapy techniques:

--- Compensatory: elimination of symptoms but no change in swallowing physiology, such as **postural techniques**. “like head extension, chin flexion, and head rotation”

--- Therapy techniques: change of swallowing physiology, such as **swallowing maneuvers**. “like supraglottic maneuver = ask the patient to take a deep breath and hold it, then try to swallow and then immediately cough after swallowing”

**Swallowing therapy:**

1. Diet modification
2. Postural techniques
3. Swallowing maneuvers
4. Sensory enhancement techniques
5. Motor exercises

**Surgical treatment:** e.g.

Medialization laryngoplasty.

**Intraoral prosthesis**

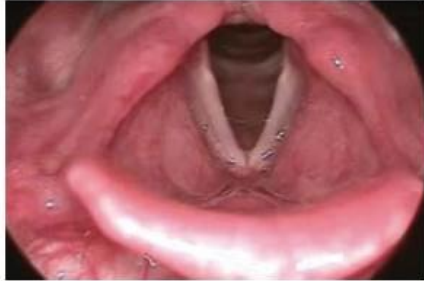**Alternative routes of feeding:** e.g. nasogastric “NG” tube.

--- Patients of CVA or RTA with silent aspiration initially cough many times during eating or drinking, then the cough will disappear and there will be recurrent pneumonitis. “stop oral feeding (NPO + NG tube)”

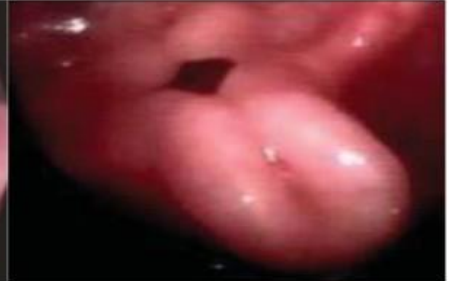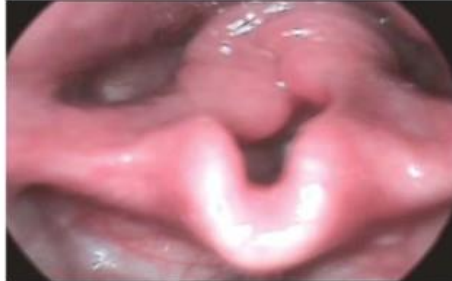--- After one month of using NG tube, switch to per cutaneous endoscopic gastrostomy

## From 430 but the doctor did not mention it

All of the following pictures regarding organic voice disorders are possible exam questions IMP :



Normal larynx



**Description:** Omega shape epiglottis whenever you see it's most likely Laryngomalacia

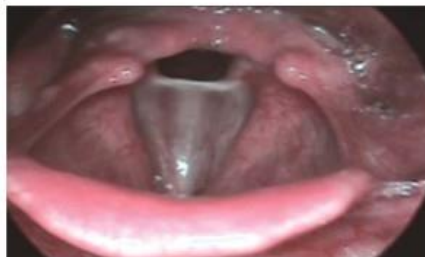It's common in children 1-2 years old

**The common presentation:** it is not a dysphonia, it's breathing problem, especially when he is laughing or playing, he can get a noisy breathing (stridor) due to collapse epiglottis over the arytenoid cartilage

**Treatment:**

Depends on the degree

**Mild case:** observation and tell the family that this condition it's self-limiting  
But in severe cases :where it's interfere with respiration we do surgery



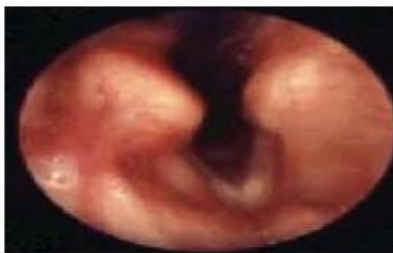**Description:** Congenital vocal folds web

The history is about 18 years old patient, he diagnosed late because he did not complain from breathing problem

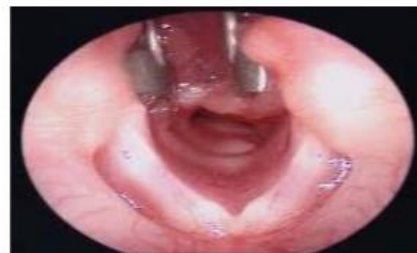**Common presentation:** The symptoms depends on the stages of the web, eg: when the web extend posteriorly, it will obstruct the air way and the patient will suffer from breathing related problems and he will be presented early.

**Treatment:**

Surgical excision but I have to be aware from post surgical atresia (eg: After the incision in approximately two weeks, there will be adhesion or synchea between the vocal cords when they are closed to each other, so I have to put some thing between them to prevent the adhesion. (I could not hear what is the name of the thing that they put it between the vocal cords ?)



This is Severe type when the cleft extend deep to the trachea



Type I in the arytenoid clefting

**Description:** laryngeal cleft or laryngotracheoesophageal cleft is a rare congenital abnormality in the posterior laryngo-tracheal wall. It means there is a gap between the oesophagus and trachea, which allows food or fluid to pass into the airway.

**Types:** Type I extends no further down than the vocal cords, type II extends below the vocal cords and into the cricoid cartilage, type III extends into the cervical section of the trachea and type IV extends the furthest—into the thoracic section of the trachea

**Management:** Surgery



**Description:** Fungal infection (Inflammatory)

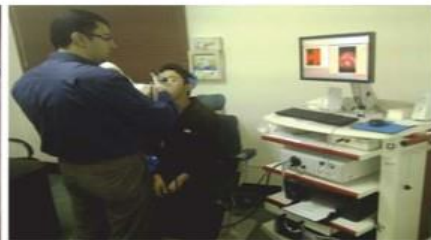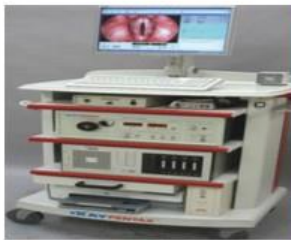**Presentation:** Imp finding is a history of immune compromised patient(diabetic patient or patient in immune suppressive drugs)

**Treatment:**Antifungal drugs

**Laryngopharyngeal Reflux (Inflammatory) :**  
Notice that You will see congestion

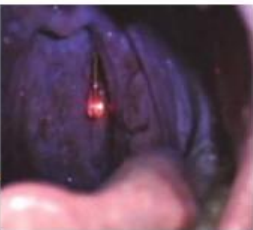
Respiration                      Phonation

- The History will help you to know the finding .
- In this case there is history of Swelling of the left side of the neck after 3 days from aspiration and choking during eating.
- **Finding:** There is Bone of chicken in pyriform sinus (notice that this is the first area that you have to look for in case of suspicion of foreign body ) !!



Video stroboscopy with Rigid or fixable Laryngoscopy

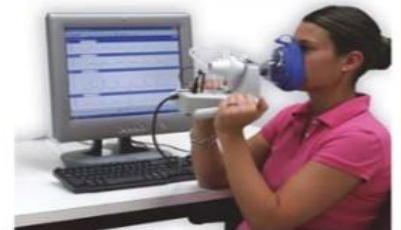High speed laryngeal imaging



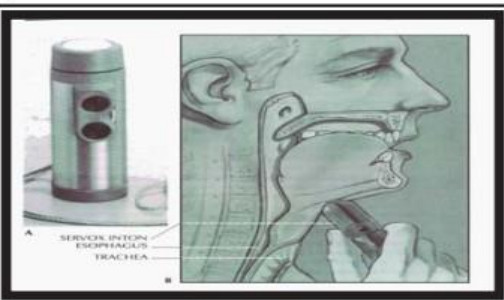
Pharyngeal pH Monitoring For GERD , A Device fixed in the oropharynx and sense the PH of reflux



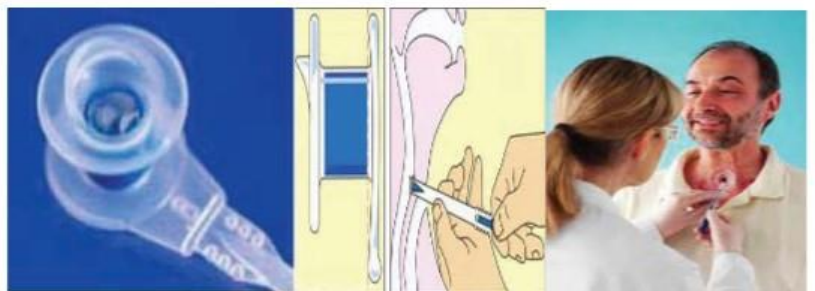Computerized speech lab. (CSL) For Voice analysis



Phonatory Aerodynamic System (PAS) Assess the phonatory air flow During (phonation and vibration )



Artificial larynx in patient who got total laryngectomy , can induce mechanical voice But most of patient do not like it



Tracheo-esophageal puncture , it is The most common procedure done for the patient who undergoes laryngectomy , an instrument is introduced in trachea and through the air entry into trachea , the phonation will occur

# Summary

Etiological classification of dysphonia: A: Organic causes:

- Congenital
- Inflammatory
- Traumatic
- Neurological
- Neoplastic
- Hormonal
- Status post---laryngectomy

B. Non-organic causes:

- Habitual:
  1. Hyperfunctional childhood dysphonia
  2. Incomplete mutation
  3. Phonasthenia (Voice fatigue)
  4. Hyperfunctional dysphonia
  5. Hypofunctional dysphonia
  6. Ventricular dysphonia

- Psychogenic:

1. Psychogenic dysphonia
2. Psychogenic aphonia

C. Benign vocal fold lesions:

1. Vocal fold nodules
2. Vocal fold polyps
3. Vocal fold cysts
4. Reinke's edema
5. Contact granuloma

D. Accompaniment of neuro---psychiatric ailments



## MCQs

**1 – Risk factor of Reinke’s edema:**

- A – Smoking
- B – Old age
- C – Alcohol
- D – infection

**2 – 24 years old female, presenting with dysphonia for the last 3 months. Laryngoscope showed Bilateral ,symmetrical lesions at the junction of anterior and middle two-thirds of membranous vocal folds. Most likely diagnosis is:**

- A – Vocal fold polyp
- B – Vocal fold cyst
- C – Vocal fold nodules
- D – Cancer of Vocal fold

Answers:

- 1- A
- 2- C

# Done By:

Othman Abid
Abdulaziz Alshalan

