



433 Teams  
**ENT**

6

# Vertigo

Color index:

432 Team – **Important** – 433 Notes – Not important

ent433team@gmail.com

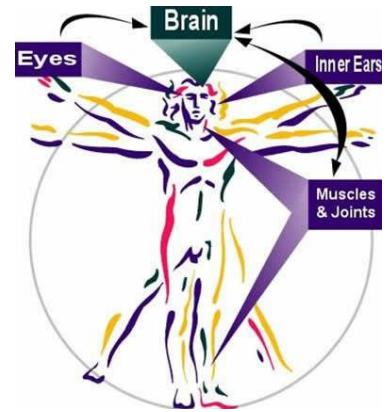


## Objectives:

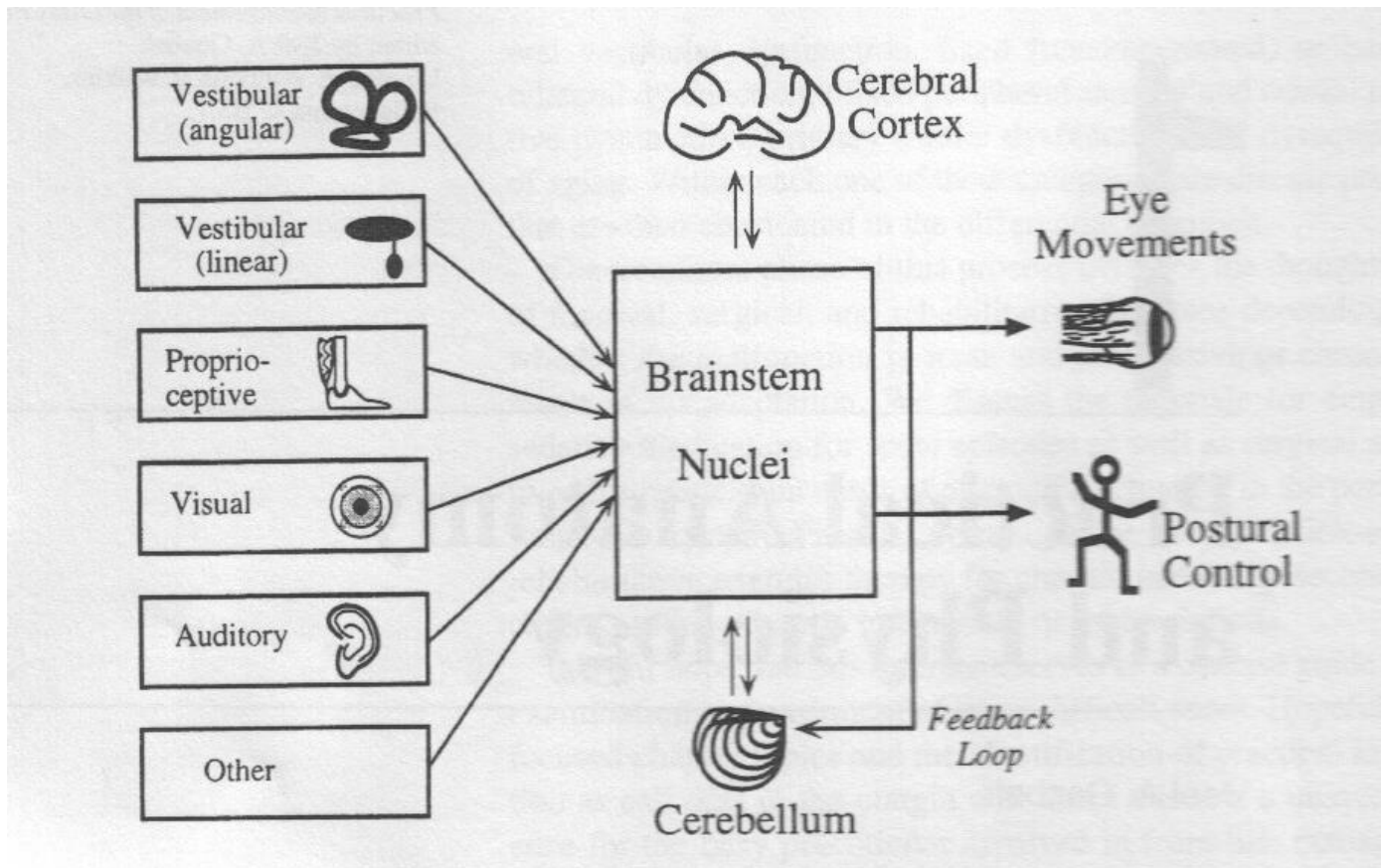
- To know anatomy of balance organs.
  - Physiology of balance.
  - Relevant history in dizzy patients.
  - Classification of vertigo.
  - Common peripheral causes of vertigo, clinical features, investigation and management.
    - Common central causes of vertigo, clinical features, investigation and management
- Vertigo Central Peripheral  
Meniere's disease BPPV Vestibular neuritis CVA Acoustic  
Neuroma Multiple Sclerosis Migraine.

## How does balance system work?

- Inner ear (3 semicircular canals and otolith organ)
- Cerebellum • Vision (VOR)
- Proprioceptive



## What are the components of balance system?



## Physiology:

Function of vestibular system: Transform of the forces associate with head acceleration and gravity into biological signals that the brain can use to develop:

- Subjective awareness of head position in space (orientation)
- Produce motor reflexes that will maintain posture and ocular stability keep the eye focused on the object of interest.

## Vertigo:

- The word "vertigo" comes from the Latin "vertere", to turn + the suffix "-igo", a condition = a condition of turning about.
- It is an illusion of being moving or the world is moving too.

What are the questions to ask in history? (**History is the most important key to diagnosis for a dizzy patient**)

- Frequency: -Recurrent - Non -Recurrent
- Duration - Seconds - Minutes - Hours to days
- Associated auditory symptoms: Tinnitus -Deafness -Fullness
- Aggravating and relieving factors: Rolling over in bed, Getting up from bed, Looking up, Consume salty food.
- Ear disease or ear surgery
- Trauma
- Migraine
- Ototoxic drug intake

Symptoms	Peripheral	Central
Imbalance	Moderate-severe	Mild-moderate
Nausea and vomiting	Severe	Variable
Auditory symptoms	Common	Rare
Neurologic symptoms	Rare	Common
Compensation	Rapid	Slow
Nystagmus	Unidirectional Horizontal or rotatory	Bidirectional Horizontal or vertical

## Peripheral vestibular loss:

### 1- Vestibular neuritis:

Mostly preceded by Viral infection of vestibular organ (Measels, mumps, herpes zoster) Or URTI.

- Affect all ages but **rare** in children.
- Affected patient presents acutely with spontaneous nystagmus, vertigo and nausea & vomiting and imbalance **WITHOUT** hearing loss that resolves over days leaving the residual imbalance that last days to weeks.
- It takes 3 weeks to recover from vestibular neuritis.

### Clinical Features:

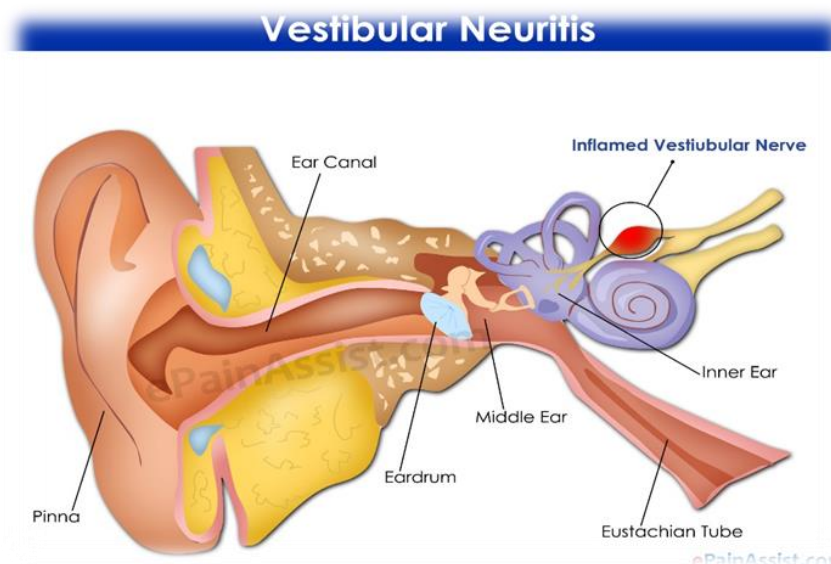
- **Acute phase:** severe vertigo with nausea, vomiting, and imbalance lasting 1 to 5 d Irritative nystagmus (fast phase towards the offending ear) Patient tends to veer towards affected side
- **Convalescent phase:** imbalance and motion sickness lasting days to weeks Spontaneous nystagmus away from affected side gradual vestibular adaptation requires weeks to months.

### Treatment:

**The patient requires only symptomatic treatment.**

Patient requires only symptomatic treatment -Acute phase: bed rest, vestibular sedatives (Gravol®), and diazepam.

- Convalescent phase: progressive ambulation especially in the elderly, vestibular exercise: (involve eye and head movements, sitting, standing, and walking)



## 2- BPPV (benign paroxysmal positional vertigo):

### Etiology:

- Due to canalithiasis (migration of free floating otoliths within the endolymph of the semicircular canal) or cupulolithiasis (otolith attached to the cupula of the semicircular canal) can affect each of the 3 semicircular canals, although the posterior canal is affected in >90%.

- **The most common cause of vertigo in patient > 40 years.**

- Repeated attacks of vertigo usually of short duration less than a minute.

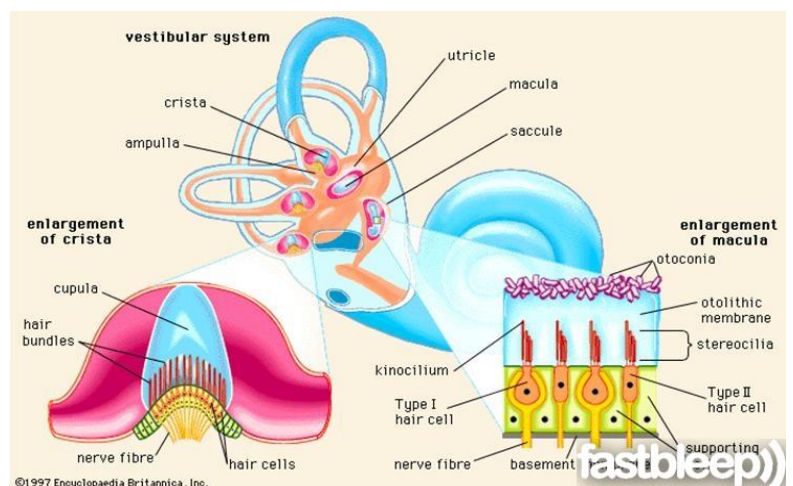
- **Provoked by certain positions** (rolling in beds, looking up, and head rotations).

- **Not** associated with any hearing impairment.

### Diagnosis:

#### - History:

- **Dix-Hallpike maneuver**



Five Signs of BPPV Seen with DixHallpike Maneuver:

- Geotropic rotatory nystagmus (**nystagmus MUST be present for a positive test**).

- Fatigues with repeated maneuver and fixation.

- Reversal of nystagmus upon sitting up.

- Latency of ~20 s • Crescendo/decrecendo vertigo lasting 20 s.

### Treatment:

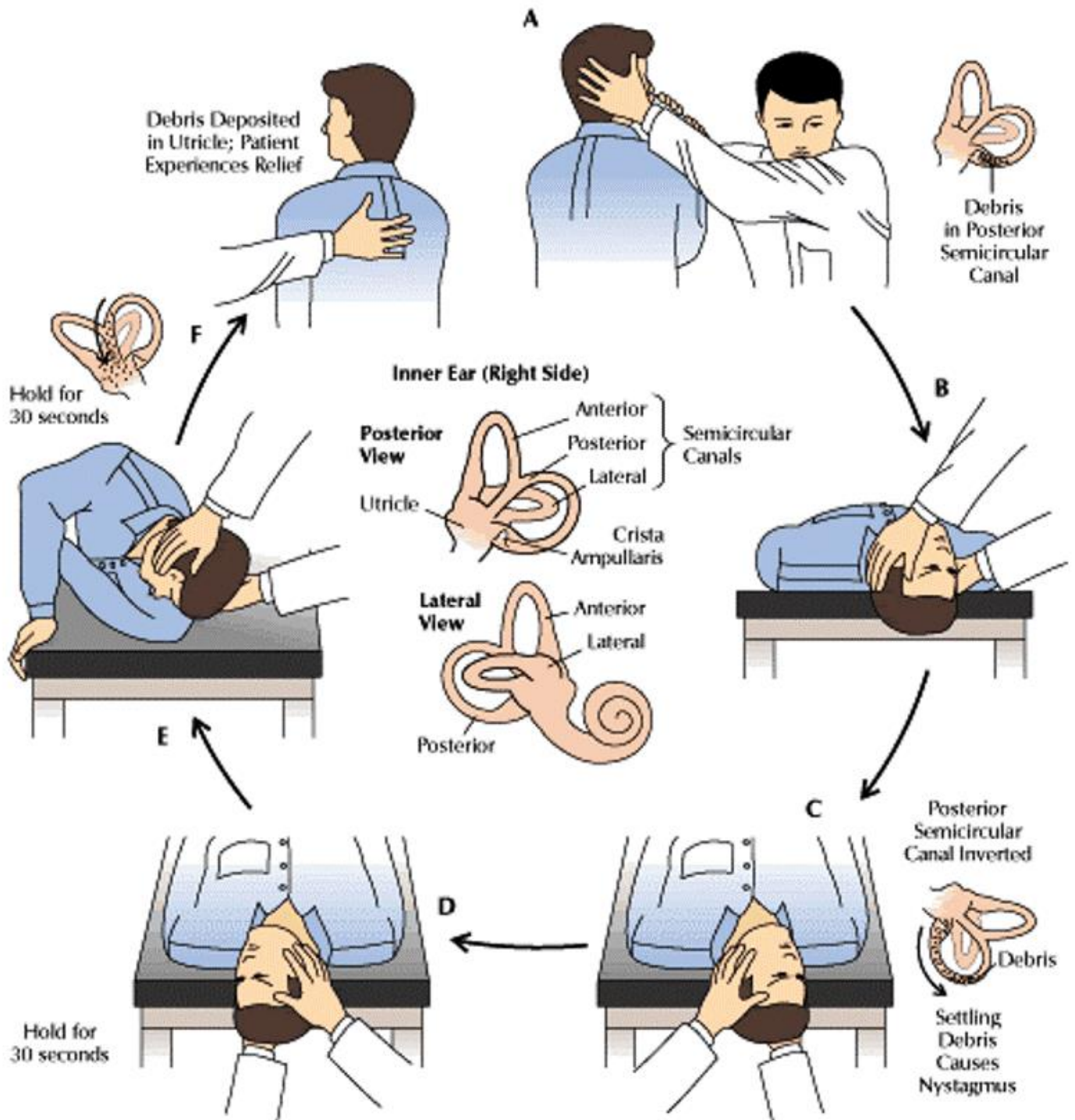
- Anti-emetics for nausea/vomiting.

Particle repositioning maneuvers: **Epley maneuver**: (Performed by MD)

Brandt-Daroff exercises (performed by patient).

- Surgery for refractory cases.

# Dix-Hallpike maneuver



### 3- Endolymphatic hydrop (Meniere's disease):

Pathophysiology: - Unknown etiology, ↑ production of fluid within inner compartment or inadequate absorption of endolymph leads to endolymphatic hydrops.

**Four main symptoms: Vertigo (minutes to hours) Hearing loss (Low frequency fluctuating SNHL) “remains” Tinnitus Fullness of the ear “pressure”**

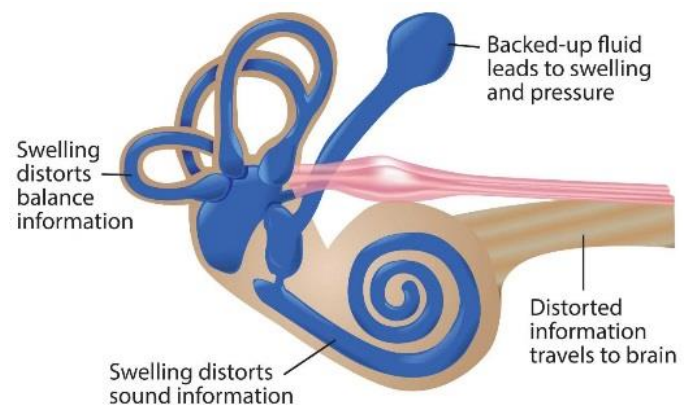
- In 10 - 20% of cases the disease later involves the opposite ear .
- Triggers: High salt intake, caffeine, stress, nicotine and alcohol.

#### Diagnosis – History.

- PTA ((pure tone audiometry))
- Must monitor the other ear as bilaterally occur in 35% of cases, so the diagnostic criteria for Meniere's Disease (must have all three):
- Two spontaneous episodes of rotational vertigo ≥20 minutes
- Audiometric confirmation of SNHL (often low frequency)
- Tinnitus and/or aural fullness

#### Treatment:

- Low-salt diet
- Medical therapy
  - Meniett device's \* See the video below
- Chemical perfusion
- Surgery



Dix-Halpike maneuver: <https://www.youtube.com/watch?v=wgWOMuB1VFY>

Eply's maneuver: <https://www.youtube.com/watch?v=9SLm76jQg3g>

Brandt-Daroff :[https://www.youtube.com/watch?v=hhinu\\_oU\\_hM](https://www.youtube.com/watch?v=hhinu_oU_hM)

Meniett device's : <https://www.youtube.com/watch?v=YeMhlqjOvBk>



## Central vestibular loss:

### 1- CVA:

Elderly patient with chronic disease like (DM, HTN) with sudden attack of vertigo +neurological symptoms.

### 2- Acoustic neuroma:

Benign tumor.

- Arise from vestibular division of VIII.

Pathogenesis: • Starts in the internal auditory canal and expands into cerebellopontine angle (CPA), compressing cerebellum and brainstem

• When associated with type 2 neurofibromatosis (NF2): bilateral acoustic neuromas, café-au-lait skin lesions, and multiple intracranial lesions

### Clinical presentation:

• Unilateral tinnitus • Hearing loss • Dizziness But true vertigo is rare as tumor growth slowly thus compensation occurs. • Facial nerve palsy and trigeminal (V1) sensory deficit (corneal reflex) are late complication.

**DDx: Acoustic neuroma mimics Meniere's disease in presentation and imaging is the only way to differentiate between them.**

### Diagnosis:

- History
- PTA (Unilateral SNHL)
- Radiology (CT, MRI)
- MRI with Gadolinium contrast is the gold standard.

### Treatment:

Expectant management if tumor is very small, or in elderly. Definitive management is surgical excision.

## MCQs

**Q1: a 34 years old patient complains of sudden attacks of loss of balance lasting for hours. He has the sensation that the surrounding environment is spinning. His loss of balance associated with nausea and vomiting. Nothing unusual is observed in his physical examination.**

**This sensation is called:**

- A. Vertigo.
- B. Dizziness
- C. Disequilibrium.
- D. Unsteadiness.

**Q2: A 56 years old female wakes up in the morning with severe vertigo lasting for seconds that returns frequently with any head movement. Her cranial nerves and ear examinations are normal.**

**The maneuver that is used to confirm the diagnosis called:**

- A. Epley's Maneuver.
- B. Dix-Hallpike.
- C. Hallpike
- D. Epley-Dix-Hallpike
- E. Dix

**Q3: A 78 years old diabetic and hypertensive female suffers severe headache, loss of consciousness and dizziness. In the emergency room, she has the following vital signs: BP 190\120, pulse: 97 and GCS 12.**

**Which of the following is least likely in the deferential diagnosis?**

- A. Migraine
- B. Transient ischemic attack
- C. BPPV
- D. Cerebrovascular accident

**Q4: A 66 years old Saudi patient complains of left ear hearing loss, fullness, tinnitus, headache and drainage for one year. These symptoms are concurrent most of the time. The ear exam reveals left eardrum perforation. The weber test lateralizes to the left ear, and the Rinne test is negative in the left ear and positive in the right ear. Your working diagnosis is peripheral vestibular system disease.**

**All of the following symptoms support your diagnosis except:**

- A. Hearing loss
- B. Tinnitus
- C. Headache
- D. Ear fullness
- E. Ear discharge.

1-A 2-B 3-C 4-C

# Done By:

Othman Abid
Majed Altulyan

