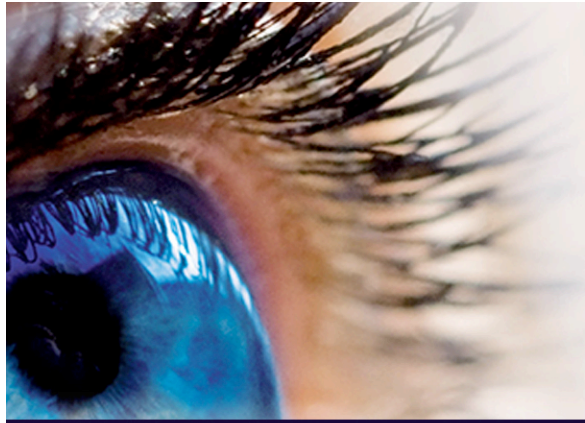



433 Teams

OPHTHALMOLOGY

Basic Anatomy & Physiology

Color index:

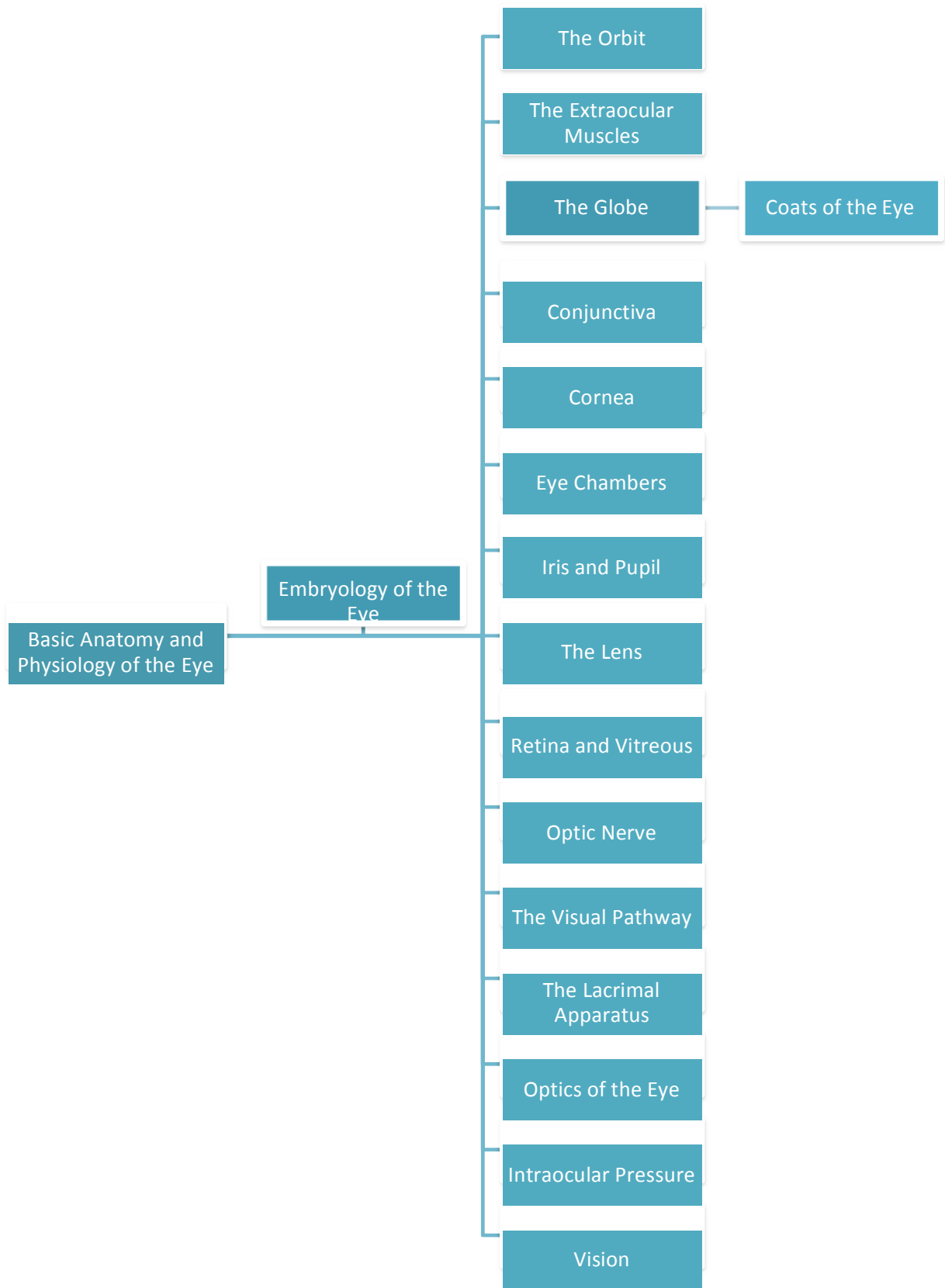
432 Team – **Important** – **433 Notes** – Not important

ophthalmology433team@gmail.com



جامعة
الملك سعود
King Saud University





Embryology of the Eye :

*This highly specialized sensory organ is derived from neural ectoderm, mesoderm and surface ectoderm.

*The eye is essentially an outgrowth from the brain (neural ectoderm).

*The Optic Nerve started as Optic vesicle connected to the forebrain by Optic stalk.

*Surface ectoderm gives cornea and lens.

Development of the Eye After Birth

At birth, the eye is relatively large in relation to the rest of the body.

*The eye reaches full size by the age of 8 years. The size got fixed at 3-6 years

*The lens continues to enlarge throughout the life.

*The iris has a bluish color due to little or no pigment on the anterior surface.

*During early infant life, the cornea & sclera can be stretched by raised IOP → enlargement of the eye due to the high elasticity of the globe.

this is what give the eye color

The Orbit

- As a socket contains and protect the eye.

- The weakest parts are the floor & the medial wall. but medial is weaker than floor

- Seven bones contribute the bony orbit.

- Surrounded by nasal sinuses.

- Nasal bone fracture is the most common facial fracture.

- **"This is a common Q" Fracture of the floor is called orbital blowout fracture** and is due to blunt trauma which causes increased IOP and fracture of the orbital floor. This fracture causes impaction of inferior rectus muscle so the eye will be displaced inferiorly "defective elevation" and posteriorly "enophthalmos" and the inferior orbital nerve will be paralyzed. The patient will complain of diplopia **"vertical diplopia"**.

Ethmoid bone has a very thin, so it is known as Lamina Papyracea **"thinnest part of the orbit"**. Patient with a **sinusitis** → invasion of the Infection from the ethmoidal sinus to the orbit results in **orbital cellulitis**, which is a serious complication.

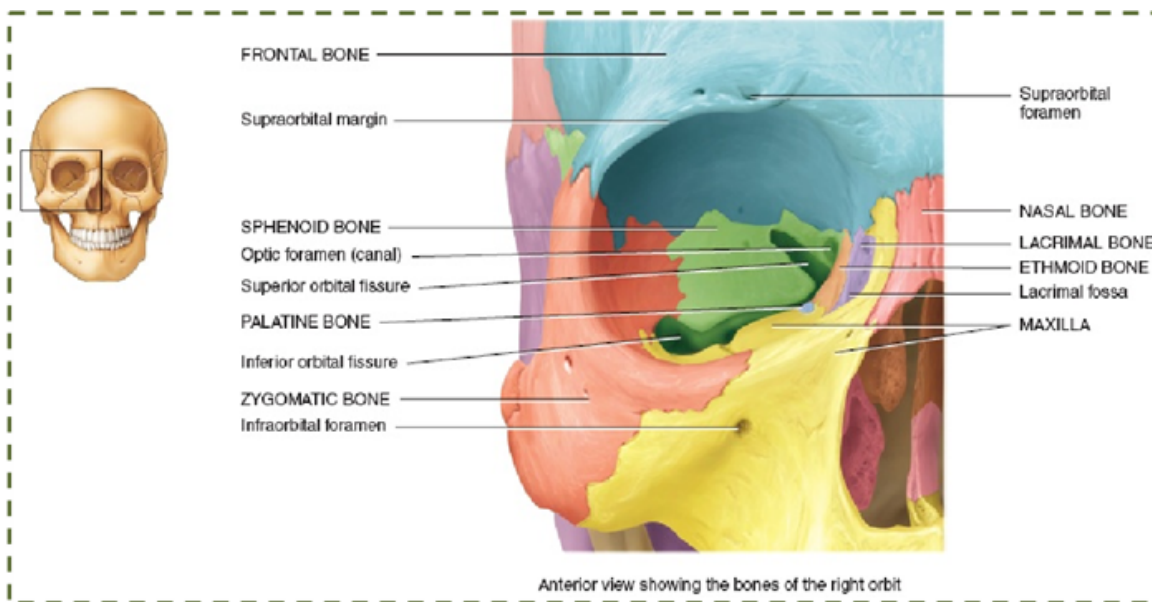
Orbital margin⁽¹⁾: Formed by the frontal, maxilla, and zygomatic bones.

Orbital cavity⁽¹⁾: The orbital cavity is pyramidal, with its base in front and its apex behind.

- I. **Roof**: Formed by the orbital plate of the frontal bone, which separates the orbital cavity from the anterior cranial fossa and the frontal lobe of the cerebral hemisphere.
- II. **Floor**: Formed by the orbital plate of the maxilla, which separates the orbital cavity from the maxillary sinus.
- III. **Lateral wall**: Formed by the zygomatic bone and the greater wing of sphenoid.
- IV. **Medial wall**: Formed from before backward by the frontal process of the maxilla, the lacrimal bone, the orbital plate of ethmoid (which separates the orbital cavity from the ethmoid sinuses), and the body of sphenoid.

Openings into the orbital cavity⁽¹⁾:

1. **Orbital opening**: Lies anteriorly, about one sixth of the eye is exposed, the remainder is protected by the walls of the orbit.
2. **Optic foramen**: The structures passing through are: **the optic nerve, ophthalmic artery, and central retinal vein.**
3. **Superior orbital fissure**: **The structures passing through are: III, IV and VI cranial nerves, lacrimal nerve, frontal nerve, nasociliary nerve, orbital branch of middle meningeal artery, recurrent branch of lacrimal artery, superior orbital vein, and superior ophthalmic vein.**
4. **Inferior orbital fissure**: The structures passing through are: **infraorbital nerve, zygomatic nerve, parasympathetics to lacrimal gland, infraorbital artery, infraorbital vein, inferior ophthalmic vein branch to pterygoid plexus.**
5. **Supraorbital notch**: Situated in the superior orbital margin, transmits the supraorbital nerve and blood vessels.
6. **Infraorbital groove and canal**: Situated in the orbital plate of the maxilla, the transmit the infraorbital nerve (a continuation of the maxillary nerve) and blood vessels.
7. **Nasolacrimal canal**: Located anteriorly in the medial wall; it communicates with the inferior meatus of the nose, and transmits the nasolacrimal duct.



The Extraocular Muscles :

Four recti: **“superior, inferior, medial, and lateral”** and two oblique muscles **“superior and inferior”**.

All are supplied by Oculomotor nerve except superior oblique muscle (Trochlear n. = 4th CN) and lateral rectus muscle (Abducent n.= 6th CN).

Attachment of the Recti Muscles to the Eye

Every muscle has a specific distance from the limbus e.g. SR muscle is 6.9 mm from the limbus, and this is the longest distance. The MR muscle is the nearest to the limbus with a distance equals to 5.5 mm. However, the clinical importance of knowing this is encountered during cataract surgery, the surgeon makes a SR suture to fix the eye while operating as this muscle is away from the limbus.

Patient with a 3rd nerve palsy, how can you rule out 4th nerve palsy? **Important OSCE question**

The clinical manifestations of 3rd nerve palsy:

- Ptosis.
- All muscles are paralyzed except the LR, so the eye will be abducted.
- The patient can not look downward because the IR is paralyzed.

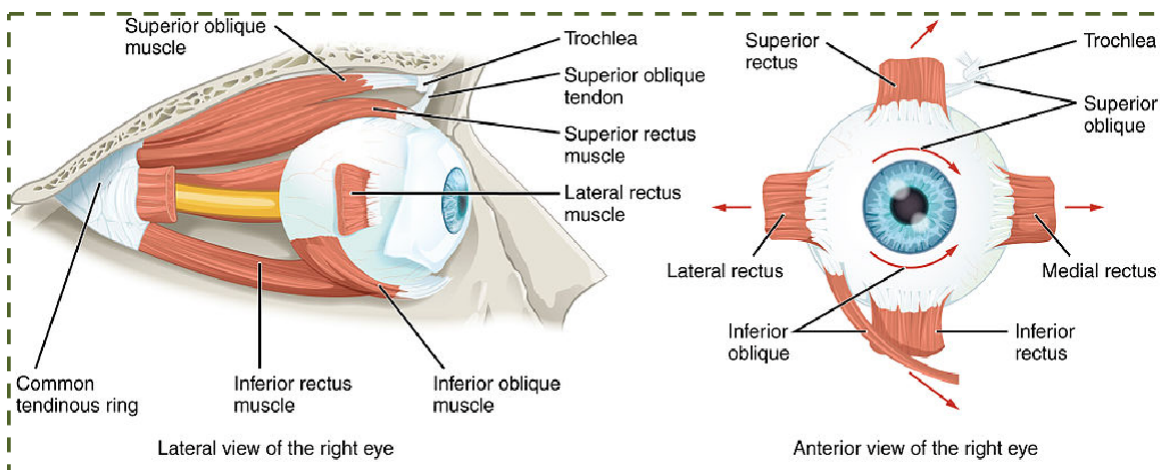
To know if the 4th nerve is intact or not, ask the patient to look downward and if the 4th nerve is intact, then the eye will be intorted due to the action of SO muscle.

Muscle Action : very very important

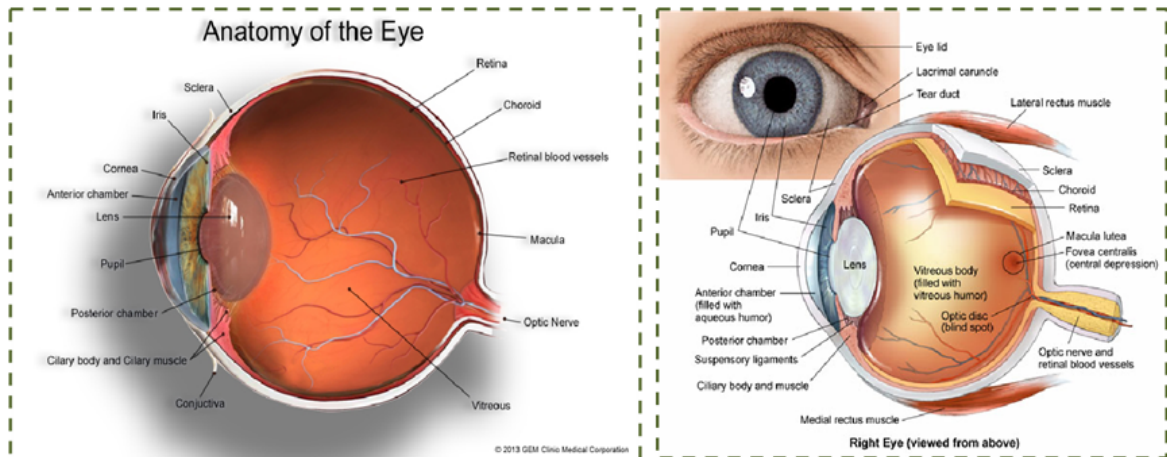
Muscle	Primary Action	Secondary Action	Tertiary Action
Superior rectus	Elevation (transverse axis)	Medial rotation or adduction (vertical axis)	Intorsion or incycloduction (sagittal axis)
Inferior rectus	Depression (transverse axis)	Medial rotation or adduction (vertical axis)	Extorsion or excycloduction (sagittal axis)
Lateral rectus	Lateral rotation or abduction (vertical axis)	—	—
Medial rectus	Medial rotation or adduction (vertical axis)	—	—
Superior oblique	Depression (transverse axis)	Lateral rotation or abduction (vertical axis)	Intorsion or incycloduction (sagittal axis)
Inferior oblique	Elevation (transverse axis)	Lateral rotation or abduction (vertical axis)	Extorsion or excycloduction (sagittal axis)

Field of action : doctor said this is enough for us but read the slide before

	<u>Direction to look</u>
• SO	Down and in
• IO	Up and in
• SR	Up +/- out
• IR	Down +/- out



The Globe :



The eye measures approximately 21-24 mm in all its main diameters

Coats of the Eye (1)

- I. **Fibrous coat “outer protective coat”**: Made up of a posterior opaque part, the sclera, and an anterior transparent part, the cornea. Both are formed of collagenous fibers with different arrangement. Lamina cribrosa is the area of the sclera that is pierced by the nerve fibers of the optic nerve. Cornea is in contact posteriorly with the aqueous humor. “the cornea is stronger than the sclera”
- II. **Vascular pigmented coat “middle vascular coat”**: Consists from behind forward, of the choroid, the ciliary body, and the iris. The choroid is composed of an outer pigmented layer and an inner, highly vascular layer. The ciliary body is continuous posteriorly with the choroid, and anteriorly, it lies behind the peripheral margin of the iris. It is composed of the ciliary ring, the ciliary processes, and the ciliary muscles. “The ciliary body has pigmented and non-pigmented epithelium, the non-pigmented one secretes the aqueous” if the ciliary body is not function: - lens will damage. - decrease IOP
- III. **Inner layer**: composed of the optic nerve and the retina. The retina extends forward to within 6 mm of the limbus.
 you should differentiate between posterior chamber and posterior segment: (IMPO)
 post. chamber > behind the iris and contains aqueous humour.
 pot. segment > it's the vitreous filled with gel-like fluid

★ Conjunctiva :

It is the outer cover of the eye, normally it has vessels and sometimes they are prominent, but if there are no vessels or redness, then the patient might be anemic.

1. **Bulbar conjunctiva:** covers the eye. In a case of vernal keratoconjunctivitis, the bulbar conjunctiva may have **tranta's spots**. "discrete whitish raised dots along the limbus"
2. **Palpebral conjunctiva:** covers the eyelid from inside.

SAQ q: patient came complaining of foreign body sensation in the conjunctiva.

- What is the diagnosis? Palpebral conjunctival foreign body you have to write the full name : palpebral conjunctiva F.B
 - What is the treatment? Removal and topical antibiotic
3. **Forniceal conjunctiva:** between the bulbar and palpebral conjunctivas.

- The stroma (no adenoid tissue until 3 months after birth).

- Follicles and Papillae

- Injection and chemosis

- Causes of ciliary injection:

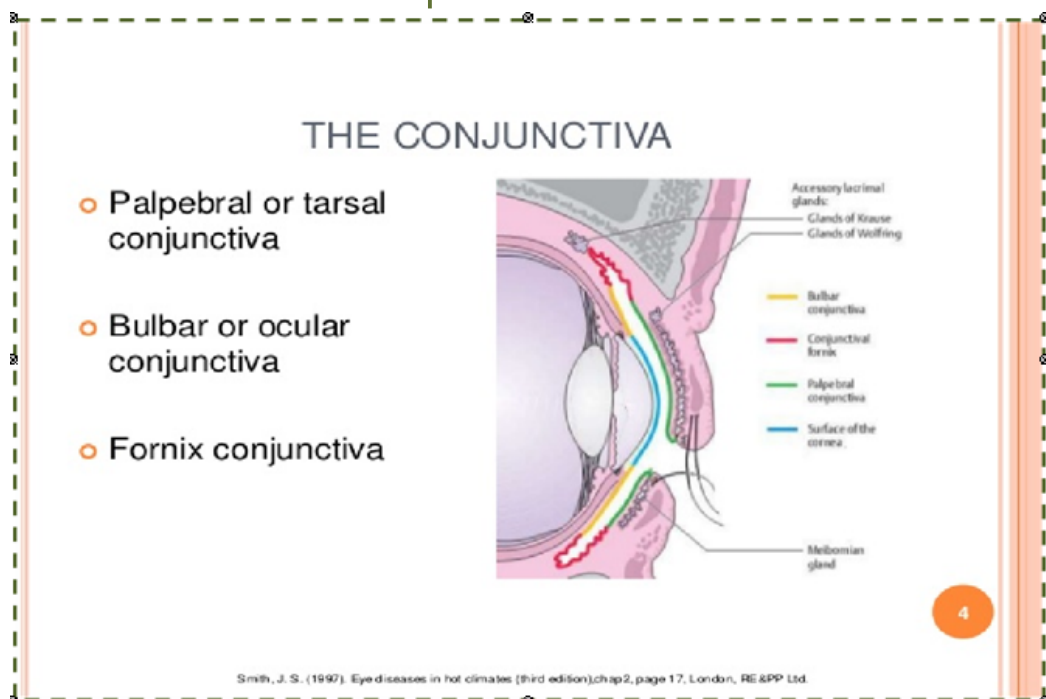
- keratitis

- Uveitis

- Acute glaucoma

- "Chemosis is the swelling of the conjunctiva due to abnormally permeable capillaries, it's a non specific sign of eye irritation and could be caused by conjunctivitis".

- "Ciliary injection is peripheral hyperemia of the anterior ciliary vessels which produces a deep red or rose color of the corneal stroma".



The Cornea “strongest part” :

The cornea is 500-530 micron in thickness. It consists of **five layers: epithelium, bowman’s layer** “called anterior limiting membrane”, **corneal stroma, descemet’s layer** “called posterior limiting membrane”, and **corneal endothelium**.

It is transparent because: **it is avascular and it has regularly arranged collagen fibers**.

The epithelium is from surface ectodermal origin, thus it is very sensitive and also it can regenerate after being injured.

The thickness of the cornea affects the IOP reading. After Lasik, the cornea becomes weak and a false low reading of IOP could occur, so the diagnosis of glaucoma might be missed.

One possible risk of Lasik is keratoconus, which is central thinning and plugging of the cornea. This might end with corneal scarring and keratoplasty "corneal transplantation"

The patient with keratoconus when he looks down, his lower eyelid becomes V shaped because of the plugging, and this is called **Munson's sign. “important”**

Keratoconus is a strong contraindication of Lasik.

When the bowman’s membrane got injured, it will heal with a scar “opacity”.

SAQ: corneal abrasion usually does not cause scars unless the bowman's layer or the stroma are injured.

The descemet's membrane is a very strong membrane, but in case of congenital glaucoma, it will be stretched and the aqueous will invade the cornea, which will disturb corneal fibers arrangement and cause corneal edema. If congenital glaucoma doesn’t get corrected early, the condition will worsen and end up with corneal scarring and keratoplasty might be needed. **So the treatment of congenital glaucoma is surgical.**

Important q: When the patient got blunt trauma in the eye, which one is more susceptible to injury, cornea or sclera?

The answer is sclera

Actually, both Cornea and sclera are made up of collagen fibers but they differ in the arrangement. The corneal fibers are arranged in vertical and horizontal planes, making it more clear and 100 times stronger than sclera. The fibers of the sclera are arranged in haphazard fashion, which make them weaker and more opaque.

Eye Chambers :

1. The anterior chamber: between the cornea and the iris. It should be always clear, abnormal blood collection in it is known as **hyphema** and it is mainly due to trauma.

Collection of pus in the anterior chamber is known as **hypopyon**.

2. The posterior chamber: immediately behind the iris, between the iris and zonule fibers.

These two chambers which communicate through the pupil are filled with clear aqueous humour

aqueous humor.

3. The vitreous cavity: filled by gel-like structure, the vitreous.

The non-pigmented ciliary epithelium covering the ciliary body secretes the aqueous with the help of carbonic anhydrase enzyme. It circulates in the posterior chamber between the iris and the lens, then it enters the anterior chamber to be drained through the **trabecular meshwork into the schlemm's canal (85%)**, and the other 15% got drained through the uveoscleral outflow (absorbed by the iris and the ciliary body to the suprachoroidal space). **Open angle glaucoma is caused by trabecular meshwork sclerosis.**

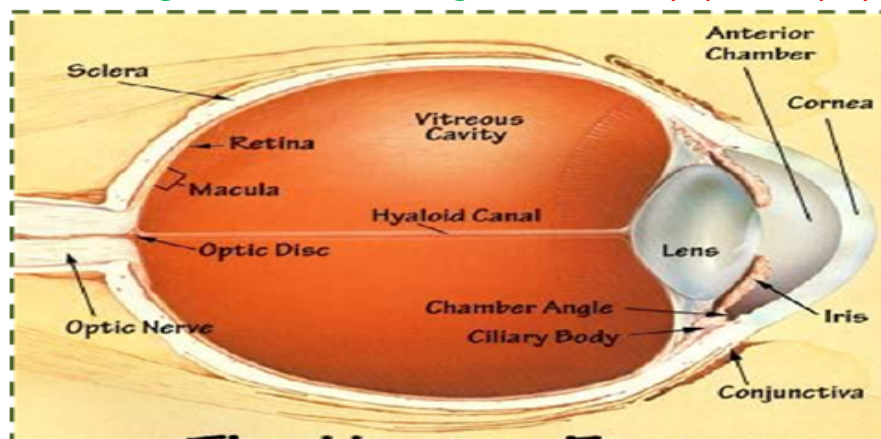
If the patient has a predisposing factor of glaucoma (e.g. hyperopia) and the pupil remained mid-dilated for a long period, the iris will adhere to the lens, and this will cause pupillary block, which in turn

leads to accumulation of the aqueous in the posterior chamber and hence raising of IOP leading to the development of acute glaucoma.

The initial treatment of acute glaucoma is carbonic anhydrase enzyme inhibitors to reduce the volume of accumulated aqueous like: **Acetazolamide “Diamox” and Sulfonamide**. These drugs act mainly on the trabecular pathway. Prostaglandins found to be active on the other pathway and has cosmetic side effects, it elongates and thickens eyelashes. **The initial intervention is laser iridotomy.**

Open angle glaucoma occurs in any age. Closed angle glaucoma “caused by pupillary block by the lens and iris” occurs in patients above 40y.

Anterior segment is anything in front of the lens including anterior chamber, cornea, iris, and lens itself. Posterior segment is anything behind the lens including vitreous, retina and optic nerve. When the patient complains of decreased vision but has normal anterior and posterior segments, then he might have **amblyopia “lazy eye”**



Hyaloid canal is an empty canal between the lens and the optic nerve. Retrolental fibroplasia "previously known as Retinopathy of prematurity (ROP)" is a disease that affects immature vasculature in the eyes of premature babies. It can be mild with no visual defects, or it may become aggressive with new blood vessel formation (neovascularization) and progress to retinal detachment and blindness. “Medscape”

When patients with proliferative diabetic retinopathy presents with disc involvement, it is an emergency situation and should be managed by surgery, because these vessels are prone to rupture and bleeding.



Iris and Pupil :

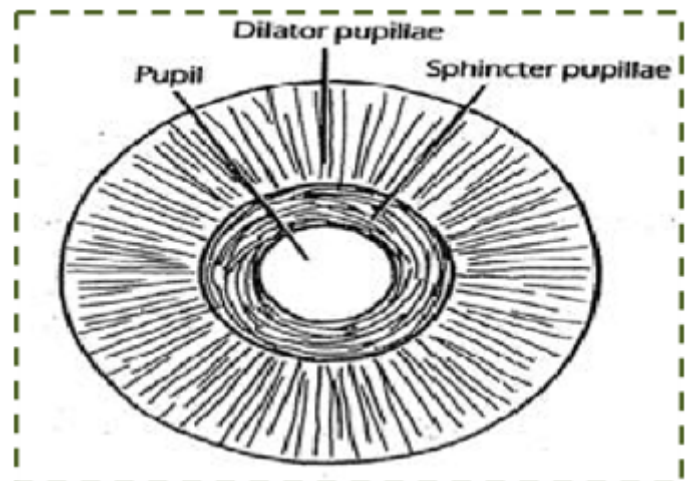
The iris is a thin, contractile, pigmented diaphragm with a central aperture, the pupil. It is suspended in the aqueous humor between the cornea and the lens.

The iris has two muscles ⁽¹⁾:

1. **Dilator pupillae:** supplied by sympathetic fibers *injury will lead to hornor's syndrome*
2. **Sphincter pupillae:** supplied by parasympathetic fibers from the oculomotor nerve.

In patients with 3rd nerve palsy and spared pupil like in diabetes, or in patients with semi dilated\fully dilated pupil and 3rd nerve palsy, what is the recommended investigation?

The answer is **MRA** "magnetic resonance angiography" because the most common cause of surgical 3rd nerve palsy is aneurysm, which can be detected using MRA.



The Lens : the refraction power is 60 (40 = cornea and 20=lens)

The lens is a transparent, biconvex structure enclosed in a transparent capsule. It is situated behind the iris in front of the vitreous body and is encircled by the ciliary processes.

The lens consists of an **elastic capsule**, which envelops the structure; a **cubeoidal epithelium**, which is confined to the anterior surface of the lens; and **lens fibers**, which are formed from the cubeoidal epithelium at the equator of the lens ⁽¹⁾.

Crystalline lens is the only structure continuously grow throughout life.

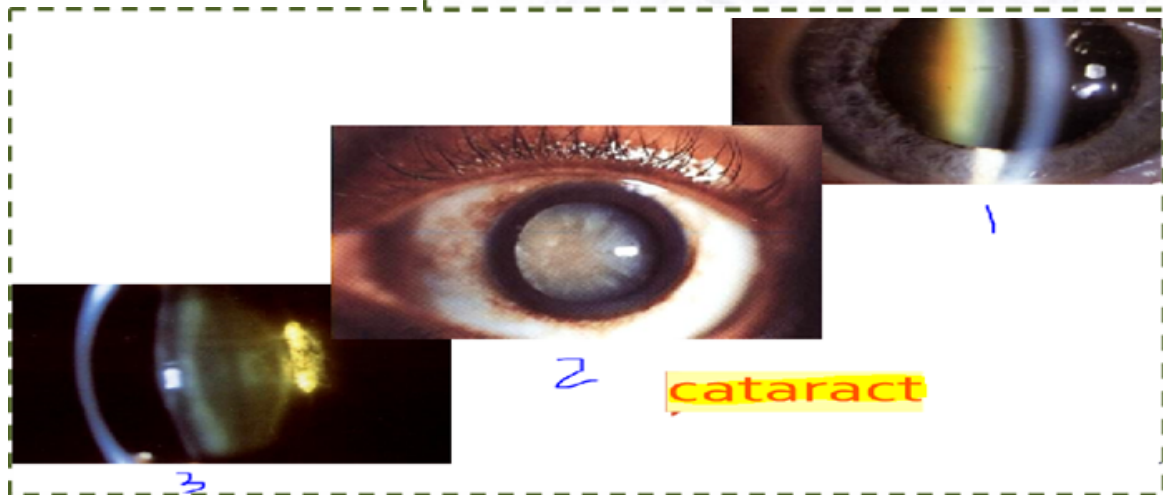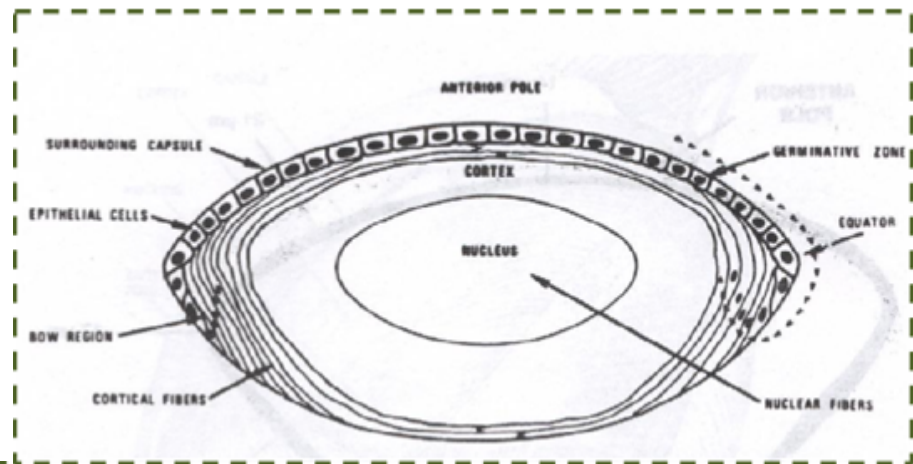
It is mainly ectodermal in origin, so it is very sensitive.

Diseases of the lens: any disease in the lens called cataract

- Congenital anomalies and effect of systemic diseases.
- Cataract

Lens structure:

- Anterior capsule
- Cortex
- Nucleus
- Posterior cortex
- Posterior capsule



Pic.1: this is a nuclear sclerosis representing a manifestation of early stage cataract.

Pic.2: cortical cataract

Pic.3: posterior subcapsular cataract Possible causes: steroids and trauma

Important question: Post kidney transplant patient on steroids came complaining of decreased vision, what is the possible cause? The answer depends on the IOP, if it is normal, then he might have posterior subcapsular cataract. If his IOP is elevated, then he might have glaucoma.

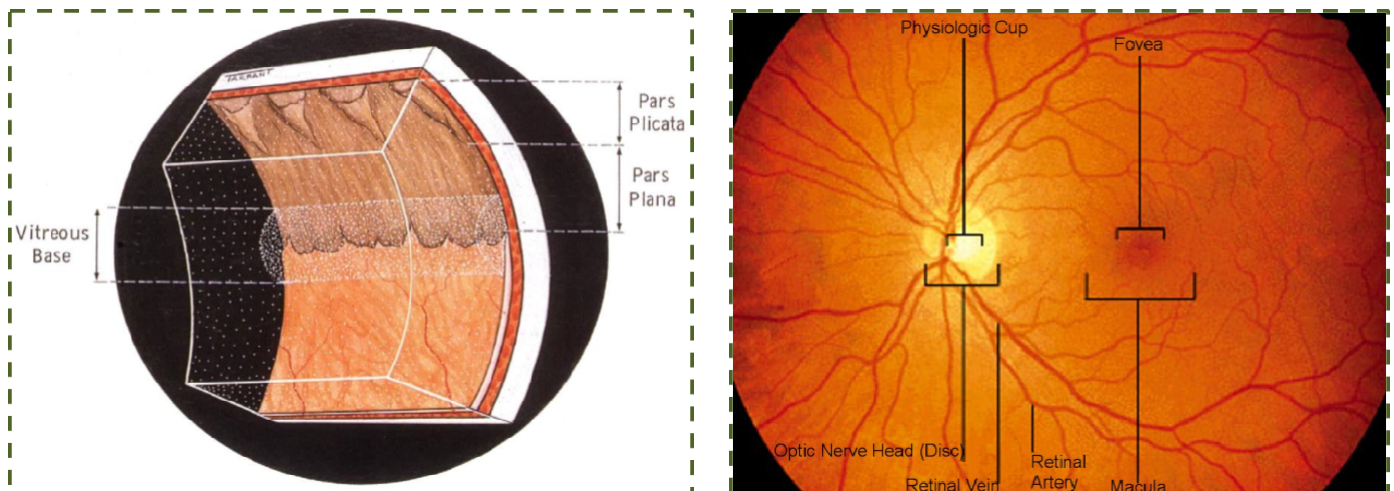
*Two approaches of cataract surgery: **phacoemulsification** and standard extracapsular cataract extraction (ECCE).

★ Retina and Vitreous :

The retina consists of an outer pigmented layer and an inner nervous layer. Its outer surface is in contact with the choroid and its inner surface is in contact with the vitreous body.

At the center of the posterior part of the retina is an oval, yellowish area, the **macula lutea**, which is the area of the retina for the most distinct vision. It has a central depression, the **fovea centralis** (1).

The optic nerve leaves the retina about 3 mm to the medial side of the macula lutea by the optic disc. **The optic disc** is slightly depressed at its center, where it is pierced by the **central retina artery**. At the optic disc, is a complete absence of rods and cones, so that the optic disc is insensitive to light and is referred to as the **“blind spot”** (1).



Ciliary body: The structure of the ciliary body is triangular in cross-section, and it encircles the inside of the eye behind the colored iris. It connects posteriorly with the choroid and anteriorly with the iris. The ciliary body has two portions, the **pars plicata** at the front and the **pars plana** at the rear. Pars plicata has the ciliary processes, and the zonular lens fibers from the crystalline lens pass deep into the valleys between them. **Pars plana is a relatively avascular area, so it is important surgically in the approach to vitreous space** (2).

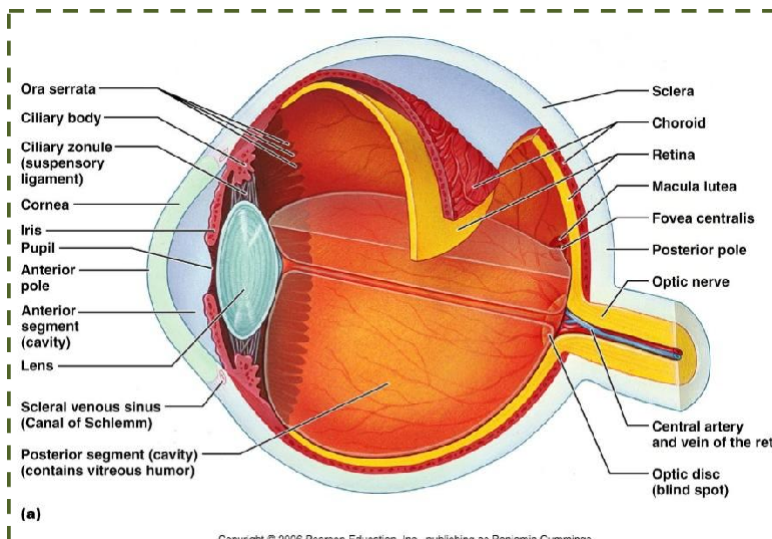
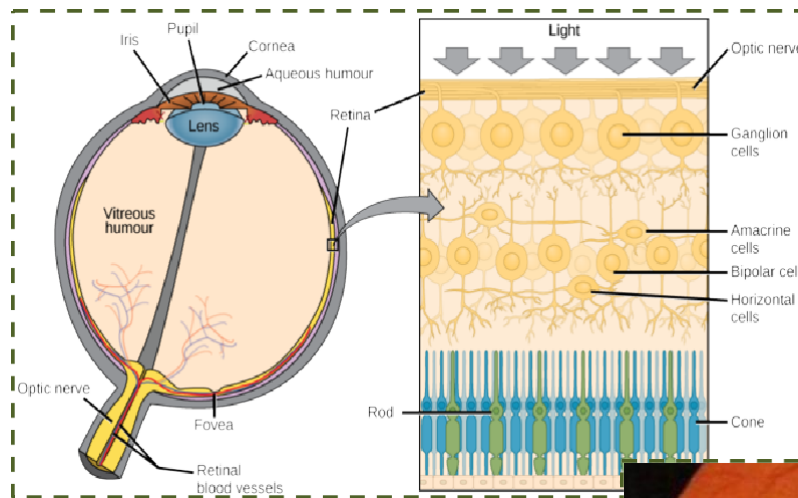
Macula: An area of the eye near the center of the retina where visual perception **is most acute** (3). “oval yellowish area surrounding the fovea”

Fovea:

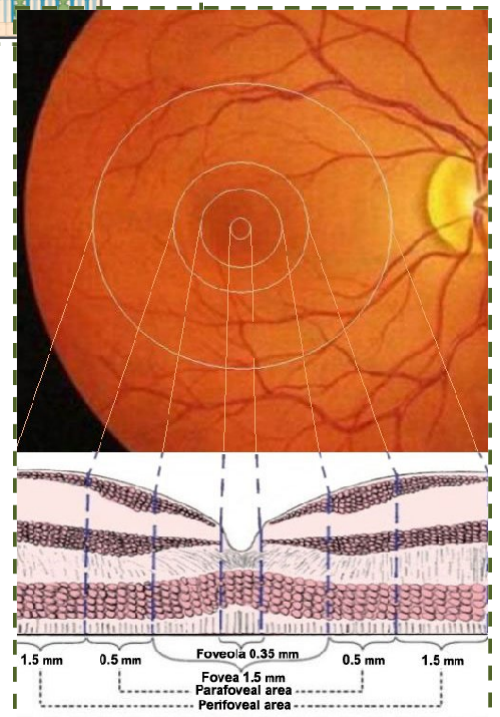
The fovea is the region in the center back of the eye that is responsible for acute (central) vision. **The fovea has a high density of cones** (4).

cones is responsible about colour vision
cones > works in light
rods > works at night

The periphery of retina is avascular; it may become vascular in sickle cell anemia or in premature baby with Retrolental fibroplasia. Diabetic retinopathy patients with vitreous hemorrhage = **do pars plana vitrectomy**



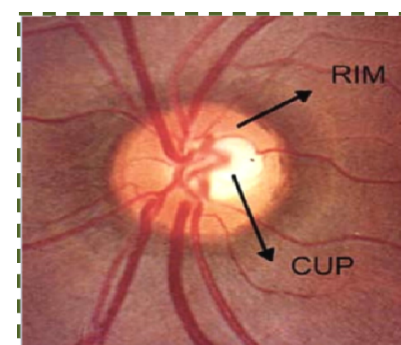
optic nerve contains 1.2 million fiber

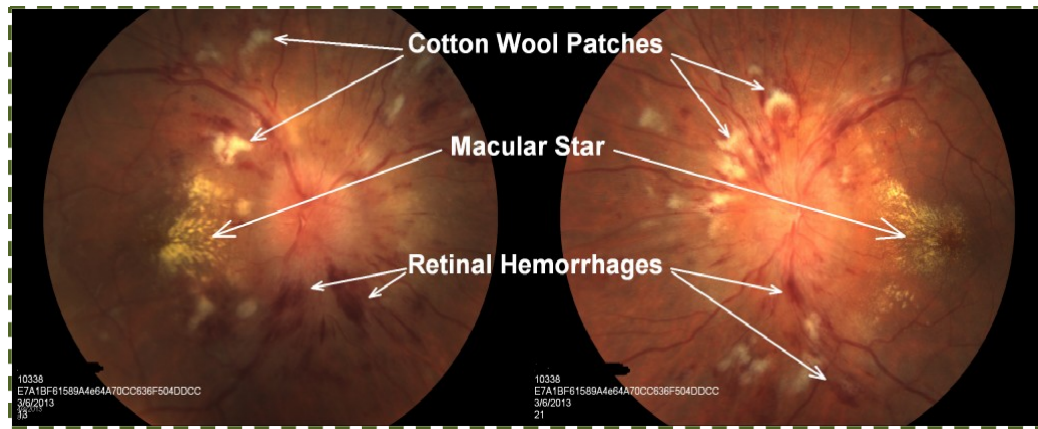


In fundus examination, you should comment on: **the optic disc, the retinal vessels, and the macula.**

Patient with chronic visual loss + the fundus is not seen = do B-scan ultrasound. **"Gold standard"**

- **Example:** patient with bilateral central retinal veins occlusion from hypertension (5). "the picture below"





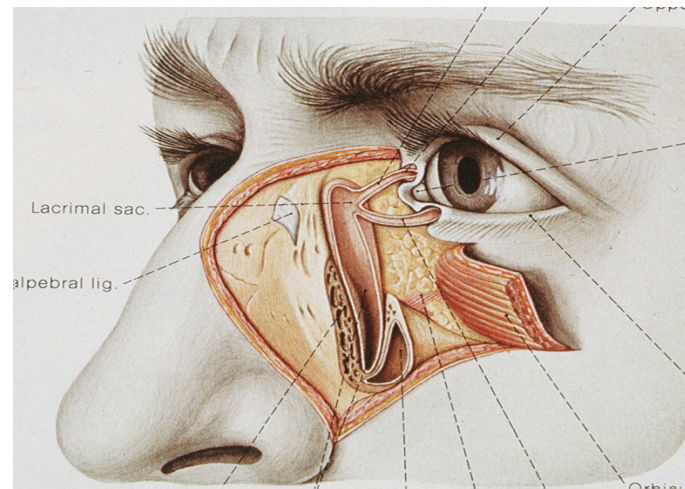
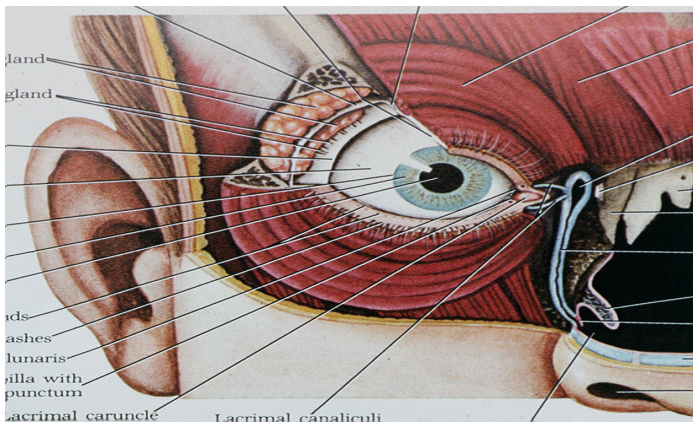
Vitreous humor: It is a gel-like substance occupied the space behind the lens and in front of the retina at the back of the eye, it comprises a large portion of the eyeball. It consists of water, collagen, salt and sugar. It maintains the shape of the eye, and it is a clear solution to the light can easily pas thought it⁽⁶⁾.

★ Optics of the Eye :

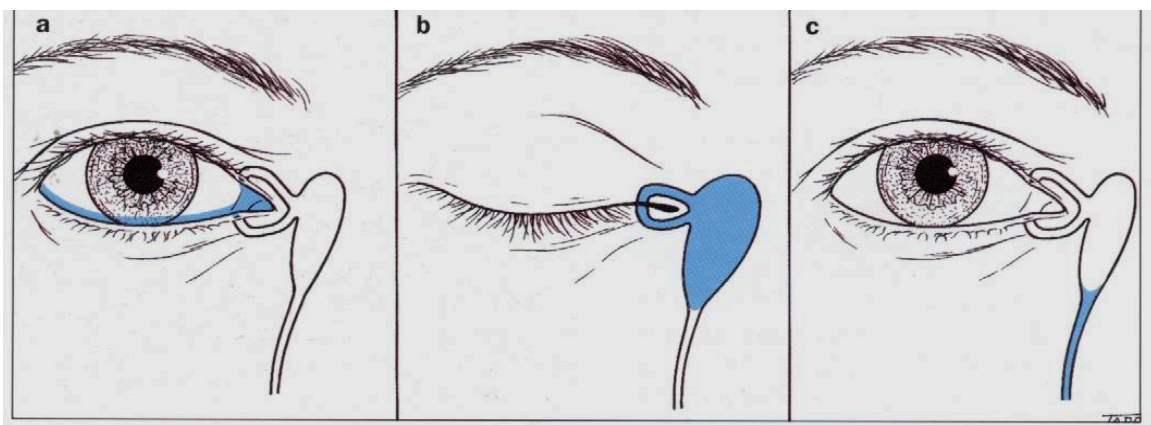
- The eye is like a camera. Light must have a clearly pathway to be clearly focused on the sensory receptors of the retina, i.e., Clear cornea, anterior chamber, lens and vitreous cavity.
- The Refractive power of the eye is about 58 -62 diopters.
- The cornea is the major refracting element of the eye with a power of approximately 40 diopters. If the curvature is greater in one meridian than the other → Astigmatism.
- The refractive power of the lens is about 17-21 diopters at rest. Accommodation can change the power of the lens markedly depending on the age.

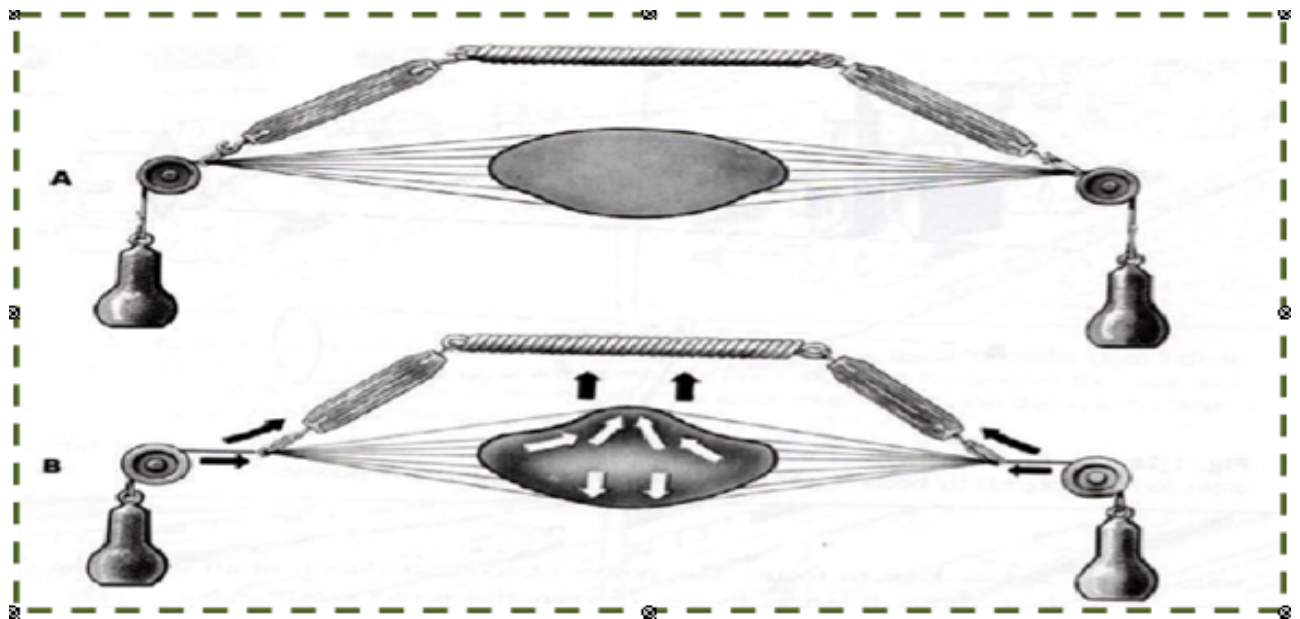
THE LACRIMAL APPARATUS

- ❑ *Lacrimal gland secretes tears into the upper fornix of the conjunctival sac which are spread over the surface of the cornea as a tear film by blinking of the lids.*
- ❑ *Tears accumulate at the inner canthus and drain into the lacrimal sac via the puncta & canaliculi.*
- ❑ *The sac is continuous inferiorly with the nasolacrimal duct which opens into the nasal cavity just beneath the inferior turbinate.*



- ❑ *Tear secretion.*
- ❑ *Layers of precorneal tear film.*
- ❑ *Drainage of tear.*





- Young kids have a strong accommodation up to 30 diopters as their lenses has 70.000 zonule fibers.

- When ciliary body contracts → relaxation of the zonules → plugging of the lens and thus increased depth of focus and you will be able to see near objects.

- When ciliary body relaxes → contraction of the zonules → thinning of the lens, so you will be able to see far objects clearly.

- **Important:** *With increased age, usually from 40s, people experience a problem with near vision "Presbyopia", why?

Because of: 1. Loss of elasticity of the lens.

2. Increased in the refractive index of the lens due to nuclear sclerosis.

- **Presbyopia is treated with convex lens.**

- **Hyperopia "farsightedness"** → treated with convex lens.

- **Myopia "nearsightedness"** → treated with concave lens.

* Patient with big eyes ">25 mm in diameter" the image will be reflected in front of the retina leading to myopia, to correct it we give the patient a concave lens, thus causes a diversion of light rays.

* Patient with small eyes "<21 mm in diameter" the image will be reflected behind the retina leading to hyperopia, to correct it we give the patient a convex lens that causes a conversion of light rays.

Intraocular Pressure :

- The pressure within the eye is maintained at a steady level by continuous formation and drainage of aqueous.
- Aqueous is secreted by the ciliary epithelium → posterior chamber → anterior chamber (through the pupil) → drained through the anterior chamber angle.
- The intraocular pressure (IOP) is normally between 10 – 22 mmHg; increased IOP causes ocular hypertension.
- High IOP almost always due to an obstruction of aqueous outflow.
- Corneal thickness affect the readings of IOP.
- Some people have glaucoma with normal IOP.

Vision :

The retina:

-The central retina contains yellow pigment, Xanthophyll, the so called **macula lutea (yellow spot)**.

-It is divided into retinal pigment epithelium and neurosensory retina.

-Photoreceptors contains visual pigment which consists of a large protein (opsin) attached to retinal (**vitamin A aldehyde**).

Light splits the opsin from the retinal with initiation of a graded electrical potential

→ Transmitted through the visual pathway to be processed in the visual cortex (occipital lobe) → vision sense.

- Vitamin A → retinal aldehyde → will go through the retina → creating impulses → will go the visual occipital cortex.

- More Vitamin A will not improve the vision.

summary

- *The socket that contains the eye called orbit.
- *The orbit is formed by 7 Bones.
- *The optic nerve passes through Optic foramen or canal.
- *The eye has six extraocular muscles 4 Recti and 2 obliques.
- *All extraocular muscles are supplied by oculomotor nerve except SO and LR.
- *When we test a patient 4th nerve we should ask him to look Down and in.
- *The space that lies behind the cornea and in front of the iris called anterior chamber.
- *The fluid that fills the chambers of the eye called aqueous humors.
- *The cavity that lies behind the lens called vitreous cavity.
- *The main refractive structure in the eye is the cornea.
- *The second refractive structure in the eye that can change its power is the lens.
- *The structure that determines the color of the eye is the iris.
- *When the lens gets opacified this condition called cataract.
- *The central part of the retina called the macula.
- *The central part of the macula called fovea.
- *The central part of the fovea called foveola.
- *The optic nerve lies in the nasal part of the retina.
- *The percentage of the decussating fibers is 53%.

Done By:

Othman Abid
Faris Almani

Revised By:

Razan AlDhahri
Sara Habis

Special Thanks to : Rahaf Altwaijri

