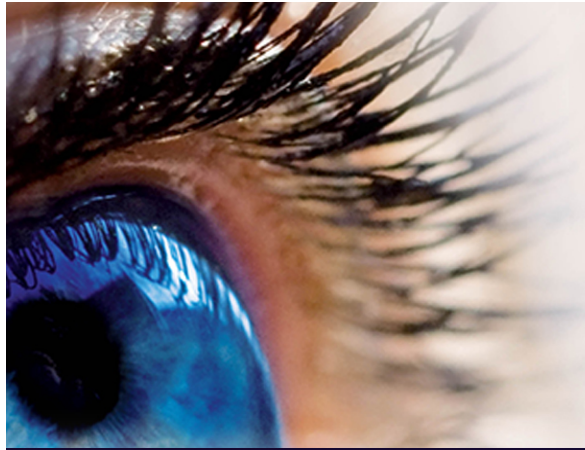



433 Teams

OPHTHALMOLOGY

Ocular Emergencies & Red Eye Part I

Color index:

432 Team – **Important** – 433 Notes – Not important

ophthalmology433team@gmail.com



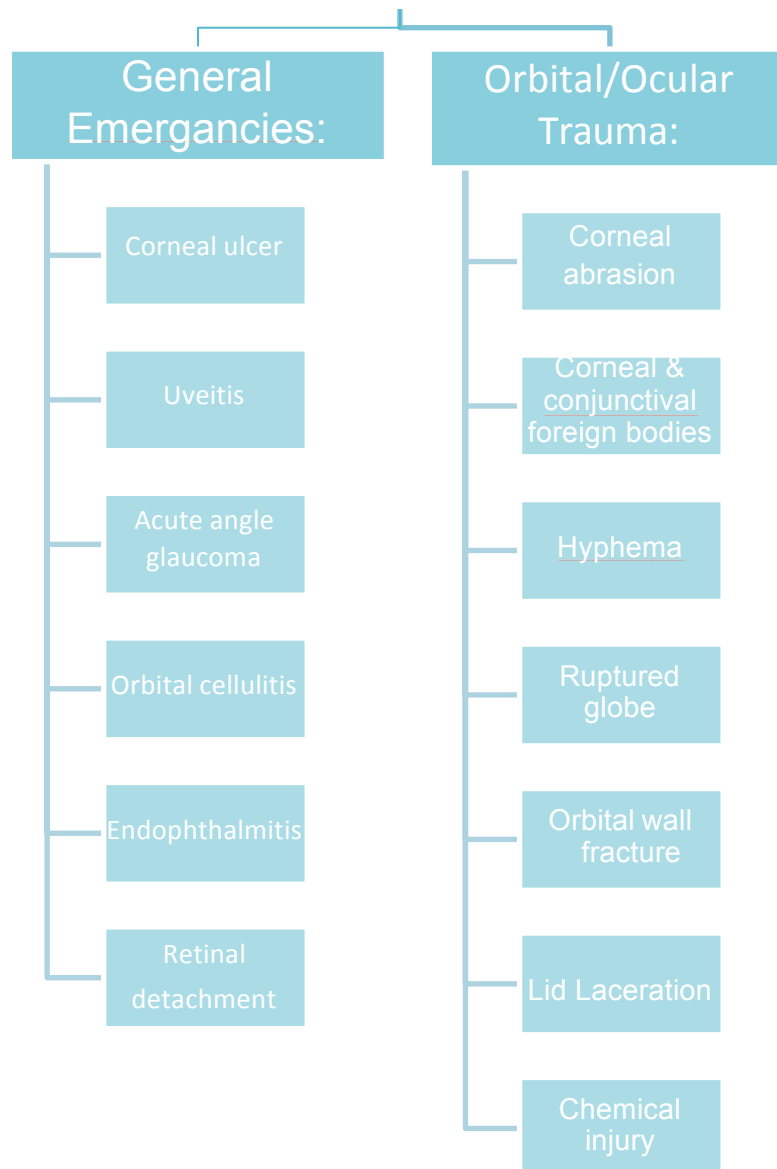
جامعة
الملك سعود
King Saud University



Objectives:

Were not given

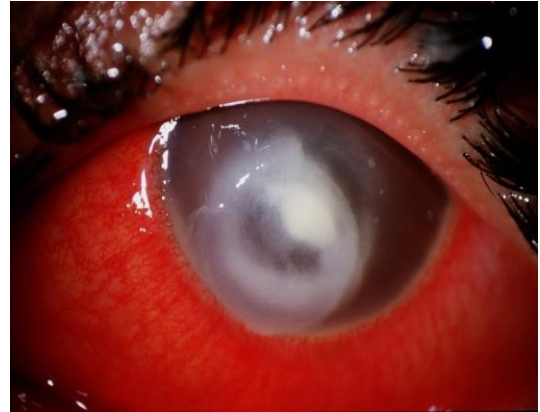Ocular Emergencies



Corneal Ulcer:

- Corneal ulcer occur secondary to lid and conjunctival inflammation but it is often secondary to trauma or contact lens wear.

- Bacterial, viral, fungal or parasitic organism.



- You may know the diagnosis clinically for example patient working in a farm or, on long use of topical steroid, on examination you see feathery margins, stellate lesions from the main infiltrate, all of these suggest fungal infection.

- Ocular pain, redness and discharge with decrease vision and corneal opacity.

- Hypopyon: white blood cells in the anterior chamber and secondary to inflammation.

- Contact lens users usually have gram-negative infections especially (pseudomonas).

Management:

- The treatment should be given based on culture and stain, if culture doesn't give result do scrapping to get biopsy from the cornea and send it to the lab.

- Promote healing and treat the primary cause if present (e.g. lid deformity, dryness), It is important to treat the cause of the infection otherwise patient will have recurrent infections. For example something in the eyelid causing the infection as Trichiasis or eye lashes rubbing over the cornea.

- Treatment with appropriate antimicrobial therapy is essential to minimize visual loss.

- Then treat the inflammatory process

- Prompt diagnosis of the etiology by doing corneal scraping.

- Start treatment immediately with antimicrobial, broad spectrum antibiotics that covers gram +ve and –ve , then wait for culture and sensitivity to give appropriate treatment accordingly, either pull the antibiotics if fungal and give for example amphotericin or arrange for it if gram +ve or –ve.

- Usually the antibiotics given are **Cefazolin** (cephalosporin first generation) which covers gram +ve, and **Ceftazidime** (cephalosporin third generation) which covers gram -ve espically **Pseudomonas**) or **Ceftazidime** and **Vancomycin** which covers gram+ especially staph. But it may be started later on to avoid resistance for full coverage of gram +ve and –ve.

- **Best coverage for pseudomonas is Ceftazidime.**

- **Why we do not start antifungal at the same time?**

1 - It is not common.

2 - It need more time to give the effect.

3 - Fungal and viral infections need time to cause damage to the eye unlike bacterial infections, which may perforate the eye in 12 hours if not treated properly.

430 team:

One of the risk factors to develop corneal ulcer is wearing contact lens, because it will lead to microabrasions that make the stroma easily accessed by the microorganism.

- **Cephalosporin:** as it goes from first to third, gram –ve coverage increase.

- **Flurocainolons:** are the opposite as ciprofloxacin (1st generation) is a good coverage for gram –ve, Ofloxacin is good for gram +ve.

- **Fluroquinolones** used for mono therapy in case of small or peripheral ulcer to cover gram –ve and +ve.

Corneal ulceration (ophthalmology lecture notes)

With so many involved in agricultural labour in the developing world, microbial keratitis, initiated by minor eye trauma, is not unusual. In northern climates, where agricultural injuries are less frequent, fungal infections are rare. But in tropical zones fungal keratitis may account for over 80% of infected cases. It is estimated that 1.5 million new cases of unilateral visual impairment due to corneal ulceration occur each year. Treatment can be expensive and is often delayed in the developing world. Some topical anti-fungal agents are highly toxic and may leave their own sequelae and corneal grafting for central scarring is seldom available. Antibiotic treatment of minor eye trauma has, however, an important role in preventing progression to a bacterial keratitis.

Contact Lens Wearer:

- Any redness occurs for patients who wear contact lens should be managed with extreme caution.
- Remove lens.
- Rule out corneal infection (i.e corneal ulcer).
- Gram-negative organisms, fungi and Acanthamoeba are common causative organisms.
- Do not patch.
- Close Follow up.

Uveitis:

- Inflammation of the uveal tissue (**iris, ciliary body, or choroid**), retina, blood vessels, optic disc, and vitreous can be involved.

It could be:

- 1- anterior as iridoscleritis.
- 2- at the back as choroiditis, retinitis.
- 3- Pan uveitis.

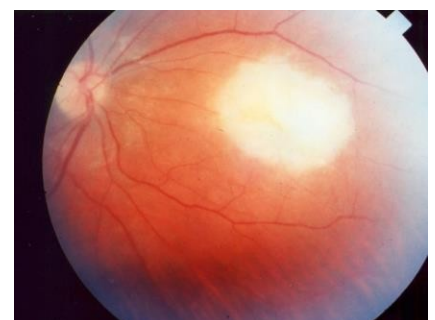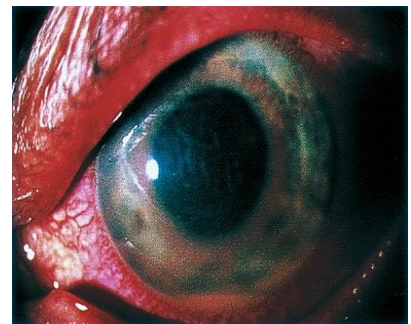- Etiology:

1- Idiopathic **50%**

2- Inflammatory diseases:

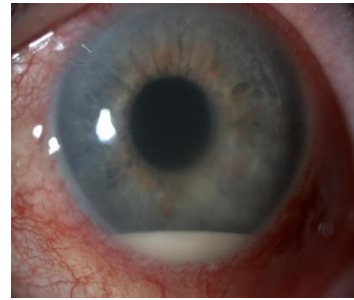
HLA B27, Ankylosing spondylitis, IBD, Reiter's syndrome, Psoriatic arthritis.

Sarcoidosis, Behcet's, Vogt-Koyanagi-Harada Syndrome.



3- Infectious:

- Herpes virus.
- Toxoplasmosis; transmitted through cats.
- Secondary Tuberculosis; granulomatous uveitis (common in KSA, India) – give anti Tb and steroids.
- Sarcoidosis; granulomatous uveitis (USA).
- Syphilis.



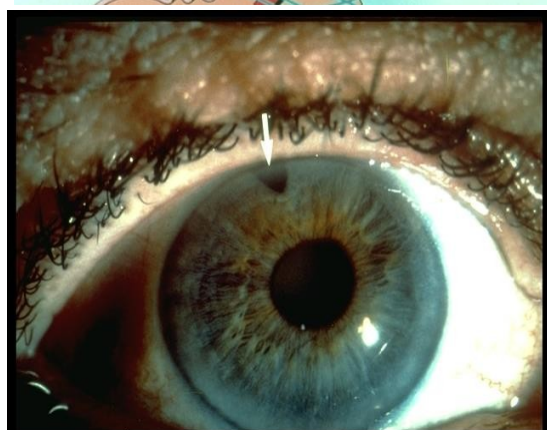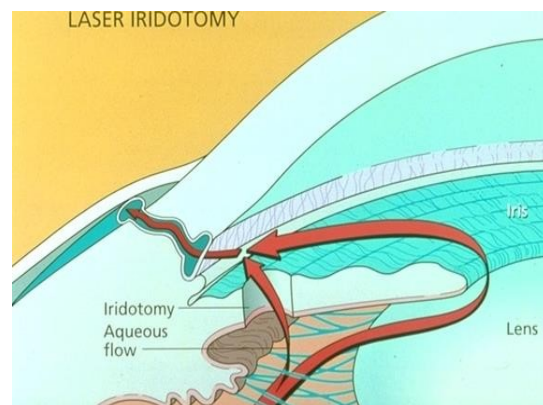
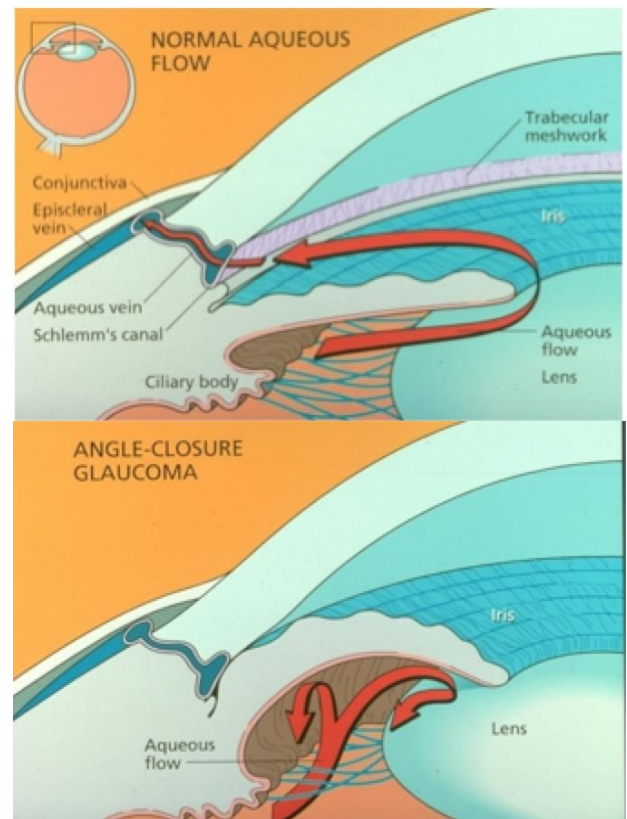
- Hypopyon secondary to uveitis

Management:

1. Identify possible cause.
2. **Topical steroid “first”**.
3. **Topical cycloplegic.** "paralysis of the ciliary muscle of the eye, resulting in a loss of accommodation."
4. Systemic immunosuppressive medication “according to workup, either shift to systemic or continue topical”.
 - Steroid.
 - Cyclosporine.
 - Methotrexate.
 - Azathioprine.
 - Cyclophosphamide.
5. Immunomodulating agents.
 - Infliximab (Anti TNF).

Acute Angle Closure Glaucoma:

- When the peripheral iris bunched up in the angle this resistance is increased and the increased pressure gradient bows the iris forward and closes the drainage angle.
- Result from **peripheral iris blocking** the outflow of fluid
- Normal IOP 10 to 21 mmHg
 - o How the patients will present?
- Present with **pain, redness, mid-dilated pupil** with decrease vision and colored haloes around lights
- Severe **headache** or nausea and vomiting
- Intraocular pressure is elevated
- Can cause **severe visual loss** due to optic nerve damage
 - o Typical history: while dimming the light.
Glaucoma increases at night more than morning because of pupil dilation at night.
 - o Medical treatment and peripheral **laser iridotomy** will be curative in most cases.

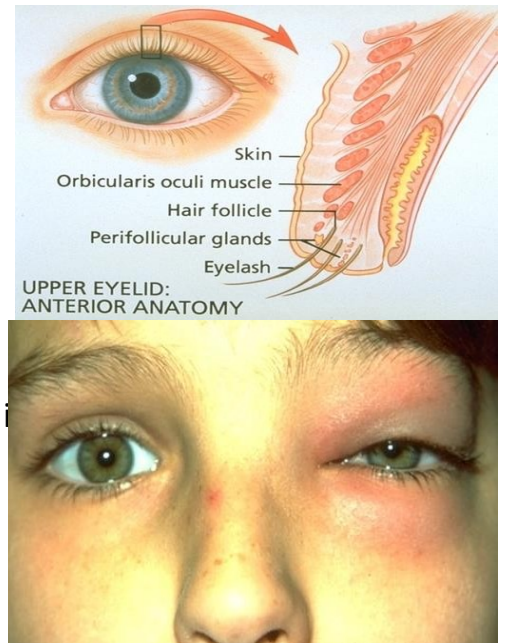


Preseptal cellulitis:

- Lid swelling and erythema
- To rule out orbital cellulitis Visual acuity, motility, pupils, and globe should be normal.

Etiology:

- Skin wound
- Laceration
- Retained foreign body from trauma
- Vascular extension, or extension from sinuses or another (e.g., dacryocystitis, chalazion)
- **Organisms:**
Staph aureus – Streptococci-
H.influenzae usually if less than five year.



Management

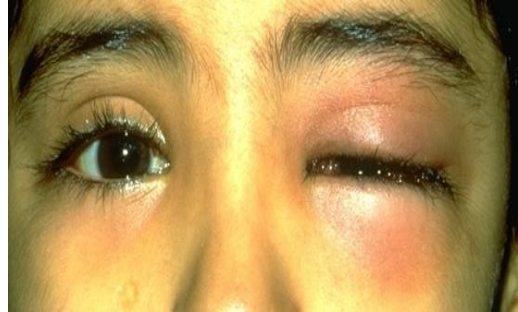- Need to be treated properly to avoid extension of the infection to the orbit, which cause orbital cellulitis.
- **Warm compresses:** vasodilatation to increase WBCs and chemotaxis.
- Systemic oral antibiotics. Without admitting the patient
- If suspicious to have sinusitis do CT.
- CT sinuses and orbit if not better or +ve history of trauma.

Cold compression:
vasoconstriction --- Usually
used for allergy

Infectious problem --- warm
compression

Orbital Cellulitis

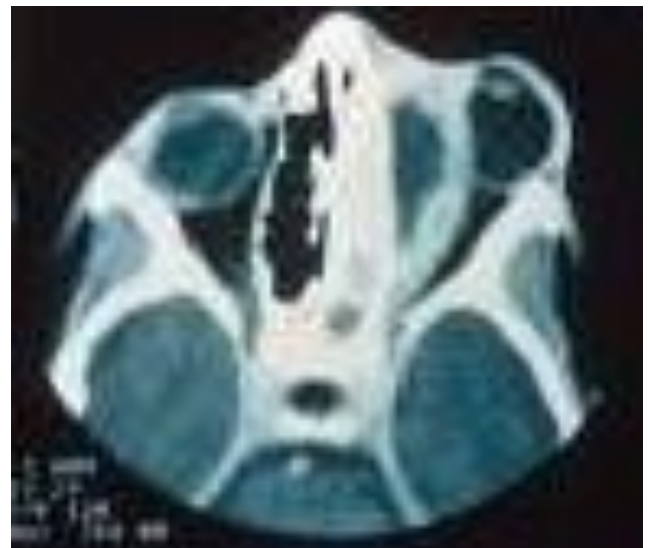- **More serious** than preseptal cellulitis because it may go to the brain and lead to death.
- May be a consequence of preseptal cellulitis.
 - Pain, **Decreased vision**.
 - Impaired ocular motility/double vision
 - Afferent pupillary defect
 - Conjunctival chemosis and injection
 - Proptosis
 - Optic nerve swelling **on fundus exam**



Motility, pupil reaction, fundal exam, color vision need to be tested to check optic nerve function.

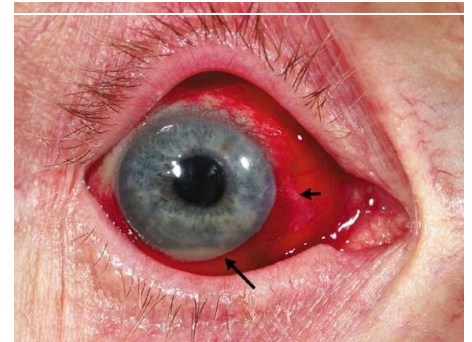Management:

- 1. Admission.**
- 2. Intravenous antibiotics**
- 3. Nasopharynx and blood cultures**
- 4. Surgery may be necessary**
as in case of subperiosteal abscess.



Endophthalmitis: (extreme ophthalmic emergency)

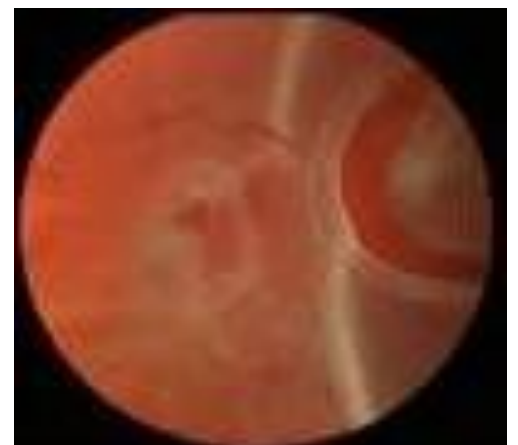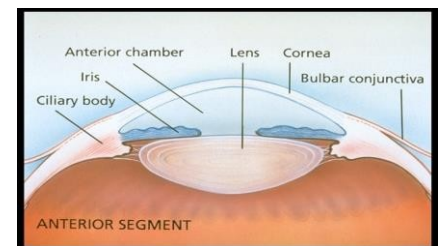
- Potentially devastating complication of any intraocular surgery
- Secondary to trauma or post-surgery (channel from outside to inside which cause bacterial entry and it found good environment to live in as there is no direct blood vessels in the vitreous to provide strong immunity)
- Sometimes the destruction is due to the inflammation not the infection itself
- Any patient in the early postoperative period (within 6 weeks of surgery) c/o pain or decrease vision should be evaluated immediately.



Sever redness, lid edema and hypopyon and on exam you find vitritis

Management:

- Vitreous sample for culture
- Intravitreal antibiotics injection plus topical antibiotics.
- Broad spectrum antibiotics or **Ceftazidime** and **Vancomycin**
- In sever infection the vitreous will be like an abscess in this case surgery is needed to drain it (Vitreotomy).
- If visualization of vitreous is not possible in case of severe infection, do B scan
- In decrease visual acuity (hand motion or less) Surgery is needed, if better give Intravitreal antibiotics only.
- Visual acuity will decide the treatment if Intravitreal antibiotics or surgery
- do surgery – if no response to antibiotics and Endophthalmitis secondary to blebitis.



Retinal Detachment:

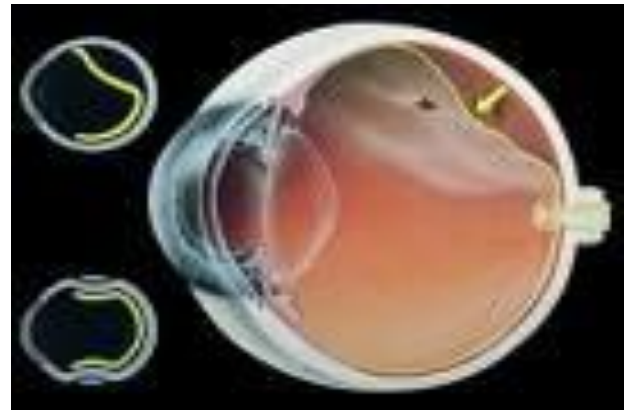
- If involving the macula (Macula off); poor prognosis and surgical intervention needed
- In the periphery (Macula on); better prognosis and quick surgical intervention
- **Retinal detachment: Intra-retinal separation between retinal pigment epithelium (RPE) and neurosensory layer.**
- **Retinoschisis: Separation between retina and choroid, no urgent intervention needed and usually congenital.**
- **Rhegmatogenous retinal detachment: (emergency and need surgery) common in people with high myopia** because they have peripheral breaks, fluid goes inside it and cause detachment.

Symptoms:

Flashes, floaters, a curtain or shadow moving over the field of vision.

Peripheral and/ or central visual loss.

History of scratching the eye



Management: the aim of the treatment is to close the causative break in the retina and to increase strength of the attachment between the surrounding retina and the RPE by inducing inflammation in that region.

Corneal Abrasion

Symptoms:

Foreign body sensation

Pain

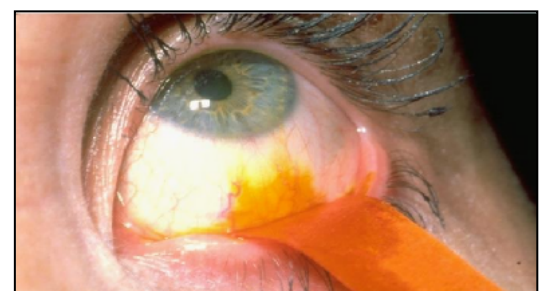
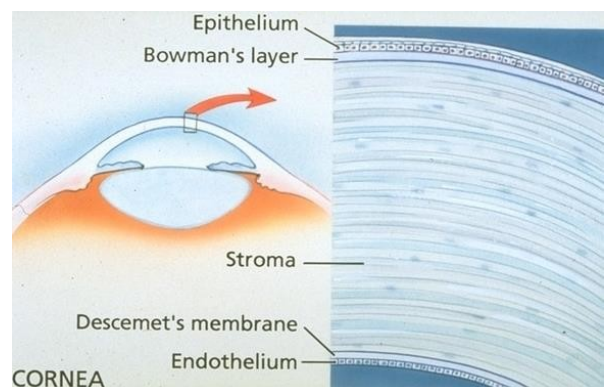
redness

Tearing

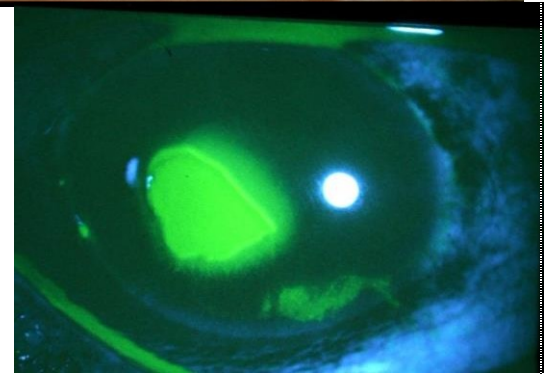
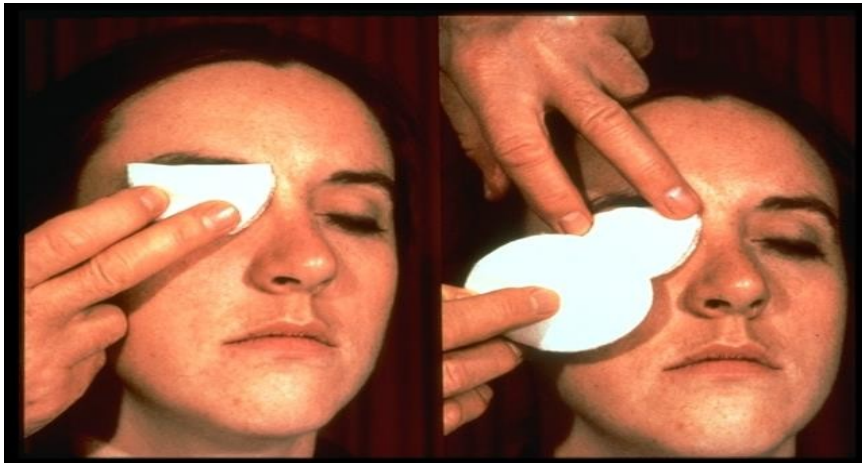
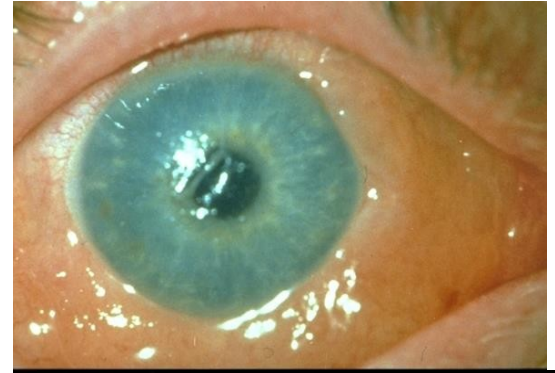
Photophobia

Treatment:

- Topical antibiotic
- Cycloplegia to dilate pupil to decrease pain



- Pressure patch over the eye
- Refer to ophthalmologist
- Important to treat to avoid infections
- If infection is suspected do scraping biopsy to rule it out.



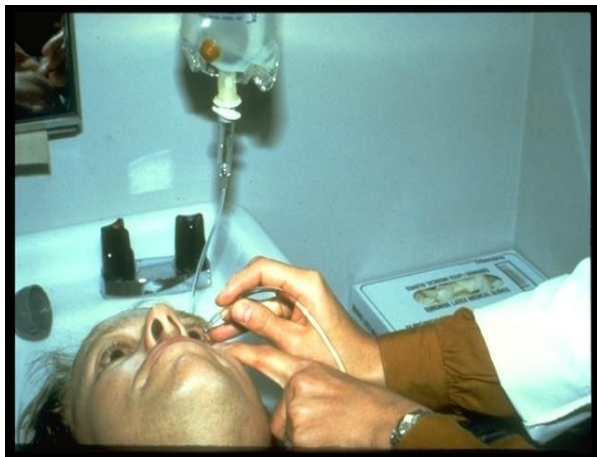
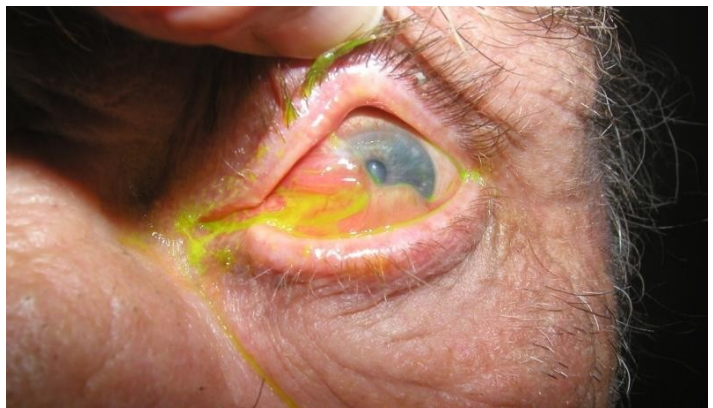Florescent dye shows epithelial defect

Chemical injuries:

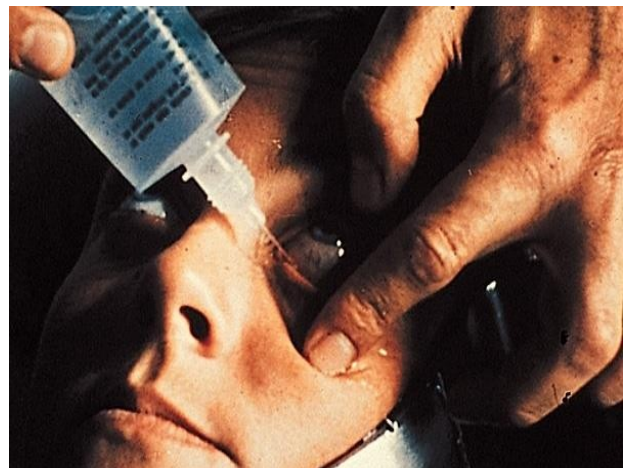- A vision-threatening emergency
- The offending chemical may be in the form of a solid, liquid, powder, mist, or vapor.
- Can occur in the home, most commonly from detergents, disinfectants, solvents, cosmetics, drain cleaners.....
- Alkaline chemical injury is worse because it will cause penetration.
- Can range in severity from mild irritation to complete destruction of the ocular surface
- It may be aggressive and destroy eye surface causing stem cell deficiency end up with blindness.
- Destruction of optic nerve common in case of glaucoma resulting from alkaline injury.

Management:

- Irrigate with clean water
- Instill topical anesthetic
- Check for and remove foreign bodies
- Immediate irrigation essential, preferably with saline or Ringer's lactate solution, for at least 30 minutes.
- Irrigation should be continued until neutral pH is reached (i.e., 7.0)
- Instill topical antibiotic
- Frequent lubrications
- Oral pain medication
- Enhance healing

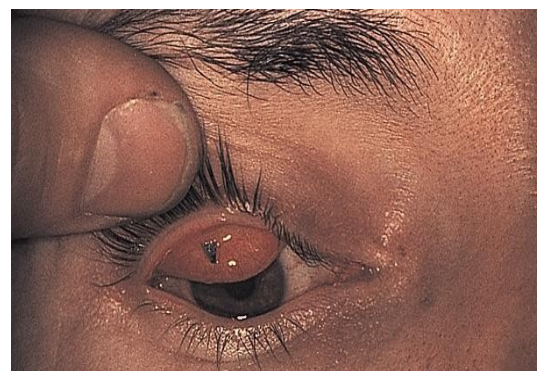

Corneal and Conjunctival Foreign Bodies



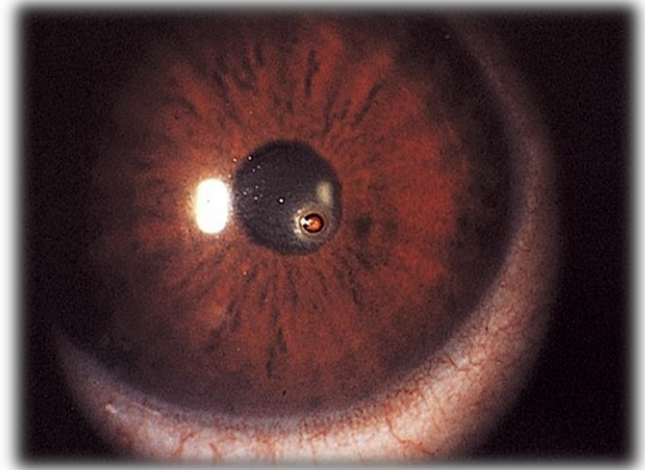
Corneal and Conjunctival Foreign Bodies:

- History of trauma
- Foreign Body Sensation-Tearing



Management:

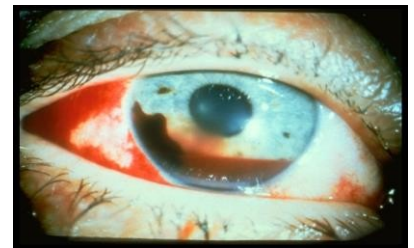
- Instill topical anesthetic.
- Removal of the foreign body.
- Topical antibiotic.
- Treat corneal abrasion.



Hyphema:

Hyphema is defined as the presence of blood within the aqueous fluid of the anterior chamber. The most common cause of hyphema is trauma.

- Can occur with blunt or penetrating injury
- Blood in the anterior chamber
- Can lead to high intraocular pressure
- Detailed history (**Sickle cell**)



Management:

- 1- Bed rest to prevent re-bleeding.
- 2- Topical steroid to reduce inflammation
- 3- Topical cycloplegic to cause pupil dilatation then prevent accommodation to prevent dislodging of the clot which cause re-bleeding.
- 4- Antifibrinolysis agents (Tranexamic acid)
- 5- Surgical evacuation if increase IOP, stays more than five days and not responding to treatment.

If total wait for 3 days if not responding and pressure more than 30mmHg do Surgical evacuation, Not total wait for 5 days if pressure less than 30 mmHg.

- 6- Sickle cell anemia patients need immediate intervention.

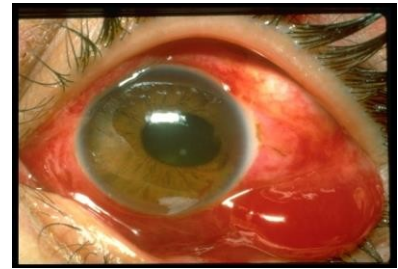Raptured Globe:

Suspect a ruptured globe if:

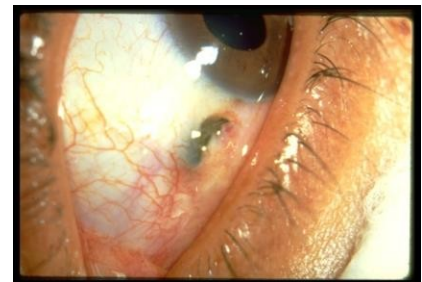- Severe blunt trauma: **rapture at weak part of the eye which is insertion of the muscles and lamina coribrosa.**
- Sharp object.
- Bullous sub conjunctival hemorrhage
- Uveal prolapse (Iris or ciliary body)
- Irregular pupil
- Hyphema
- Vitreous hemorrhage
- Lens opacity
- Lowered intraocular pressure

IF suspect a ruptured globe:

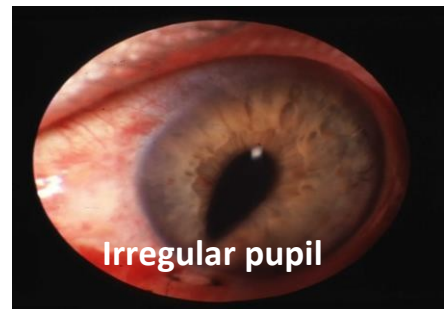
- 1- Stop examination
- 2- Shield the eye
- 3- Give tetanus prophylaxis
- 4- Refer immediately to ophthalmologist



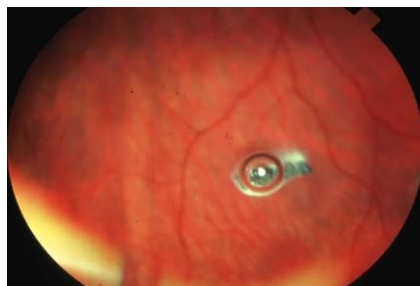Bullous sub conjunctival hemorrhage



Uveal prolapse (Iris or ciliary body)



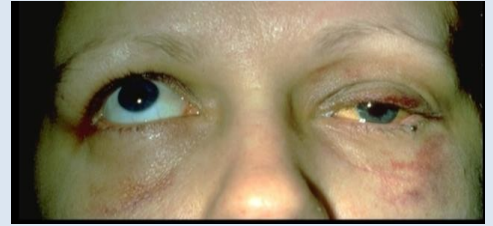
Irregular pupil



Intraocular foreign body

Orbital fracture:

- Assess ocular motility
- Assess sensation over cheek and lip
- Palpate for bony abnormality
- **Enophthalmos; eye sinking inside**



When evaluating orbital fractures, focus on the following exam findings:

1. Vision, color: Make sure the optic nerve isn't involved.
2. Extraocular movements: Usually decreased from swelling or muscle contusion, but make sure there isn't any gross muscle entrapment. If concerned, you can perform forced ductions. This involves pulling on the eye with forceps to see if the eye is mobile.
3. Proptosis: Measure the degree of proptosis or enophthalmos using the Hertel exophthalmometer (a fancy ruler).
4. Palpate: Feel along the orbital rim for step-off fractures and subcutaneous emphysema (air crepitus).
5. Sensation: Check sensation of the V1 and V2 sensation on the forehead and cheek. V2 runs along the orbital floor and can be damaged with floor fractures.

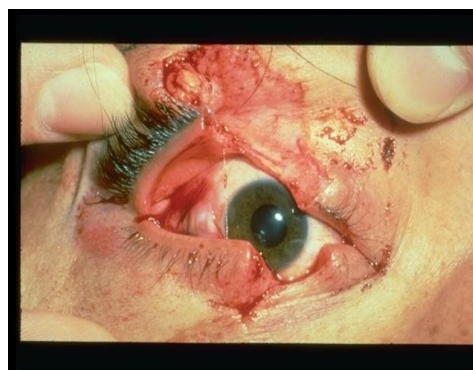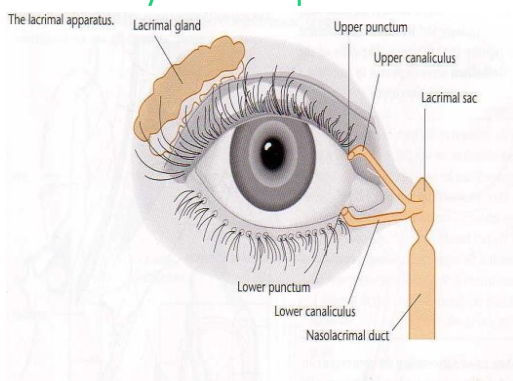
*OphthoBook

Lid Laceration:

- Can result from sharp or blunt trauma
- Rule out associated ocular injury

Treatment: surgery (approximate the lids and close them following normal anatomy)

If approximation is not following the normal anatomy: patient will have problems (the lids will be deformed, tearing won't be appropriate and the eye will be prone to infections)



Summary

- **Corneal ulcer** occur secondary to lid and conjunctival inflammation but it is often secondary to trauma or contact lens wear.
- Start treatment immediately with antimicrobial, broad spectrum antibiotics that covers gram +ve and –ve
- **Uveitis:** Inflammation of the uveal tissue (**iris, ciliary body, or choroid**), **retina, blood vessels, optic disc, and vitreous** can be involved.
- **Acute Angle Closure Glaucoma:** Can cause severe visual loss due to optic nerve damage.
- **Best coverage for pseudomonas is Ceftazidime.**
- **Preseptal cellulitis** - need to be treated properly to avoid extension of the infection to the orbit, which cause orbital cellulitis.
- In **Orbital cellulitis** admit patient and give IV antibiotics.
- In chemical injury do **immediate irrigation**.
- Sickle cell anemia patients need immediate intervention if presented with Hyphema.

1. You have a contact lens wearer with a small corneal abrasion. He is in excruciating pain and requests that you pressure-patch his eye for comfort. Will this speed up healing?

Patching may speed healing by keeping the eye immobile and lubricated - but you should never patch an abrasion that might fester an infection. Thus, you don't patch contact lens wearers as you don't want a pseudomonas infection brewing under that patch! If you decide to patch a patient, you should really follow them closely to make sure they don't develop an ulcer.

2. What findings would prompt you to take a patient with an orbital floor fracture to surgery?

If the patient has muscle entrapment or significant enophthalmos. Most patients have some degree of EOM restriction from soft-tissue swelling. Entrapment causing reflexive bradycardia would also push you toward surgery.

3. A patient accidentally splashes a large amount of bleach-based cleaner in her eye. What should she do?

Wash it out immediately - the faster, the better!!!! If an ambulance picks her up, have the EMTs irrigate in route, and alert the ER to irrigate her eyes as soon as she hits the door.

4. An African American presents with hyphema after trauma. What additional workup might you consider? Are there any medications you would avoid?

You may consider getting basic coagulation labs and a sickle prep. Avoid CAIs as these promote acidosis and can worsen sickling of blood in the anterior chamber and worsen glaucoma.

****OphthoBook**

Table 9.1 Some causes of uveitis (not an exhaustive list).

Infectious	Non-infectious ocular disease	Systemic disease-associated
Toxoplasmosis	Sympathetic ophthalmitis	Juvenile chronic arthritis
Herpes simplex	Fuchs' heterochromic cyclitis	Ankylosing spondylitis
CMV (AIDS)	Angle closure glaucoma	Psoriatic arthritis
Tuberculosis	Retinal detachment	Sarcoidosis
Fungal	Intraocular tumours	Behçet's disease
	Autoimmune reaction to advanced cataract. Phakogenic	Vogt-Koyanagi-Harada disease (VKH)
	Post-injury or surgery	Reiter's disease
		Inflammatory bowel disease

MCQs:

Q1: A female patient came to ER after a splash of chemical detergent into her eyes. She opens her eyes with difficulty and is complaining of severe pain.

What is the best initial management?

- A. Immediate eye irrigation
- B. Oral pain medication
- C. Put a clear shield on the eye
- D. topical anaesthetic drop

Q2: A 20-year-old patient presented with painless upper lid swelling of 3-month duration. What is the most common cause?

- A. Blepharitis
- B. Chalazion
- C. Dacrocystitis
- D. Dermoid Cyst

Q3: A patient presenting with lid swelling and fever but normal motility and vision and no proptosis. How to treat him?

- A. Oral Antibiotics without admitting the patient
- B. I.V Antibiotics and admitting the patient
- C. Intravitreal antibiotics and admitting the patient

Answers:

A, B, A (preseptal cellulitis)

Done By:

Othman Abid
Abdullah alasmari

Reviewed By:

Aisha Alraddadi
Sara Habis

