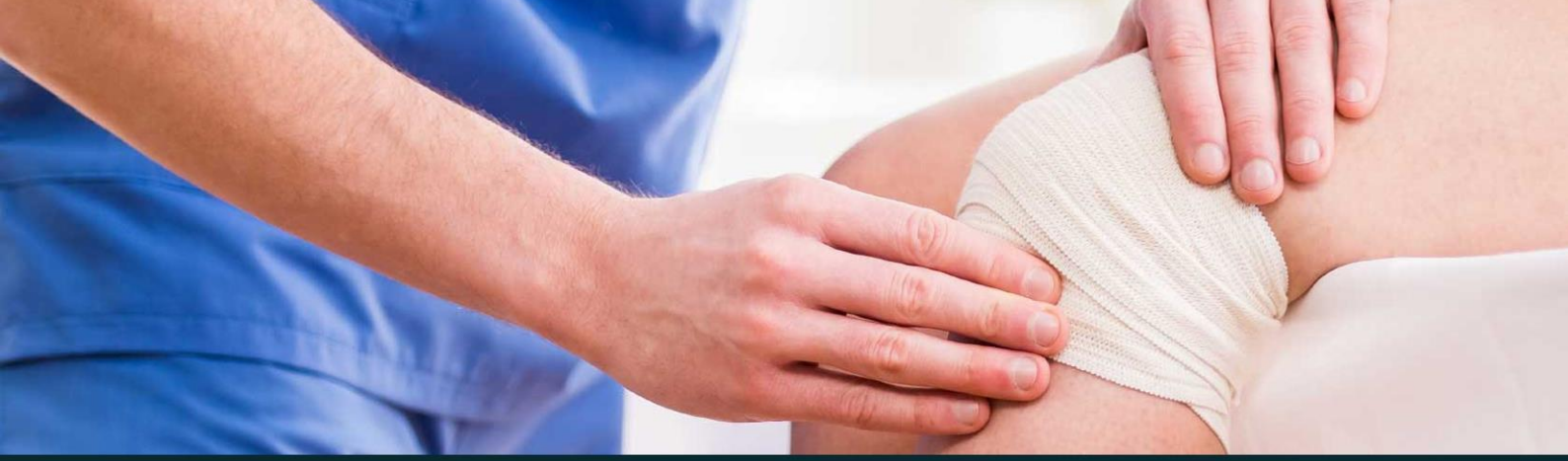



433 Teams  
**ORTHOPEDICS**

Lecture 3

**Compartment Syndrome and Acute Joint  
Dislocation**

[Ortho433@gmail.com](mailto:Ortho433@gmail.com)

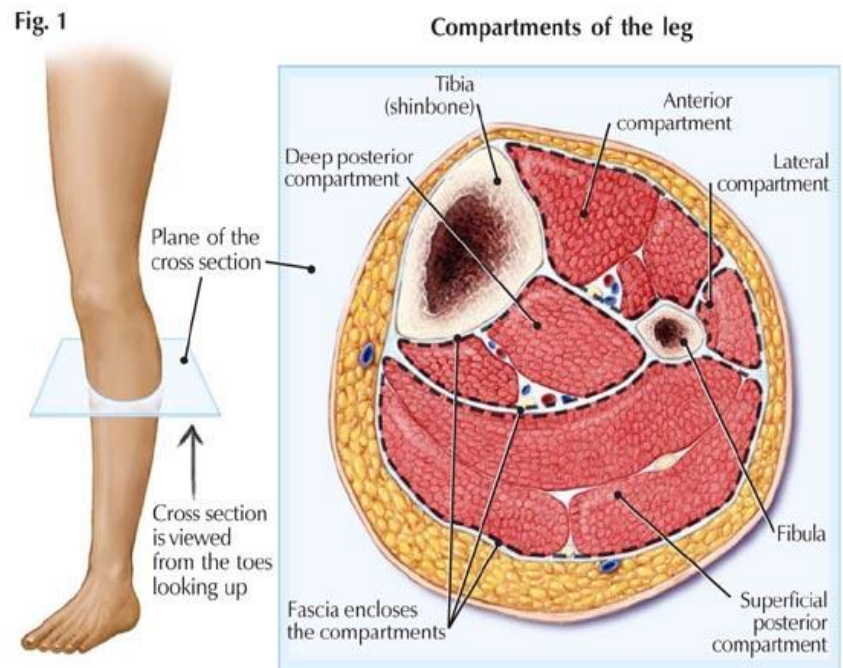


جامعة  
الملك سعود  
King Saud University



## Fascial Compartments

- Fascial compartment is a section within the body that contains muscles and nerves and surrounded by fascia.
- i.e. The leg has 4 compartments: anterior, lateral, superficial and deep posterior compartments. All of them have separate nerves and blood vessels that supply each compartment.



- Normally the pressure of the compartment is lower than the systemic diastolic pressure; to facilitate the diffusion and exchange in the capillary bed.
  - The normal pressure of a tissue compartment falls between 0 and 8 mmHg

## Acute Compartment Syndrome:

### • Introduction:

- Compartment syndrome occurs when **increased pressure within a compartment compromises the circulation and function of the tissues within that space.**
- Compartment syndrome may occur acutely, often following trauma, or as a chronic syndrome, seen most often in athletes, that presents as insidious pain. Acute compartment syndrome (ACS) is a surgical emergency.

### • Pathophysiology:

- Ischemia begins when local blood flow cannot meet the metabolic demands of surrounding tissue.

- **As compartment pressure rises, venous outflow is reduced and venous pressure rises, leading to a decrease in the arteriovenous pressure gradient.**
- Ultimately arteriolar pressure is insufficient to overcome compartment pressure and blood is shunted away from intracompartmental tissues.
- Arterioles collapse when tissue pressure exceeds end-arteriolar pressure.
- Inadequate venous drainage results in tissue edema and a rise in interstitial pressure.
- Lymphatic drainage may compensate in part initially, but is soon overwhelmed.

- **Risk Factor:**

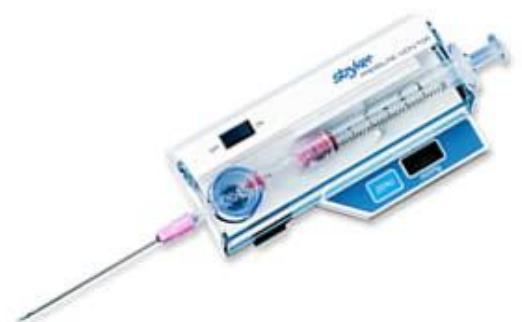- **General cause:**

- Hypotension: It is a co-factor to trauma or direct cause. E.g. patient after RTA may develop hypovolemia that leads to hypotension, which decreases the difference between the diastolic blood pressure and the compartment pressure (delta pressure), which leads to acute compartment syndrome.
- Head injury: Unconscious or obtunded patients with prolonged limb compression can develop ACS secondary to soft tissue injury and swelling.

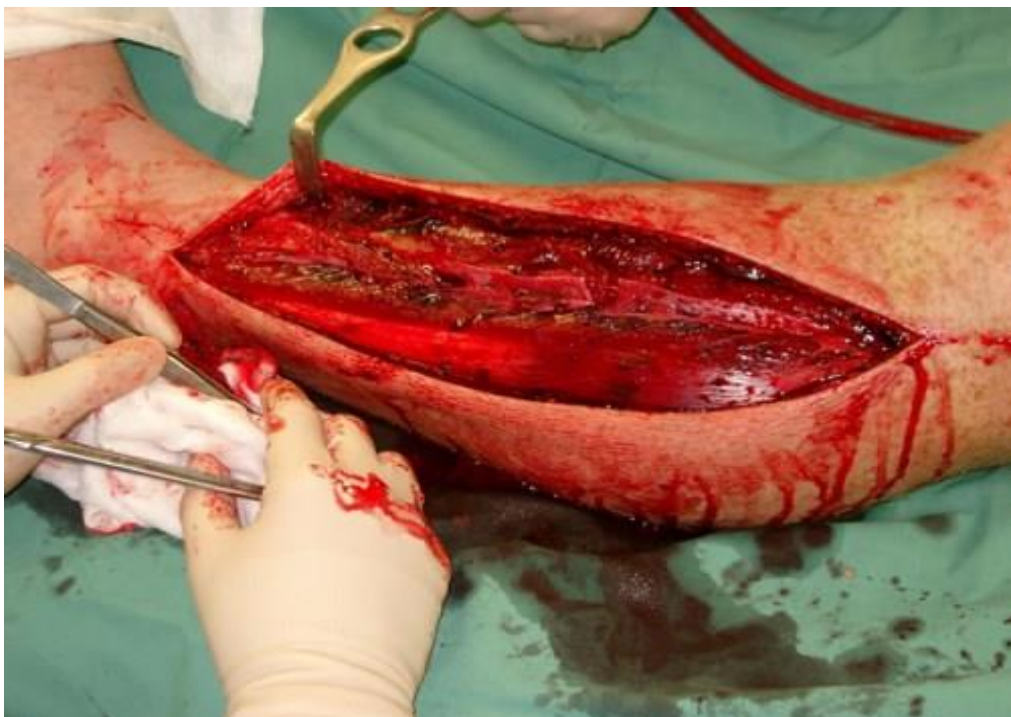- **Local Causes:**

- **Trauma:** crush (the worst), or fracture (75%). How? Cell damage > leakage of cell fluid > Edema intracompartmently > increased compartment pressure > ACS!
- **Thermal injuries:** particularly full-thickness burns. Secondary to tissue constriction, eschar, and edema. The large fluid shifts associated with major burns also contribute.
- Injection: following intravenous or inadvertent intraarterial injection of drugs.
- **Bleeding:** Arterial bleeding increases compartment pressures and muscle deprived of arterial blood flow becomes ischemic and prone to reperfusion injury, which in turn causes swelling and a further increase in compartment pressures.

- Prolonged vascular occlusion (reperfusion injury): Tissue Damage caused by return of blood flow after a period of ischemia.
  - Venomous bite
  - Intra-osseous fluid replacement
  - IV fluid extravasation when fluid enters the compartment it may increase the pressure causing compartment syndrome
  - Tight bandage
  - Post-surgery: symptoms can mimic postoperative pain making the diagnosis difficult.
- **Diagnosis:**
  - Early:
    - Pain out of proportion to apparent injury.
    - Increases while stretching the involved compartment. Eg. dorsiflexion to check the posterior compartment of the leg.
    - High index of suspicion
    - Presence of Risk Factors.
    - Measurement of compartment pressure is high “rarely done”
  - Late: 4 Ps: Paralysis, Paresthesia, Pallor and Pulslessness.
    - Pulslessness usually not common; very high compartment pressure to cause it.
    - Tight, woody compartment
    - Tender compartment
    - Measurements Rarely necessary, must be done at area of highest expected pressure and may give false low result
  - Time window for CS is 6 Hours. But it varies to each situation.
  - **Intracompartment pressure measurement:**
    - Capillary blood flow becomes compromised when compartment pressure increases to **within 25 to 30 mmHg of mean arterial pressure.** Eg. BP 90/60, compartment pressure 35, the later is within 25-30 of MAP.
    - ACS delta pressure = diastolic blood pressure – measured compartment pressure



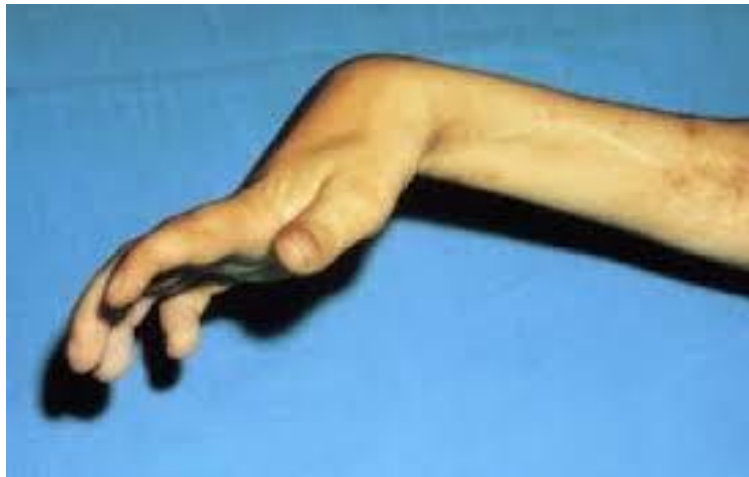- ACS delta pressure <20 to 30 mmHg strongly suggests ACS and require urgent fasciotomy.
- **Management:**
- **Initial (undeveloped CS):**
  - Maintain normal blood pressure, with boluses of intravenous isotonic saline.
  - Relieving all external pressure on the compartment, dressing, splint, cast...etc.
  - Elevate the limb at heart level; to avoid reductions in arterial inflow and increases in compartment pressures from dependent swelling.
  - Regular close monitoring (15-30 minute intervals).
  - Avoid nerve blocks, sedation and strong analgesia to obtain patients feedback.
- **Fully developed ACS:**
  - **Fasciotomy to fully decompress all involved compartments is the definitive treatment for ACS in the great majority of cases**
  - Diuresis to avoid kidney tubular injury if late.
- **Fasciotomy:**
  - A fasciotomy consists of one or more fascial incisions and remains the only effective way to treat ACS.
  - Allows swollen muscles to expand in volume that results in decreased compartment pressure and avoids further damage.
  - **Debridement of all necrotic tissue is necessary.**
  - **It is indicated in the following:**
    - 6 hours of total ischemia time.



- Significant tissue injury.
- Worsening initial clinical picture.
- Delayed presentation with a picture of developed CS.
- Absolute Compartment pressure >30 mmHg or <30 mmHg difference from diastolic pressure.
- Ideally should be done as soon as diagnosis is made, and should be done as long as there is still viable tissue.
- **it should be avoided when the muscle is already dead;** fasciotomy in such instances provides no benefit and increase the risk of infection. Definitive treatment for such injuries often involves amputation.
- Second and third look surgeries are often required.
- Closure of skin is usually achieved after swelling has subsided, and skin grafting is often required.

### • Complications:

- **Myonecrosis**, leads to **myoglobinemia**, then **myoglobinuria** that results in **kidney tubular damage**.
- Loss of function of the involved compartment:
  - Flexion contracture
  - Paralysis
  - Loss of sensation
  - Leg:
    - Anterior compartment: Drop foot we give him splint to protect his toes while walking
    - Deep posterior compartment: Clawed toes and Loss of sensation in the sole
  - Forearm:
    - **Volar compartment** > **Volkman contracture**



## Acute Joint Dislocation:

- **Introduction:**

- **Joint stability:**

- Bony stability:
  - Shape of the joint (ball and socket like hip joint and it is a very stable joint vs round on flat like shoulder joint)
- Soft Tissue:
  - Dynamic stabilizer:
    - Tendons/Muscles: patella can move laterally but when quadriceps contracts; it comes back to its place.
  - Static stabilizer: Ligaments ± meniscus/labrum
    - When leg moves to valgus or varus, it holds its place because of tendons and ligaments mostly. Also shoulder, what keeps humerus stable in its place is the capsule and the labrum.
  - Complex synergy leading to a FUNCTIONAL and STABLE joint.

- **Joint dislocation:**

- Dislocation is a **total loss of contact** between the articular surfaces of the joint while **Subluxation is a partial loss of contact** between the articular surfaces of the joint.
- Risk groups are:
  - Major trauma victims especially unconscious patient
  - Athletes and sport enthusiasts
  - Connective tissue disorder patient; due to increased joint instability in result of abnormal soft tissue stabilizers.
- Dislocation of a major joint should lead to considering other injuries.
  - Major joints: Spine, shoulder, elbow, wrist, hip, knee and ankle
- Different joints have different force vectors that may lead to a

dislocation

- It depends on the direction of the force and the position of the joint while receiving this force.
- A joint dislocation is described by stating the location of the distal segment
  - Anterior shoulder dislocation: anterior displacement of the humeral head relative to the glenoid.
  - Posterior hip dislocation: posterior displacement of the femoral head relative to the acetabulum.
  - When a joint is strained:
    - It may be sprain
    - It may be fracture
    - It may be dislocated
    - It may be fracture and dislocated
- ✓ Damage to the labrum Bankart's lesion, and capsule
- ✓ Damage to the head of humerus
  
- **Diagnosis:**
  - **History** of a traumatic event (major trauma or any trauma with the limb in high risk position)
    - **Pain** and **inability** to use the limb
    - Deformity
    - **Shortening**
    - **Malalignment**
    - **Malrotation**
  - **X-ray** is the milestone in diagnosing dislocation:
    - Should be done urgently without delay if dislocation is suspected
    - Two perpendicular views of the involved joint.
    - Occasionally, special views are required such as the axillary view for shoulder dislocation
    - X-rays to the joint above and below.
  - Should check for **other injuries** (distracting injury)
  - Should always check the **distal neurovascular status**. □
  - Should check for **compartment syndrome**.
  
- **Managements:**
  - Must rule out other injuries.
  - Pain relief.



- Urgent reduction.
- Check stability and safety zone. After reduction you move the limb in all directions till you feel that at a certain level he might dislocate his joint again. Then after that you tell him not to move his limb above this level.
- Check neurovascular status after reduction.
- X-rays after reduction.
- Protect the joint for 2 to 3 week to heal and after that send them to physical thereby department.
- Rehabilitation.
- Follow for late complications.

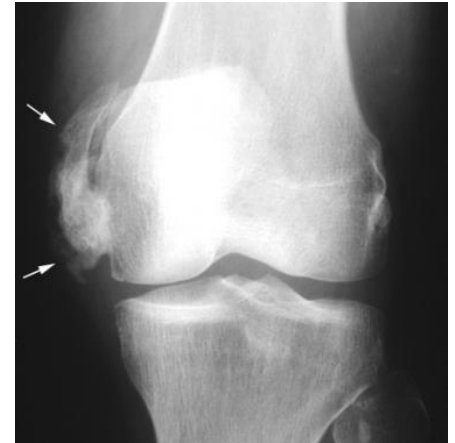- **Reduction:**

- Monitor **vitals**.
- IV **analgesia** (opioid).
- IV **sedation** (to relax the muscles).
- **Gradual traction** to distract the joint.
- **Realignment and rotation** to reduce the joint based on direction of dislocation.
- A **palpable clunk** will be felt.
- **Check ROM** and stability of the joint.
- Once joint is felt to be reduced, **check distal NV status**.
  - If it was intact before but not after, farther urgent management is needed.
  - If it was not present before but intact after, check again later to confirm.
- **Observe patients vitals** until medications wear out.
- **Stabilize joint** and get **X-rays**.
- If irreducible or partial reduction only:
  - Urgent closed reduction under general anesthesia and possible open reduction if closed reduction fails, Usually due to insufficient muscle relaxation or Entrapment of soft tissue.

## • Complications:

### • Early Complications:

- Heterotopic ossification. (bone formation at an abnormal anatomical site, usually in soft tissue, see picture)
- Neurological injury (reversible or irreversible)
- Vascular injury (more commonly with neurological injuries)
- Compartment syndrome
- Osteochondral fracture/injury

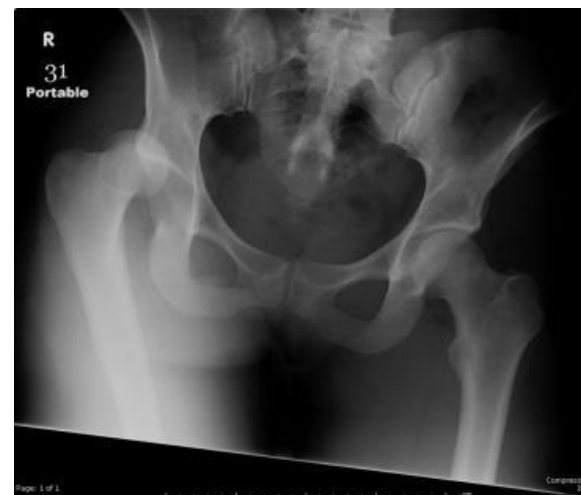

### • Late complications:

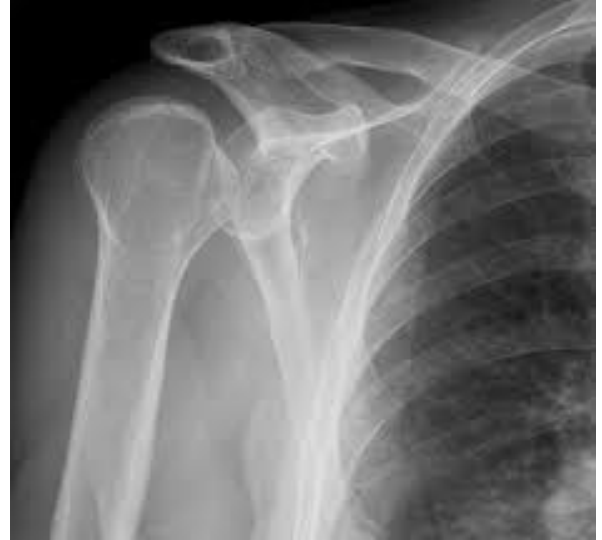- Stiffness
- Heterotopic ossification
- Chronic instability more common in shoulder joint
- Avascular necrosis it may appear after 4 to 6 month and more common in the head of femur
- Osteoarthritis

## • Special consideration:

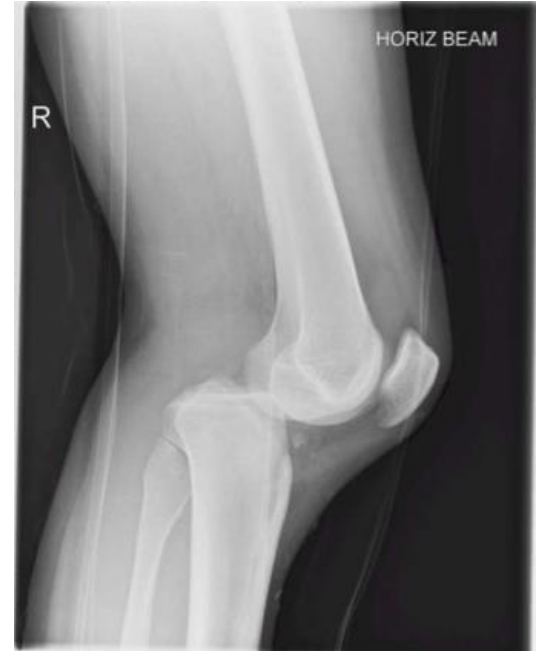- **Hip joint Dislocation:**
- Posterior dislocation is commonest
- An orthopedic emergency!
- Major trauma with hip flexed (dashboard injury in RTAs)
- Sciatic nerve injury is common; check extension and flexion of the big toe.
- High incidence of late avascular necrosis



- **Shoulder dislocation:**
- Common.
- **Anterior dislocation is more common**
- Patients with seizures prone to posterior dislocation. □ (Because they can't protect themselves when they fall while having a seizure)
- May cause chronic instability.
- Can result in axillary nerve injury and **wasting in deltoid muscle and numbness over its area.**



- **Knee dislocation:**
  - **Very serious emergency.**
  - It could be anterior dislocation or posterior dislocation.
  - Three or more ligaments are teared.
  - Usually with severe (high energy) trauma.
  - May be associated with **popliteal artery injury or peroneal nerve injury.**
  - Limb threatening and needs accurate vascular assessment.
  - May be associated with fracture/ compartment syndrome.
  - Most require surgery either early or late or both.



# Done By:

Faisal Alghamdi	
Ahmad Alzoman	

