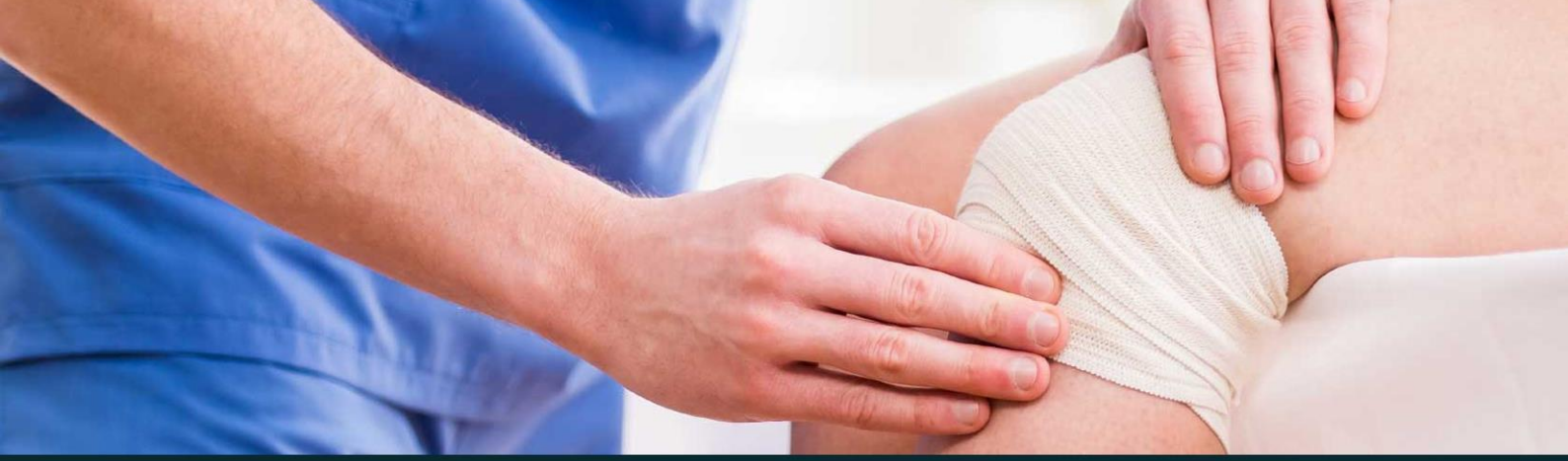



433 Teams  
**ORTHOPEDICS**

**Lecture 7**

**Bone and Joint Infections**

Ortho433@gmail.com

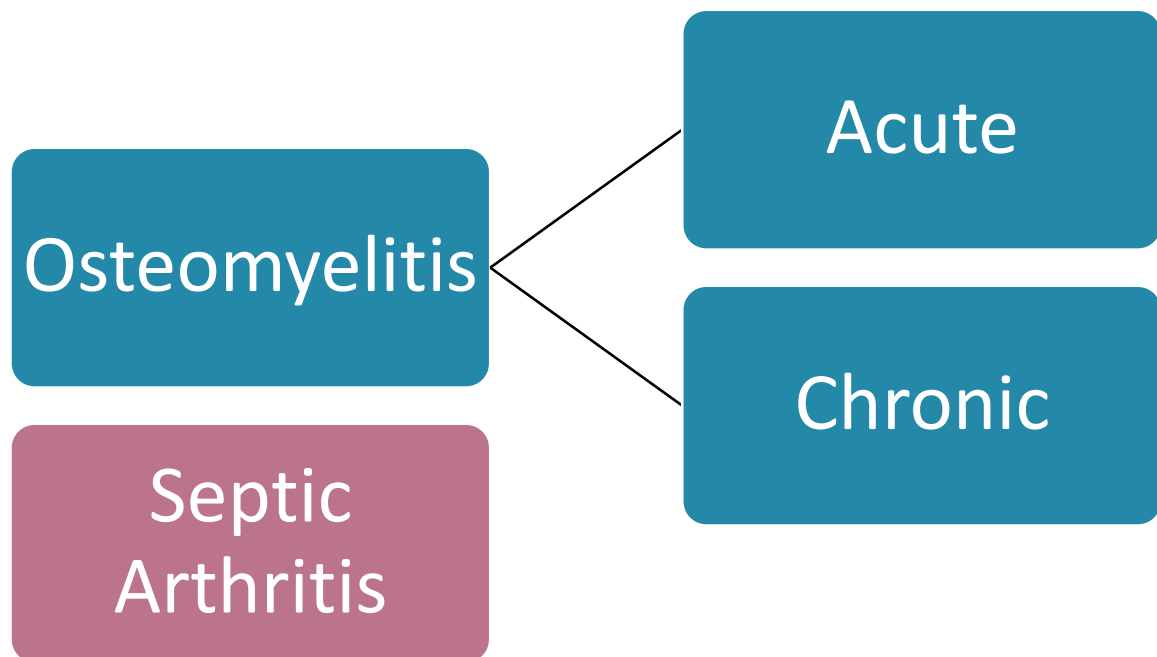


جامعة  
الملك سعود  
King Saud University



## Objectives

- ❖ What is bone and joint infection?
- ❖ Why we consider bone and joint infection as a red flag.
- ❖ How does the presentation in children and adults differ?
- ❖ What are the most involved organisms in children and adults?
- ❖ How do we diagnose and confirm diagnosis of bone and joint infection?
- ❖ Principles of management of bone and joint infection.
- ❖ Complications of bone and joint infection.



## Terminology

**Pseudoparalysis:** Apparent paralysis due to voluntary inhibition of motion because of pain, incoordination, or other cause, but without actual paralysis.

# Acute Osteomyelitis

## Definition

Osteomyelitis is an inflammation of bone and bone marrow caused by an infecting organism. **It is a serious condition.**

It may remain:

- 1- Local
- 2- Spreads to marrow, cortex, periosteum and/or soft tissue.

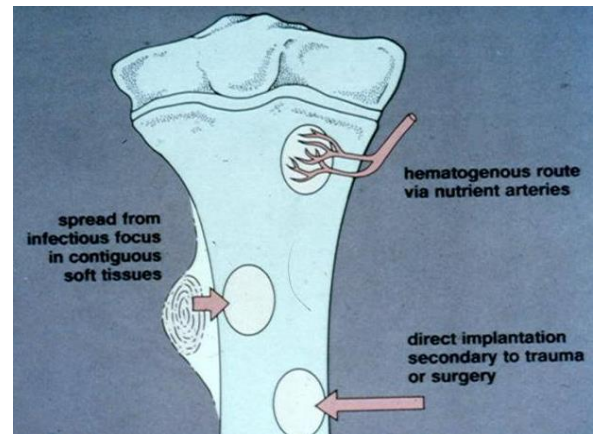
## Classification

### 1) Duration

- A) Acute less than 3 weeks
- B) Subacute 3-6 weeks
- C) Chronic >6 weeks

### 2) Route of Infection

- A) **Hematogenous:** (most common)
  - (tooth extraction, abrasions...)
- B) Exogenous:
  - (direct trauma, open fracture, surgery...)



hematoma is the best media for bacteria culture

**Organisms** (433 A1 doctor did not focus on this part but mentioned some points)

**Neonates:** **Staph aureus**, Strep, E coli.

**Children:** **Staph aureus**, E coli, Serratia, Pseudomona.

(H. influenza < 4 yrs., the most common in those whom not vaccinated [rural areas], but generally rare).

**Sicklers:** Staph aureus, **Salmonella** (most unique).

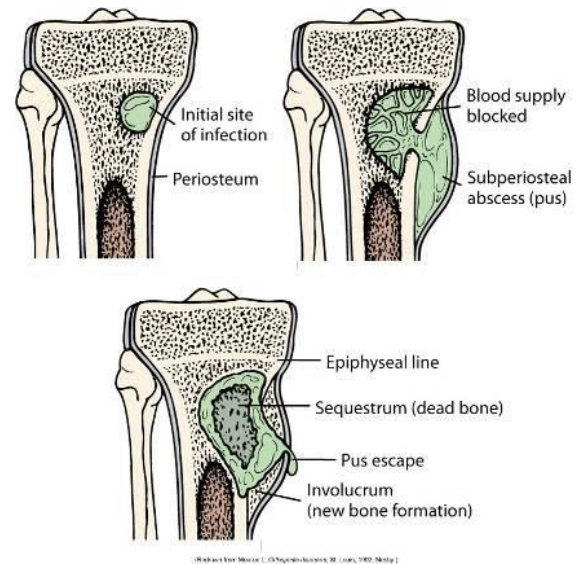
**Drug addicts:** **Staph aureus**, Pseudomonas (most unique).

**The causal organism is usually Staphylococcus aureus (found in over 70% of cases),** less often **Streptococcus pyogenes** or **S. pneumoniae**.

**Less common infections:** **Tuberculosis**, **Brucellosis**, Syphilis and Fungal.

## Spread of infection

- I. Infection starts at bone marrow.
- II. Infection spreads to cortex and lifts up “stripping” periosteum; swelling becomes tense → **increase of pain**.
- III. Local blood vessels get obstructed.
- IV. Periosteum bursts into soft tissues and pus becomes under skin; eventually **spontaneous discharge**.
- V. If pus bursts into epiphysis; **epiphyseal arrest** will occur.
  - Increase in general symptoms with every step
  - The local spread is affected by gravity .( downward spread )



## Incidence

**Age:** more in children (between 2 and 6 yrs.)

**Sex:** Boys > Girls

**Site of infection:** Metaphysis, **why? \***

**Bones:** lower extremities > upper extremities. (Tibia > femur > humerus)

Commonest are tibia and femur. In children the organisms usually settle in the vascular metaphysis of a long bone, most often at the proximal or distal end of the femur or the proximal end of the tibia. (rich in blood supply)

**sickle-cell disease** patients are prone to infection by **Salmonella typhi**. (from apley's)

432

Predilection for this site has traditionally been attributed to the peculiar arrangement of the blood vessels in that area: the non-anastomosing terminal branches of the nutrient artery twist back in hair pin loops before entering the large network of sinusoidal veins; the relative vascular stasis and consequent lowered oxygen tension are believed to favor bacterial colonization

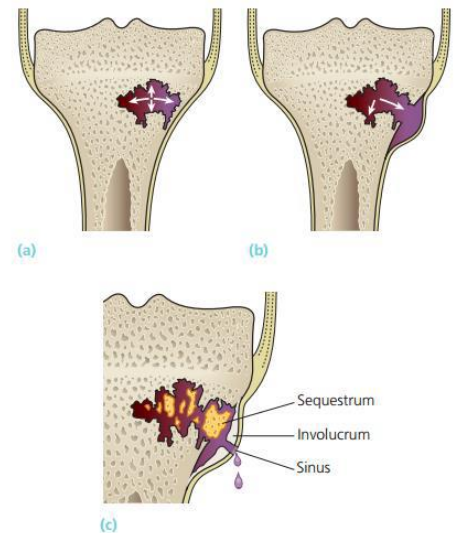
(form apley but the doctor had the same explanation so go through it) (432)

Doctor did not mention that (433)

## Risk factors

**Table 2.1 Factors predisposing to bone infection**

Malnutrition and general debility
Diabetes mellitus
Corticosteroid administration
Immune deficiency
Immunosuppressive drugs
Venous stasis in the limb
Peripheral vascular disease
Loss of sensibility
Iatrogenic invasive measures
Trauma



**2.2 Acute osteomyelitis** (a) Infection in the metaphysis may spread towards the surface, to form a subperiosteal abscess (b). Some of the bone may die, and is encased in periosteal new bone as a sequestrum (c). The encasing involucrum is sometimes perforated by sinuses.

## Sequestrum and Involucrum

### Sequestrum

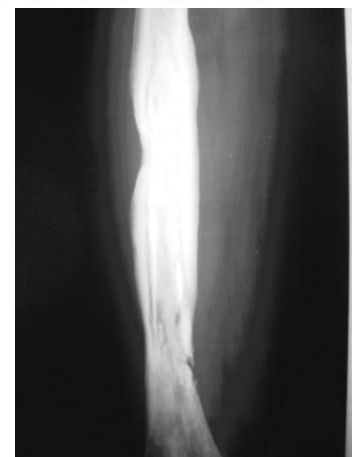
**Dead bone** separated piece from its surroundings.

This happens when blood supply is cut off from

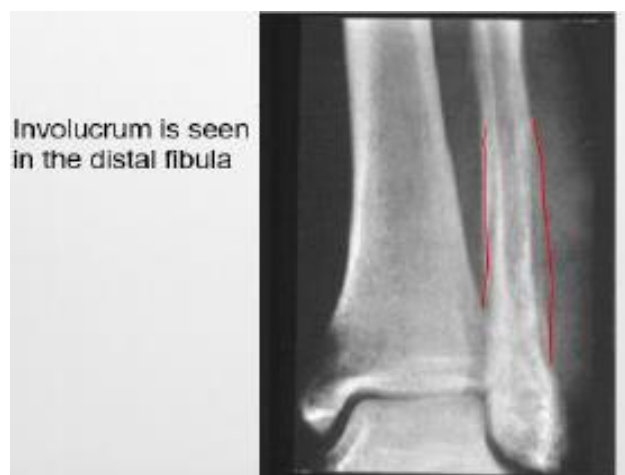It attracts bacteria, will lead to chronic osteomyelitis, and must be removed. (decrease WBC+ Antibiotic effect)

### Involucrum

**New bone** formed at site of infection and trapping a cavity of bone. (Sub periosteal)



**Plain x-ray showing:**  
Large sequestrum inside involucrum



Involucrum is seen in the distal fibula

## Clinical picture

### History & Symptoms

#### (General SSX)

- ❖ Fever
- ❖ Pain and tenderness
- ❖ Identified potential source like trauma
- ❖ Malaise
- ❖ Restlessness
- ❖ Vomiting usually seen in kids

#### (Local SSX)

- ❖ swelling at a limb usually near a joint like knee or hip or shoulder with increased local temperature.
- ❖ Pseudoparalysis, limping, inability to walk due to pain (patient will be in rest position)
- ❖ Tenderness
- ❖ Fluctuating fluid under skin

### Laboratory

- ❖ CBC: raised WBC (predominantly poly morphs.) (could be in normal range in immunocompromised)
- ❖ ESR: 24-36hrs (takes time to rise)
- ❖ C-reactive protein: 4-6hrs (the most sensitive monitor) (CRP is most sensitive because it rapidly increases and rapidly decreases with treatment)
  - ❖ ALT (increased), calcium, phosphorus.
- ❖ Blood cultures (positive up to 50% of cases); (ALWAYS do it if temperature above 38.5 C°)
- ❖ Aspiration (send for Gram stain and C&S)

#### CARDINAL FEATURES OF ACUTE OSTEOMYELITIS IN CHILDREN

Pain  
Fever  
Refusal to bear weight  
Elevated white cell count  
Elevated ESR  
Elevated CRP

## Radiology investigation

### Plain x-rays

(Usually normal but may not reveal any findings except **soft tissue swelling** at site of infection. Bony changes take up to 10 days to show suspected bone involvement, but osteopenia may appear earlier. Later on may show abscess formation(baseline) **(x ray is not diagnostic)**)

### Ultrasound

(may show pus below periosteum and it may show the defect earlier than x-ray)

### Isotope Bone scan

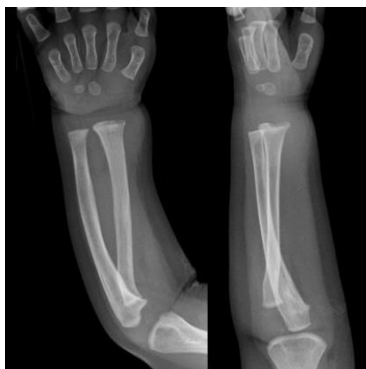**Tcm99 bone scan** or **Gallium bone scan (specific for infection)** are **diagnostic** “although doctor said it is not diagnostic”, as increased local tracer uptake; but **take time to appear** (needs 48 hrs)

### MRI

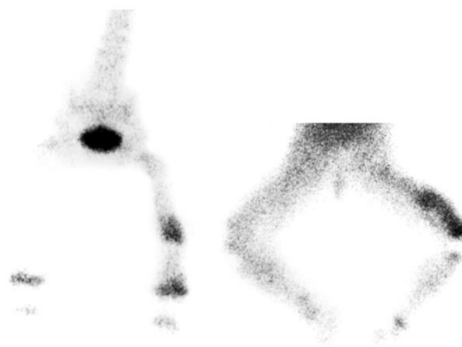
**the modality of choice** to detect early changes and for children.

(children require general anesthesia because of fear)

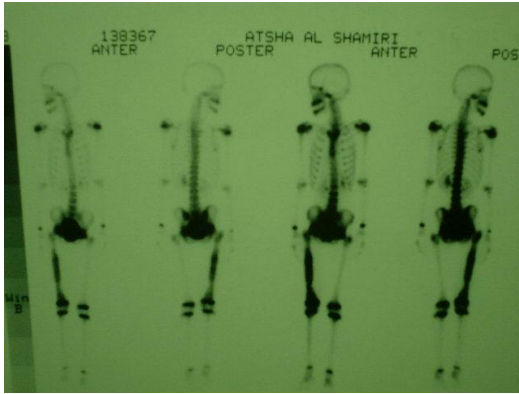
(Best diagnosis to localize the cavity)



**Plain x-rays in early days:**  
No bony changes, but soft tissue swelling may be evident.

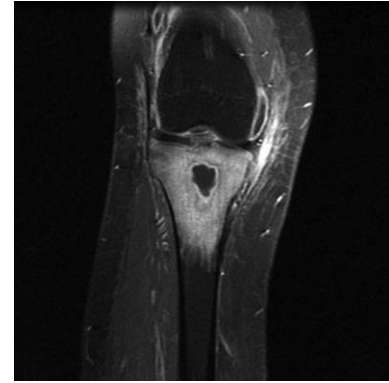


**Isotope bones scan:**  
Increased uptake in the lower left femur



#### Isotope bones scan:

Increased uptake of most of right femur



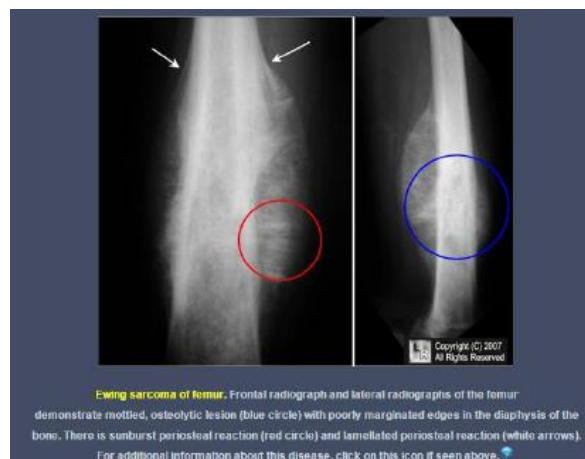#### MRI:

shows alter-signal in bone and bone marrow abscess before plain films

decreased T1-weighted bone marrow signal intensity  
increased post gadolinium fat-suppressed T1-weighted signal intensity  
increased T2-weighted signal relative to normal fat

## Differential Diagnosis

- ❖ **Acute septic arthritis (if it is close to joint)**
- ❖ **Cellulitis** this is often mistaken for osteomyelitis. There is widespread redness and lymphangitis. A source of skin infection may not be obvious and should be searched for (e.g. between the toes). If doubt remains about the diagnosis, MRI will help to distinguish between bone infection and soft-tissue infection. (from apley's)
- ❖ **Ewing's Sarcoma** "faster than other tumors" in children 5-10 yrs
- ❖ **Sickle cell bone crisis** patients with sickle-cell disease may present with features like those of acute osteomyelitis. Where Salmonella is endemic it would be wise to treat these patients with suitable antibiotics until infection is definitely excluded. (due to occlusion of blood vessels)
- ❖ **Acute rheumatoid arthritis** "not that common in KSA very rare"



**Ewing sarcoma of femur.** Frontal radiograph and lateral radiographs of the femur demonstrate mottled, osteolytic lesion (blue circle) with poorly margined edges in the diaphysis of the bone. There is sunburst periosteal reaction (red circle) and lamellated periosteal reaction (white arrows). For additional information about this disease, click on this icon if seen above.



## How to confirm diagnosis?

- Ultrasound guided aspiration from site of swelling or abscess.
- X-ray guided aspiration of suspected bone involvement (according to MRI).
- Via open incision –drainage procedure (drilling of bone) when there is high suspicion "you will see pus leakage".
- Aspirated or obtained material at open incision are sent urgently for **Direct Smear** and **Culture & sensitivity** "C&S" including anaerobic, TB and Fungal.
- Histo-pathology examinations are recommended as well. "good in TB"

## Treatment out line

- If osteomyelitis is suspected on clinical grounds (RED flag) , patient should be admitted immediately , blood and fluid **samples** should be taken for laboratory investigation and then treatment started **immediately** without waiting for final confirmation of the diagnosis.
- Patient should receive adequate hydration and pain relief at the same time as investigations.
- Pain relief include: analgesics and splint.
- Broad spectrum IV **antibiotics ( third generation cephalosporin)** is started **after obtaining material** for culture or sending blood culture when there is fever.
- **Definitive diagnosis depends on seeing organisms at direct smear, or culturing organisms**
- **Histo-pathology confirmation is important but usually result is late.**
- **When treating patients with bone or joint infection it is wise to maintain continuous collaboration with a specialist in microbiology**

## Empirical Treatment

- ❖ When patient is acutely ill; empirical IV antibiotic treatment to be started immediately after sending samples for culture.
- ❖ This empirical treatment depends on **suspected organisms** according to:
  - **Age:** Newborn, young or adult.
  - **Presence of other circumstances:** sickle cell disease or Hemodialysis or drug addicts.

### For sickle cell disease patients:

Salmonella is a characteristic organism, the primary treatment is fluoroquinolones "ciprofloxacin" (only in adults), and alternative treatment is 3<sup>rd</sup> generation cephalosporin.

### To simplify empirical treatment:

1. Always suspect **staph aureus**: ( oxacillins ) except sicklers.
2. **3rd generation IV** antibiotics for special cases. "good choice in general"

**Definitive Antibiotic Treatment depends on result of culture of isolated organisms.**

## When do we consider surgery?

When we are sure (as a result of our investigations) there is pus or suspect highly that there is **pus inside** the bone or in the soft tissues near bone.

We have to let pus out (drain the pus out) to stop bone and tissue destruction and improve the general condition by getting rid of source of infection in the body.

## How do we do Surgery for Bone Infection?

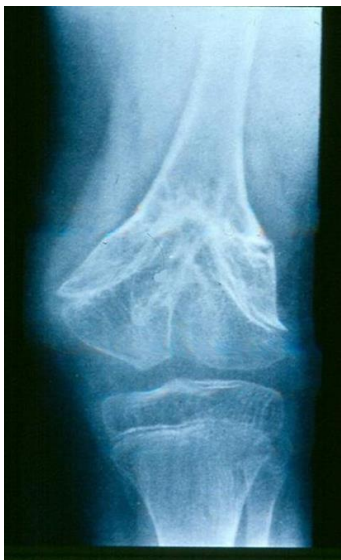1. Patient should be prepared well for surgery.
2. Surgery is done under GA usually.
3. X-ray guidance (image intensifier) is used usually to help exact location of site of drainage.
4. Soft tissue abscesses are drained and bone site of infection is drilled or a window is opened in the cortex to drain pus and curette infected material from inside medulla. "then send it to histopathology and irrigate with NaCl 10 L"
5. In case of presence of **sequestrum** it has to be **removed**. "to stop progression to chronic OM"
6. Vacuum drainage is to be left at site of drainage till discharge is minimal.

## Post-Operative management

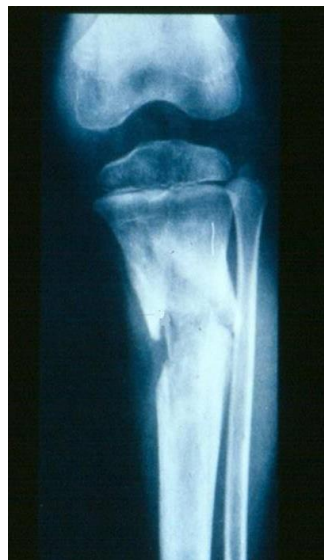1. Definite antibiotic should be continued via IV route for **6 weeks** usually.
2. Monitoring of general condition and blood investigations should be done frequently as in patient, especially CBC, ESR and CRP.
3. Repeat follow up plain X-rays or CT or MRI may be required.
4. Patient should be **pain free and generally well** before discharge.
5. Long term follow up should be done to exclude late complications

## Complication “very important”

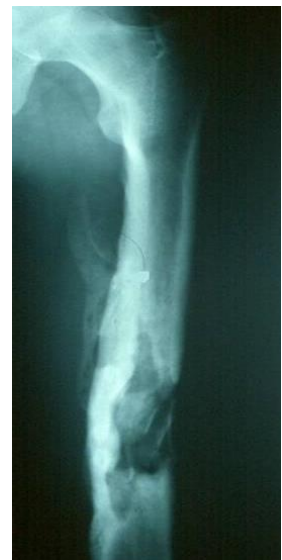- ❖ Septicemia and distant abscesses.
- ❖ Septic arthritis.
- ❖ Growth disturbance in skeletally immature.
- ❖ Pathological fracture.
- ❖ Chronic osteomyelitis.



Growth disturbance



Pathological fracture



Chronic osteomyelitis



### KEY POINTS

- Osteomyelitis can be a result of haematogenous or direct spread.
- The earliest radiographic change is periosteal elevation.
- MRI is effective in the early detection of osteomyelitis.
- The bacterial pathogen varies on the basis of the patient's age and mechanism of infection.

# Chronic Osteomyelitis

## Introduction

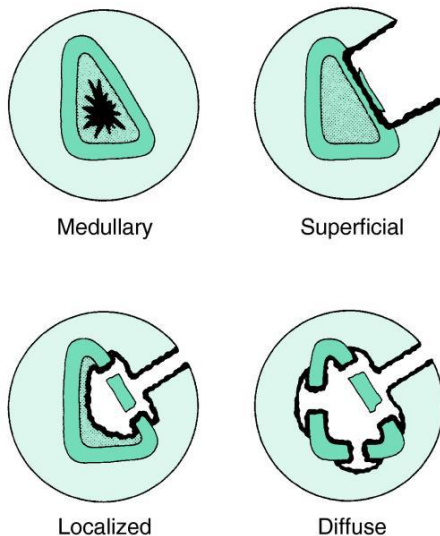
**Chronic osteomyelitis** used to be a common sequel to acute osteomyelitis; nowadays it more frequently follows an open fracture or operation.

Reappearance of discharge after treatment of acute OM is a sign of chronic change, look for Sequestrum

### Common in:

- ❖ **Inappropriately treated acute OM.** like people who are treated by giving them **oral antibiotic**
- ❖ Diabetics due to impairment of chemotaxis and of phagocytosis
- ❖ Trauma
- ❖ Immunosuppressed
- ❖ IV drug abuse

### Anatomical classification (in medulla "Dry OM" or sequestrum)



**Table 2.2 Staging for adult chronic osteomyelitis**

LESION	TYPE
Stage 1	Medullary
Stage 2	Superficial
Stage 3	Localized
Stage 4	Diffuse
HOST CATEGORY	
Type A	Normal
Type B	Compromised by local or systemic conditions
Type C	Severely compromised by local and systemic conditions

## Features

- ❖ Skin and soft tissues involvement.
- ❖ **Sinus tract** "from bone to skin" formation may occasionally develop **squamous cell carcinoma**. "marginal ulcer"
- ❖ Periods of **quiescence**, followed by acute **exacerbations**.

## Diagnosis

- Nuclear medicine → activity of the disease.
- **Best test to identify the organisms → Operative sampling of deep specimens from multiple foci.**
- During acute flares the CSR, ESR and WBC levels may be increased; these non-specific signs are helpful in assessing the progress of bone infection but they are not diagnostic.
- CT and MRI are invaluable in planning operative treatment: together they will show the extent of bone destruction and reactive oedema, hidden abscesses and sequestra.

## Treatment

- ❖ Surgical debridement: complete removal of compromised bone and soft tissue
- ❖ Chronic infection is rarely eradicated by antibiotics alone. Yet bactericidal drugs are important:
  - A. to suppress the infection and prevent its spread to healthy bone
  - B. to control acute flares.
- ❖ **Empirical therapy is not indicated**
- ❖ **IV antibiotics → must be based on deep cultures**
- ❖ Most common organisms :
  - **S. aureus**
  - Enterobacteriaceae
  - P. aeruginosa
  - Streptococcus in children < 10 years
- ❖ Bacterial colonization and resistance to antibiotics is also enhanced by the ability of certain microbes (including Staphylococcus) to adhere to avascular bone surfaces and foreign implants, protected from both host defenses and antibiotics by a protein polysaccharide slime (**glycocalyx**) "biofilm".
- ❖ **We must take the implants out. "most important factor"**

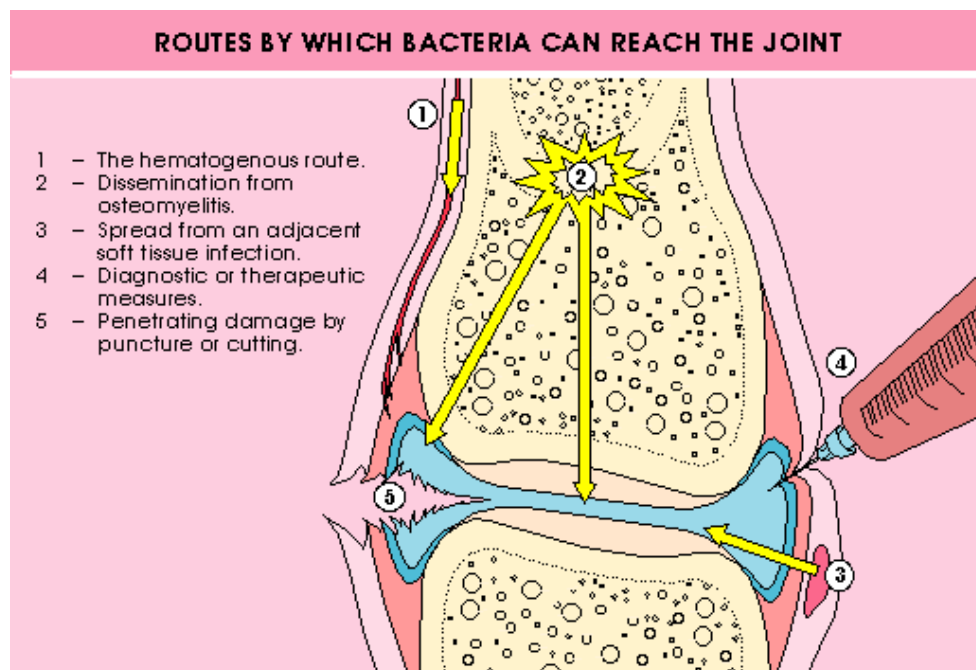
## Complications

- ❖ Recurrence
- ❖ Pathological fracture
- ❖ Growth disturbance in skeletally immature
- ❖ **Squamous cell carcinoma transformation (fistula)**
- ❖ Amputation

# Septic Arthritis

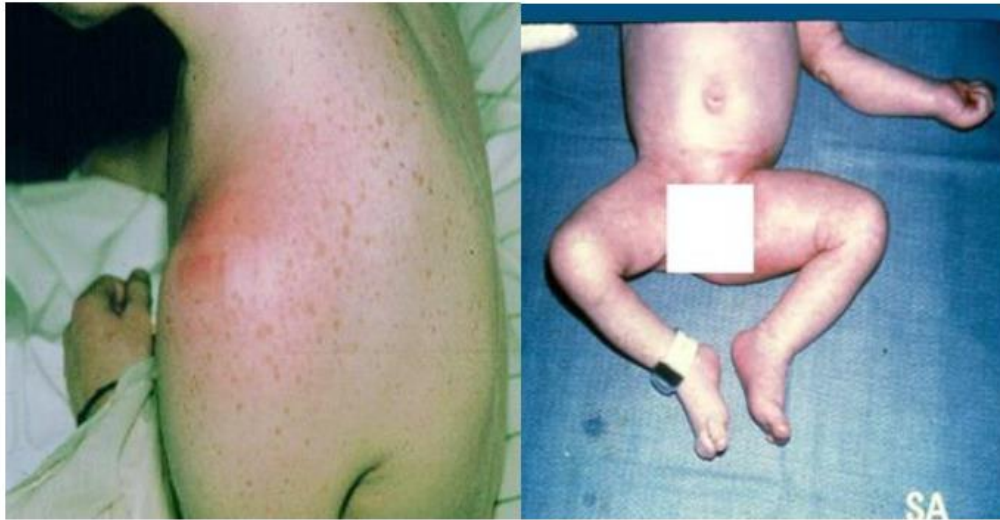## Introduction

- ❖ Infection of the joint
- ❖ May affect any age and any joint.
- ❖ The knee and hip are most affected.
- ❖ **Pathology:** **hematogenous** or from adjacent bone or **direct trauma**.
  - **In neonates: transphyseal vessels**
  - In joints where the metaphysis is intracapsular (Hip, shoulder, proximal radius and distal fibula) "**in children**"
- ❖ The causal organism is usually **S. aureus**; in children between 1 and 4 years old, **H. influenzae** is an important pathogen unless they have been vaccinated against this organism



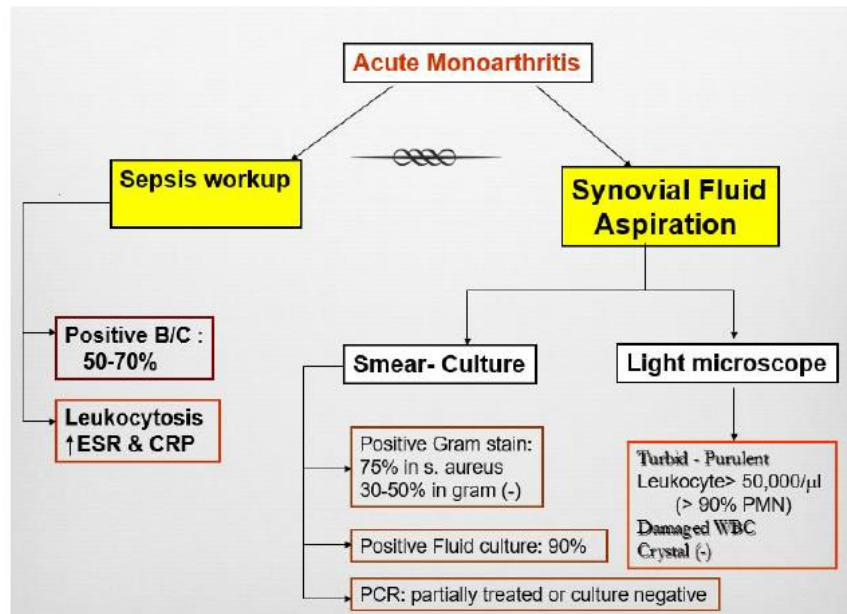
- ❖ **Symptoms:** like acute osteomyelitis
- ❖ **Signs:** hot swollen and **erythema** joint which is **painful to any motion with tenderness**, inability to bear weight
- ❖ **Joint is fixed in the position of ease** "more than acute OM"

Typical features are acute pain and swelling in a single large joint – commonly the hip in children and the knee in adults. However, any joint can be affected. The patient becomes ill, with a rapid pulse and swinging fever. The WBC is raised and blood culture may be positive.



## Investigations

- ❖ Basic lab for infection (CBC, ESR and CRP), Blood cultures and bone profile.
- ❖ Plain x-ray and Ultrasound
- ❖ Joint aspiration: WBC >50,000 (>90%PMNL), damaged WBC and **No crystals**  
"Turbulent / Pus / Blood means pathology normally it is yellow clear fluid"
- ❖ Organisms: similar to acute OA: *S. aureus*, *H.influnza*. Salmonella "Sicklers"
- ❖ Rx: Admission for Emergency arthrotomy and washout, broad spectrum IV antibiotics and splintage . **it's an emergency.**
- ❖ Main DDX: transient synovitis of the hip, in children causes symptoms and signs which are less acute, but there is always the fear that this is the beginning of an infection.



Synovial Fluid Aspiration For simulated cases vimto+oil=fracture

## Differential diagnosis

- ❖ Acute osteomyelitis
- ❖ Transient synovitis (<10 years)
- ❖ Reactive arthritis
- ❖ Vasculitis eg: Henoch-Schonlein purpura
- ❖ Traumatic haemoarthrosis
- ❖ Haemophilic arthritis

## Management

- Emergency **drainage** of the septic joint: Either arthroscopic Or Open.
- Joint should receive lavage and debridement, and a drain should be left at joint till discharge is clear and minimal.
- IV **antibiotics** should be administered for **4 weeks**.

## Complications

- ❖ Septicemia
- ❖ Abscess
- ❖ Osteomyelitis
- ❖ Joint destruction
- ❖ Joint subluxation and dislocation "due to pus inside the joint"
- ❖ Ankylosed joint "fibrous or bony"
- ❖ Avascular necrosis of the femoral head
- ❖ Growth disturbance



### KEY POINTS

- Any acutely hot or painful joint is septic arthritis until proven otherwise.
- Investigation of choice is aspiration of the joint fluid and microbiological assessment.
- In likely cases of septic arthritis, commence antibiotic therapy as soon as possible.



# Tuberculosis

## Introduction

- ❖ Granulomatous bone infection
- ❖ Tuberculosis is **chronic** bone infection.
- ❖ Could affect joints
- ❖ May affect any age
- ❖ **Causative organism :**
  - **Mycobacterium tuberculosis** "human type"
  - Mycobacterium Bovine
  - Mycobacterium africanum

Tuberculosis is on the increase; bones or joints are affected in about 5% of patients. *Mycobacterium tuberculosis* has a predilection for the vertebral bodies and the large synovial joints.

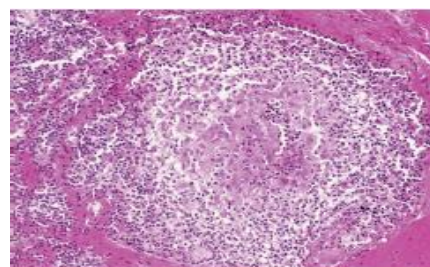
Where pulmonary tuberculosis is endemic, skeletal tuberculosis is seen mainly in children and young adults. In non-endemic areas the disease usually appears in patients with chronic debilitating disorders or reduced immune defence mechanisms (e.g. acquired immunodeficiency syndrome [AIDS]).

## Mycobacterium Tuberculosis “very important”

- Thin non-motile rod
- Strictly aerobic
- **Acid fast bacillus**
- **Can be diagnosed sometimes by direct smear**
- **When bacillus is seen it is diagnostic of TB**
- **It takes up to 6 weeks to culture**
- Requires enriched culture medium to grow
- Common in our region and other developing countries
- Endemic in poor non-developed countries
- Increasing in developed countries along with the increase in AIDS
- Affects anyone at any age, but it is **more common in the immunocompromised** (AIDS, chronic renal failure, substance abuser)
- Usually affects young individuals in developing countries while it affects the older in developed countries

## Pathology

- Inflammation Hyperemia
- **TB Follicles (tubercle): Lymphocyte, monocytes, Endothelial cells, Langhans giant cells**
- **Coalesce**
- **Caseation**



2.12 Tuberculosis – histology A typical tuberculous granuloma, with central necrosis and scattered giant cells surrounded by lymphocytes and histiocytes.

## Musculoskeletal TB

- ❖ 1-8% of all T.B
- ❖ Secondary to other primary TB lesions (Pulmonary, Renal, LN)
- ❖ 50% associated with pulmonary primary site
- ❖ **Route of spread:**
  - **Hematogenous**
  - Direct (much less): Bone to joint, Soft tissue to bone
- ❖ **MSK targets:**
  - **Spine (50%) “Pott’s Disease”**
    - Thoracic (50%)
    - Lumbar (25%) can cause **Eguda equine**
    - Cervical (25%)
  - Pelvis > Hip > Knee > Ankle and shoulder
- ❖ **What can it do to the site :**
  - **Spine:** Deformity (gibbus, kyphus), Neurological compromise (motor>sensory) “**Pott’s paraplegia**” , Muscle spasm
  - **Joints:** Swelling, Stiffness, Locking, Loss of function
  - **Bones:** Ulcers, Sinuses, Swelling, Deformity Presentation

## T.B of The Spine: (Pott’s disease)

- ❖ Usually secondary to hematogenous spread
- ❖ Can affect two or more adjacent vertebrae , **May skip levels**
- ❖ Primarily does not affect the disc but eventually the disc is affected
- ❖ Affects most commonly the anterior part of the vertebral endplates
- ❖ **Causing erosion and destruction and finally anterior wedging of the vertebrae**
- ❖ The disc herniates into the weakened and destructed body and narrowing of the disc height follows
- ❖ Infection spreads to adjacent level under the longitudinal ligaments and hematologically
- ❖ Eventually a **kyphotic** deformity occurs

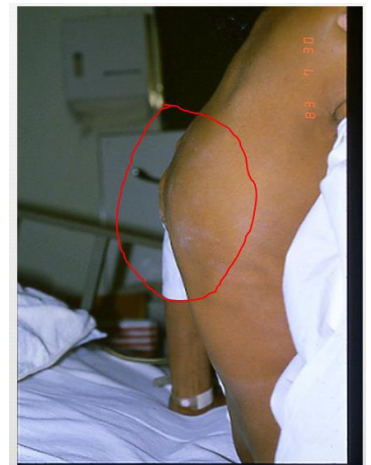- ❖ **Para vertebral abscess** is common and may be distant as well "CT-scan to see as multiple pockets in vertebra"
  - **Cervical > retropharyngeal abscess**
  - **Lumbar > psoas abscess**
  - Compression of the spinal cord is more likely to occur at the thoracic level
- ❖ Neurological deficits occur due to the compression secondary to the **deformity** or compression from the **abscess** "cold abscess", **Paraplegia** may occur
- ❖ **Reversible if treated early**
- ❖ **Mostly treated non-surgically**

## Presentation

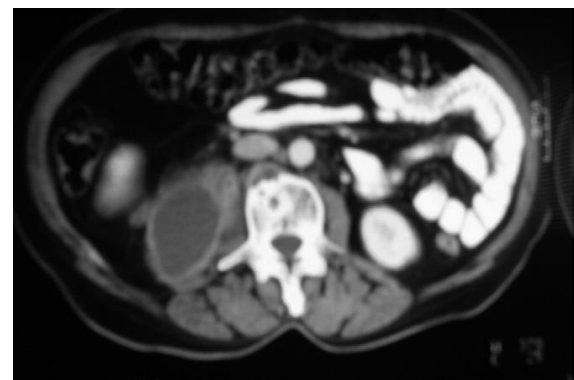
- ❖ **Constitutional symptoms: Fever, Weight loss, Night sweats, Anorexia**
- ❖ Pain
- ❖ Stiffness
- ❖ Deformity

## Diagnosis

- ❖ **History and physical**
  - High risk
  - Constitutional symptoms
  - Atypical clinical picture
- ❖ **Blood work**
  - Lymphocytosis
  - Anemia
  - Elevated ESR
  - ELISA
  - PCR
  - Brucella titer



kyphosis



TB spine with Psoas abscess

## Radiology

### Plain X-rays

#### ❖ Spine

- Erosion and end plates destruction
- Narrowing of disc space
- Soft tissue mass shadow
- Anterior wedging of vertebrae
- Kyphus deformity

#### ❖ Joints: usually **monoarticular** “**PHEMISTER’S TRIAD**”

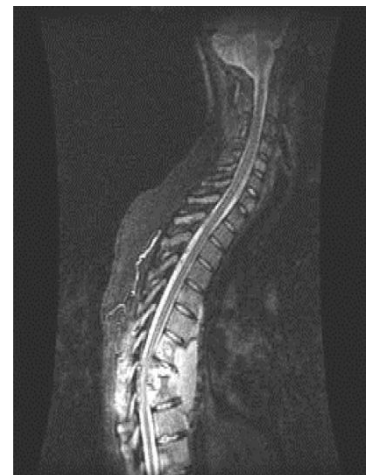- Peri-articular osteopenia
- Subchondral and peripheral erosions affecting both sides of the joint
- Loss of joint space

### CT

Further delineate bony destruction and sequestrum

### MRI with contrast

- ❖ Soft tissue mass, abscess
- ❖ Nerve root, cord status
- ❖ Distant abscess
- ❖ Non-enhanced cold abscess with enhanced peripheral ring



### Special tests

- ❖ **Mantoux skin test**
- ❖ Spine: CT guided needle biopsy
- ❖ Joints: Synovial aspiration (**low yield**) , Should get bone/soft tissue.

Send for aerobic/non-aerobic bacteria, fungal, AFB, enriched culture media. Takes up to 4-6 weeks

## Treatment

- ❖ Usually non-surgical by Triple or Quadruple drugs :
- ❖ **RIPE**: "no longer we use streptomycin due to ototoxicity "

Isoniazid, Rifampin, Ethambutol, Pyrazinamide are commonly chosen.

- ❖ Modify according to culture results
- ❖ **Given for prolonged period of time (6 months up-to 18 months)**

### Indications of surgery:

- ❖ Marked and progressive neurological deficit not responding to medical treatment requiring **decompression**
- ❖ **Spinal instability requiring stabilization**
- ❖ **Tissue biopsy to confirm diagnosis**
- ❖ Joint lavage and removal of rice bodies
- ❖ **Abscess drainage if resistant to conservative treatment**

## Brucellosis

- ❖ Ask about Milk and milk products "milk pasteurization"
- ❖ Back pain and stiffness
- ❖ Muscle spasms
- ❖ Fever (mild)
- ❖ Most common **Sacro-iliac joint** then **wrist and hip joint**.
- ❖ Less destructive than TB
- ❖ **Brucella titer: Titers higher than 1:160 in conjunction with a compatible clinical presentation are considered highly suggestive of infection. Titers higher than 1:320 are considered to be more specific. "mentioned by the Dr + medscape"**
- ❖ Antibiotics: E.g. Septrin – Oxytetracycline **if failed use third generation cephalosporin.**

## Summery

1. Be aware about red flags
2. Acute osteomyelitis: Empirical wide spectrum IV Abx till final culture (6 wks)
3. Chronic osteomyelitis: IV Abx according to C/S
4. Septic arthritis:
  - A. Joint aspiration under GA for children
  - B. Emergency Joint washout
  - C. Required Immediate wide spectrum IV Abx till final culture (4wks)
  - D. Bone and joint infection requires prolonged antibiotic

Pathology	Clinical picture	investigation	Treatment
<b>Acute osteomyelitis</b>	-severe pain, malaise and a fever - Even the gentlest manipulation is painful and joint movement is restricted (pseudo paralysis)	-CBC: raised WBC -ESR -C-reactive protein (most sensitive) -Blood cultures -Aspiration	Start on wide spectrum antibiotic
<b>Septic Arthritis</b>	- hot swollen joint which is painful to any motion, inability to bear weight - Joint is fixed in the position of ease	-Joint aspiration: WBC >50,000 (>90%PMNL), damaged WBC and No crystals	Admission for Emergency arthrotomy and washout, broad spectrum IV antibiotics and splintage
<b>Transient Synovitis</b>	-Sudden onset of hip pain -low grade favorite	-WBC count <12,000 -Mildly elevated ESR (<40), CRP (<2)	-Self-limited after 2-7 days -NSAIDs
<b>Vasculitis</b>	purpura, arthritis and abdominal pain	-High urea and creatinine -Raised IgA -Diagnosis confirmed by biopsy	

# Done By:

<b>Done by:</b>	<b>Abdulmalek Alqhahtani Muhannad Alwabel</b>
<b>Revised by:</b>	<b>Noha Almndeel</b>
<b>Team Leader:</b>	<b>Abdulrahman Albasseet Mariam Bawazir</b>

