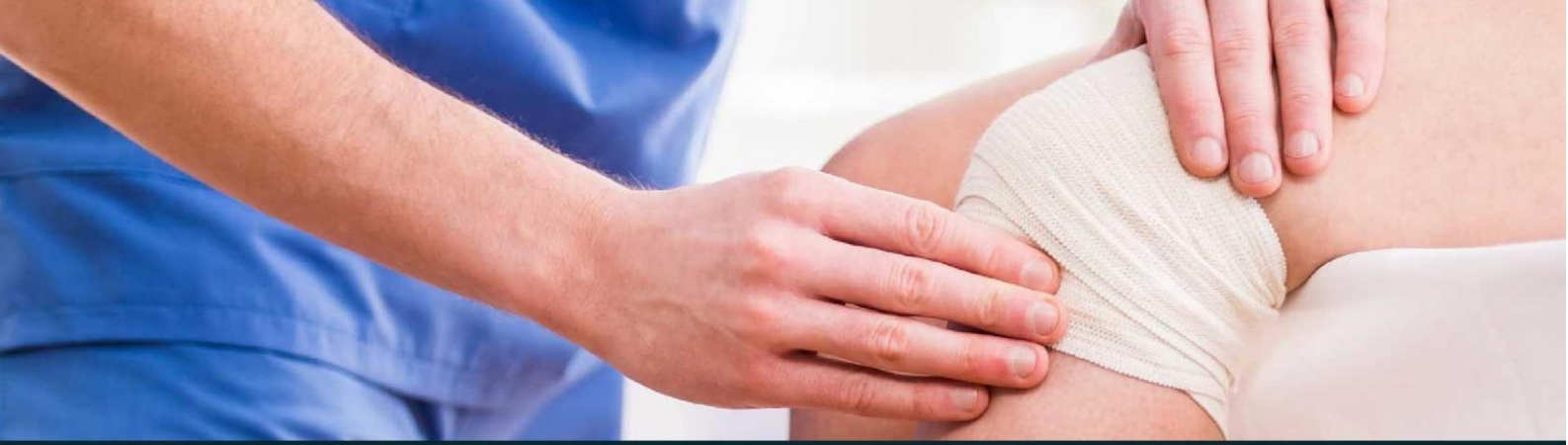



433 Teams

ORTHOPEDICS

Lecture 15

Sport & Soft Tissues Injuries

Ortho433@gmail.com



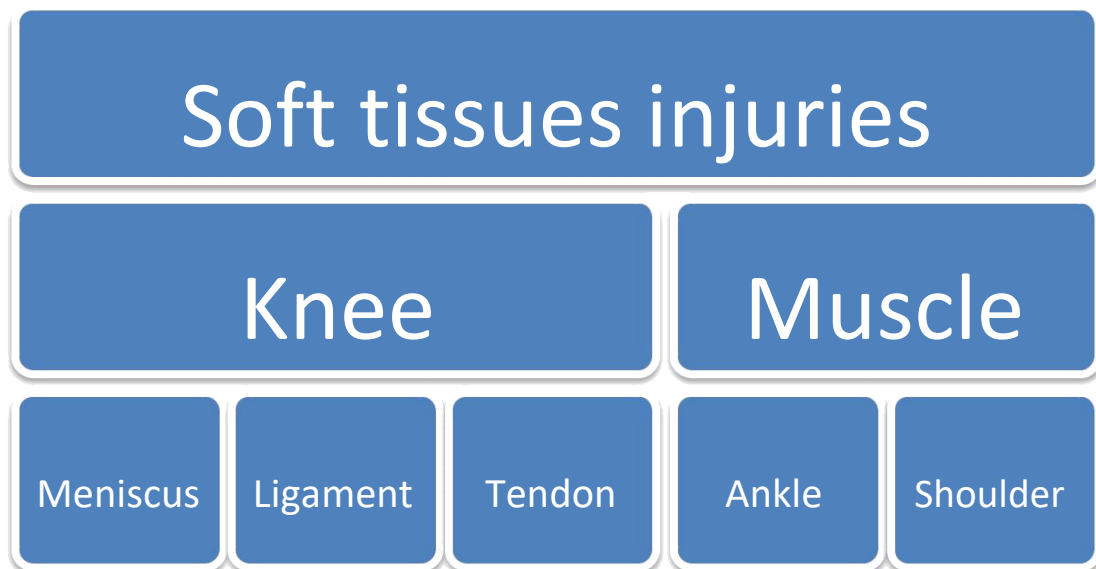
جامعة
الملك سعود
King Saud University



Objectives

By the end of this lecture you should be able to:

1. Specify the symptoms, signs and potential immediate complications of common sport and soft tissues injuries involving muscles, tendons, and ligaments for commonly injured joints; like shoulder, knee, and ankle.
2. Outline the assessment and appropriate investigation and immediate and long term management of patients with muscles, tendons, ligaments and meniscal injuries.
3. Demonstrate knowledge of non-operative and operative measurements used for sport/soft tissue injuries and their indications.



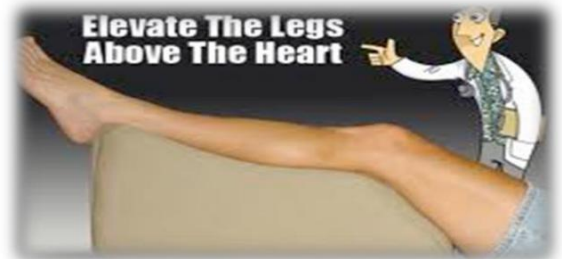Initial management

RICE

Rest



Ice



s

ay "Initial Management" we don't mean the definite management,

Initial management means the first thing you do when you have an injury and definite treatment means when you treat the injury.

- So in the Exam you will have a scenario question and at the end you will see "What is the **initial** management or what is the definite Management so be careful when you read the question because there is a difference between them".
- The initial management in sport or soft tissue injury or even in other injuries is RICE (Rest - Ice - Compression - Elevation "at heart level").
- So if the question is "What is the **initial** treatment?" you choose one of them "RICE".

Muscle injury

- The muscles most at risk are those that their origin and insertion **cross two joints**.

- Frequently injured muscles act in an **eccentric** fashion (i.e., lengthening as they contract).

Muscle injuries can be divided into:

- Muscle strain
- Muscle Contusion
- Muscle Laceration
- Delayed-onset soreness

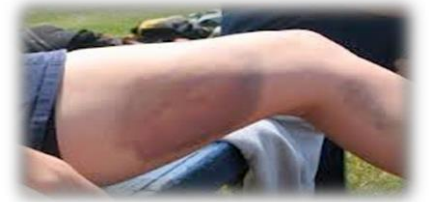Muscle Strain:

- The **most common** muscle injury suffered in sports, it's different from the muscle spasm.
- **Immediate pain associated with diminished function.**
- Both complete and incomplete muscle tears can occur by passive stretch of an activated muscle.
- Muscle tears also typically occur at or near to the myotendinous junction.
- **Treatment:**
 - **RICE**
 - NSAID
 - Physical therapy

Muscle Contusion:

- Caused by a non-penetrating blunt injury (direct blow) to the muscle resulting in hematoma and inflammation, **common scenario knee on tight injury**.
- **Quadriceps and Brachialis** muscles are common involved regions.
- **Clinical features:**

- ✓ Pain with active and passive motion +/- swelling.
- ✓ Decreased range of motion of joints spanned by the injured muscles.
- ✓ Occasionally a permanent palpable mass, sometimes we do MRI to rule out any serious conditions.



- **Treatment:**

Most of it resolve spontaneously

- ✓ **RAISE, Short** period of **immobilization** “at maximum length of the muscle “
- ✓ Followed by early mobilization and Physiotherapy
- ✓ NSAID

Rarely it causes small muscle mass (fibrosis)

- Patient may present to you later **after the trauma** with a mass, you think of Myositis ossificans. “Calcification within the Muscle” Treatment: initial RICE, early mobilization then physiotherapy (**not operative**) 431 team.

Muscle Laceration: penetrating injury

- If superficial we do nothing, if full rupture we suture it.
- If it ischemic we do debridement and washing, if it viable we repair it by approximate the two ends or do 1-2 sutures.

Delayed -Onset Soreness: (if you run a distant you never ran before)

- Structural muscle injury leads to progressive edema formation and resultant increased intramuscular pressure.
- Is primarily associated with **eccentric loading**-type exercise. Usually occur when you play soccer without warming up.
- **Clinical features:** muscular pain that occurs 1-3 days after vigorous exercise.
- **Treatment:** Will resolve in a few days, may use NSAIDs

Complications of Muscle Injuries:

- Scar formation lead to muscle weakness.
- **Compartment syndrome:** At the level of the muscle fibers, capillary bleeding and edema can lead to hematoma formation and can cause compartment syndrome in areas in which the volume is limited by the fascial envelope. **Pt with bleeding disorders is at high risk.**

- Myositis ossificans:

Bone Formation within the muscle secondary to blunt trauma.

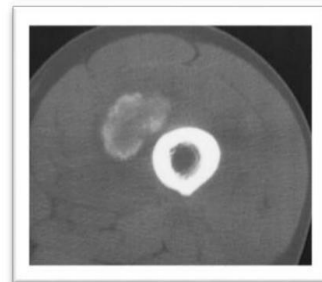
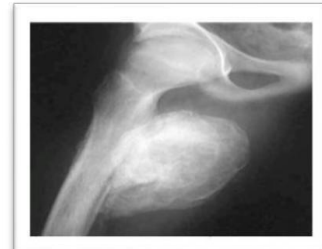Characterized by initially pain then hard mass.

Not heterotopic ossification: is the presence of bone in joints after RTA

Symptoms:

- **Early: Pain-** swelling- decreased ROM.
- Erythema, warmth, induration, tenderness.

- **Late:** painless swelling with decreased ROM.
 - ✓ It's sometimes confused with **osteogenic sarcoma** on radiograph and biopsy. **You have to exclude cancer**
 - ✓ May have increased ESR or Alkaline Phosphate.
 - ✓ Myositis ossificans becomes apparent **approximately 2 to 4 weeks post-injury.**



Treatment: They will advise conservative treatment initially which will include rest, possible immobilization of the affected limb for 3 or 4 weeks. This may give time for the body to reabsorb the calcification. An X-ray of the muscle can be done to see when it is safe to start rehabilitation and strengthening exercises. In particularly severe cases surgery can be performed to remove the bone growth.

Tendon injuries

- Function -to transfer force from muscle to bone to produce joint motion.
 - Type of injuries
 - Overuse tendinopathies.
 - Tendon rupture.

1 - Overuse tendinopathies: most common

- **Osteotendinous junction** is the most common site of overuse tendon injury.
- Tendons are relatively **hypovascular** proximal to the tendon insertion. This hypovascularity may predispose the tendon to hypoxic tendon degeneration and has been implicated in the etiology of tendinopathies.
- Tendinopathy not tendenitis.

Most Common Diagnoses and Locations of Chronic Tendinopathies

Diagnosis	Location
Rotator cuff <u>Tendinopathy</u>	Supraspinatus tendon insertion
Lateral <u>epicondylosis</u> (tennis elbow)	Common wrist extensor tendon origin (mainly involved ECRB)
Medial <u>epicondylosis</u> ("golfer's elbow")	Common wrist flexor tendon origin
Hamstring <u>Tendinopathy</u>	Hamstring tendon origin
Quadriceps <u>Tendinopathy</u>	Quadriceps tendon insertion
Patellar <u>Tendinopathy</u> (jumpers knee)	Patellar tendon origin
De Quervain's disease	Sheath/pulley of abductor <u>pollicis longus</u>
Achilles <u>Tendinopathy</u>	Sheath, <u>midsubstance</u> , or calcaneal insertion

We found it in Sucker plyers because they need to run backward

treatment:

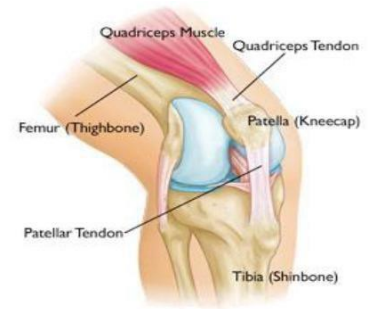
- **Goal:** reduce pain and return

function.

- Mainly is **conservative** Rx
 - **Rest**, Ice (Cryotherapy), Physiotherapy (stretching and eccentric strengthening while the muscle it's extended).
 - Analgesics, Corticosteroids injection, Orthotics and braces
 - Other modalities: U/S, **ESWT (main goal to maximize the blood to the area)**.
 - Surgical treatment:
 - ✓ Failed conservative treatment (at least **3-6** months).
 - ✓ Excision of abnormal tendon tissue and performance of longitudinal tenotomies to release areas of scarring and fibrosis.

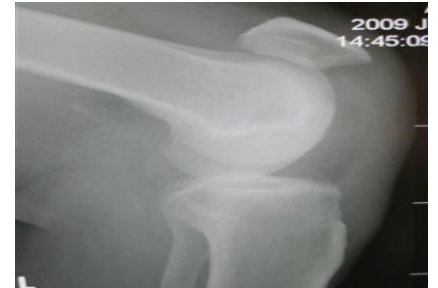
2- Tendon rupture

- Knee extensor mechanism
 - **Quadriceps tendon**
 - **Patellar tendon**
- **Achilles tendon**
- Partial vs complete



Patellar/Quadriceps tendon rupture:

- Predisposing factors:
 - **Steroid (injection or oral)**, chronic disease, and tendinopathy.
- Age: Patellar <40 YO >Quads
- Location: at the tendon attachment to the patella.



Patella-alta (high riding patella) seen with patella tendon rupture.
MCQ

Physical examination:

- Tenderness at the site of the injury, hematoma, and a palpable defect in the tendon (gap between the muscle), **usually at acute stage**.
- Diffuse swelling.
- Unable to extend the knee against resistance or to perform a straight-leg raise. **Called extension lag loss of active action but passive action is passable.**

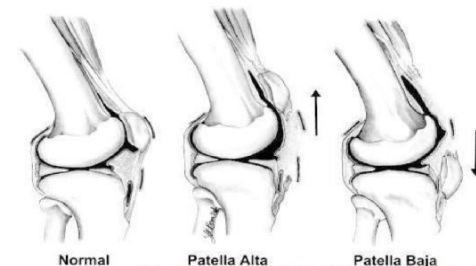
Investigation:

X-ray (first line of investigation):

- **Patella-alta: Patellar tendon rupture. MCQ**
- **Patella-infera (Baja): Quadriceps rupture. MCQ**

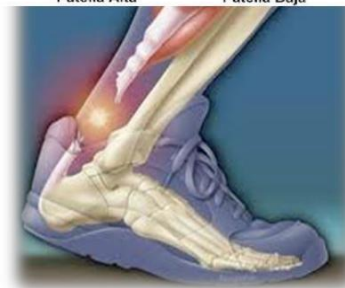
MRI: to see it is complete rupture or not

Treatment: Surgical then cast for 4-6 weeks.



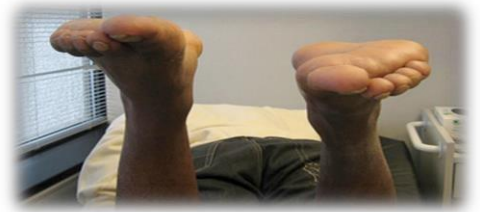Achilles tendon rupture:

- Most ruptures (75%) occur during sporting activities.
- **History:**
 - ✓ The patient reports a “pop” or the sensation of being **kicked in the heel during the injury**.
 - ✓ Weakness and difficulty walking.



Examination:

Contusion, increased resting dorsiflexion with the knees flexed, a palpable gap, weak plantar flexion, and an abnormal Thompson test (lack of plantar flexion when squeezing the calf).

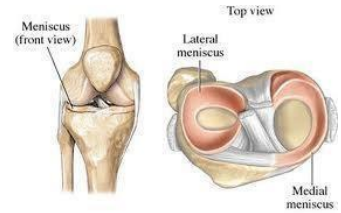


- **Diagnosis** is clinical, but MRI or ultrasound can confirm if you are not sure.
- **treatment:** depend on Pt factor stage of casting (plantar flexion position) or surgical (**surgical treatment for young and athletic pts. Recovery period is less and low rerupture rate**).

Knee (Menisci, ACL, MCL, LCL, PCL, Knee dislocation)

Meniscus anatomy the doctor didn't explain it (just go through it)

- The menisci are crescent-shaped, with a triangular appearance on cross section.
- The lateral meniscus covers 84% of the condyle surface; it is 12 to 13 mm wide and 3 to 5 mm thick.
- The medial meniscus is wider in diameter than the lateral meniscus; it covers 64% of the condyle surface and is 10 mm wide and 3 to 5 mm thick.
- Medial and lateral menisci, the medial is larger fixed and less mobile while the lateral is more mobile and more circular.
- Common elective procedure in orthopedics is arthroscopy for injured menisci, Cause of twisting injury.



Meniscus tear

Meniscus function

- The meniscus provides stability, absorbs shock, increases articular congruity, aids in lubrication, prevents synovial impingement, and limits flexion/extension extremes.
- The most important function of the meniscus is **load-sharing** across the knee joint.

Epidemiology of meniscus injuries

- Meniscus injuries are among the most common injuries seen in orthopedic practices.
- Arthroscopic partial meniscectomy is one of the most common orthopedic procedures.

Incidence:

- Meniscal tears are unusual in patients younger than age 10 years.
- **Most meniscus tears in adolescents and young adults occur with a twisting injury or with a change in direction.**
- Degenerative type happens in old people due to ageing mostly accompanied with osteoarthritis.
- Middle-aged and older adults can sustain meniscus tears from squatting or falling.
- ACL injury more prone to accompanied with Lateral menisci than medial.

History:

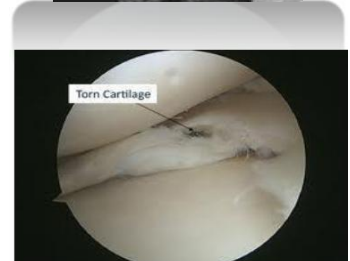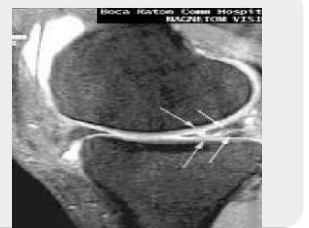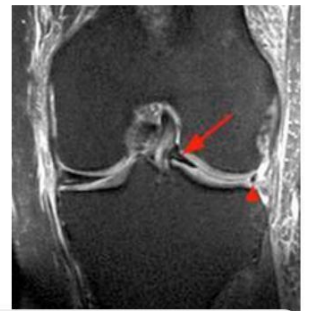- With an acute meniscal tear, an **effusion** may develop **slowly several hours after injury**. This differs from an anterior cruciate ligament (ACL) injury, where swelling develops **rapidly** within the **first few hours**.
- Patients with meniscal injuries localize pain to the joint line or posterior knee and describe mechanical symptoms of **locking (unable to fully extend the knee)** or catching. (دائماً تعلق الركبة)
- Chronic meniscal tears demonstrate intermittent effusions with mechanical symptoms.

Physical examination:

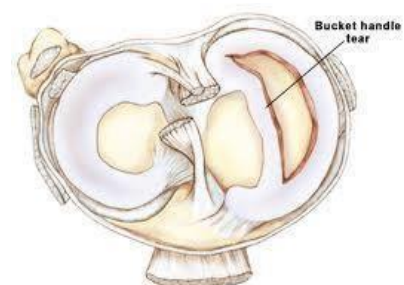
- Small joint effusions and **joint line tenderness** (most sensitive test) with palpation are common findings with meniscus tears.
- Manipulative maneuvers, including the McMurray and Apley tests, may produce a palpable or audible click with localized tenderness, but they are not specific for meniscal pathology.
- Range of motion is typically normal, **but longitudinal bucket-handle tears may block full extension of the knee joint**.

Investigations:

- Standard knee radiographs should be obtained for evaluating bone injuries or abnormalities (**Osteoarthritis**).
- MRI remains the **noninvasive diagnostic procedure of choice** for confirming meniscal pathology, **it is a clinical diagnosis but MRI for confirming**.
- The most common injury is posterior horn



- * What is the type of meniscal tear that causes locking?
Bucket handle tear.



Treatment:

Nonsurgical Management:

- Not all meniscus tears cause symptoms, and many symptomatic tears become asymptomatic.
- Tear types that commonly may be managed **nonsurgically include**:
 - Stable longitudinal tears <10 mm in length with <3 to 5 mm displacement
 - Degenerative tears associated with significant osteoarthritis
 - Short (<3 mm in length) radial tears
 - Stable partial tears
- Nonsurgical management can include ice, nonsteroidal anti-inflammatory drugs, or physical therapy for range of motion and general strengthening of the lower extremities.

Surgical indications:

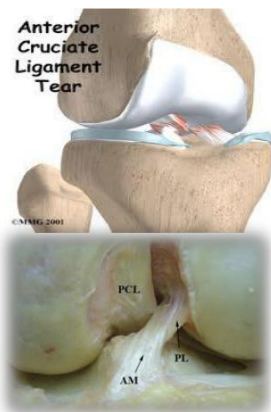
- Failure of conservative treatment
- Grade three
- **Locked knee (urgent surgery due to increased risk of stiffness).**
- Concomitant ACL surgery
- Type of surgical intervention:
 - Excision (Arthroscopic partial/subtotal/ or total meniscectomy)
 - Repair

ACL injury (Anterior Cruciate Ligament) الرباط المتصلب الأمامي

Anatomy: ACL Origin is in the tibia between tibia spines, then it goes to the lateral femoral condyle side and attached in medial surface of the lateral femoral condyle. It prevents anterior translation of the tibia over the femur.

Mechanism of Injury: **mostly twisting**

- Noncontact (70%)
 - Cutting or Pivoting
 - Contact = Injury in medial Collateral Ligament “MCL”
- Sports-Related (80%)
- “Pop” (70%)
- Female: 2-4x > **male** (many theories: intercondylar notch narrower in female, hormonal change and laxity). But in our community male > female because usually males do exercises more.



- Common Mechanism is when there is internal rotation of legs with body going on external rotation with **valgus** and flexion. Or jumping and landing on the legs wrongly “legs go **valgus**”.

Diagnosis:

- Symptoms:
 - Instability “**giving way episodes**” (chronic)
 - Swelling (Hem arthrosis) is noted **immediately** after the injury (acute)
 - Pain only in acute stage and caused by tibial contusion not by the ACL tears itself. ACL tear is painless (after 3-4 months of the injury) or if associated with **meniscus tear**.

Physical examination:

Examine the patient again after 3 weeks to be able to do the special tests. (just put splint for immobilization). Do x-ray to make sure there is no fracture.

- The patient needs to be relaxed and comfortable.
- Must be compared with those of the normal knee.
- A moderate to severe **effusion** is usually present in the acute cases
- ROM: in acute injury the range of motion may **limited** by:
 - Pain
 - Effusion
 - Hamstring spasm,
 - ACL stump impingement
 - Meniscal pathology.

Special tests:

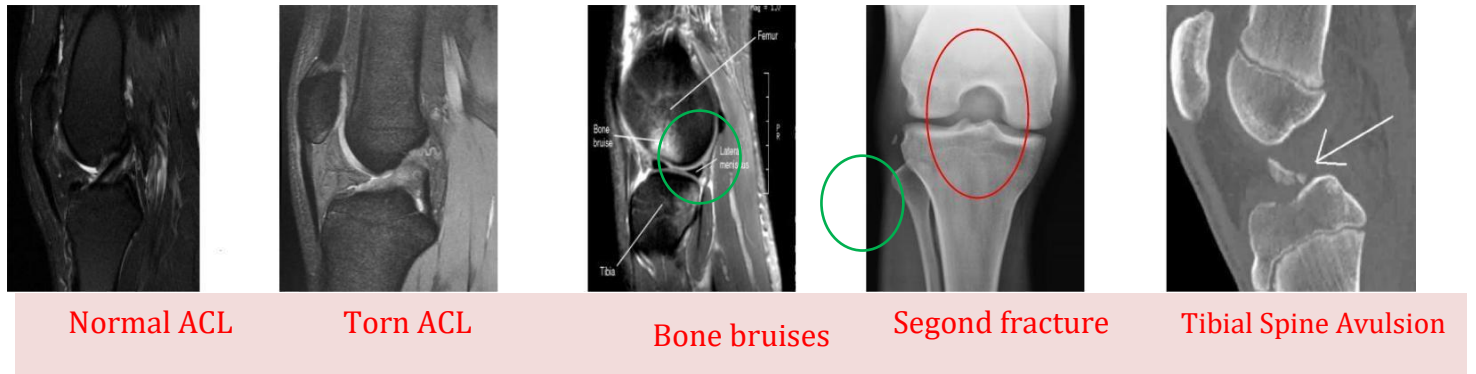
- Lachman’s test
- Anterior Drawer test
- Pivot shift test: is pathognomonic for ACL injury (best in the chronic setting).

Investigations:

- X-ray: may see Segond Fracture*
- MRI (Only for confirmation. Not 100%)*
- In the skeletally mature patient, the femoral insertion or midsubstance is usually the site of disruption “**Ligament is Stronger than bone in immatures young**”
- In the skeletally immature patient, the tibial attachment may be avulsed with or without a piece of bone.

* **Segond Fracture is pathognomonic for ACL tear because there is a capsule and there’s a ligament called anterolateral ligament, with subluxation of tibia due to ACL tear there will be avulsion fracture which is segond fracture**

* You can see the marks of bone contusion in the Left MRI picture due to ACL rupture and that's what mainly causes acute pain.



The green circle is the right one

Injuries Associated with ACL Disruption:

- Injuries of the ACL rarely occur in isolation. The effects of other injuries, Including:
 - Other ligament sprains medial Collateral Ligament (MCL)
- Meniscal tears. **The commonest meniscus to be injured in acute ACL tear is the lateral meniscus, Chronic ACL tear comes with medial meniscus) MCQ**
 - Articular cartilage injuries
 - Bone bruises
- ACL has only acute pain if there is chronic pain think about the other injury accompanied ACL injury.
- Complicate the treatment and eventual outcomes of ACL disruptions.

Treatment:

Nonsurgical Management:

- Appropriate for asymptomatic patients with partial injuries to the ACL.
- Patients who are **older or less physically** active may elect to modify their activities and proceed with **nonsurgical treatment**. If nonsurgical treatment fails or knee instability persists, surgery can be performed.
- Nonsurgical treatment involves rehabilitation to strengthen hamstrings and quadriceps, as well as proprioceptive training.
- Activity modification is also an important part of nonsurgical management, as patients who avoid cutting and pivoting sports are at lower risk for knee instability.
- Functional braces and simple knee sleeves improve proprioception, which may give patients a sense of improved knee function and stability.

Surgical Treatment:

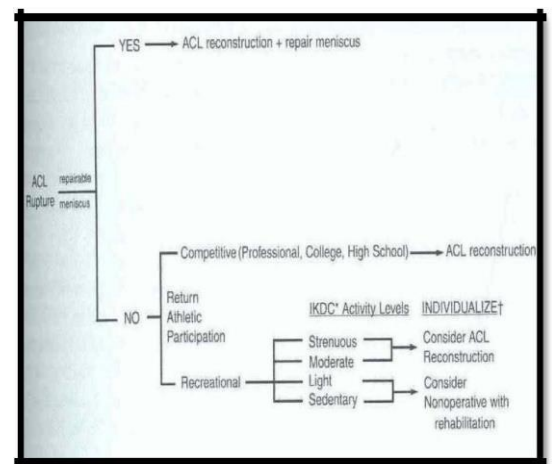
- **Athletes with ACL** injuries rarely return to cutting and pivoting sports, such

as basketball, football, soccer or squash, without first undergoing surgery. For individuals who wish to return to such sports, **surgery is generally recommended** to avoid instability and secondary meniscal and/or articular cartilage damage.

- Individuals who work in occupations that may involve physical combat, such as police officers, or risk, such as firefighters, should have ACL reconstruction before returning to work.
- Most patients can function well and perform activities of daily living (ADLs) without instability after a complete ACL injury. However, some have difficulty performing even simple activities of daily living “ADLs” because of ACL deficiency-related instability, and they may require surgery.

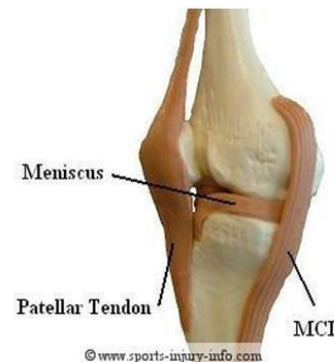The doctor summarized it into a few points: 431team

- Young “usually below 20” with torn ACL = ACL reconstruction “Surgery” even if they are not symptomatic.
- Athletes = ACL reconstruction “Surgery”
- If not athletes nor young, and if not symptomatic and have no intention of doing sports then we don’t do surgery.
- Reconstruction means we remove the torn ligament and replace it by another one, we usually take the Hamstring **tendon**.
- Having a meniscal tear is an indication of Surgery
- Elderly and not physically active = Non-Surgical.
- In acute stage first do initial treatment Rice physio etc.



Medial Collateral Ligament:

- The main function of this complex is to **resist valgus and external rotation loads**.
- The tibial MCL is the most commonly injured ligament of the knee. The true incidence may be underestimated due to a lack of reporting for lesser grades of injury.
- Concomitant ligamentous injuries (95% are ACL) occur in 20% of grade I (**valgus opening 0-5 mm**), 52% of grade II (**valgus opening 5-10 mm**), and 78% of grade III injuries (**>10 mm opening**). (doctor did not focus on the grading)



- Concurrent meniscal injuries have been noted in up to 5% of isolated medial ligamentous injuries.
- Usually result from **contact injury** like a direct blow to the lateral aspect of the knee.
- Can be partial or complete

Symptoms:

- **Pain in the medial side of the knee** at 1st 6 weeks leading to inability to fully flex the knee, Limited ROM.
- If there is tenderness think of meniscus tear and MCL, we differentiate between them by MRI.

Physical examination:

Valgus stress test should be performed with the knee at 0° and 30° of flexion.

- Laxity at 30°: isolated MCL
- Laxity at both 0° and 30°: concurrent injury to the posteromedial capsule and/or cruciate ligaments.

Rule out associated injuries (ACL and medial meniscal tear)

Investigations:

- Is a **clinical diagnosis** and most of the time does not need further investigation.
- If the injury is severe or suspecting associated injuries (e.g. significant knee effusion) then the **MRI** will be the modality of choice.
- X-ray: to rule out fractures (e.g. lateral tibia plateau fracture)

Treatment:

Conservative treatment: Is the mainstay of treatment for the isolated MCL injuries. (**hinged brace**)

Indications:

- ✓ All isolated grade I and II injuries
- ✓ Grade III injuries that are stable in extension without associated cruciate injury.

- Crutches, ice, compression, elevation, and anti-inflammatory/pain medication.
- No brace is usually required for grade I injuries; crutches can be used as necessary. **hinged brace** (for walking) is recommended for grade II and grade III injuries.

Timing of return to sports is directly related to the degree of injury: Grade I injuries, 5 to 7 days; grade II injuries, 2 to 4 weeks; grade III injuries, 4 to 8 weeks.

Surgical treatment:

- If conservative treatment failed.
- Grade III MCL tear.
- If associated with other ligaments injury.

Lateral Collateral ligament:

- The LCL is the primary restraint to **varus stress**
- Less commonly injured compared to MCL
- Injuries to the lateral ligament of the knee most frequently result from **motor vehicle accidents and athletic injuries.**
- **treatment:**
 - Isolated injury: non operative.
 - Combined injury: surgical (**or with neural symptoms**).

Posterior Cruciate Ligament:

- The PCL is the primary restraint to posterior tibial translation. The patient complains of uncomfortablity not stability.

Mechanism of injury:

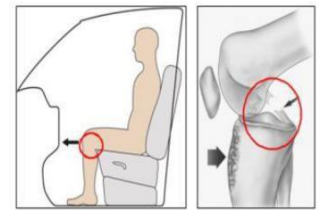
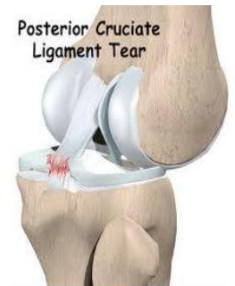- A direct blow to the proximal aspect of the tibia is the most common cause of PCL injury or **Dashboard injury**

In athletes > a fall onto the flexed knee with the foot in **plantarflexion**, which places a posterior forces on the tibia and leads to rupture of the PCL.

- PCL insufficiency significantly increased the risk of developing **medial femoral** condyle and patellar cartilage degeneration over time.

Treatment:

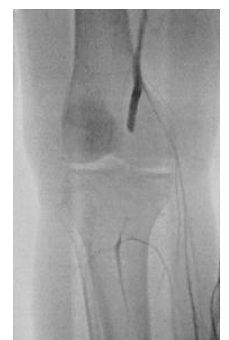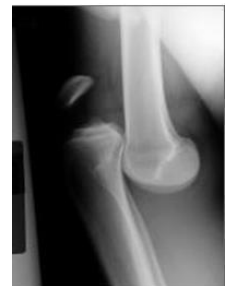- Non-operative
- Surgical if combined ligament injury



Dashboard injury

Knee dislocation:

- **Multiligaments** Injuries due to knee dislocation
- Multiligament knee injuries are usually caused by high-energy trauma and are often considered as knee dislocations.
- Less frequently, low-energy trauma or ultra-low-velocity trauma in obese patients can also result in this injury pattern.
- A bicruciate (ACL+PCL) injury or a multiligament knee injury involving three or more ligaments should be considered a spontaneously reduced knee dislocation.
- A knee dislocation should be considered a limb-threatening injury, and careful monitoring of **vascular status** after the injury is imperative.
- Popliteal artery (estimated at 32%) or peroneal nerve injury (20% to 40%) also can occur.
- Vascular examination is critical in an acutely dislocated knee.
- ✓ **Pulse might be normal in intimal tear so we should do ankle-Brachi al index (ABI). An ABI of less than 0.90, and most certainly less Than 0.80, should be considered abnormal.**



✓ If there is any concern about an **abnormal vascular examination angiogram**, there should be a low threshold for ordering an

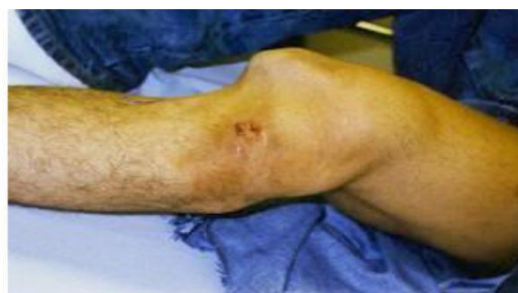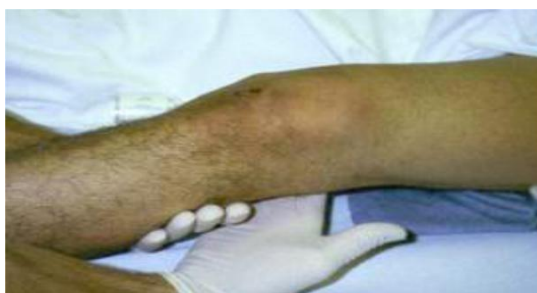✓ If **pulses are still abnormal** or absent following reduction of the dislocation, immediate vascular **surgery consultation** with intraoperative exploration should be the next step in management.

✓ A vascular injury in a knee dislocation is a limb-threatening injury and needs to be corrected within 6 to 8 hours. If not corrected, amputation may be required.

• Neurologic examination is also critical, as peroneal nerve injury can occur with multiligament injuries, particularly in concomitant lateral/posterolateral corner injuries.

NEED EMERGENT REDUCTION:

• Emergent closed reduction and splinting, bracing or external fixator (best) should be performed immediately. Post-reduction radiographs should be taken to confirm knee reduction.



• So the steps in management are: Check neurovascular > analgesia > Reduce > Splint > Check neurovascular again > check for compartment syndrome > ABI > x-Ray >

• If knee reduced and there is no pulse, next step is call vascular surgeon.

Ankle sprain:

• Ankle sprain is a common sports related injury.

• **Lateral sprains**

accounting for 85% of all such injuries.

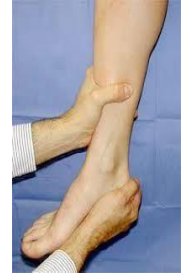Classification of

- **Grade 1 injuries** - the ligament is stretched, with microscopic (but not macroscopic) tearing. Swelling is mild, with little or no functional loss and no joint instability. The patient bears weight at least partially.
- **Grade 2 injuries** - the ligament is stretched with partial tearing. Swelling is moderate-to-severe, with ecchymosis. There is moderate functional loss and mild-to-moderate joint instability. Patients usually have difficulty bearing weight.
- **Grade 3 injuries** - the ligament is completely ruptured. Swelling is immediate and severe, with ecchymosis. The patient usually cannot bear weight (or not without severe pain). There is moderate-to-severe instability of the joint.

Acute Lateral Ankle Sprains: the doctor did not mention it.!!!

History and physical examination:

- History suggestive of inversion injury
- Localized tenderness, swelling, and ecchymosis over the **anterior talofibular** ligament (ATFL) and/or calcaneofibular ligament (CFL).
- If there is one ligament sprain it will not affect stability.
- Examination should localize pain to the lateral ankle. The **anterior drawer** test may demonstrate anterior **talar subluxation**.
- The **talar tilt stress** test may demonstrate positive **tilt to inversion stress**.

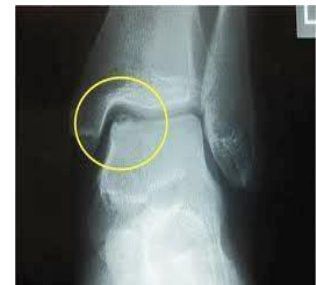

Investigations:

- X-ray ankle to R/O associated injuries (lateral process of talus, anterior process of calcaneus, and fifth metatarsal base).
- MRI and MR arthrography can show ligamentous disruption or attenuation, but they provide no distinct advantage over physical examination.
- MRI is most useful when looking for other pathology (peroneal tear, osteochondral lesions of the talus). **Consider MRI if pain persists 8 weeks after ankle sprain.**

Associated injuries:

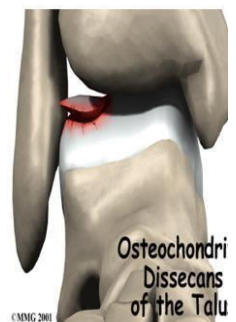- Osteochondritis dissecans lesions (15% to 25%)
- Loose bodies (20%)
- Peroneal pathology (up to 25%)



Treatment:

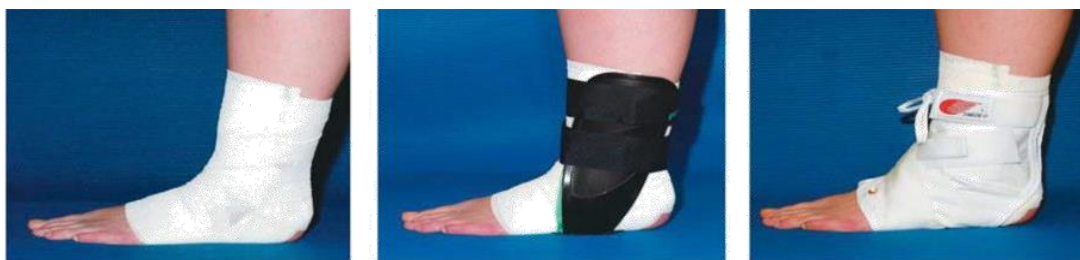Nonsurgical:

- Initial treatment is (RICE).
- Early weight bearing and use of a protective brace during functional activities facilitates recovery better than non-weight bearing or immobilization.
- Functional instability may result and should be treated with a course of physical therapy, emphasizing isometrics and resistive training, peroneal strengthening, range of motion, and proprioceptive training.
- Residual mechanical instability may be managed effectively with bracing or taping.



- Patients may return to unrestricted activity when cutting, running, and hopping on the affected leg are no longer painful.
- Ninety percent of acute ankle sprains resolve with RICE and early functional rehabilitation.

Surgical: Surgery is a reasonable option when an adequate trial of nonsurgical treatment fails to control symptoms.



Summary

- The initial management in sport or soft tissue injury or even in other injuries is RICE (Rest - Ice - Compression - Elevation “at heart level”).
- Commonest type of muscle injury is muscle strain, treated with RICE – NSAID – PT.
- Complications of muscle injury are Scar formation lead to muscle weakness, Compartment syndrome and Myositis ossificans.
- Osteotendinous junction is the most common site of overuse tendon injury. Treatment Goal is to reduce pain and return function, mostly conservative.
- Risk Factors for quadriceps and patellar tendon rupture are: Steroids, Chronic Disease, Tendinopathy, Age (Patella<40 years>Quads) and also the location (at the attachment to the Patella). And treatment for quadriceps and patellar tendon rupture is usually surgical.
- 75% of achilis tendon rupture Most ruptures occur during sporting activities. Usually in ankle dorsiflexion. Treated surgically.
- ACL tear commonly presented as “giving way leg”. It is treated surgically if the patient is young or athlete or a worker who tendon needs repair.
- MCL is the most common injured ligament of the knee, treatment is conservative unless associated with other injuries.
- LCL and PCL are treated conservatively unless surgery is needed.
- Knee dislocation is an emergency and closed reduction and splinting or bracing should be performed immediately with checking N\V before and after.
- Meniscal tear is commonly seen in orthopedics, Treatment is generally nonsurgical “conservative”. Need surgery if ACL injury is associated, if there is mechanical block, or if conservative treatment is failed.
- Ankle sprain is a common sports related injury. Lateral sprains accounting for 85% of all such injuries. Treated first by conservative, if failed we do surgery.

MCQs

1) A bucket-handle tear in the medial cartilage of the knee is repaired by performing which of the following?

- (A) synovectomy
- (B) arthrotomy
- (C) meniscectomy
- (D) ACL repair

2) An 18-year-old football player is seen in the emergency ward with severe knee pain incurred after being hit by a tackler while running. Physical examination is consistent with tearing of a meniscus. Meniscal tears usually result from which of the following circumstances? (A) Hyperextension

- (B) Flexion and rotation
- (C) Simple hyperflexion
- (D) Compression
- (E) Femoral condylar fracture

3) An 18-year-old football player is seen in the emergency ward with severe knee pain incurred after being hit by a tackler while running. Which of the following findings on physical examination is most sensitive for an anterior cruciate ligament injury? (

- (A) Excessive valgus laxity of the knee
- (B) Excessive varus laxity of the knee
- (C) Locked knee
- (D) Positive Lachman test
- (E) Positive posterior drawer test

4) A 25-year-old man experiences pain in the right knee while skiing, causing his knee to twist and him to fall to the ground. His knee is swollen. He cannot bear full weight or fully extend or bend his leg. There is tenderness over the medial joint line (Fig.

12-6). Emergency- room x-ray findings were normal, and the range of motion (ROM), although restricted, is stable to varus and valgus stress. Straight-leg raise is unrestricted. Which is the most likely type of injury?

- (A) Anterior cruciate ligament
- (B) Tuberosity
- (C) Transverse genicular ligament
- (D) Medial meniscus
- (E) Posterior cruciate ligament

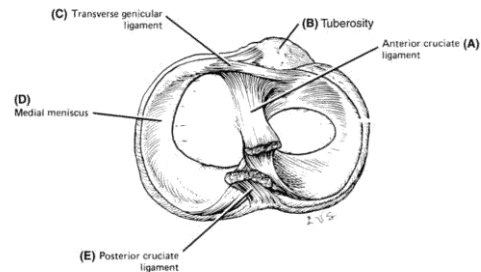


Figure 12-6.
Superior aspect of the right tibia showing ligaments. (Reproduced, with permission, from Lindner HH: Clinical Anatomy. Appleton & Lange, 1989.)

5) A 50-year-old man hears a “snap” and then feels pain in his right leg while lunging for a forearm drive playing tennis. He walks off the court with difficulty, but his leg is swollen and painful. Findings on x-rays of the leg and ankle in the emergency room are negative. Foot sensation is normal, but findings on the Thompson test (failure of plantar flexion to occur after squeezing the gastrocnemius) are positive. What is the diagnosis?

- (A) Gastrocnemius muscle tear
- (B) Acute thrombophlebitis
- (C) Rupture of the Achilles tendon
- (D) Acute compartment syndrome
- (E) Fibula fracture

1-C, 2-B, 3-D, 4-D, 5-C

***MCQs from Lange Q&A surgery book:**

[http://vstudentworld.yolasite.com/resources/books/Lange%20Q&A%20%20Surgery%20\(McGraw-Hill,%202007\).pdf](http://vstudentworld.yolasite.com/resources/books/Lange%20Q&A%20%20Surgery%20(McGraw-Hill,%202007).pdf)

Answers:

- 2) Most meniscal tears are produced by flexion and rapid rotation. A classic example (football knee) involves a player who is hit while running. The knee, supporting the entire player's weight, usually is slightly flexed, and the foot is anchored to the ground by cleats. Impact from an opposing player usually causes rotation almost entirely restricted to the knee. The injury involves rapid rotation of the flexed femoral condyles about the tibial plateau, which most frequently tears the medial meniscus. (Less frequently, the lateral meniscus is torn.) A tear in the inner free border of the cartilage is also common whenever excessive rotation without flexion or extension occurs. Early surgical removal of the displaced menisci is usually recommended to prevent further damage to the cartilage or ligaments.

- 3) Lachman test is a sensitive and reliable clinical test to evaluate for injury to the anterior cruciate ligament (ACL). The knee is held in slight extension and while holding the thigh steady with one hand the tibia is pulled anteriorly with the other hand. Anterior translation of the knee suggests a torn ACL. The posterior drawer test is used to evaluate for a posterior cruciate ligament injury and is essentially the reverse of the Lachman test with a slightly flexed knee. A "locked knee" occasionally occurs with a displaced meniscal tear and prevents full extension of the knee. Excessive valgus laxity (outward deviation of the leg) is associated with a medial cruciate ligament injury while excessive varus laxity can be seen with a lateral cruciate ligament injury.

- 4) Restriction of motion ("locking"), effusion ("swelling"), and medial jointline tenderness are the hallmarks of meniscal tears. Stability-to-stress testing eliminates collateral ligament rupture, and the ability to elevate the straight leg eliminates patella dislocation and quadriceps tendon ruptures. In addition, patella dislocation would also be characterized by gross patella deformity laterally.

- 5) Of all the conditions listed, only an Achilles tendon rupture will result in positive findings on the "squeeze" test (Thompson's sign), whereby a squeezing of the gastrocnemius muscle fails to cause plantar flexion of the foot.

Done by:

Suliman alsuliman

Abdulmalik alqahtani

Edited by:

Hajar Al-Otaibi



