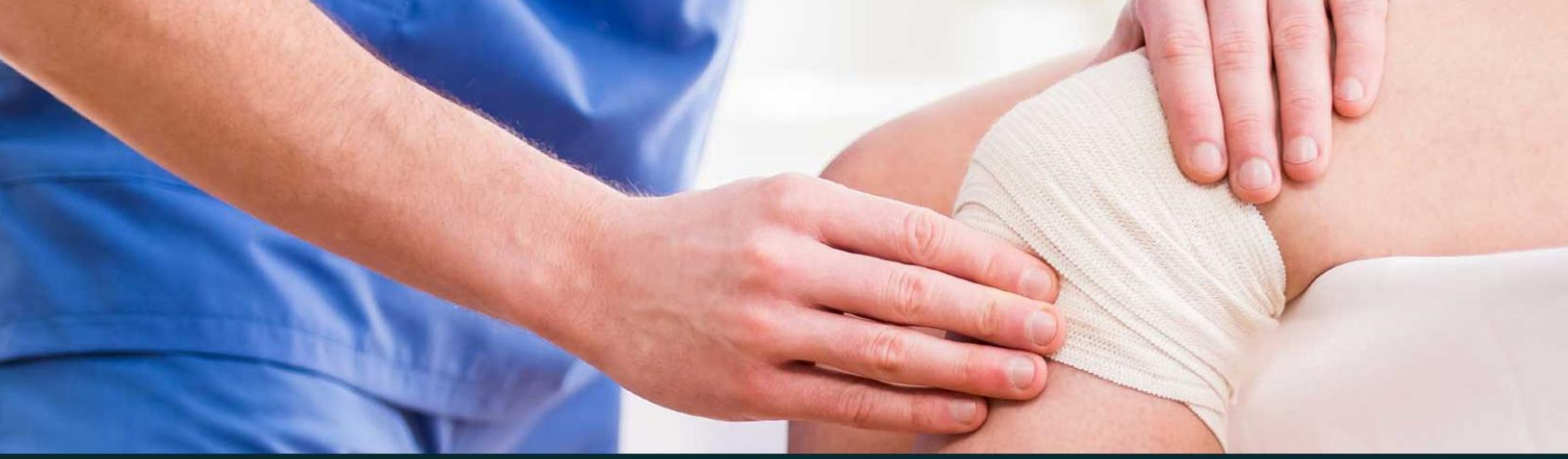



433 Teams
ORTHOPEDICS

Lecture 16

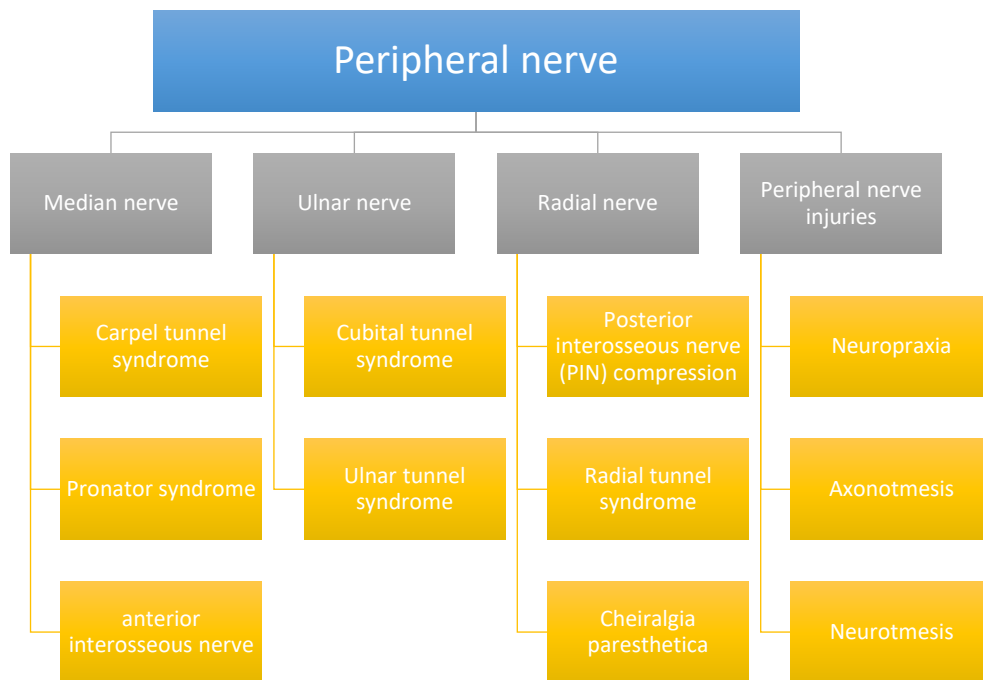
Peripheral Nerve Injury

Ortho433@gmail.com



جامعة
الملك سعود
King Saud University





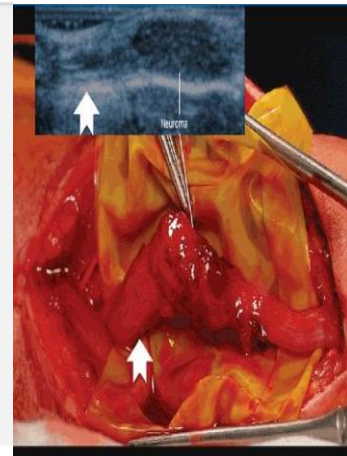
Compression Neuropathy:

- It is a Chronic condition with sensory, motor, or mixed involvement.
- if mixed pathology, sensory function is affected first and then motor is affected
“this is because Motor fibers have thick myelin sheath”
- As a result, first symptom to appear is hypoesthesia and lastly atrophy of the muscles which means severe disease.
- The sensory functions lost are as follows “in order”
 - First lost → light touch – pressure – vibration (mild)
 - Last lost → pain sensation loss – temperature (severe)
- The pathophysiology of compression neuropathy:
 Microvascular compression due to any cause → neural ischemia → paresthesia →
 Intraneural edema → more microvascular compression → demyelination →
 fibrosis → axonal loss.

COMMON SYSTEMIC CONDITIONS LEADING TO COMPRESSION NEUROPATHY:

ANATOMIC
 SYNOVIAL
 FIBROSIS
 LUMBRICAL ENCROACHMENT
 ANOMALOUS TENDON
 MEDIAN ARTERY
 FRACTURE DEFORMITY
 MASS (COMMON WITH ULNAR)
 GANGLION
 LIPOMA
 HEMATOMA

INFLAMMATORY
 Rheumatoid arthritis
 Infection
 Gout
 Tenosynovitis
Fluid Imbalance
 Pregnancy
 Obesity
Systemic
 Diabetes
 Alcoholism
 Renal failure
 Raynaud



Localized edema caused by compression. It's NOT a true neuroma "psudoneuroma".

- pseudoneuroma : is enlargement of the nerve due to compression and edema.
- **Symptoms:** “Rule out systemic causes” –any disease that might cause systemic swelling like heart failure ,kidney failure ,diabetes ,RA ,hypothyroidism ,obesity ,pregnancy.
 - Night symptoms “Sign of advanced disease and indication to surgery”
 - Dropping of objects
 - Clumsiness -due to sensory, motor and proprioception loss
 - Weakness

➤ **Physical examination**

- Examine individual muscle power → grades 0 to 5 → pinch strength - grip strength. compare with the other side
- Neurosensory testing:
 - Dermatomal distribution
 - Peripheral nerve distribution (differentiate between radial and median distribution or C5 because it might be upper level problem .)

➤ **Special tests:**

<p>Semmes-Weinstein monofilaments: (The best test) (can detect very early neuropathy)</p>	<p>- Cutaneous pressure threshold → function of large nerve fibers which is first to be affected in compression neuropathy.</p> <p>Sensing 2.83 monofilament is normal</p>
<p>Two-point discrimination:</p>	<p>- Static function is lost first and then dynamic. - Performed with closed eyes - Inability to perceive a difference between points > 6 mm is considered ABNORMAL “Late finding”.</p>

<p>Electro-diagnostic testing:</p> <ul style="list-style-type: none"> - Sensory and motor nerve function can be tested through EMG and NCS - They are operator dependent (disadvantage) - Objective evidence of neuropathic condition - Helpful in localizing point of compromise - In the early disease, there is a High false-negative rate 	<ul style="list-style-type: none"> ➤ NCSs (nerve conduction studies) only nerve no muscle - Measure conduction velocity and distal latency and amplitude (nerve takes time to respond) - Demyelination → ↓ conduction velocity + ↑ distal latency - Axonal loss → ↓ potential amplitude ➤ EMG (Electromyography) - □ Test muscle electrical activity - In case of muscle denervation → fibrillations, Positive sharp waves, fasciculations
---	---

- **DOUBLE-CRUSH PHENOMENA ***

Blockage of axonal transport at one point makes the entire axon more susceptible to compression elsewhere along the nerve.

- E.g. In thoracic outlet syndrome the lower trunks of the brachial plexus are compressed which makes the ulnar nerve vulnerable to compression. e.g. if a patient with thoracic outlet syndrome comes with ulnar nerve symptoms and you treat the ulnar nerve, the patient will still **have the symptoms or be slightly better because you did not treat the cause (thoracic outlet)**

- **MEDIAN NERVE COMPRESSION**

1. Carpal Tunnel Syndrome.
2. Pronator Syndrome
3. Anterior Interosseous Neuropathy

1- CARPEL TUNNEL SYNDROME

- **Most common compressive neuropathy in the upper extremity.**
- Anatomy of the carpal tunnel
 1. Volar aspect → TCL (transverse carpal ligament)
 2. Radial aspect → scaphoid tubercle + trapezium
 3. Ulnar aspect → pisiform + hook of hamate
 4. Dorsal aspect → proximal carpal row + deep extrinsic volar carpal ligaments

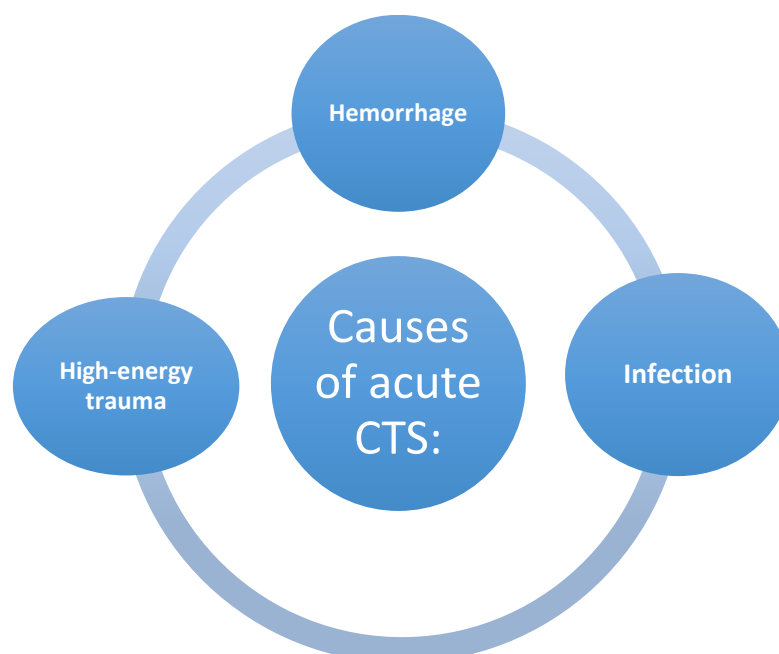
- Content of the carpal tunnel:
 - Median nerve + FPL (flexor pollicis longus) + 4 FDS (flexor digitorum superficialis) + 4 FDP (flexor digitorum profundus) = 10
 - Normal pressure in the tunnel → 2.5 mm Hg “not measured or used clinically”.
 - >20 mm Hg → ↓↓ epineural blood flow + nerve edema
 - >30 mm Hg → ↓↓ nerve conduction

➤ Forms of carpal tunnel syndrome:

- Idiopathic → most common in **adults**
- Mucopolysaccharidosis → most common cause in **children**
- Anatomic variation: (rare)
 - Persistent median artery
 - Small carpal canal
 - Anomalous muscles
 - Extrinsic mass effect

➤ Risk factors:

- Obesity
- Thyroid disease
- Inflammatory arthropathy
- Storage diseases
- Pregnancy
- Alcoholism
- Diabetes
- Chronic renal failure
- Vitamin deficiency
- Advanced age
- Vibratory exposure (using drills and electrical saws) during occupational activity



- **Acute CTS requires emergency decompression (surgical)**
- **For example distal radius fracture, scaphoid fracture.**

➤ **Diagnosis of CTS:**

- **1- Symptoms:** Paresthesia and pain, often at night involving the volar aspect of thumb, index, middle fingers + radial half of ring finger.

- **REMEMBER: Sensory function loss in order:**

Affected first → light touch + vibration

Affected later → pain and temperature

- Symptoms of late findings: Weakness - loss of fine motor control - abnormal two-point discrimination
- Thenar atrophy → severe denervation

- **2- Provocative test** → carpal tunnel compression test - Durkan test

→ The Most sensitive test.(do compression for 1 min)

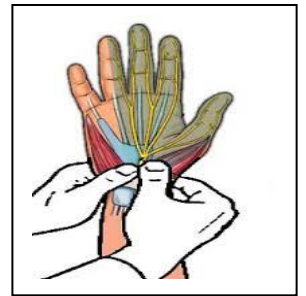
- - Other provocative tests include Tinel and Phalen

- **3- Semmes-Weinstein monofilament testing :**

→ Early CTS diagnosis

- **4- Electro-diagnostic Testing:**

- Not necessary for the diagnosis of CTS (just to reassure the patient)
- Distal sensory latencies > 3.5 msec
- Motor latencies > 4.5 msec
- NCS: ↓ conduction velocity and ↓ peak amplitude → less specific
- EMG: ↑ insertional activity - sharp waves -fibrillation – APB (abductor pollicis brevis) fasciculation.



➤ **Differential diagnosis of CTS:**

- **Cervical radiculopathy (C5/C6)**
- Brachial plexopathy
- **TOS (Thoracic Outlet Syndrome)**
- **Pronator syndrome (most likely)**
- **Ulnar neuropathy with Martin- Gruber anastomoses**
- Peripheral neuropathy of multiple etiologies

➤ Treatment of CTS:

NON-OPERATIVE

- Activity modification
- Night splints (less pressure)
- NSAIDS
- Single corticosteroid injections (transient relief):
 - 80% after 6 weeks
 - 20% after one year
 - Ineffective corticosteroid injection is an indication of poor prognosis therefore less successful surgery rate.
- If the steroid injection did not work it mean either wrong place or there is cervical radiculopathy associated with CTS.

OPERATIVE

- Can be in different approaches:
- open - mini-open – endoscopic
- Internal median neurolysis or flexor tenosynovectomy shows o benefit
- Too ulnar surgical approach → Ulnar neurovascular injury
- Too radial surgical approach → recurrent motor branch of median nerve injury
- Recurrent motor branch variations
 - ✓ Extraligamentous → 50%
 - ✓ Subligamentous → 30%
 - ✓ Transligamentous → 20%

Endoscopic release: (more expensive)

➤ Short term: (within 4 to 6 weeks):

- ✓ Less early scar tenderness.
- ✓ Improved short-term grip/pinch strength.
- ✓ Better patient satisfaction scores.
- ✓ Early return to work.

➤ Long-term:

- ✓ No significant difference (after one year).
- ✓ May have slightly higher complication rate.
- ✓ Incomplete TCL (transverse carpal ligaments) release.

Release outcome:

- Pinch strength → will come back in **6 weeks**
- Grip strength → will come back in **3 months**
- Persistent symptoms after release indicate one of the following:
 - ✓ **Incomplete release**
 - ✓ **Iatrogenic median nerve injury**
 - ✓ Missed double-crush phenomenon
 - ✓ Concomitant peripheral neuropathy
 - ✓ Space-occupying lesion
- Revision success → identify underlying failure cause

Pronator Syndrome

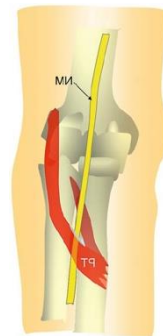Median nerve compression at arm and **forearm** (entrapment of the median nerve between 2 heads of the pronator muscle).

Symptoms:

- Proximal volar forearm pain
- Sensory symptoms → palmar cutaneous branch

Other differential diagnosis:

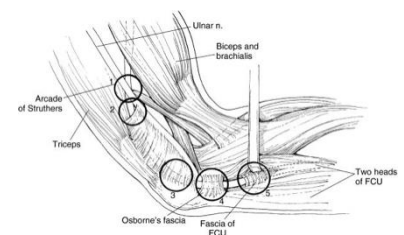
- **Anterior interosseous syndrome:** motor deficit and pain



Ulnar nerve compression

1. Cubital Tunnel Syndrome

- Second most common compression neuropathy of the upper extremity
- Cubital tunnel borders:
 - floor → MCL and capsule
 - Walls → medial epicondyle and olecranon
 - Roof → FCU fascia and arcuate ligament of Osborne
- **Compression sites:** many- more than 5 areas.
- **Clinical presentation:**
 - Paresthesia of ulnar **half of ring finger and small finger**
 - **Provocative tests:** (if the numbness developed, it means +ve test)
 - Direct cubital tunnel compression
 - Tinel sign
 - Elbow hyperflexion (increase the tension for the nerve. So, in mild symptoms casting with extended elbow will release the nerve)
 - **Froment sign:** flexion of the thumb and Interpharyngeal joint when a sheet/credit card is held between the fingers (weak adductor pollicis)



- **Treatment:**

- **Electrodiagnostic tests** → diagnosis and prognosis
- **Nonoperative treatment**
 - activity modification (avoid putting their hands on hard object and prevent hyperflexion of the elbow)
 - night splints → slight extension
 - NSAIDs
- **Surgical Release:** Numerous techniques
 - In situ decompression, Anterior transposition, Subcutaneous, Submuscular, Intramuscular, Medial epicondylectomy
 - No significant difference in outcome between simple decompression and transposition

In case of idiopathic cubital tunnel syndrome: you can use any technique from above. But if the cause is known (severe cubitus varus or deformity of the medial epicondyle) the management is totally different.

2. Ulnar Tunnel Syndrome

- Compression neuropathy of ulnar nerve in the Guyon canal

- **Causes:**

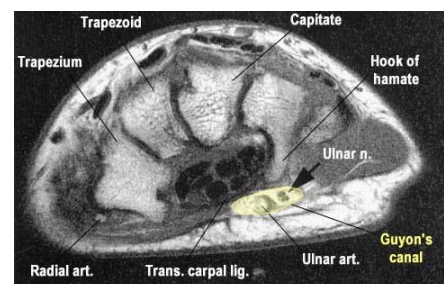
- Ganglion cyst (80%)
- Hook-of-hamate nonunion (in basketball players)
- Ulnar artery thrombosis

- **Investigations:** (you have to do it all to exclude)

- **CT:** for hook-of hamate non-union
- **MRI:** in case of Ganglion cyst (the best test)
- **Doppler:** for ulnar artery thrombosis
- **Nerve conduction study**

- **Treatment** (you have to identify cause)

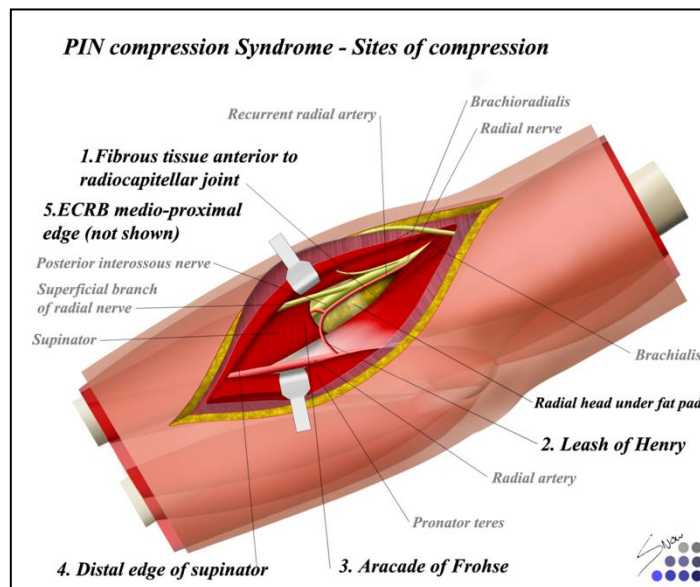
- **Non-operative treatment**
 - activity modification
 - splints
 - NSAIDs
- **Operative treatment** → decompressing by removing underlying cause
- If the patient presented with ulnar compression at Guyon canal + CTS ⇒ CTS release is enough



Radial nerve compression

Rarely compressed and mainly presented with motor symptoms and very vague symptoms.

- **Posterior interosseous nerve (PIN) compression**
 - lateral elbow pain
 - muscle weakness
- **Radial Tunnel Syndrome**
 - lateral elbow and radial forearm pain
 - no motor or sensory dysfunction
- **Cheiralgia paresthetica:** compression or trauma to the **superficial-sensory branch of the radial nerve**.
 - pain
 - numbness
 - paresthesia over dorso-radial hand



Peripheral nerve injuries:

Nerve injury: It is a condition, in which the conductivity of the nerve is affected, can be partial or complete.

Causes (important to know it)

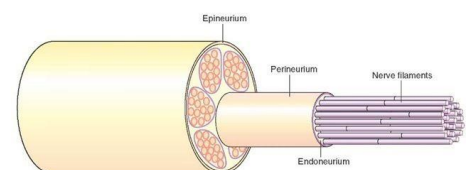
- **Compression** (acute fracture of the distal radius is associated with carpal tunnel syndrome)
- **Stretch** (After surgery, for example humerus surgery and the patient present post-op with drop-wrist due to stretching of the nerve)
- **Blast** (Gun-shoot wound or explosion)
- **Crush** (Heavy object fell down on the patient and usually present with multiple injuries)
- **Avulsion** (Gun-shoot wound when the bullet perpetrates the body it pulls some tissue with it or with retraction in the OR)
- **Transection** (Knife stab or iatrogenic in the OR)
- **Tumor invasion**

Prognostic factors for recovery	
Good factors	Poor factors
Young age (most important factor)	Crush or blast injuries
Stretch injuries (better than transection and crush etc.)	Infected or scarred wounds
Clean wounds	Delayed surgical repair (more than 2 weeks)
After direct surgical repair	

Classifications for peripheral nerve injury:

1. Neuropraxia

- Mild nerve **stretch or contusion**
- Focal conduction block
- No wallerian degeneration (will be explained)
- Disruption of myelin sheath
- Epineurium, perineurium, endoneurium intact
- Prognosis excellent with full recovery (best prognosis)



2. Axonotmesis

- Incomplete nerve injury
- Focal conduction block
- Wallerian degeneration distal to injury
- Disruption of axons
- Sequential loss of axon, endoneurium, perineurium
- May develop neuroma-in-continuity
- Recovery unpredictable
- **Associated with trauma and fractures**

3. Neurotmesis

- Complete nerve injury (**complete cut**)
- Focal conduction block
- Wallerian degeneration distal to injury
- Disruption of all layers, including epineurium (**painful**)
- Proximal nerve end forms neuroma
- Distal end forms glioma
- Worst prognosis

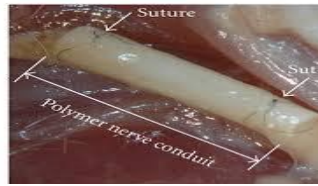Wallerian Degeneration

- Starts in distal nerve segment
- Degradation products is removed by phagocytosis
- Myelin-producing Schwann cells proliferate and align to form a tube to receive regenerating axons
- Nerve cell body enlarges and increased structural protein production
- proximal axon forms sprouts connect to the distal stump → migrate 1 mm/day
(so if there is 1cm gap it takes 10 days)

Surgical repair:

- Best performed within **2 weeks** of injury
- Repair must be **free of tension** (**any tension force will decrease blood supply**)
- Repair must be within clean, well-vascularized wound bed
- Nerve length may be gained by neurolysis or transposition (**neurolysis: release the proximal and distal tension of the nerve**)
- **Repair techniques** (No technique deemed superior)
 - Epineurial (**simple suture between the epineurium**)
 - Individual fascicular
 - Group fascicular

- Nerve conduits → popular for digital nerve gaps >8 mm → polyglycolic acid and collagen based



- Larger gaps → grafting (from the same patient –by using a nerve with minimal function)
- Autogenous → sural - medial/lateral antebrachial cutaneous - terminal/PIN
- Vascularized
- Growth factor augmentation → insulin-like and fibroblast → promote nerve regeneration
- Chronic peripheral nerve injuries → neurotization and/or tendon transfers
- Use of nerve transfers for high radial and ulnar nerve injuries gaining popularity

Questions mentioned by Dr. Hisham which he might ASK ABOUT in the exam:

- **Mention one of the important non-operative treatment for cubital tunnel syndrome?** Night splint
- **Scenario for carpal tunnel syndrome and doctor will ask about treatment options** (you have to know the management for each degree mild, moderate and severe)
- **Someone presented with thenar muscle atrophy. How severe is the case?** Very severe (since the motor function is least to be affected).
- **What information you should tell CTS patient pre-op?** the pain might not go away
- **A pregnant lady came to the clinic with carpal tunnel syndrome would you do surgery for her?** No, the symptoms may disappear by its own after the pregnancy.
- **Distal radius fracture patient started to feel numb what would you do for**

Done By:	Mohammed Alnafisah Ahmed Alhussien
Reviewed By:	Aisha Maher Alsafi

