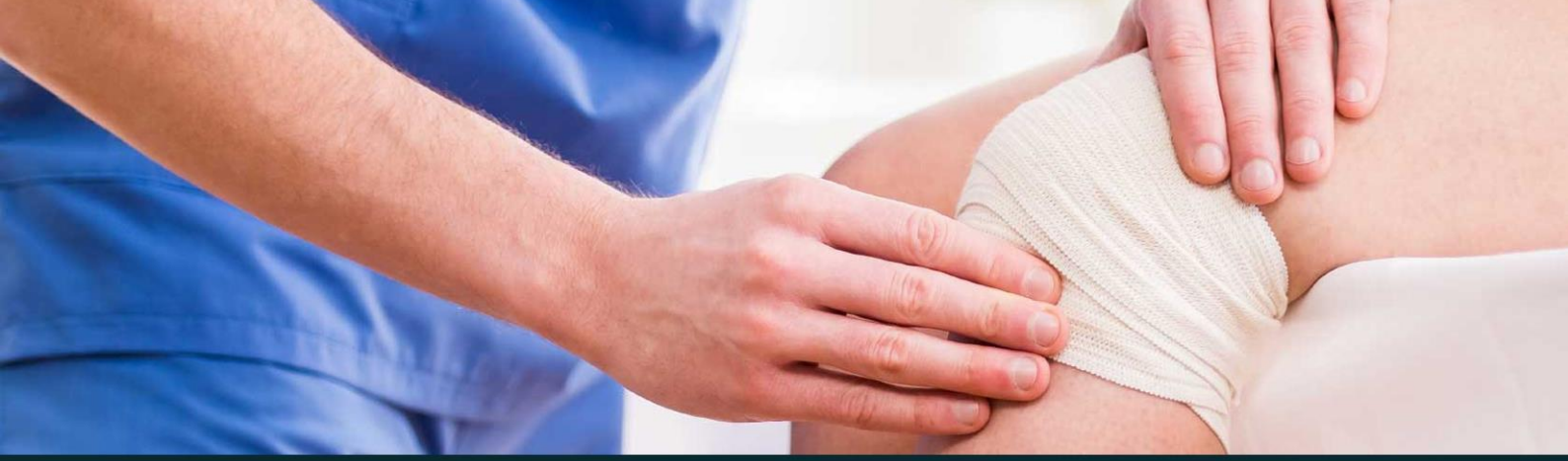



433 Teams  
**ORTHOPEDICS**

Lecture 12

**Common foot and ankle  
disorders**

Ortho433@gmail.com



جامعة  
الملك سعود  
King Saud University



## Objectives

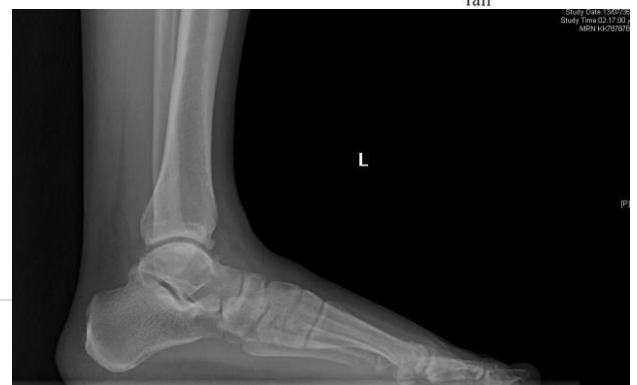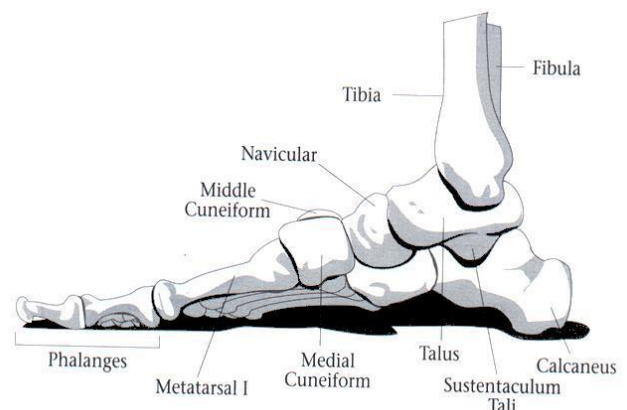
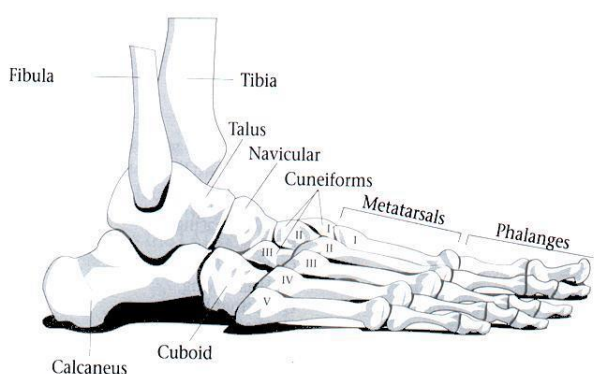
- To understand the importance of bony and soft tissues structure of Foot and Ankle. (Know the names of the bones of the foot)
- To get a concise idea on common Foot and Ankle disorders.
- To differentiate from simple disorders and serious ones.
- To learn about initial management and prognosis.

## Importance of Foot and Ankle:

They are the structures which are subject to most weight bearing (Loading) of the body.

- Have very important proprioception function. (You might fall if you don't have a good proprioception function)
- Their sensory role is very important. (It's more important in the hands, but wounds & injuries are common in the feet. Because feet just take more of a beating in our daily lives than hands do, and we don't look at them as often, so it's harder to spot a wound and it's much harder in diabetes and other neuropathies conditions).
- Their appearance or deformity is easily noticeable.
- Faulty or improper shoe wear can cause symptoms.
- With advancing age; deformity becomes more common.

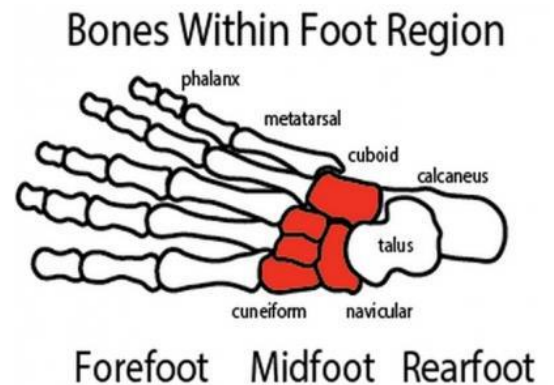
Anatomy: (You should know the names).



**X-ray:** (The standard views of the **ankle** are: AP, **mortise** (an AP view with the ankle internally rotated 15–20 degrees) and Lateral view. -Apley's-.

The standard views of the **foot** are AP & lateral. *Toronto notes 2014.*)

**Forefoot:** Phalanx + Metatarsals  
**Midfoot:** Navicular + Cuboid + 3 cuneiforms  
**Hind (rear) foot:** Talus + Calcaneus



## Common foot & ankle disorders

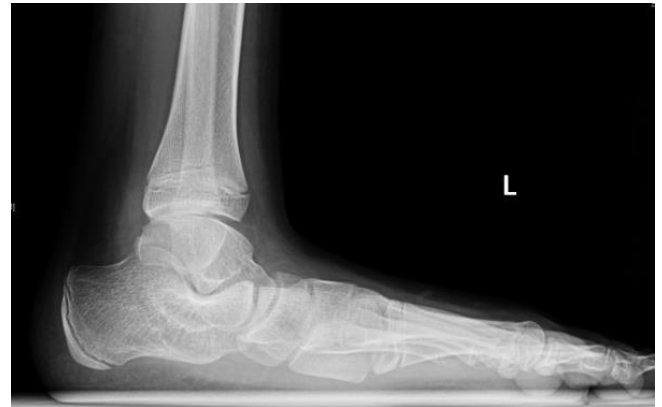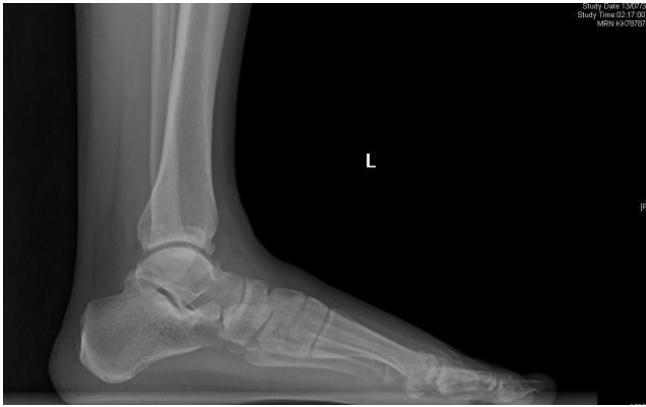### 1- Flat foot (pes planus):

- Means reduced longitudinal arches of the foot.
- Most cases are developmental: i.e. arches do not develop normally. (**Normally, the arch is formed within 4-6 years**)
- Usually is **painless**. (**In flexible flat foot**)
- Rarely acute flat foot can be encountered (**Unilateral and usually happens after trauma**).

(Unilateral flat-foot **in adult** should make one think of **tibialis posterior** synovitis or rupture. Women in later midlife are predominantly affected. Onset is usually insidious, affecting one foot much more than the other. There may be identifiable systemic factors such as obesity, diabetes, corticosteroid medication or past surgery. Apley's).

- Rigid flat foot can be the result of **tarsal coalition\*** (fibrous or bony cross union between bones of the foot )

\* (**Tarsal coalition: the fibrous, cartilaginous, or bony fusion of two or more of the tarsal bones**).



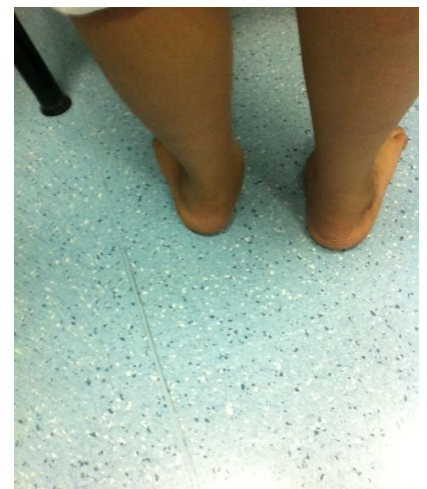CT scanning is the most reliable way of demonstrating tarsal coalitions. Apley's.

### Flat Foot: rigid or flexible? (OSCE):

- Rigid flat foot can be suspected by simple test: when patient is inspected from behind and asked to stand on tip-toes; the heel normally moves inward.
- In cases of rigid flat foot heel does not move inward.
- Also; on examination table: when ankle is held still and heel is moved sideways; it does not move in stiff heel as normally

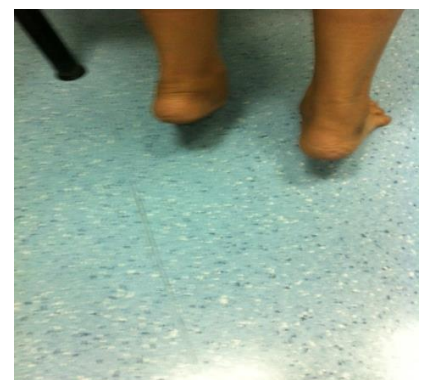(In this picture, we can see excessive valgus in left heel and mild valgus in the right heel)

- Normally the heel is straight or minimally in valgus. (we don't accept any varus in the heels)
- This patient has normal appearance Right heel and excessive valgus Left heel.



(We asked him to stand on his tip toes)

- Both heels correct their valgus and point medially in some varus:
- This is NOT rigid flat foot and there is no tarsal coalition (most common cause of rigid flat foot especially in teenager) or bony bar connecting tarsal bones.

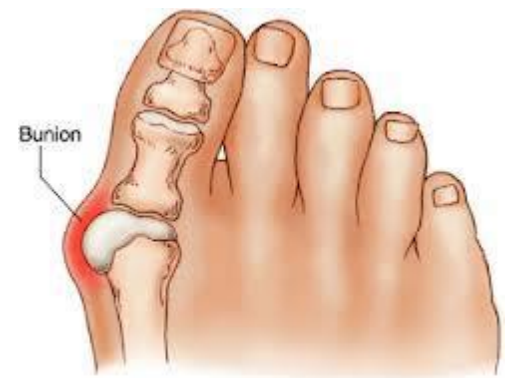

## Flat Foot management:

- Usually NO action is needed.
- Foot exercises is prescribed; but its value is not confirmed.
- Orthotics, insoles and heel cups are sometimes prescribed; but its benefit is doubtful.
- However choosing correct and good type of shoes can be of benefit on the long run (patients should not wear shoes with soft heel cups).
- Rigid flat foot may require surgical management.

## 2- Hallux Valgus (Bunion):

- Means lateral deviation of big toe.
- Usually at the metatarsophalangeal joint.
- Often is associated with a **bunion** (swelling and protrusion at the medial aspect of big toe). Most often associated with poor-fitting footwear but can be hereditary. *Toronto notes 2014*



- Common at **middle age** and elderly (*rheumatoid arthritis*), **mainly females**.

**Hallux valgus is the commonest of the foot deformities -and probably of all musculoskeletal deformities.**

- Most cases are painless. **Pain, if present, may be due to:**

**(1) shoe pressure on a large or an inflamed bunion;**

**(2) splaying of the forefoot and muscle strain (metatarsalgia);**

**(3) associated deformities of the lesser toes; or**

**(4) secondary osteoarthritis of the first metatarsophalangeal joint.**

- When severe it interferes with shoe wear and may cause symptoms.

### Hallux Valgus Measurements: (doctor skipped this part)

Hallux Valgus Angel: angle between line extending along 1st metatarsal and a line extending along proximal phalanx.

Normal angles:  $< 15$

Mild HV: 16-25

Moderate HV: 26-35

Severe HV:  $> 35$

**1st intermetatarsal angle: Important angle for the diagnosis of Metatarsus primus varus** Angle between 1st metatarsal long axis and 2nd metatarsal

$N < 10$

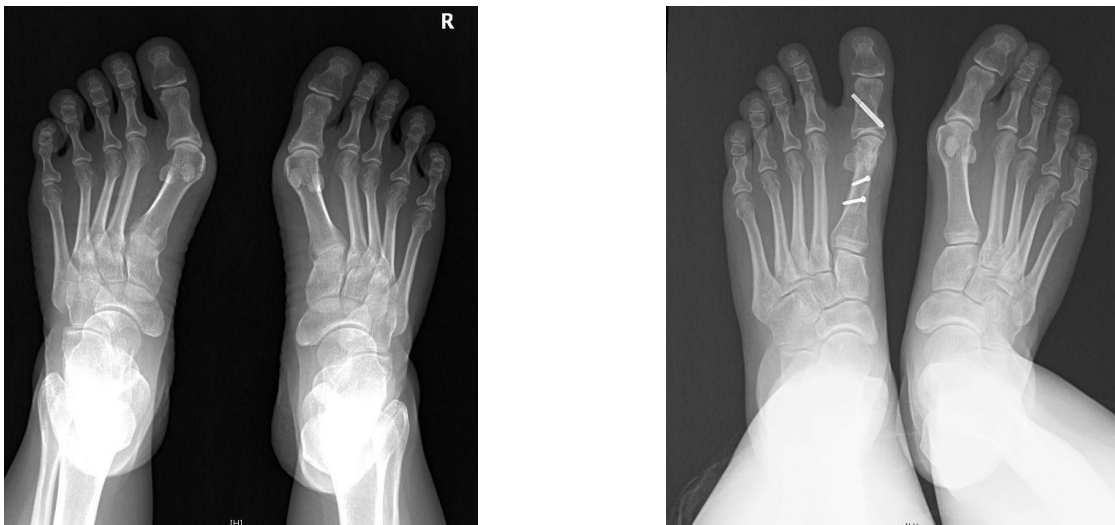Hallux interphalangeus angle:

- Angle between long axis of proximal and distal phalanges

$N < 8$

## Hallux Valgus Management:

- Correct and suitable shoe wear. (initial management)
- Avoidance of tight shoes.
- Protection to the bunions. By using bunion cushions.
- Surgery is reserved for symptomatic and disturbing cases. only if it's painful.
- Following surgery; patient has to continue proper shoe wear

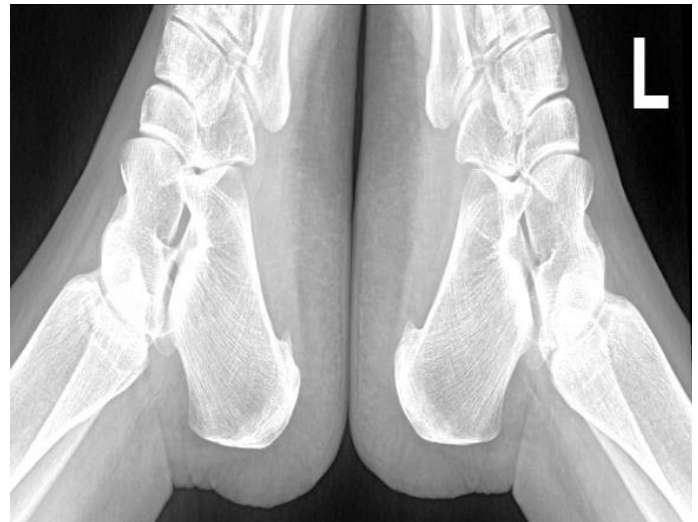
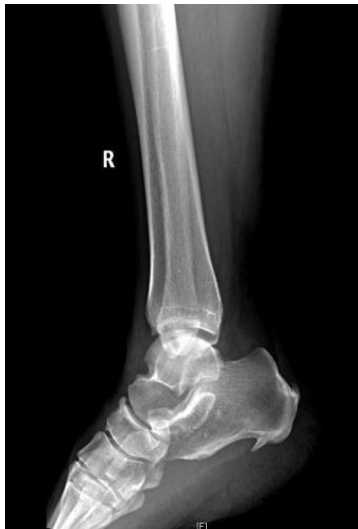
### Note:

- DON'T confuse Bunion with gout. Yes they share some similarities. However, there are some differences as well.
- Bunions are a gradual deformity, while gout pain is often felt suddenly and can be more severe than bunion pain (if there is any). Also, Gout pain and swelling tend to occur in episodes, while bunion pain is more constant. Lastly, a bunion is likely to cause a bony protrusion on the inner side of the foot, while gout does not.

### 3- Heel Pain: Plantar Fasciitis:

- Common disorder at middle age and elderly.
- Insidious in onset; unilateral or bilateral.
- Vague pain at heel region.
- **Localized tenderness** to insertion of plantar fascia into calcaneum.
- Plain lateral X-ray of heel frequently shows **calcaneal spur** (specific sign) (prominence or ossification at the site of anterior calcaneum at plantar fascia insertion site). **An abnormal bony growth on the calcaneus.**



- Commonly associated with flat feet.
- No visible heel swelling, no skin changes and no increase in local temperature. • Inflammatory process is at site of pain; i.e. at plantar fascia insertion into calcaneum.
- spur is secondary to inflammation, not the cause of pain. Toronto notes 2014
- Heel pain like stabbing pain when patient puts foot to the ground (It is worse on weight bearing) first thing in **the morning**; and gets less after some walking.



## Plantar Fasciitis management:

- At present NO easy or simple management is available.
- Mainly conservative. Includes: stretching exercises to plantar fascia: active and passive. Use of soft heel insoles (Silicone) may be helpful.
- Shock wave therapy (SWT) may be effective.
- Local steroid injections are helpful sometimes.

## 4- Ankle Sprains:

- One of most common injuries. **especially in young male population.**
- Usually occurs during **sports activities.**
- But may occur at home or at street.
- Is the result of twisting injury? **plantar flexion, inversion, and rotation.**
- There is pain, swelling and local bruising.
- X-rays do not show fracture. **However, about 15% of ankle sprains reaching the Emergency Department are associated with an ankle fracture.**  
*Apley's.*
- The injury is partial or complete ligament rupture. **If the tear is partial, healing is likely to restore full function to the joint; however, with complete tears, joint instability may persist.** *Apley's.*

Most commonly injured ligament is the **Anterior Talo-Fibular Ligament.**

- **Ankle anterior drawer test** is used to detect its rupture. **When the result is inconclusive, Do an ankle stress x-ray.**
- Other ligaments are Posterior Talo-Fibular Ligament and Calcaneo-Fibular ligament. **More than 90% of ankle ligament injuries involve the lateral side – usually the anterior talofibular, or both this and the calcaneofibular ligament; only in the most severe injuries is the posterior talofibular ligament torn.** *Apley's.*

### Clinical picture of Ankle Sprains:

- Always there is a history of twisting injury.
- Pain, swelling and bruising at and around ankle.
- No tenderness of lateral malleolus; but tenderness anterior, posterior or inferior to it i.e. over ligaments.
- Dorsi-flexion and plantar flexion possible; but inversion and eversion very painful.
- X-Rays: NO fracture.

X-ray examination is called for if there is: (any sign of bone fracture)

- Pain around the malleolus.
- Inability to take weight on the ankle immediately after the injury.
- Inability to take four steps in the Emergency Department.
- Bone tenderness at the posterior edge or tip of either of the malleoli or the base of the fifth metatarsal bone. *Apley's*

### **Management of Ankle Sprain:**

- **RICE**: Rest, Ice, Compressors, Elevation.
- Used to apply Back-slab splints for few days.
- Rest should only be for few days.
- **PRICES**: recent view = Protection (splints), Relative Rest, Ice, Compression, Elevation and Support.

(Splints are better than back slab casts because you can wear/remove splint anytime and splints allow dorsiflexion and plantarflexion movements)

## 5- Osteochondral Defects of talus (OCD):

- Very localized areas of joint damage; due to lack of blood supply.
- Lack of blood supply is often **post traumatic** (**most common cause**), but occasionally No cause can be found.
- A local cartilage and varying depth of underneath bone are involved and may separate of main talus inside the ankle joint.
- Usually postero-medial part of dome of talus.
- **Localized pain** on weight bearing and even at rest may present.

### Management of OCD:

- Depends on how much symptoms and disturbance the patient suffers.
- Also when the OCD is large and Loose or almost loose.
- Arthroscopic debridement of the lesion and drilling of its crater (base).  
(From431: - If it didn't separate we surgically enter and create holes to make artificial channels to facilitate for the bone's blood supply (doesn't succeed 100% about 70-80%), this helps in giving blood supply to the ischemic bone so it won't separate, then it will reunite with the rest of the bone (this also happens in the knee and shoulder). This only works if there is ischemia and the bone still didn't separate.
  - If a line of demarcation is seen after a long period of ischemia an indication of dead bone (not connected to the rest of the bone), in this case we remove the bone, we don't leave it since it is a dead bone. Cartilage grafting/transplantation is done in weight bearing areas).
- Rarely Fixation of a large defect which has significant bony part, by absorbable screws.
- If left untreated, osteoarthritis may occur.

## 6-Diabetic Foot:

- Long term diabetes or failure to control diabetes adequately may result in **Neuropathy**.
- Neuropathy: is nerve damage.
- It can result in numbness, tingling and reduced sensation of the feet.
- Decreased circulation associated with neuropathy can result in small cuts on feet being overlooked and becoming infected. **Uncontrolled diabetes reduces immunity and, in combination with peripheral neuropathy and ischemia, increases the risk of infection after minor trauma. Apley's**
- Infection in diabetic foot may result in **Gangrene**.

### Foot care and diabetes:

- Very important as well as blood sugar control.
- Daily self-inspection of feet is mandatory.
- If patient is unable to do self inspection (due to poor sight or hips and knees stiffness); a member of the family or assistant should do it.
- Regular inspections by healthcare personnel should be arranged
- A visit to a doctor should take place immediately whenever any complication occurs.

### Surgery in Diabetic Foot:

- Skilled care of wounds and ulcers in diabetic foot is required.
- **Wound debridement**, antibiotics and repeated dressing should be done. • Amputations may become necessary when there is Gangrene.
- Toe amputation or ray amputation, forefoot amputation, below or above knee amputation.

## 7-Charcot Foot (Neuroarthropathy):

- Occurs in people who have significant nerve damage to the foot.
- The bones of the foot become weak and the joints inflamed, swollen and lax.
- walking on the foot leads to disintegration and collapse of the joints and Deformity: such as Rocker- bottom deformity.

### Charcot Foot Causes:

- Any disorder which lead to Neuropathy. Ex; diabetes.
- There is decreased sensation and decreased ability to feel temperature, pain and trauma.

### Clinical picture of Charcot Foot:

- Warmth of an area of foot or whole foot.
- May become red or dusky in color.
- Swelling in the area. **Sometimes with history of trauma.**
- Pain (**Mild**) or soreness.
- X-rays changes are important to detect and interpret, as early there is NO changes.
- Later: haziness, osteopenia, irregular joint destruction, subluxation or even dislocation.

### Diagnosis of Charcot Foot:

- Good history and clinical examination.
- Awareness.
- Exclusion of other causes which may give similar picture: like infection or tumour.
- MRI, bone scans, aspiration biopsies can help.
- **Always ask about diabetes and whether it's controlled or not.**

## Management of Charcot Foot:

Non surgical:

- Immobilization.
- Custom Shoes and Bracing.
- Activity modification.

Surgical:

- May be indicated in certain cases. 30% success rate in severe cases.

(From 431: **Amputation in Charcot foot:**

- May be indicated as a last option (**Remove if the leg won't help the patient with his mobility function or if there is a susceptibility to infection**).
- Mainly when there is severe instability that cannot be controlled by surgery or orthosis.
- Also when surgery fails to achieve stability.
- Presence of refractory infection increases the possibility of amputation.





<b>Done By:</b>	Ahmad Alzoman
<b>Revised By:</b>	Zhour Abdullah Alhedyan
<b>Team leaders :</b>	Abdulrahman Albasseet(A1) Mariam Bawazir (F1)

