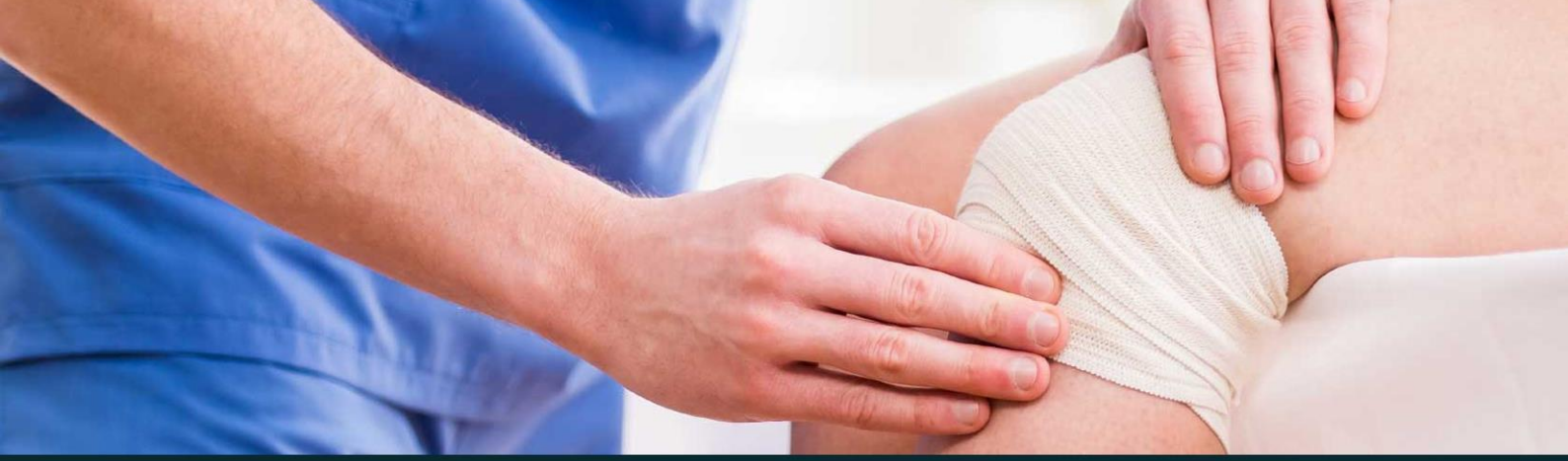



433 Teams

ORTHOPEDICS

Skills 2

Splinting and casting

Ortho433@gmail.com



جامعة
الملك سعود
King Saud University



Introduction:

The initial approach to casting and splinting requires a thorough assessment of the injured extremity for proper diagnosis. Examine the skin, neurovascular status (before and after: a. reduction, b. casting or splinting), soft tissues, and bony structures to accurately assess and diagnose the injury.

Indication for immobilization

- Fractures
- Sprains
- Severe soft tissue injuries
- Reduced joint dislocations
- Inflammatory conditions: tendinopathy, tenosynovitis.
- Deep laceration repairs across joints
- Tendon laceration

Materials and Equipment

- Stockinet (2-3 inches for upper limb, 4 inches for lower limb)
- Sheets, under pads (to minimize soiling of the patient's clothing)
- Plaster or fiberglass casting material
- Padding (soft rolls)
- Elastic bandage (for splints)
- Casting gloves (necessary for fiberglass)
- Basin of water at room temperature (dipping water)
- Bandage scissors
- Adhesive tape
-

Control of setting time

The normal setting time is 4-5min.

Factors that speed setting time	Factors that slow setting time
Warm water	Cold water
Soft water	Hard water
Fiber glass cast use	Plaster of Paris (POP)
Accelerator use: potassium sulfate borate	retarder use: sodium
Reuse of dipping water	

The most important variable affecting the setting time is **water temperature**. The faster the material sets, the greater the heat produced, and the greater the risk of significant skin burns.

A good rule is that heat is inversely proportional to the setting time and directly proportional to the **number of layers used**.

Gypsum is the precursor of P.O.P, known as calcium sulphate dihydrate. Gypsum + heat = P.O.P + water

General Application Procedures :

The physician should carefully **inspect the involved extremity and document skin lesions, soft-tissue injuries, and neurovascular status before splint or cast application. Following immobilization, neurovascular status should be rechecked and documented.**

Pay attention to the patient comfort status and pain level; never re-align a fracture without adequate analgesia.

The patient's clothing should also be covered with sheets to protect it and the surrounding area from being soiled by water and plaster or fiberglass.

Before you start: wash your hands, wear gloves, take permission and expose the fractured part.

Types and techniques:**A. Complete cast:**

- Measure the length
- The physician hold the limb reduced and the assistant apply stockinet
- Stockinet; 10 cm longer than the required length, therefore can be folded
- Soft roll application; in the same position the limb will be immobilized, avoid folds at joint line, apply extra padding at bony prominence (each layer with 50% overlap)
- Assistant immerses P.O.P in warm water until all air bubble within the bandage disappears
- Squeeze the bandage to expel excess water
- P.O.P applied around the limb with gentle firmness, each circle should overlap about half the width
- The plaster should be smoothed and molded
- Limb should be elevated and iced in the first 48hrs to decrease the swelling

General roles for cast fixation:

- Immobilize the joint above and below the fracture
- Try not to immobilize any joint unnecessarily
- Immobilize the joint in functional position whenever possible; e.g. **knee 10-15 degree flexion, elbow 90 degree flexion, ankle and wrist are neutral**
- **At the wrist stop just proximal to the distal palmer crease, to keep metacarpophalangeal joint free**

- Proximally:

A. Below elbow: two finger width distal to the elbow crease

B. Above elbow: just below deltoid insertion

-For the foot: distally keep all the toes exposed

- Proximally:

A. Below knee: Just below The tibial tuberosity

B. Above knee: upper third of the thigh

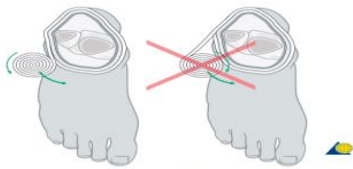


Figure: Note handling the soft rolls and POP cast.

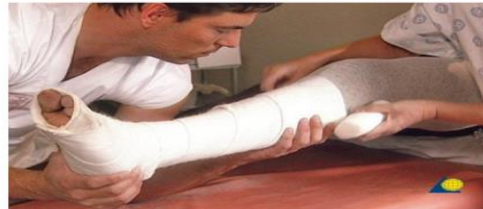
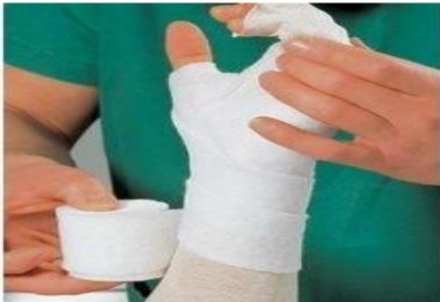
Figure: 50% overlap for the soft rolls when applied.

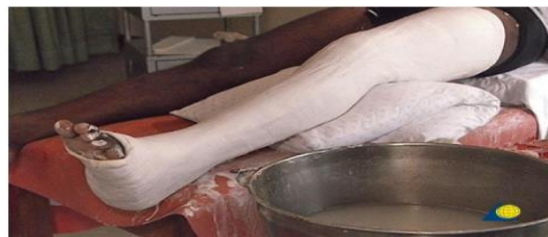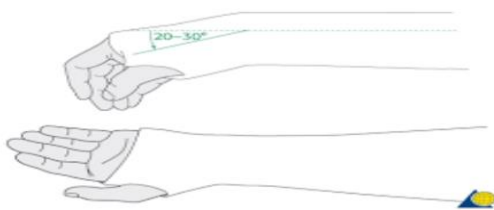


Figure: Distally the distal palmer crease should be seen, for distal lower limbs all the toes are exposed.

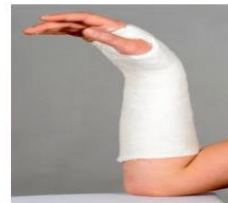
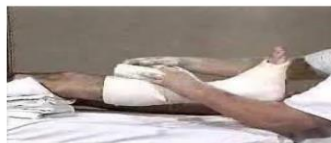
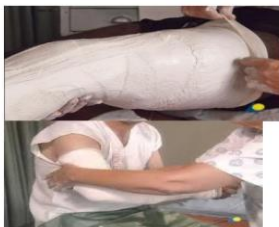Figure: for above knee at upper third of thigh (note folding of the stockinet to make smooth upper end), for below knee the proximal end just below tibial tubercle, for below elbow two fingers width below elbow crease and above elbow just below deltoid insertion.

- Lower limb Complete Cast (below knee) : <https://youtu.be/pxuzevCF92k>
- Upper limb Complete Cast (above elbow) : <https://youtu.be/4w76zbUHH-g>

Advantages of Complete Cast :	Disadvantages of Complete Cast :
Cheap and easily available	More time and skills needed to apply
Versatile	More complication compared to slab
Fairly strong	Stiffness of immobilized joints
More effective immobilization compare to slab	Pressure problems
-----	Not water proof
-----	Heavy compared to fiberglass cast

B. Plaster slab:

- Measure the length
- The physician hold the limb reduced and the assistant apply stockinette
- Stockinette; 10 cm longer than the required length, therefore can be folded
- Soft roll application; in the same position the limb will be immobilized, avoid folds at joint line, apply extra padding at bony prominence
- A longitudinal piece of plaster prepared to the required length, folded in 10 layers
- Assistant immerses P.O.P in warm water until all air bubble within the bandage disappears
- Squeeze the bandage to expel excess water
- Apply dorsally and hold by gauze bandage
- Limb should be elevated and iced in the first 48hrs to decrease the swelling

Advantages of Slab :	Disadvantages of Slab :
Faster and easier to apply	Lack of patient compliance
Because a splint is non-circumferential, it allows for the natural swelling that occurs during the initial inflammatory phase of the injury	Excessive motion at the injury site
A splint may be removed more easily than a cast, allowing for regular inspection of the injury site	-----

Complication of cast application:

- **Compartment syndrome**
- **Ischemia**
- **Heat injury**
- **Pressure sores and skin breakdown**
- **Infection**
- **Dermatitis**
- **Joint stiffness**
- **Neurologic injury**

Cast instructions should be provided to the patient:

- Keep limb elevated esp. first 48hrs
- Move fingers/toes
- Exercise all joints not included in the cast
- If fingers/toes become swollen, painful or stiff raise the limb, apply ice and move the fingers/toes
- If no improvement in half hr. return to the hospital immediately
- If the cast becomes loose or cracked report to hospital

Indication for splitting or removal of cast:

- Swelling of toes/fingers without ischemia → **split the cast**
- Swelling of toes/fingers with sign of ischemia/compartment syndrome → **remove the cast and all compressive dressing down to skin .**

Cast removal:

- A cast saw is a specialized saw made just for taking off casts. It has a flat and rounded metal blade that has teeth and vibrates back and forth at a high rate of speed.
- **The cast saw is made to vibrate and cut through the cast but not to cut the skin underneath.**
- After several cuts are made in the cast (usually along either side, in and out technique), it is then spread and opened with a special tool to lift the cast off.
- The underlying layers of cast padding and stockinet are then cut off with scissors.



Figure: Handling of the saw, in and out controlled cuts.

- Lower Leg Cast Removal: <https://youtu.be/y1n623RB1CY>
- Below elbow Cast Removal : <https://youtu.be/IMbVc2KGNQM>

Done By:	Rahma Al-shehri
Revised by :	Mariam bawazir

