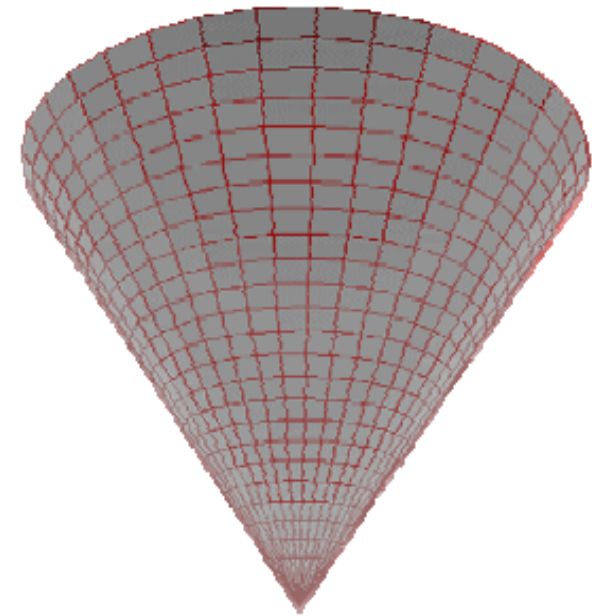


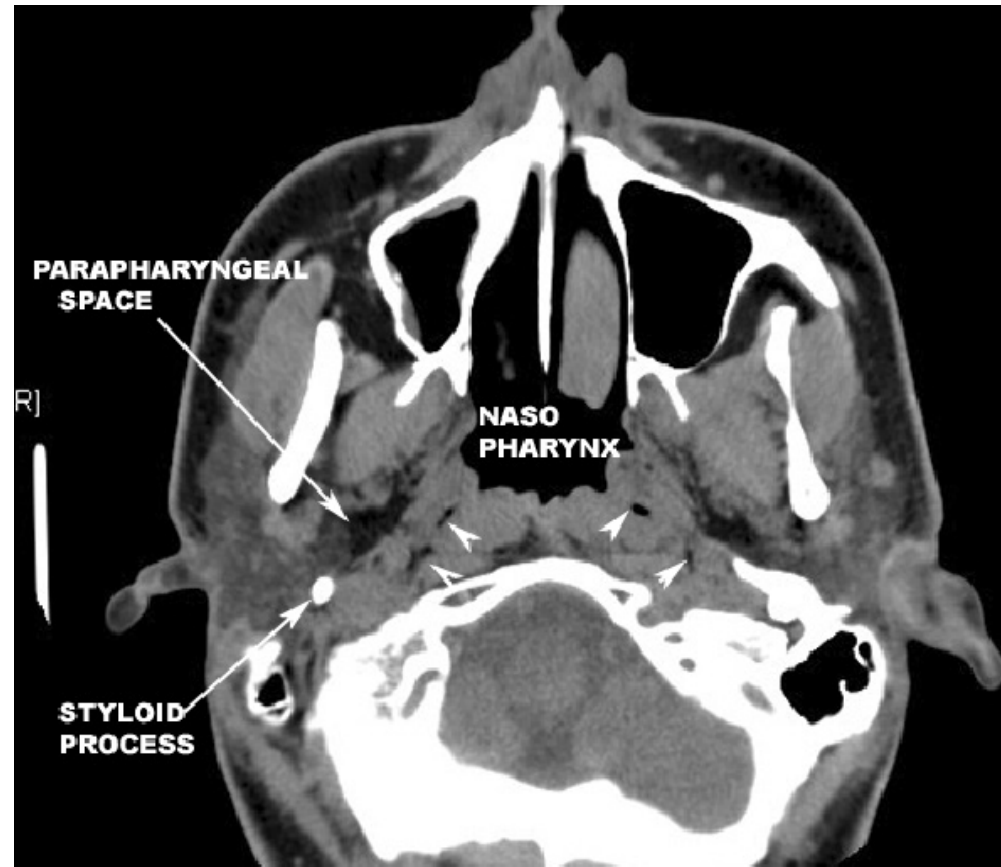
The parapharyngeal space (PPS)

- Cone shaped
 - Base at temporal bone
 - Apex at the hyoid bone
- Between
 - Pharyngeal
 - Lat + med pterygoid muscles



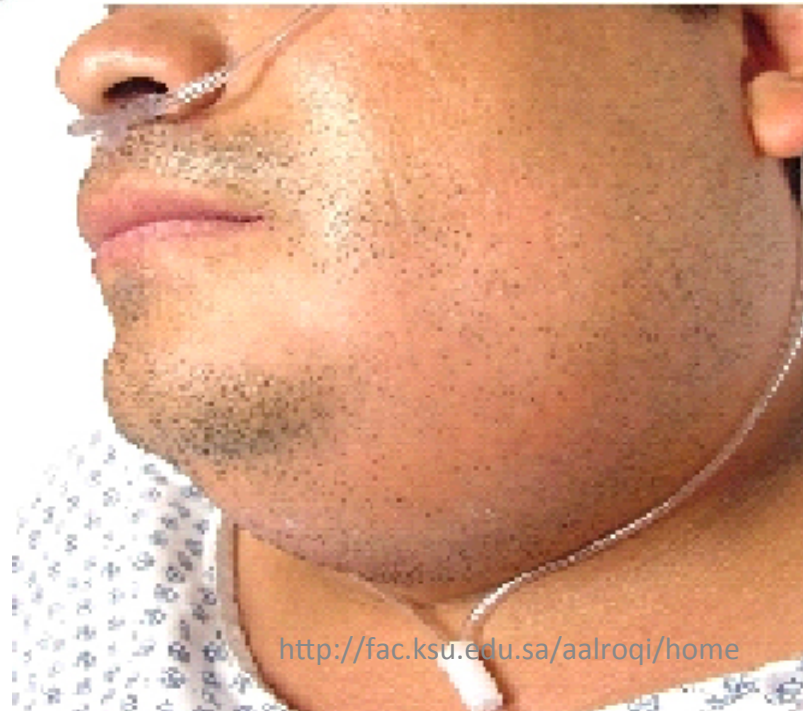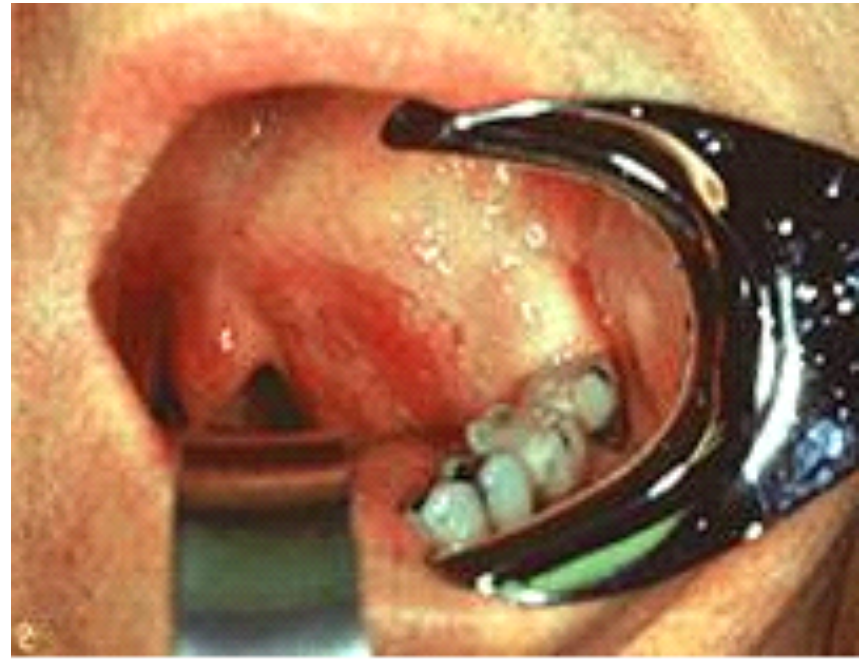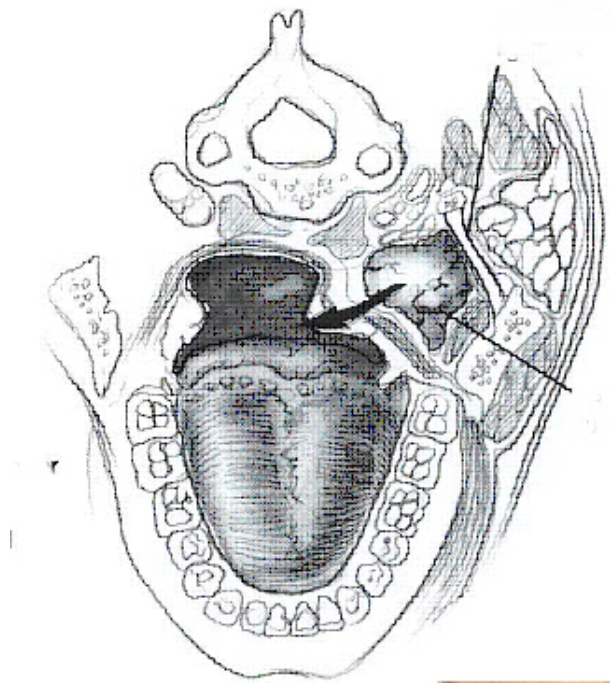
Contents

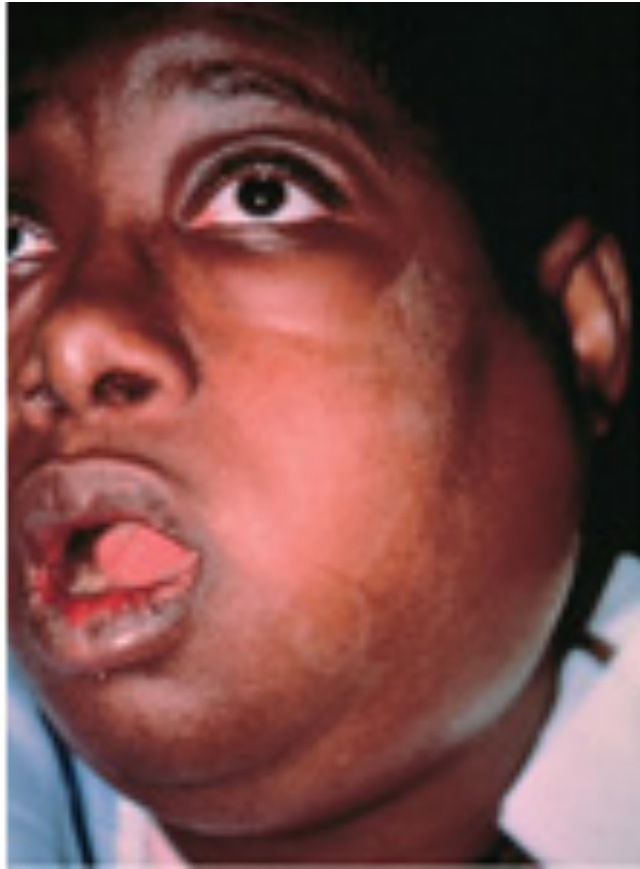- Loose fibrofatty tissues
- Carotid artery
- Internal jugular vein
- Cranial nerves IX, X, XI, and XII;
- Cervical sympathetic chain
- Lymph nodes
 - Nasal cavity, paranasal sinuses
 - Nasopharynx and oropharynx,
 - Mastoid tip



Clinical features of parapharyngeal abscess

- Systemic manifestations
- Pain, trismus, swelling



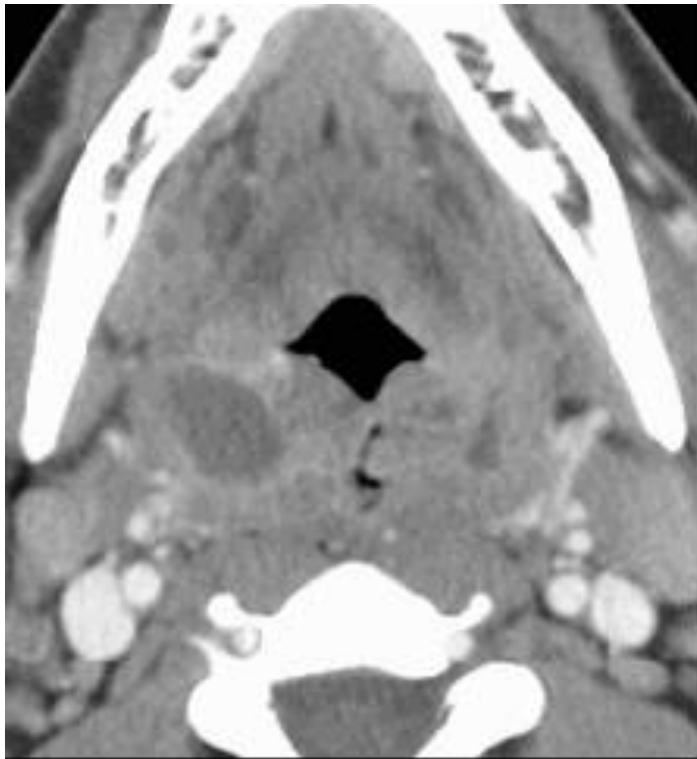

CLINICAL FEATURES

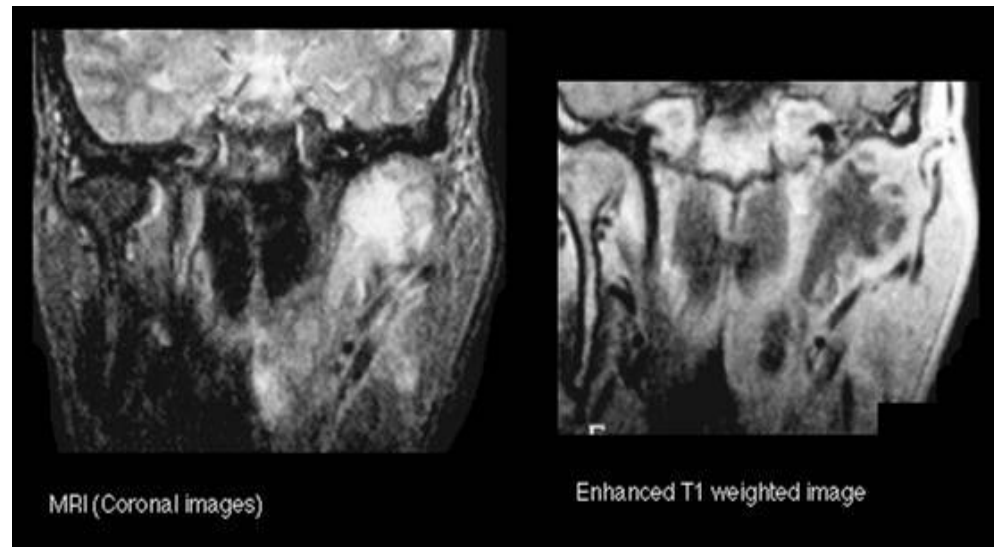
- Systemic manifestations
- Pain, trismus, swelling

INVESTIGATION

- Laboratory and bacteriology
- CT
- MRI



79



<http://fac.ksu.edu.sa/aalroqi/home>

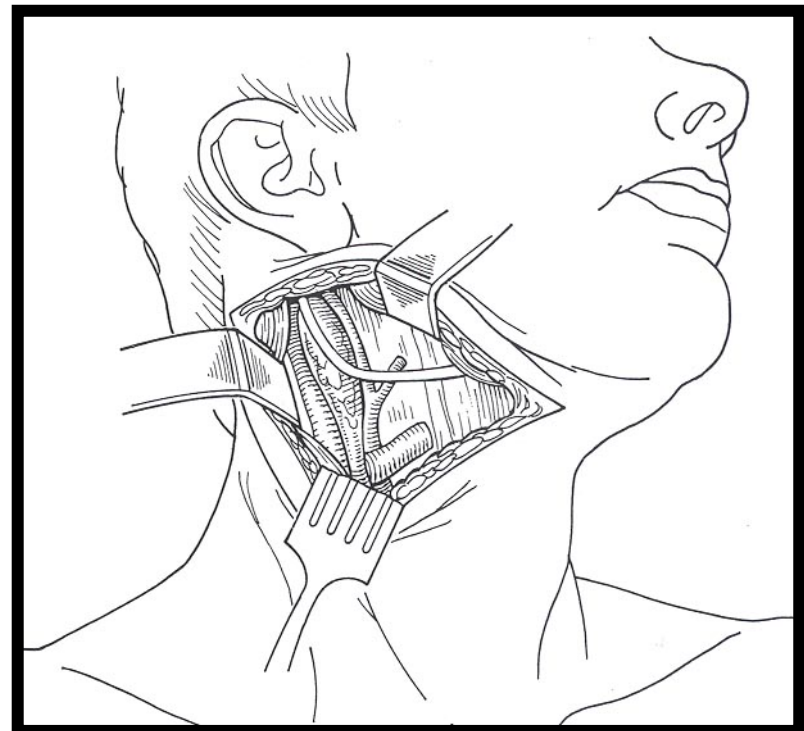
4/7/14 11:06 PM

PRINCIPLES OF TREATMENT

- Secure the airway
- Antimicrobial therapy
- Surgical drainage

DRAINAGE OF PARAPHARYNGEAL ABSCESS

- External cervical incision
- In order to avoid injury to the great vessels



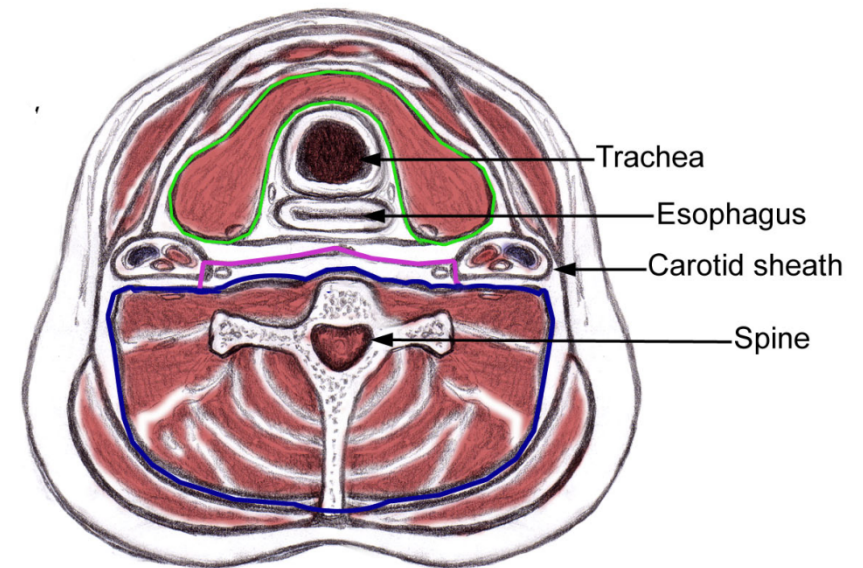
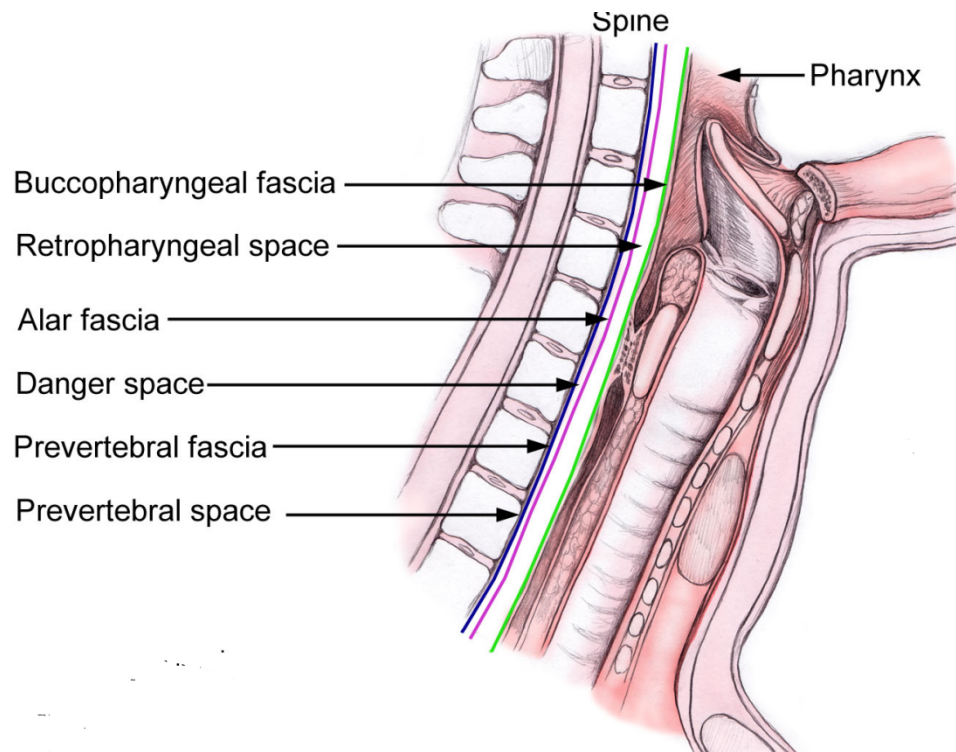
COMPLICATIONS OF ACUTE TONSILLITIS

- General:
 - Acute rheumatism
 - Acute glomerulonephritis
 - Septicaemia
- Local:
 - Peritonsillitis & peritonsillar abscess (Quinsy)
 - Neck Abscess
 - Parapharyngeal abscess
 - **Retropharyngeal abscess**

Retropharyngeal space

- Between
 - Prevertebral fascia
 - Posterior pharyngeal wall and esophagus fascia
- From
 - Skull base
 - Tracheal bifurcation
- Major route → mediastinum.

Anatomy of retropharyngeal space

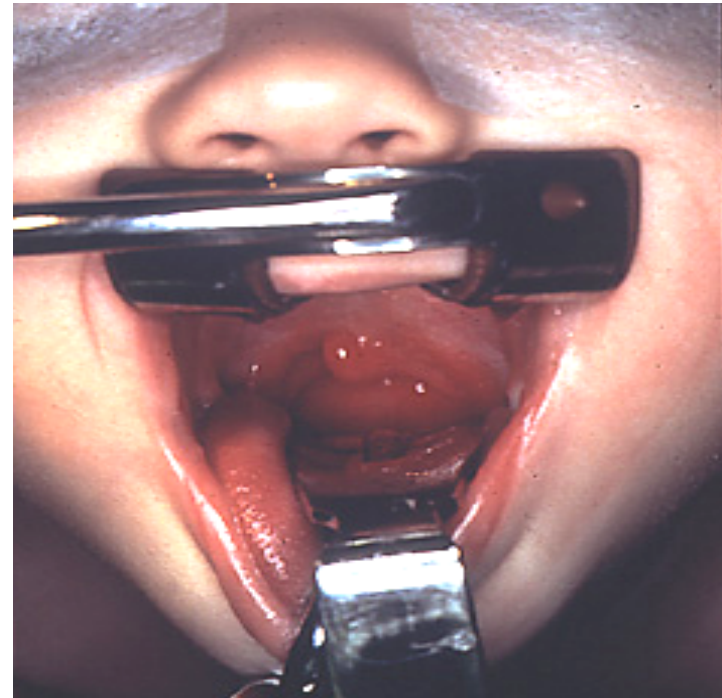

ACUTE RETROPHARYNGEAL ABSCESS

- Due to suppuration of the retropharyngeal lymph nodes present in the retropharyngeal space

CLINICAL FEATURES

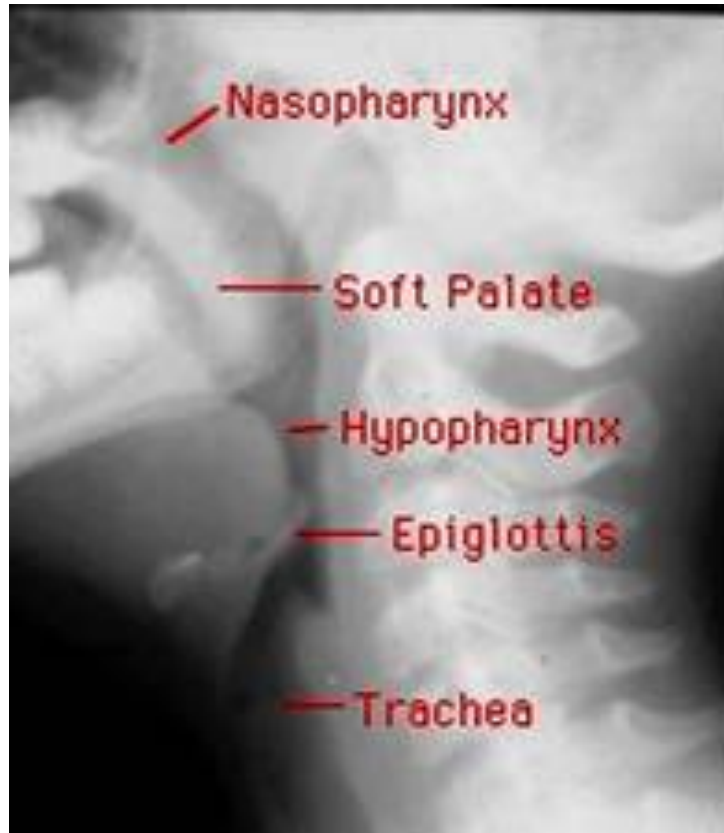- Systemic manifestations
- Respiratory obstruction
- Odynophagia & Dysphagia
- Swelling of posterior pharyngeal wall (usually unilateral)



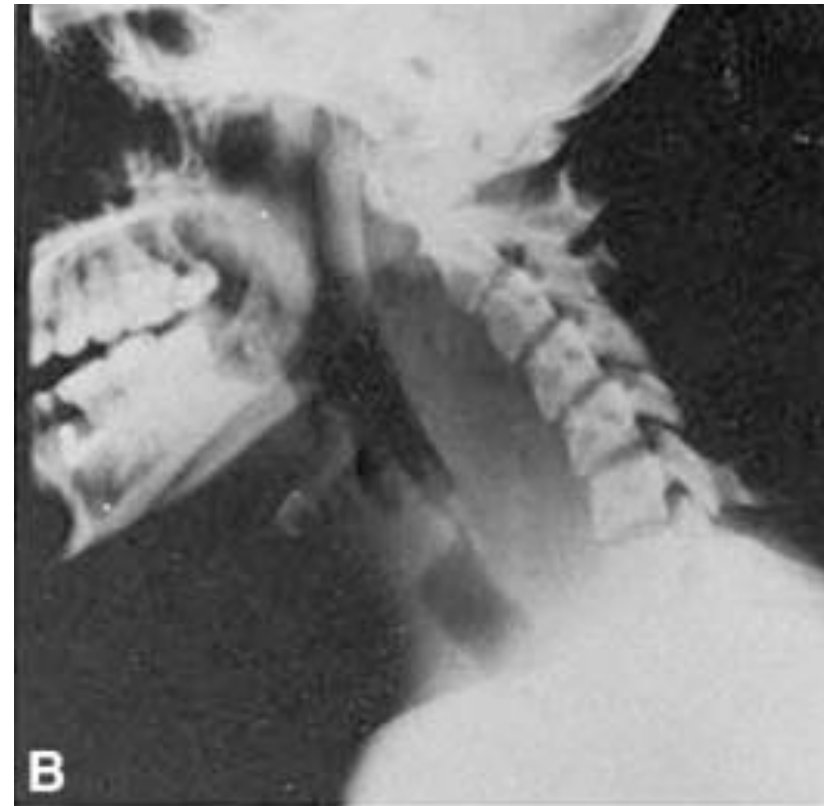
INVESTIGATION

- Laboratory and bacteriology
- Plain X-rays

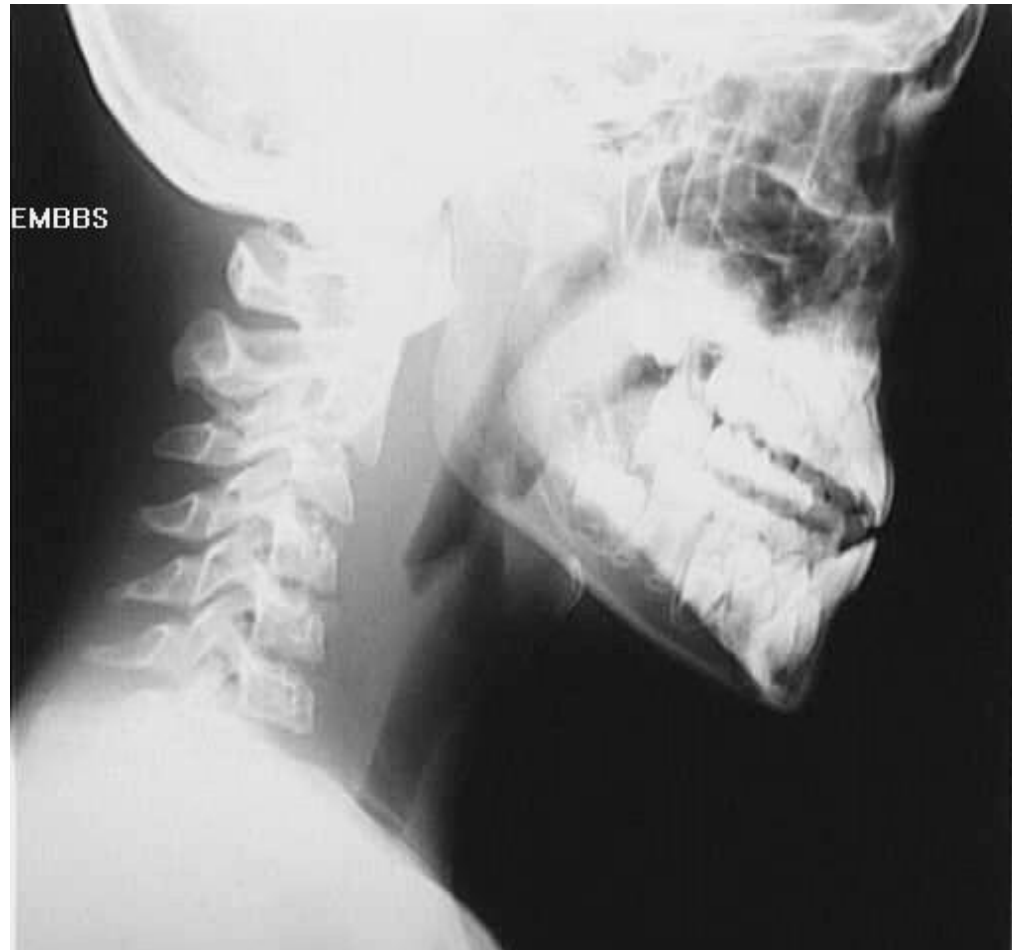PLAIN X-RAYS



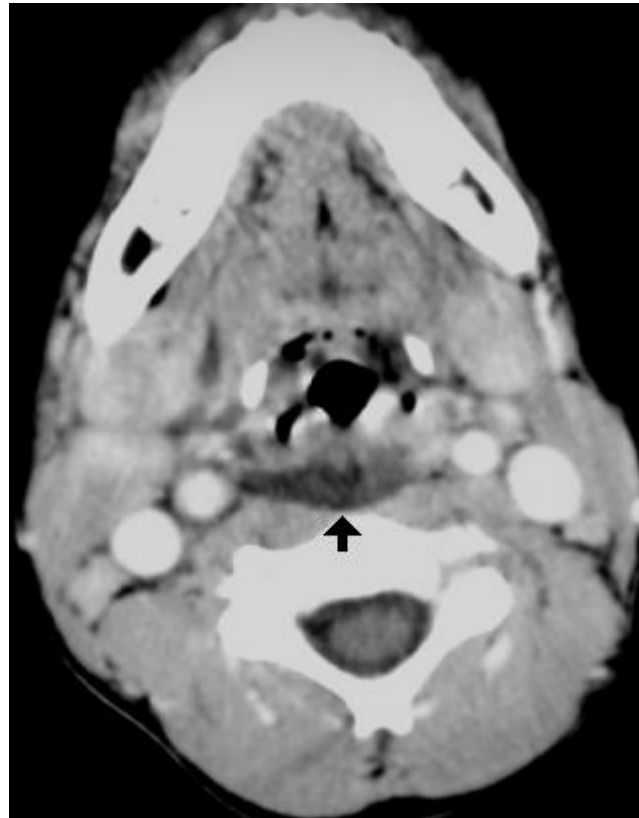
Normal



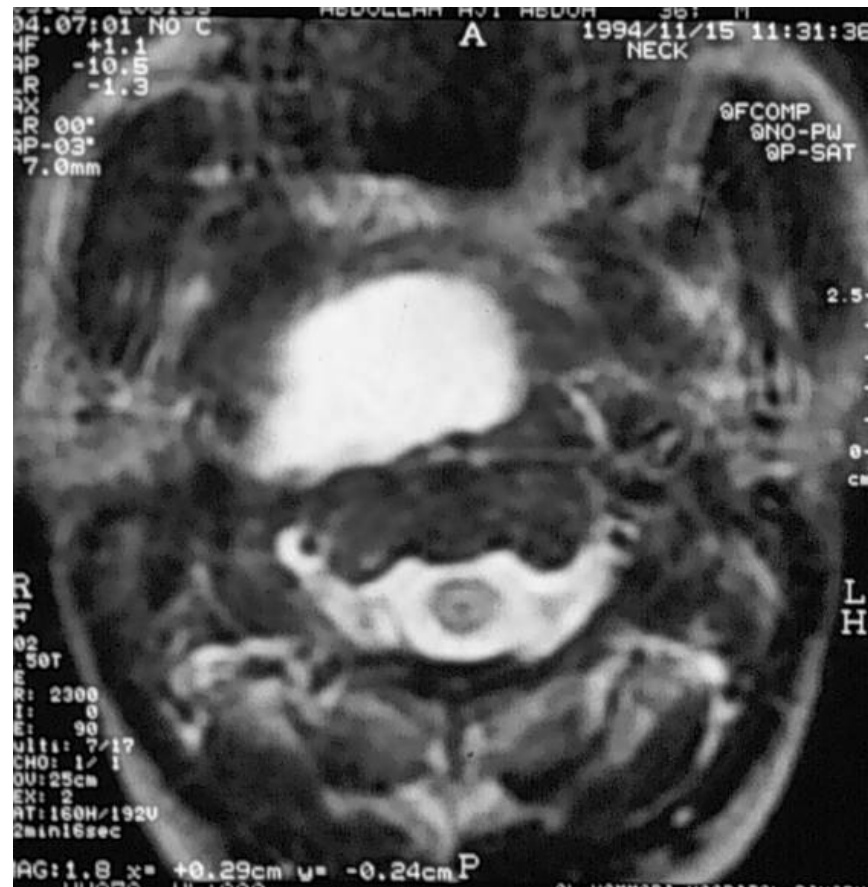Retropharyngeal abscess



CT

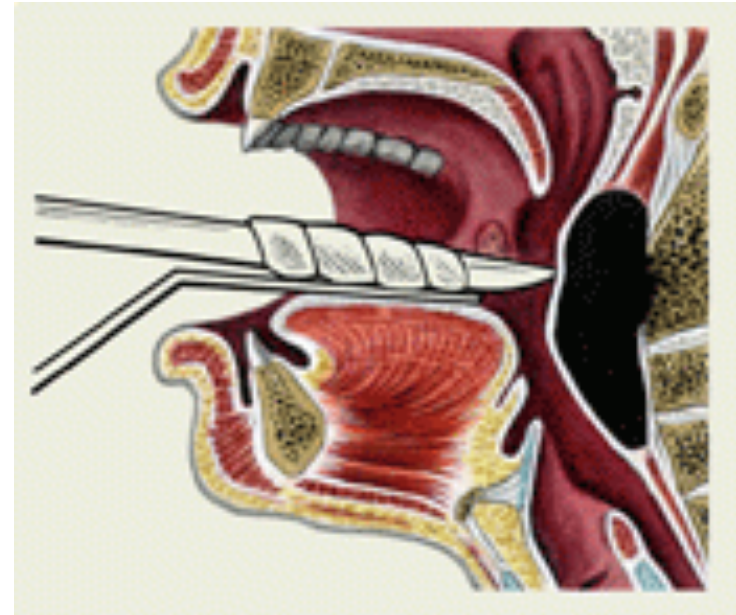


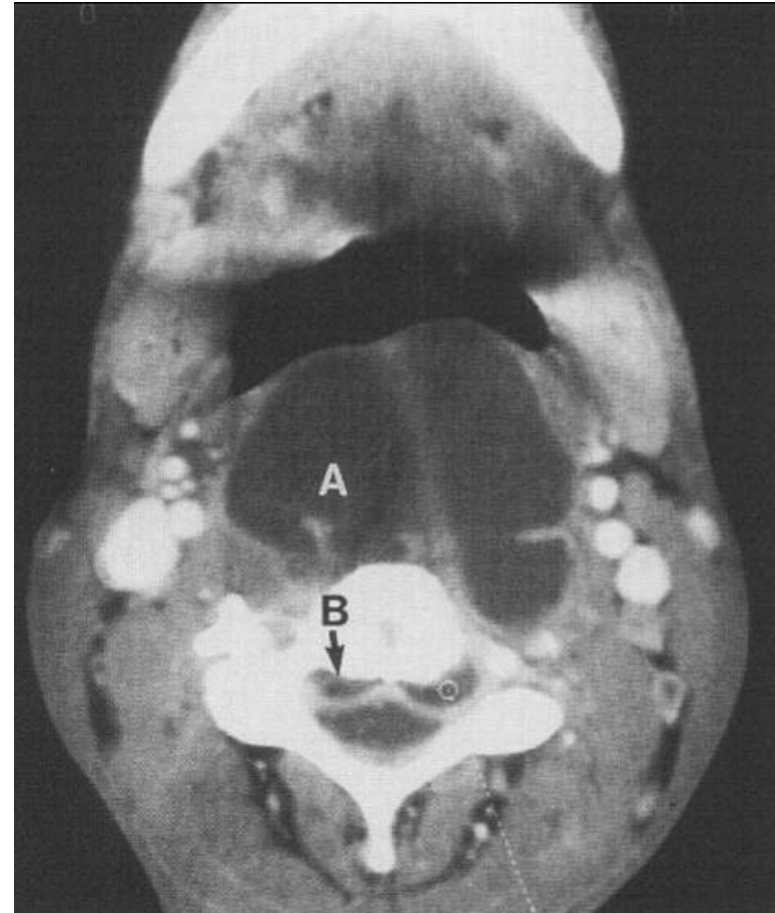
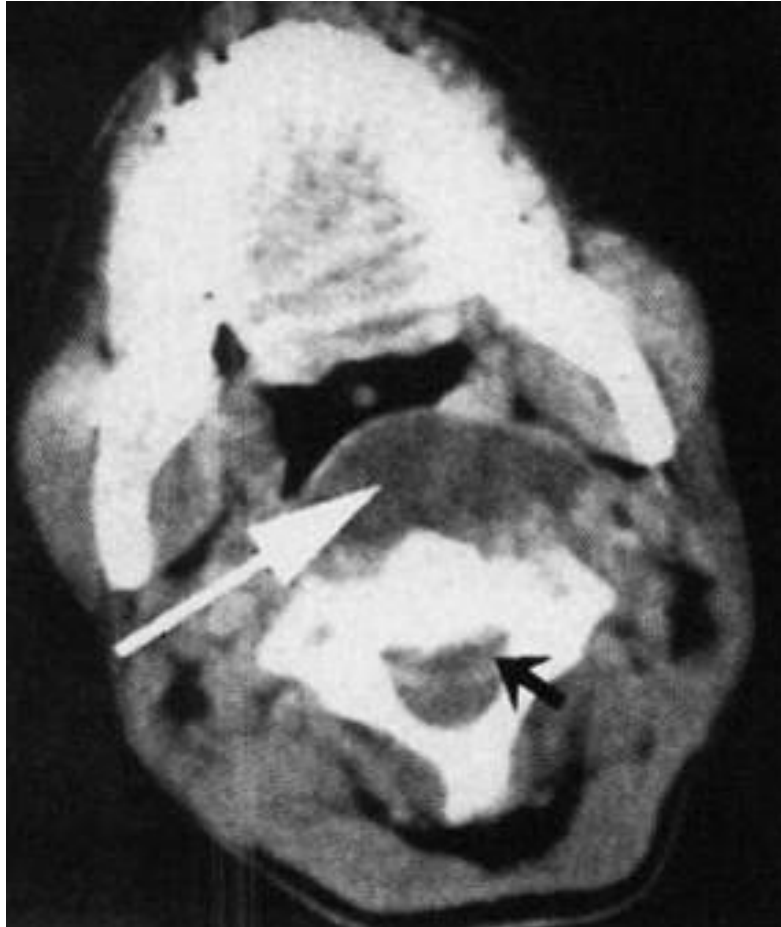MRI



TREATMENT OF ACUTE RETROPHARYNGEAL ABSCESS

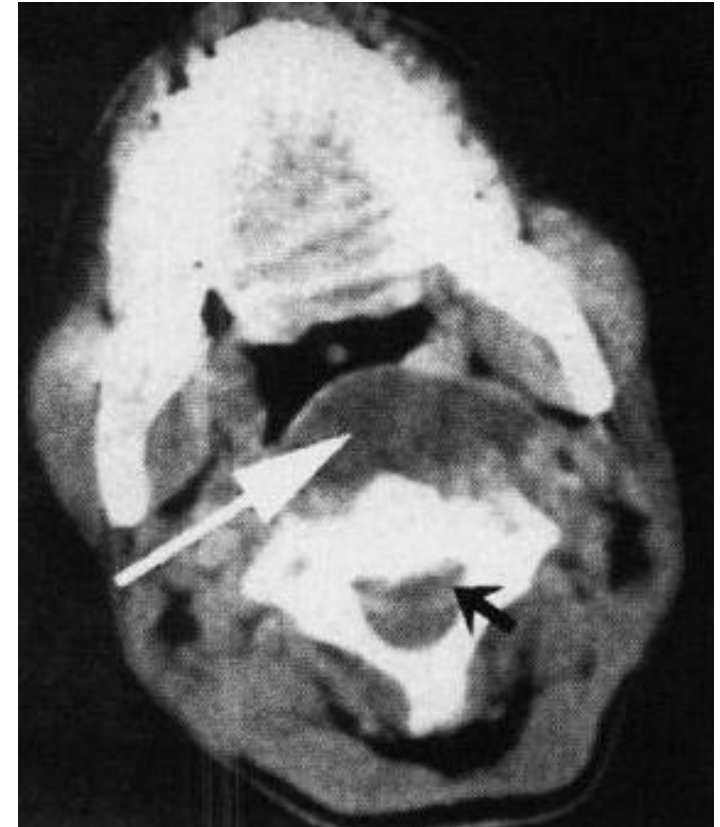
- Secure airway
- Antimicrobial
- Surgical drainage
 - Trans oral





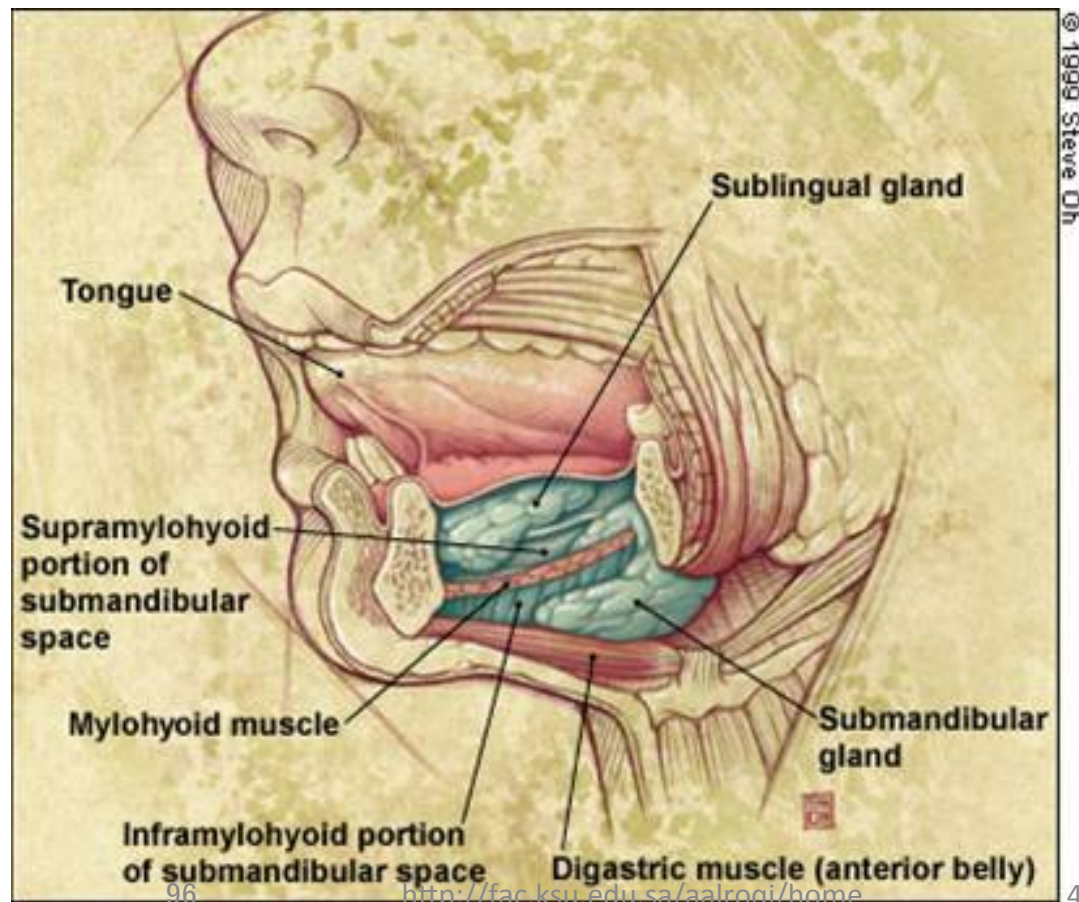
CHRONIC RETROPHARYNGEAL ABSCESS

- Tuberculous (cold abscess)
- Usually due to TB spines but may be secondary to TB lymphadenitis
- Symptoms are insidious
- Treatment is by anti tuberculous medication, repeated aspiration and external drainage



Ludwig's Angina

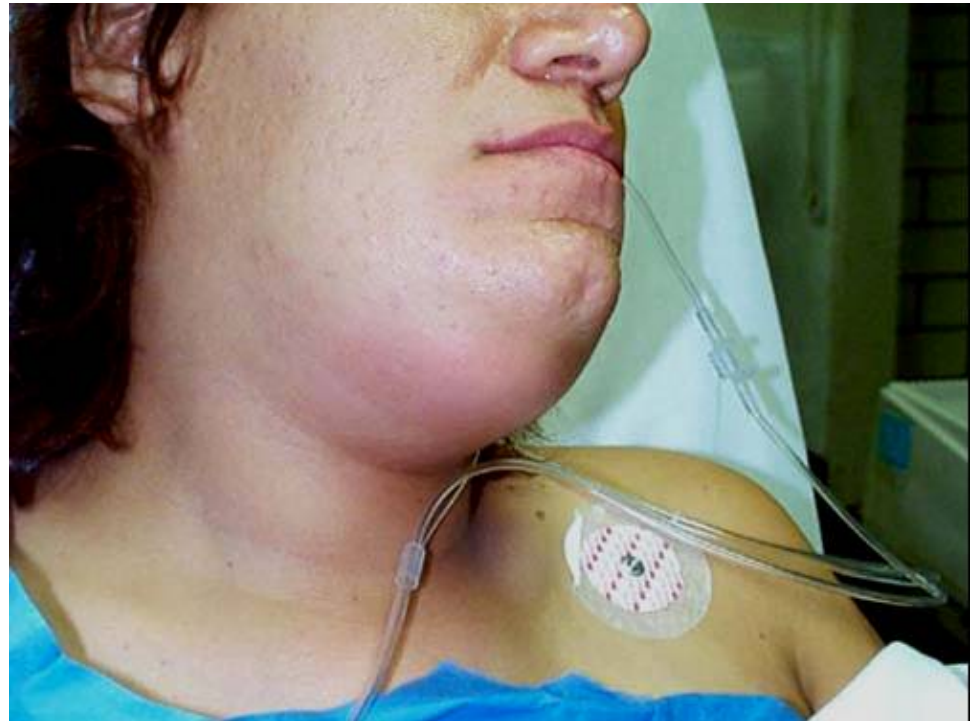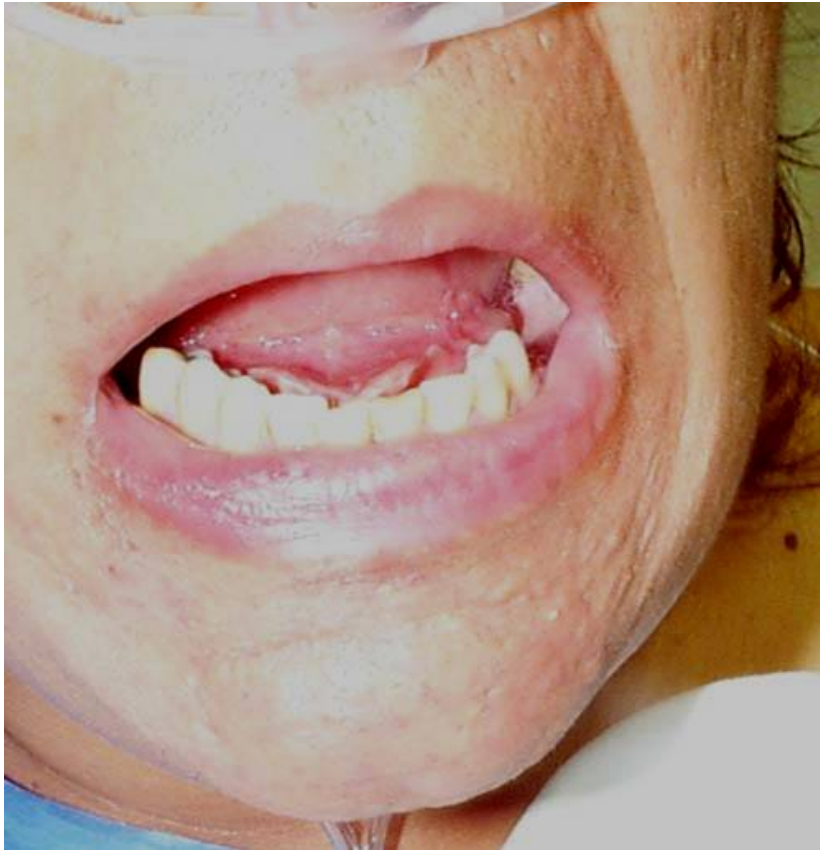- Infection of the submandibular space



Causes of Ludwig's Angina

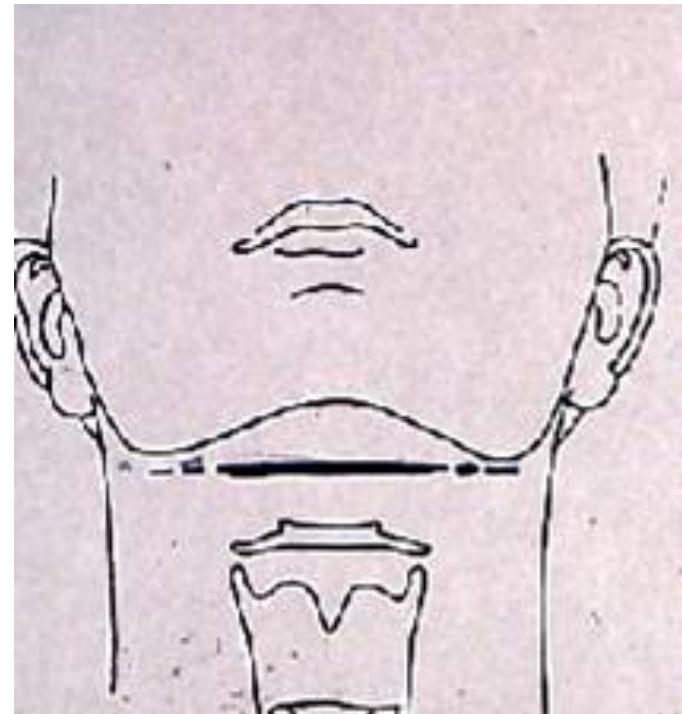
- Usually secondary to dental infection or trauma

Presentation of Ludwig's Angina



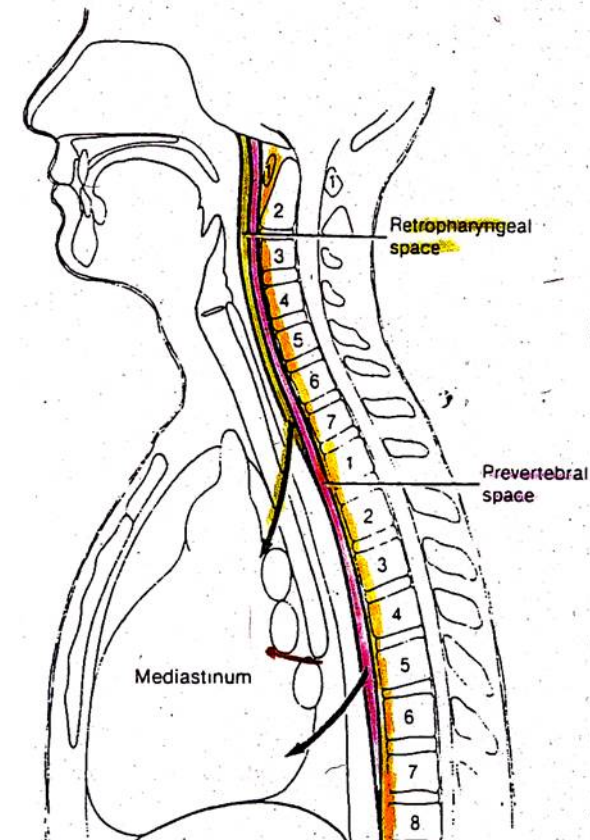
TREATMENT

- Secure airway
- Most cases respond to antibiotics
- Drainage may be needed



Complications of neck spaces infections

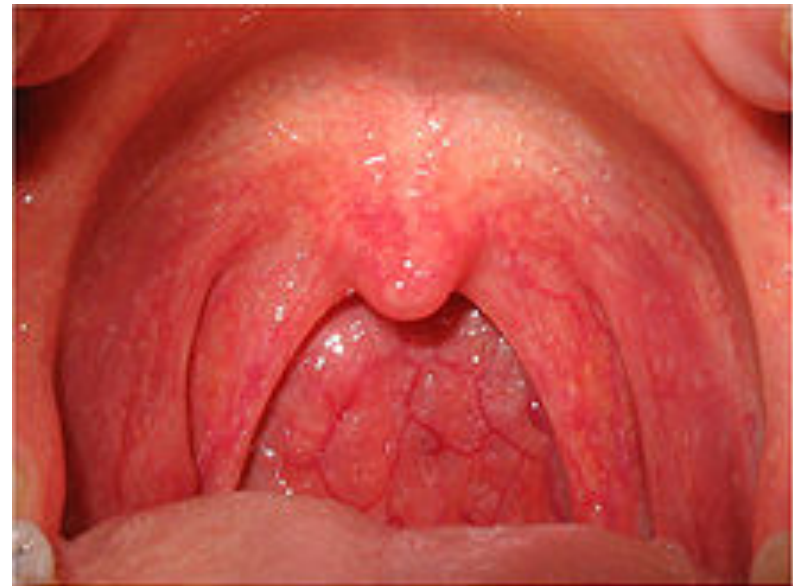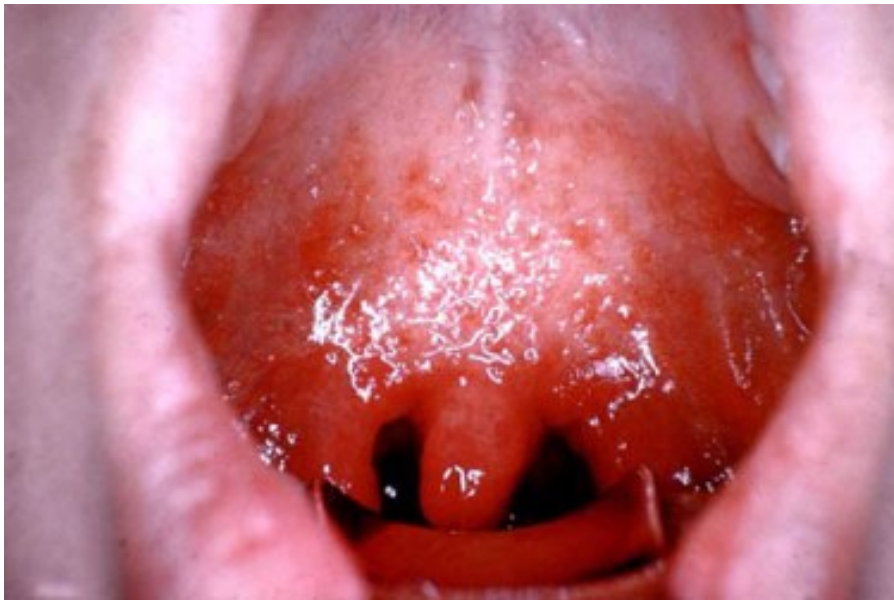- Respiratory obstruction
- Spontaneous rupture (inhalation pneumonia)
- Extension of infection
 - Other spaces
 - Carotid & internal jugular
 - Mediastinitis



ACUTE INFECTIONS OF THE OROPHARYNX

- Acute tonsillitis
- Acute non-specific pharyngitis
- Acute diphtheria
- Infectious mononucleosis
- Vincent's Angina
- Scarlet fever
- Moniliasis

ACUTE NONSPECIFIC PHARYNGITIS



ACUTE INFECTIONS OF THE OROPHARYNX

- Acute tonsillitis
- Acute non-specific pharyngitis
- Acute diphtheria
- Infectious mononucleosis
- Vincent's Angina
- Scarlet fever
- Moniliasis

ACUTE DIPHTHERITIC PHARYNGITIS

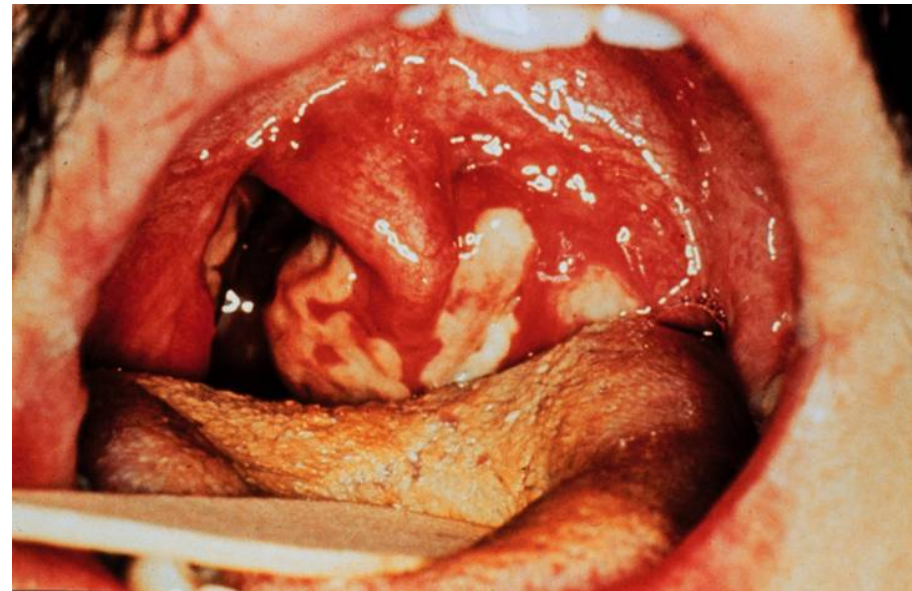
- A severe infection caused by *Corynebacterium diphtheriae*
- Affect children at age 2-5 years
- Spread by droplets or contaminated articles
- The incidence has fallen markedly because of immunization

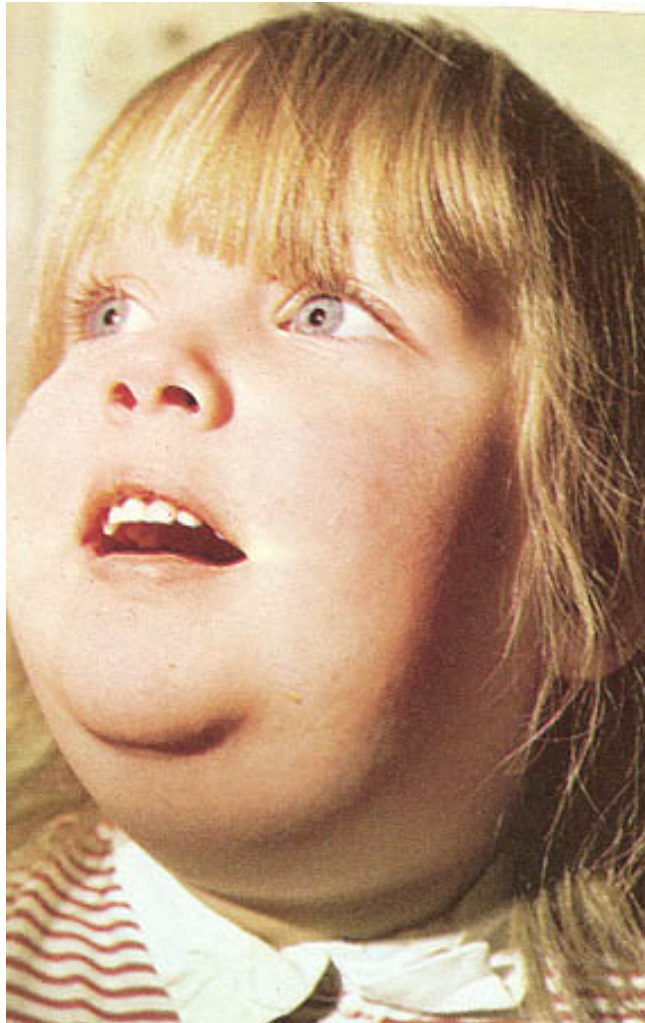PATHOLOGY

- Local grayish membrane (composed of fibrin, leukocytes, and cellular debris)
- Exotoxins travels to heart and nervous system

CLINICAL MANIFESTATIONS

- Systemic symptoms due to the exotoxins
 - Toxemia
 - Mild fever
 - Tachycardia
 - Paralysis
- Local manifestations
 - Sore throat
 - Membrane
 - Marked lymphadenitis (‘bull neck’)





DIAGNOSIS

- Isolation of the organism

TREATMENT

- Starts before culture confirmation
 - Airway maintenance
 - Antitoxin
 - Antibiotics (erythromycin, penicillin G, rifampin, or clindamycin)

PREVENTION

- Vaccine

COMPLICATIONS

- Respiratory obstruction
- Heart failure
- Muscular paralysis

ACUTE INFECTIONS OF THE OROPHARYNX

- Acute tonsillitis
- Acute non-specific pharyngitis
- Acute diphtheria
- **Infectious mononucleosis**
- Vincent's Angina
- Scarlet fever
- Moniliasis

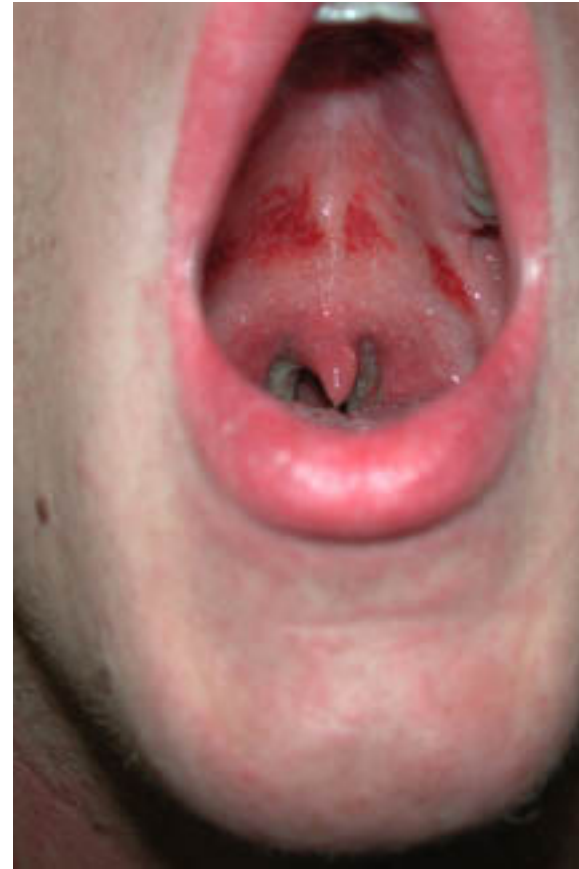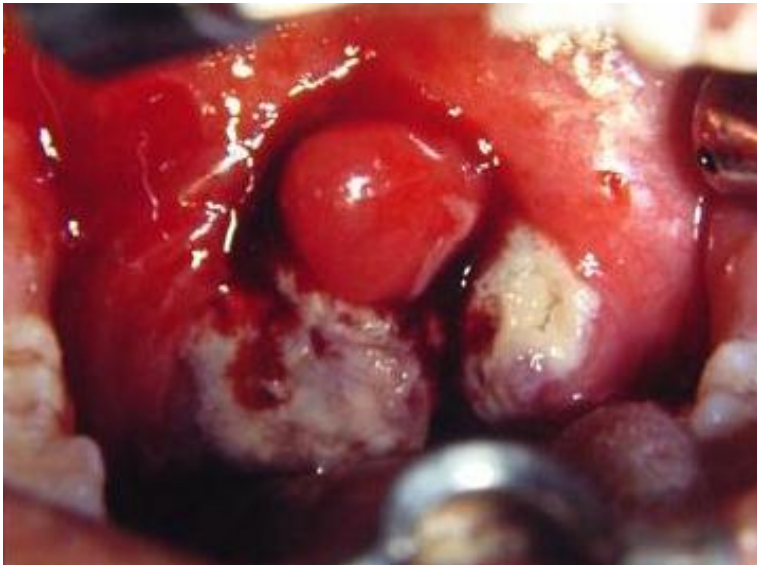
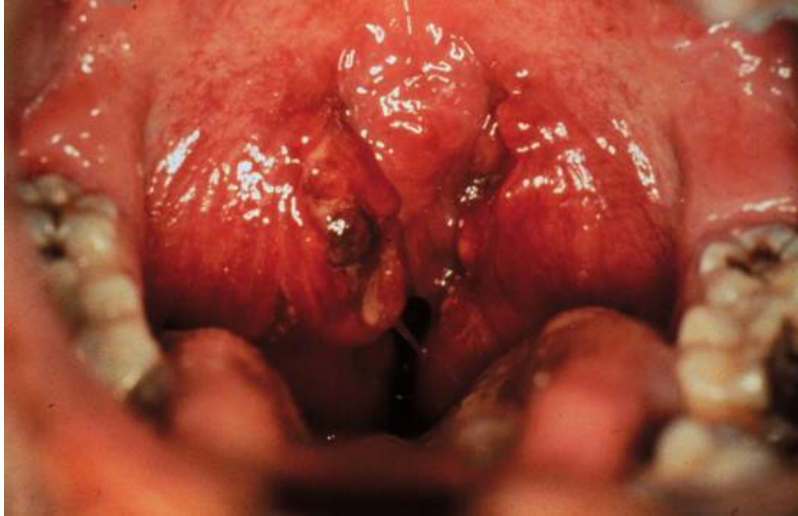INFECTIOUS MONONUCLEOSIS

- Systemic infection caused by Epstein-Barr Virus (EBV)
- Selectively infects B-lymphocytes
- Clinical disease is usually seen in young adults

CLINICAL MANIFESTATIONS

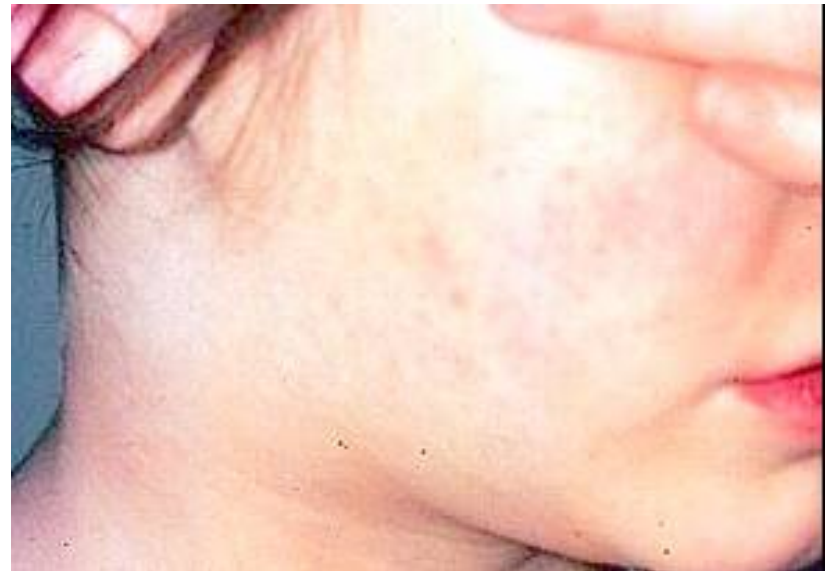- Clinical triad
 - Fever
 - Lymphadenopathy
 - Pharyngitis and/or tonsillitis

INFECTIOUS MONONUCLEOSIS



CLINICAL MANIFESTATIONS

- Clinical triad
 - Fever
 - Lymphadenopathy
 - Pharyngitis and/or tonsillitis
- Other clinical findings
 - Splenomegaly – 50%
 - Hepatomegaly – 10%
 - Rash – 5%

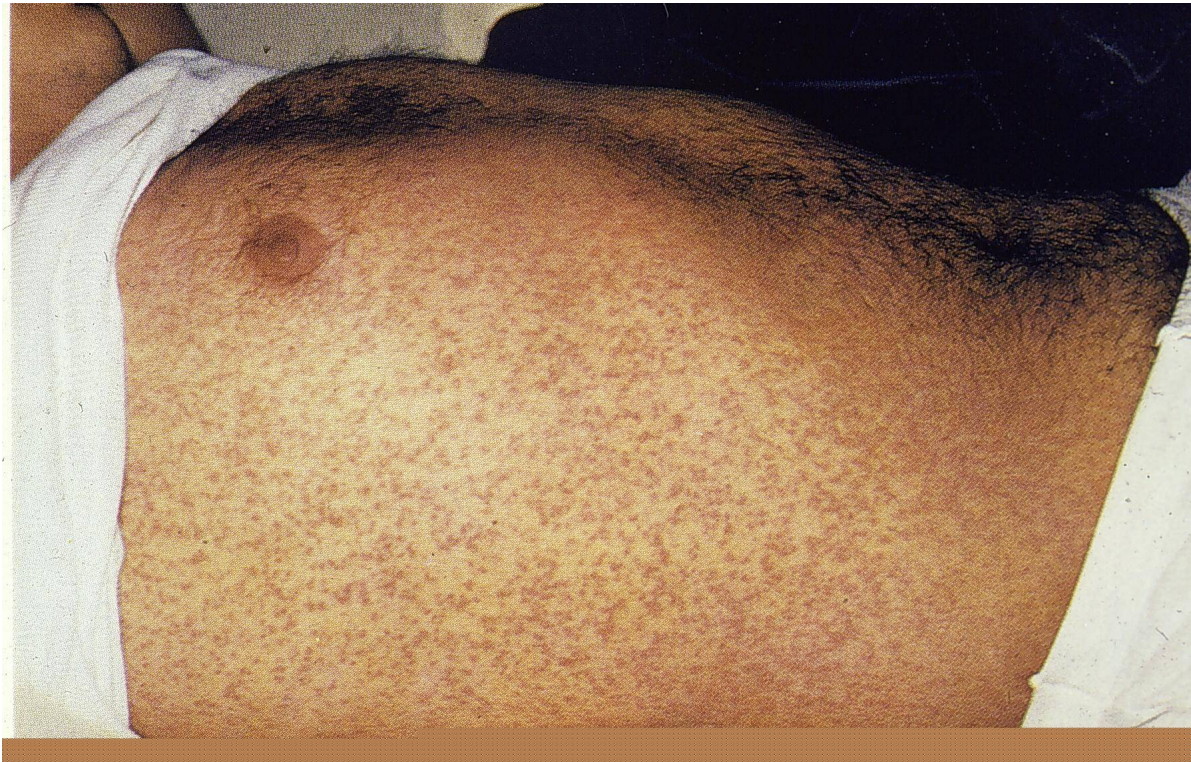

DIAGNOSIS

- CBC with differential (atypical lymphocytes)
- Detection of heterophil antibodies (Paul-Bunnell or Monospot test)

TREATMENT

- Symptomatic & supportive treatment
- Steroids (severe cases)
- Avoid ampicillin



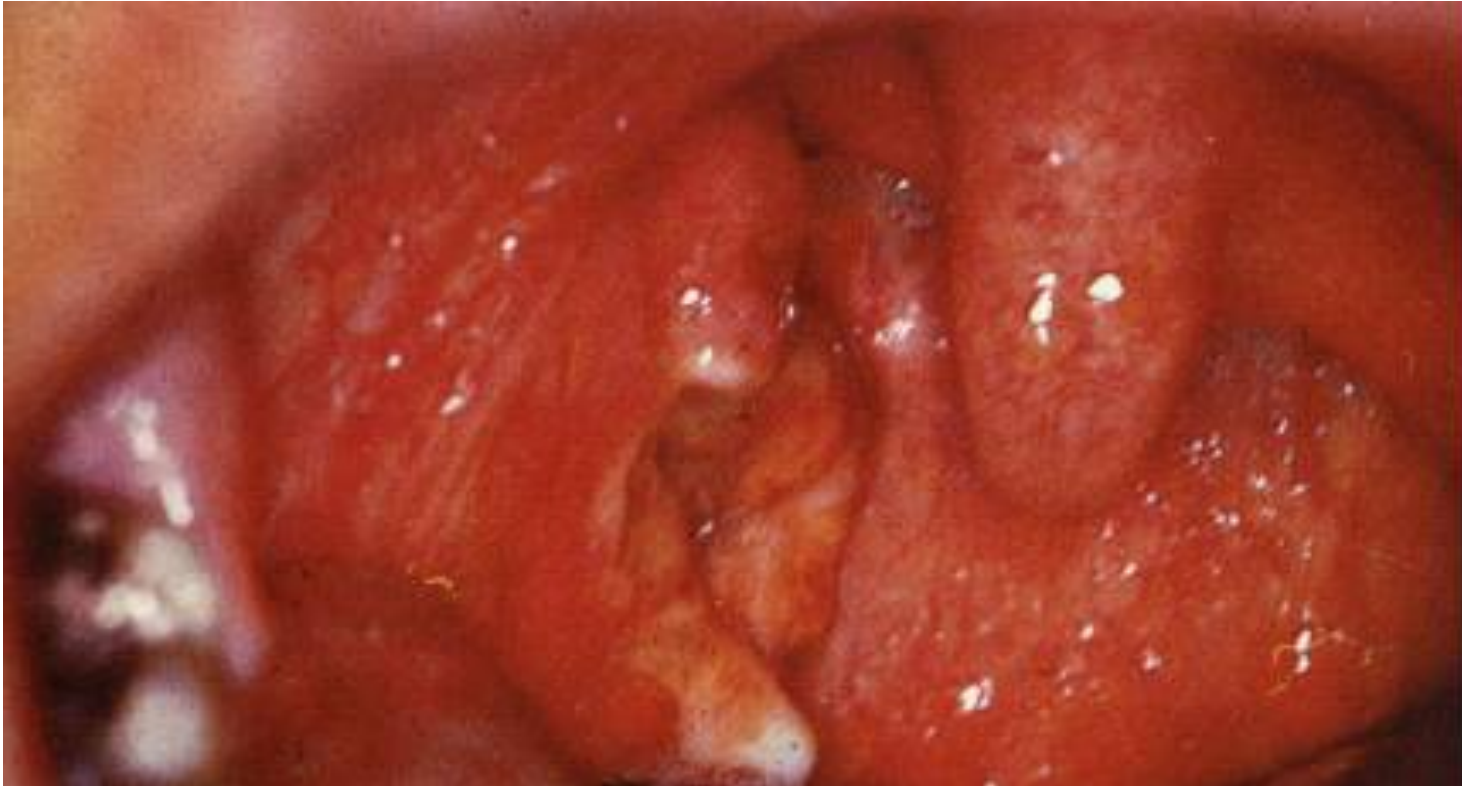
COMPLICATIONS

- Autoimmune hemolytic anemia
- Cranial nerve palsies
- Encephalitis
- Hepatitis
- Pericarditis
- Airway obstruction

VINCENT'S ANGINA

- ❑ Subacute infection due to *Spirochaeta denticolata* and Vincent's fusiform bacillus
- ❑ Most commonly in overcrowded conditions
“trench fever”
- ❑ Mild local and systemic symptoms

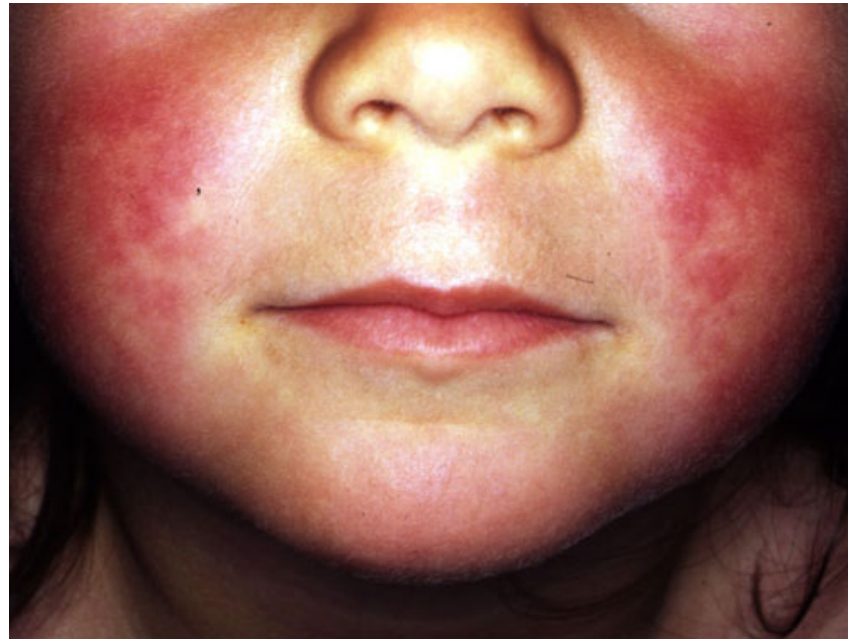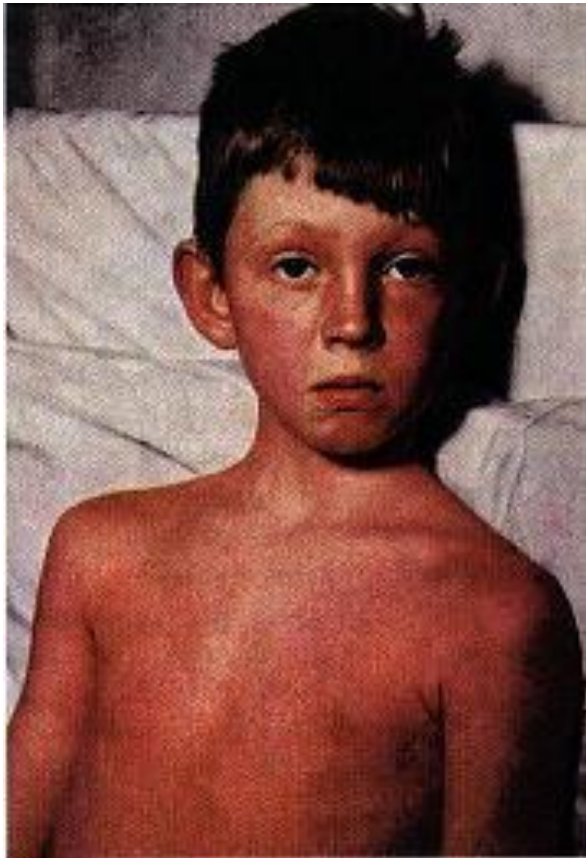VINCENT'S ANGINA



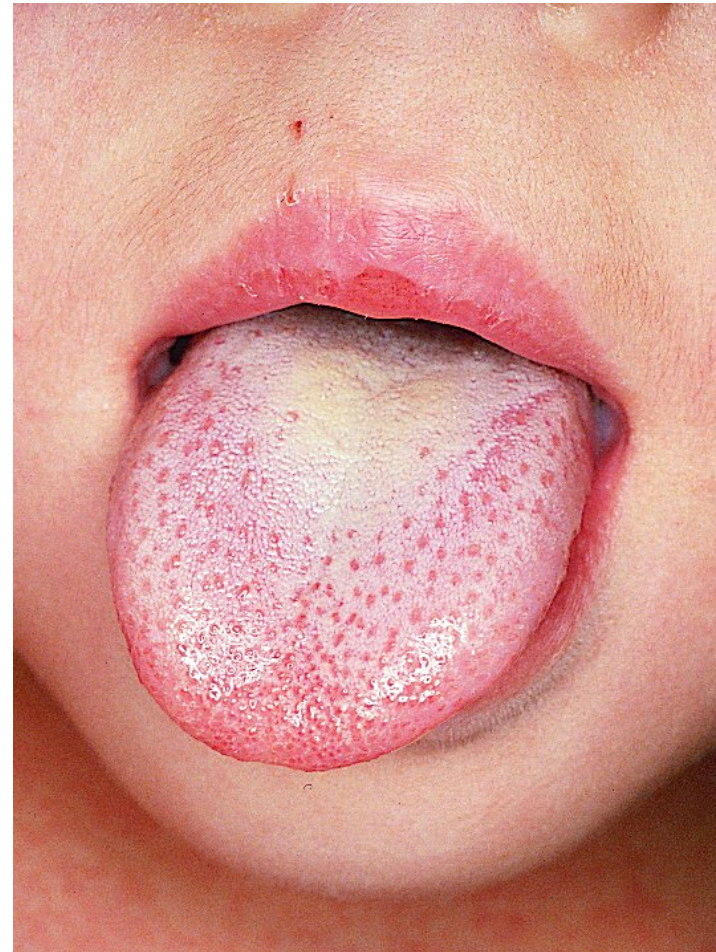
VINCENT'S ANGINA

- Subacute infection due to *Spirochaeta denticolata* and Vincent's fusiform bacillus
- Most commonly in overcrowded conditions
“trench fever”
- Mild local and systemic symptoms
- Management is with penicillin and local oral hygiene

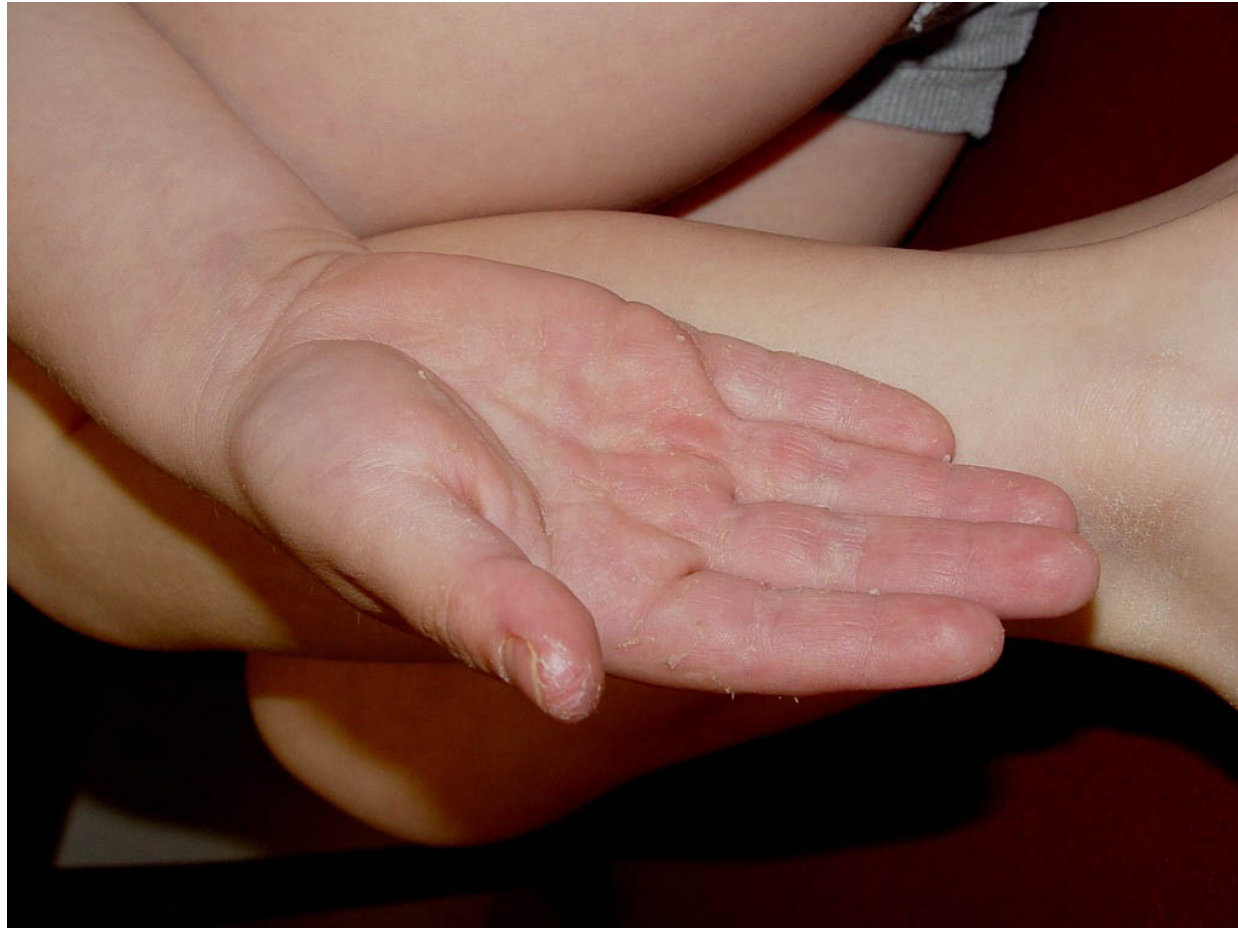SCARLET FEVER



SCARLET FEVER



SCARLET FEVER

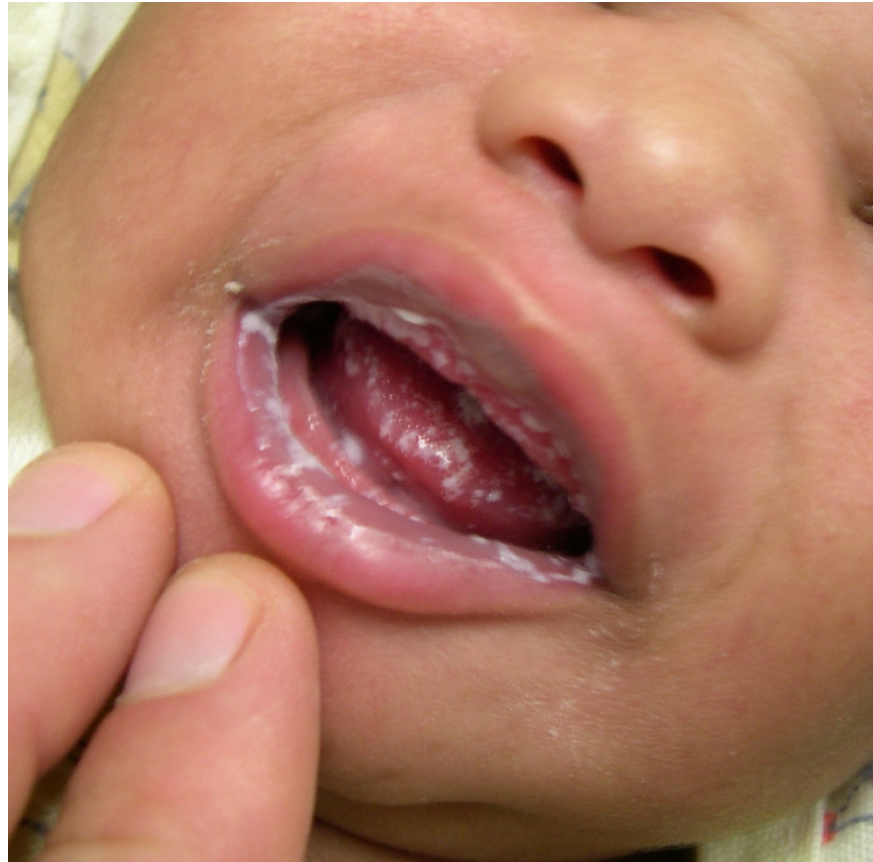

FUNGAL PHARYNGITIS

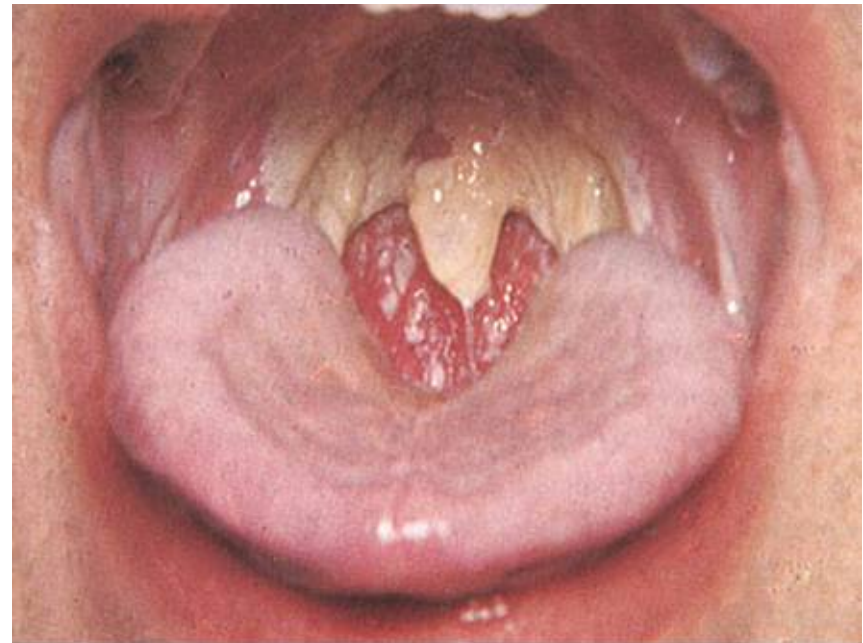
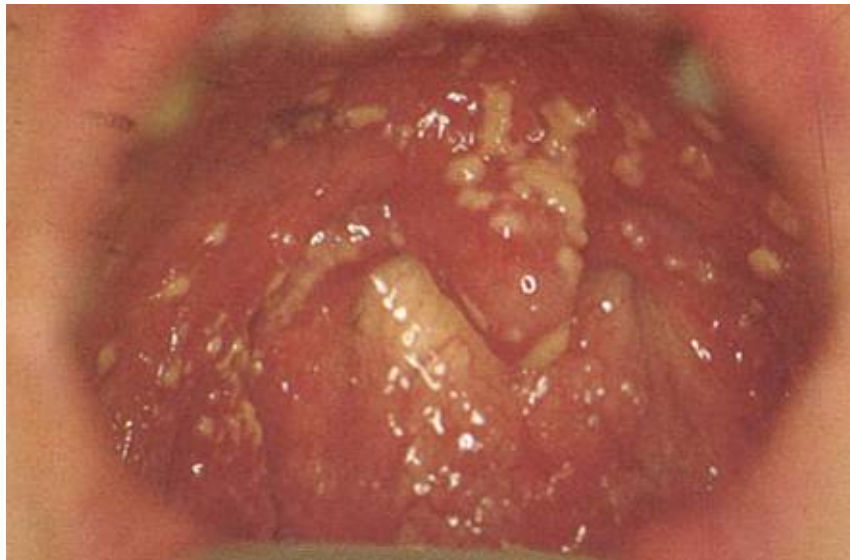
CAUSES

- Long term antibiotics
- Immunosuppression (Leukopenia,
Corticosteroid therapy etc)

CANDIDIASIS (MONILIASIS, THRUSH)



CANDIDIASIS (MONILIASIS, THRUSH)



Treatment

- Nystatin
- Fluconazole

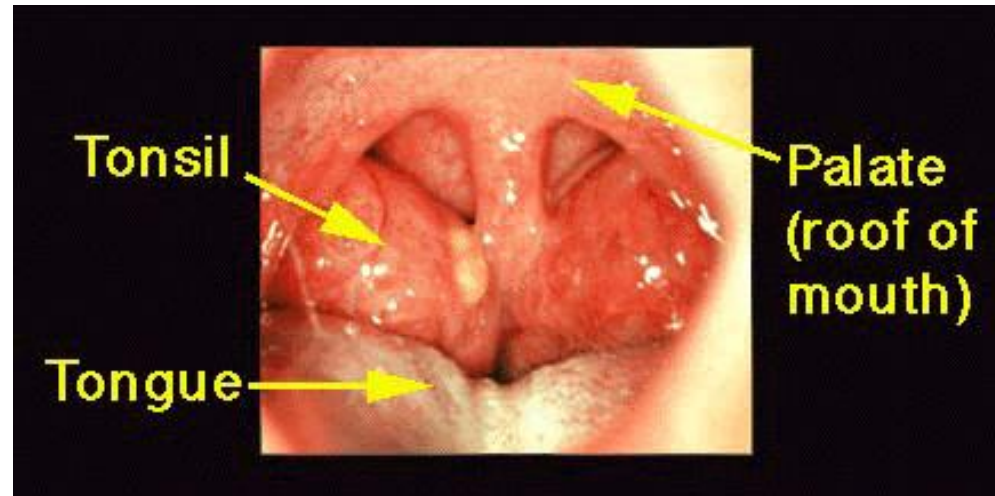
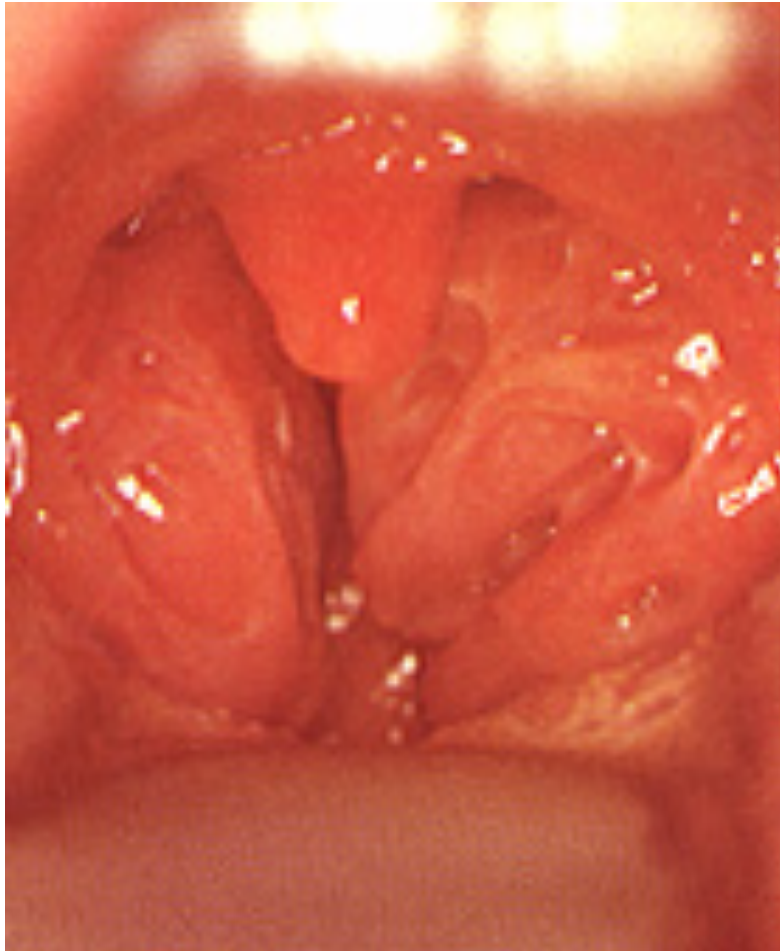
CHRONIC TONSILLAR HYPERTOPHY

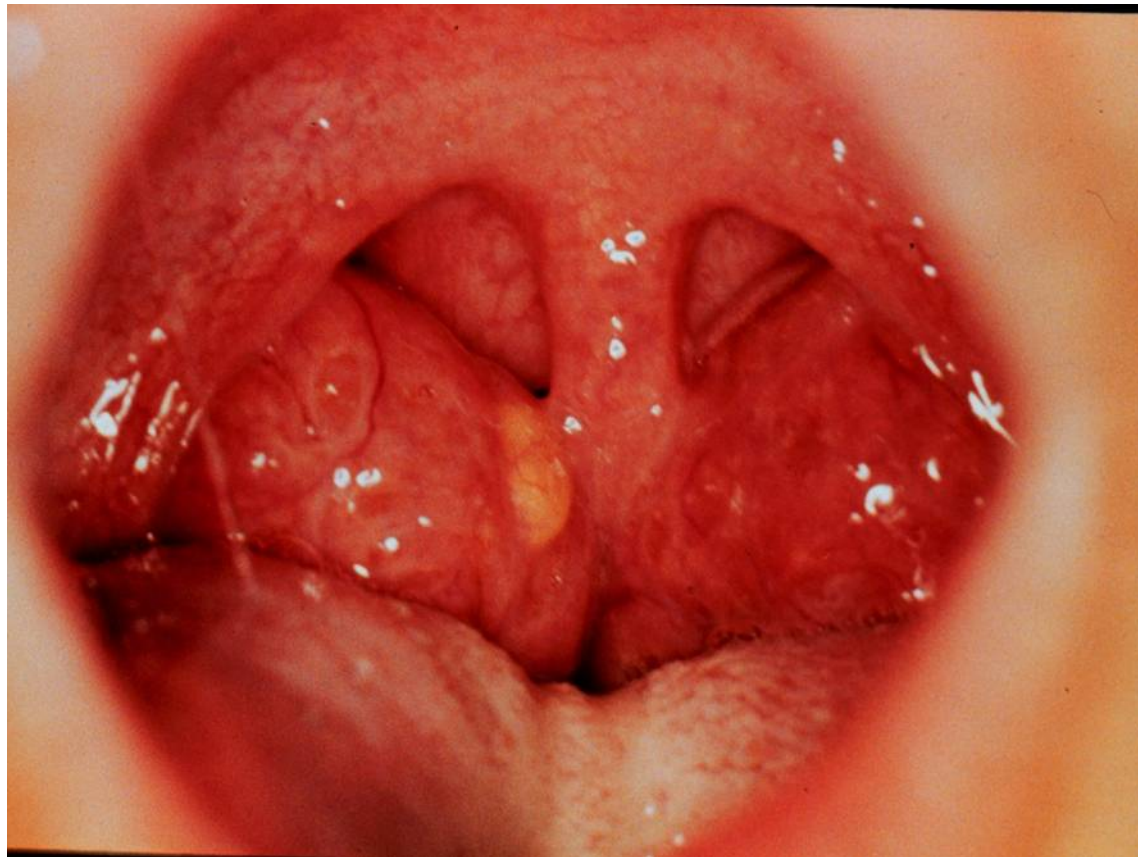
CAUSES

- Chronic or frequent acute infections
- Idiopathic (?exaggerated immune response)

PRESENTATION

- Upper airway obstruction
 - Mouth breathing, snoring
 - Disturbed sleep and apnea
- Pulmonary hypertension, cor pulmonale and heart failure





TREATMENT

- Tonsillectomy & adenoidectomy

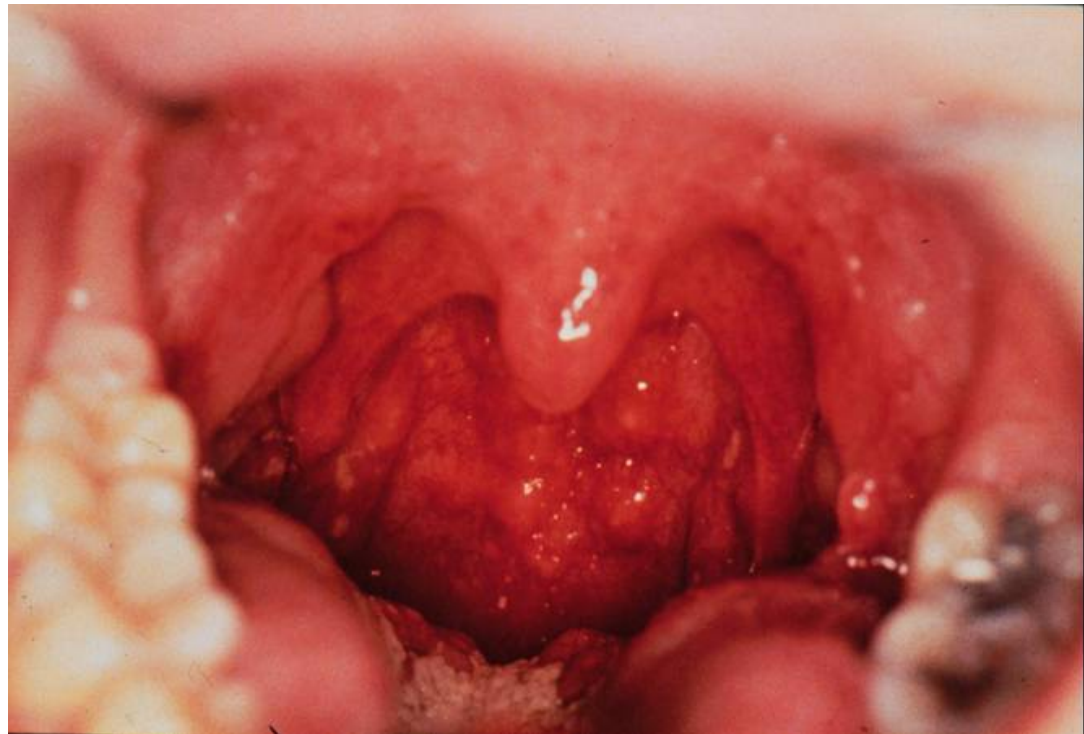CHRONIC INFECTIONS OF THE PHARYNX

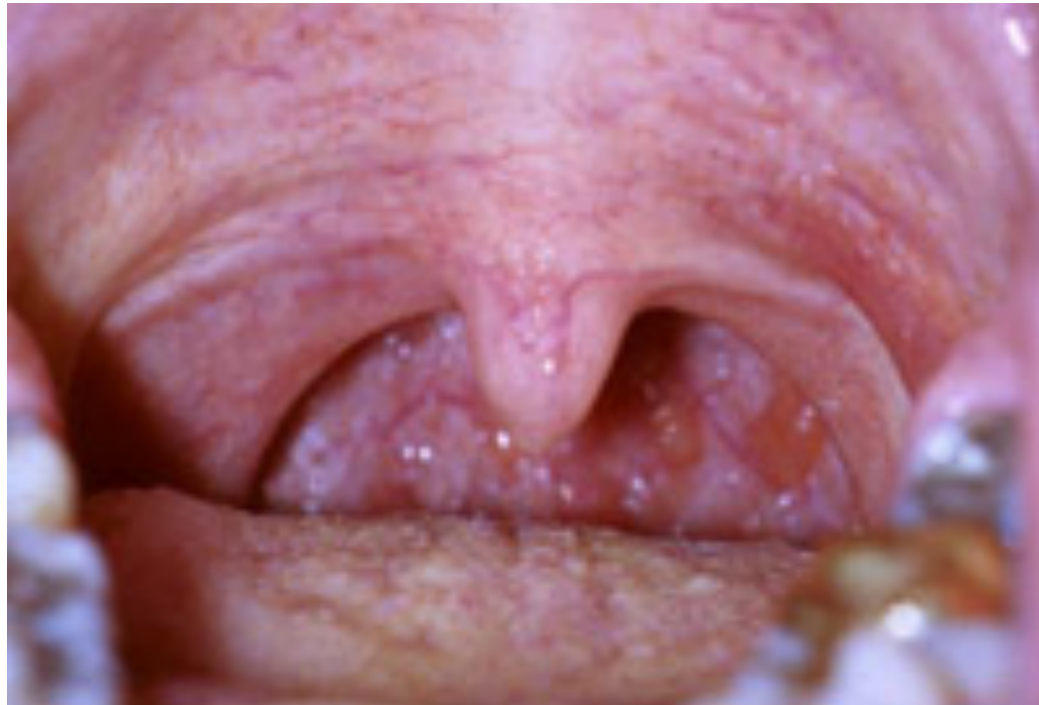CHRONIC NON-SPECIFIC PHARYNGITIS

- Primary
- Secondary
 - Sinonasal disease
 - Dental infections
 - Chest infections
 - Smoking
 - Gastro esophageal reflux

CLINICAL FEATURES

- Sore throat
- Irritation
- Cough
- O/E





TREATMENT

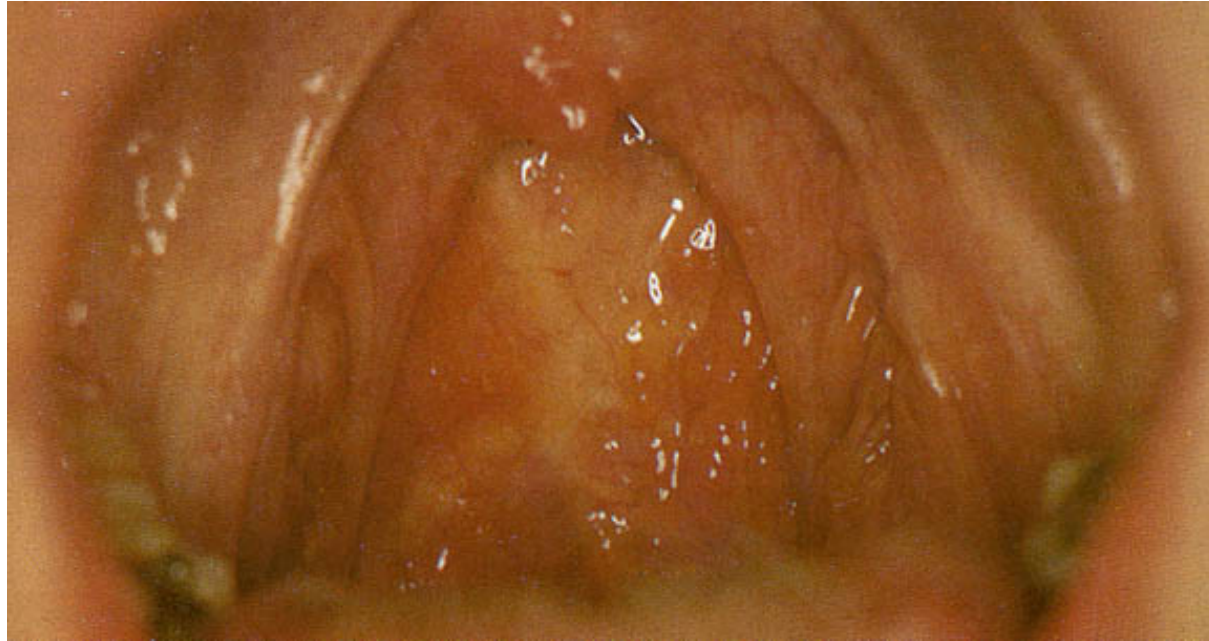- Treatment of the cause
- Humidification

CHRONIC SPECIFIC PHARYNGITIS

- Tuberculosis
- Syphilis
- Lupus vulgaris
- Leprosy
- Sarcoidosis

CHRONIC TONSILLITIS

- Persistent or recurrent sore throat
- Persistent cervical adenitis
- Halitosis
- Congested tonsils



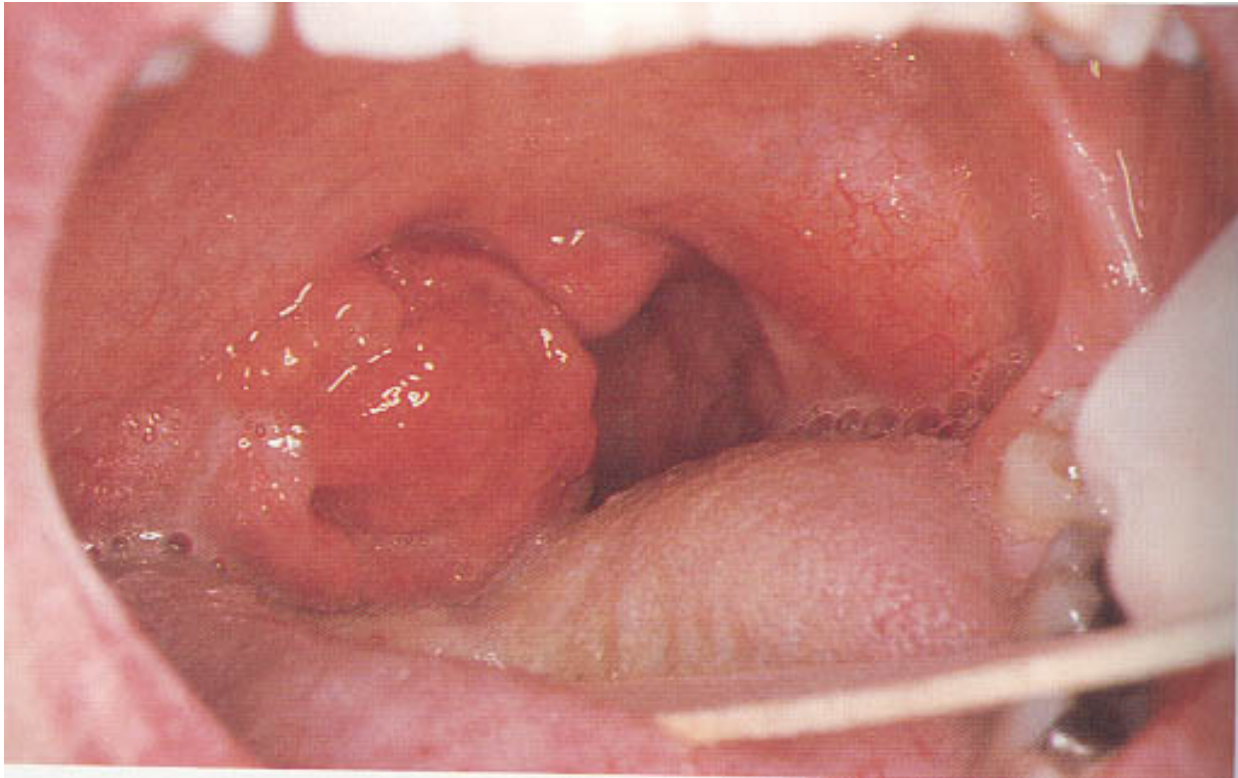
TREATMENT

Tonsillectomy

TONSILLECTOMY

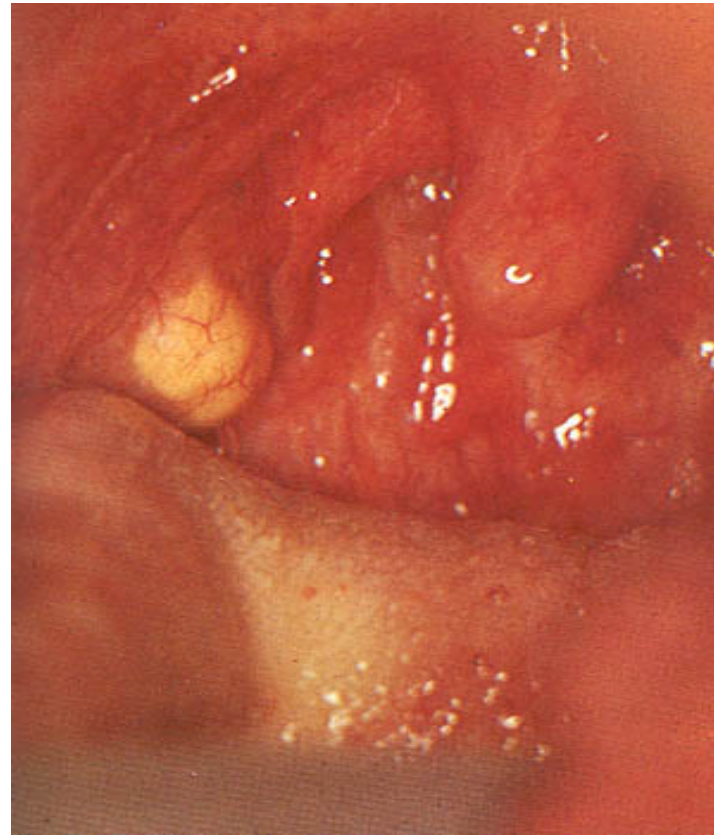
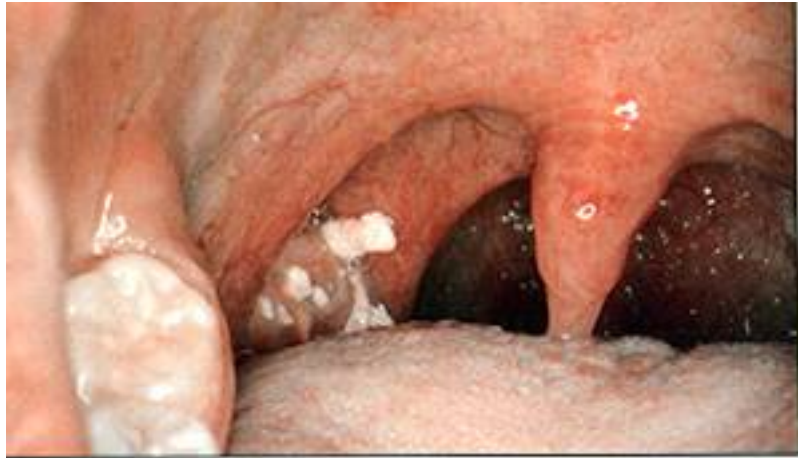INDICATIONS

- Obstructing tonsillar enlargement
- Suspected malignancy



INDICATIONS

- Obstructed tonsillar enlargement
- Suspected malignancy
- Repeated attacks of tonsillitis
- Chronic tonsillitis
- One attack of quinsy
- Others



CONTRAINDICATIONS

- Bleeding tendency
- Recent URTI

COMPLICATIONS

- Hemorrhage
 - Primary
 - Reactionary
 - Secondary
- Respiratory obstruction
- Injury to near-by structures
- Pulmonary and distant infections

Primary Hemorrhage

- Bleeding occurring during the surgery
- Causes
 - Bleeding tendency
 - Acute infections
 - Aberrant vessel
 - Bad technique
- Management
 - General supportive measures
 - Diathermy, ligature or stitches
 - Packing

Reactionary Hemorrhage

- Bleeding occurring within the first 24 hours postoperative period
- Causes
 - Bleeding tendency
 - Slipped ligature
- Diagnosis
 - Rising pulse & dropping blood pressure
 - Rattle breathing
 - Blood trickling from the mouth
 - Frequent swallowing
 - Examination

Reactionary Hemorrhage

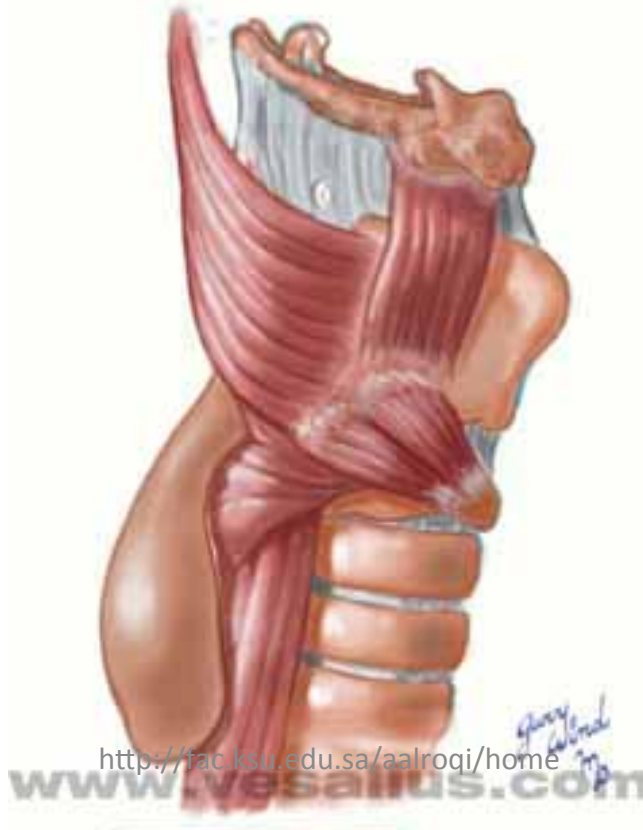- Treatment
 - General supportive measures
 - Take the patient back to OR
 - Control like reactionary hemorrhage

Secondary hemorrhage

- Occur 5-10 days posoperatively
- Due to infection
- Treated by antibiotics
- May need diathermy or packing

Pharyngeal (Zenker's) Pouch

A mucosal sac protruding through Killian's dehiesence



Pathogenesis

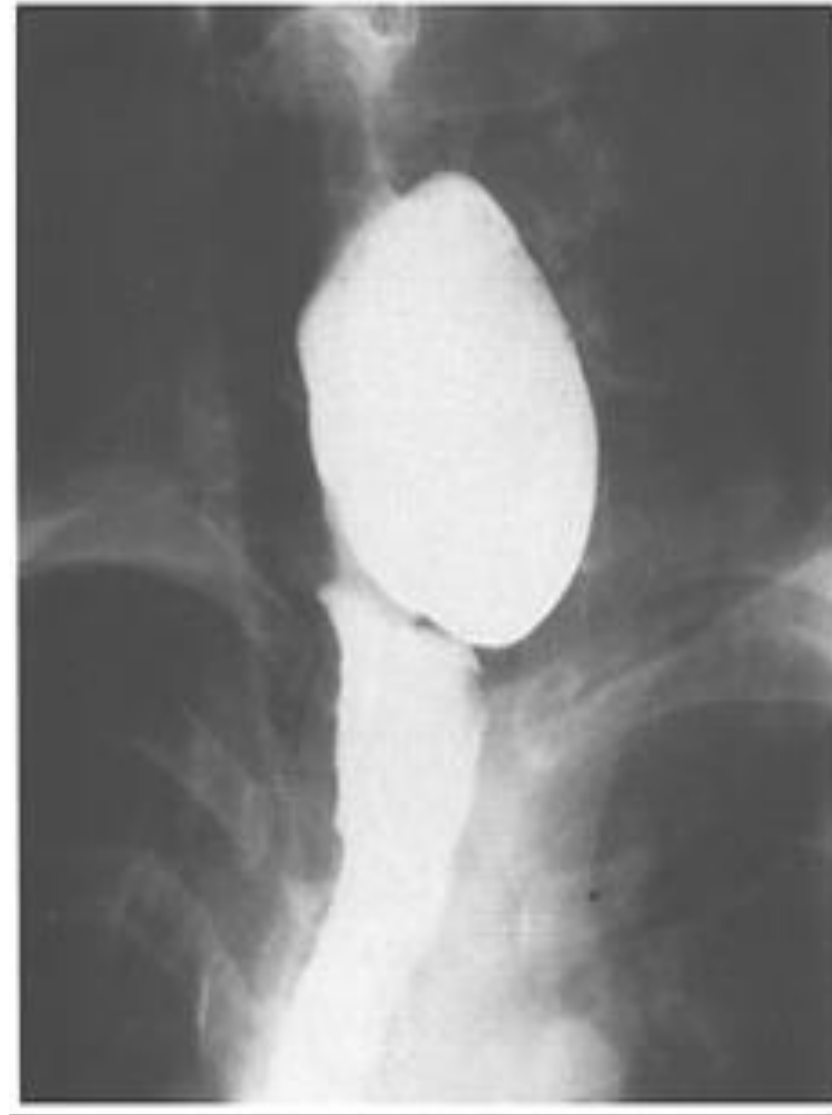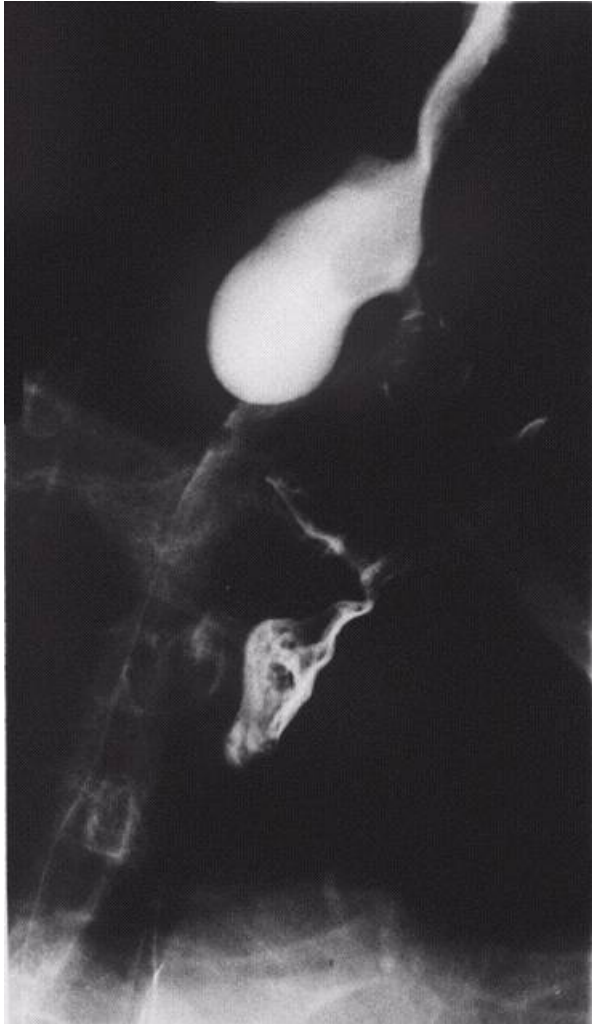- Most probably related to neuromuscular incoordination
 - ? Failure of relaxation of cricopharyngeus
 - ? Early closure of cricopharyngeus
 - ? Spasm of cricopharyngeus

Clinical Features

- Dysphagia
- Regurgitation
- Aspiration

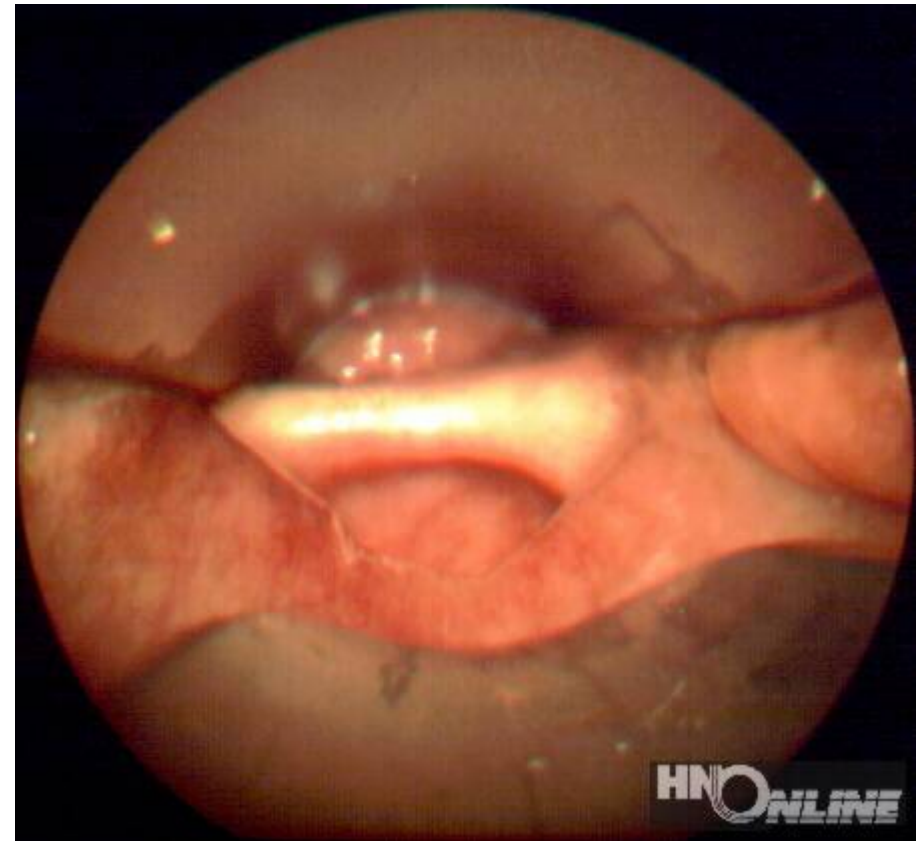
Diagnosis

- Clinical examination
- Barium swallow



Diagnosis

- Clinical examination
- Barium swallow
- Endoscopy



Treatment

- Excision

THANK YOU