



COMMON ADULT FRACTURES

Dr. Ahmad Saleh Bin Nasser, MBBS, FRCSC

Assistant Professor

Chairman Department of Orthopaedics

College of Medicine

King Saud University Medical City

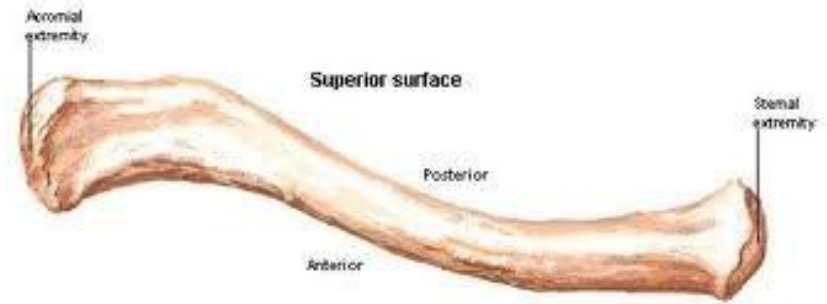
Objectives

- CLAVICLE FRACTURE
- HUMERUS (PROXIMAL& SHAFT)
- BOTH'BONE'FOREARM'FRACTURS'
- DISTAL'RADIUS'FRACTURE
- HIP FRACTURE
- FEMUR'SHAFT'FRACTURE'
- TIBIAL'SHAFT'FRACTURE'
- ANKLE'FRACTURE



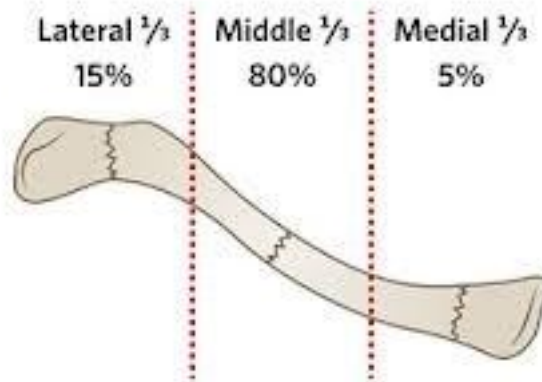
CLAVICLE FRACTURE

- Clavicle is S shape bone
- It is anchored to scapula via ACJ.
- It is anchored to trunk via SCJ
- Most of fracture occurs as result from fall onto shoulder.



Fracture is classified into: proximal, middle and lateral third fractures.

Most of fractures are of middle third.

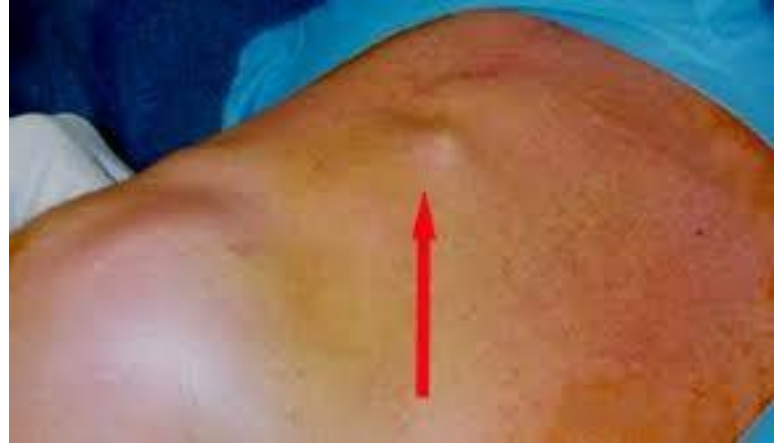

© The Royal Children's Hospital,
Melbourne, Australia

Clinical findings:

Injury to brachial plexus and subclavian artery/vein may be present

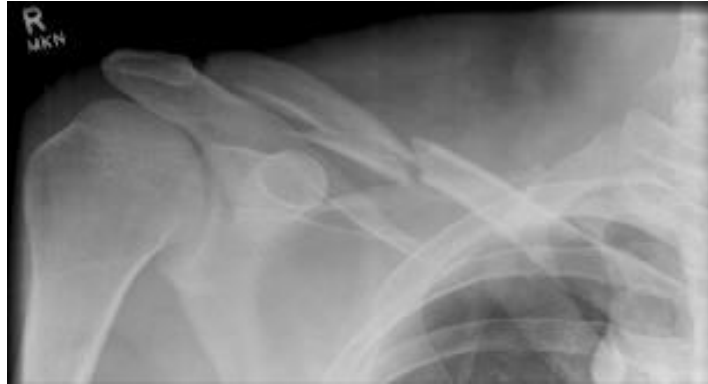
Rarely, Pneumothorax can occur.



X-rays:

AP chest

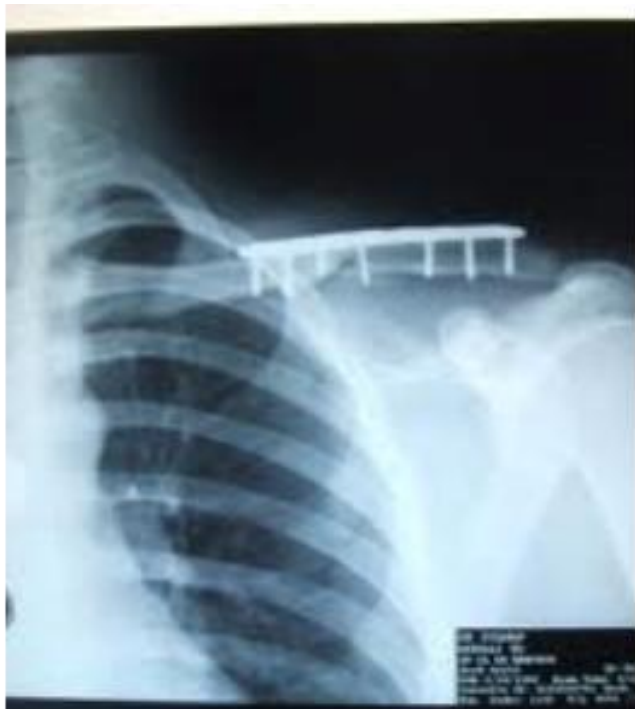Clavicle special view



Treatment

Most of clavicle fractures are treated with a sling.





Few fractures should be treated surgically with open reduction and internal fixation

Skin is tented

Severe displacement:

100% displacement

2 cm overlap

PROXIMAL HUMERUS ANATOMY

Proximal humerus has four anatomic parts:

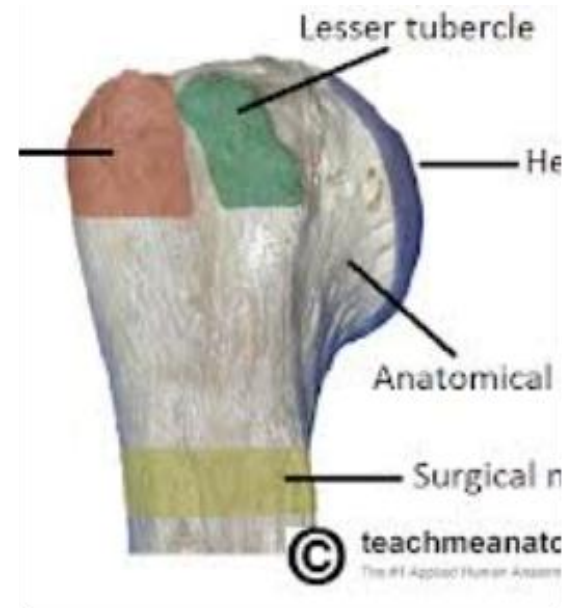
Head

Greater tuberosity

Lesser tuberosity

Shaft

Anatomic neck v.s. Surgical neck

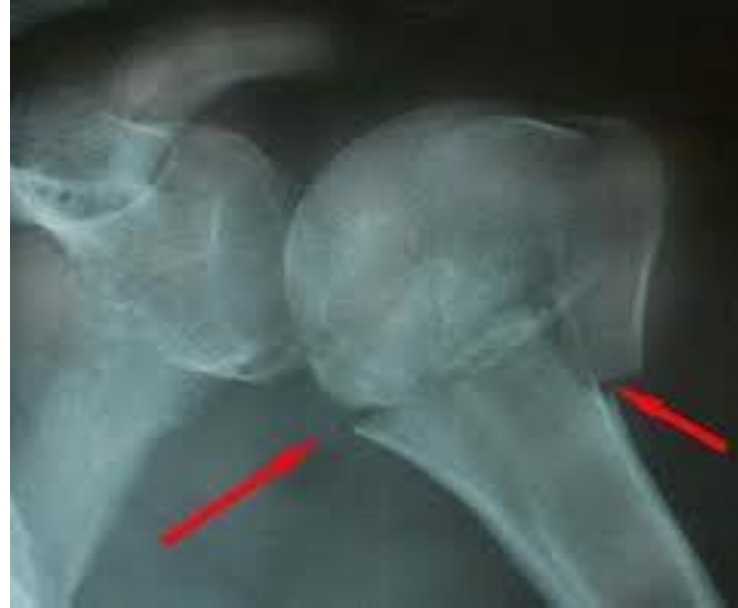


PROXIMAL HUMERUS FRACTURE

In younger patients: violent trauma


In older patients: minor trauma

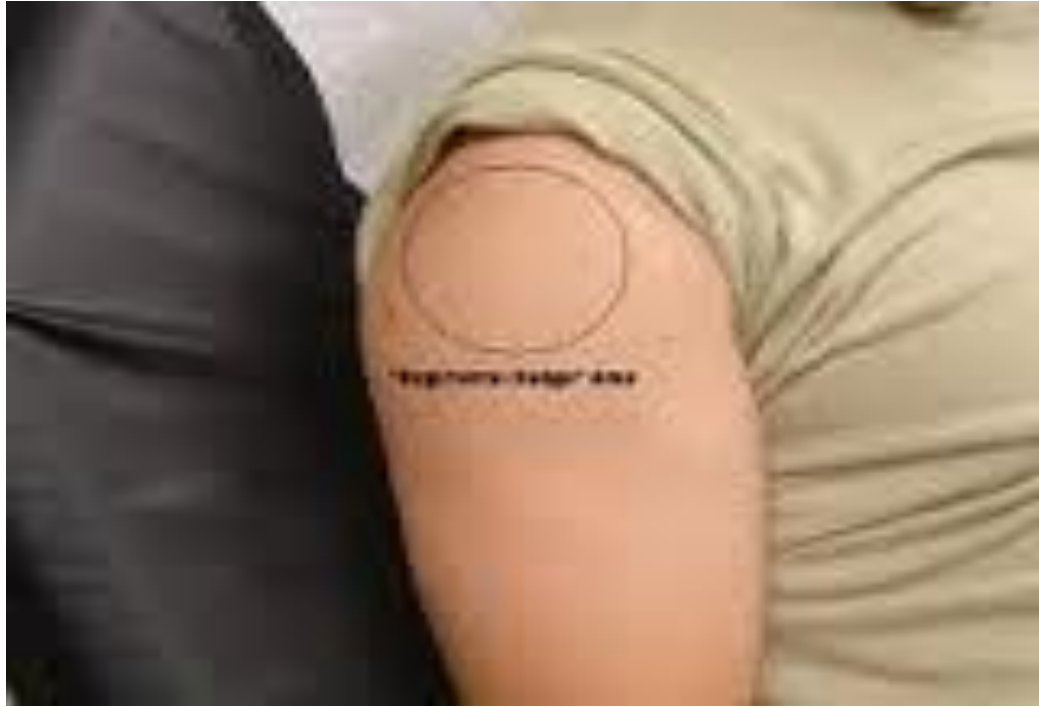
Most fractures are minimally displaced



PHYSICAL EXAM

- Expose the shoulder very well.
- Look for fracture signs
- Check the skin.
- Peripheral N/V exam.
- Axillary nerve: lateral skin patch.
- Examine cervical spine






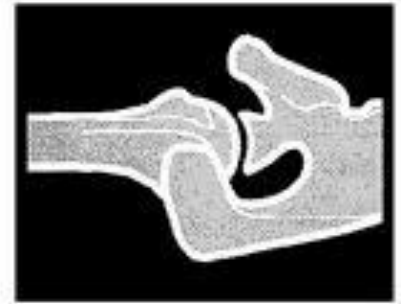
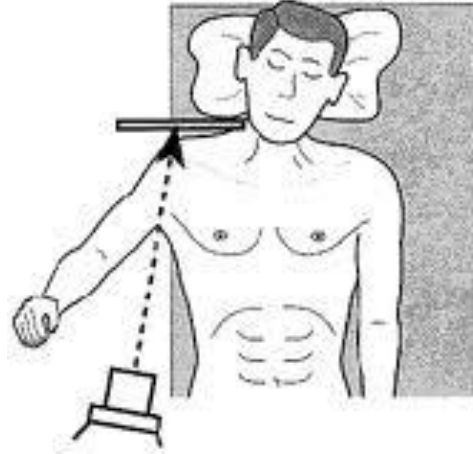
X-RAYS

AP

Lateral

Axillary views.

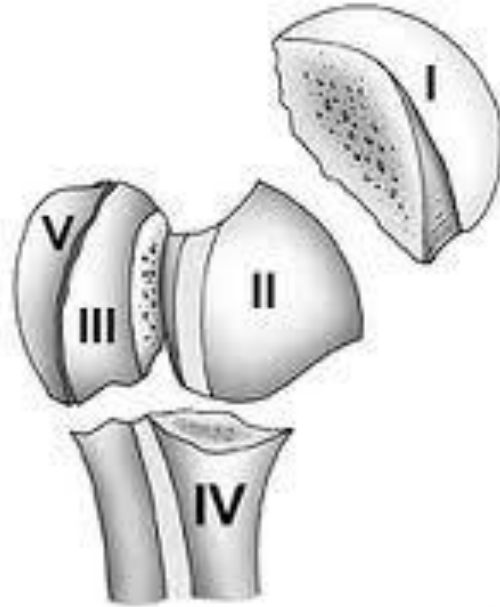
CT scan for displaced fractures



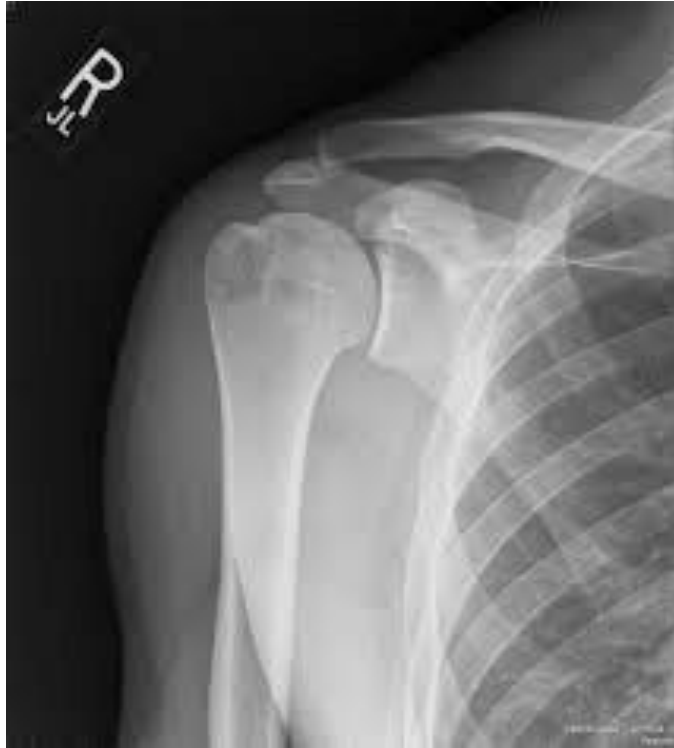
X-RAYS

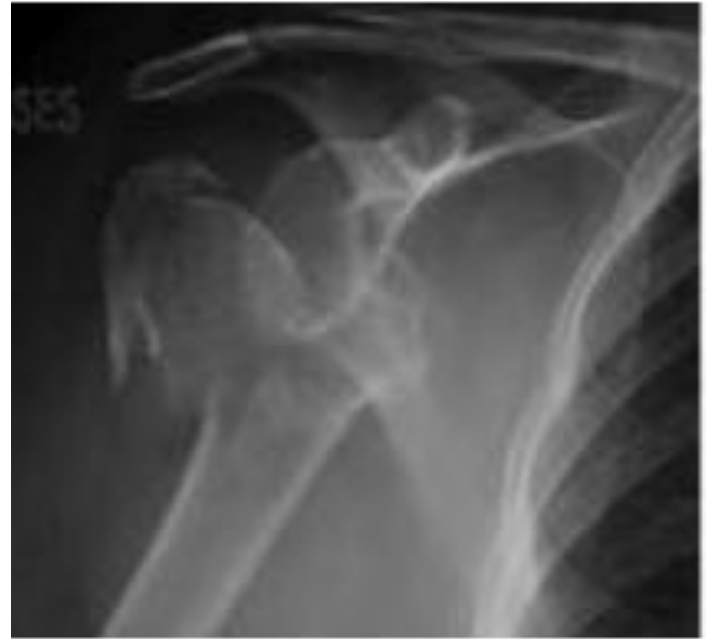
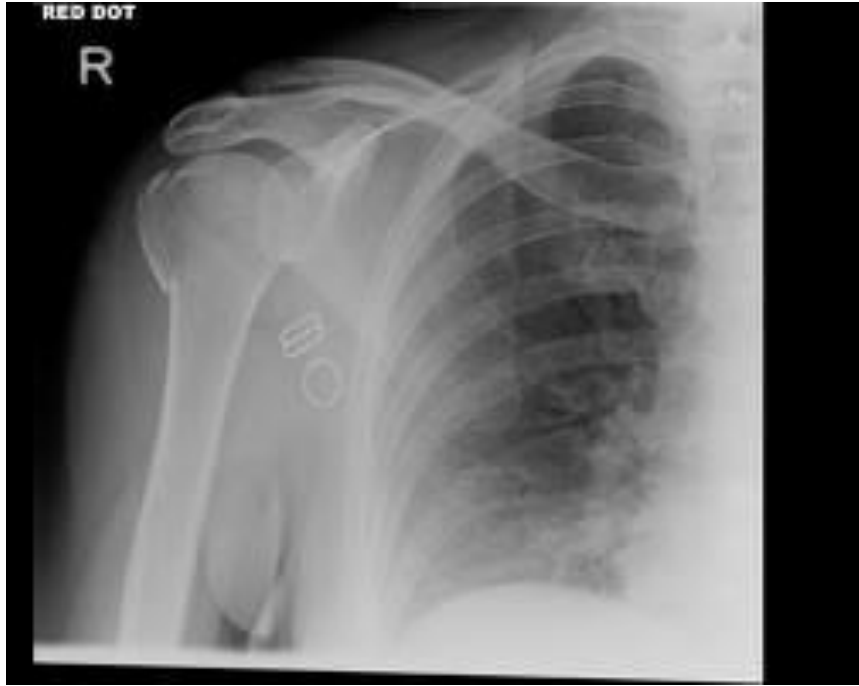Fracture is defined by the fragments displaced.

Displacement: more than 1 cm.



NORMAL AP SHOULDER





If fracture is not displaced:

- Treatment with sling and NWB of UE for 6-8 weeks.
- Early ROM exercises after 2-4 weeks.
- Normal function can be resumed after 3-4 months.

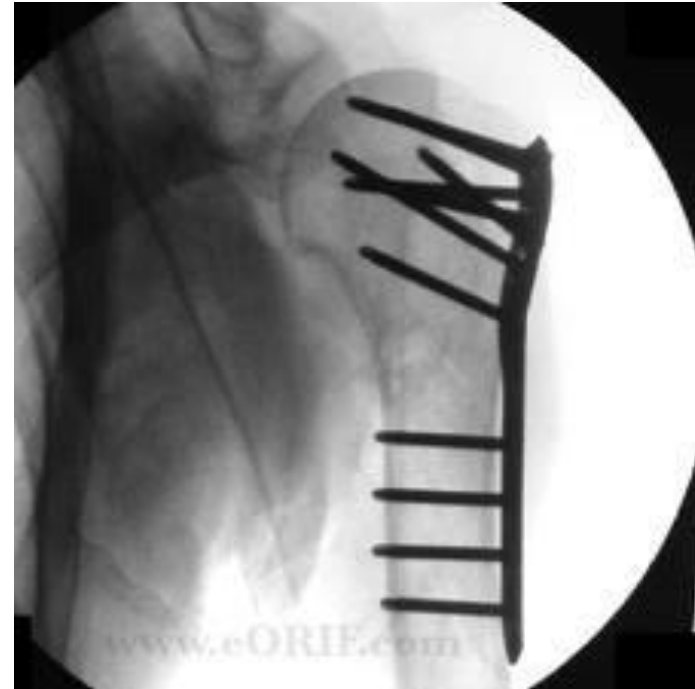

If the fracture is displaced:

Surgery is indicated.

ORIF is indicated (plate and screws).

Shoulder hemi-arthroplasty is indicated in some cases.



HUMERUS SHAFT FRACTURE


It can be classified based on location of fracture. (proximal, middle and distal)

Fracture symptoms

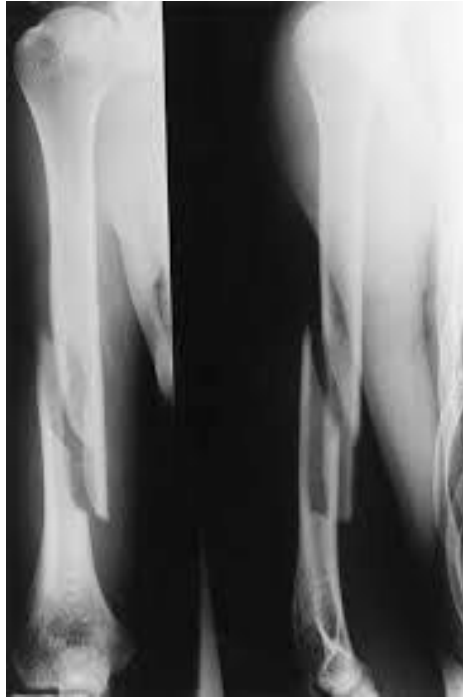
On exam:

- * Skin
- * N/V
- * Compartment

Watch for radial nerve palsy:

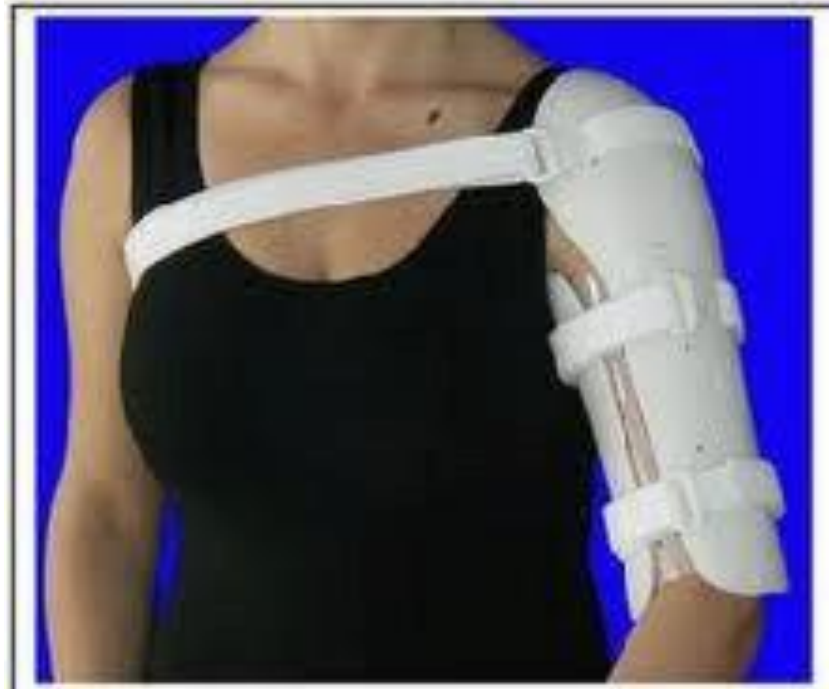

X-RAYS



Almost all humerus shaft fracture can be treated non-surgically.

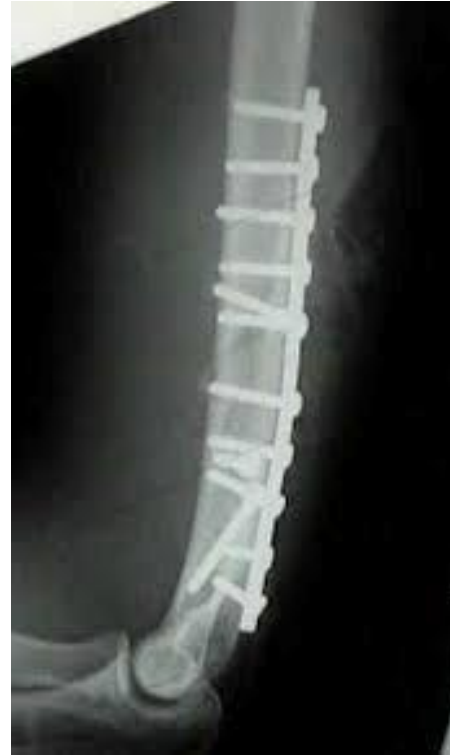- Close reduction
- Functional brace x 4-6 weeks + NWB
- Early ROM of elbow and shoulder.



Surgery is indicated for specific conditions like:

- . Segmental fracture
- . Open fracture
- . Obese patient
- . Bilateral fracture
- . Floating elbow (forearm and humerus)

Surgery: ORIF with plate and screws



BOTH BONES FOREARM FRACTURE

Forearm is complex with two mobile parallel bones.

Radius and ulna articulate proximally and distally.

It very unlikely to fracture only one bone without disruption of their articulation:

- . Both bone fracture
- . Monteggia fracture
- . Galeazzi fracture



Fractures are often from fall or direct blow.

Both bones fracture:

Means radius and ulna are broken.

Monteggia fracture:

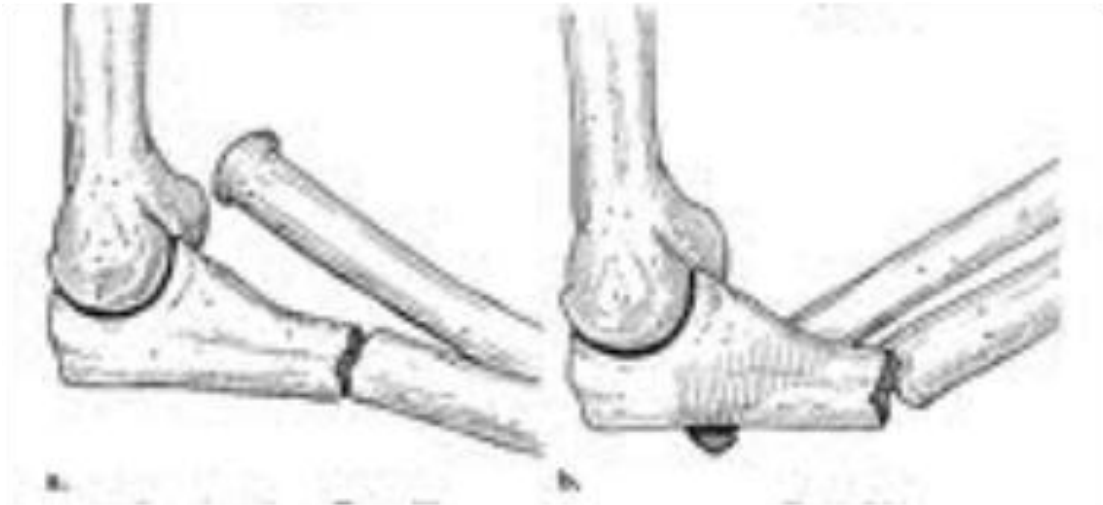
Means proximal or middle third ulna shaft fracture with dislocation of radius proximally (at elbow)

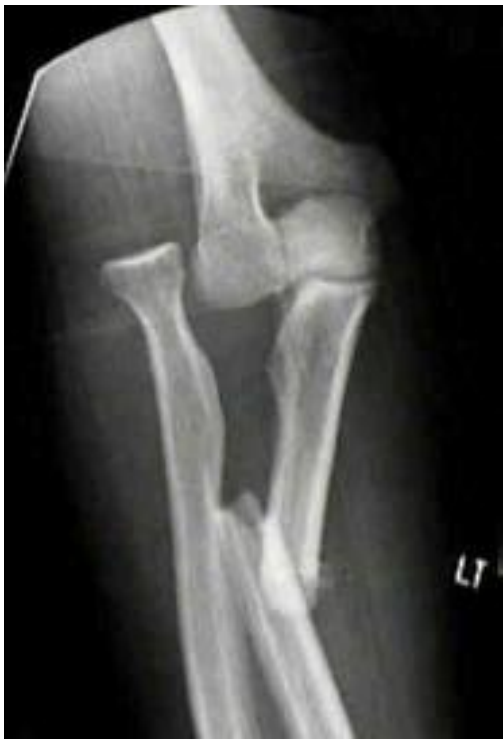Galeazzi fracture:

Means distal third shaft radius fracture with disruption of DRUJ.


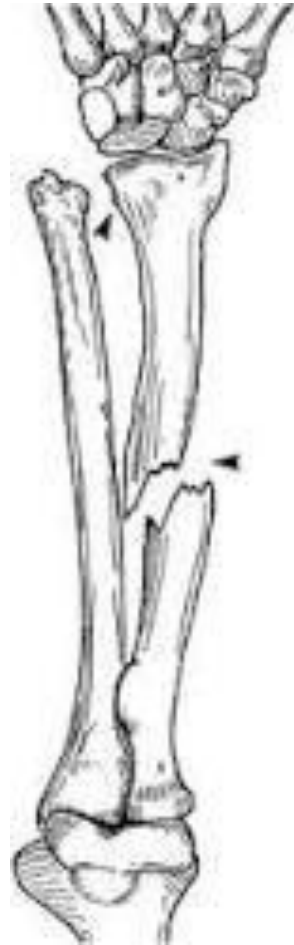


MONTEGGIA

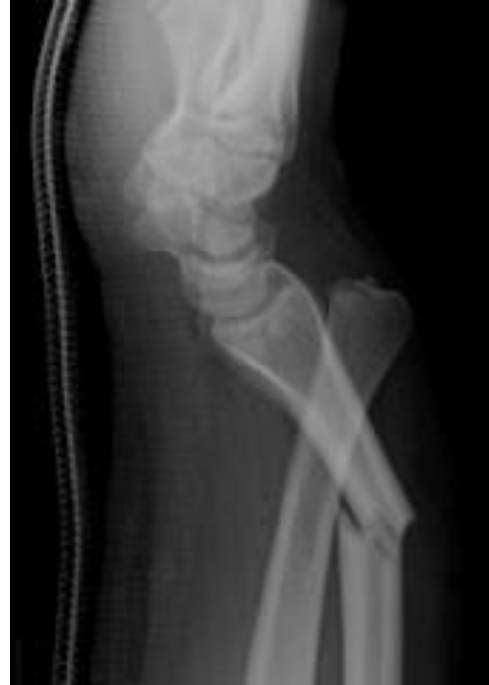



GALEAZZI




GALEAZZI



CLINICAL

Symptoms and signs of fracture


- Check the skin
- Check the compartments of forearm
- Check Ulnar, median and radial nerve (PIN, AIN)
- Check vascularity: color, temperature, capillary refill and pulse.



INVESTIGATIONS

2 orthogonal views

CT scan if fracture extends into joint.



*Frame A: AP forearm (including both joints)
Frame B: Lateral forearm (including both joints)
Image courtesy of Dr. Maveed Ahmad*

TREATMENT

Both bone fracture:

Reduce and splint at ER/clinic (temporary)


Are treated almost always with ORIF: (plate and screws)

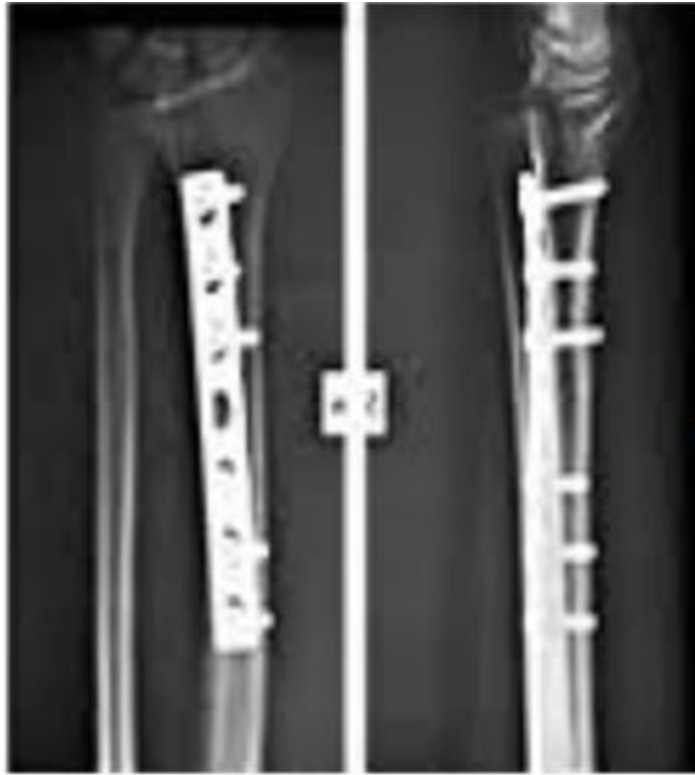
Monteggia fracture:

ORIF ulna and close reduction of radial head

Galeazzi fracture:

ORIF radius and close reduction of DRUJ





DISTAL RADIUS FRACTURE

- . Most common fracture of upper extremity.
- . Most frequently are seen in older women.
- . Young adults fractures are most commonly secondary to high energy trauma.





Extra-articular:

Colles/ Fracture: dorsal angulation, shortening and radial deviation

Smith's fracture: shortening and volar angulation. (reverse Colles')


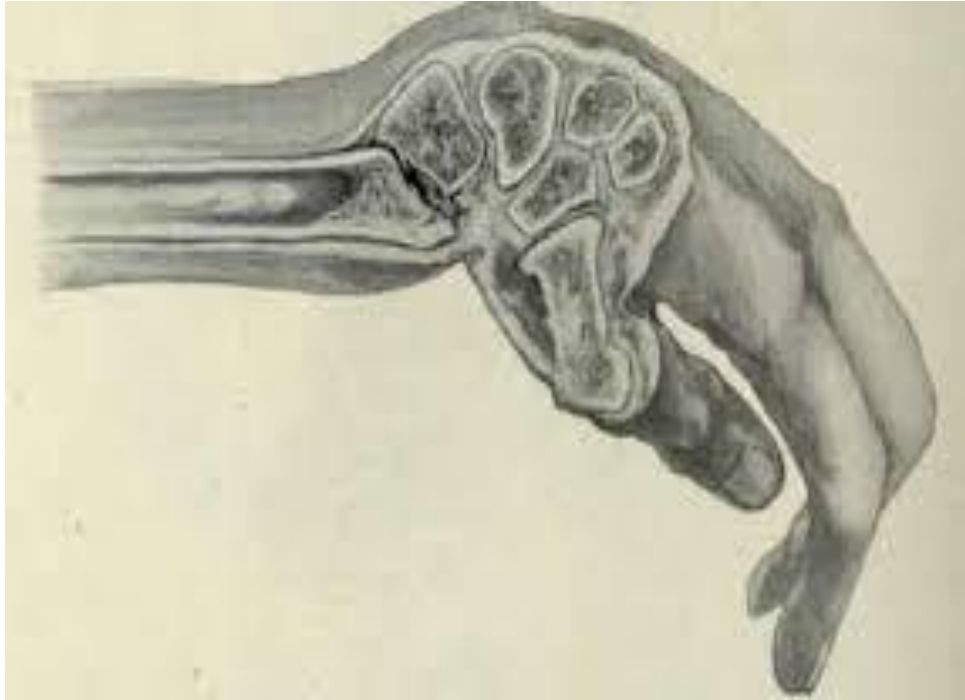
Intra-articular:

Barton's fracture: volar or dorsal

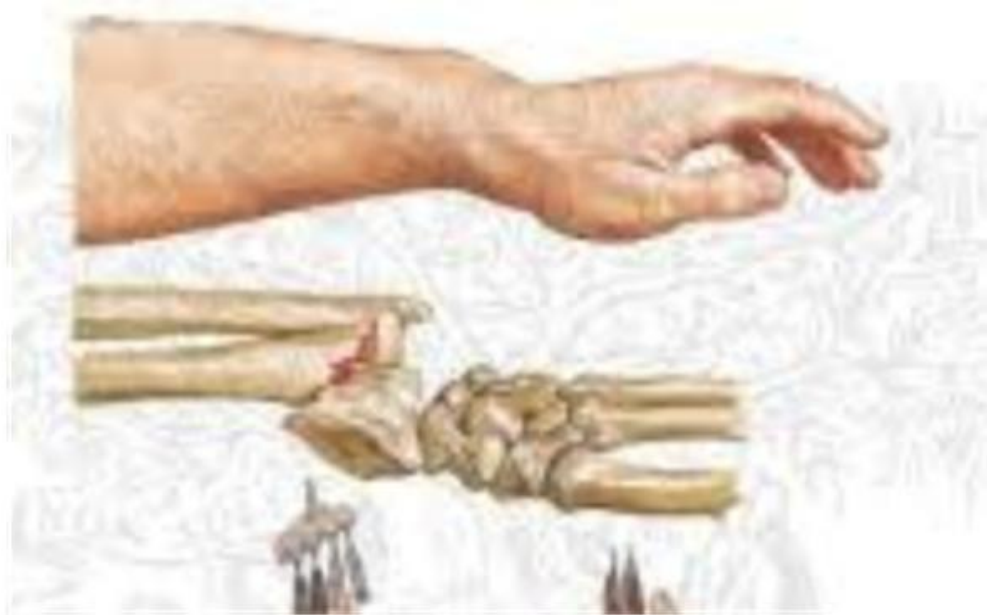
others

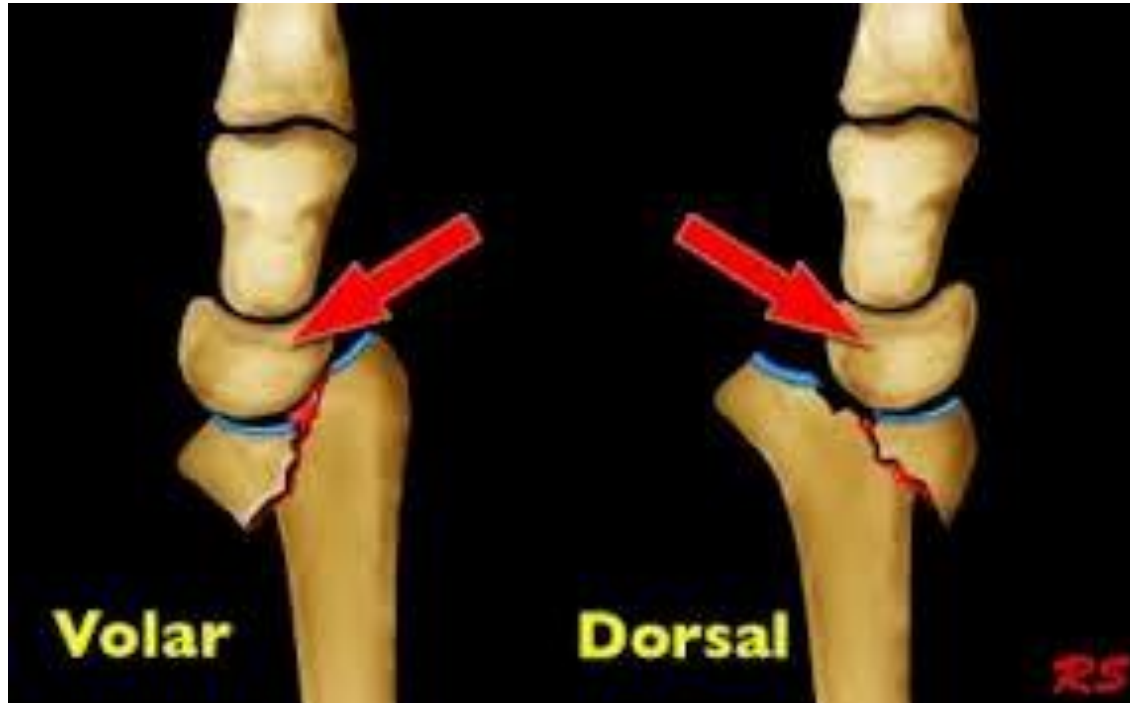


COLLES'




SMITH'S





DORSAL ↑


Colles fracture



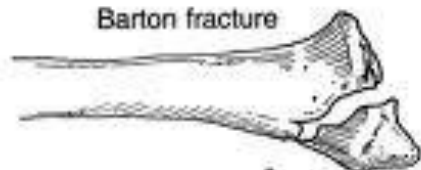
Smith fracture




Barton fracture



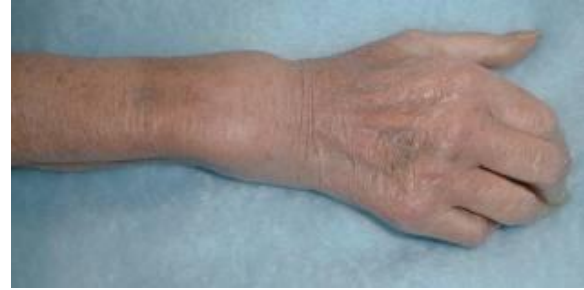
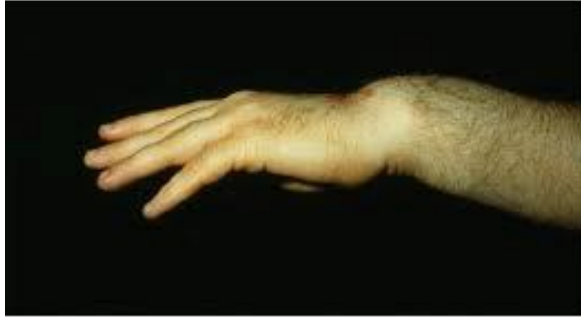Barton fracture



VENTRAL ↓

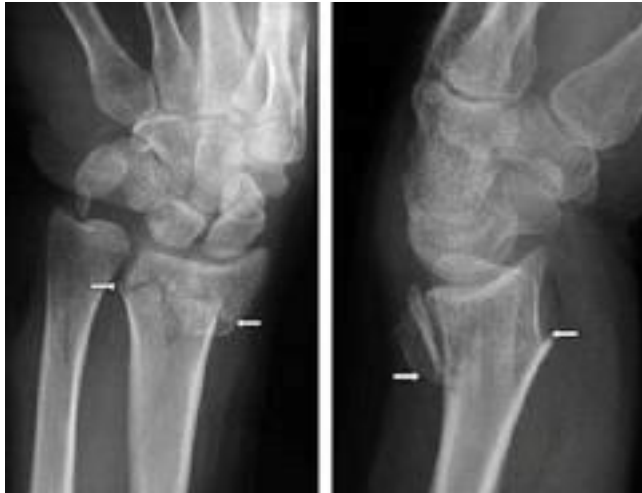

CLINICAL

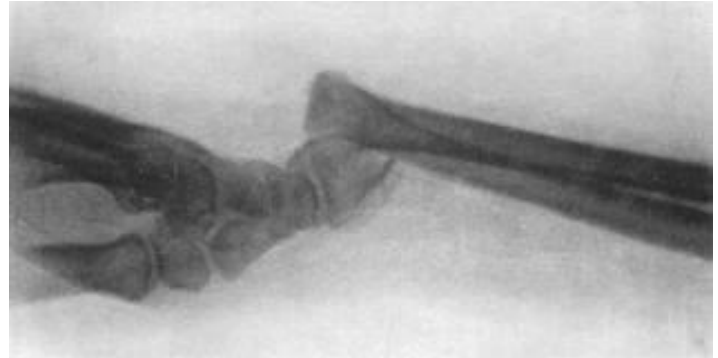

X-RAYS


Colles'



Smith's



CT scan if fracture extends into joint



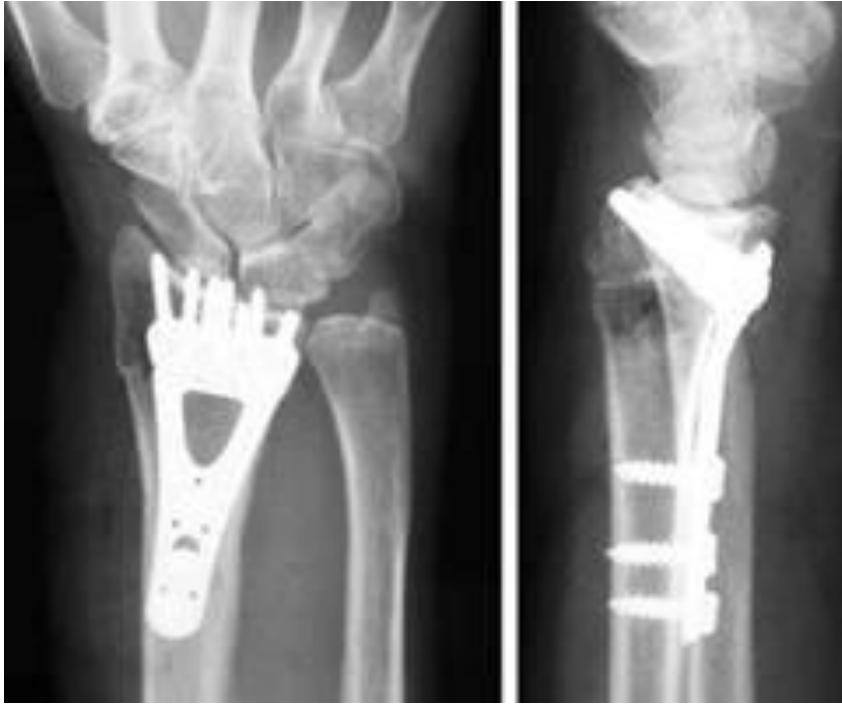Extra-articular fractures:

- . Close reduction and cast application.
- . Immobilization for 6-8 weeks.
- . ROM exercises after cast removal.
- . Surgery: if reduction is not accepted.

Intra-articular fracture:

- . A step more than 2 mm is an indication for surgery.
- . ORIF with plate and screws.







LOWER EXTREMITY

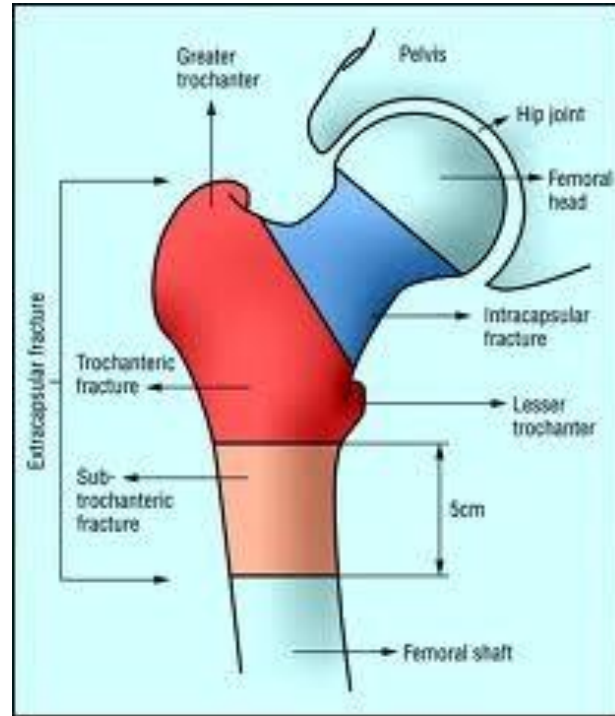
HIP FRACTURE (Old patients: > 60 yrs)

- It is the most common fracture of LL.
- It is associated with osteoporosis.
- Most common mechanism is a fall from standing height.
- Other causes of fall (stroke, MI) should be rolled out during clinical evaluation.
- It is a life changing event.



Fractures can be classified

- Intra-capsular
- Extra-capsular
- Displaced vs not displaced



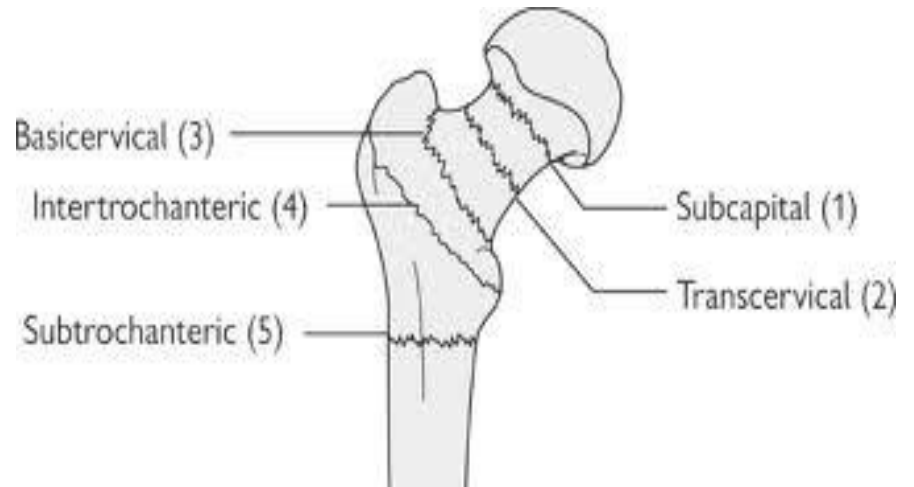
Intra-capsular:

- Subcapital
- Trans-cervical

Extra-capsular:

- Basicervical
- Intertrochanteric

AVN risk is higher with intra-capsular fracture.



CLINICAL

- Full detailed history of mechanism of injury.
- R/O syncope, chest pain, weakness, etc.
- A detailed systemic review.
- Deformity: Abduction, External rotation and shortening.
- Assess distal N/V status
- Avoid ROM if fracture is expected.



Common associated injuries:

1. Distal radius fracture
2. Proximal humerus fracture
3. Subdural hematoma



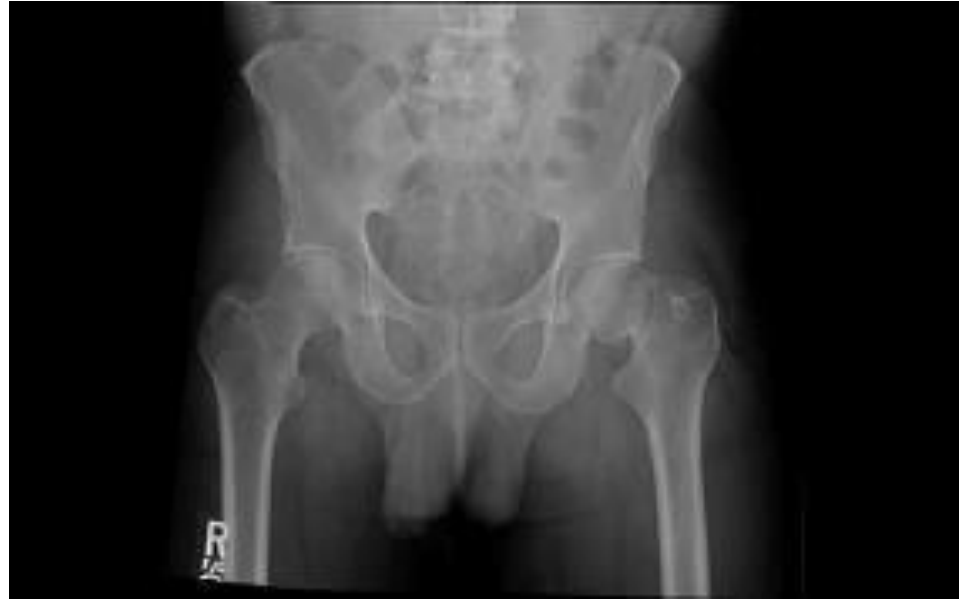3 views are needed:

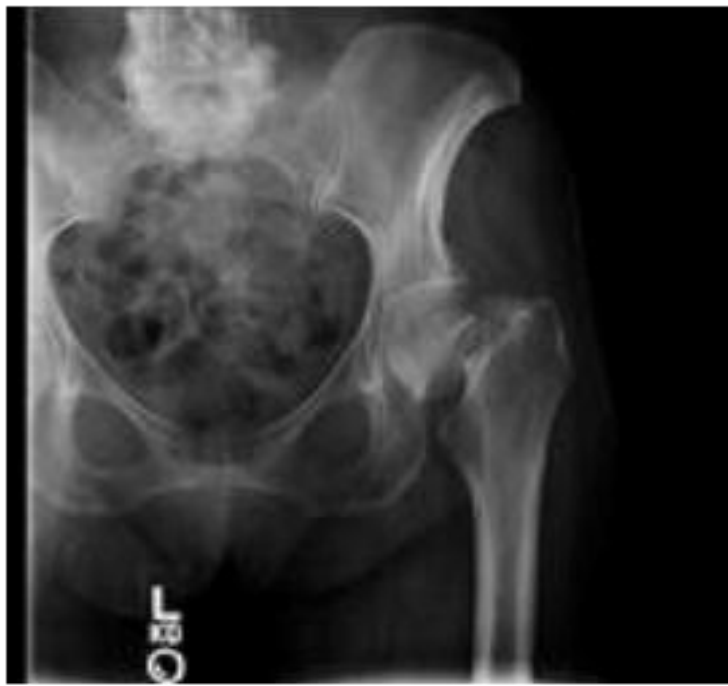
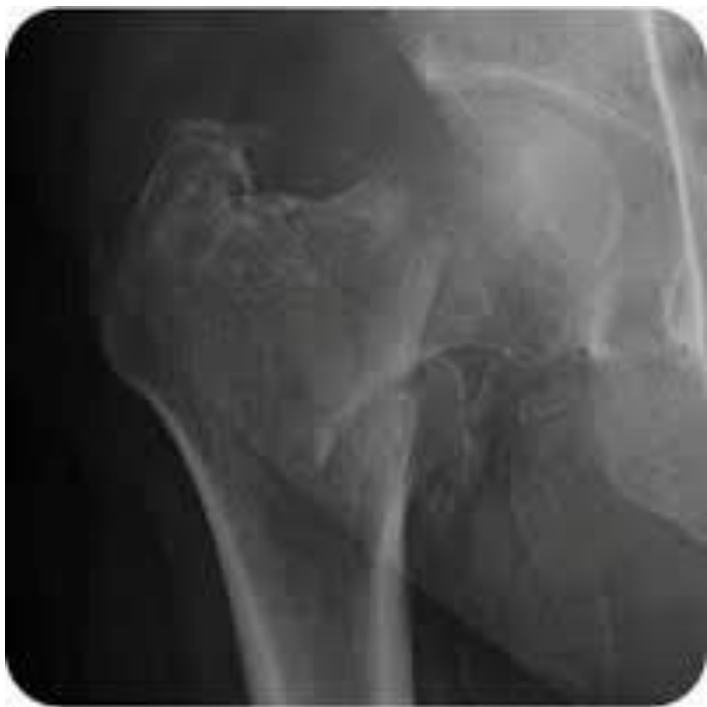AP pelvis

AP hip

Lateral hip

MRI is sensitive for occult fracture.





TREATMENT

- No close reduction is needed.
- No traction is needed.
- Patient needs surgery ideally within 48 hours.
- The goal is to ambulate patient as soon as possible.
- Be sure that DVT Prophylaxis is started.
- Be sure that patient will be evaluated for osteoporosis after discharge.

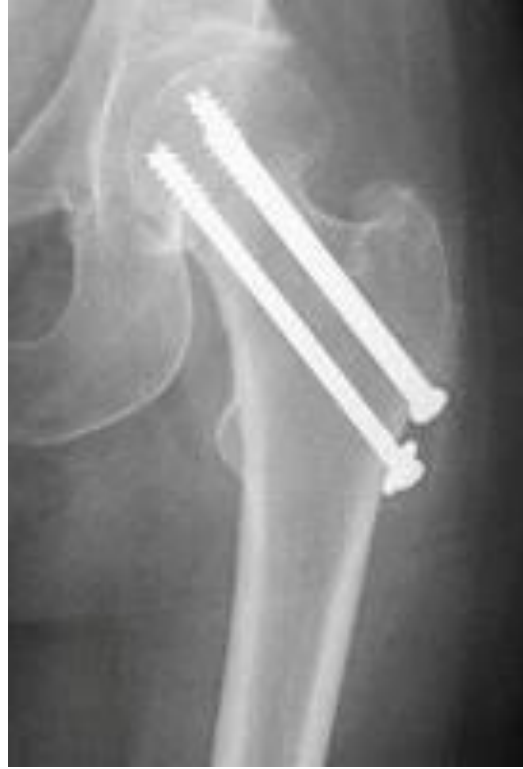
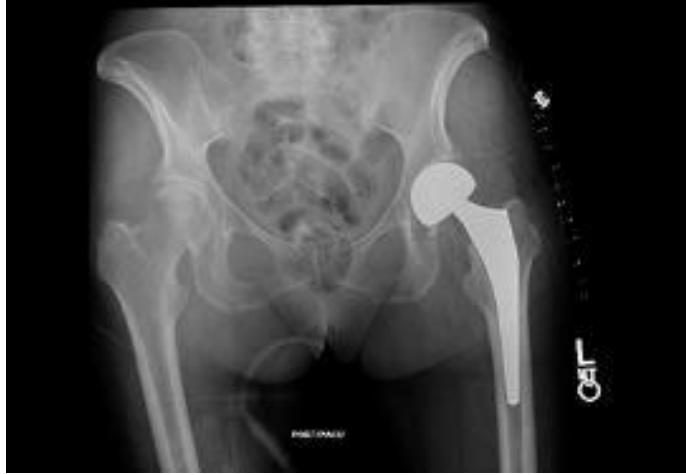

TREATMENT

If fracture is intra-capsular:

Hemiarthroplasty: percutaneous in situ Screws fixation.





If fracture is Extra-capsular:

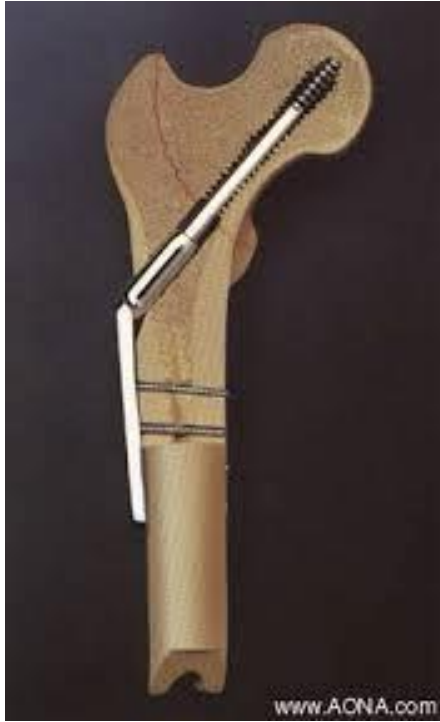- . Stable: Close reduction and DHS
- . Unstable: Intra-medullary devise

Fracture instabilities signs:

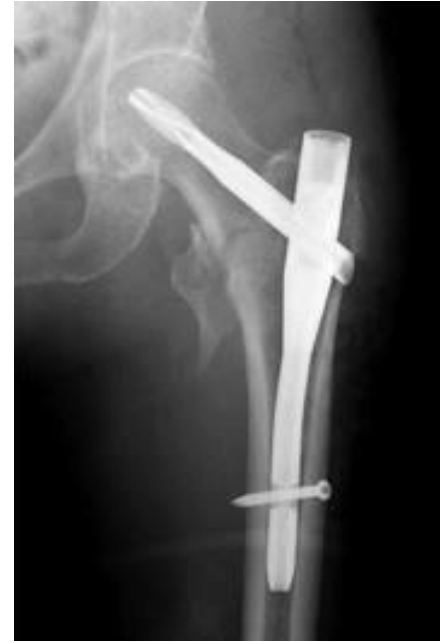1. Large LT fragment
2. Extension to subtrochantric region
3. 4 parts fracture



DHS



IM Nail



COMPLICATIONS

Nonunion

2% (IT fractures)

5% (non displaced neck fracture)

30% (displaced neck fracture)

AVN (femoral neck fracture):

10% (non displaced)

30% (displaced)

Death: early 4%. At 1 year: 20-40%

VTE



FEMORAL NECK FRACTURE (Young Patients)

It is a completely different entity from similar fractures in elders (>60 years).


High energy mechanism.

ATLS protocol.

2.5% associated femoral shaft fracture. (long femur X-ray)

Nonunion: 30% (most common complication)

AVN: 25-30%



FEMORAL SHAFT FRACTURE

Most common:

high energy mechanisms

Young patients (male, < 30 years).

ATLS protocol,

Less common:

low energy mechanism (torsional forces)

Old patients.

Spiral type fracture




Associate musculoskeletal injuries:

- . Ipsilateral femoral neck fracture (10%. Missed in 30-50%)
- . Knee ligaments injuries: 50%
- . Meniscal tear 30%
- . Floating knee injury: less common
- . Vascular/nerve injuries: rare
- . Contralateral femur shaft fracture (worse prognosis among above)




Associated non-MS injuries:

- . Fat embolism
- . ARDS
- . Head injuries.
- . Abdominal injuries




CLINICAL

- ATLS
- Fracture symptoms and signs
- Skin integrity
- N/V exam.
- Compartment assessment
- Knee swelling or echymosis.



INVESTIGATIONS

- AP and lateral views femur
- 15° Internal rotation AP view ipsilateral hip.
- Lateral view ipsilateral view
- If femoral neck fracture is suspected: CT scan hip.
- Knee AP and lateral views




MANAGEMENT

ATLS: ABC resuscitation.

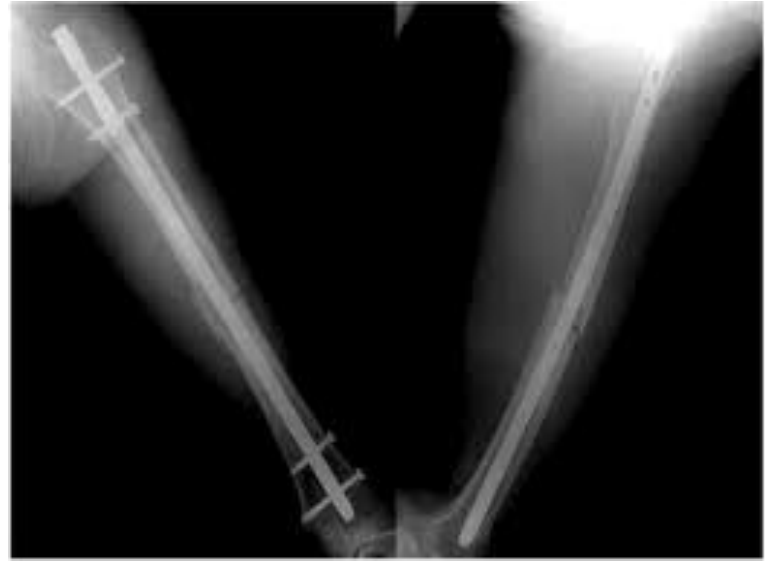
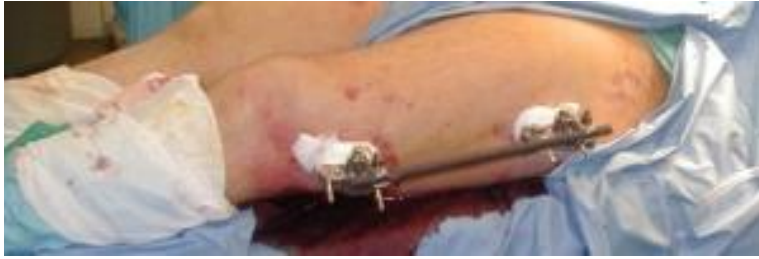Skeletal traction (proximal tibial pin)

Early surgical fixation:

- Proven to reduce Pulmonary complications.
- Must be within 24 hrs (ideally < 6 hrs).
- If patient is unstable: External fixation.
- If patient is stable IM nailing



FEMUR SHAFT FRACTURE



COMPLICATIONS

Malunion:

- . Most common.
- . More common with proximal fracture (subtrochantric fracture)
- . Rotational, angulation and shortening

Nonunion: rare

Infection.

VTE.



TIBIA SHAFT FRACTURE

- . It is a subcutaneous bone (high suspicion for skin injury).
- . Most common large long bone fracture.
- . It can be secondary to low or high energy mechanism.
- . It carries the highest risk of compartment syndrome.
- . 20% of tibial fracture can be associated with ankle intra-articular fracture



- It can be classified based on location and morphology:
 - Proximal third
 - Middle third
 - Distal third
- Displaced vs. Non-displaced:



Clinical:

- . Skin integrity.
- . Assess compartments of leg: needs serial exam.
- . Serial N/V exam.



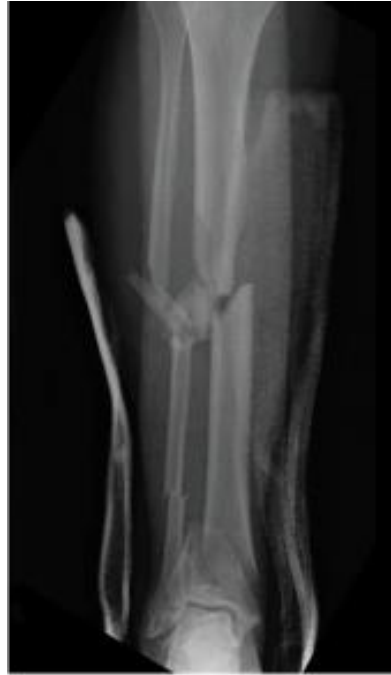
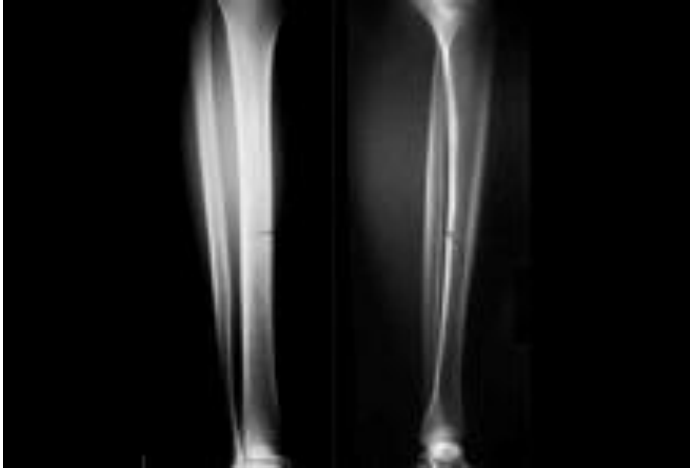INVESTIGATIONS

X-rays:

- AP and lateral tib/fib.
- AP/lateral knee
- AP/Lateral ankle

CT SCAN IF FRACTURE EXTENDS INTO JOINTS ABOVE OR BELOW.





MANAGEMENT

Indications for non-surgical treatment:

- . NO displacement: $< 10^\circ$ angulation on AP/lateral x rays.
- . < 1 cm shortening.
- . Not comminuted.

C/I:

- . Displacement.
- . Open fracture.
- . Compartment syndrome.
- . Floating knee.



MANAGEMENT

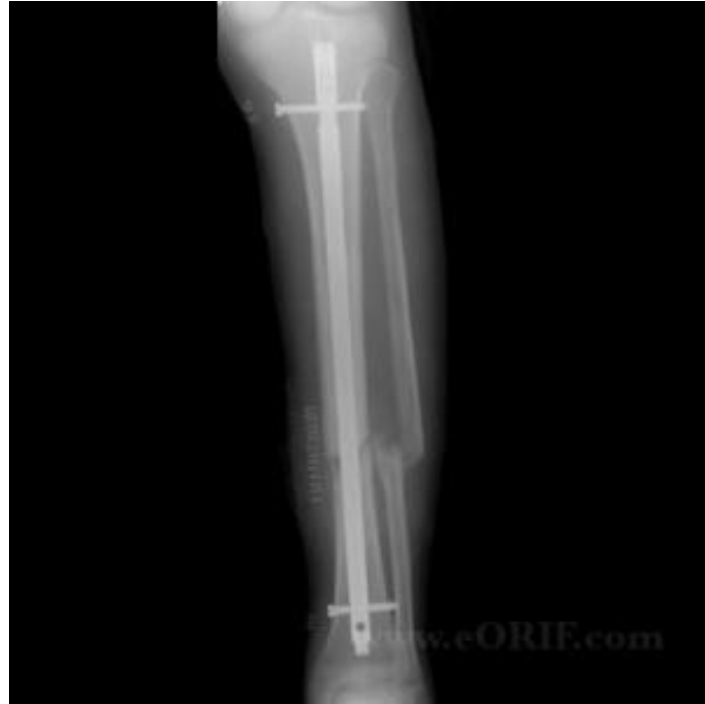
Close reduction and cast immobilization:

- Above knee back slab and U slab if surgical treatment is chosen.
- Above knee full cast if non-surgical treatment is chosen: it must be bivalved to minimized compartment syndrome.
- Always provide patient with Compartment Syndrome checklist if patient is discharged home with cast.
- NWB for 8 weeks with cast immobilization.



Surgical treatment:

- . Most common modality of treatment
- . Most commonly IM nail fixation.



COMPLICATIONS


- . Non-union: most common complication
- . Delayed union
- . Infection: open fracture
- . DVT/PE

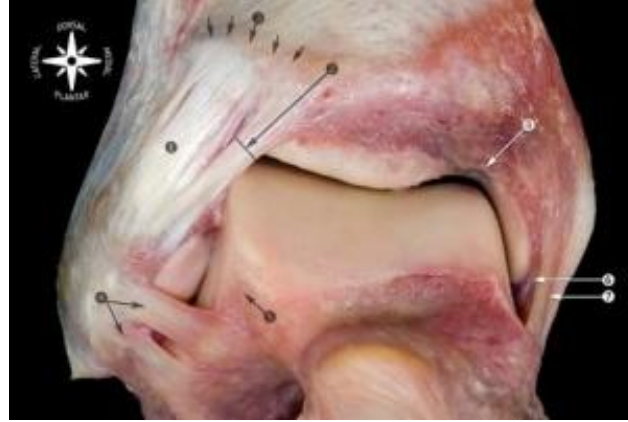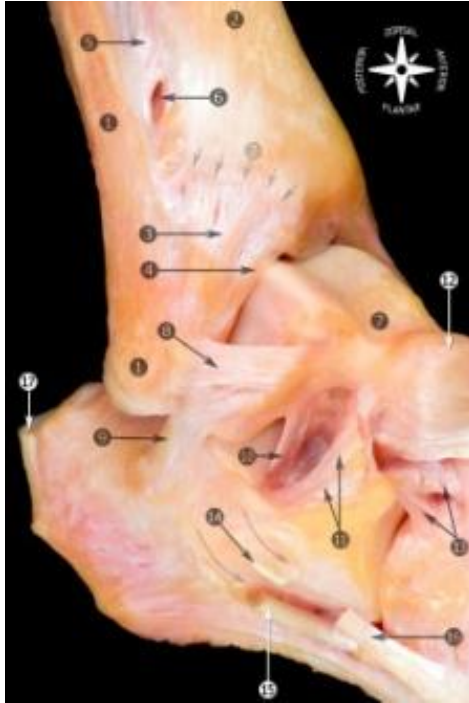


ANKLE FRACTURE

Ankle anatomy:

- . Medial and lateral malleoli, distal tibia and talus.
- . Highly congruent joint
- . Fibula is held to distal tibia by syndesmotic ligament.
- . Medial malleolus is held to talus by deltoid ligament.
- . Lateral malleolus is held to talus by LCL.





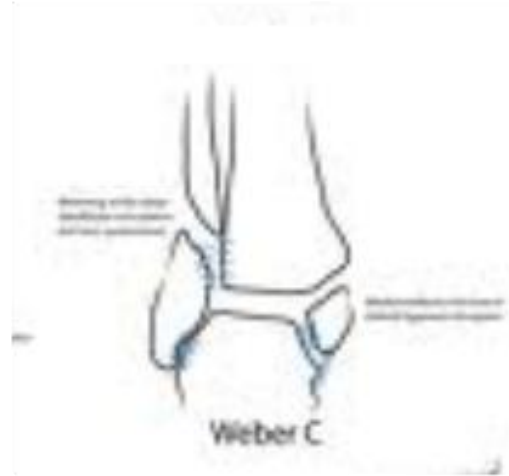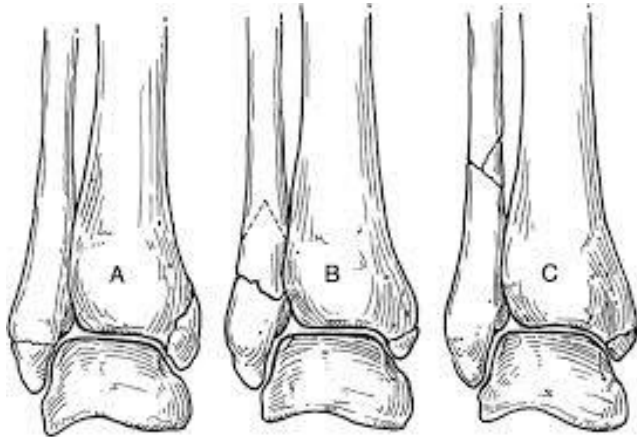
Low energy (torsional): malleoli fracture.

Classification:

- Stable v.s. Unstable fracture:
 - Lateral displacement of talus
- Medial, lateral or bimalleolar fracture
- Lateral malleolus: Weber A, B, C



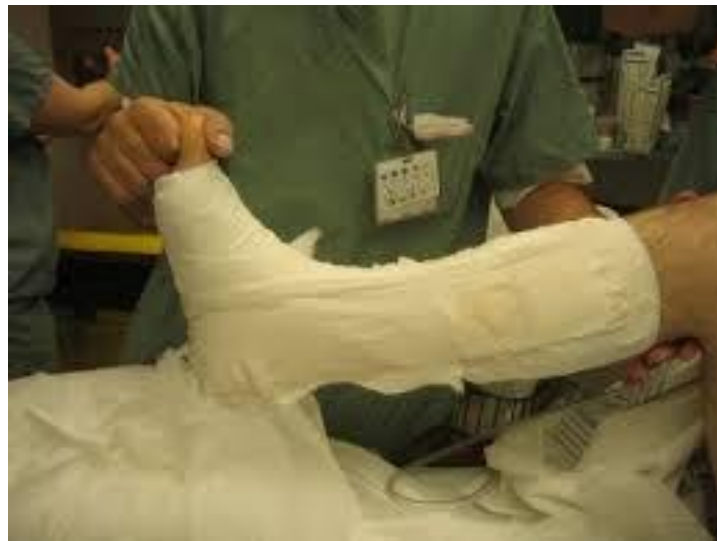
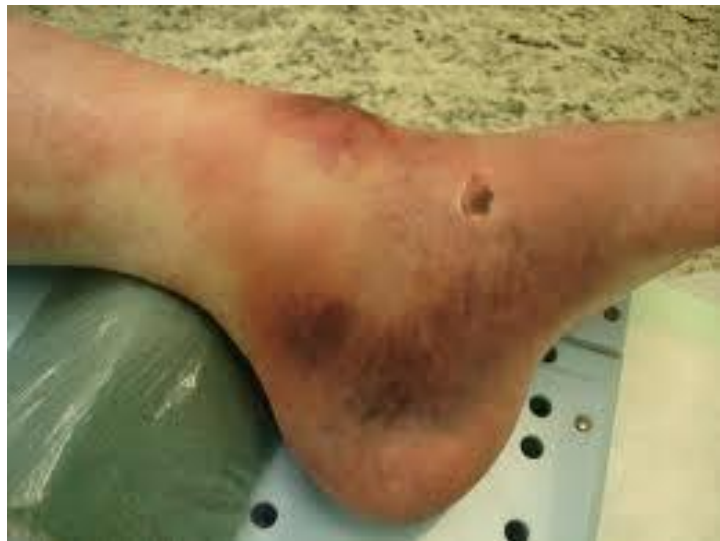
ANKLE FRACTURE



CLINICAL

- Look for Fracture symptoms and signs.
- Assess medial joint ecchymosis or tenderness to assess medial malleolus and deltoid ligament integrity.
- Assess N/V status (before and after reduction).



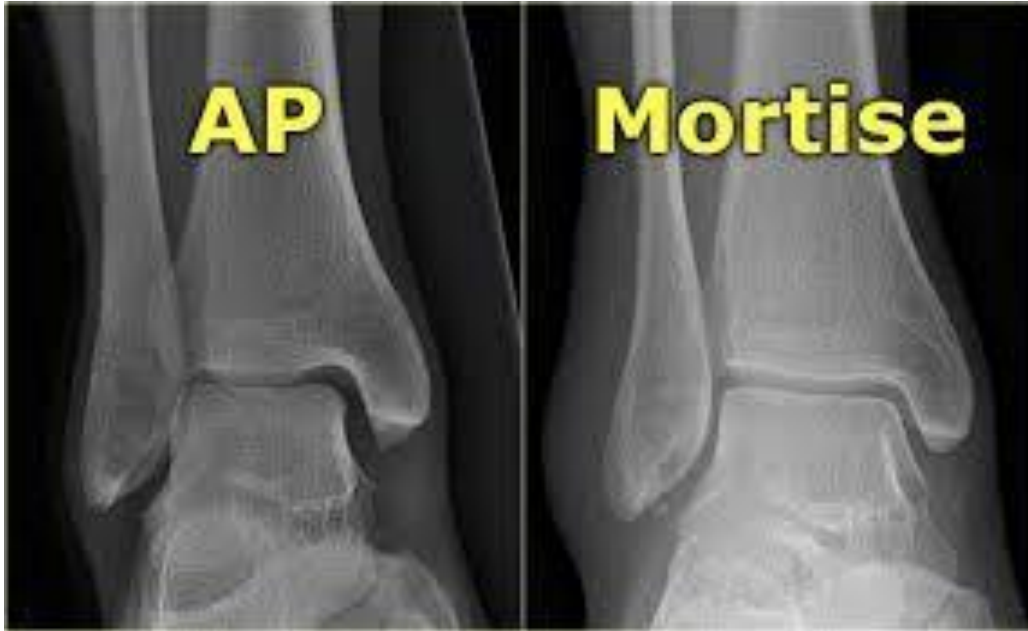


X-rays:

- . AP
- . Lateral
- . Mortise view
- . Long leg x-rays: if only medial malleolus is broken.

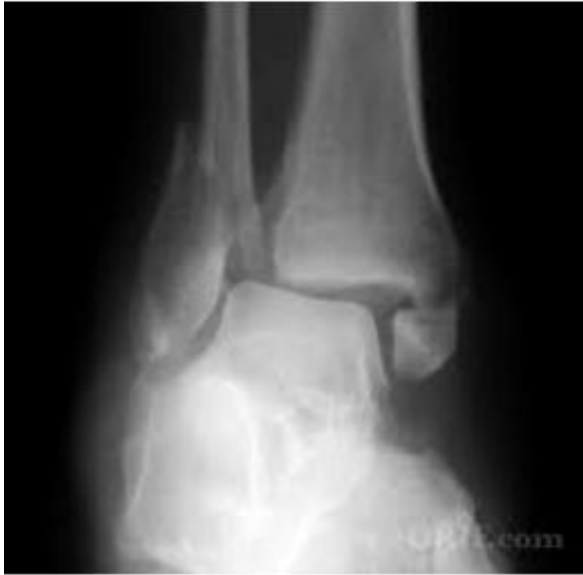CT SCAN IF FRACTURE EXTENDS TO ARTICULAR DISTAL TIBIA SURFACE.




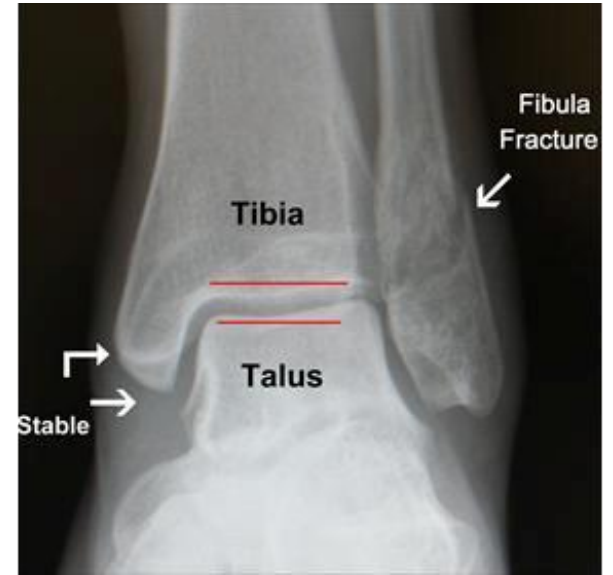

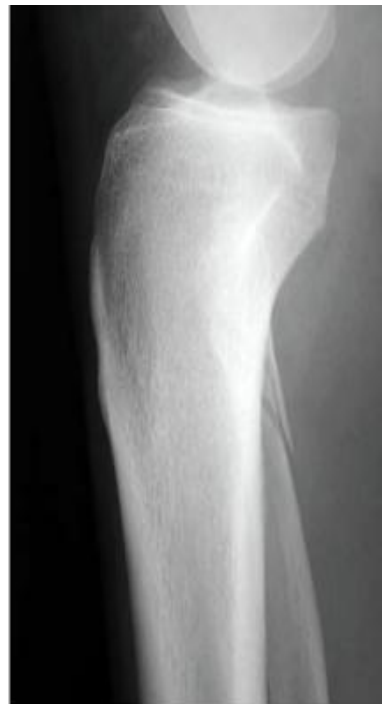
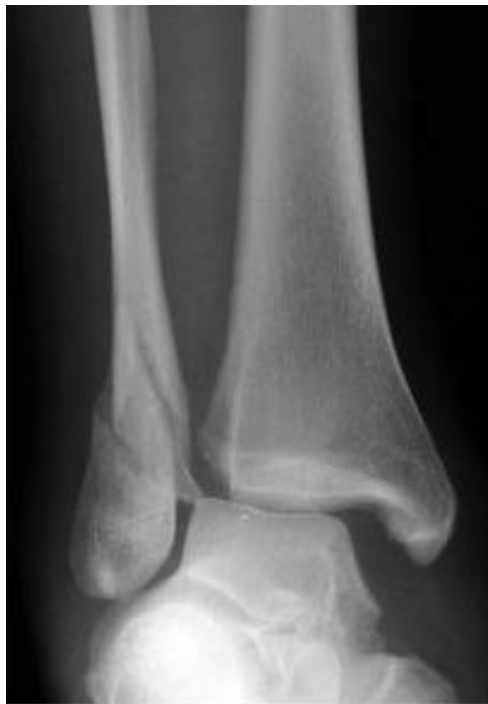
Unstable: > 4mm lateral

translation



Stable





Intact medial malleolus:

Weber A:

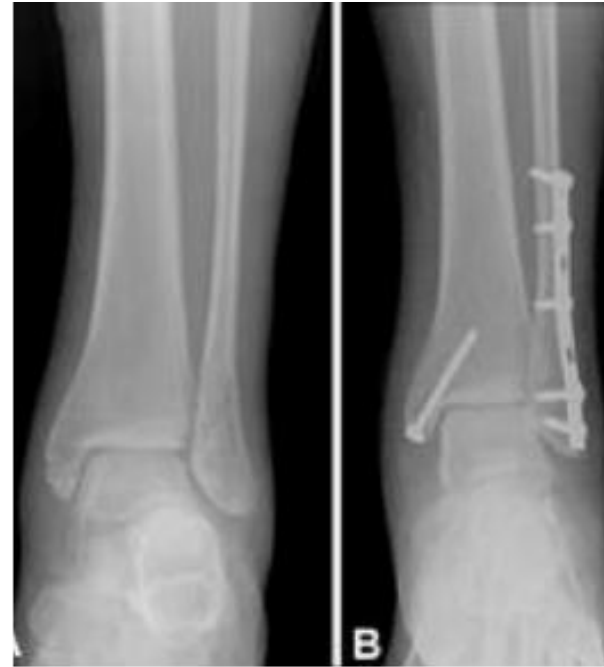- Splint + NWB X 6 weeks.
- Early ROM.

Weber B/C:

- If medial joint line widen (unstable):
ORIF
- If not: Call Orthopedic for stress film
x-rays.

If both malleoli are broken:

- ORIF



Thank
you!

A colorful, hand-drawn illustration of the words "Thank you!" in a playful, bubbly font. The letters are filled with various colors like orange, purple, green, and pink, and decorated with patterns like zig-zags and dots. There are several stylized flowers in blue, pink, and purple scattered around the text. The entire illustration is set against a white background, which is itself centered on a dark blue background with geometric shapes.