



Pharynx I&II

Done by : Maram Al-Aqel

Objectives:

- ✓ To know the basic pharynx anatomy and physiology.
- ✓ To recognize assessment and management of common pharyngeal diseases, include ability to obtain patients' history, perform comprehensive physical and mental status assessment, interprets findings.
- ✓ To know how to handle common pharyngeal emergencies.
- ✓ To be aware of common pharyngeal operations.
- ✓ Pharynx I:
 - anatomy of the pharynx and deep neck spaces (retro and parapharyngeal)
 - physiology (function of pharynx in brief)
 - acute and chronic pharyngitis (non-specific and specific) e.g. scarlet fever, infectious monoliasis, fungal, Vincent angina, diphtheria
 - Zenker diverticulation (in brief)
- ✓ Pharynx II:
 - adenoid and tonsil diseases.
 - complication of pharyngeal diseases (Quinsy, para and retropharyngeal, Ludwig's angina) + Radiological illustrations)
 - adenotonsillectomy (indications, complication and management)

Correction File

Color Index :

Slides - Team 433 - Important Notes - Doctors' Notes - Lecture notes book -Toronto notes

❖ Anatomy of Pharynx:

It extends from the base of the skull to the level 6 cervical vertebra at the lower border of cricoid cartilage.

Funnel shaped, 10 cm length

Cases

- My child snores; he is mouth breather (Adenoid)
- I have sore throat every day (Chronic pharyngitis)
- I have fever, sore throat, dysphagia, I can't open my mouth (Tonsillitis, or its complication)

❖ Structures of pharynx

❖ Pharyngeal Wall:

- ✓ Mucous membrane
- ✓ Submucosa
- ✓ Muscular layer
- ✓ Fibrous layer (Buccopharyngeal fascia)

○ Mucous membrane:

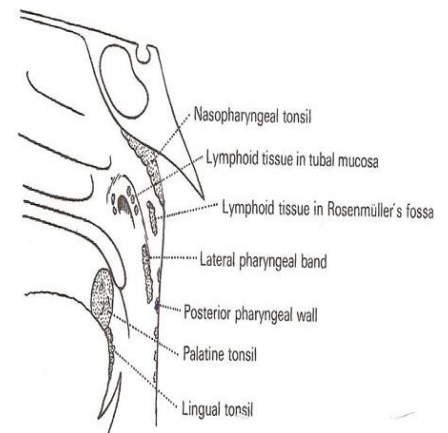
- ✓ Nasopharynx – Ciliated columnar epithelium
- ✓ Oro and hypopharynx – Stratified squamous epithelium
- ✓ Sub epithelial lymphoid tissue of the pharynx (Waldeyer's ring)

○ Submucosa:

- ✓ Nerves, blood vessels, and lymphatic's.
- ✓ Mucous and salivary glands
- ✓ Sub epithelial lymphoid tissue (Waldeyer's Ring).

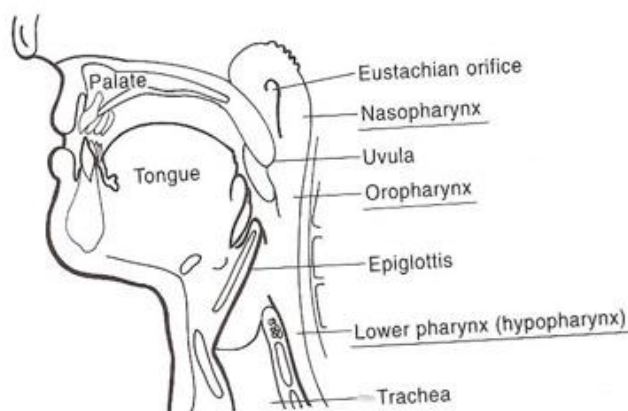
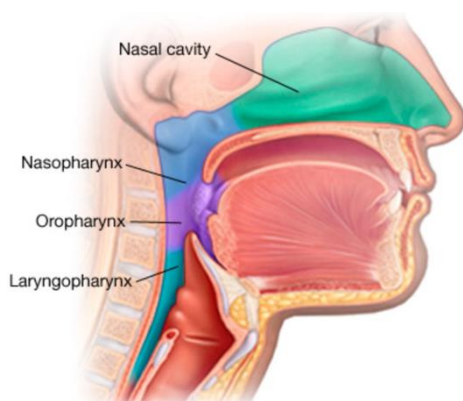
○ Characteristics of Waldeyer's Ring:

- ✓ No afferents
- ✓ Efferent to deep cervical nodes
- ✓ No capsule except the palatine tonsils



❖ Parts of Pharynx:

	Open ant to	Above	below	Lateral	Extra
<i>Nasopharynx</i>	nose	base of skull	Soft palate	1-opening of the Eustachian tube. 2-torus tuberosus*. 3-Pharyngeal recess** (fossa of rosenmuller). 4-Adenoid. 5-Nasopharyngeal isthmus***.	*Torus tubarius or cushion of the auditory canal is a mucosal elevation in the lateral aspect of the nasopharynx, formed by the underlying pharyngeal end of the cartilaginous portion of the Eustachian tube. **Behind the ostium of the Eustachian tube (ostium pharyngeal tuba auditiva) is a deep recess, the pharyngeal recess *** opening in the floor between the soft palate and the posterior pharyngeal wall.
Oropharynx	Mouth and divided from the oral cavity by Tonsillar pillar.	soft palate	Upper border of epiglottis		-What does oropharynx contain?? Palatine tonsils; between the anterior and posterior pillars. 2-Valleculae: Is a depression on each side of the median glossoepiglottic It is the area between the epiglottis and base of the tongue.
Laryngopharynx (hypopharynx)	larynx	upper border of the epiglottis	lower border of cricoid		Between them we have: 1-Pyiform fossa (potential space that lie on either side of the larynx). When the patient presents with halitosis, check the oral hygiene and make sure that the patient is cleaning the tongue, and exclude other causes like reflux and diverticula.



Muscular coat

EXTERNAL: Three constrictor muscles:

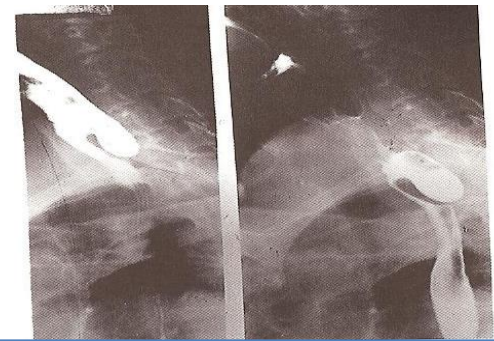
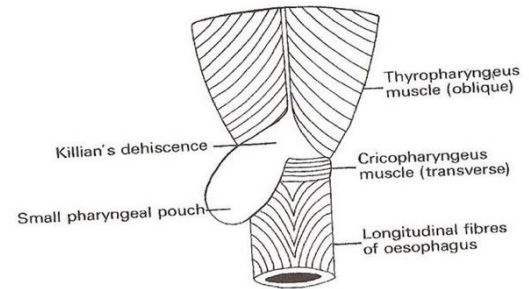
Superior constrictor
 arise from pterygoid, ptergomandibular ligament post end of mylohyoid fibers

Middle constrictor:
 Arise from the hyoid bone and stylohyoid ligament

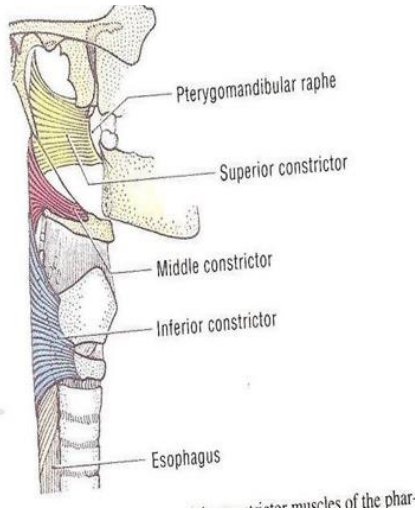
Inferior constrictor: (2 parts)
 Thyropharyngeus (Attached to thyroid)
 Cricopharyngeus (attached to cricoid)

Killian's dehiscence
 Potential gap between the thyropharyngus and cricopharyngus.

potentially weak spot where a pharyngoesophageal diverticulum (Zenker's diverticulum) is more likely to occur.



**Case: vomiting undigested food → DDX: Pouch
 How to confirm → Barium enema**

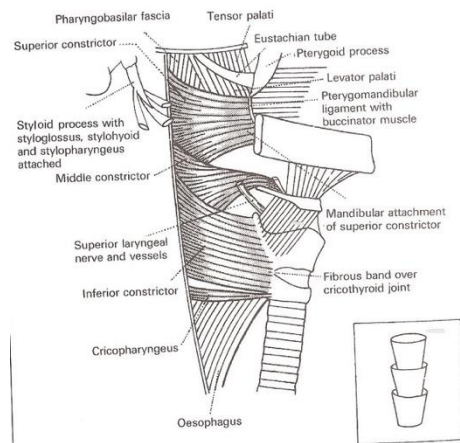


Internal: Three muscles

Stylopharyngus

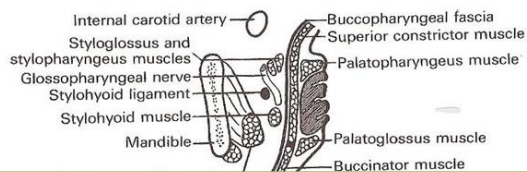
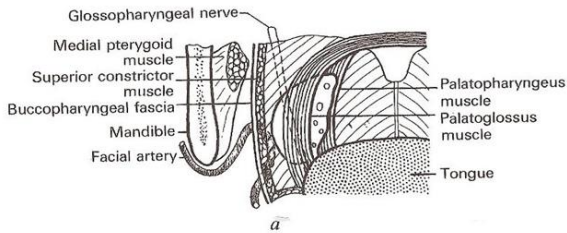
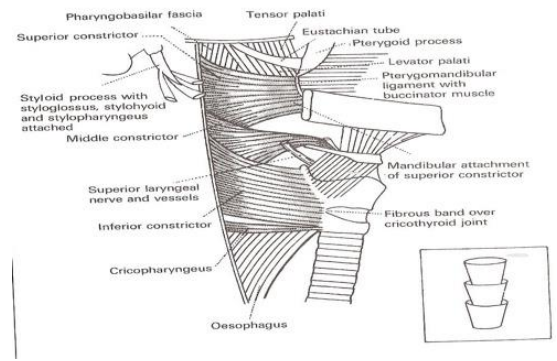
Salpingopharyngus

Palatopharyngus



Pharyngeal aponeurosis:

- ⊙ **Incomplete connective tissue coat in the lateral and posterior walls of the pharynx between the muscular layers, it gives the muscles and the wall of the pharynx more support and strength.**
- ⊙ **Pharyngobasilar fascia**



Buccopharyngeal fascia:

thin lamina, the buccopharyngeal fascia, which closely invests the constrictor muscles of the pharynx and is continued forward from the constrictor pharyngis superior onto the buccinator.

Relation of the pharynx:

Posteriorly:
prevertebral fascia.

Anteriorly:
Parapharyngeal space

Parapharyngeal space:

Potential space lies outside the pharynx
Triangular in cross section, it extends from the base of the skull above to the sup mediastinum and apex of hyoid bone, Its relation:

Anteromedial wall: buccopharyngeal fascia

Posteromedial wall: cervical vertebrae, prevertebral muscle and fascia

Lateral wall:

(up) the mandible, tergooid muscle, parotid gland

(Lower) sternomastoid muscle

-Styloid process separates the space into two Compartment:

Prestyloid:

internal maxillary artery, fat, inferior alveolar, lingual, and auriculotemporal nerves.

Post styloid: (More serious structures)

neurovascular bundle (carotid artery, internal jugular vein, sympathetic chain: CN IX, X and XI.

Abscess untreated in post styloid → carotid rupture, cranial nerve paralyse.

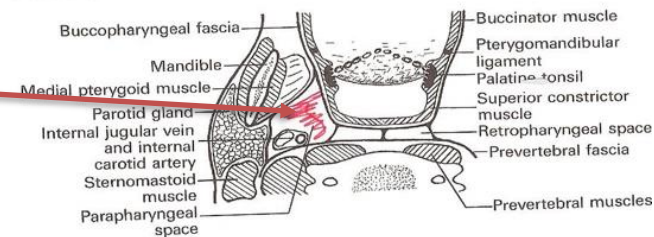
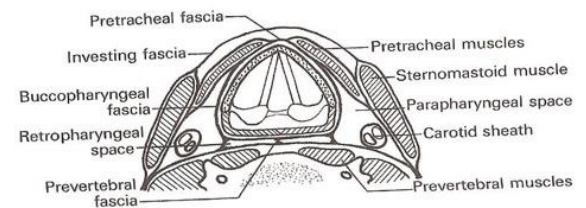
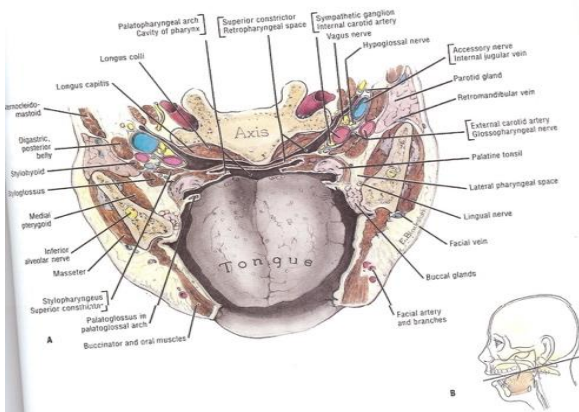


figure 11.6 Fascial compartments of neck at level of C2



- (if the patient has tonsillitis and on examination there is bulge in lateral pharyngeal wall, on CT there is poststyloid abscess so I have to
- do incision and drainage since this is a dangerous area, they could have carotid rupture.



Retropharyngeal space:

It extends from the base of skull to supra mediastinum

Lies behind the pharynx.

Ant: posterior pharyngeal wall and its covering buccopharyngeal fascia

Post: cervical vertebrae and muscles and fascia.

Contents:

Only retropharyngeal lymph nodes.

(If a child has tonsillitis and on examination you found a bulge in the posterior wall (in front of you) you do CT scan it is abscess, but if he is adult but without any acute infection, you think about TB).

Physiology

Case: Child with recurrent tonsillitis → its not immunity anymore, should be removed (tonsillectomy).

1-Functions of the sub epithelial lymphoid tissue: (Mainly immunity)

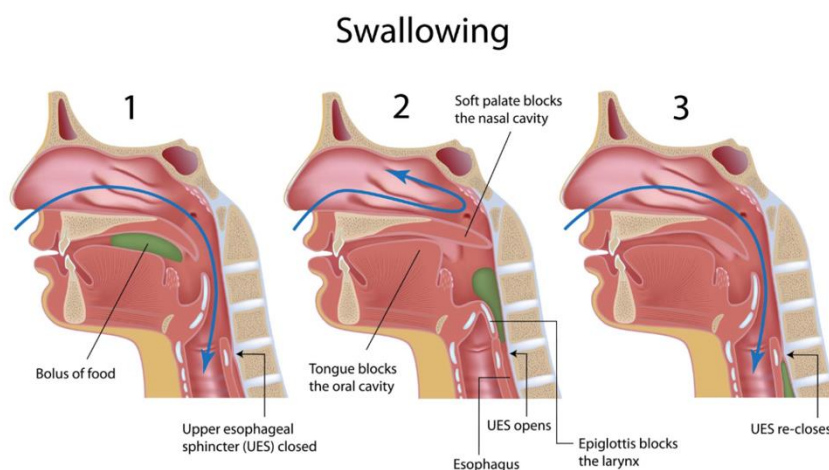
- ⊙ Protective functions:
 - Formation of lymphocytes
 - Formation of antibodies
 - Acquisition of immunity
 - Localization of infection

2-Salivation

3-Deglutition: (Swallowing)

- ⊙ Three stages
- ❖ **Oral stage:** voluntary (can still spell out the food), closure of mouth, cessation of respiration (Choking happen due to this), raising of larynx, sudden elevation of the tongue, press the tongue against the palate, and pushes it backwards towards the oropharynx
- ❖ **Pharyngeal stage:** reflex (can't spell the food), contraction of nasopharynx sphincter with soft palate closure to prevent food coming from the nose, larynx rises more, laryngeal inlet closure, epiglottis diverts the food into cricopharyngeal sphincter, contraction of constrictor muscles, relaxed cricopharyngeal sphincter.

-Children → Soft palate short, weak uvula → regurgitation.
-Esophageal sphincter spasm → Dysphagia, Choking → Relax by Botox or surgery



- ❖ Respiration
- ❖ Speech
- ❖ Resonating cavity
- ❖ Articulation
- ❖ Taste: taste buds

Radiotherapy to the neck → affect salivary gland (decreased saliva) patient will complain off difficulty in swallowing.

-Nerve Supply:

○ **Sensory:** Each of the three sections of the pharynx have a different innervation:
 The **nasopharynx** is innervated by the maxillary branch of the trigeminal nerve (CN V).
 The **oropharynx** by the glossopharyngeal nerve (CN IX).
 The **laryngopharynx** by the vagus nerve (CN X).

Motor: All the muscles of the pharynx are innervated by the vagus nerve (CN X), except for the stylopharyngeus, which is innervated by the glossopharyngeal nerve (CN IX).
 Also the Sympathetic fibers of the superior cervical ganglia play a role in the innervation.

-Blood supply:

Arterial from the external carotid artery:

- . Ascending pharyngeal
- . The lingual artery
- . The facial artery
- . The maxillary artery

Venous drainage to the internal jugular.

-Lymphatic's:

- Retropharyngeal nodes.
- Deep cervical (jugular) nodes.

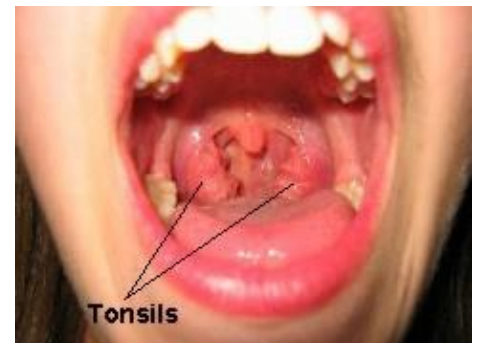Palatine tonsils

12-----15 crypt = small grooves,

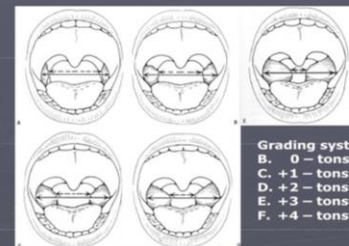
The deep surface is separated from the constrictor muscles of the pharynx by connective tissue(capsule)

why it's called palatine?? To differentiate it between lingual tonsils.
Clinical presentation: Halitosis, bad taste and white cheese like pieces from the mouth?? Food remnant stuck into these crypts.

When tonsillectomy is performed you have to make the incision in the connective tissue, if the surgeon goes more medially he will enter the tonsils, if more lateral he will enter the muscles.



Grading the Size of Tonsils



Grading system:
 B. 0 – tonsils in fossa
 C. +1 – tonsils less than 25%
 D. +2 – tonsils less than 50%
 E. +3 – tonsils less than 75%
 F. +4 – tonsils greater than 75%

Adenoid (Nasopharynx)

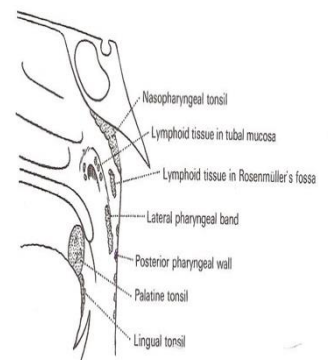
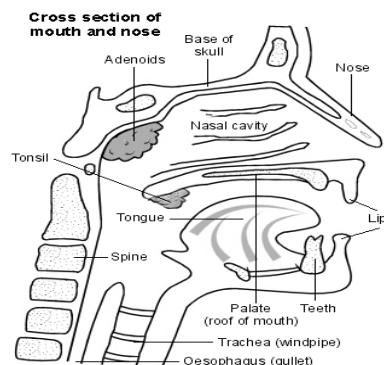
Recurrence of adenoid after adenoidectomy can happen due to the absence of capsule, unlike tonsils (Has capsule).

- ⊙ No capsule
- ⊙ Lingual tonsils
- ⊙ Tubal tonsils
- ⊙ Lateral pharyngeal bands
- ⊙ discrete nodules

Relation to pharynx:

Posteriorly: prevertebral fascia

Anteriorly: Parapharyngeal space



Summary

- **The pharynx is situated behind the nasal cavities, the mouth and the larynx. - It is divided into nasal, oral and laryngeal parts - It extends from base of the skull into the 6 cervical vertebra**
- **It is fibro muscular structure which is covered by mucus membrane and 4 layers and lymphatic tissue called (Waldeyer's ring)**
- **It has 3 external muscles and 3 internal muscles**
- **Killian's dehiscence is the weakest area where Zenker's diverticulum occur**
- **Para and retropharyngeal spaces are important for their relations to the pharynx and infection and abscess formation**
- **Function of the lymphatic tissue in the pharynx for protection by formation lymphocytes and antibodies**
- **Function of pharynx is salivation, Deglutition, respiration, speech, resonating cavity, articulation and taste.**

Adenoid

- A hypertrophy of the nasopharyngeal tonsil to produce symptoms.
- Most commonly between the age of 3---7 years.

Clinical features:

- Mouth breathing.
- Snoring.
- Hyponasality (loss of normal resonance associated with a clear nasopharynx).
- Adenoid face (long, open-mouthed, dumb-looking face of children with adenoid hypertrophy).
- Nasal discharge.
- Eustachian tube obstruction (can be due to enlarged adenoid).

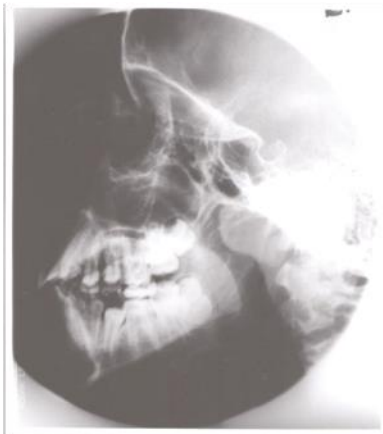Since ET is the ventilation to middle ear → after obstruction mucosa will secrete fluid →
OM with effusion, secretory OM, glue ear (DON'T WRITE OM ONLY!) → surgery (myringotomy ventilation tube)
indication, contra, complication (Exam Q's)

Pathological types:

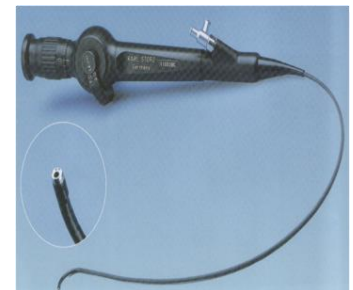
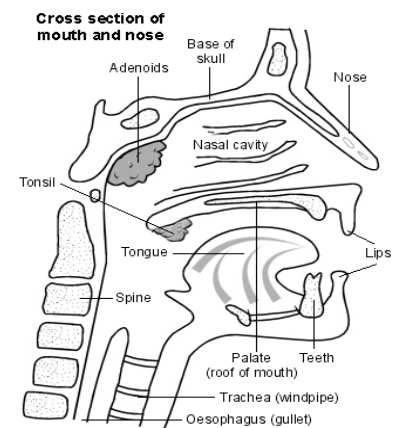
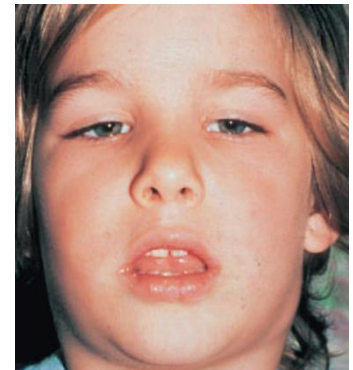
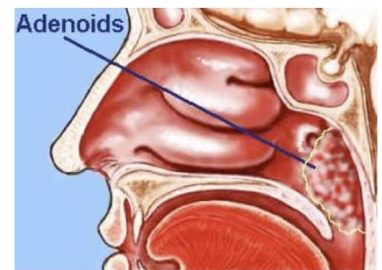
- Simple inflammatory
- Tuberculosis

Diagnosis:

- X-ray ((should be done with the neck extended in order to fully visualize the adenoid)
- Flexible fiber optic (now used instead of x-ray)



In the absence of fiber optic use x-ray.



-Examining the Adenoid:

By Fiber optic

(May come in the SAQ)

-Identify the device in the picture)

-Mention 2 indications:

1-Diagnostic (Exam nose, nasopharynx, Larynx, Pharynx, Biopsy be additional Port).

2-Therapeutic.

Main Adverse effects:

Nasal obstruction, pharyngitis (due to dry mouth), otitis media, rhino sinusitis, recurrent upper respiratory tract infections, and obstructive sleep apnea.

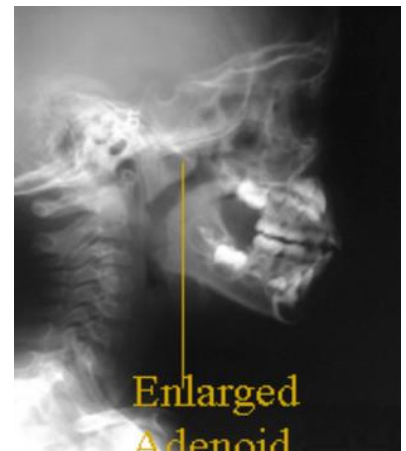
Using fiber optic, adenoid hypertrophy is graded based on the degree of obstruction:

- ✓ Grade 1: <25% obstruction
- ✓ Grade 2: 25-50% obstruction
- ✓ Grade 3: 50-75% obstruction
- ✓ Grade 4: 75-100% (complete obstruction)

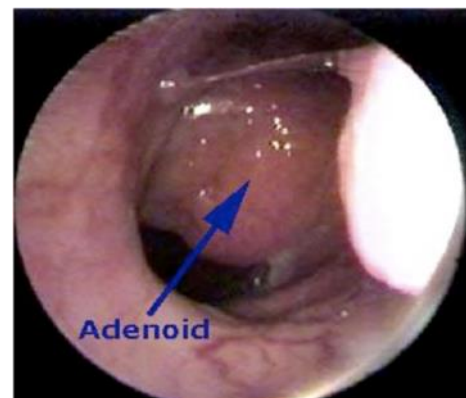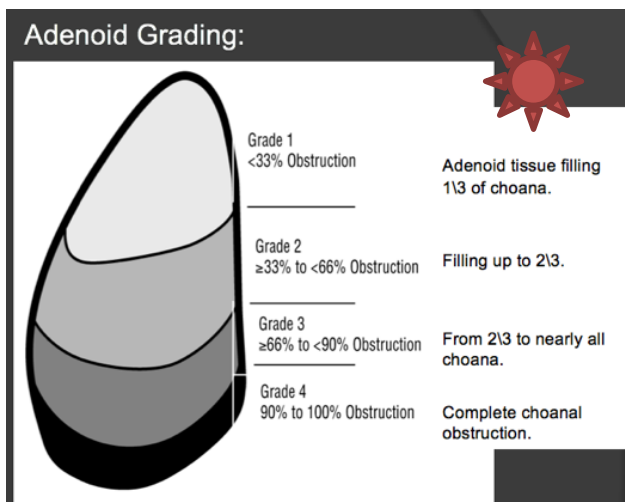
Treatment:

- Conservative
- Surgical: adenoidectomy

Snoring in children is not an indication for adenoidectomy unless its accompanied by obstructive sleep apnea. Adenoid enlargement in adults keep in mind NPC (nasopharyngeal carcinoma) OR TB → swollen neck mass.



lateral x ray shows enlarge adenoid showing grade 3 adenoid



Adenoidectomy at grade 3 & 4

➤ **430 teamwork**

○ **Treatment of adenoid:**

- ✓ **If small adenoid:** conservative steroidal nasal spray.
- ✓ **surgical:** adenoidectomy. Indications: recurrent/ persistent otitis media, recurrent/chronic sinusitis, and obstructive sleep apnea.

Adenoids are removed by inserting a catheter through the throat to retract the soft palate and visualize the adenoid. Then, the enlarged adenoid is removed using a curette or suction diathermy (heat).

Sleep apnea and snoring:

- Snoring is a sign of partial obstruction of the upper airway during sleep.
- Snoring is always present during type of sleep apnea.
- Sleep apnea: Cessation of airflow at the mouth and nostrils lasting 10 seconds for at least 30 apnoeic episodes.

Snoring in children is not an indication for adenoidectomy unless its accompanied by obstructive sleep apnea.

Case: Child with dyspnea during

Types:

- Central sleep apnea: Failure of respiratory drive from the brain
- Obstructive sleep apnea (OSA): Due to anatomical narrowing of the upper airway “For example: deviated nasal septum, large inferior turbinate, polyp, adenoid, large tongue, large tonsils and retrognathia (posterior positioning of the maxilla or mandible)”.
- Mixed

430 teamwork

- Types of sleep apnea:
 - ✓ Central sleep apnea: absent chest movement and should be treated by a neurologist.
 - ✓ Obstructive sleep apnea: the chest is moving.

Stage of sleep: (Not Mentioned by the doctor)

- Slow wave sleep:
 - Brain waves are slow deep restful sleep.
 - Decrease in vascular tone and respiratory rate and basal metabolic rate.
- Rapid eye movement: Brain quite active \ active dream

Pathophysiology of OSA:

- During REM or deep sleep, obstructive occurs resulting in decrease arterial oxygen and increased arterial carbon dioxide pressure
- Nocturnal desaturation arouses patient and causes increase pulmonary artery, systemic arterial pressure
- lead to hyper somnolence.

Investigation: (Not Mentioned by the doctor)

- Sleep study:
 - EEG, EKG, EOG, pulse oximeter, respiration rate, nasal and oral air flow.

Treatment:

- Nonsurgical:
 - Behavior modification: **weight reduction and avoid alcohol at night.**
 - Medical treatment
 - For uncomplicated snoring, various devices improve the caliber of the nasal airway or splint the jaw forward to improve the pharyngeal airway.**
 - CPAP (continuous positive airway pressure).

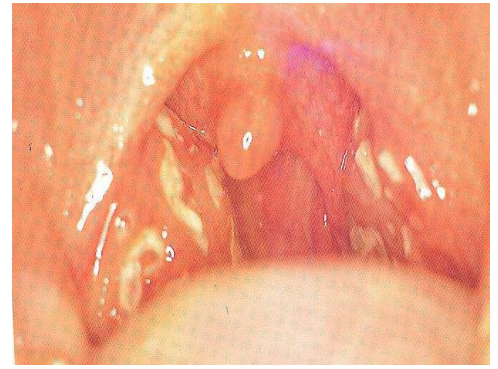
- Surgical:

UPPP (Uvulopalatopharyngoplasty): a procedure that is done when the soft palate is redundant or if big tonsils or adenoids are present.

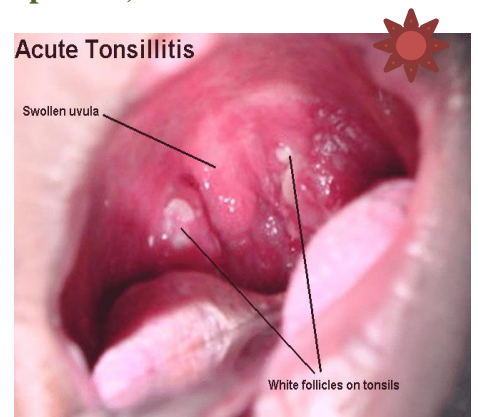
Acute infection of oropharynx

1-Acute tonsillitis:

- **Causes:** viral followed by bacterial (group AB-hemolytic streptococcus, Moraxella, H. influenza, bactericides).
- **SSX:** fever, sore throat, odynophagia, trismus, halitosis (case with these symptoms)
- **Phases:** erythema, exudative, follicular tonsillitis (gross picture)



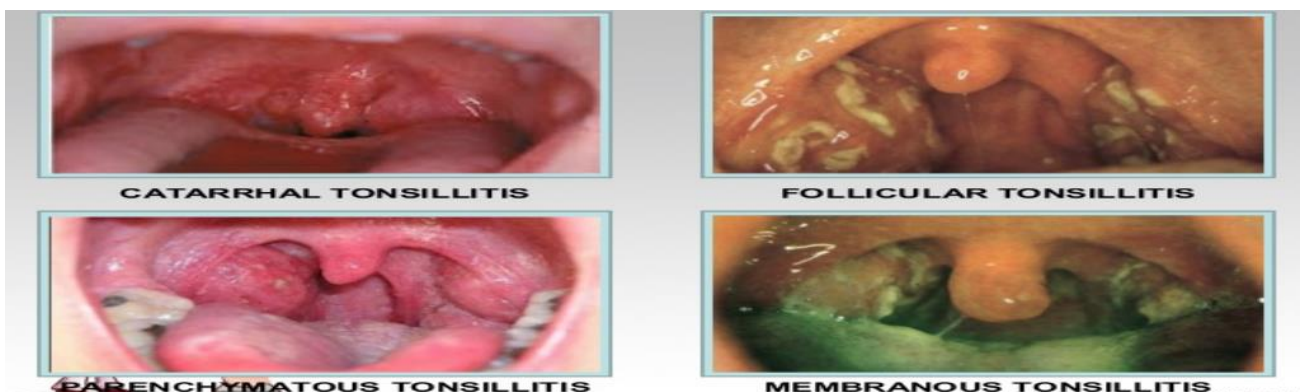➤ **Complication:** (if not treated well)
peritonsillar abscess, parapharyngeal or retropharyngeal abscess, rheumatic fever (we are afraid the most from it), glomerulonephritis (bacteria attack heart valve).



- **Rx:**
-Oral antibiotics (penicillin), bed rest, hydration, analgesia.

-If the symptoms are severe: admit the patient and give IV fluids, IV antibiotics and analgesia.

-The Centor criteria (not accurate) to diagnose and treat GAS pharyngitis. These include the following (A score of 0-1 makes GAS infection unlikely; a score of 4 makes it likely): Fever, Anterior cervical lymphadenopathy, Tonsillar exudate, Absence of cough.



2-Infectious mononucleosis

Pathogen: Epstein Barr virus (Adolescents are especially susceptible (kissing disease)).

SSX: membrane on tonsils (membranous tonsillitis), fever, bilateral lymphadenopathy (as a hint) malaise, exudative tonsillitis, hepatosplenomegaly (hint)

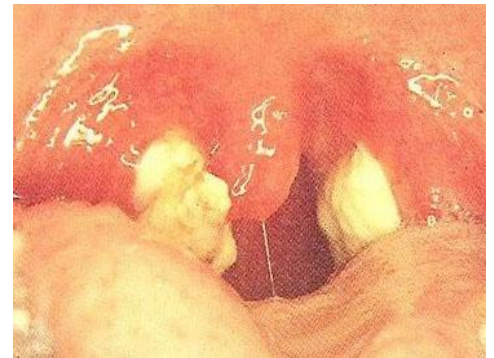
DX:

Monosopt test, paul bunnell test (heterophil antibodies in serum)
80% mononuclear and 10% atypical lymphocytes on smear.
CBC shows a higher count of lymphocytes than neutrophils.

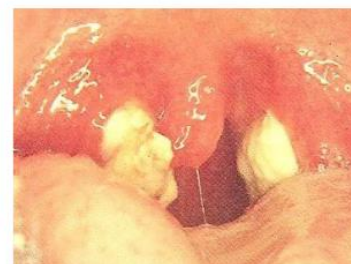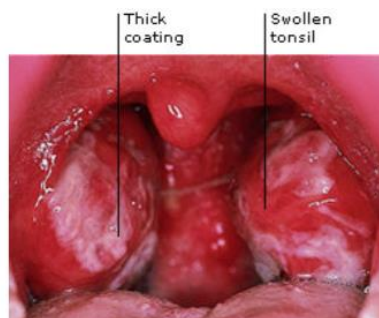
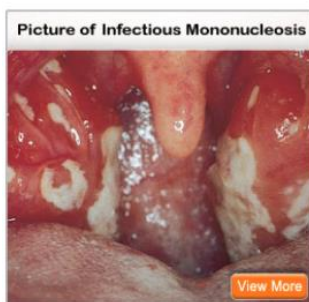Complication: cranial nerves involvement, meningitis, autoimmune hemolytic anemia, splenic rupture (activity restriction may be necessary to prevent splenic rupture in patients with splenic enlargement).

RX: hydration, analgesia oral hygiene, Steroid (in severe cases) avoid ampicillin.

Differential diagnosis: Diphtheria (grey membranes on tonsils).



No follicles, only white membrane. (to differentiate)



3-Scarlet fever:

- Endotoxin produced by by type A B-hemolytic streptococcus.
- Scarlet fever (known as scarlatina in older literature references) is a syndrome characterized by exudative pharyngitis, fever, and bright-red exanthema (rash).

SSX:

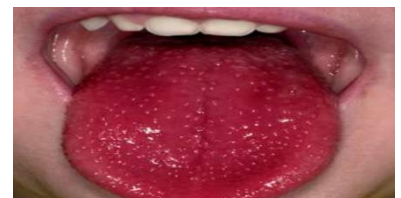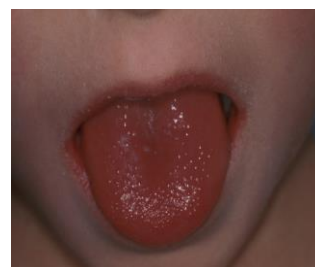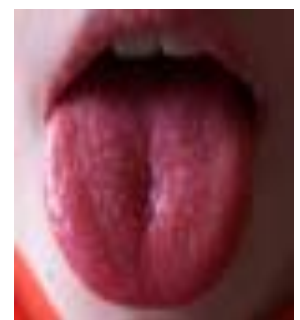
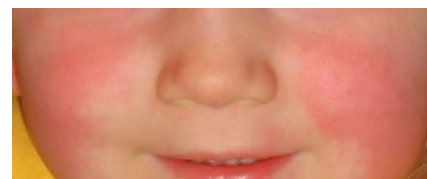Red pharynx, strawberry tongue, perioral skin erythema and desquamation, dysphagia, malaise, sever cervical lymphadenopathy

DX

- dick test

RX:

- ABX (Penicillin or Amoxicillin)



Picture may come

4-Diphtheria

Corynebacterium diphtheria, the incidence fallen markedly because of immunization.

SSX:

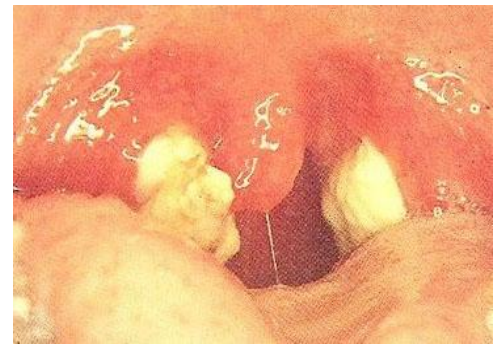- Local manifestation: sore throat, fever, green plaques friable membrane.
- Characterized by a grey membrane (difficult to remove) on tonsils, fauces, and uvula, which bleeds on scraping.
- Systemic symptoms due to the exotoxins: Toxemia, Mild fever, Tachycardia and Paralysis. [SEP]

DX: culture

Complication: Myocarditis nephritis, airway obstruction, death

RX: ABX (penicillin or erythromycin), antitoxin.

Diphtheria antitoxin is a horse-derived hyper immune antiserum that neutralizes circulating toxin prior to its entry into the cells.



No follicles, only white membrane. (to differentiate) Similar to EBV

5-Vincent's angina:

- Acute ulcerative lesion
- Gram negative fusiform bacillus and a spirillum with anaerobic

SSX:

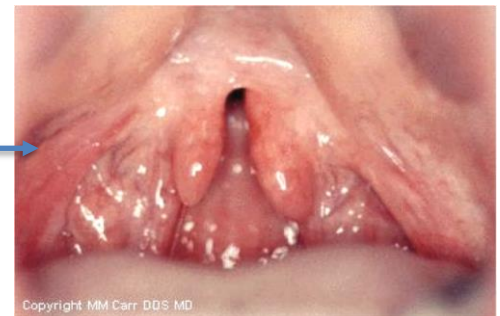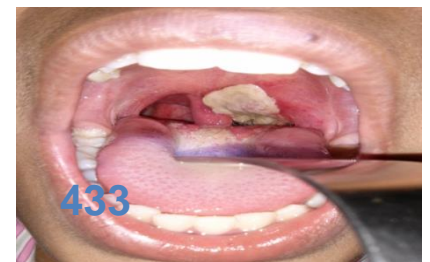Sudden in onset, pain, fever, cervical adenitis, the base of the deep ulcers bleeds when the membranous slough is removed, the symptoms subside in 4–7 days.

RX: metronidazole, antiseptic, mouthwash

Severe mouth pain, severe ulcer caused by gram negative, fever, cervical lymphadenopathy.

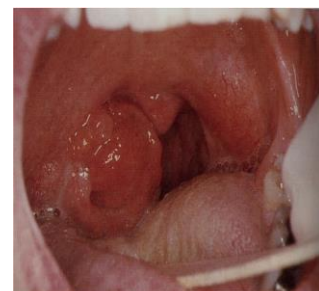
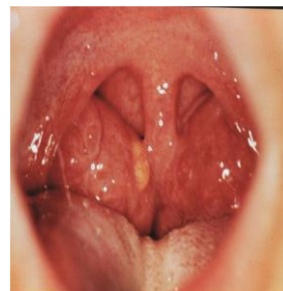RX:

Anti bacterial ABX (metronidazole= flagyl)



Copyright MM Carr, DDS MD

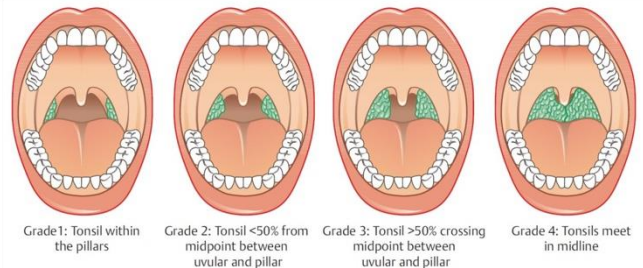
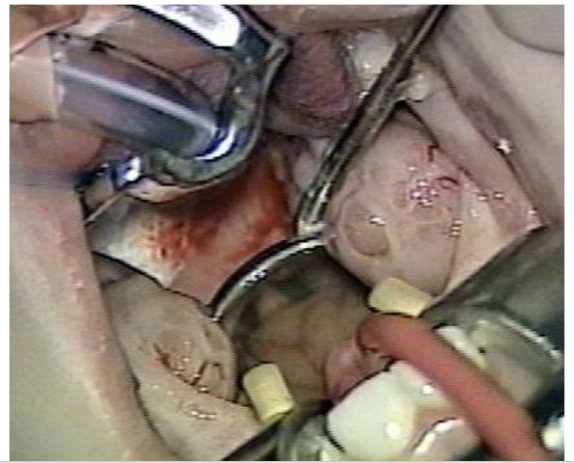
Water coming from nose, Hyper nasality speech after adenoidectomy?? Missed bifid uvula OR sub mucosal cleft when examining the throat before → both are contraindication for adenoidectomy. If palate is not fully adequate (bifid uvula OR sub mucosal cleft) we do partial adenoidectomy: removing the upper part of the **adenoid** for relief of nasal obstruction while leaving the lower portion of the **adenoid** intact to ensure velopharyngeal competence.



tonsillectomy

Indications:

- Recurrent tonsillitis
 - 6 Attacks for 1 year
 - 4 attacks per year for 2 years
 - 3 attacks per year for 3 years
- Malignancy suspicion (Old man, Heavy smoker with enlarged solitary tonsil.
- Hypertrophied tonsil causing obstructive sleep apnea, using the Grading
- **Quinsy**, also known as a **peritonsillar abscess** (Case: Worsening of the symptoms of tonsillitis after taking the Abx, New symptoms: trismus, can't open the mouth, muffled voice (hot potato voice)
Rx: incision, drainage, Abx, secure airway.
Tonsillectomy after 6 weeks.



Kissing Tonsils (Grade 4): touching or overlapping the uvula or **kissing** each other.

Complication of adenotonsillectomy:

- ⊙ Hemorrhage
 - Primary
 - Reactionary.
 - Secondary
- ⊙ Respiratory obstruction
- ⊙ Injury to near-by structures (Tonsillar artery, Teeth, Tongue)

Pulmonary and distant infections

Primary:

- Bleeding occurring during the surgery
- Causes
 - Bleeding tendency
 - Acute infections
 - Bad technique
- Management
 - General supportive measures
 - Diathermy, ligature or stitches
 - Packing

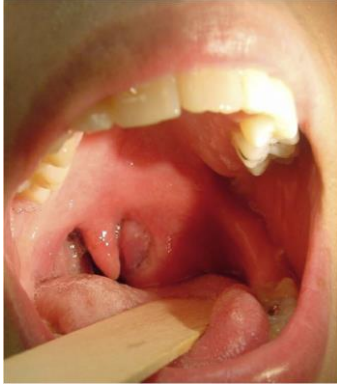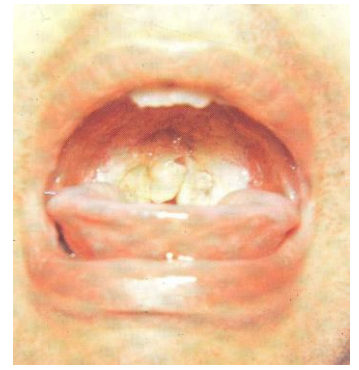
Secondary:

- Occur 5-10 days postoperatively
- Due to infection
- Treated by antibiotics
- May need diathermy or packing
- Treatment
 - General supportive measures
 - Take patient back to OR
 - Control like reactionary hemorrhage

Reactionary:

- Bleeding occurring within the first 24 hours' postoperative period
- Causes
 - Bleeding tendency
 - Slipped ligature
- Diagnosis
 - Rising pulse & dropping blood pressure
 - Rattle breathing
 - Blood trickling from the mouth
 - Frequent swallowing
 - Examination

post tonsillectomy slough tissue will replace tonsils, this slough tissue will be removed normally during eating and swallowing → Normal recovery.
 If the patient is not eating will → Accumulation of the tissue → good media for bacteria → Cause bleeding.

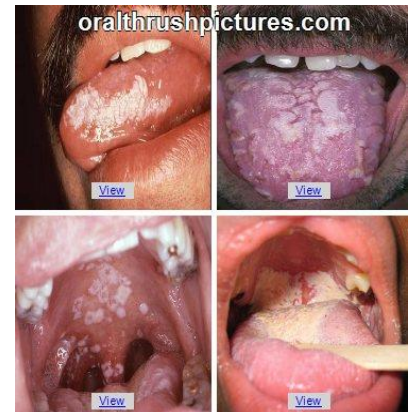

Absence of one tonsil (Right)

6-Monoliasis

- White patches caused by candida albicans fungus.
- In bronchial asthma patients (using inhaled steroids) or immunocompromised patients.
- like patients on renal dialysis

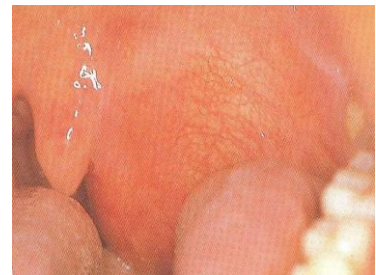
RX: nystatin (antifungal) Fluconazole



7- Peritonsillar abscess (quinsy):

- An abscess between the tonsil capsule and the adjacent lateral pharyngeal wall

SSX: fever, otalgia odynophagia, uvular deviation, trismus (stiff jaw), drooling of saliva, hot potato voice, the patient, already suffering from tonsillitis, becomes more ill, has a peak of temperature and develops severe dysphagia with referred otalgia. On examination, a most striking and constant.



Complication:

- Para and retropharyngeal abscess (moving abscess),
- aspiration pneumonia

Rx:

- I&D
- aspiration
- Iv ABX

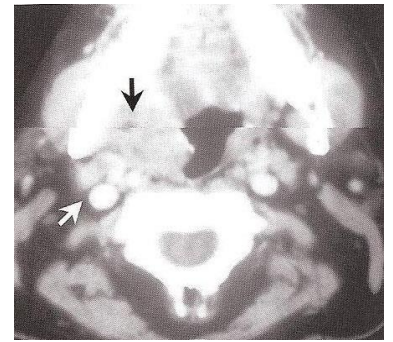
8- Parapharyngeal abscess Complication of Peritonsillar abscess

Source of the infection:

- odontogenic (from tooth), tonsils, parotid.

SSX:

- trismus, fever, muffled voices , intraoral bulge, neck swelling, Bulging in the lateral posterior pharyngeal wall (when examining the oral cavity→ CT).



CT Scan

Complication:

- aspiration, cranial nerve palsy, airway compromise, septic thrombophlebitis, carotid blowout
- , endocarditis

RX:

- external drainage, iv ABX, Secure airway.

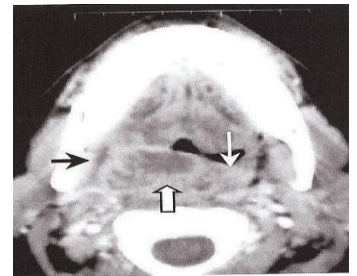
Investigations: Laboratory and bacteriology / CT (best modality) / MRI

9-Retropharyngeal Abscess Complication of Peritonsillar abscess

- More common in children who have tonsillitis for few days

SSX:

- odynophagia, hot potato voice, drooling, stiff neck fever, stridor, Bulging in the lateral posterior pharyngeal wall (when examining the oral cavity→ CT).



Complication:

- mediastinitis, respiratory distress, rupture abscess.

RX:

- Internally drainage, IV ABX, intubate (secure airway)

10-Ludwig's angina

- Bilateral cellulitis of submandibular (below the tongue) and sublingual spaces due to previous abscess.

SSX:

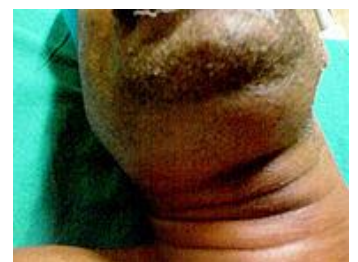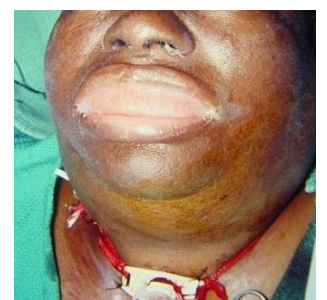- wooden floor of the mouth (key to know its ludwig's), neck swelling and indurations , drooling, abscess pushes the tongue upwards -> blocks airway -> respiratory distress ,swollen tongue ,dysphagia trismus.

Complication:

- airway distress , sepsis

Rx:

- Secure airway by tracheotomy ,external drainage IV ABX



-Indication of tracheostomy: Ludwig's angina.

11-Chronic pharyngitis

Pathogenesis:

- postnasal drip; halitosis (chronic sinusitis, Allergic rhinitis), irritant (dust. Dry heat, smoking, alcohol), reflux esophagitis chronic mouth breathing ,allergy granulomatous disease connective tissue disease , malignancy.

SSX:

- constant mouth clearing , dry throat pharyngeal crusting (usually after waking up), thick granular wall.

RX:

- address underlying etiology .

-DDX for halitosis:

Tooth decay.

Reflux.

White tonsil debris.

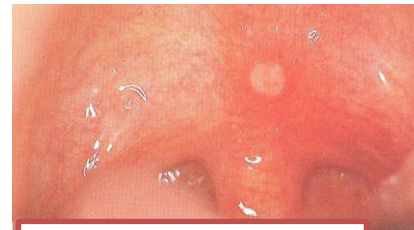Not brushing the tongue.

Post nasal drip.

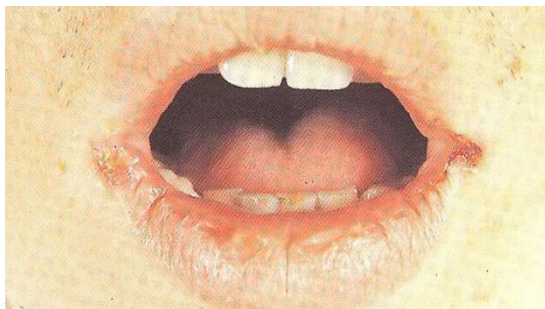
-Management: CT for etiology

12-Apthous ulcer

Etiology: Unknown but could be viral, food type.



Will come in the exam



Angular Stomatitis:
Iron deficiency anemia

13- Zanker's diverticulum

- Herniation of the mucosa at Killian's triangle due to increased intraluminal pressure

SSX:

- dysphagia, regurgitation of undigested food aspiration

DX: barium swallow.

RX:

- Cricopharyngeal myotomy (upper sphincter of esophagus)
- Diverticulectomy

