



# Nose I - IV

**Done by : Rana AlJunidel & Noura almofarej**

**Reviewed by : Hadeel B. Alsulami**

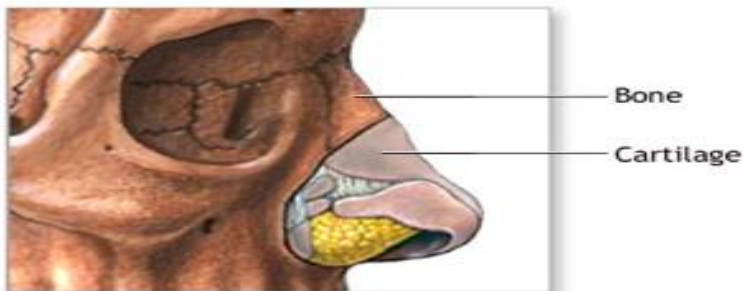
**Correction File**

**Color Index : Slides - Important Notes - Doctors' Notes - EXTRA – 433 team**

## ANATOMY OF THE NOSE:

- The nose consists of the external nose and the nasal cavity.
- Both are divided by a septum into right and left halves.

### 1\ External Nose



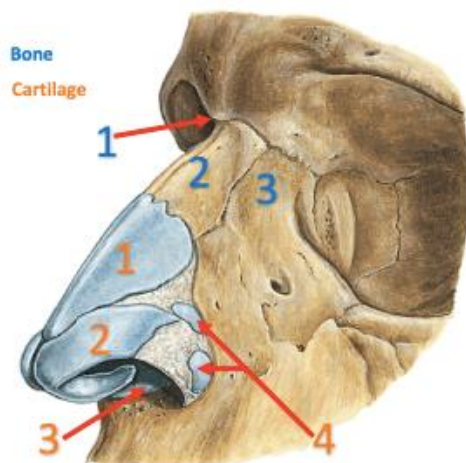
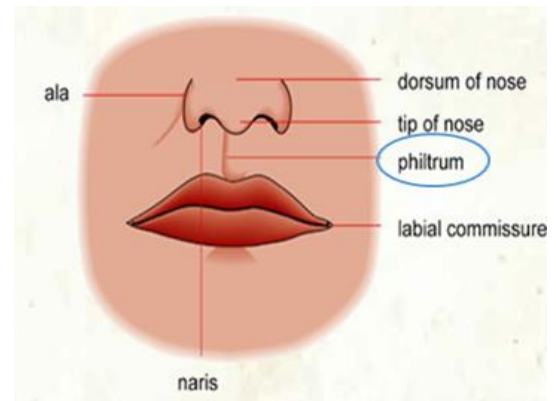
The external nose has two elliptical orifices called the naris (nostrils), which are separated from each other by the nasal septum.

The lateral margin, the ala nasi, is rounded and mobile.

#### Note:

**In facial nerve palsy** > affect part of the nose compared to the unaffected side. Due to paralysis of external muscles of the nose.

**Nasal flaring:** in respiratory distress to aid in respiration



#### A\ Structures:

##### -The Nasal Pyramid:

###### Bony constituents:

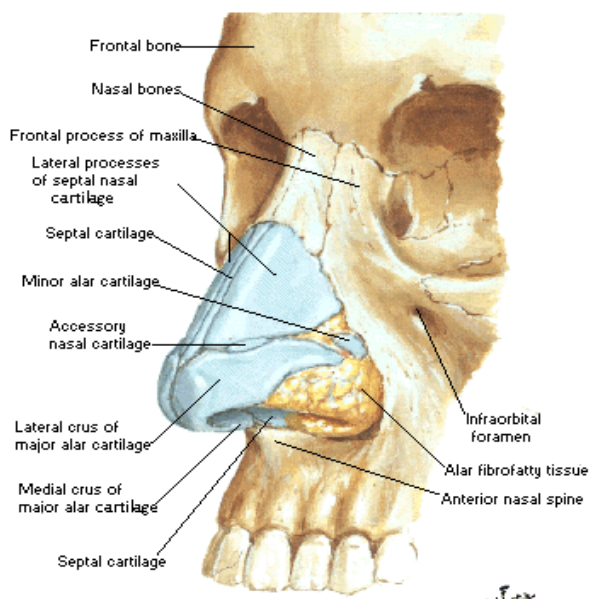
Support the upper part of the external nose:

- 1.Nasal processes of the frontal bones.
- 2.Nasal bones.
- 3.Ascending processes of the maxillae.

###### Cartilaginous constituents: ( hyaline cartilage )

Support the lower part of the external nose:

- 1.Upper lateral cartilages.
- 2.Lower nasal cartilages.
- 3.Quadrilateral cartilages of nasal septum.
- 4.Alar cartilages



#### - Skin

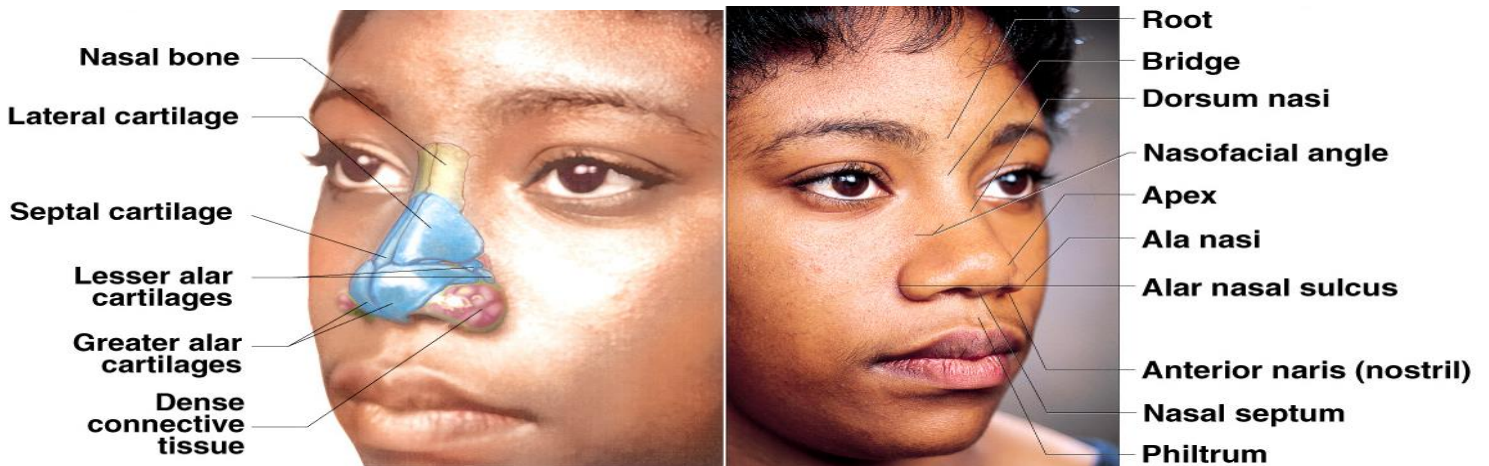##### -Anterior nares (Nostrils):

Situated in the base of the nose and open downwards, they are separated by (columella), a strip of skin, connective tissue and medial crura of the lower lateral cartilage.

Inside the aperture of the nostril is a slight dilatation, the vestibule. It is lined by skin containing hairs and sebaceous glands, and extends as a small recess toward the apex of the nose.

The framework of the external nose is made up above by the nasal bones, the frontal processes of the maxillae, and the nasal part of the frontal bone. Below, the framework is formed of plates of hyaline cartilage.

Note: The nasion is the midline bony depression between eyes where the frontal and two nasal bones meet. Lower nasal cartilage makes the shape of the nose (e.g. flat, long or straight).



**B\ MUSCLES:**

**Nerve supply:** they are all supplied by branches of **facial nerve**.

**Arterial supply:** all supplied by maxillary and facial arteries.

- Procerous elevate the skin of dorsum
- Nasalis compressor of naris
- Dilators naris
- Depressor septi

**C\Blood Supply of the External Nose:**

The skin of the external nose is supplied by **branches of the ophthalmic and the maxillary arteries**.

The skin of the ala and the lower part of the septum are supplied by branches from the facial artery.

**D\Nerve Supply of the External Nose:**

The infratrochlear and external nasal branches of the ophthalmic nerve (CN V) and the infraorbital branch of the maxillary nerve (CN V).

## Nasal Cavity:

The nasal cavity has a floor, a roof, a lateral wall, a medial or septal wall, and extends from the nostrils anteriorly to the choanae posteriorly. The right and left nasal fossae (cavities) are separated by the nasal septum. The nasal fossae are lined with mucous membranes.

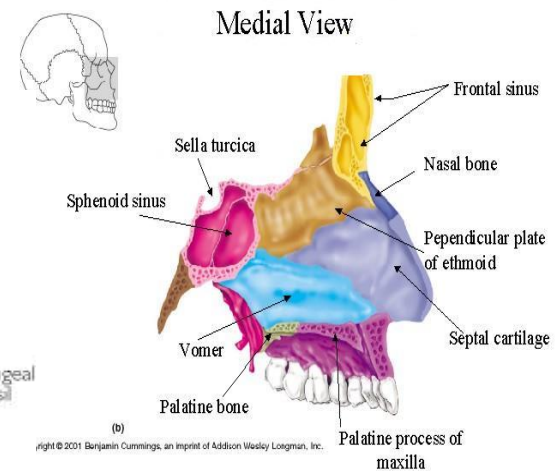
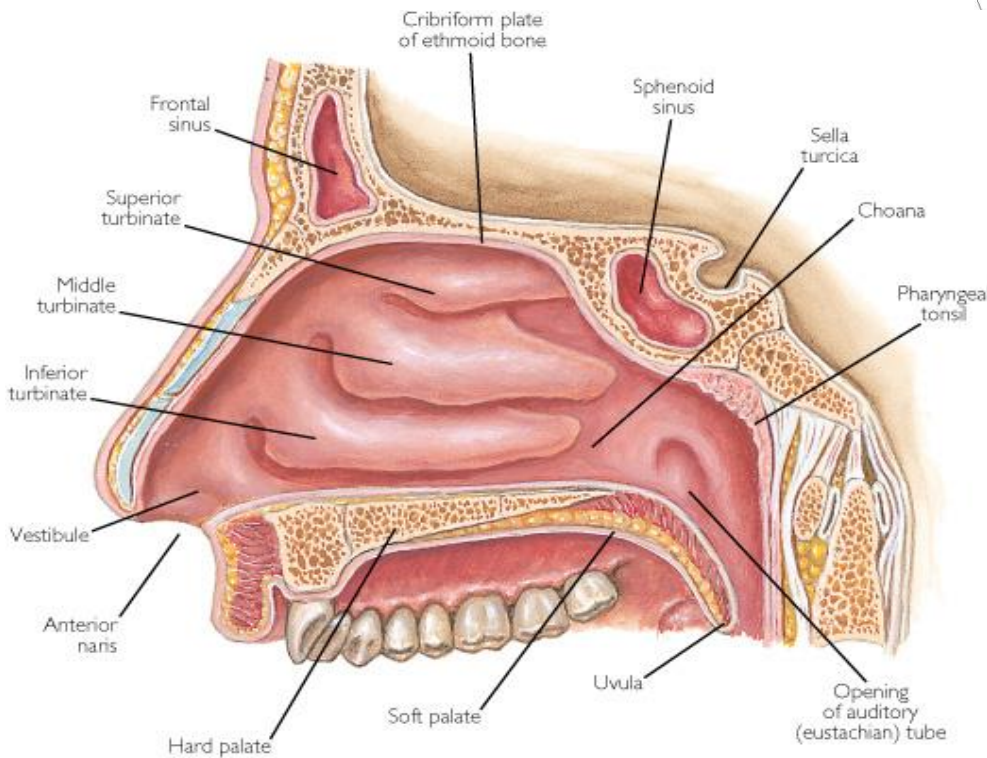
Each fossa communicates with:

1. The paranasal sinuses, through their **Ostia**.
2. The nasopharynx, through the posterior **choanae**.

## Boundaries of nasal cavity :

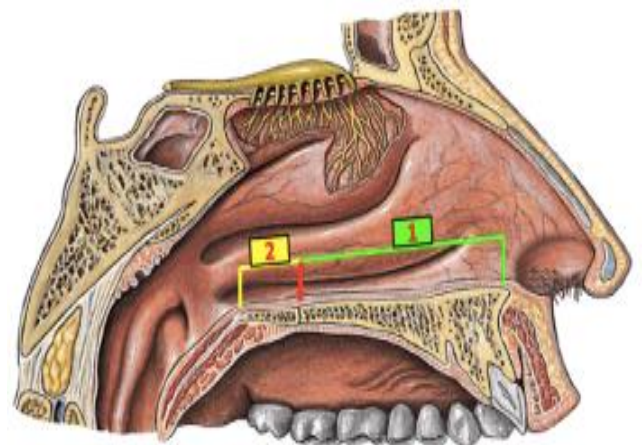
### The Roof:

- Narrow, It is formed
  - anteriorly beneath the bridge of the nose by the nasal and frontal bones,
  - in the middle by the cribriform plate of the ethmoid, located beneath the anterior cranial fossa,
  - Formed posteriorly by the downward sloping body of the sphenoid



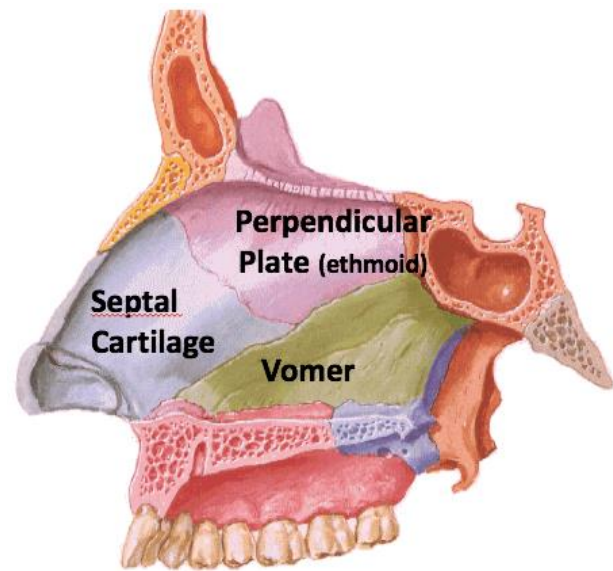
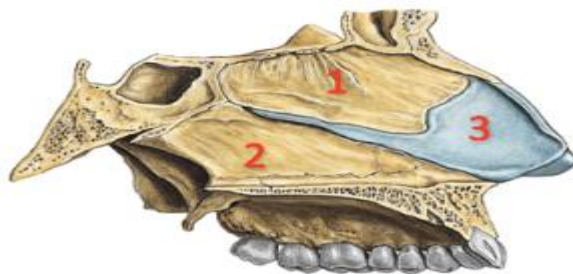
### The Floor of Nasal Cavity: 2 hard bones

- Palatine process maxilla (anterior 3 quarters)
- Horizontal plate palatine bone (posterior quarter)



## The Medial Wall of Nasal Cavity: (The Nasal Septum)

- Divides the nasal cavity into right and left halves
- It has osseous and cartilaginous parts
- Nasal septum consists of the
  - 1-perpendicular plate of the ethmoid bone (superior) **connected to brain (skull based fracture)**
  - 2-the vomer (inferior)
  - 3-septal cartilage (anterior)



## The Lateral Walls of Nasal Cavity:

### -In neonate

- The nasal & orbital floors are located at the same level
- **Lateral nasal wall serves as the medial orbital wall**
- Maxilla, contributes minimally in fetus & neonate

### -In adult

- Only the upper half of the lateral nasal wall forms the medial orbital wall
- **The nasal floor is at lower level than orbital floor**

•The medial surface of the maxilla is incomplete (maxillary hiatus) => the aperture of the hiatus is reduced by presence of palatine and lacrimal bones and the inferior concha.

The lateral wall is Marked by 3 projections: Turbinates (conchae or **قرنيه**): three bony elevations covered by mucus membranes

- Superior concha
- Middle concha
- Inferior concha

The space below each concha is called a meatus and each meatus receive the opening of a paranasal sinus as follows:

### • 1-Inferior meatus:

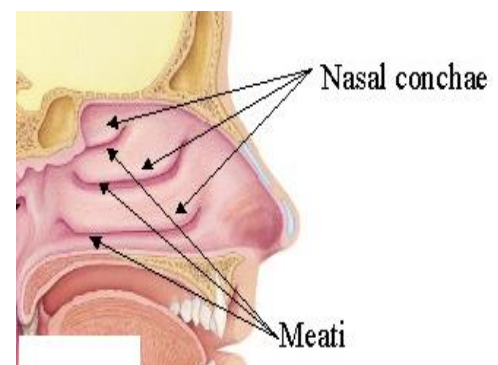
The inferior meatus **runs the length of the lateral wall**. Receives the nasal opening of the **nasolacrimal duct**.

### • 2-Middle meatus:

Occupies the **posterior two thirds of the lateral wall**, it is the most complex and by far the most important.

The ostia of **maxillary, anterior ethmoidal, and frontal sinuses open into it**.

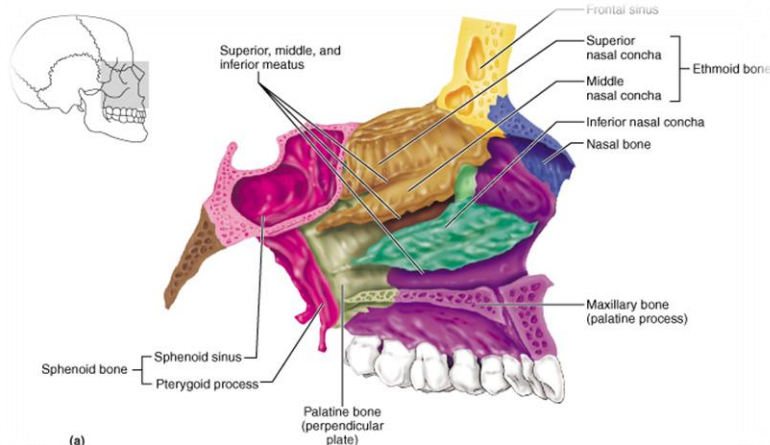
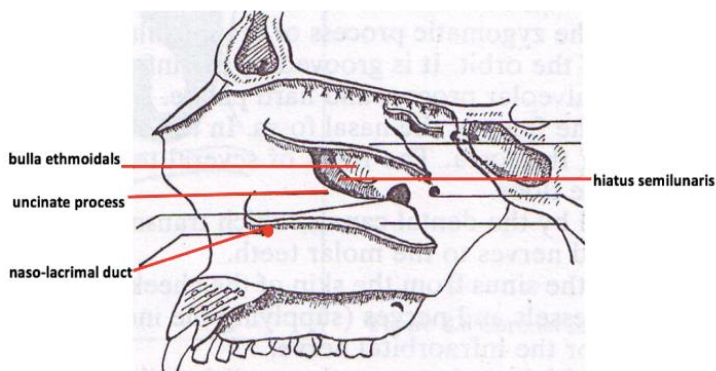
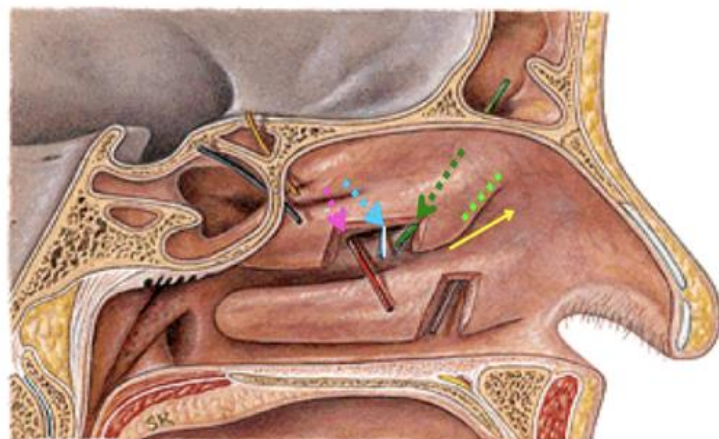
-The atrium is forward continuation of middle meatus.



-The agger nasi is curved ridge lying above the atrium.

The **bullae ethmoidalis** is a smooth rounded mass formed by anterior ethmoidal cells, the ostia of these cells open on to the bulla.

The **hiatus semilunaris** lies below and in front of bulla. It is bounded below by uncinat process of ethmoid. The anterior end of the hiatus leads to a funnel-shaped channel called the infundibulum, which is continuous with the frontal sinus. The maxillary sinus opens through the hiatus semilunaris.



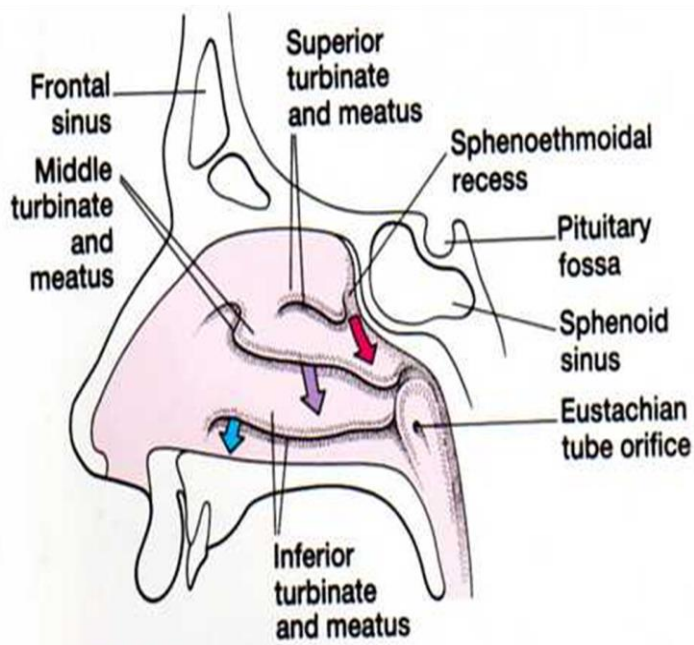
Note : Agger nasi is the most anterior cell in the anterior ethmoid. When agger nasi enlarge they cause obstruction leading to sinusitis. \*Bulla ethmoidalis is the largest cell of the anterior ethmoid. It is adjacent to the maxillary sinus. And one of the good landmarks during surgeries.

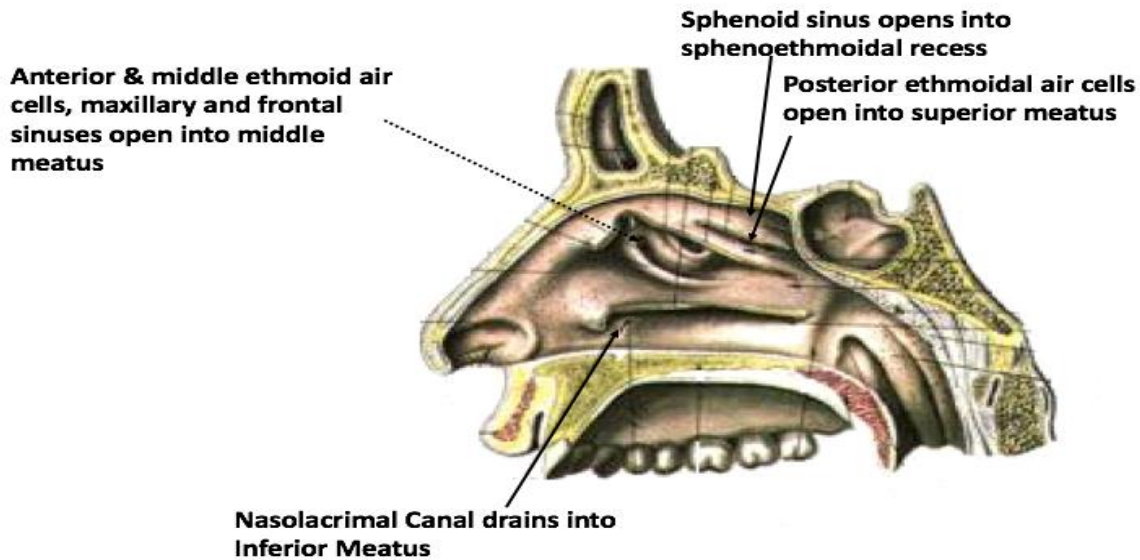
### 3-Superior meatus:

Occupies the posterior third of the lateral wall. Contains the ostia of posterior ethmoidal sinus.

### 4-Sphenoethmoidal recess:

Lies above the superior turbinate and receives the ostium of sphenoidal sinus.





### ➤ Mucosal Lining of nasal cavity:

- **Modified Skin:** Keratinized stratified squamous epithelium covering the vestibule. It contains sebaceous glands, sweat glands, and short, curved hair called vibrissae.
- **Olfactory:** Specialized olfactory epithelium. Present in the olfactory cleft, which occupies the area between the superior turbinate, cribriform plate, and the corresponding area of the septum.

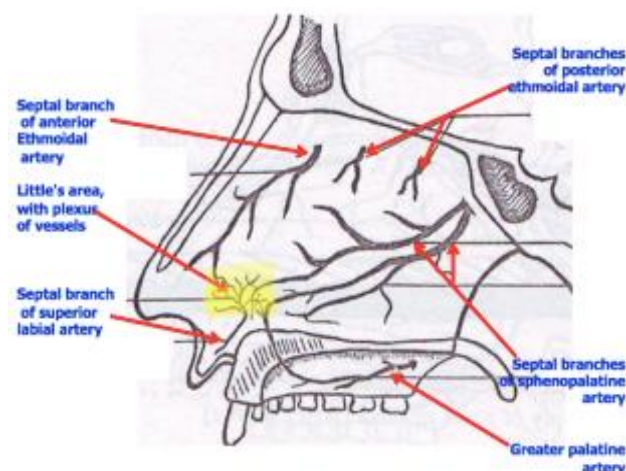
Note: Olfactory epithelium is in the upper part of the nose. When removing polyps on the upper part you have to be cautious not to injure the olfactory epithelium.  
 - One of the complications of sinus surgery is losing smell.

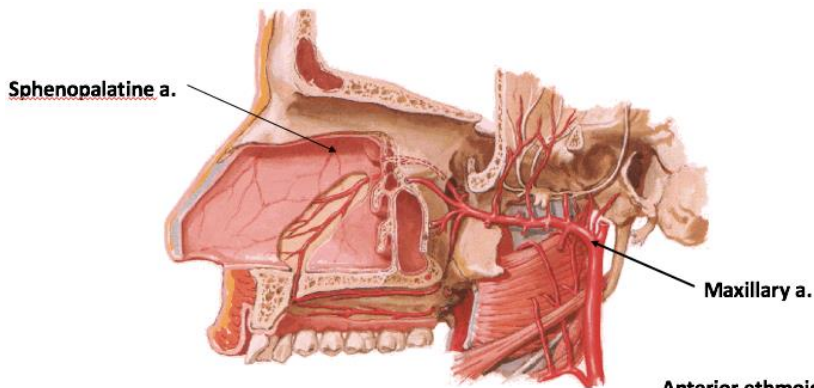
- **Respiratory mucosa:** **Ciliated pseudostratified columnar epithelium with goblet cells.** It lines the lower two-thirds of the nasal septum, the lateral wall of the nose below the superior turbinate, and the floor of the nasal cavity. It extends into the sinuses through their Ostia and is thinner there. It is also continuous with the epithelia of the nasolacrimal duct and Eustachian tube.

### Blood Supply to the Nasal Cavity:

The nasal fossae and paranasal sinuses are supplied by branches of the external and internal carotid arteries:

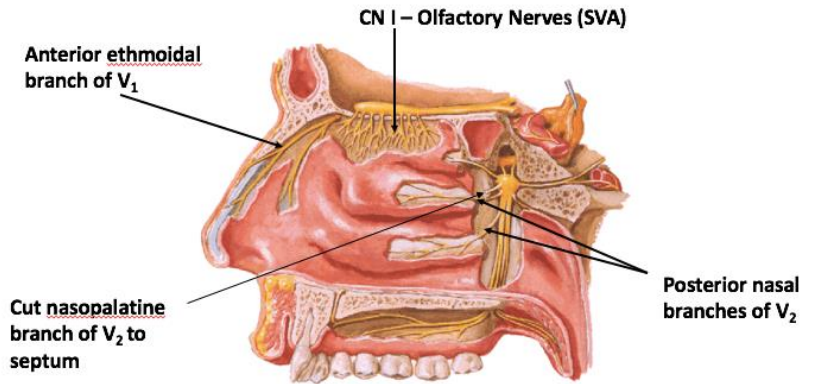
- From branches of the maxillary artery, one of the terminal branches of the external carotid artery.
- The sphenopalatine artery anastomoses with the septal branch of the superior labial branch of the facial artery in the region of the vestibule. (The most important branch is the sphenopalatine artery)
- **Kiesselbach's plexus, in Little's area (most common site for epistaxis).**
- The submucous venous plexus is drained by veins that accompany the arteries.





**Nerve Supply of the Nasal Cavity:**

- The olfactory nerves from the olfactory mucous membrane ascend through the cribriform plate of the ethmoid bone to the olfactory bulbs .
- The nerves of ordinary sensation are branches of the ophthalmic division (V1) and the maxillary division (V2) of the trigeminal nerve.



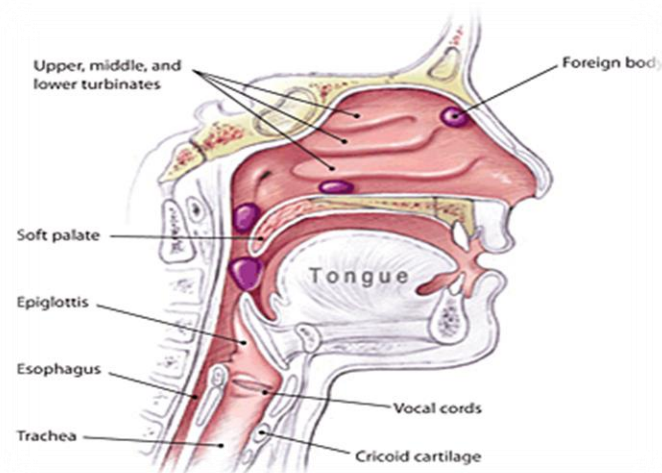
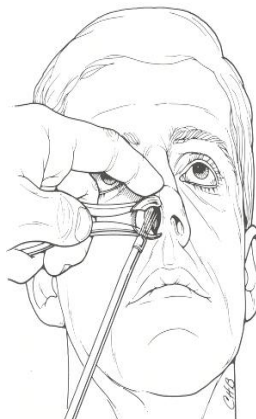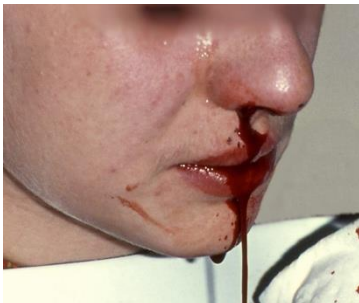**Lymph Drainage of the Nasal Cavity:**

- The lymph vessels draining the vestibule end in the submandibular nodes.
- The remainder of the nasal cavity is drained by vessels that pass to the upper deep cervical nodes.

Note:  
 - Most common cause of epistaxis is nasal dryness  
 - most common site for epistaxis is Little's area  
 - they are valveless so they can go intrograde or retrograde —> infections can spread to the brain

**Clinical Notes:**

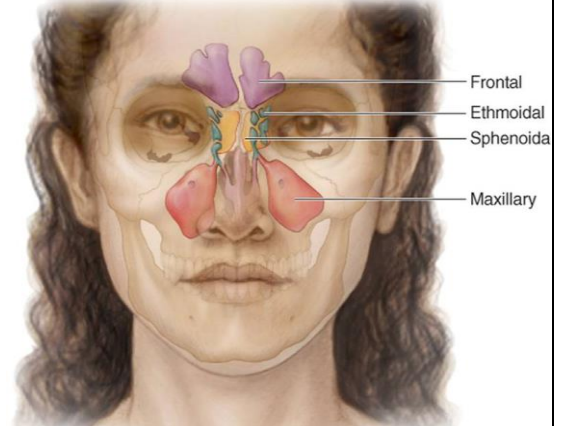
- Examination of the Nasal Cavity
- Trauma to the Nose
- Infection of the Nasal Cavity
- Foreign Bodies in the Nose (any foreign body should be remove as quickly as possible but if battery right away!! If not alkaline causes distraction of tissue most common septal proliferation)
- Nose Bleeding (Epistaxis)





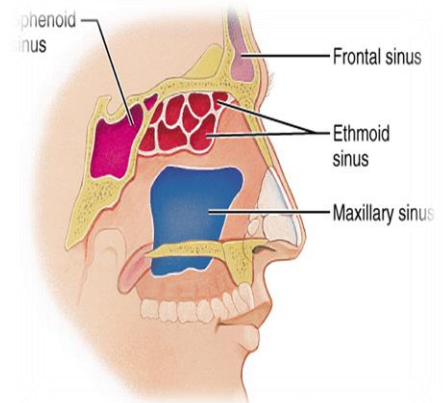
## The Paranasal Sinuses

- The paranasal sinuses are cavities found in the interior of the maxilla, frontal, sphenoid, and ethmoid bones .
- They are lined with mucoperiosteum and filled with air.
- They communicate with the nasal cavity through relatively small apertures.



### Drainage of Mucus and Function of Paranasal Sinuses:

- They drain into an ostium than into their drainage openings in the meatuses
- The mucus produced by the mucous membrane is moved into the nose by ciliary action of the columnar cells.
- Drainage of the mucus is also achieved by the siphon action created during the blowing of the nose.



### ➤ Functions of the PNS:

- Humidifying and warming the inspired air
- Regulation of intranasal pressure.
- Increasing surface area for olfaction.
- Lightening the skull.
- Adding resonant effect to voice.
- Absorbing shock.
- Contributing to facial growth.

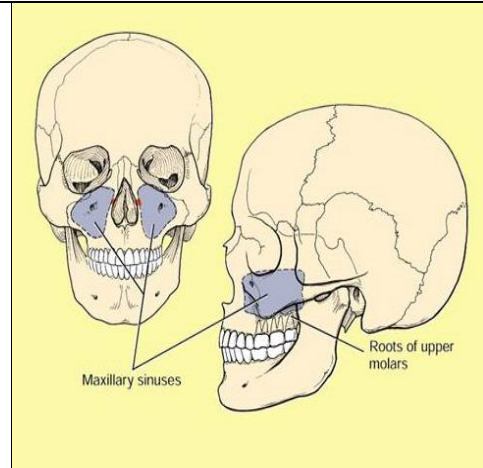
In general, their functions are to ensure:

Patent ostia + Normal Ciliary Function + Normal Quality of Mucous. \*\* Disturbance of these Function will lead to sinusitis

- Note : Facial growth center is present in paranasal sinus.

## Maxillary Sinus

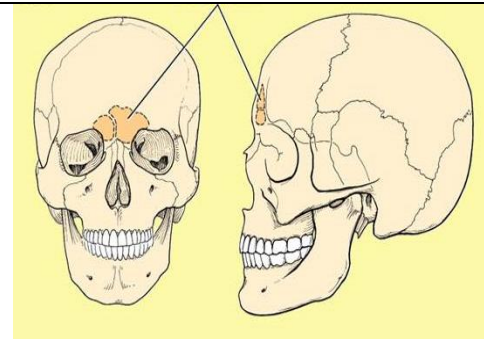
- **Pyramidal in shape**, The largest sinus
- **Paired & symmetric**
- **Located within the body of the maxilla behind the skin of the cheek.**
- **The roof is formed by the floor of the orbit, and the floor is related to the roots of the 2<sup>nd</sup> premolars and 1<sup>st</sup> molar teeth.**
- **The maxillary sinus opens into the middle meatus of the nose**
- **The Orbit:** Separated from the antrum by the thin roof of the sinus, which contains the infraorbital nerve



**Note :** Maxillary sinus is the first to develop Infraorbital nerve (sensation of anterior part of the cheek) is a continuation of the maxillary nerve. When a patient has paraesthesia in the cheek suspect mass around the infraorbital nerve, common in RTA also when there is fracture of the floor

## Frontal Sinuses

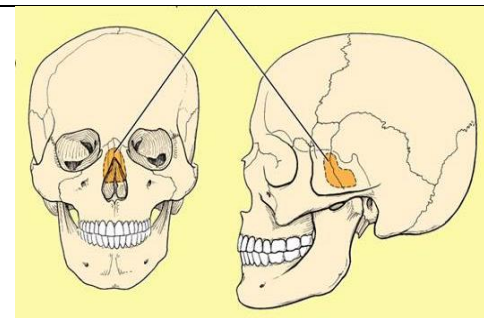
- **Rarely symmetrical**
- **Contained within the frontal bone .**
- **Separated from each other by a bony septum.**
- **Each sinus is roughly triangular**
- **Extending upward above the medial end of the eyebrow and backward into the medial part of the roof of the orbit.**
- **Opens into the middle meatus**



**Note :** - Frontal sinus is the last sinus to develop during puberty. - In frontal sinus, if infection extend posteriorly towards the brain it will cause meningitis. - And if infection extend anteriorly it will cause osteomyelitis (Pott's puffy tumor is osteomyelitis of the anterior bone of the frontal sinus) e.g. patient with two weeks history of frontal swelling and redness, CT shows some collection and abscess and inflammation, the patient has Pott's puffy tumor. - In the floor of frontal sinus there is agger nasi

## Sphenoidal Sinuses

- **Lie within the body of the sphenoid bone**
- **Below sella turcica**
  - **Extends between dorsum sellae and post clinoid processes**
- **Opens into the sphenoethmoidal recess above the superior concha**



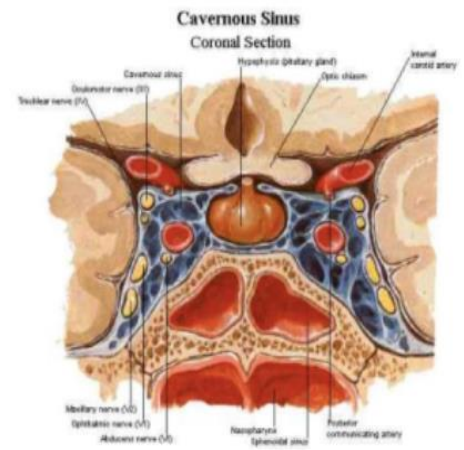
## Sphenoidal Sinuses

Relations: Laterally: the cavernous sinus containing:

1. Cranial nerves: 3rd, 4th, 5th (ophthalmic and maxillary divisions), and 6th.
  2. Internal carotid artery
  3. Optic nerve
- Above the sinus: Pituitary gland, optic chiasm, frontal lobe of brain, and olfactory tract.

The pituitary gland may be approached surgically through the sinus.

- Note : Most dangerous sinus during surgery is sphenoidal due to its relation with cavernous sinus contents, mainly carotid > massive bleeding if injured.



## Ethmoid Sinuses

- They are anterior, middle, and posterior
- Consists of a number (approximately 7-15) thin-walled cavities
- They are contained within the ethmoid bone, between the nose and the orbit
- Anterior & middle

-Drains into middle nasal meatus

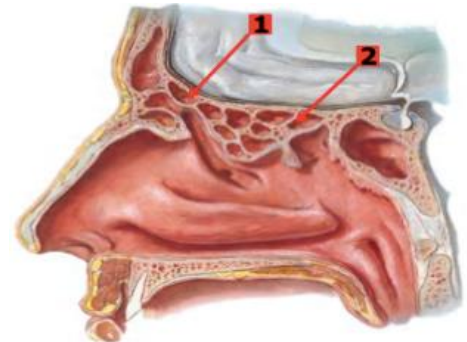
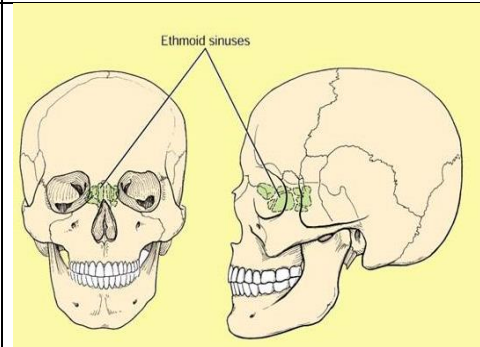
- Posterior

-Drain into superior nasal meatus

- Separated from the orbit by a thin plate of bone so that infection can readily spread from the sinuses into the orbit

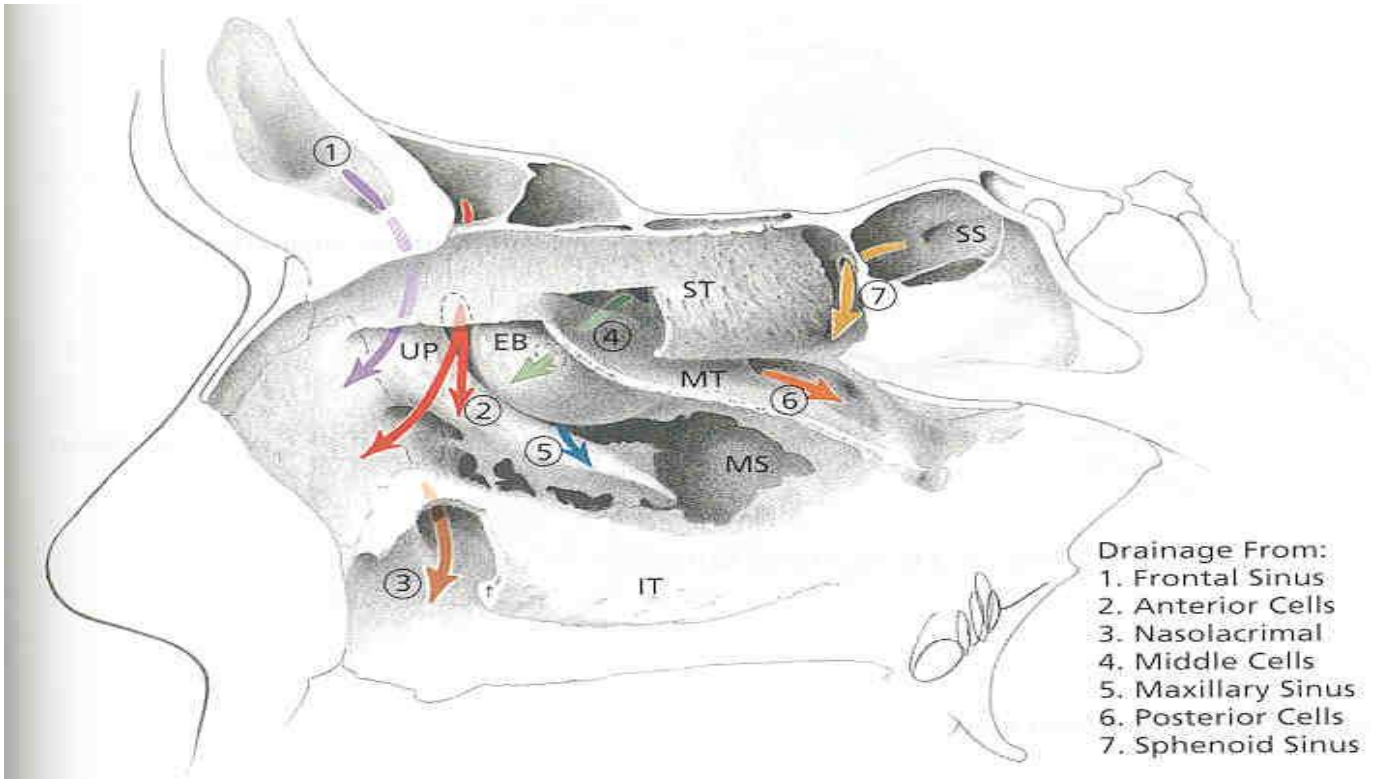
➤ 1. Anterior: Usually small and numerous. They open into the upper part of the hiatus semilunaris or above the bulla ethmoidalis, ultimately draining into the middle meatus.

➤ 2. Posterior: Usually large and few, they open into the superior meatus.



- Note : Nasal septum divides the right and left ethmoid. The anterior and posterior groups of ethmoid are separated by the basal lamella (3rd part of the middle turbinates).

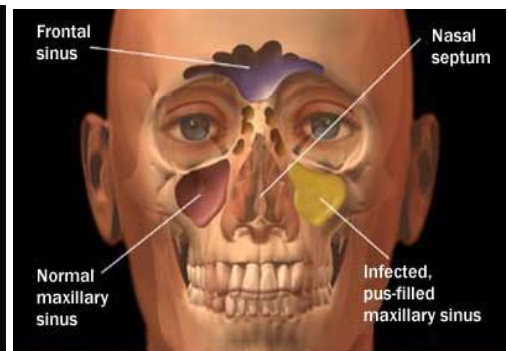
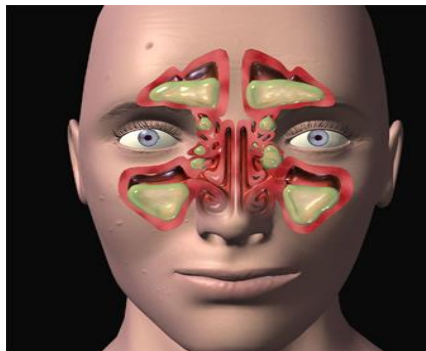
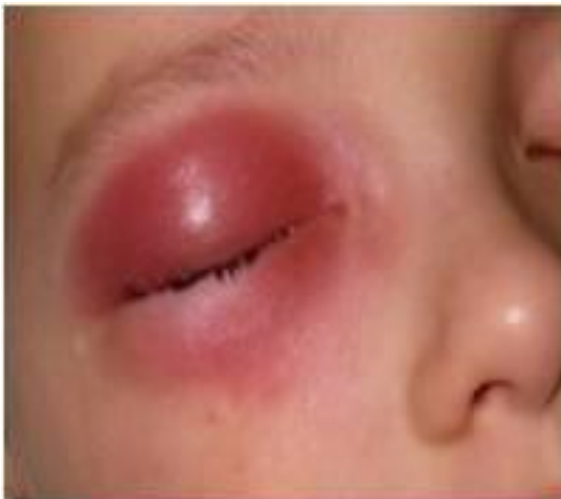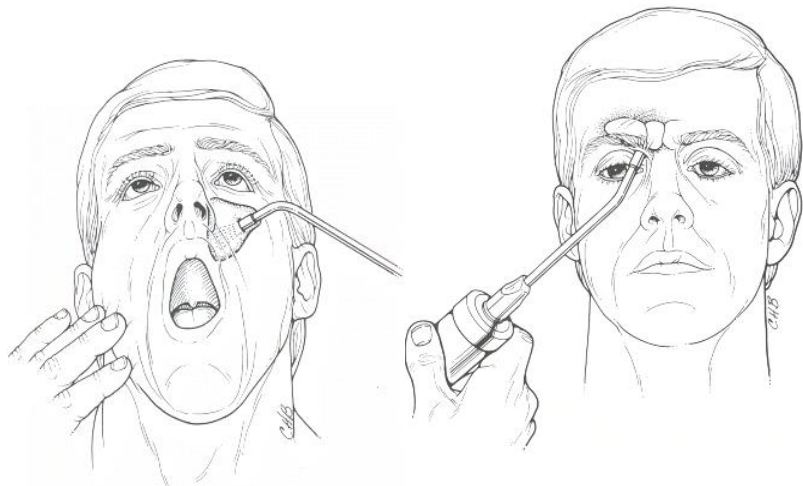
# Sinus Drainage Schema



## Clinical Notes

- Examination of the Paranasal Sinuses
- Sinusitis
- Basal skull fracture

You can examine paranasal sinuses by scope either rigged or flexible



# PHYSIOLOGY OF THE NOSE (mentioned in the objectives+433 team)

**3 major functions of the nose:** ➤ Olfaction ➤ Respiration (the most important)  
➤ Defense - Additional minor functions ➤ Aiding and modifying voice production ➤  
Providing vocal resonance ➤ Serving as a secondary sex organ

## Modification of inspired air

### Humidification

Nose adjust precisely the inspired air to have a humidity of 85 % ⇨ This enhances the gas exchange - Large portion returned to the nasal mucosa during exhalation. ⇨ This prevents overdrying of the nasal mucosa and thickening of the nasal secretions.

### Warms the inspired air

The rich capillary beds that make up the side wall of the nose, along with their accompanying venous sinusoids

### Purification of inspired air

Large particles are detected by the vibrissae of the nasal vestibule and the smaller particles are dealt with by lysosomal enzymes, macrophages and antibodies in the mucosal blankets of the nasal fossa.

\*The secretion of the nasal mucosa has three layers thin, semi-thin and thick layers. Nasal mucosa and paranasal sinuses secrete 800cc per day.

## NASAL VALVE

The smallest cross-sectional diameter and greatest resistance of the airway - The muscle activity prevents alar collapse during inspiration. - Resistance in this segment is created by the turbinate size, which is altered by the vascular tone and blood volume of the nasal sinusoids. - Induced by exercise, posture changes, and hyperventilation. - Chemical irritants, medications, pain, and emotion - Formed by upper lateral cartilage ➤

## NASAL CYCLE

Alternating changes in patency of the right & the left nasal cavities - Occur in rhythmic sequence in about 80 % of normal individuals - The total resistance to the nasal airflow remains constant - Controlled through the o Autonomic adrenergic centers o Hypothalamic control center - If the cervical ganglion is sectioned, there is abolition (termination) of the nasal cycle on the same side

## OLFACTION

Important in food choices and in social interaction - Warning sign for toxic gases and spoiled foods. - To smell a substance, it must somehow reach the olfactory mucosa located in the roof of the nose - The odor-producing substance must have a vapor pressure and must be relatively water- and lipid-soluble in order to be sensed.

## ANOSMIA “inability to smell”

Nasal obstruction and nasal infection. - The receptor molecule cannot reach the olfactory mucosa to stimulate a response. - Nasal polyposis and nasal deformities are reversible conditions in adults. - Infections and allergies cause temporary interruption of smell, and olfactory capability returns when the conditions resolve. - Smell can trigger an asthmatic attack and can worsen emphysema. (possible theory for this: Trigeminal reflex, which is induced by a chemical irritant stimulating the nasal mucosa and leads to reflex bronchial constriction) 433 ENT Team Nose I & II 17 | Page >

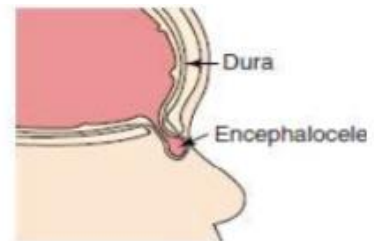
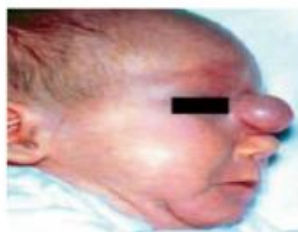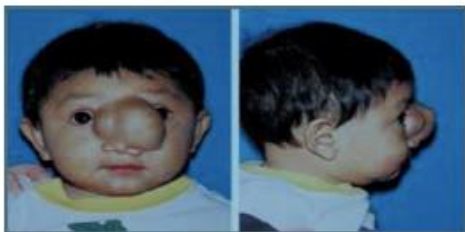## IMMUNOLOGY

Secretory immunoglobulin A (IgA) is the major immunoglobulin found in nasal secretions - The concentration of IgG (3 percent) and IgM (1 percent) increases during actual infections (this might be due to transudation of plasma resulting from mucosal injury).

## Developmental errors of the anterior neuropore

- > Encephalocele
- > Nasal glioma
- > Nasal dermoid

### 1) NASAL ENCEPHALOCELE:



- Definition: **Extracranial Herniation of meninges and/or brain tissue through defects in the skull.**

(Meningocele: Present similarly but without herniation of brain tissue).

- Described by location of dehiscence in the skull base:  
Occipital (75%) Sincipital (25%) Basal (1%)

Encephalocele is an extracranial herniation of cranial contents through a defect in the skull. When an encephalocele includes meninges only it is termed meningocele. Encephaloceles are divided into occipital, sincipital and basal type.

### Clinical Features:

Symptoms: Bluish mass over the glabella or inside the nose that is compressible, pulsatile and transilluminates with light.

- Positive Frustenberg test: Expansion with compression of bilateral jugular veins. Expansion may also be triggered by crying or straining (Valsalva).

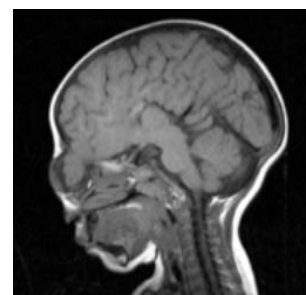
### INVESTIGATIONS:

- **MRI:** To identify intracranial extension (masses with subarachnoid extension)

- To differentiate between meningocele and encephalocele.

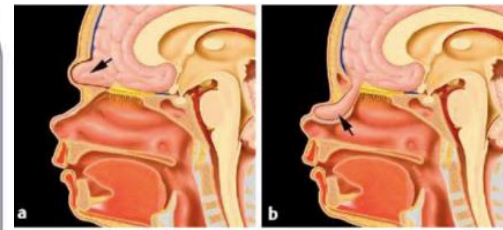
- **CT scan:** To detect skull base defect.

Mass containing brain tissue in continuity with the frontal lobe, this is a nasoethmoidal encephalocele



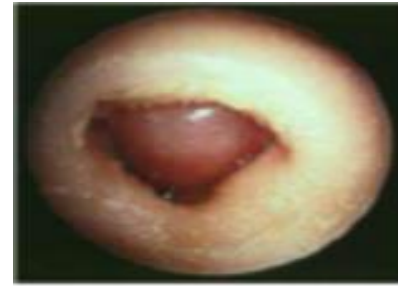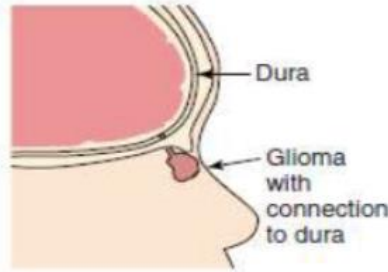
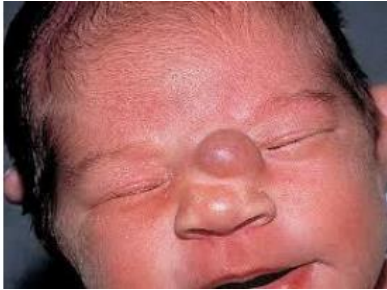A) Sincipital encephaloceles are also known as Frontoethmoidal encephaloceles. They occur between the frontal and ethmoid bones at the foramen cecum immediately anterior to the cribriform plate. They may be further subdivided as nasofrontal, nasoethmoidal and naso-orbital and manifest as external nasal masses

B) Generally Basal Encephaloceles arise through the cribriform plate or through the superior orbital fissure and manifest as an intranasal mass



(A) Sincipital Encephalocele (B) Basal Encephalocele

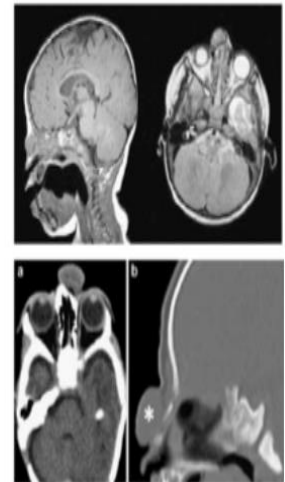
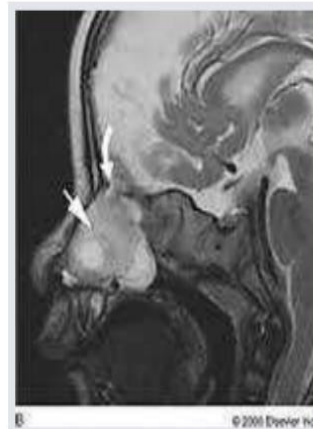## 2) NASAL GLIOMA:



- **Presentation (based on location):** may be present at birth “grow in proportion with the child age”
  - Extra-nasal: (60%) - Smooth, firm and non-compressible masses, skin telangiectasia - Glabella type “most common”, nasomaxillary suture line type.
  - Intra-nasal: (30%) - Arise in lateral nasal wall near the middle turbinate. - Polypoid type “pale masses” - Nasal septum type “rare”
  - Combined: (10%)
- **Nasal gliomas DO NOT trans-illuminate or enlarge with with crying or straining.**

## INVESTIGATIONS:

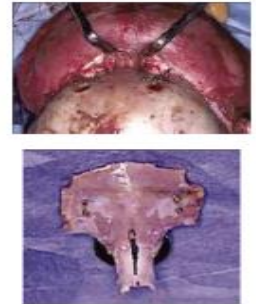
- **MRI:**
  - Hypotense on T1 , + hyperintense on T2
  - Presence of fibrous stalk “in 15%”
  - Rare enhancement.
- **CT scan :** To assess the bony anatomy of the skull base.



Intranasal glioma showing a fibrous stalk and are more commonly seen in those that are intranasal (35%)

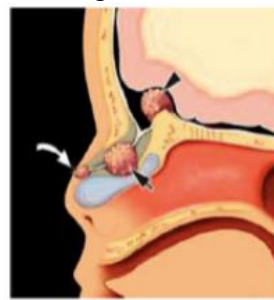
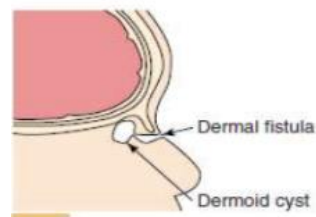
## Surgical Treatment

- ▶ For Meningocele, Gliomas limited to nasal cavity
  - ▶ Endoscopic repair with clipping the stalk
  - ▶ Defect is repaired with free mucosal grafts or mucoperichondrial flap
- ▶ For Encephaloceles, Gliomas and Dermoids with intracranial extension
  - ▶ Multidisciplinary approach
  - ▶ Transglabellar Subcranial Approach
  - ▶ Frontal craniotomy in combination with external Rhinoplasty and lateral rhinotomy approach



### **NASAL Dermoids:** the commonest congenital nasal anomaly.

- Definition: Epithelial-lined cavities (cysts) or sinus tracts consisting of both ectodermal and mesodermal elements, including hair follicles, sebaceous glands, and sweat glands.



#### ▪ **Presentation:**

- Midline mass or cyst with sinus opening: - Firm lobulated non-compressible mass. - Sinus opening -> Purulent or sebaceous material.
- Widened nasal bridge
- Protruding hair “Pathognomonic”: in minority of cases.
- Intracranial extension in 2-45% “attach to dura, falx cerebri ..etc”
- Up to 50% have fistula or sinus tract.

Dermoid sinus cysts of the nose present as a midline nasal pit, fistula or infected mass located anywhere from the glabella to the nasal columella. They may secrete sebaceous material or pus and may become intermittently infected causing abscess formation, meningitis even cerebral abscess for those with intracranial extension.

#### ▪ **Treatment:**

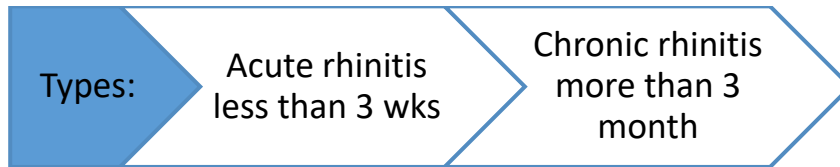
- Direct external excision.
- Medial canthal approach “Lynch”, external rhinoplasty, endoscopic resection.



## Definition of Rhinitis

\*Sometimes the disease is called “Rhinosinusitis” because usually sinusitis will accompany rhinitis attacks.

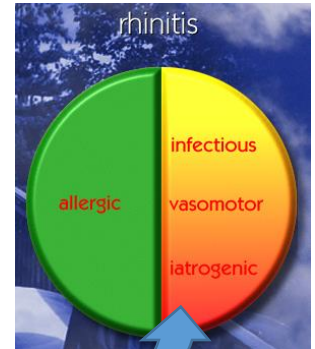
Rhinitis is inflammation of the lining of the nasal cavity. As the lining of the nasal cavity and the para-nasal sinuses is continuous, inflammatory process tend to involve both areas to a greater or lesser extent.



## Classification of Rhinitis

- Allergy
  - Seasonal, Perennial, food related, drug induced
- Infectious
  - Acute
  - Chronic

Iatrogenic (post-surgery)



## Types based on etiology:

- (1) Infectious rhinitis , (2) Vasomotor rhinitis , (3) Occupational rhinitis ,
- (4) Hormonal rhinitis : Menstruation ,pregnancy ,Untreated hypothyroidism ,Sexual excitement (Honeymoon rhinitis)
- (5) Drug-induced rhinitis , (6) Gustatory rhinitis , (7) Nonallergic rhinitis with eosinophilia syndrome (NARES)

## Allergic rhinitis:

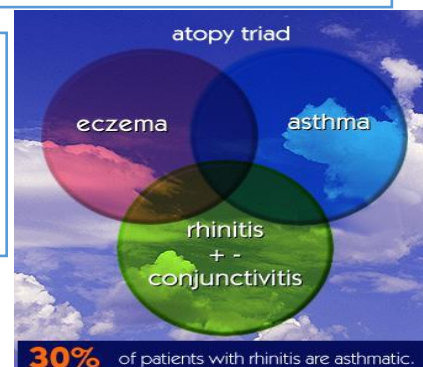
(Allergy is an abnormal reaction of the tissues to certain substances)

- Its an IgE mediated hypersensitivity (type 1) response to allergen lead to rhinitis, associated allergic conjunctivitis and asthma may occur.
- The disease is common, prevalence depend on age, gender, geographical distribution.

When pt come to you in the clinic with allergic rhinitis you have to ask about asthma\ eczema\Conjunctivitis or eye symptoms \ hyper sensitivity to some medications (Aspirin(NSAIDs)) to check if he has (samter's triad, which is a triad of **aspirin sensitivity, asthma** and nasal polyps)

**Atopy (atopic syndrome) :** Characterized by a tendency to be “hyperallergic”.

A person with atopy typically presents with one or more of the following: eczema (atopic dermatitis), allergic rhinitis (hay fever), or allergic asthma. Some patients with atopy display what is referred to as the “allergic triad” of symptoms, i.e. all three of the aforementioned conditions.



## Types: “old classification”

1) **Seasonal** Start Early Spring by [tree pollen] then in Midsummer by [grass pollen] and end in autumn by [molds].

2) **Non-seasonal** (perennial) Occurs all year round & can be a myriad of substances, although house dust mite is high on the list.

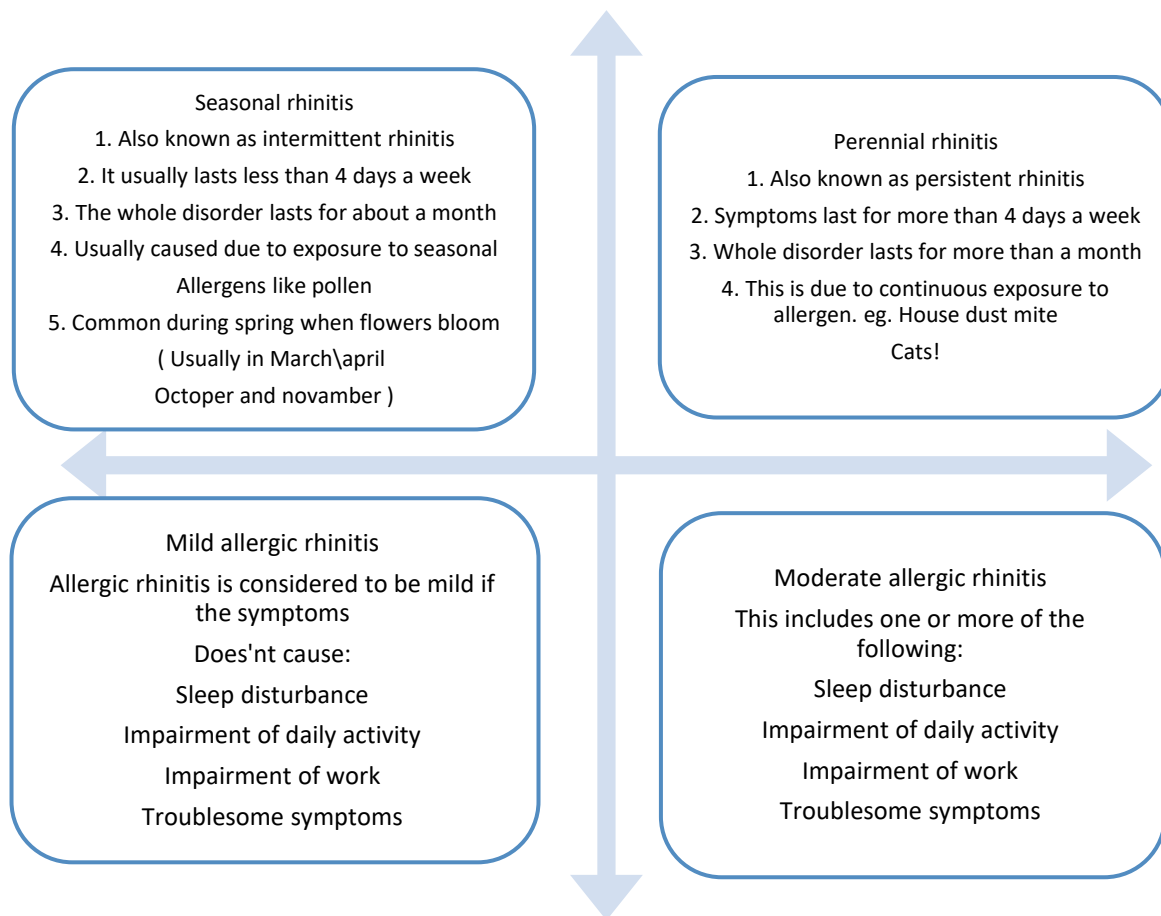
-The classification "seasonal" and "perennial" allergic rhinitis has been changed to "intermittent" and "persistent" allergic rhinitis

## Allergic rhinitis classification

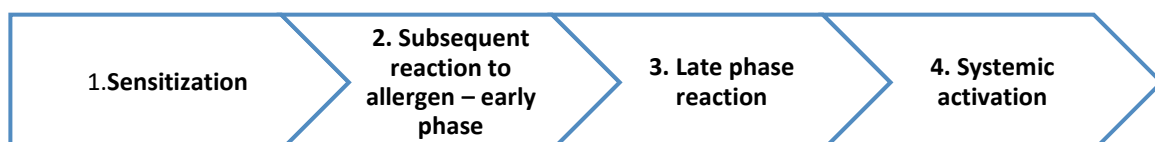1. Intermittent (Seasonal)
2. Persistent (Perennial)
3. Mild
4. Moderate - severe

### WHO Classification:

- 1) Mild
- 2) Moderate
- 3) Severe



## Allergic rhinitis pathophysiology (The reaction occurs in 4 phases): Video



## Diagnosis:

History “when I get exposed to dust I have the symptoms”

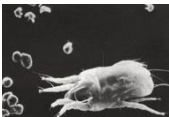
- Eosinophilis
- Skin tests (Antihistamine should be discontinued 3-6 days before test)
- Blood tests “e.g. radioallergosorbent test (RAST) to assess total Ig E level”

\*\* Allergic rhinitis can be: Ig E mediated (type 1 hypersensitivity) OR non Ig E mediated

Ig E mediated: There is an antigen-antibody reaction.

Non Ig E mediated: Like vasomotor rhinitis.

## Etiology of Allergic Rhinitis

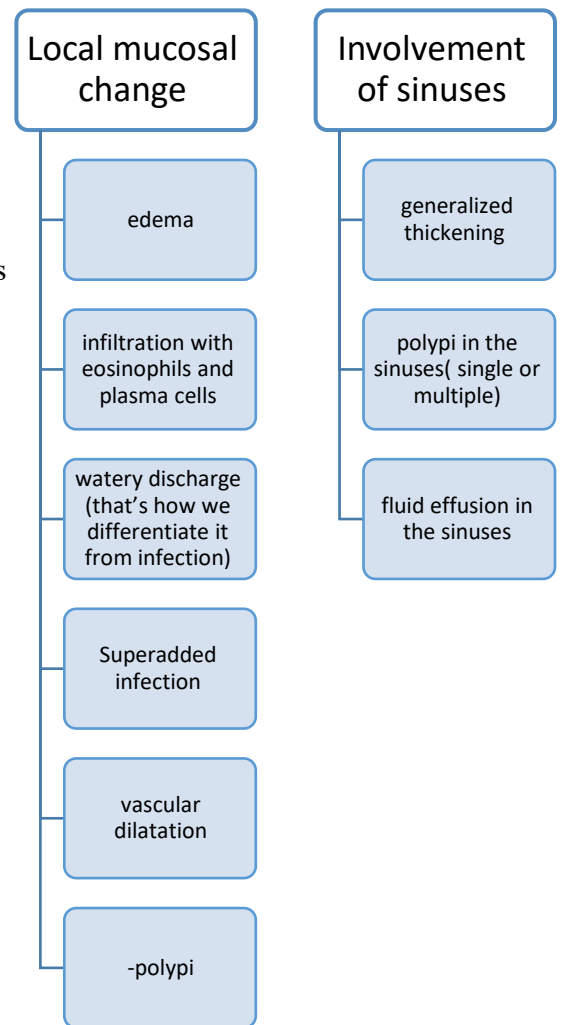


**What is this? Dust mite**  
**Causes? Rhinitis**

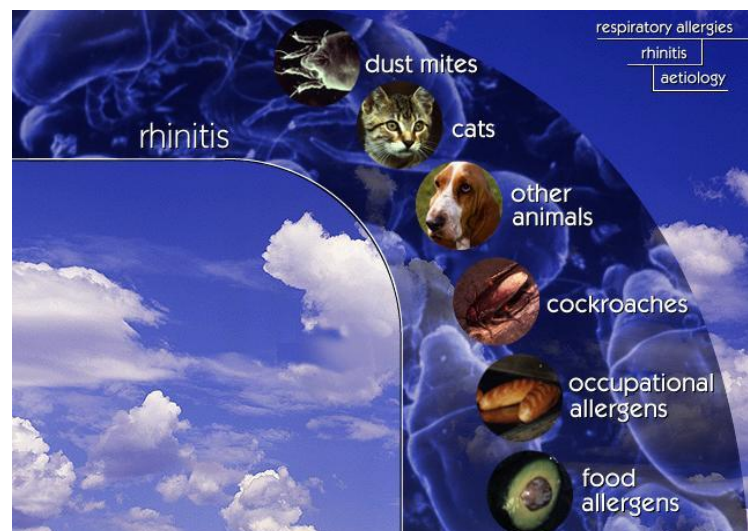
## Clinical features:

- Sneezing , may be in paroxysm.
  - Rhinorrhea
  - nasal obstruction and loss of smell
  - Itchiness of nose ,eye,palate
  - Tearing ,itching ,redness of eyes
  - Burning sensation in the throat.
  - symptom related to asthma (cough,shortness of breath, wheeze)

## Pathological change:



Local ENT examination :allergic nasal mucosa appear pale or bluish, boggy with swelling and watery discharge. there may be polyp, structural (septal deviation ,prominent turbinate).



## Occupational allergins:

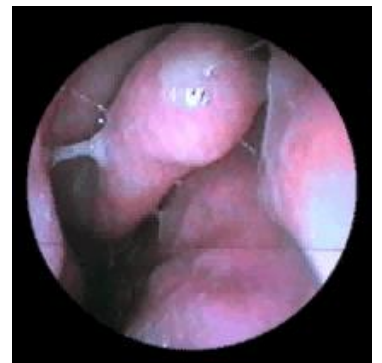- Rhinitis may occur as a consequence of allergins inhaled in work place frequently associated with asthma
- Biological agent include flour (in baker ,grain worker), laboratory animal ,wood dust,biological washing powder,latex
- Chemical agent
  - paint manufacturer and painter (spray)
  - platinum salt in platinum refiner
  - drugs in pharmaceutical worker

## Food induced rhinitis:

- It's a rare cause of allergic rhinitis, symptom of rhinitis often associated with urticaria, angioedema and GIT symptom
- Food may occasionally provoke IgE induced rhinitis
- In children Milk, egg, cheese,
- In adult nuts ,fish, shellfish, citrus fruit

## Examination

- General
- Local ENT examination :allergic nasal mucosa appear pale or bluish, boggy with swelling and watery discharge. there may be polyp, structural (septal deviation ,prominent turbinate).
- Systemic



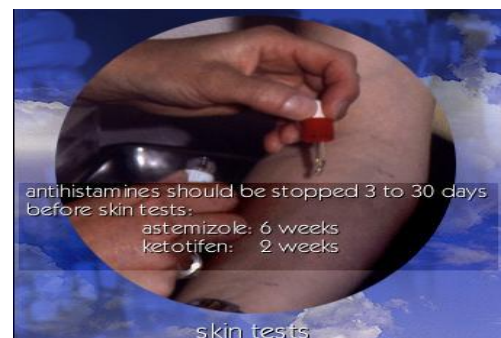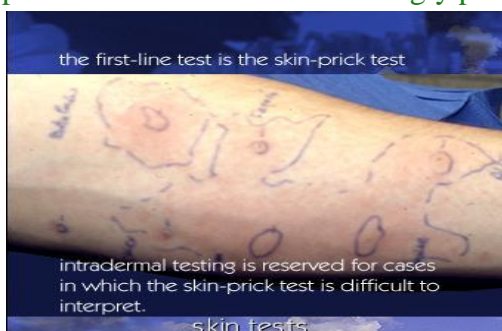
## Investigations:

1- Skin Tests: it's a primary tool in the investigation of allergy. its positive in seasonal rhinitis ,less than 50%in others

- it consist of pricking skin, with special needle few drops of allergin .
- Appearance of wheal and flare in 15-20 min ,the size of wheal is usually equal or greater than 3mm and interpreted by positive and negative control
- Antihistamine should be discontinued 3-6 days before test
- Intradermal test is rarely used because of extensive tissue reaction or anaphylaxis

## Skin prick test

Stop the anti-histamin for a week to avoid false negative, if it's more than 3 mm weekly positive more than 10 mm strongly positive



**Laboratory tests:**

- If the pt has any contraindication for skin test (like eczema, bad skin, bleeding disorders) then go to ->Laboratory tests:

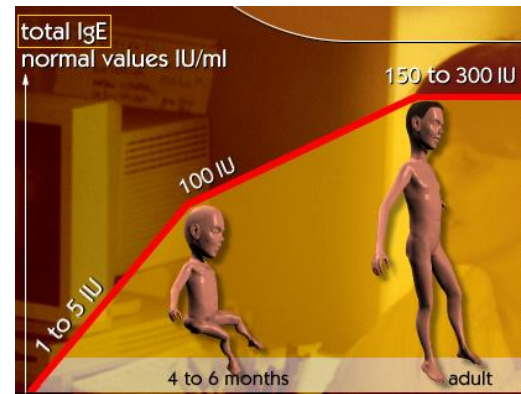
-nasal cytology ,eosinophil count in nasal secretion,blood  
 -IgE level measurement (total cap test)

- A raised IgE level usually confirm allergic constitution but it is neither sensitive nor specific
- Elevated level seen in smoker and parasitic infestation
- IgG go down
- IgE go up
- End up to abnormal immune reaction



**Treatment:**

- Avoidance of precipitating factors ( Allergins)
- Antihistamine drugs “Mainstay of treatment specially if the patient has other allergies like Asthma, they are preferred in acute settings because of their rapid onset of action”
- Topical Steroid “preferred in the long-run and good stabilizers”
- Desensitization “immunotherapy”: used in case of failure of antihistamines and steroids. “now available in sublingual form”
- Surgery “not for the allergy itself but for other symptoms resulting from it e.g. Polyp, hypertrophied turbinate etc” \* The same uniform classification of allergic rhinitis is proposed for: Rhinitis, Conjunctivitis, Asthma, Eczema/dermatitis, Urticaria, Food hypersensitivity, Drug hypersensitivity, Venom hypersensitivity, Anaphylaxis



Type of drug	Drug and administration
Antihistamines	<ul style="list-style-type: none"> <li>• Systemic :sedating , non sedating</li> </ul>
Steroid	<ul style="list-style-type: none"> <li>• Topical : beclomethazone, fluticasone</li> <li>• Systemic (short course)</li> </ul>
Alpha receptor agonist (decongestant)	<ul style="list-style-type: none"> <li>• Topical :pseudoephedrine</li> <li>• Systemic :xylometazoline</li> </ul>
Mast cell stabilizer	<ul style="list-style-type: none"> <li>• Topical :cromoglycate</li> <li>• Systemic :ketotifin</li> </ul>
Anticholenergic	<ul style="list-style-type: none"> <li>• Topical :ipratropium</li> <li>• Systemic :hyoscine</li> </ul>
Anticholenergic/ sympathemetic	<ul style="list-style-type: none"> <li>• Systemic: imipramine , chlorphenamine</li> </ul>

## Desensitization:

- it consist of injection of allergin in increasing dose S.C to be tolerated by the subject.
- Sublingual allergin available ,its popular but less effective .

## Surgery:

- Polypectomy
- Reduction surgery of inferior turbinate (**turbinoplasty**)
- For polyp , (FES) = **Functional endoscopic Sinus surgery**  
عملية تنظيف الجيوب بالمنظار

## Drug Induced Rhinitis



## Rhinitis Medicamentosa

The condition is the result of over medication with local nasal decongestants causing rebound phenomenon occurs resulting in turbinate hypertrophy. If the decongestant treatment is repeated the condition become rapidly self-perpetuating and a chronic nasal obstruction unresponsive to decongestant results. The treatment is immediate cessation of the decongestant with replacement by nasal or systemic steroid. If this is not successful then inferior turbinectomy may be required.

## Hormonal induced rhinitis

- Menstruation ,pregnancy
- Untreated hypothyroidism
- Sexual excitement (Honeymoon rhinitis)

## Acute rhinitis

- Common cold & influenza & Para Influenza viruses:  
“influenza & Para Influenza viruses are more severe than common cold”
- Etiology: in chronic we see more gram -ve like pseudomonas
- Conveyed by contact or air borne droplets

### Viruses

- Rhinovirus,  
Coronavirus,  
Adenovirus,  
Parainfluenza virus  
Respiratory syncytial  
virus, Enterovirus

### Bacteria

- Strept penumonia,  
Srtept Pyogen, HF,  
Maxerella Cataralis

➤ **Clinical features “stages” of common cold:**

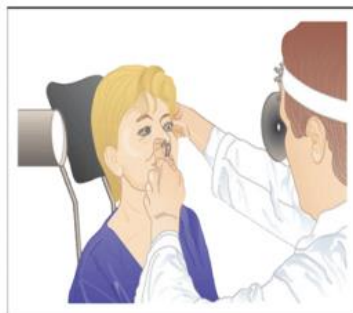Stage	Features
<b>Ischemic</b>	- 1-3 days of incubation period - Sneezing - Loss of smell “obstructed olfactory area” - Burning sensation in the nasopharynx
<b>Hyperemic</b>	- profuse rhinorrhea - Nasal obstruction - Pyrexia
<b>Secondary infection</b>	- Discharge becomes yellow or green “this happens usually after the common cold resolve by its own i.e. 1 week later”
<b>Resolution</b>	- This means resolution of both common cold the 2ry infection. - occurs 5-10 days (if persist >10 days => Bacterial cause)

➤ **Examination:**

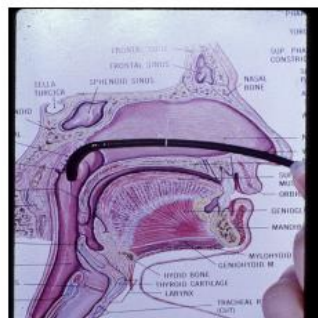
➤ Anterior Rhinoscopy

➤ Endoscopic Examination: 2 types: flexible “pic2 and ”Rigid “Pic3”

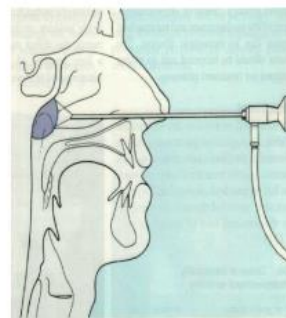
Fig. 2.1 Anterior rhinoscopy



Anterior Rhinoscopy



Flexible Endoscopy



Rigid Endoscopy

for children , poor cooperative patient , the image is not the same quality as the rigid endoscope

better image quality

➤ **Treatment:**

- Prophylactic: Avoid contact with patient

- Therapeutic:

-Rest -Analgesics -Decongestants -Antibiotics “rarely given because in 95% of the cases it is viral”

**Chronic rhinitis**

Classifications:

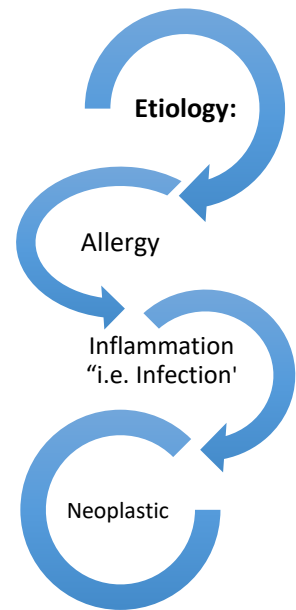
- Specific:	- Non-specific:
<ol style="list-style-type: none"> <li>1) Syphilis</li> <li>2) Wegner’s granuloma</li> <li>3) Medline lethal granuloma</li> <li>4) Sarcoidosis</li> <li>5) Mycobacteria</li> <li>6) Atrophic rhinitis</li> </ol>	<ol style="list-style-type: none"> <li>1- Simple chronic rhinitis</li> <li>2- Hypertrophic rhinitis</li> <li>3- Atrophic rhinitis</li> </ol>

# Nasal polyp:

A pendunculated portion of oedematous mucosa of the nose.

## Clinical features of Nasal polyps:

<b>Nasal obstruction – Unilateral / bilateral</b>	<b>Anosmia</b>
<b>Loss of taste</b>	<b>Rhinorrhoea – <u>watery</u> / mucoid / mucopurulent</b>
<b>Headache</b>	<b>Broadening of nose (Frog face)</b>



## Sites of origin:

- 1) Ethmoidal (commonest sites)
- 2) Antral (antrochoanal polyps)

Antrochoanal polyp (present from the nose going to the nasopharynx)

\* In general the ethmoidal and antrochoanal polyp are almost the same and have the same management.

## Individual polyp “unilateral”:

 seen in

- AFS “Allergic fungal sinusitis” in early stages
- Antrochoanal polyp.
- Inverting Papilloma
- Encephaloceles
- Gliomas, hemangiomas, juvenile nasopharyngeal angiofibromas, rhabdomyosarcoma, lymphoma, neuroblastoma, sarcoma, chordoma

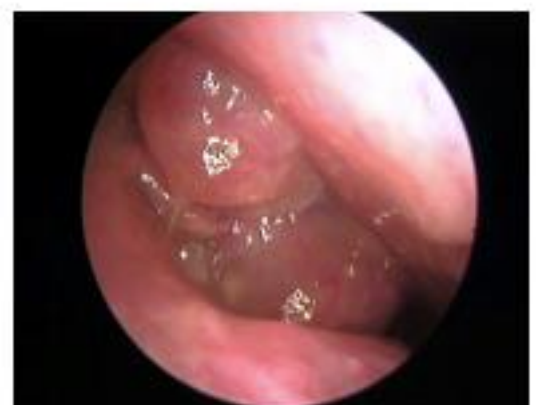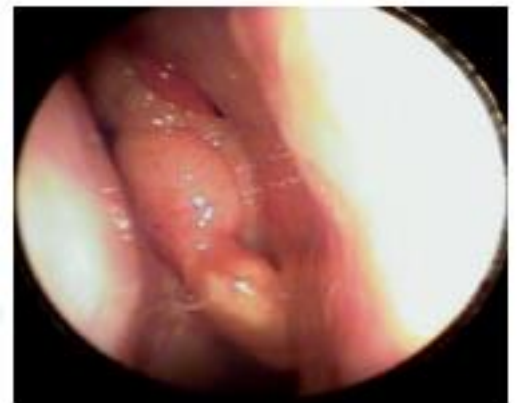## Multiple polyps are usually found in:

Chronic sinusitis\* “we divide it into 2 types based on presence of polyps”

Allergic rhinitis\*

Cystic fibrosis (CF)\*

Allergic fungal sinusitis (AFS)\*\*



\*Usually bilateral involvement.

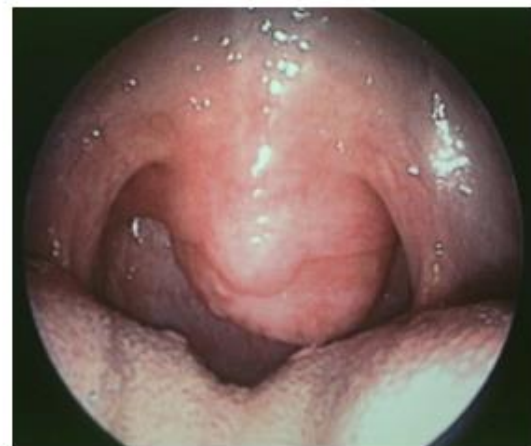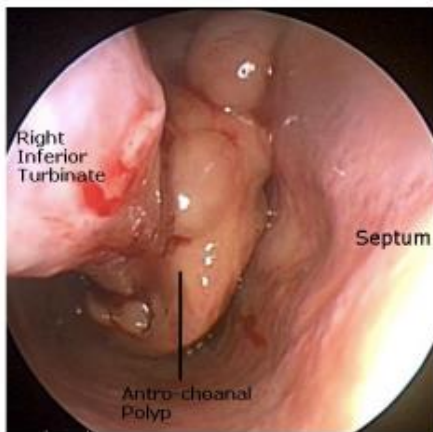
\*\* Usually start unilateral but in advanced cases it becomes bilateral.



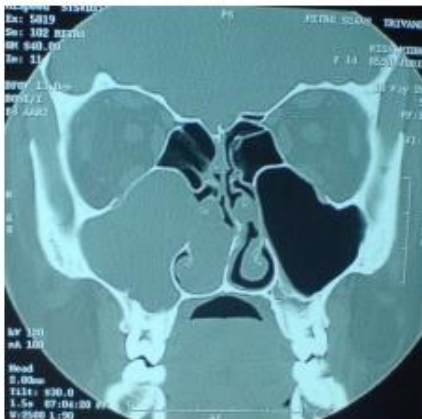# Antrochoanal Polyp

“diagnosed on examination and imaging basis”

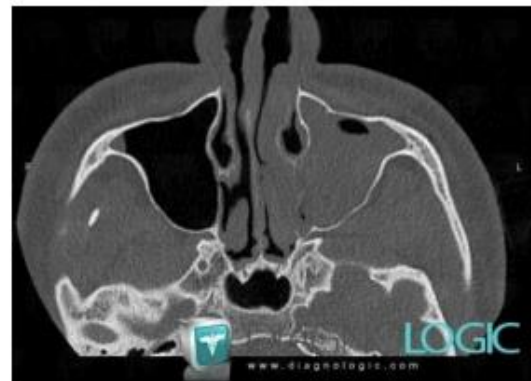- Polyp originating in the maxillary sinus, protruding in the middle nasal meatus
- Further posterior extension moves the polyp through the choana into the nasopharynx, and a very large lesion may appear as an oropharyngeal mass.
- Antrochoanal polyp can be seen exiting out of accessory ostium



Posterior extension to the nasopharynx



Coronal section CT scan showing unilateral mass in the maxillary sinus

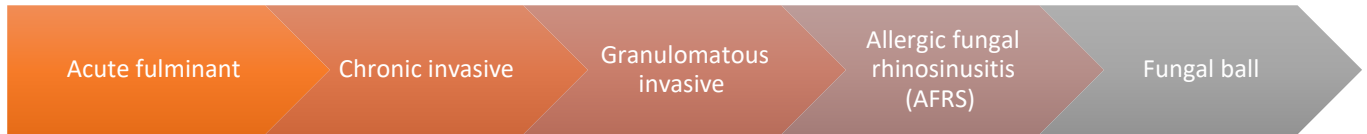

CT scan showing unilateral mass in the maxillary sinus “axial”

# Fungal polyp

5 Different types:

(possible SAQ) What do you see in the photo? -nasal polyp. Give ddx? -Simple nasal polyp. -Allergic nasal polyp. - Allergic fungal rhinosinusitis. -Malignancy - Inverted papilloma.



## Acute fulminant:

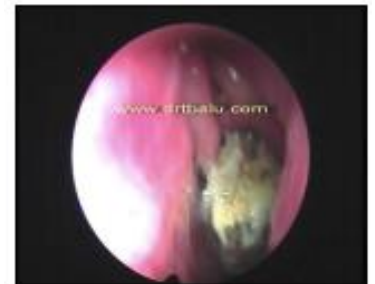Sudden onset and usually present in immunocompromised patients leading to serious consequences.

## Chronic Invasive:

Invades the basement membrane and go to the adjacent structures causing necrosis and ischemia.

## Fungal Ball:

- **Immunocompetent**
- Fungal ball is tightly packed hyphae of aspergillus (common)
- Antifungal trt is not necessary

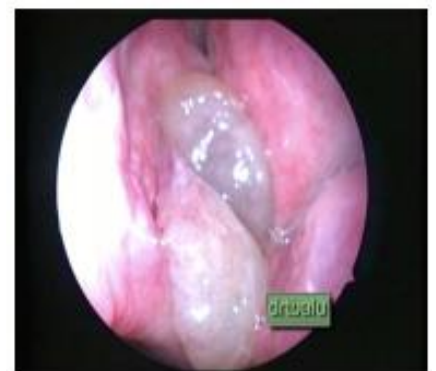

## Allergic fungal rhinosinusitis (AFRS):

AFRS most commonly seen in Saudi Arabia.

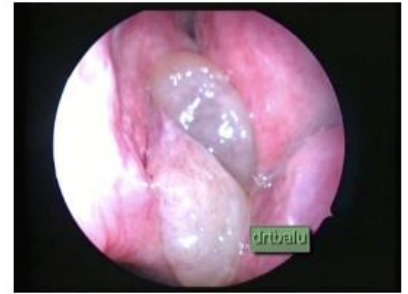Bent's criteria

- Type I hypersensitivity (demonstrable)
- Nasal polyposis
- **Heterodense mass lesion seen in CT scans and remodeling**
- Presence of eosinophilic mucin mixed with non-invasive fungus
- + Fungal stain / culture



## Examination:

- ✓ Smooth glossy grape-like multiple mass seen in anterior rhinoscopy
- ✓ Insensitive on probing. Probe can be passed around the polyp (when touched the patient will not feel).
- ✓ Soft and mobile

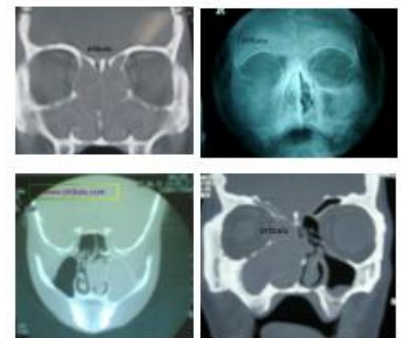

## Differential diagnosis:

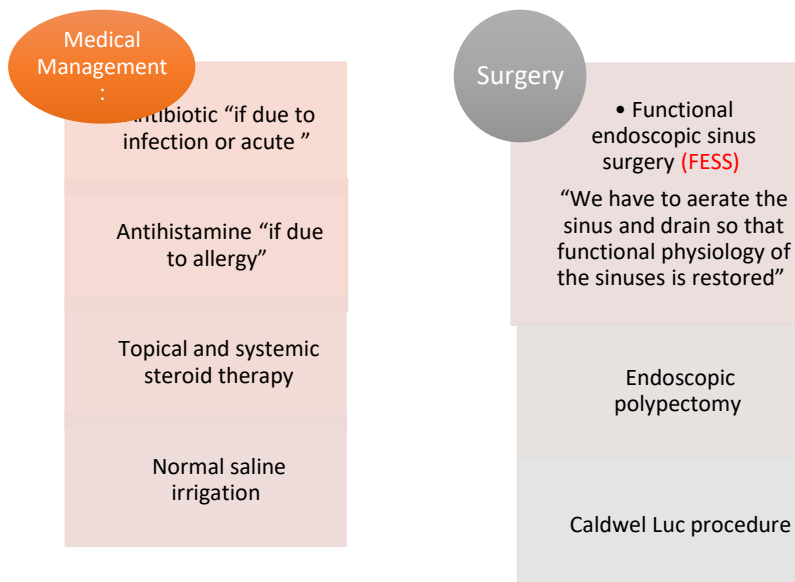
- ✓ Meningocele.
- ✓ Angiofibroma.
- ✓ **Sq cell carcinoma** (squamous cell carcinoma is the most common malignancy in the nose).
- ✓ Enlarged turbinates.
- ✓ **Inverted papilloma** (benign tumor).

## Radiology:

- ✓ Heterogeneity, remodelling > Allergic fungal.
- ✓ No heterogeneity, expanding, unilateral > Malignancy.



## Treatment of Nasal polyp : “treat the underlying cause”



**In general start with medical treatment, if failed > surgical.**

FESS risks (complications):

- Bleeding
- Synechiae formation
- Orbital injury
- Diplopia
- Orbital hematoma
- Blindness
- CSF leak
- Direct brain injury
- Nasolacrimal duct injury/epiphora

## Infections of external nose

- **Furunculosis**
- **Infection of hair follicles**
- **Hard tender painful red**
- **Cavernous sinus thrombosis**
- **Local heat application**
- **Systemic A.B.**
- **Parantral A.B. (if large or cellulitis)**

## Diseases of Nasal vestibules:

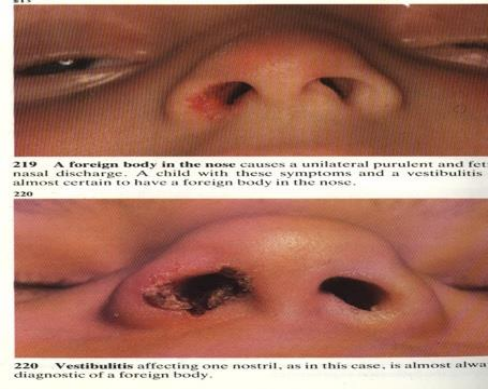
### - Vestibulitis:

#### inflammation of nasal vestibules

- ❖ **Usu. Staf. Aureus**
- ❖ **Coryza**
- ❖ **Atopy**
- ❖ **Unilateral :F.B.**

Vestibule is the most anterior part of the nasal cavity that is lined by skin epithelium “squamous epithelium” and has hair follicles.

There will be pain, swelling, and other signs of local inflammation and sometimes fever.



### - Furunculosis of nasal vestibulae:

**Definition:** Acute staphylococcal infection of hair follicle.

**Clinical features:** pain, tenderness, indurated swelling in the vestibulae.

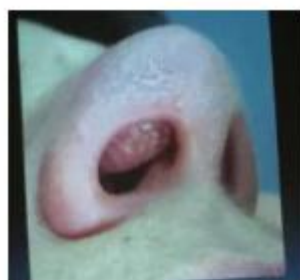
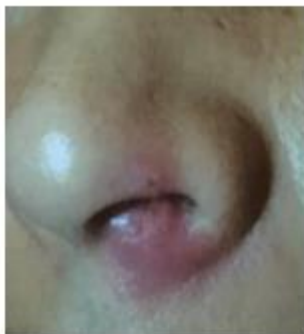**Treatment:** systemic antibiotics or topical depends if the patient is immune-compromised or extreme of age.

**Complication:** cavernous sinus thrombosis (because the head& neck venous drainage system is VALAVELESS), cellulitis of upper lip.

\*Vestibule: is lined by squamous cell epithelium not respiratory epithelium, so it can be affected by skin diseases like dermatitis and furunculosis.

Furunculosis: the same as vestibulitis, with pus.

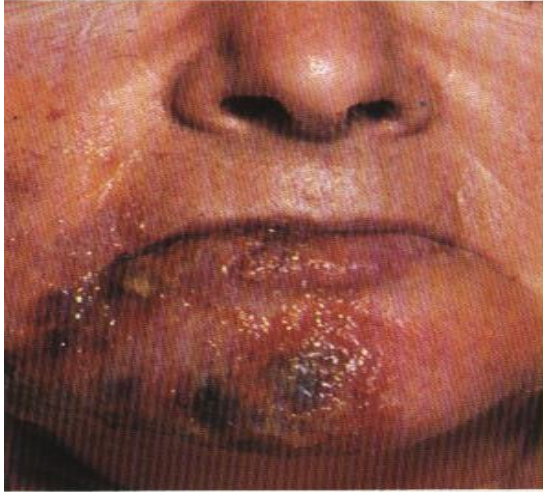Vestibulitis: more broad term than furunculosis, infection of skin and hair follicles. Cellulites: skin infection without pus.



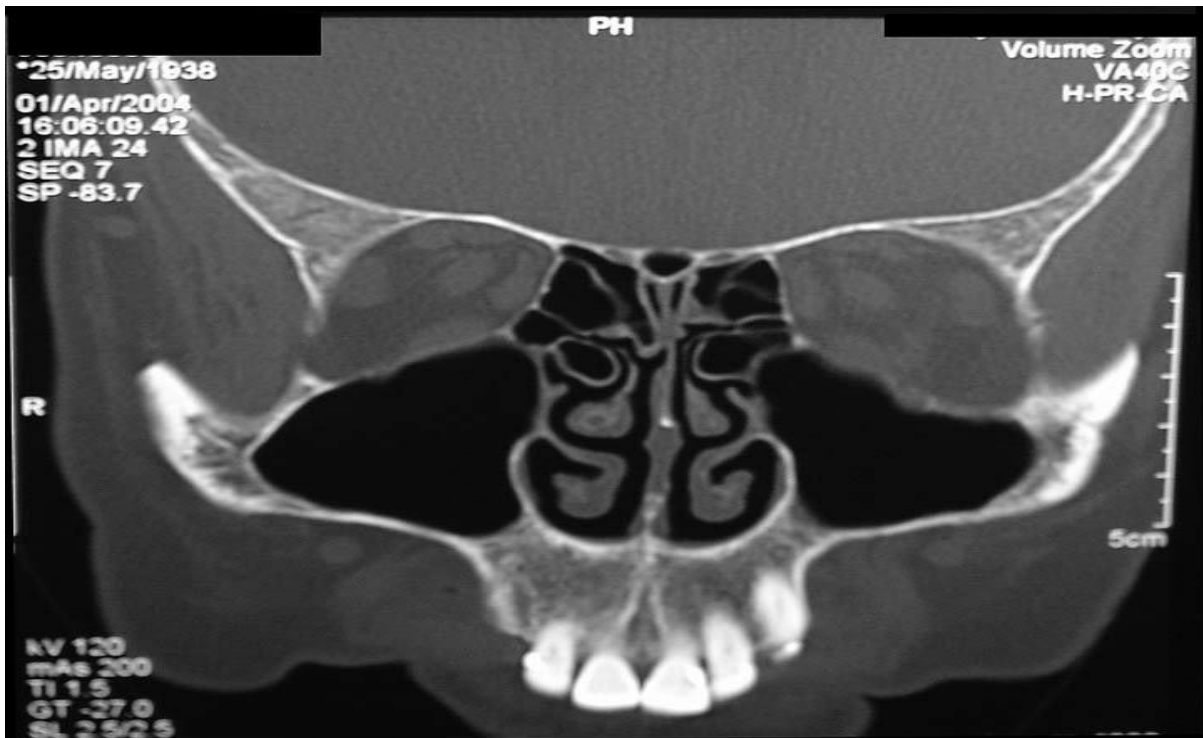
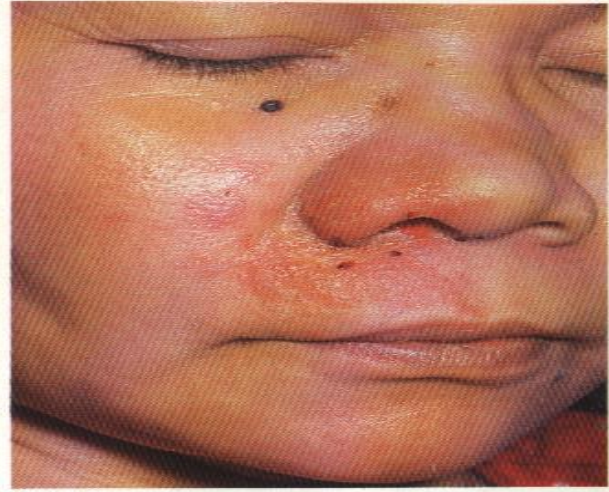**Nasal Vestibulitis**

- *Herpes zoster :*
- *Ophthalmic branch of trigeminal n.*
- *Cheek ,palate & vestibule*

95



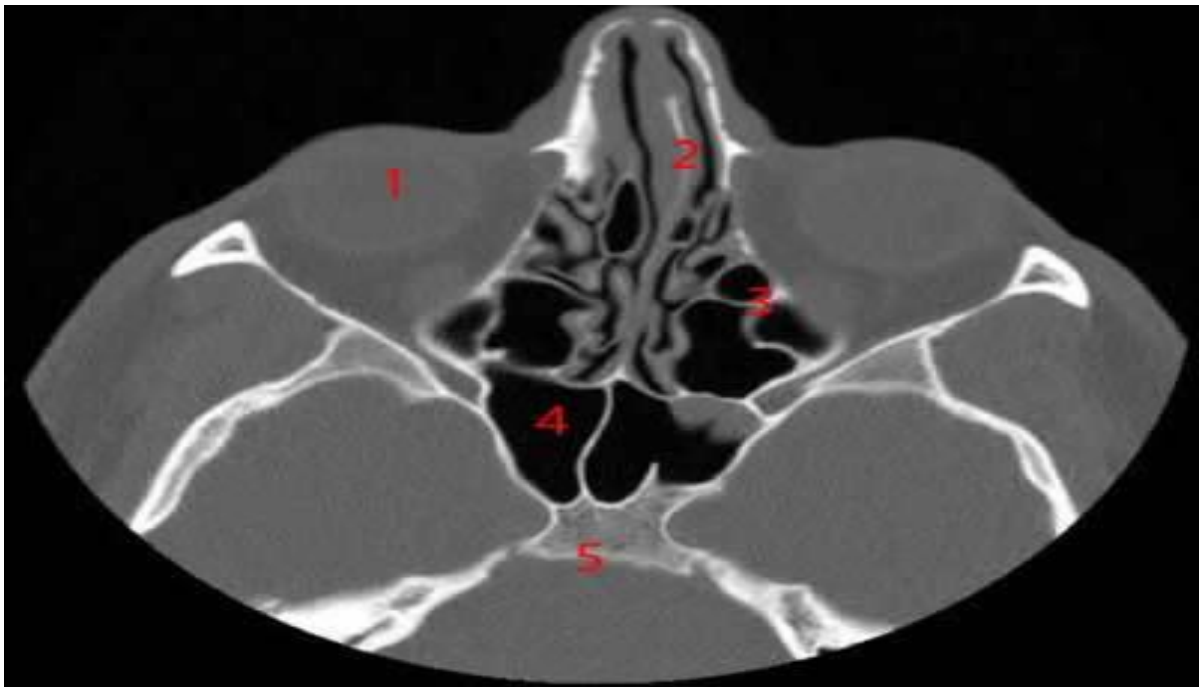
96



CT  
Coronal

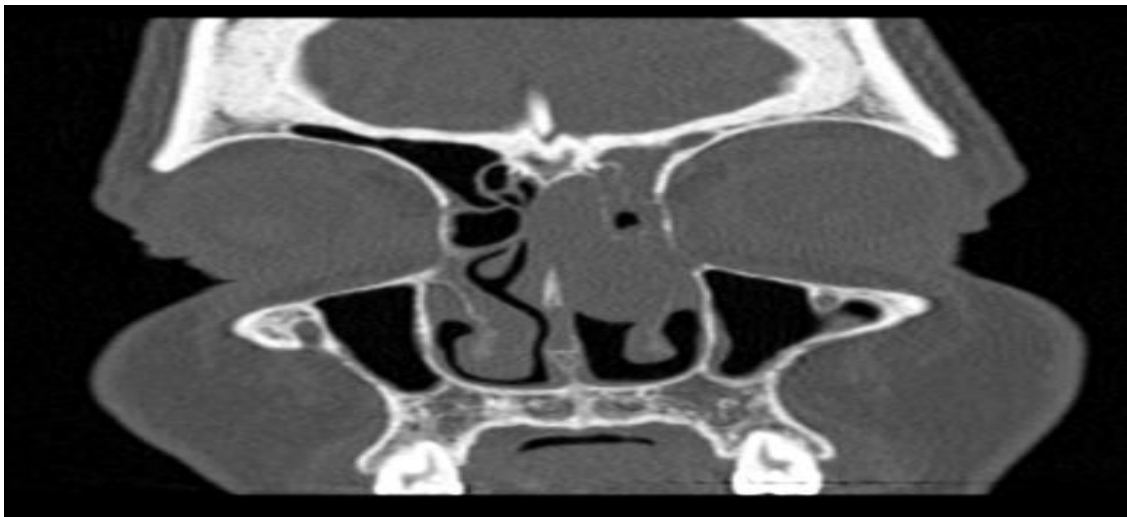Gold standard imaging for the sinuses is CT scan coronal section  
At which level? Para-nasal sinuses

Septum , Maxillary sinus , ethmoid (multiple)  
Orbit, inferior, middle, superior turbulent



CT scan , paranasal sinuses, (axial), Bone window (because we can see the characteristics of the bone+ the brain is not clear)

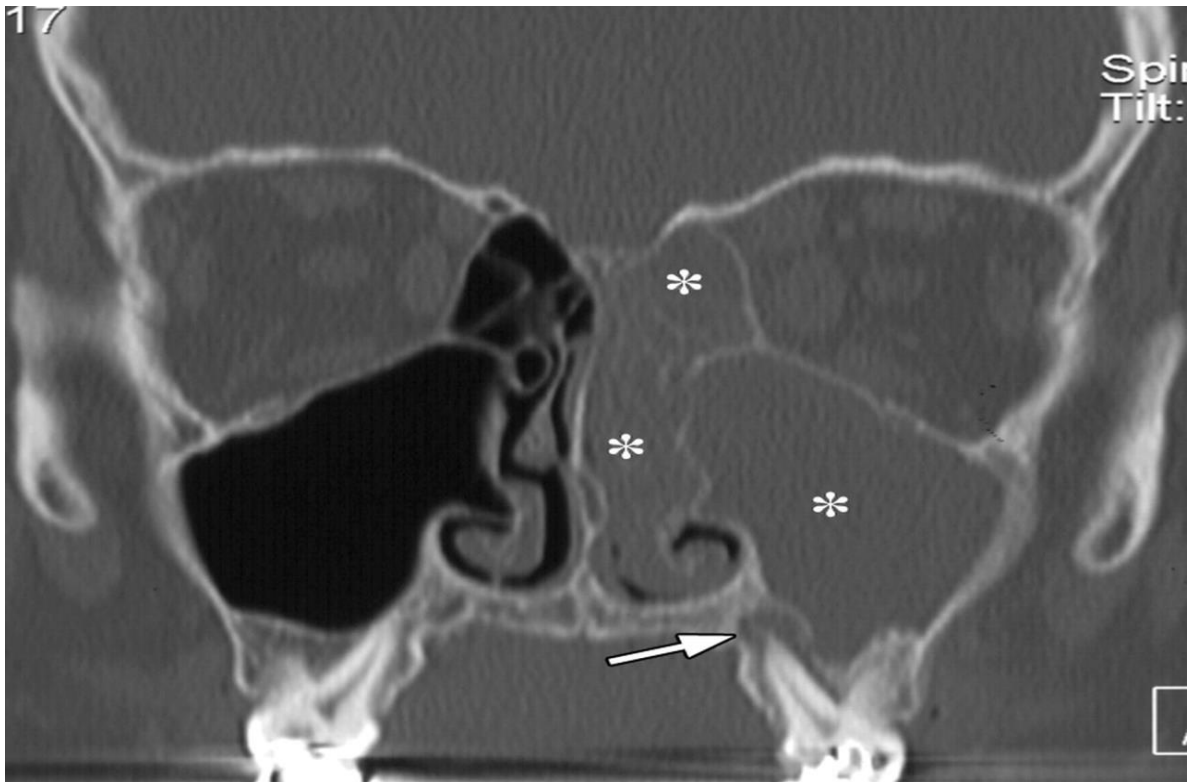
- 1- Orbit
- 2- Septum
- 3- Ethmoid (posterior) , (anything above the level of the globe is anterior and anything below the level of the globe is posterior )
- 4- Sphenoid
- 5- Sellaturseca



CT scan , Coronal cut ,  
 Infraorbital nerve, septum, maxillary, ethmoid, frontal.  
 Abnormal (Radiologicaly , opacity, radioopace at the left side

DDX: Polyo (inflammatori) , tumer,

Veric papilom Is the most common benign tumer of the sinuses  
 Malignant like Sequems cell carcinoma



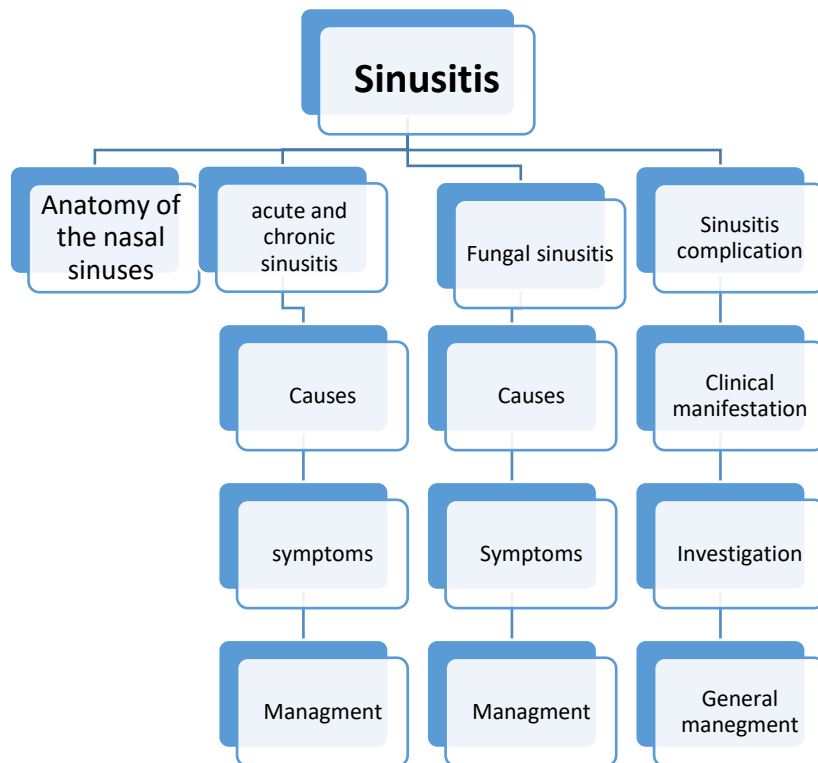
CT scan

Inferior, middle turbulent

Opacity left side maxillary sinus , ethmoif, nasl cavity, (frontal we can not mention because we are far posterior

**Objective:**

- Acute & chronic sinusitis (causes, clinical, management)
- Fungal sinusitis (in brief)
- Complication of sinusitis (classification, management & with special attention to orbital complications, investigation & general treatment)
- Radiology illustration
- Diseases of nasal septum (DNS etc.)
- Epistaxis (causes, clinical & management)-
- Turbinate hypertrophy
- Nasal operations (FESS, septoplasty, turbinate surgery) in short



## Acute Sinusitis:

The persistence of upper respiratory symptoms for greater than a 7-day course but lasts less than 4 weeks..

- It affects huge number of people worldwide and has an impact on their life.

## Predisposing factors:

1. **Nasal obstruction** by nasal polyps, tumors, mucous plug, edema, large adenoid, foreign bodies, septal deviation or head trauma causing blockage of sinonasal pathway or **OMC Obstruction** \***Osteomeatal complex**: is a common channel that links the frontal sinus, anterior ethmoid air cells and the maxillary sinus to the middle meatus allowing airflow and mucociliary drainage\*
2. **Ciliary dysfunction** (Primary ciliary dyskinesia) like in Kartagener's syndrome.

- Both will result in stagnation of nasal secretions, creating a good environment for the bacteria to grow.

3. **Altered quantity or quality of the nasal mucous**. - This is commonly caused by dehydration (common in elderly) and cystic fibrosis (in which, mucous is thick and poorly discharged, almost 99% of cystic fibrosis patient will encounter an episode of sinusitis in their life).

The Most important pathologic process in disease is **obstruction of natural ostia**, which leads to hypooxygenation, then leads to **ciliary dysfunction** and **poor mucous quality**

\*Ciliary dysfunction leads to retention of Bacteria\*

## Etiology:

**Viral** (More in common cold).

**Bacterial** (**Streptococcus pneumonia**, **H.Influenza**, **Moraxella cattharalis**).



## Clinical Manifestations of Acute sinusitis:

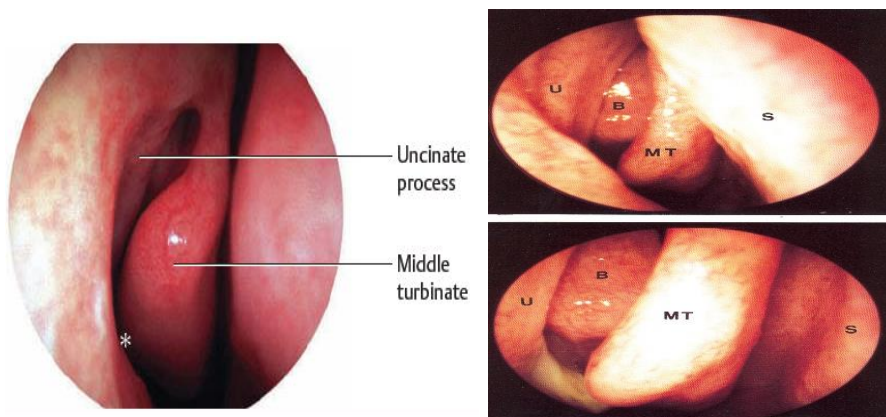
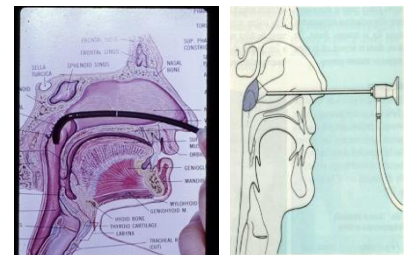
- **Nasal congestion and obstruction** \*Ask whether unilateral or bilateral\*
- **Purulent and copious rhinorrhea.**
- **Facial pain or pressure** that is worse when bending forward and **periorbital swelling.**
- **Other signs and symptoms include** fever, fatigue, cough “day and night”, hyposmia or anosmia, ear pressure or fullness, headache, and halitosis.
- **Dental issues** (Especially if unilateral symptoms) (e.g. a patient presents with symptoms of acute sinusitis due to tooth extraction and spread of organisms "**Usually anaerobes**" from the tooth origin to maxillary sinus all the way to the other paranasal sinuses causing acute sinusitis). (**In this case, the Treatment is Metronidazole or Clindamycin**)

## Examination:

- Fever, facial edema, erythema and tenderness around the nose and over sinues.
- using a speculum to inspect the nose from inside or by a nasoscope: signs of inflammation (**redness, swelling and discharge**).
- Look at any cause of obstruction or deviated nasal septum.
- sometimes, brief look at the oral cavity to see the teeth is important if you suspect the origin of infection is dental.
- **most specific-- Mucopurulence, periorbital swelling, facial tenderness.**

### **Nasal Exam:**

**Nasal endoscopy:** A thin, flexible tube (**endoscope**) with a fiber-optic light inserted through your nose allows your doctor to inspect the inside of your sinuses.



U: Uncinate proses.  
MT: Middle turbinate.  
S: Septum

### **Endoscopy landmark**

### **Endoscopy Finding**

### **Treatment of Acute Rhinosinusitis:**

Antibiotics: Amoxicillin (**If allergy, give them Macrolides or Fluoroquinolones**)

The initial treatment aims to relieve the symptoms, since almost everyone will improve within 7-10 days.

At this stage, antibiotics can only be **used if there is clear evidence of severe bacterial infection**, so as an initial treatment, we can give acetaminophen or ibuprofen for the pain, flushing the nose and sinuses with a saline solution to decrease pain associated with nasal congestion, and nasal decongestants to temporarily treat congestion.

**Nasal decongestants** ◇ (No nasal adverse effects with Systemic nasal decongestant, but local might cause Physiological addiction)

Second-line treatment includes **nasal steroids** to reduce swelling inside the nose, amoxicillin can be prescribed if bothersome symptoms of sinusitis persist for more than 10 days, or improve and worse again within the same period.

Because antibiotics are effective only against bacterial, and not viral, infections most people with acute sinusitis do not need antibiotics and would be putting themselves at risk for medication side effects and for developing antibiotic

resistance by taking them for nonbacterial sinusitis. **UPTODATE**

<https://www.uptodate.com/contents/acute-sinusitis-sinus-infection-beyond-the-basics>

### **Recurrent Acute Rhinosinusitis:**

Repeated acute episodes completely resolving within 12 week time frame.

### **Chronic Sinusitis:**

Persistence mucosal inflammation for > 12 consecutive weeks despite medical therapy or occurrence of more than 4 episodes a year.

**-Chronic rhinosinusitis with nasal polyps**

**-Chronic rhinosinusitis without nasal polyps**

### **Predisposing factors:**

1. Long standing nasal obstruction. ( Choanal atresia , Deviated septum, Polyps/foreign bodies, Turbinate/adenoid hypertrophy )
2. Transnasal tube or NG tube that is left for a long time (e.g. in ICU).
3. Atopic (Allergic) rhinitis.
4. Primary ciliary dyskinesia.
5. Cystic Fibrosis.
6. Poor quality of the mucous.
7. Hormonal factors (a common disease in puberty and pregnancy due to hormonal changes).
8. Acid reflex (GERD).
9. Immunodeficiency.
10. Patients with hyper inflammatory status such as Wegner's disease (also called Granulomatosis polyangiitis).
10. Dental procedures.
11. Churg-Strauss syndrome.

### **Etiology:**

Almost always a bacterial cause (**Staphylococcus aureus, coagulase negative staphylococci** and pseudomonas species and less commonly Bacteroids and other anaerobes)

### **History:**

Symptoms: Just like acute sinusitis.

- No fever (**very important hint for chronic sinusitis**).
- Ear symptoms
- Halitosis
- Dental issues
- Visual and neurological symptoms
- Immune status
- Duration: **more than 3 months**.
- **It's important to ask about cough and exaggeration of asthma** (They are commonly associated with chronic sinusitis) - It was noticed that when you deal with chronic

sinusitis, asthma symptoms improves a lot and the need of asthma medications is reduced dramatically)

### Diagnosis of Chronic sinusitis:

Major Factors	Minor Factors
Facial pain/pressure	Headache
Facial congestion/fullness	Fatigue
Nasal obstruction/blockage	Halitosis
Nasal discharge/purulence/discolored postnasal drainage	Dental pain
Hyposmia/anosmia	Cough
Purulence in nasal cavity on examination	Ear pain/pressure/fullness
Fever	

### One of the following situations:

- Two major factors
- One major factor and two minor factors
- Pus in the nose on examination

### Investigations

**CBC** (Eosinophilia, since many patients have chronic sinusitis due to allergic Rhinitis.

**Culture** (If the patient wasn't responsive with the treatment)

The culture must be directly from the sinus cavity because nasal culture have no diagnostic value (normal flora)

**CT** (**standard to be done in chronic sinusitis**, to confirm the diagnosis and to assess the severity of the disease also should be done pre-surgically.

**MRI** (**look for complications**).

Others: IgE, ESR, Serology (in case of autoimmune diseases).

### Radiography:

#### Plain X Rays

##### Traditional views

**Water's: Occipitmentum**

**Caldwell: Occipitofrontal**

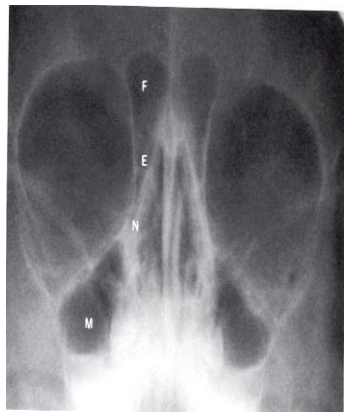
**Lateral**

**Submentovertex**

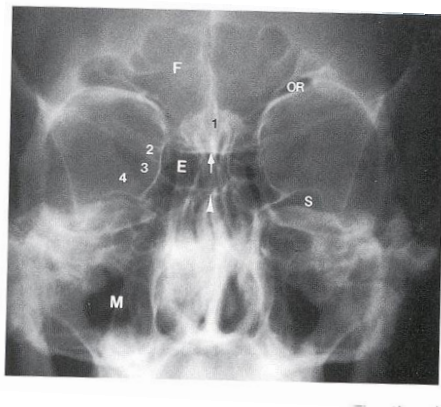
#### CT scan

#### MRI

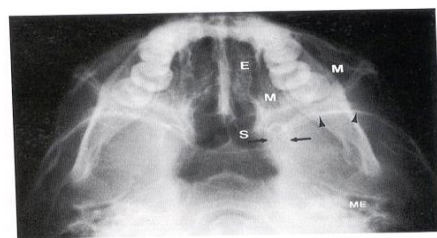
**Plain Radiography:**



**Water's**  
**Computed Tomography:**  
**Study Type:**



**Caldwell**

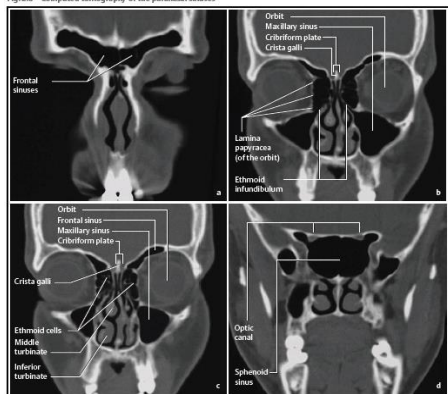


**Submentovertex**

**Coronal:** Perpendicular 2 Hard Palate  
**Axial:** Paralell 2 Hard Palate  
**Reformatted Sagittal**  
**Multiplanr CT Scan axail and reformatted other cuts: We just take an axial cut and reformat the sagittal and coronal.**

**Coronal CT Scan**

Fig. 2.6 Computed tomography of the paranasal sinuses



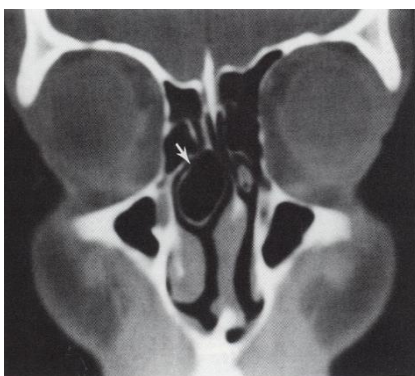
Four representative coronal CT scans are shown.

**Scan Acquisition**

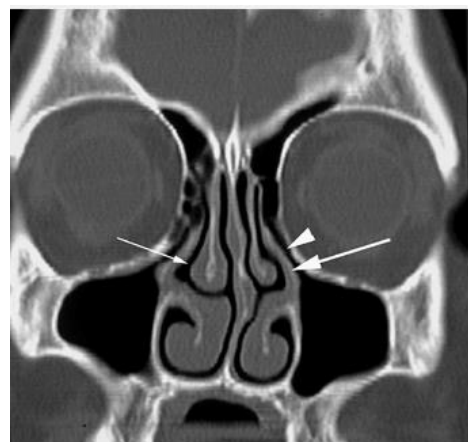Scans can be acquired using the sequential, single-slice technique (conventional CT) or a continuous spiral technique (helical CT). The axial base of

**Interpretation**

Normally aerated paranasal sinuses exhibit air density on CT scans—i.e., they appear black. The normal mucosal lining of the sinuses is not visualized. The



**Sagittal CT scan**



**Concha Bullosa**

**Indications for CT scan:**

**Gold standard for CRS\*Chronic rhinosinusitis \***


**Planning surgery or failed medical management**

**Clinical unresponsiveness to medical therapy**

**Immunosuppressed patient**

**Severe symptoms or signs**

**Life threatening complications \* CT and MRI for complication\***



**MRI for chronic rhinosinusitis:** Indicated for Disease Extension

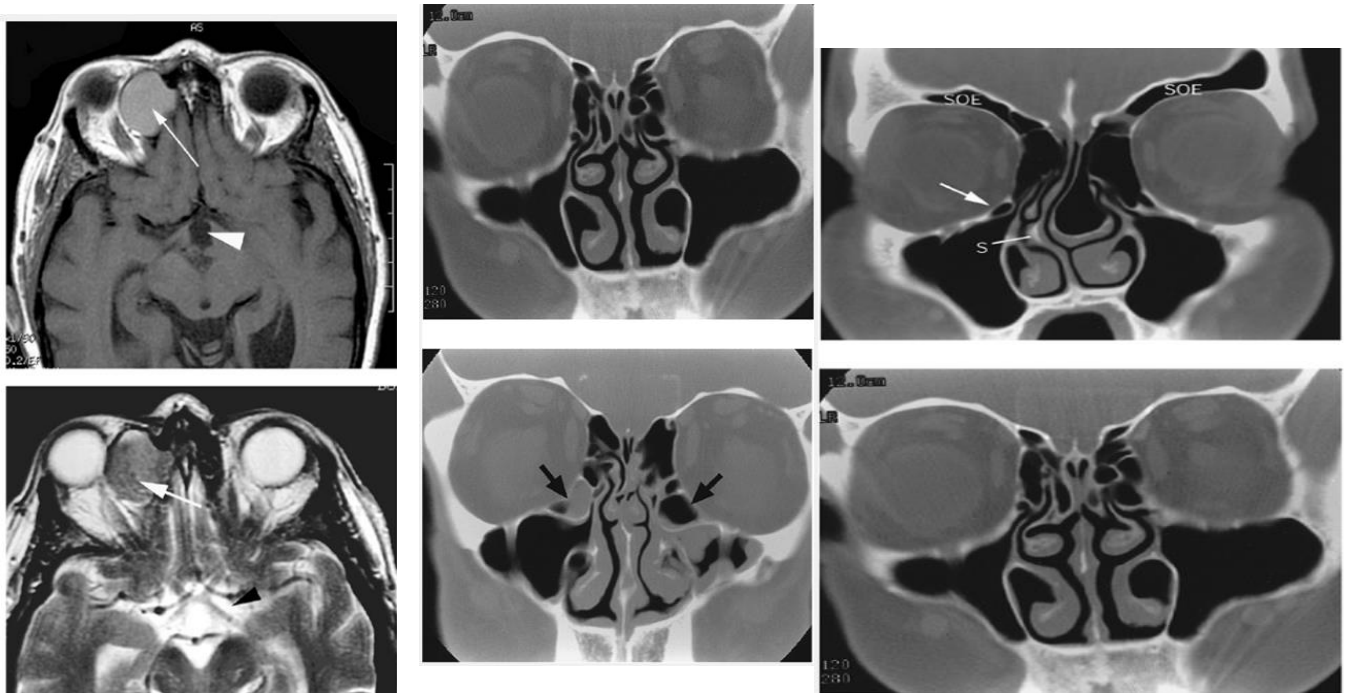
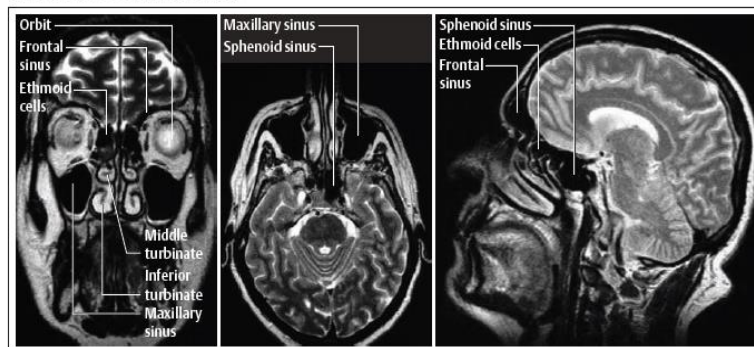


Fig. 2.10 MRI of the paranasal sinuses



a Coronal, b axial, and c sagittal magnetic resonance images.

**Treatment**

**Mainstay treatment is local intranasal corticosteroids**

**)Systemic steroids orally (Only given in chronic sinusitis**

**Antibiotics: given for 14 days**

**1st line: Amoxicillin, if the patient is penicillin allergic give Macrolides (Clarithromycin or Azithromycin)**

**-2nd line when 1st line treatment fails (Amoxicillin + Clavulanic acid) if the patient is penicillin allergic give Fluoroquinolones (Ciprofloxacin or Levofloxacin).**

**Next step is surgical treatment + Steroid is given after the surgery to reduce the inflammatory changes (e.g. scarring) during the process of healing.**

## **Surgical Treatment:**

**Conservative FESS “Functional endoscopic sinus surgery”.**

### **Advantages:**

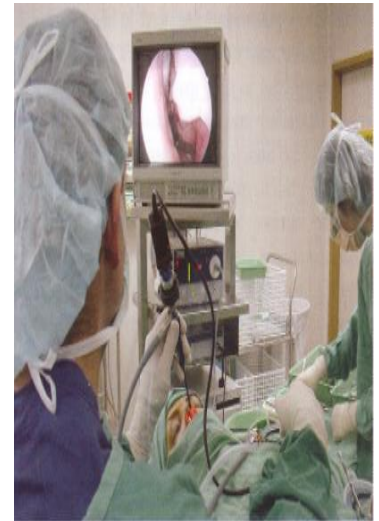**Superior visualization, better precision, preserves function and completeness.**

### **Disadvantages:**

**Requires one-handed technique, monocular vision.**

### **Contraindications:**

**Osteomyelitis, no evidence of paranasal disease on CT, inaccessible lateral frontal sinus disease.**



## **FESS Indications:**

### **Absolute:**

- Complete nasal obstruction in CF
- Antrochoanal polyp
- Intracranial or orbital complications
- Mucocoeles or mucopyocoeles
- Traumatic injury in optic canal
- Resistant dacryocystorhinitis-
- Fungal sinusitis
- Some meningoencephaloceles/neoplasms

### **Possible:**

- Persistent chronic rhinosinusitis that fails optimum medical treatment and after exclusion of systemic disease.
- Asthmatic exacerbations associated with rhinosinusitis.

## **Complications of sinusitis:**

### **Three main categories:**

Orbital (60-75%)

Intracranial (15-20%)

Bony (5-10%)

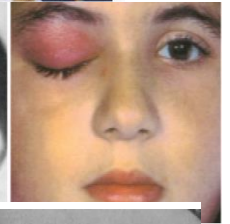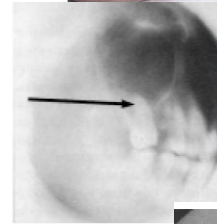
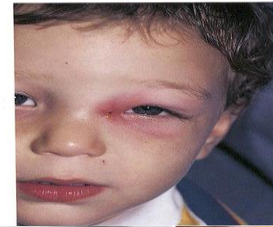### **Orbital Complications:**

“Chandler Criteria” Five classifications:

- Preseptal cellulitis\*Inflammatory edema\*
- Orbital cellulitis
- Subperiosteal abscess
- Orbital abscess
- Cavernous sinus thrombosis bilaterally.

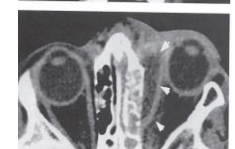
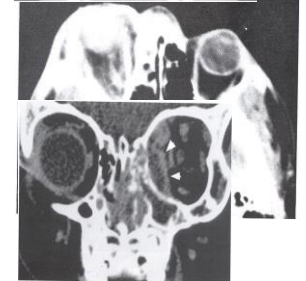
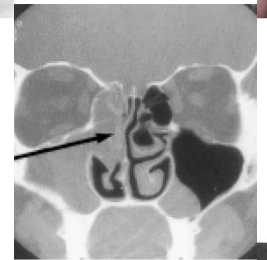
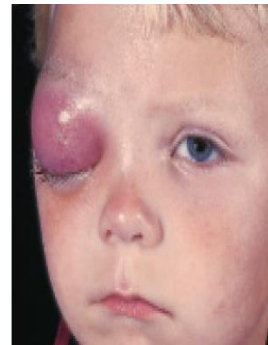### Stage I:

Periorbital inflammatory edema  
Obstruction of venous channels  
No vision loss  
No EOM limitation\*Extra-ocular muscle\*



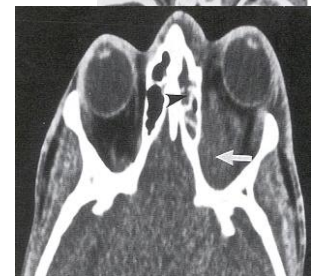### Stage II:

Orbital cellulitis with edema, chemosis, proptosis, pain  
No abscess  
Ophthalmoplegia may occur due to edema or spasm  
No visual loss.



### Stage III

Subperiosteal abscess  
Globe displaced laterally or downward  
Orbital cellulitis present with decreased EOM  
Vision decreased.



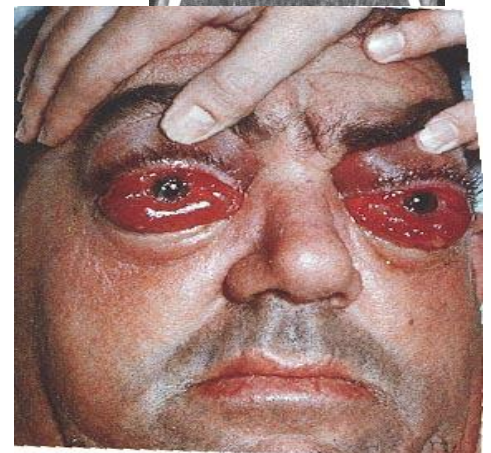### Stage IV

**Orbital abscess**  
**Severe proptosis and chemosis**  
**Usually no globe displacement**  
**Ophthalmoplegia present**  
**visual loss (13%) due to ischemia or neuritis**

### Stage V

**Cavernous sinus thrombosis** usually results from retrograde transmission through valveless veins leading to the cavernous sinus

**Progressive symptoms**  
**Proptosis and fixation**  
**CN II, IV, VI**  
**Meningitis**  
**High mortality**



### Intracranial Complications:

- Meningitis **“the most common”**
- Epidural abscess
- Subdural abscess
- Intracerebral abscess

- Cavernous sinus, venous sinus thrombosis

### **Mucoceles:**

Mucoceles are chronic, cystic lesions of the sinuses lined by pseudostratified epithelium

Expand slowly, often requiring many years

Etiology is debated either due to obstruction of ostia or to simple

Obstruction of minor salivary gland.

30% are idiopathic.

### **Others Complications:**

Osteitis, Pot's Puffy Tumor, Superior Orbital Fissure Syndrome, Orbital

Apex Syndrome Sinocutaneous Fistula.

### **Fungal sinusitis:**

- A fungal infection of the paranasal sinuses.

Fungal colonization of the upper and lower airways is a common condition, since fungal spores are constantly inhaled into the sinuses and lungs.

#### **1/Allergic fungal sinusitis:**

It's a hypersensitivity reaction against normal fungal flora which the patient is allergic to.

Treated by steroids only.

#### **2/Invasive fungal sinusitis:**

Can be acute or chronic.

**A - Acute invasive fungal sinusitis** is usually seen in immunocompromised patients (Very common in cancer patients who're receiving chemotherapy) and has a time course of days to few weeks.

It is very dangerous and should be detected and treated early, otherwise the patient may die.

Those patients are usually hospitalized and are very sick with fever, cough, nasal discharge, headache, and mental status changes.

**B - Chronic invasive fungal sinusitis** is usually seen in patients who are less immunocompromised with a time course greater than 3 months. Patients with fungal sinusitis in general are immunocompromised, usually due to uncontrolled diabetes, cancer, HIV, organ transplantation or using systemic or intranasal glucocorticoids.

### **Signs and symptoms:**

Pain, Obstruction, Discharge, fever, dark ulcers within the septum, turbinates, or palate due to ischemia. In the late stages, signs and symptoms of cavernous sinus thrombosis are present.

#### **Diagnosis:**

- Early nasal endoscopy and biopsy of affected tissues once you suspect fungal sinusitis (**Very important**), culture of the specimen is usually positive.

- CT or MRI: Assessing the extent of infection.

#### **Treatment:**

1/Aggressive **endoscopic debridement** including the orbit if involved (The orbit may be removed completely, that's why you need to diagnose the patient correctly by a biopsy and differentiate it from bacterial sinusitis).

2/IV antifungal medications (**Amphotericin B**).

3/Leukocytes transfusion.

4/Granulocyte-macrophage colony-stimulating factor (GM-CSF): Given to stimulate WBCs release from bone marrow.

**Always remember: Sinonasal symptoms in an immunocompromised patient is fungal sinusitis until proven otherwise.**

### **Allergic fungal sinusitis:**

**Inflammatory process with nasal polyposis (often unilateral) and eosinophilic mucin.**



**Histologic examination of the mucin is diagnostic if it shows hyphae present in the eosinophilic mucin.**

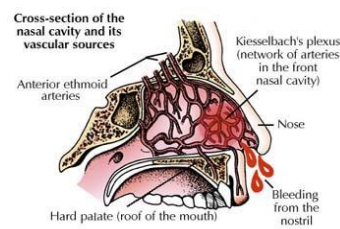
- ❖ **The pathophysiologic basis for AFS is thought to be a hypersensitivity reaction to the fungi growing in the mucin.**

**Fungal cultures may not always be positive and generally show a dematiaceous fungus such as *bipolaris* or *curvularia***

## **Epistaxis:**

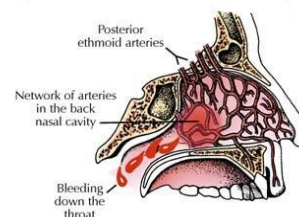
### **Bleeding from the nose.**

- Very common, ranges from mild one to very severe  
Anatomical importance Little's area (**Kiesselbach's plexus**), a round area located at the tip of the nose specifically the most anteroinferior part of nasal septum, formed of anastomosis between four arteries.



### **Local Causes of Epistaxis:**

- Nasal trauma (nose picking, foreign bodies, forceful nose blowing)
- Allergic, chronic or infectious rhinitis
- Chemical irritants
- Medications (topical)
- Drying of the nasal mucosa from low humidity
- Deviation of nasal septum or septal perforation
- Bleeding polyp of the septum or lateral nasal wall (inverted papilloma)
- Neoplasms of the nose or sinuses
- Tumors of the nasopharynx especially Nasopharyngeal Angiofibroma.-
- Vascular malformation.-



### **Systemic Causes of Epistaxis:**

- Systemic arterial hypertension
- Endocrine Causes: pregnancy, pheochromocytoma
- Hereditary hemorrhagic telangiectasias**
  - Hepatic disease
  - Blood diseases and coagulopathies such as Thrombocytopenia, ITP, Leukemia, and Hemophilia.

### **Types of Nosebleeds:**

#### **ANTERIOR**

- Most common in younger population-
- Usually due to nasal mucosal dryness
- Usually controlled with conservative measures

#### **POSTERIOR**

- Usually occurs in older population-
- HTN and SYS diseases are common contributing factors
- Significant bleeding in posterior pharynx
- More challenging to control.

### **Patient History:**

- Previous bleeding episodes
- Nasal trauma
- Family history of bleeding
- Hypertension - current medications and how tightly controlled
- Hepatic diseases
- Use of anticoagulants

## Physical examination:

Measure blood pressure and vital signs.

Apply direct pressure to external nose to decrease bleeding

Use vasoconstricting spray mixed with tetracaine in a 1:1 ratio for topical anesthesia

### Identify the bleeding source

## Investigations

**CBC** (Look for anemia and platelet count)

**Coagulation profile** (PT/PTT and Coagulation factors).

**Cross matching** (If the patient present to ER with active bleeding to save time when the patient needs blood transfusion)

**CT scan** (Helps in detecting the etiology, e.g. nasal tumor as a source of Bleeding and pre-surgical assessment.

**Angiography** (Diagnostic and Therapeutic "Embolization to block the Bleeding source.

## Treatment:

### 1- Initial treatment

Estimate the Blood loss

Vital sign ( tachycardia, low blood pressure )

Blood workup ( Hematocrit )

**In case of serious trauma, start managing the patient by ATLS protocol + prepare 2**

**Large bore IV lines (for blood, packed RBCs or Cryoprecipitate).**

**For stable patients, packing "By a gauze**

### 2- Prevention

-Try to avoid any trauma even minor ones

-Keep allergic rhinitis under control, Use saline nasal spray frequently to cleanse and moisturize the nose

-Humidification and lubrication: Consider using a humidifier in the bedroom

-Self-management: Teach the patient to compress the tip of the nose immediately when bleeding starts and wait for 5 minutes, then leave it without washing to prevent rebleeding and bend the head down.

### 3-Mainstay treatment

Packing (Can be absorbable (for patient with bleeding tendency) and non-absorbable)

Most patients may be treated as outpatients but hospital admission and observation should be strongly considered when a posterior pack is used

**Chemical cauterization (By silver nitrate)**

"Be very cautious not to cauterize both sides otherwise patient will end up with nasal septal necrosis and perforation due to ischemia"

Instead, do one side and wait for healing then the other side can be done as well.

Electrical cauterization (Very painful, try to avoid it as much as possible)-

-Ligation (Under Rhinoscope, safe procedure, most commonly to the sphenopalatine artery)

-Embolization (Under Angiogram, it has risk of blindness)

### **Treatment of Posterior Epistaxis:**

-IV pain medication and antiemetics may be helpful.

- Use topical anesthetic and vasoconstrictive spray for improved visualization and patient comfort.

-Balloon-type epistaxis devices often easiest.

-Foley catheter or other traditional posterior packs may be necessary.