

---

# History and Examination

---



2017-2018

## Objectives:

- To know the basic ophthalmic anatomy and physiology.
- To recognize assessment and management of common ophthalmic diseases.
- To know how to handle common ophthalmic emergencies.
- To handle simple ophthalmic diagnostic instruments.
- To be aware of common ophthalmic

## Done By:

Lamyaa Althawadi

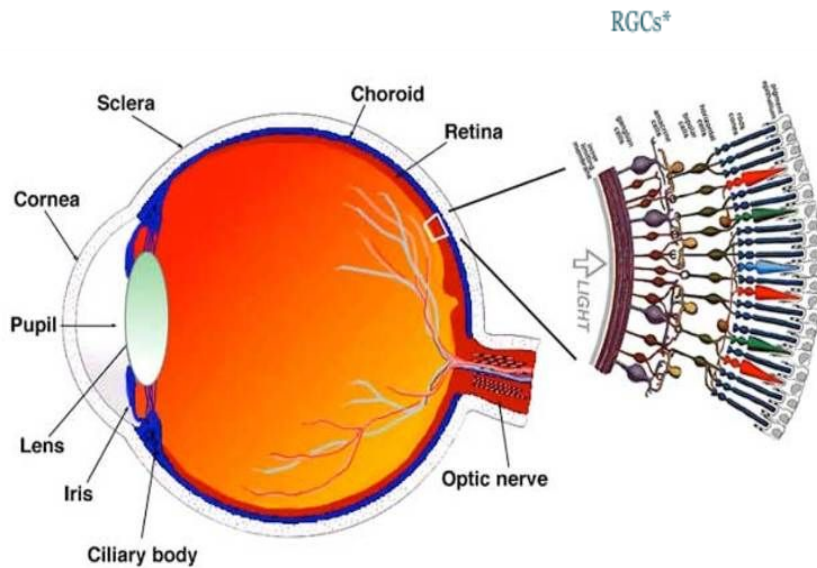
Rawan Ghandour

Resources: Team 433, Doctors Notes.

[Editing File](#)

433 Team, Lecture  
**Important**  
Doctor's Notes  
Explanation

# The Visual Pathway



- **Phototransduction:** By photoreceptors (rods and cones)
- **Image processing:** By horizontal, bipolar, amacrine and RGCs
- **Output to optic nerve:** Via RGCs and nerve fiber layer

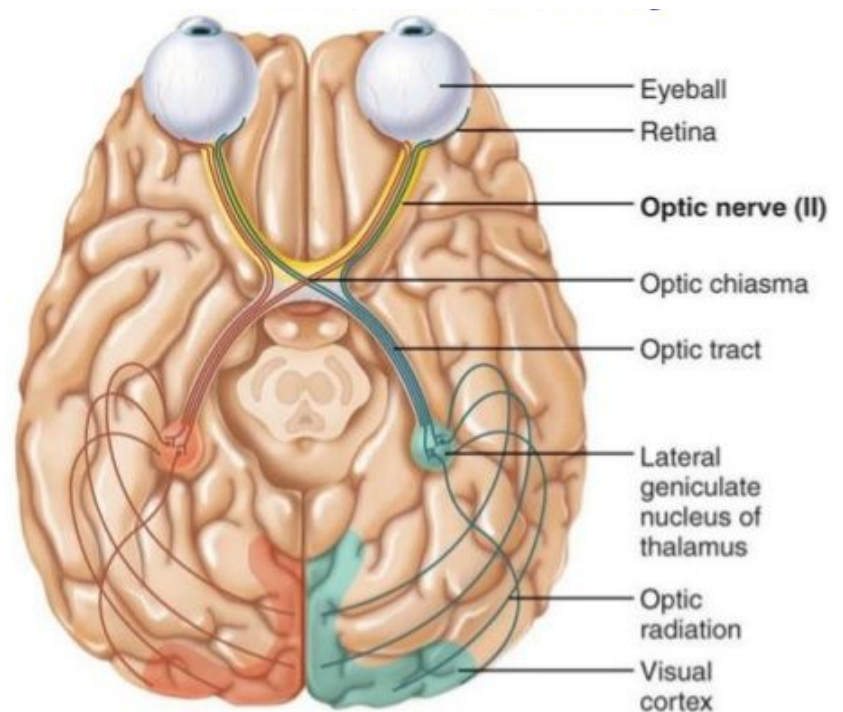
Light enters the eye via a refractive media called cornea, then pass's through anterior chamber, lens, and vitreous then stimulates the retina photoreceptors posteriorly (Rods and cones). Through a series of other retinal cells, the end result is that the RGCs stimulated, then it will send it's axon or fibers, in the nerve fiber layer to the optic disc and then down to the optic nerve.

In order to see, you need clear media, but if it's not clear it called media opacity (so in OSCE the absence of red reflex in ophthalmoscopic exam is called **media opacity**)

**Media opacity** caused by ( hyphema, scar, cataract, vitreous haemorrhage, retinal detachment)

From the optic nerve, about half of the fibers cross over at the chiasm to the opposite optic tract, and the other half remains at the same side. the fibers in the optic tract synapse in the lateral geniculate nucleus of the thalamus. neurons in the lateral nucleus projected to the occipital lobe to the primary visual cortex. From there, there is further processing with projections to other cells in visual cortex and elsewhere. result in conscious visual perception.

\*This pic may come in exam



\*Retinal Ganglion Cells

# The importance of eyes:

- Diagnostically and functionally, it is the most important **square inch** of the body surface.
- The eye is so intimately connected with the rest of the body that it reveals enormous amount of general information.
- Eye is the only part of the body where blood vessels and central nervous system tissues can be viewed directly.

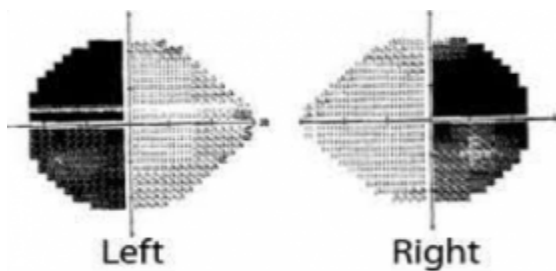
## 1. Neurological connections:

- The 12 cranial nerves provide us with a large part of our information about the brain. Of these, the eye examination evaluates CN II, III, IV, V, VI, VII, VIII ( 7 cranial nerves ).
- Provides information about the autonomic pathways. (sympathetic/parasympathetic)

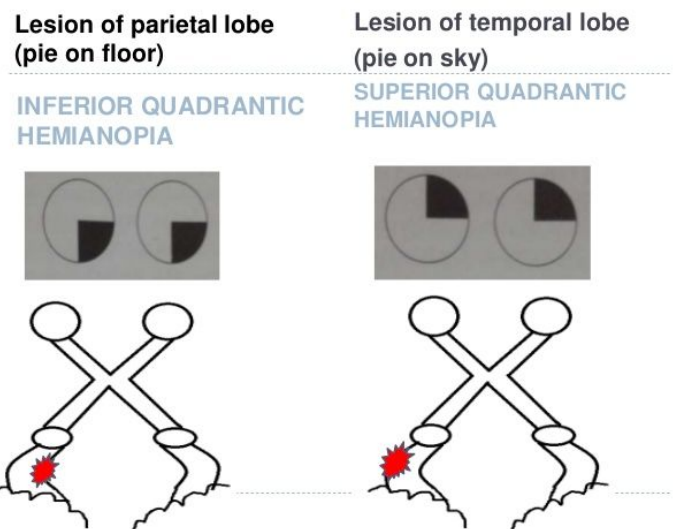
**Remember** :sympathetic : dilatation of the pupil /Parasympathetic : constrict the pupil.

- Best known connection between the brain and the eye is the optic nerve (ON)
- Visual pathway, which extends from front to back across the brain can be studied easily and safely using perimetry. It can differentiate accurately between lesions of the temporal, parietal and occipital lobes. In SAQ there was question> visual field with quadrantic defects. so it will be either **temporal** or **parietal lobe**. if there is lesion in the **temporal lobe** = pie in the **sky**. If the lesion in the **parietal lobe** = pie in the **floor**
- **Optic Nerve** has important clinical relationships to the pituitary gland, the middle ventricles, the venous sinuses, the meningeal and bony structures of base of the skull

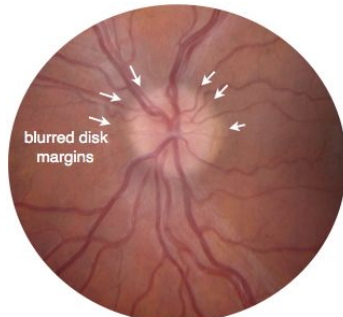
### Pituitary gland and Visual Field



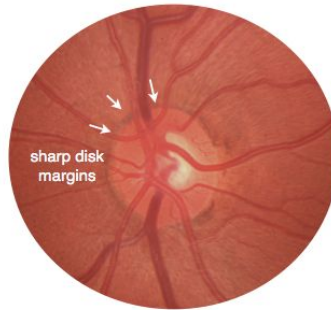
It may come in SAQ :  
you know that the fiber decussate in optic chiasma so if the lesion was pituitary gland Adenoma so the defect will be **bitemporal hemianopia**.



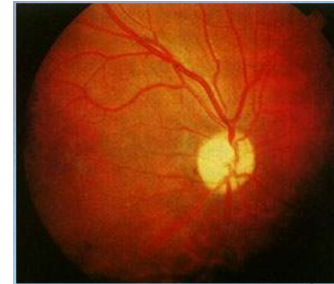
- **Optic Nerve** has the diagnostically useful capability of swelling with  $\uparrow$  ICP (papilledema) optic discs edema (**unclear disc margin** best answer will be disc edema in OSCE, rather than Papilledema) to detect increase in ICP help to diagnose **brain tumor**.
- **Optic Nerve** could be visibly pale (**optic atrophy**) when its nerve fibers damaged at any point from Retina  $\rightarrow$  LGB.



**Papilledema**

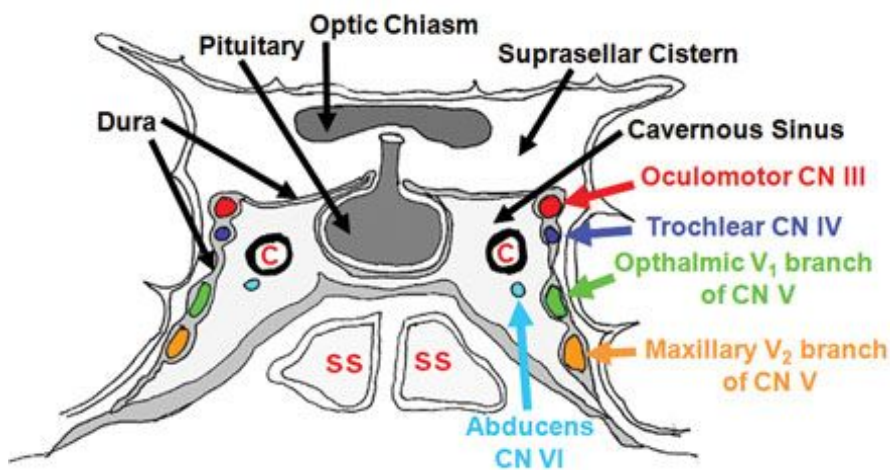


**Normal Optic Disk**



**Optic atrophy**

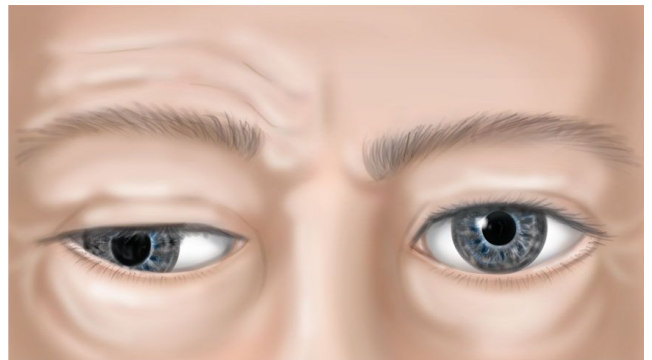
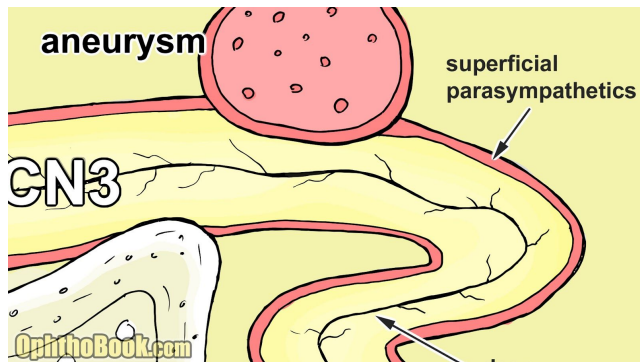
- Study of the cranial nerves III, IV, V, VI can evaluate the brain stem, cavernous sinus, apex of orbit
- Unilateral dilated pupil after head injury can occur due to pressure on pupil constrictor fibers of CN III.\* parasympathetic fibers run with oculomotor nerve.
- CN VI involved in mastoid infection (petrous ridge)
- Parotid gland, Inner ear disease  $\rightarrow$  CN VII.
- Nystagmus  $\rightarrow$  CN VIII



**Very important pic:** content of cavernous sinus

- mandibular nerve and third division of trigeminal nerve pass through foramen rotundum.
- Abducens nerve is longest and important in trauma so in (six nerve palsy) you have to ask about trauma.

- phacomorphic glaucoma ( cataract induced glaucoma by increase lens size that lead to increased IOP ) > so severe pain
- optic neuritis



- remember all the muscle of the eye are supplied by third cranial nerve except lateral rectus and superior oblique, so there will be restriction in all eye movement except Lateral rectus and superior oblique, that will be represented in **lateral movement of the eye** and **ptosis** .
- CN III is composed of 2 parts:
  - Superficial parasympathetic pupillomotor Usually affected by compression. ( aka dilated surgical 3rd nerve palsy)third nerve palsy with dilated pupil mean the lesion affect superficial part so that mean there timer aneurysm >> emergency condition
  - Deep motor Usually affected by medical causes like DM\HtN (aka surgical 3rd nerve palsy) third nerve palsy without dilated pupil >> the lesion affected the blood supply, like in blood, systemic disease ( hypertension , diabetes .. )

#### How do we know if CN IV is involved in addition to CN III ?

- Patient will not be able to **look down** (damaged CN III)
- Eyes will **not intort** (damaged CN IV)

#### ❖ Focal brain lesions:

- Visual Field defect
- Vascular occlusions
- Hemorrhage
- Neoplasm

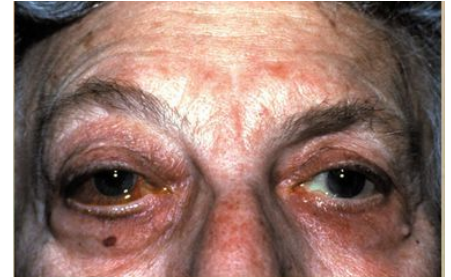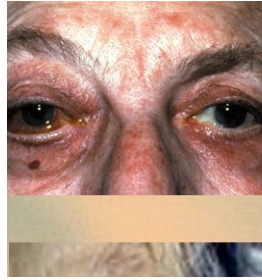#### ❖ Diffuse brain lesions:

- Infections
- Demyelinating disorders → nerve damage.

## 2. Vascular connections:

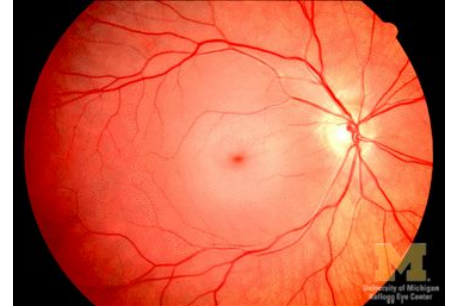
### ❖ Venous flow disorder:

- cavernous sinus thrombosis
- carotid – cavernous fistula (it has the same clinical presentation of cavernous sinus except that it has increased IOP, and Thrill+pulsating eyes (Prue))
- Bilateral carotid artery aneurysm Binasal Hemianopia.
- orbital congestion
- Arterial emboli can reach the retina from carotid artery, heart valves, subacute endocarditis, also traumatic bone fracture. Came in the exam: central retinal artery occlusion / history: of multiple bone fracture, what is the diagnose? Retinal central artery fat embolism.



### ❖ Specific disease of the vessels like:

- PAN, HTN, temporal arteritis (Giant cell Arteritis)
- investigate the patient with ESR, CRP, BIOPSY. (Best initial investigation is ESR, followed by C-reactive protein, then Biopsy (a negative biopsy does not rule out the dx due to the focal and segmental nature of the infiltrates))
- When a patient complains of any changes in vision, rule out DM first!

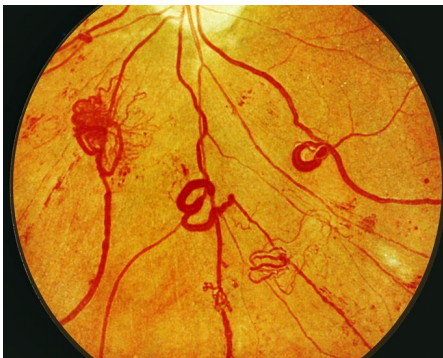


### ❖ Hematological disorders:

- All types can manifest in the fundus. (Anemia, leukemia, AIDS)
- AIDS you can also diagnosed by cotton wool spots in the retina (ischemia of the nerve fiber in the retina)

### ❖ metabolic disorders (Almost all can affect the eye)

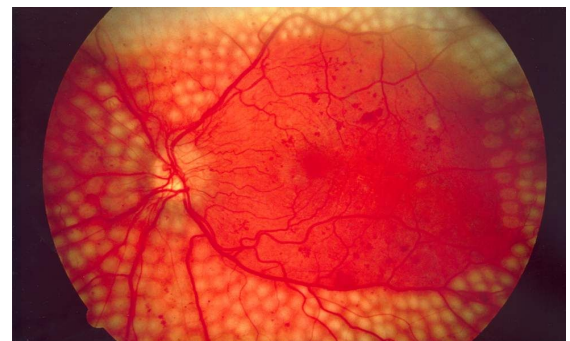
- **DM**: Diabetic Retinopathy, cataract, Refractive Errors, ophthalmoplegia. (PDR) treated with pan-retinal laser photocoagulation
- **Hypoparathyroidism**: cataract
- **Wilson's disease**. (Kayser-Fleischer corneal ring (a brownish-yellow ring around the cornea of the eye))



A

A New dilated tortuous vessel in the retina in diabetic retinopathy

B This pic came in OSCE: Retinal Scars from retina lesser (this pic is after treat above condition)



B

### 3.Thyroid eye disease:

- Also known as infiltrative ophthalmopathy "Graves ophthalmopathy" or thyroid eye disease
- Since they have increased IOP we perform visual field exam
- Commonest cause of unilateral and bilateral **proptosis, Exophthalmos, Lid retraction.**

### 4.Infections:

- Syphilis
- Toxoplasmosis
- Rubella

### 5.Mucocutaneous disorders:

SJS, pemphigus

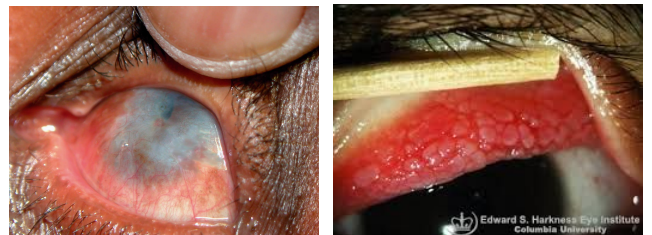
### 6.Elastic tissue:

(Pseudoxanthoma elasticum)

### 7.Allergy:

Vernal keratoconjunctivitis (VKC)

known by Spring catarrh الرمد الربيعي "Commonest eye allergy in KSA Treat with steroids and antihistamines. Can cause blindness. Why? Chronic use of topical steroids lead to increased IOP ( steroid induced glaucoma)



### 8.Chromosomal abnormalities:

Trisomy:13,15,21.

### 9.Eye poisoning

- Morphine addict lead to meiotic pupil
- Lead poisoning, vitamin A intoxication lead to papilledema
- Coma+pinpoint pupil = Morphine overdose or Pontine hemorrhage ( Differentiate between them by hyperpyrexia with Pontine hemorrhage)
- 90% of our information reaches our brain via sight
- Unfortunately, of all the parts of the body, the eye is the most vulnerable to minor injury.

# History Taking & Physical Examination

## History:

- It is gathering information process from the patient guided by an educated and active mind
- It is a selective guided and progressive elicitation and recognition of significant information
- History by skilled person can arrive at the proper diagnosis in 90% of patient
- It gives vital guidance for -physical examination -laboratory work -therapy
- Failure to take history can lead to missing vision or life threatening conditions

**chief complaint:** (The patient's own words)

**\*She can not see with right eye**

You should not come to conclusion that her problem is nearsightedness and write down(Myopia of RE). The patient needs will not be satisfied until he\she has received an acceptable explanation of the meaning of the chief complaint and its proper management

## History of the present illness

- Detailed description of the chief complaint to understand the symptoms and course of the disorder
- Listen and question and then write down in orderly sequence that make sense to you
- The time sequence (when, how fast, what order event occur?)
- Frequency and intermittency
- Location and laterality
- Severity
- Associated symptoms
- Documentation (old record and photo indicate ptosis, proptosis and VII N palsy.

Examples:

Gradual painless decrease vision both eyes for 1y Sudden painless decrease vision RE for 10 min

**Cannot see with right eye(RE)!!**

- Only distance vision blurred?
- Blind spot is present in the center of visual field (VF)?
- Right side of visual field of the RE lost?
- Right VF of both eye lost?
- A diffuse haze obscures the entire field of RE?
- Each of these has different diagnostic implication
- Most patient has difficulty providing precise and concise description



### Disturbance of vision:

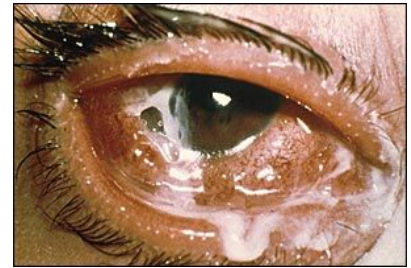- Blurred or decreased central vision
- Decreased peripheral vision (glaucoma)
- Altered image size (micropsia, macropsia and metamorphopsia)
- Diplopia (monocular and binocular)
- Floaters
- Photopsia (flash of light)
- Color vision abnormalities
- Dark adaptation problems
- Blindness (ocular and cortical)
- Oscillopsia (shaking of images)

### DDx of Acute Visual Loss: (Always remember these 4 )

1. Age related macular degeneration (AMD)
  2. Vascular occlusion (DM, HTN)
  3. Retinal detachment
  4. Acute glaucoma
- **Morning** visual disturbances > Eye dryness
  - Blurring of vision for **20 min** > Migraine aura
  - Patient still complains of problems with his\her vision although all his exams and investigation are **normal** > Do visual field exam (could be stroke!)
  - There are two types of color blindness. complete and partial (most common), both are diagnosed by Ishihara's test
  - "Convergence insufficiency" is a condition that can cause pain especially in pediatric patients.
  - Refractive errors never cause pain. Ciliary injection (red eye) is mainly caused by 4 things:
    1. Acute conjunctivitis
    2. Acute iritis
    3. Acute glaucoma
    4. Acute keratitis (*corneal ulcer; a combination of conjunctivitis and iritis*)

### Ocular pain or discomfort:

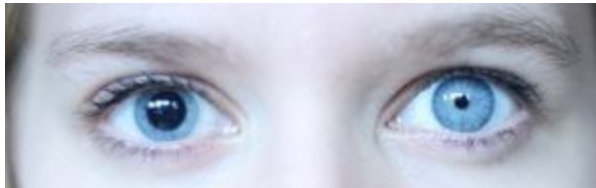
- Foreign body sensation
- Ciliary pain (*aching, severe pain in or around the eye, often radiating to the ipsilateral forehead, molar area*) Photophobia
- Headache
- Burning
- Dryness
- Itching: *patient rub the eye vigorously (allergy)*
- Asthenopia (*eye strain*)
- Abnormal ocular secretions
- Lacrimation, epiphora
- Dryness
- Discharge (purulent, mucopurulent, mucoid, watery)



### Abnormal ocular secretions:

- Lacrimation, epiphora
- Dryness
- Discharge (purulent, mucopurulent, mucoid, watery) Redness, opacities, masses

### Anisocoria



### Family history

- Many eye conditions are inherited .Examples: RE, glaucoma, strabismus, retinoblastoma, neoplastic, vascular disorders
- Familial systemic disease can be helpful in ophthalmic evaluation and diagnosis. Examples: Atopy, thyroid diseases, DM, certain malignancies
- Ask about any eye problem in the family background?
- Ask specifically about corneal diseases, glaucoma, cataract, retinal diseases or other heritable ocular conditions.

### Systematic review

- Ask questions designed to confirm or exclude your tentative diagnosis
- significant positive      -significant negative “Significant is equal to expected”
- Predict the physical and lab findings likely to be present
- Any discrepancy between the history and physical examination requires explanation

## Ophthalmic Examination:

### The purpose is to evaluate:

- Function: Visual / nonvisual (eye movement and alignment)
- Anatomy: the globe , / Adnexa (lids+periocular tissue), / Orbit
- 

### vision:

- Vital sign (MUST)
- Good vision: intact neurological visual pathway, / structurally healthy eye, / Proper focus
- Subjective

#### 1. How to test it?

- Display of different- sized targets shown at a standard distance from the eye
- Snellen chart
- 20/20, 6/6
- Uncorrected,corrected

#### 2. Testing poor vision

If the patient is unable to read the largest letter <(20/200)

- Move the patient closer e.g.5/200

If patient cannot read:

- Count fingers (CF)
- Hand motion (HM)
- Light perception (LP)
- No light perception (NLP)

## Ophthalmic Examination:

- Visual acuity
- External examination
- Motility and alignment
- Pupil examination
- Slit lamp biomicroscopy
- Tonometry
- Ophthalmoscopy
- Gonioscopy

(To observe the anterior chamber angle if the angle is open or narrow or if the eye can be dilated safely. Its most important function is in determining whether a patient's ↑IOP is due to a "open angle" or "closed angle" mechanism)

- Retinoscopes

## External Examination:

- Evaluate by gross inspection and palpation
- Ocular adnexa. (lid, periocular area)
- Skin lesions, growths, inflammatory lesions
- Ptosis
- Proptosis, exophthalmos, enophthalmos
- Palpation of bony rim, periocular soft tissue
- General facial examination e.g. enlarged preauricular lymph node, temporal Retinoblastom. Very artery prominence.

## ocular motility:

Evaluate: 1-Alignment 2-movement

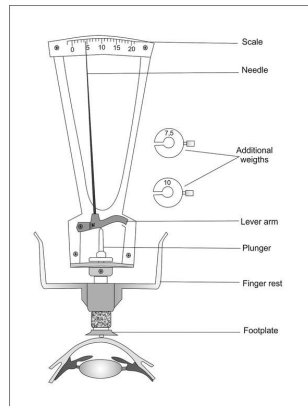
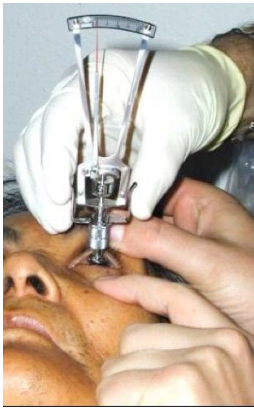- Follow a target with both eyes in each of the four cardinal directions of gaze.
- Note:
  - speed /smoothness
  - range
  - symmetry
  - unsteadiness of fixation (e.g nystagmus)
- Examine for size, shape, reactivity to both light and accommodation.
- Direct response and consensual response
- Afferent pupillary defect ( **lesion in optic nerve caused by glaucoma , optic nerve compression , diabetic retinal detachment**)(APD/Marcus Gunn pupil). **you should know exactly how to do it for OSCE!**
- Efferent pupillary defect: **third nerve palsy**
- Pupillary abnormalities:
  - neurologic disease
  - previous inflammation–adhesion -acute intraocular inflammation
  - spasm
  - atony
  - prior surgical trauma
  - effect of systemic or eye medication -benign variation of normal
- Is a table-mounted binocular microscope with special illumination source.
- A linear slit beam of light is projected onto the globe – optic cross section of the eye

## Tonometry

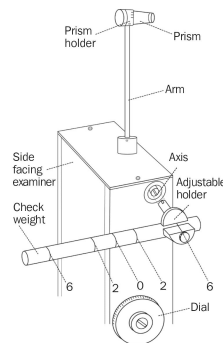
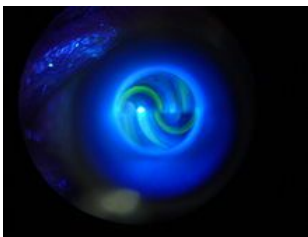
- Tonometry is a procedure performed to determine the intraocular pressure(IOP). It is an important test in the evaluation of patients at risk from glaucoma. Most tonometers are calibrated to measure pressure in millimeters of mercury(mmHg).
- The globe is a closed compartment with constant circulation of aqueous humor.
- This maintains the shape, and relatively uniform pressure within the globe
- Normal pressure 10–21 mmHg

## Types of Tonometry

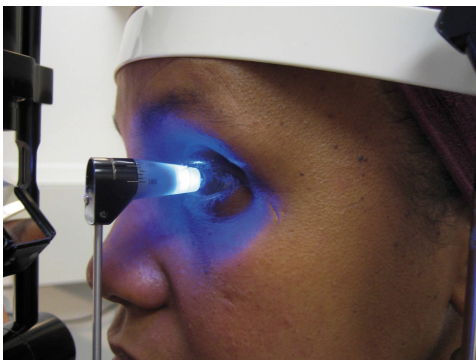
1. Schiotz tonometer **Very important for SAQ! Please make sure you spell the full name right.**



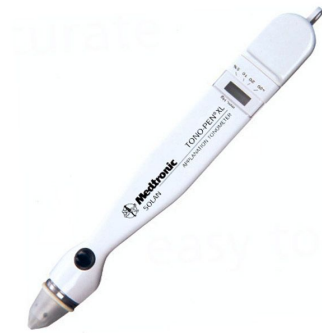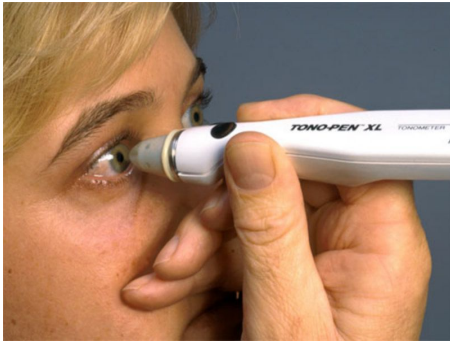2. Goldman tonometer



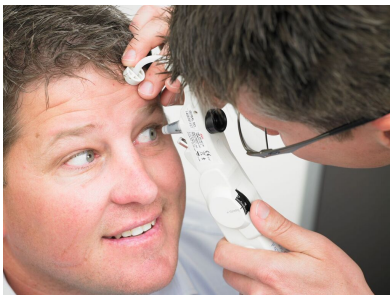3. Glodmann applanation tonometer



#### 4. Tonopen tonometer



#### 5. Perkin tonometer



#### 6. Air-puff tonometer

##### Glaucoma:

Diagnosis made by checking:

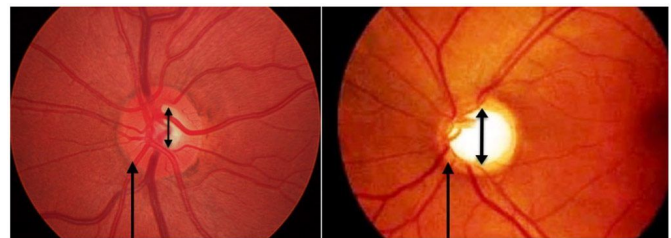

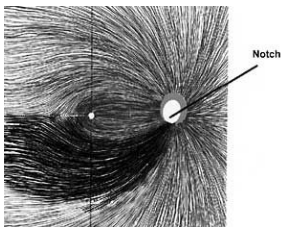
1- IOP

2- Disc cupping

Came in the exam : large cup , and the pressure is 40 ( normal 10-21 )

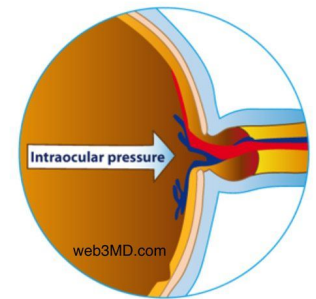
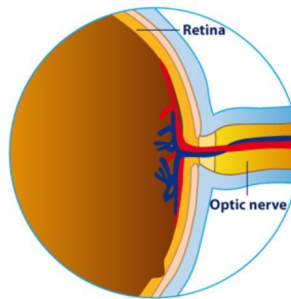
**How to confirm diagnosis ??** Visual field

3- Visual field defect



Healthy eye with a normal optic nerve head

Glaucoma eye with glaucomatous cupping of the the nerve head



Neurological defects doesn't respect horizontal/vertical lines of visual field

## Ophthalmoscopy:

### Direct ophthalmoscopy:

- handheld instrument.
- standard part of the general medical examination
- Portable

### Indirect ophthalmoscope

1. provide much wider field of view
2. less magnification (3.5X with 20D lens)
3. brighter light source – better view.
4. Binocular – stereoscopic view.
5. Allow entire retina examination till the periphery.

#### Disadvantage:

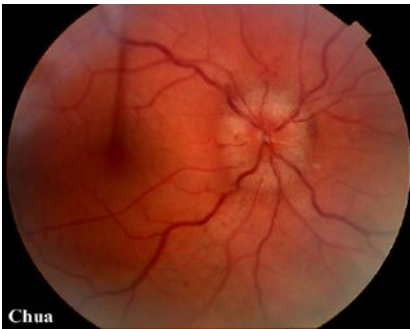Inverted retinal image.

Brighter light is uncomfortable to the patient.

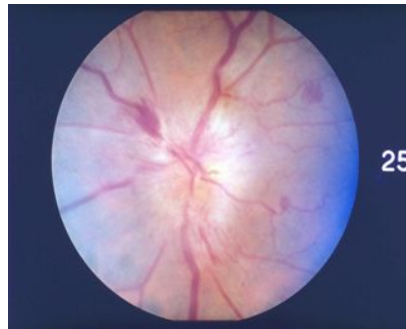
#### Magnification :

Direct : 3-5

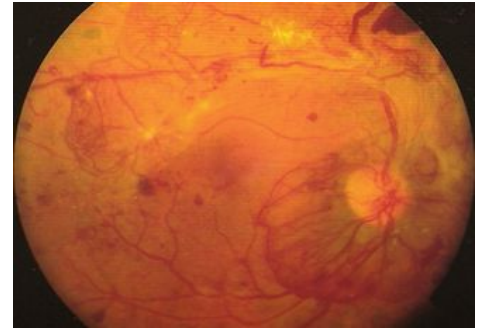
Indirect : 15



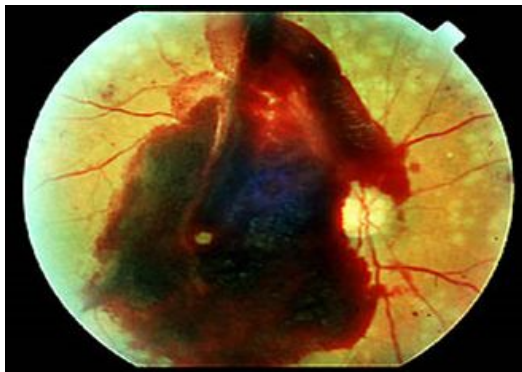
**Disc Edema**



**Retinal Hemorrhage**



**Proliferative Retinopathy**



**Vitreous Hemorrhage**

special lenses:

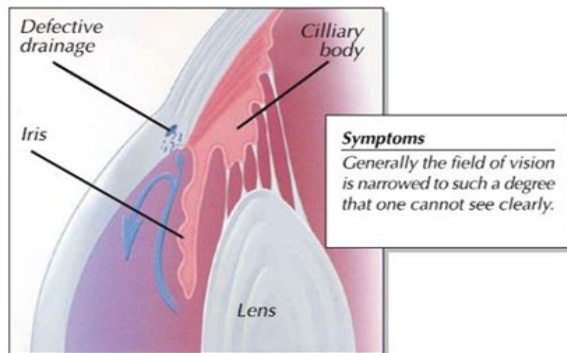
- Goniolens
- Other lenses allow evaluation of the posterior segment



**Importance of Gonioscopy**

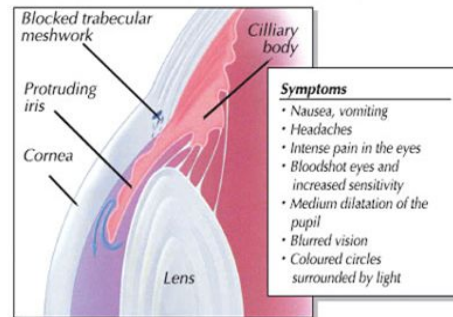
important in evaluat anterior chamber : Open angle in chronic glaucoma,Closed angle in acute glaucoma

**OPEN ANGLE GLAUCOMA**



The angle is open but drainage is defective.

**CLOSED ANGLE GLAUCOMA**



The angle between the iris and the cornea narrows or closes, blocking the drainage of the aqueous humor.

**Retinoscope**

