



Ocular Pharmacology & Toxicology



2017-2018

Objectives:

1. General pharmacological principles
 - A. -Pharmacodynamics
 - B. -Pharmacokinetics
 - C. -Factors influence drug penetration
 - D. -Ocular drug preparations
2. Ocular pharmacotherapeutics
3. Ocular side effects of systemic drugs

Done By:

Rawan Ghandour

Lamyaa Althawadi

Resources: Team 433, Doctors Notes

[Editing File](#)

433 Team
Important
Doctor's Notes
Explanation



❖ General pharmacological principles:


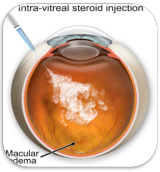
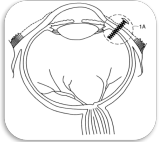

1- Pharmacodynamics :

- Mechanism of action : **it's the effect of the drug in certain area**
- Most drugs act by binding to regulatory macromolecules
- A. Neurotransmitters
- B. Enzymes
- C. Hormonal receptors
- Agonist or antagonist (**receptor level**)
- Activator or inhibitor (**enzyme level**)

2- Pharmacokinetics :

- it is the absorption, distribution, metabolism, and excretion of the drug : **how the drug reach particular area and how it will be excrete**
- A drug can be delivered to ocular tissue **as**:

locally	Eye Drop 	<ul style="list-style-type: none"> ● most common , best way ,can use it during day time ★ one drop = 50 µl , more than third of the drug will wash out so one drop is more than enough ★ volume of conjunctival cul-de-sac 7-10 µl ● measures to increase drop absorption , so increase effect : <ul style="list-style-type: none"> → wait 5-10 minutes between drops , it will decrease diluted effect → compress lacrimal sac , that will decrease systemic effect → keep lids closed for 5 minutes after instillation , increase local effect and decrease systemic effect ● doesn't reach in high concentrate behind the lense ● once you the bottle , if it preserved like in fridge you can use it till expiry date , if it outside the fridge then you can use for 1 month only
	Ointments 	<ul style="list-style-type: none"> ● Increase the contact time of ocular medication to ocular surface thus better effect ● It has the disadvantage of vision blurring ● The drug has to be high lipid soluble with some water solubility to have the maximum effect as ointment ● it cover the eye at the bed time
	<p>eye drop and ointments likely to affect anterior segment of the eye (cornea , conjunctiva , anterior chamber , the iris , lens and posterior chamber , but not any further so , we need to use injection around the eye or directly to the eye</p>	
	Periocular injections	<ul style="list-style-type: none"> ● Reach behind iris-lens diaphragm better than topical application <p>e.g. subconjunctival, subtenon, peribulbar, or retrobulbar</p> <ul style="list-style-type: none"> ● This route bypass the conjunctival and corneal epithelium :

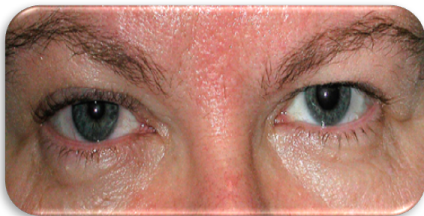
		<p>good for drugs with low lipid solubility (e.g. penicillins)</p> <ul style="list-style-type: none"> ● Also steroid and local anesthetics can be applied this way ● Use it when higher concentration , longer duration wanted in the anterior chamber so inject behind the eye , and use it in critical condition like Endophthalmitis which is (inflammation inside the eye) and give antibiotic ● Use short needle or you will puncture the glop
	<p>Intraocular injections</p> 	<ul style="list-style-type: none"> ● Intracameral or intravitreal <ul style="list-style-type: none"> → intracameral acetylcholine (miochol) during cataract surgery → Intravitreal antibiotics in cases of endophthalmitis → Intravitreal steroid in macular edema → Intravitreal anti-VEGF for DR
	<p>Sustained-release devices</p>  	<ul style="list-style-type: none"> ● These are devices that deliver an adequate supply of the medication at a steady-state level ● e.g. <ol style="list-style-type: none"> 1. Ocusert delivering pilocarpine 2. Timoptic XE delivering timolol 3. Ganciclovir sustained-release intraocular device 4. Collagen shields 5. Liposomes
<p>systemic</p>	<ul style="list-style-type: none"> ● Oral or IV ● Factor influencing systemic drug penetration into ocular tissue: <ol style="list-style-type: none"> 1. lipid solubility of the drug: more penetration with high lipid solubility , Major factor : more lipid binding less effect 2. Protein binding: more effect with low protein binding 3. Eye inflammation: more penetration with ocular inflammation , note -: second generation cephalosporin in normal situation doesn't cross blood brain barrier (BBB) in adequate concentration but in meningitis even second generation can cross BBB so high concentration in the eye 	

3-Factors influencing local drug penetration into ocular tissue:

Drug concentration:	The higher the concentration the better the penetration e.g. pilocarpine 1-4%
Viscosity:	Higher viscosity increases drug penetration by: <ul style="list-style-type: none"> • <u>increasing the contact time with the cornea</u> • <u>altering corneal epithelium</u>
Lipid solubility:	<u>The higher lipid solubility the more the penetration</u> (lipid rich environment of the epithelial cell membranes)
pH:	the normal tear pH is 7.4 and if the drug pH is much different, this will cause reflex tearing (more drug acidity >> more tear >> more washing out of the drug)

❖ Ocular pharmacotherapeutics

1- Cholinergic agents (agonists) :

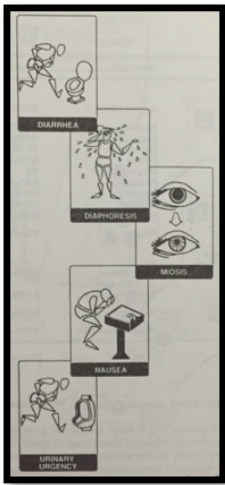


Directly acting agonists: [pilocarpine, acetylcholine]	Indirectly acting (anticholinesterases) : More potent with longer duration of action	
Uses: To Induce miosis, for glaucoma	Reversible inhibitors [physostigmine used in the diagnosis of Myasthenia Gravis]	Irreversible inhibitors [phospholine iodide]
mechanisms: <ul style="list-style-type: none"> • Miosis by contraction of the iris sphincter muscle • Accommodation by circular ciliary muscle contraction 	<ul style="list-style-type: none"> • Used in glaucoma and lice infestation of lashes • Side effect: CNS side effects 	<ul style="list-style-type: none"> • Used in accommodative esotropia (they have strabismus when focusing in typically farsightedness)

- increases aqueous outflow (inside eye to outside) through the trabecular meshwork by longitudinal ciliary muscle contraction

Side effects:

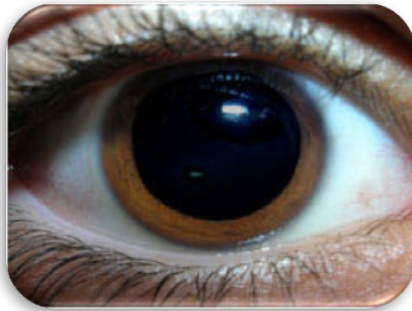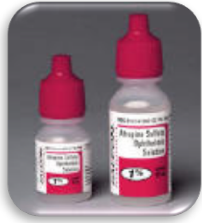- **Local:** diminished vision (myopia with long use), headache, cataract, miotic cysts, and rarely retinal detachment
- **Systemic:** diarrhea, lacrimation, salivation, perspiration, bronchospasm, nausea, vomiting and urinary urgency



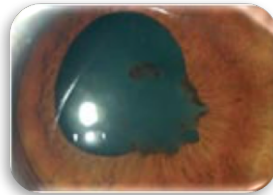
- **Side effect:** iris cyst and anterior subcapsular cataract
- **Contraindicated:** in angle closure glaucoma, asthma, Parkinsonism -causes apnea if used with succinylcholine or procaine

Contraindications: asthma, Parkinsonism

2- Cholinergic antagonists :

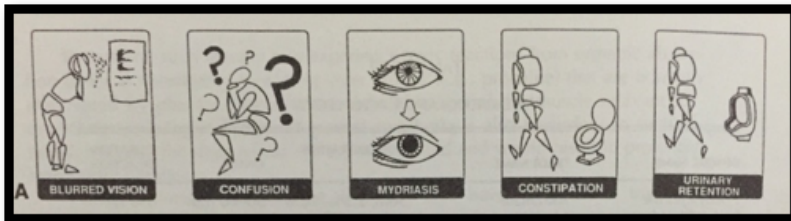


- tropicamide, cyclopentolate, homatropine, **atropine** (stays for 2 weeks)
- **cause:** mydriasis (by paralyzing the sphincter muscle) with cycloplegia (by paralyzing the ciliary muscle so there is loss of accommodation)
- Uses: funduscopy, cycloplegic refraction (procedure to measure accommodation) , anterior uveitis (because it's attenuate endotoxin induced uveitis)



- **Side effects:**

- **Local:** allergic reaction, blurred vision
- **Systemic:** nausea, vomiting, pallor, vasomotor collapse, constipation, urinary retention, and confusion
- Specially **in children** they might cause flushing, fever, tachycardia, or delirium




- **Treatment** by DC or physostigmine

- In children ointment better than eye drop cause not going to lachrymal system so less systemic effect

3- Adrenergic agonists (be careful for: cardiac disease, asthma and BP) :

<p>Non-selective agonists (α_1, α_2, β_1, β_2) epinephrine, dipivefrin (prodrug of epinephrine)</p>	<p>Alpha-1 agonists phenylephrine</p>	<p>Alpha-2 agonists (brimonidine, apraclonidine)</p>
<p>Uses: glaucoma</p>	<p>Uses: mydriasis (without cycloplegia), decongestant</p>	<p>Uses : glaucoma treatment [treatment of the open angle not the closure angle] and prophylaxis after glaucoma laser procedures</p>
<p>Side effects: headache, arrhythmia, increased blood pressure, conjunctival adrenochrome, cystoid macular edema in aphakic eyes</p>	<p>Adverse effect:</p> <ul style="list-style-type: none"> • Can cause significant increase blood pressure especially in infant and susceptible adults • Rebound congestion • Induce acute angle-closure glaucoma in patients with narrow angles 	<p>Mechanism: decrease aqueous production, and increase uveoscleral outflow</p>
<p>Contraindication:in closed angle glaucoma , cardiac patient</p>	<p>Contraindication: cardiac patient</p>	<p>Side effects:</p> <ul style="list-style-type: none"> • local: allergic reaction, mydriasis, lid retraction • systemic: oral dryness, headache, fatigue, drowsiness, orthostatic hypotension, vasovagal attacks
<div data-bbox="175 1423 495 1640" data-label="Image"> </div> <p>- Pic : notes the small dots if it present , you have to ask about these drug , the dots are dangerous because it is a pigmentation lesion</p>		<p>Contraindications: infants, MAO inhibitors users MAO : monoamine oxidase inhibitors for depression</p>

4- adrenergic antagonists:

<p>Alpha adrenergic antagonists</p> <p>Not widely used</p>	<p>Beta-adrenergic blockers</p> 
<p>thymoxamine, dapiprazole</p>	<p>nonselective: timolol (commonly used to treat glaucoma), carteolol</p> <p>selective: betaxolol (beta 1 “cardioselective”) (Good for asthmatic)</p>
<p>Uses: to reverse pupil dilation produced by phenylephrine (better not to be used because of the risk of retinal detachment)</p>	<p>Uses: glaucoma (by suppressing aqueous production)</p>
	<p>Mechanism: reduce the formation of aqueous humor by the ciliary body</p>
	<p>Side effects: bronchospasm (less with betaxolol) (non- selective:exacerbates bronchial asthma, COPD) , cardiac impairment</p>

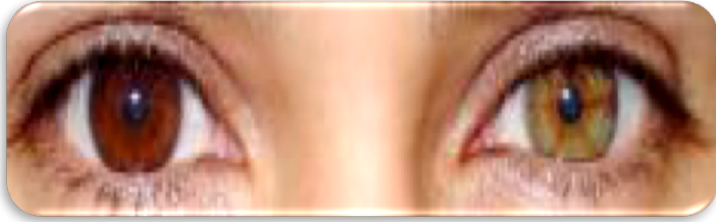5- Carbonic anhydrase inhibitors (carbonic anhydrase have a role in producing aqueous humor) :

- acetazolamide, dorzolamide
- **Uses:** glaucoma, cystoid macular edema, pseudotumour cerebri
- **Mechanism:** aqueous suppression
- **Side effects:** myopia, **paresthesia**, GI upset, headache, altered taste and smell (decreases CSF production) , Na and K depletion, metabolic acidosis, renal stone, bone marrow suppression “aplastic anemia”
- **Contraindication:** sulpha allergy, digitalis user's , pregnancy

6- Osmotic Agents (used to suppress IOP as fast as possible in Acute attacks) :

- Dehydrate vitreous body which reduce IOP significantly
1. Glycerol 50% syrup (cause nausea, hyperglycemia)
 2. Mannitol 20% IV (cause fluid overload, avoid in heart failure) (screen CVS before use)
- Use in case of acute angle closure glaucoma to reduce IOP rapidly

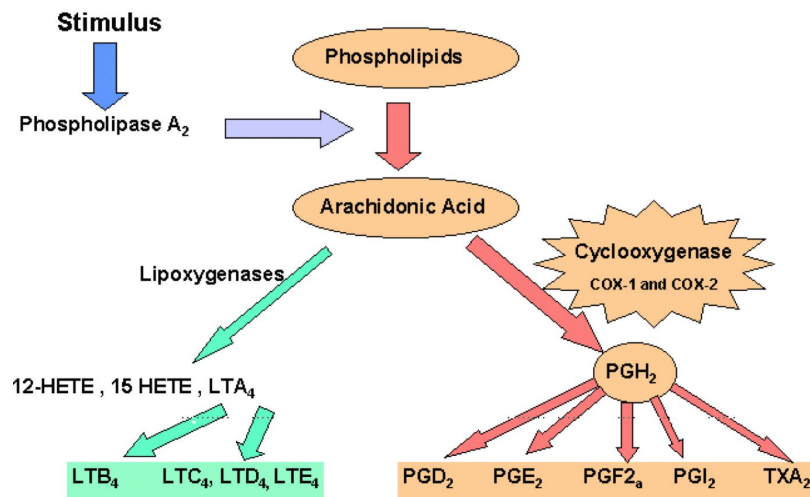
7- Prostaglandin analogues:


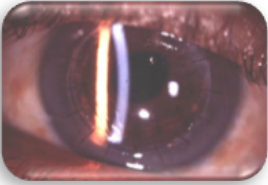

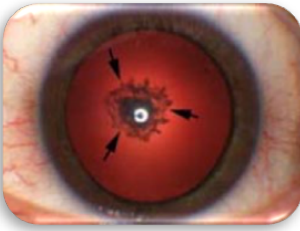


- latanoprost, bimatoprost, travoprost, unoprostone
- **Uses:** glaucoma
- **Mechanism:** increase uveoscleral aqueous outflow
- **Side effects:** darkening of the iris (heterochromia iridis), lengthening and thickening of eyelashes, intraocular inflammation, macular edema

8- Anti-inflammatory (The 3rd category: steroid sparing agent.)

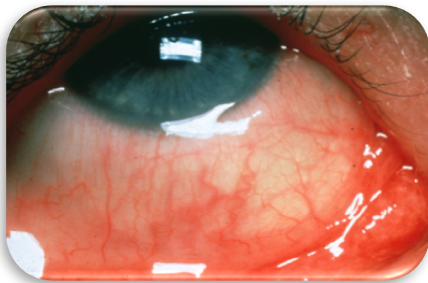Figure 2 : Biosynthesis of eicosanoids



<p style="text-align: center;">Corticosteroids</p> <p style="text-align: center;">Mechanism: inhibition of arachidonic acid release from phospholipids by inhibiting phospholipase A2</p>		<p style="text-align: center;">NSAID</p> <p style="text-align: center;">Mechanism: inactivation of cyclooxygenase</p>
<p>1- Topical</p> <p>fluorometholone, hydrocortisone, rimexolone (weakest), prednisolone, dexamethasone (both are strong).</p>	<p>2- Systemic</p> <p>prednisolone</p>	<p>ketorolac, diclofenac, flurbiprofen</p> 
<p>Mechanism: inhibition of arachidonic acid release from phospholipids by inhibiting phospholipase A2</p>		<p>Mechanism: inactivation of cyclooxygenase</p>
<p>Uses: postoperatively, anterior uveitis, severe allergic conjunctivitis (they suffer a lot because when we give steroids they feel better so they used it a lot but at the end they develop glaucoma, cataract), vernal keratoconjunctivitis, prevention and suppression of corneal graft rejection, episcleritis, scleritis</p> 	<p>Uses: posterior uveitis, optic neuritis, temporal arteritis with anterior ischemic optic neuropathy</p>  	<p>Uses: postoperatively, mild allergic conjunctivitis, episcleritis, mild uveitis, cystoid macular edema, preoperatively to prevent miosis during surgery</p> <p>(Surgical trauma induce miosis due to PG release, that's why we use NSAID)</p>
<p>Side effects: susceptibility to infections (especially fungal) , glaucoma, cataract, ptosis, mydriasis, scleral melting, skin atrophy</p> <p>In topical steroids it is likely to</p>	<p>Side effects:</p> <ul style="list-style-type: none"> Local: posterior subcapsular cataract, glaucoma, central serous retinopathy Systemic: suppression of pituitary-adrenal axis (so, 	<p>Side effects: stinging</p>

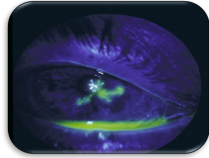
induce glaucoma but less likely cataract in comparison, while the systemic steroids to induce cataract but it can induce glaucoma as well.	reduce dose to allow intra production) , hyperglycemia, osteoporosis, peptic ulcer, psychosis	
--	---	--



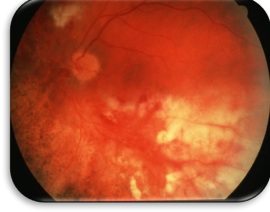
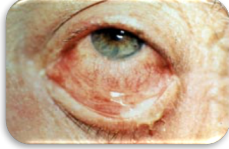
9- Anti-allergics :

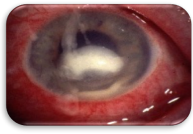


- Avoidance of allergens, cold compress, lubrications
- **Antihistamines** (pheniramine, levocabastine)
- **Decongestants** (naphazoline, phenylephrine, tetrahydrozoline) not preferable as it causes rebound congestion.
- **Mast cell stabilizers** : takes few days to start induce action. (e.g. cromolyn, lodoxamide, pemirolast, nedocromil, **olopatadine**)
- **NSAID** ketorolac
- **Steroids** if other treatments failed. (e.g. fluorometholone, rimexolone, prednisolone)
- **Drug combinations** Try to mix and let the steroids your least option.

10 - Anti-microbial :

Antibiotics	Antifungal	Antiviral
Penicillins, Cephalosporins, Sulfonamides, Tetracyclines, Chloramphenicol, Aminoglycosides , Fluoroquinolones, Vancomycin, macrolides	Uses: fungal keratitis, fungal endophthalmitis	Acyclovir interact with viral thymidine kinase (selective) used in herpetic keratitis 
<ul style="list-style-type: none"> • Used topically in prophylaxis (pre and postoperatively) and treatment of ocular bacterial infections. 	Polyenes <ul style="list-style-type: none"> • damage cell membrane of susceptible fungi • amphotericin B, natamycin 	Trifluridine more corneal penetration can treat herpetic iritis

<ul style="list-style-type: none"> Used orally for the treatment of preseptal cellulitis 	<ul style="list-style-type: none"> side effect: nephrotoxicity 	
<ul style="list-style-type: none"> Can be injected intravitreally for the treatment of endophthalmitis [with vancomycin and septazidine] Used intravenously for the treatment of orbital cellulitis 	<p>Imidazoles</p> <ul style="list-style-type: none"> crease fungal cell membrane permeability miconazole, ketoconazole 	<p>Ganciclovir</p> <p>used intravenously for CMV retinitis</p> 
<p>Trachoma (contagious bacterial infection of inner surface of lid) can be treated by topical and systemic tetracycline or systemic azithromycin.</p> 	<p>Flucytosine</p> <p>act by inhibiting DNA synthesis</p>	
<p>Bacterial conjunctivitis is usually self limited but topical erythromycin or fluoroquinolones can be used</p>	<p>Usually we don't diagnose fungal infection easily, so we treat it as antibacterial if no improvement we add antifungal. And we take swab from cornea and culture it, and we change antibacterial accordingly.</p>	
<p>Bacterial keratitis (bacterial corneal ulcers) can be treated by topical fortified antibiotics (cephalosporins, aminoglycosides, vancomycin, or fluoroquinolones)</p>		




you have to be aggressive with treatment of pre-septal cellulitis > to avoid complications

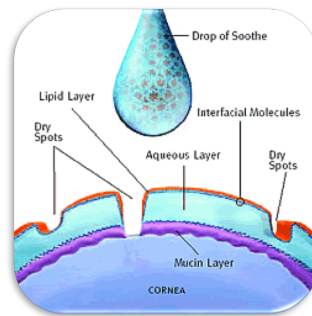
11- Ocular diagnostic drugs:

<p>Fluorescein dye Available as drops or strips (The fluorescein is hydrophilic so any damaged structure without epithelium will be dyed with it)</p>	<p>Rose bengal stain Stains devitalized (diseased) epithelium</p>
<ul style="list-style-type: none"> ● Uses: stain corneal abrasions, applanation tonometry, detecting wound leak, NLD obstruction, fluorescein angiography ● Caution: <ul style="list-style-type: none"> → stains soft contact lens → Fluorescein drops can be contaminated by Pseudomonas sp. <div data-bbox="126 1318 716 1556"> </div>	<p>Uses: severe dry eye, herpetic keratitis</p> <div data-bbox="878 953 1463 1167"> </div>

12- Local anesthetics

Topical:	Orbital infiltration:
<ul style="list-style-type: none"> ● propacaine, tetracaine ● Uses: applanation tonometry, gonioscopy, removal of corneal foreign bodies, removal of sutures, examination of patients who cannot open eyes because of pain ● Adverse effects: toxic to corneal epithelium (if diseased so used when it's needed only) , allergic reaction rarely 	<ul style="list-style-type: none"> ● peribulbar or retrobulbar ● causes anesthesia and akinesia for intraocular surgery ● lidocaine, bupivacaine 

13- Other ocular preparations :Lubricants :



- use it if needed only because it inhibit the reflex tearing and with time inhibiting the nasal secretion if not the main lacrimal
- drops or ointments
- Polyvinyl alcohol, cellulose, methylcellulose
- Preserved or preservative free

14- Intravitreal Injections

★ Anti VEGF (anti vascular endothelial growth factors) :

- bevacizumab (Avastin)
- Ranibizumab (Lucentis)

★ Uses:

- Age related macular degeneration (AMD)
- DM (macular edema, PDR =proliferative diabetic retinopathy).
- CRVO/BRVO (crvo = central retinal venous occlusion) (BRVO = Branch retinal venous occlusion)
-

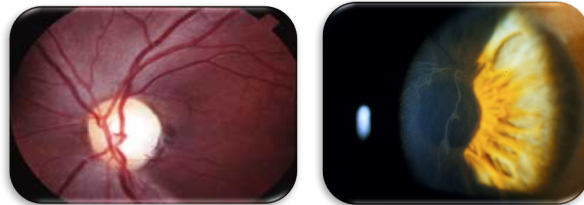
❖ Ocular toxicology

❑ Complications of topical administration:

- * **Mechanical injury from the bottle:** corneal abrasion
- * **Pigmentation:** epinephrine adrenochrome
- * **Ocular damage:** topical anesthetics, benzalkonium
- * **Hypersensitivity:** atropine, neomycin, gentamicin
- * **Systemic effect:** topical phenylephrine can increase BP.

❑ Amiodarone

- A cardiac arrhythmia drug
- Causes optic neuropathy (mild decreased vision, visual field defects, **bilateral optic disc swelling**)
- Also causes **corneal vortex keratopathy (corneal verticillata)** which is whorl-shaped pigmented deposits in the corneal epithelium



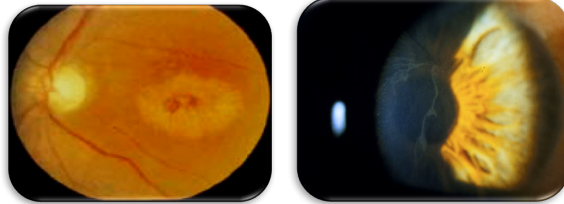
❑ Digitalis:

- A cardiac failure drug.
- Causes **chromatopsia** not reversible (objects appear yellow) with overdose.



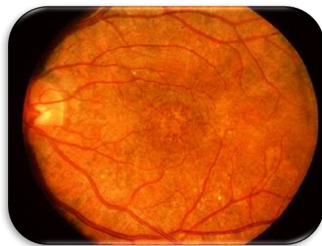
❑ **Chloroquine** : no significant effect.

- chloroquine, hydroxychloroquine
- Used in malaria, rheumatoid arthritis, SLE
- Also cause retinopathy (**bull's eye maculopathy**)
- Cause **vortex keratopathy (corneal verticillata)** which is usually asymptomatic but can present with glare and photophobia



❑ **Thioridazine:**

- A psychiatric drug
- Causes a pigmentary retinopathy after high dosage(**salt and pepper appearance**)



❑ **Chlorpromazine:**

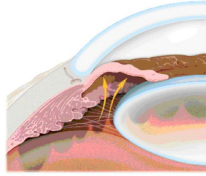
- A psychiatric drug
- Causes **corneal punctate epithelial opacities, lens surface opacities**
- Rarely symptomatic
- Reversible with drug discontinuation.

❑ **Diphenylhydantoin:**

- An epilepsy drug
- Causes dosage-related cerebellar vestibular effects:
 - Horizontal **nystagmus** in lateral gaze
 - **Diplopia, ophthalmoplegia**
 - Vertigo, ataxia
- Reversible with the discontinuation of the drug.

❑ Topiramate:

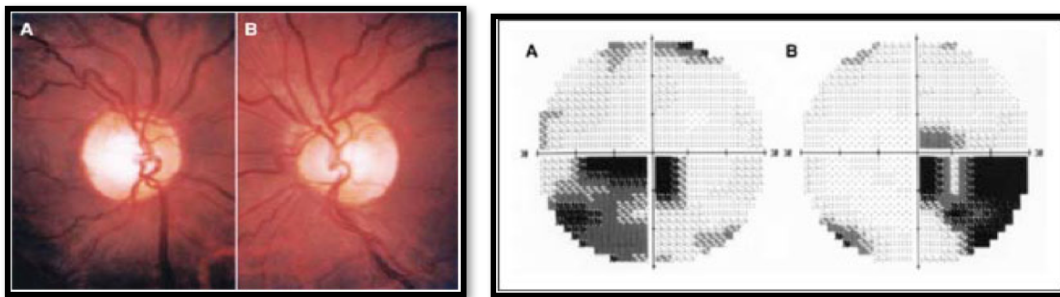
- A drug for epilepsy (if the patient came with glaucoma ask if he is epileptic) also usually come with same side headache)
- Causes **acute angle-closure glaucoma** (acute eye pain, redness, blurred vision, haloes) . moves iris lense diaphragm more anteriorly, block anterior angle, no drainage , in this case we treat by atropine and cyclopentolate , the result will be dilatation ,so it'll pull lense back word



- Treatment of this type of acute angle closure glaucoma is by: cycloplegia and topical steroids (rather than iridectomy) with the discontinuation of the drug.

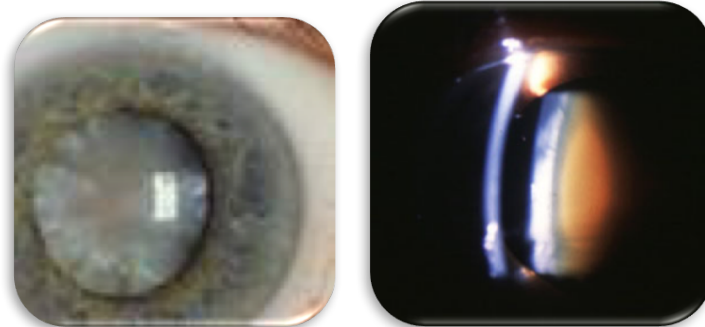
❑ Ethambutol:

- An anti-TB drug
- Causes a dose-related **optic neuropathy**
- Usually reversible but occasionally permanent visual damage might occur.



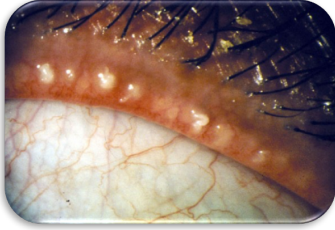
❑ HMG-CoA reductase inhibitors (statins)

- Cholesterol lowering agents
- pravastatin, lovastatin, simvastatin, fluvastatin, atorvastatin, rosuvastatin
- Can cause **cataract** in high dosages especially if used with erythromycin



❑ **ROACCUTANE :**

- Isotretinoin (Retinoid agents)
- Used in Acne
- Avoid tetracycline
- Severe dry eye (evaporative) with rec. chalazion



❑ **Other agents:**

- **methanol** – optic atrophy and blindness
 - **Contraceptive pills** – pseudotumor cerebri (papilledema), and dryness (CL intolerance)
 - **Chloramphenicol and streptomycin** – optic atrophy
 - **Hypervitaminosis A** – yellow skin and conjunctival , pseudotumor cerebri (papilledema), retinal hemorrhage.
 - **Hypovitaminosis A** – night blindness (nyctalopia), keratomalacia.
-

433 team notes:

This is a useful piece of extra-information that we would like to add:

- Preseptal cellulitis (or periorbital cellulitis) is an infection of the anterior portion of the eyelid, not involving the orbit or other ocular structures. In contrast, orbital cellulitis is an infection involving the contents of the orbit (fat and ocular muscles). Neither infection involves the globe.
- Although preseptal and orbital cellulitis may be confused with one another because both can cause ocular pain and eyelid swelling and erythema, they have very different clinical implications.
- Preseptal cellulitis is generally a mild condition that rarely leads to serious complications, whereas orbital cellulitis may cause loss of vision and even loss of life. Orbital cellulitis can usually be distinguished from preseptal cellulitis by its clinical features (ophthalmoplegia, pain with eye movements, and proptosis) and by imaging studies. In cases in which the distinction is not clear, clinicians should treat patients as though they have orbital cellulitis. Both conditions are more common in children than in adults, and preseptal cellulitis is much more common than orbital cellulitis. (Source:UpToDate)

Summary

- **Pharmacodynamics:** It is the biological and therapeutic effect of the drug (mechanism of action)
 - **Pharmacokinetics:** It is the absorption, distribution, metabolism, and excretion of the drug.
 - **Factors influencing local drug penetration into ocular tissue:** Drug concentration and solubility, Viscosity, Lipid solubility, Surfactants, PH, Drug tonicity.
 - **Types:** Eye drops, ointments, periocular injection, intraocular injection, sustained release device, systemic drugs.
 - **Ocular pharmacotherapeutics include:** Cholinergic agonists, cholinergic antagonists, adrenergic agonists, adrenergic antagonists, carbonic anhydrase inhibitor, osmotic agents, prostaglandin analogs, antimicrobial, anti-inflammatory, ocular diagnostic drugs, local anesthetics, other ocular preparations, intravitreal injection.
-