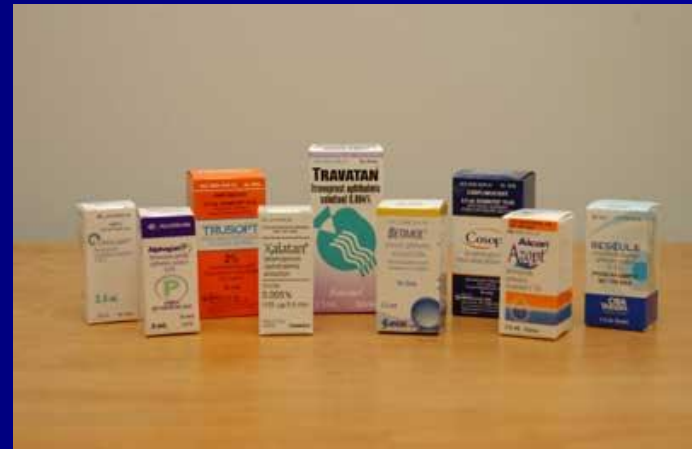

# Ocular pharmacology and toxicology

Hatem Kalantan, MD  
Assistant Professor  
Ophthalmology Dept.  
College of Medicine  
King Saud University




# **General pharmacological principles**

# Pharmacodynamics

- It is the biological and therapeutic effect of the drug (**mechanism of action**)
- Most drugs act by binding to regulatory macromolecules, usually neurotransmitters or hormone receptors or enzymes
- If the drug is working at the receptor level, it can be **agonist or antagonist**
- If the drug is working at the enzyme level, it can be **activator or inhibitor**

# Pharmacokinetics

- It is the absorption, distribution, metabolism, and excretion of the drug
- A drug can be delivered to ocular tissue as:
  - Locally:
    - Eye drop
    - Ointment
    - Periocular injection
    - Intraocular injection
  - Systemically:
    - Orally
    - IV





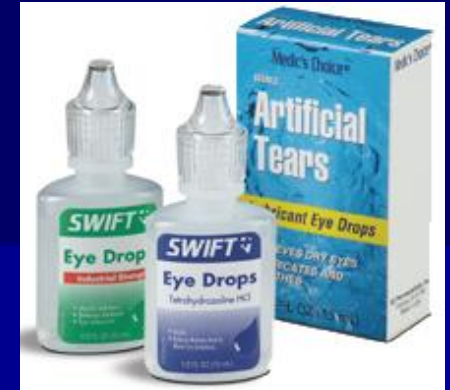# Factors influencing local drug penetration into ocular tissue

- **Drug concentration and solubility:** the higher the concentration the better the penetration e.g pilocarpine 1-4% but limited by reflex tearing
- **Viscosity:** addition of methylcellulose and polyvinyl alcohol increases drug penetration by increasing the contact time with the cornea and altering corneal epithelium
- **Lipid solubility:** because of the lipid rich environment of the epithelial cell membranes, the higher lipid solubility the more the penetration

# Factors influencing local drug penetration into ocular tissue

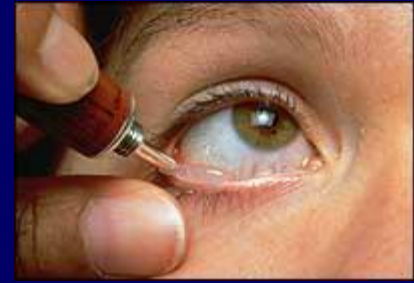- **Surfactants:** the preservatives used in ocular preparations alter cell membrane in the cornea and increase drug permeability e.g. benzylkonium and thiomersal
- **pH:** the normal tear pH is 7.4 and if the drug pH is much different, this will cause reflex tearing
- **Drug tonicity:** when an alkaloid drug is put in relatively alkaloid medium, the proportion of the uncharged form will increase, thus more penetration

# Eye drops



- Eye drops- **most common**
- one drop = 50  $\mu$ l
- volume of conjunctival cul-de-sac 7-10  $\mu$ l
- measures to increase drop absorption:
  - wait 5-10 minutes between drops
  - compress lacrimal sac
  - keep lids closed for 5 minutes after instillation

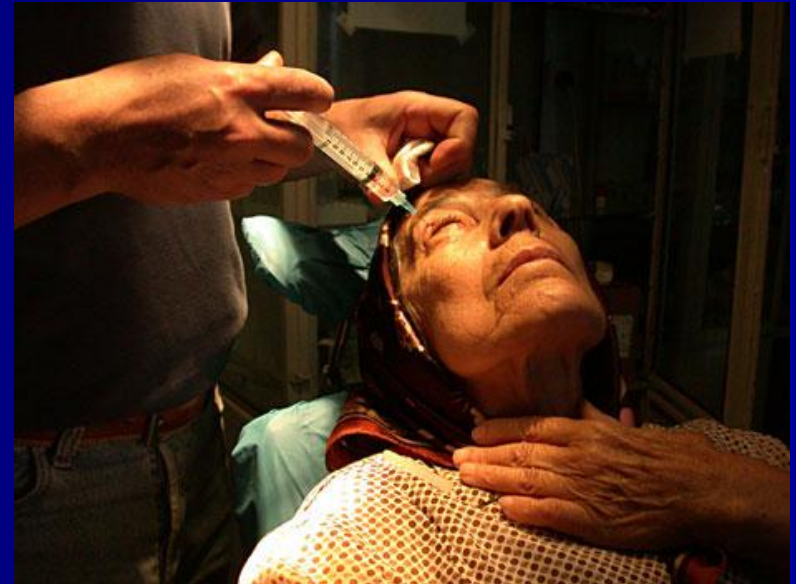# Ointments



- **Increase the contact time** of ocular medication to ocular surface thus better effect
- It has the disadvantage of vision blurring
- The drug has to be high lipid soluble with some water solubility to have the maximum effect as ointment

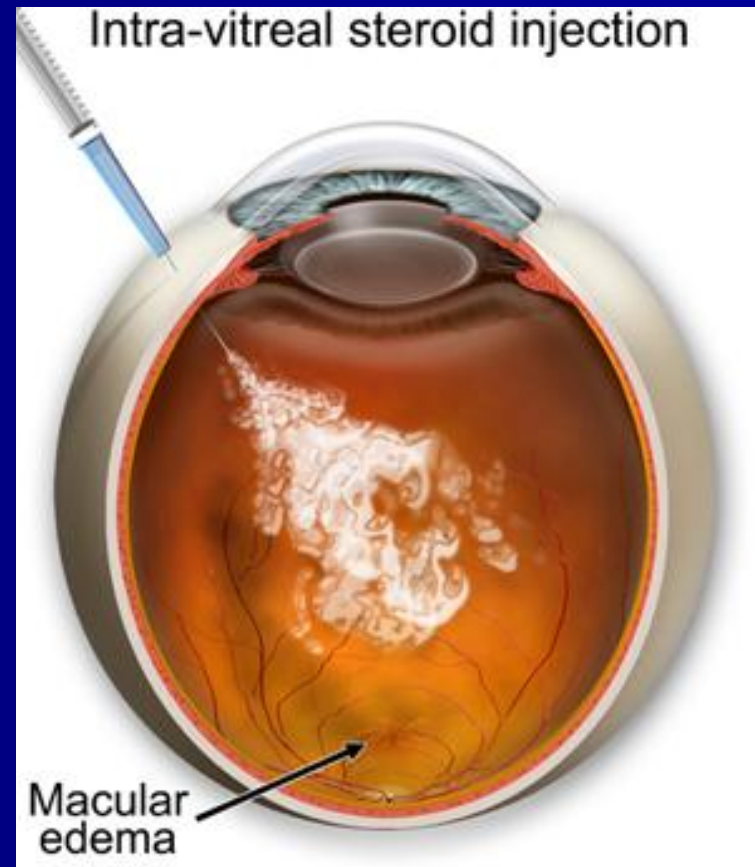
# Peri-ocular injections

- They reach behind iris-lens diaphragm better than topical application
- E.g. subconjunctival, subtenon, peribulbar, or retrobulbar
- This route bypass the conjunctival and corneal epithelium which is good for drugs with low lipid solubility (e.g. penicillins)
- Also steroid and local anesthetics can be applied this way



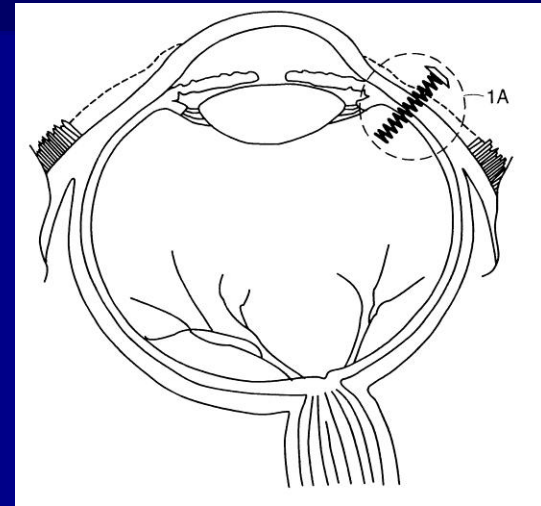
# Intraocular injections

- Intracameral or intravitreal
- E.g.
  - Intracameral acetylcholine (miochol) during cataract surgery
  - Intravitreal antibiotics in cases of endophthalmitis
  - Intravitreal steroid in macular edema
  - Intravitreal Anti-VEGF for DR



# Sustained-release devices

- These are devices that deliver an adequate supply of medication at a steady-state level
- E.g.
  - Ocusert delivering pilocarpine
  - Timoptic XE delivering timolol
  - Ganciclovir sustained-release intraocular device
  - Collagen shields





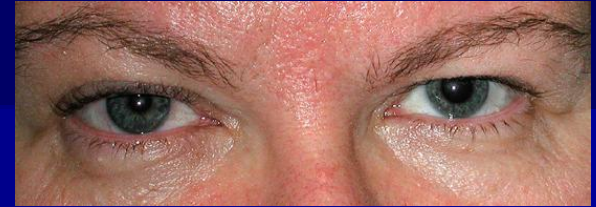# Systemic drugs

- Oral or IV
- Factor influencing systemic drug penetration into ocular tissue:
  - **lipid solubility of the drug:** more penetration with high lipid solubility
  - **Protein binding:** more effect with low protein binding
  - **Eye inflammation:** more penetration with ocular inflammation



# **Ocular pharmacotherapeutics**

# Cholinergic agonists



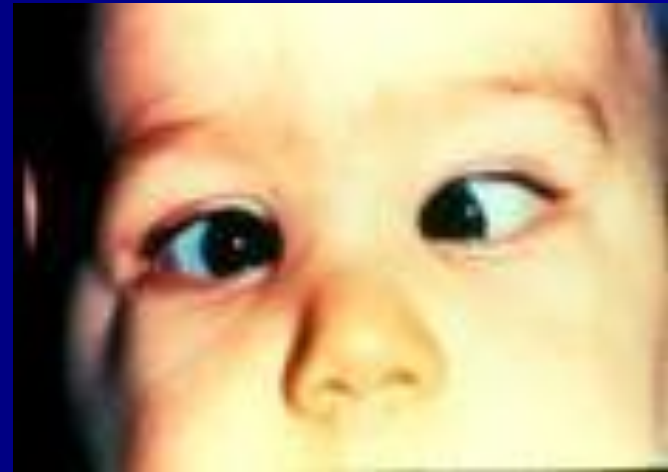- Directly acting agonists:
  - E.g. pilocarpine, acetylcholine (miochol), carbachol (miostat)
  - **Uses:** miosis, glaucoma
  - **Mechanisms:**
    - Miosis by contraction of the iris sphincter muscle
    - increases aqueous outflow through the trabecular meshwork by longitudinal ciliary muscle contraction
    - Accommodation by circular ciliary muscle contraction
  - **Side effects:**
    - Local: diminished vision (myopia), headache, cataract, miotic cysts, and rarely retinal detachment
    - systemic side effects: lacrimation, salivation, perspiration, bronchial spasm, urinary urgency, nausea, vomiting, and diarrhea

# Cholinergic agonists

- **Indirectly acting (anti-cholinesterases) :**
  - More potent with longer duration of action
  - **Reversible inhibitors**
    - e.g. physostigmine
    - used in glaucoma and lice infestation of lashes
    - can cause CNS side effects

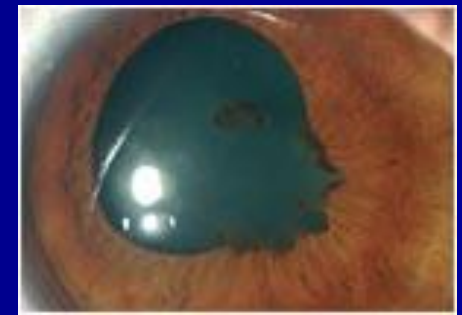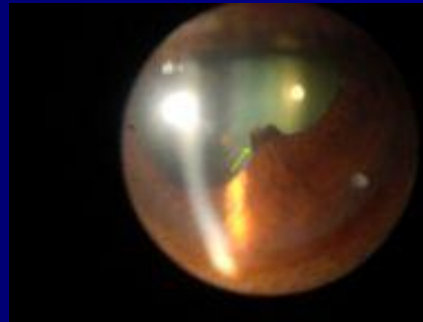
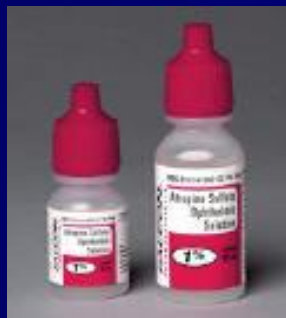# Cholinergic agonists

- Indirectly acting (anticholinesterases):
  - Irreversible:
    - e.g. phospholine iodide
    - **Uses:** in accommodative esotropia
    - **side effects:** iris cyst and anterior subcapsular cataract
    - **C/I** in angle closure glaucoma, asthma, Parkinsonism
    - **causes apnea if used with succinylcholine or procaine**



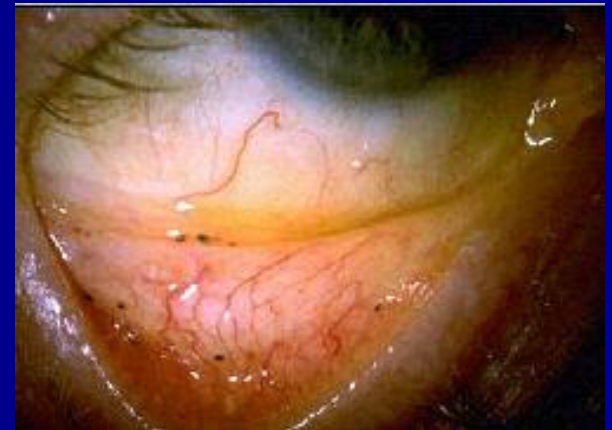# Cholinergic antagonists

- E.g. tropicamide, cyclopentolate, homatropine, scopolamine, atropine
- **Cause** mydriasis (by paralyzing the sphincter muscle) with cycloplegia (by paralyzing the ciliary muscle)
- **Uses:** funduscopy, cycloplegic refraction, anterior uveitis
- **Side effects:**
  - local: **allergic reaction**, blurred vision
  - Systemic: nausea, vomiting, pallor, vasomotor collapse, constipation, urinary retention, and confusion
  - specially **in children** they might cause flushing, fever, tachycardia, or delirium
  - Treatment by DC or physostigmine



# Adrenergic agonists

- Non-selective agonists ( $\alpha_1$ ,  $\alpha_2$ ,  $\beta_1$ ,  $\beta_2$ )
  - E.g. epinephrine, depevefrin (pro-drug of epinephrine)
  - **Uses:** glaucoma
  - **Side effects:** headache, arrhythmia, increased blood pressure, **conjunctival adrenochochrome**, cystoid macular edema in aphakic eyes
  - C/I in closed angle glaucoma



# Adrenergic agonists

- Alpha-1 agonists
- E.g. phenylephrine
- **Uses:** mydriasis (without cycloplegia), decongestant
- **Adverse effect:**
  - Can cause significant increase in blood pressure specially in infant and susceptible adults
  - Rebound congestion
  - precipitation of acute angle-closure glaucoma in patients with narrow angles

# Adrenergic agonists

## ■ Alpha-2 agonists

- E.g. brimonidine, apraclonidine
- **Uses:** glaucoma treatment, prophylaxis against IOP spiking after glaucoma laser procedures
- **Mechanism:** decrease aqueous production, and increase uveoscleral outflow
- **Side effects:**
  - local: allergic reaction, mydriasis, lid retraction, conjunctival blanching
  - systemic: oral dryness, headache, fatigue, drowsiness, orthostatic hypotension, vasovagal attacks
- **Contraindications:** infants, MAO inhibitors users

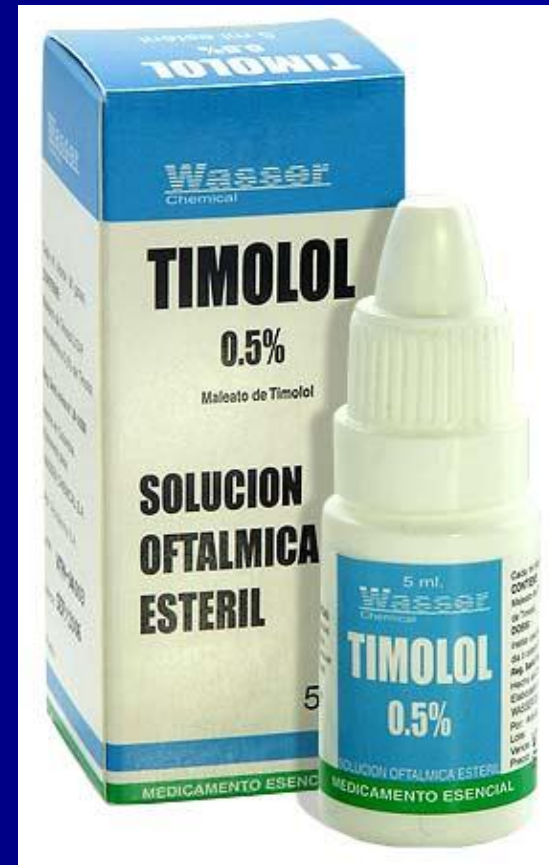

# Alpha adrenergic antagonists

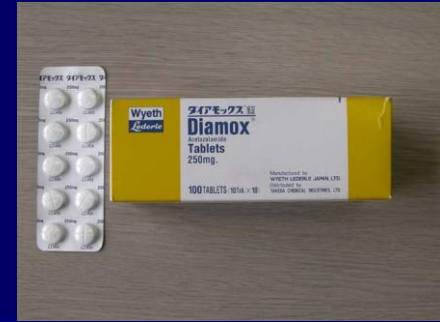- E.g. thymoxamine, dapiprazole
- **Uses:** to reverse pupil dilation produced by phenylephrine
- Not widely used

# Beta-adrenergic blockers

- E.g.
  - non-selective: timolol, levobunolol, metipranolol, carteolol
  - selective: betaxolol (beta 1 "cardioselective")
- **Uses:** glaucoma
- **Mechanism:** reduce the formation of aqueous humor by the ciliary body
- **Side effects:** bronchospasm (less with betaxolol), cardiac impairment



# Carbonic anhydrase inhibitors



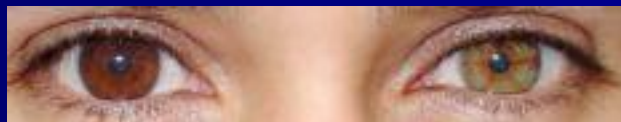- E.g. acetazolamide, methazolamide, dichlorphenamide, dorzolamide, brinzolamide.
- **Uses:** glaucoma, cystoid macular edema, pseudotumour cerebri
- **Mechanism:** aqueous suppression
- **Side effects:** myopia, **parasthesia**, anorexia, GI upset, headache, altered taste and smell, Na and K depletion, metabolic acidosis, renal stone, bone marrow suppression "aplastic anemia"
- **Contraindication:** sulpha allergy, digitalis users, pregnancy

# Osmotic agents

- **Dehydrate vitreous body** which reduce IOP significantly
- E.G.
  - glycerol 50% syrup (cause nausea, hyperglycemia)
  - Mannitol 20% IV (cause fluid overload and not used in heart failure)

# Prostaglandin analogues

- E.g. latanoprost, bimatoprost, travoprost, unoprostone
- **Uses:** glaucoma
- **Mechanism:** increase uveoscleral aqueous outflow
- **Side effects:** darkening of the iris (heterochromia iridis), lengthening and thickening of eyelashes, intraocular inflammation, macular edema



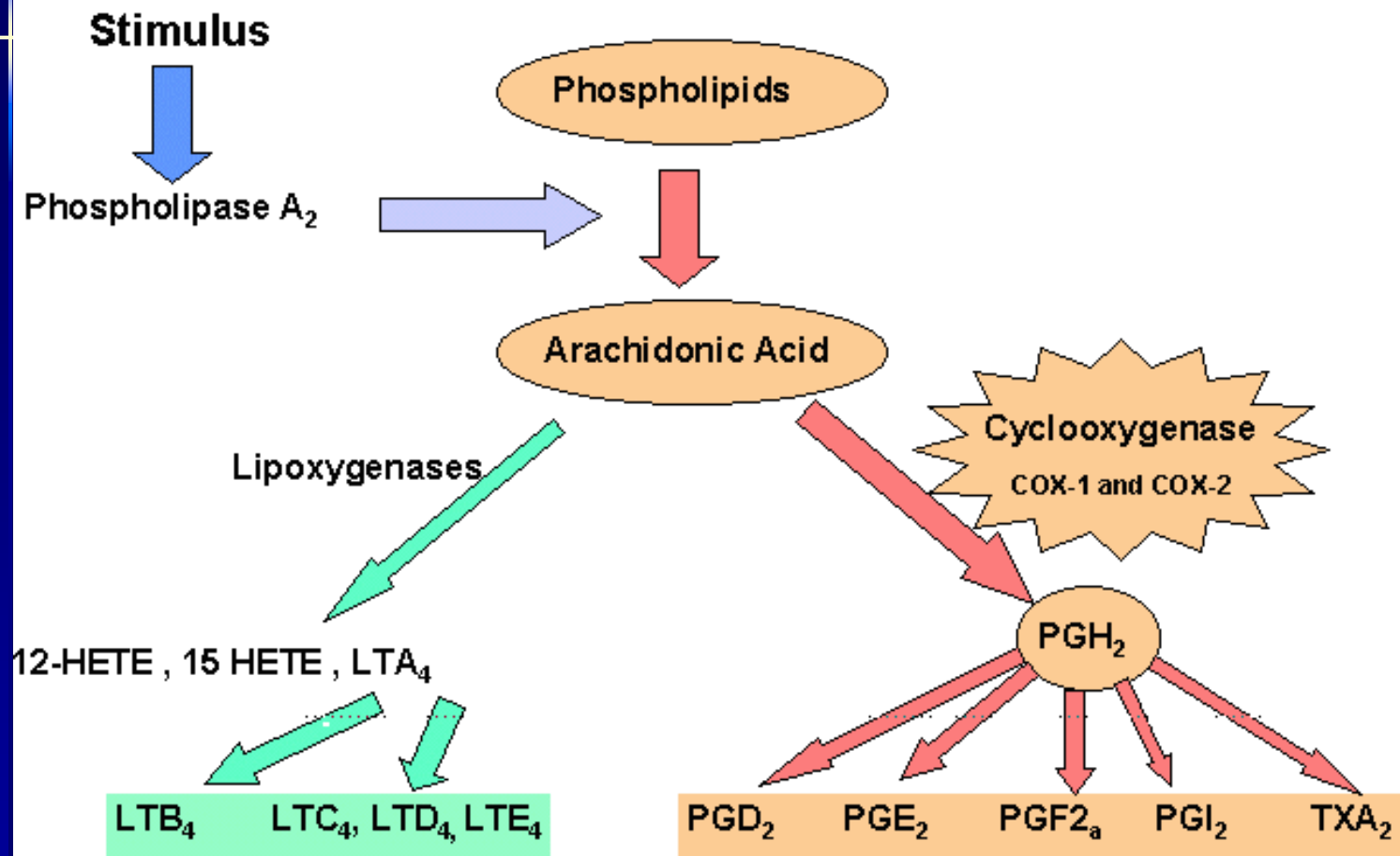
Anti-inflammatory

```
graph TD; A[Anti-inflammatory] --> B[corticosteroid]; A --> C[NSAID]
```

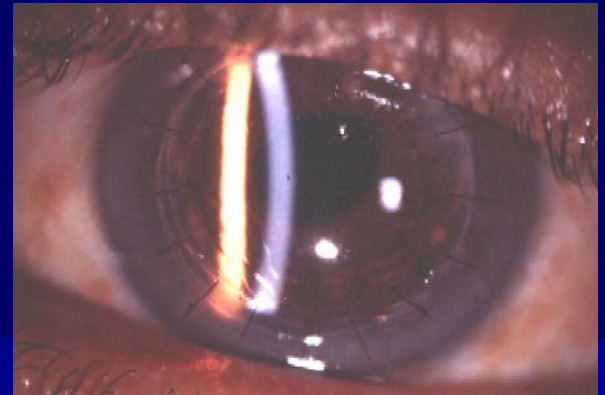
corticosteroid

NSAID

Figure 2 : Biosynthesis of eicosanoids



# Corticosteroids

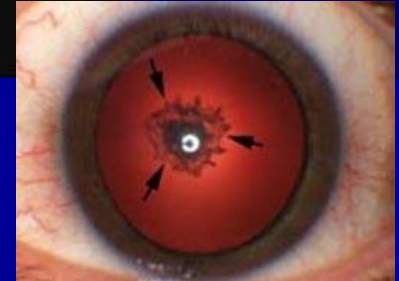
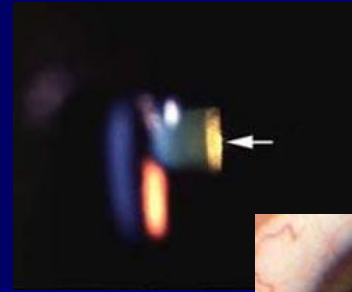


## ■ Topical

- E.g. fluorometholone, remixelone, prednisolone, dexamethasone, hydrocortisone
- **Mechanism:** inhibition of arachidonic acid release from phospholipids by inhibiting phospholipase A2
- **Uses:** postoperatively, anterior uveitis, severe allergic conjunctivitis, vernal keratoconjunctivitis, prevention and suppression of corneal graft rejection, episcleritis, scleritis
- **Side effects:** susceptibility to infections, glaucoma, cataract, ptosis, mydriasis, scleral melting, skin atrophy



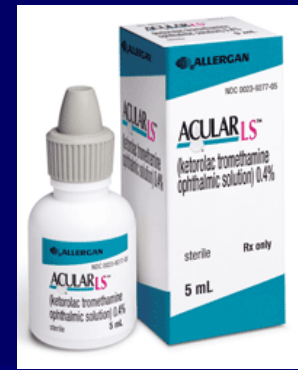# Corticosteroids



## ■ Systemic:

- E.g. prednisolone, cortisone
- **Uses:** posterior uveitis, optic neuritis, temporal arteritis with anterior ischemic optic neuropathy
- **Side effects:**
  - Local: posterior subcapsular cataract, glaucoma, central serous retinopathy
  - Systemic: suppression of pituitary-adrenal axis, hyperglycemia, osteoporosis, peptic ulcer, psychosis

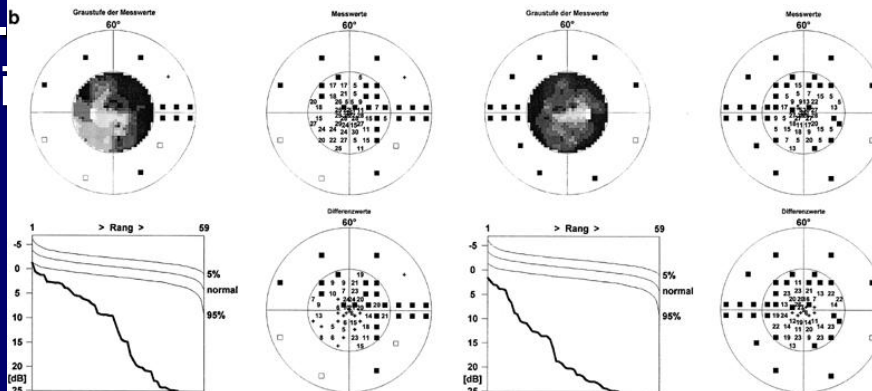
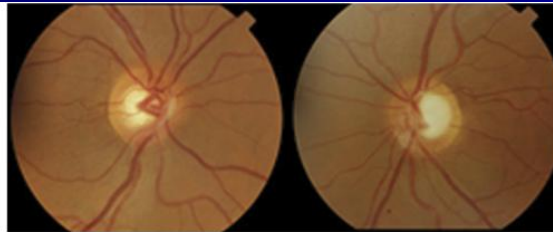
# NSAID



- E.g. ketorolac, diclofenac, flurbiprofen
- **Mechanism:** inactivation of cyclo-oxygenase
- **Uses:** postoperatively, mild allergic conjunctivitis, episcleritis, mild uveitis, cystoid macular edema, preoperatively to prevent miosis during surgery
- **Side effects:** stinging

# Anti-allergics

- Avoidance of allergens, cold compress, lubrications
- **Antihistamines** (e.g. pheniramine, levocabastine)
- **Decongestants** (e.g. naphazoline, phenylephrine, tetrahydrozoline)
- **Mast cell stabilizers** (e.g. nedocromil, cromoglycate)
- **NSAID** (e.g. ibuprofen)
- **Steroids** (e.g. beclomethasone, fluticasone, mometasone, budesonide, flunisolide)
- Drug combinations

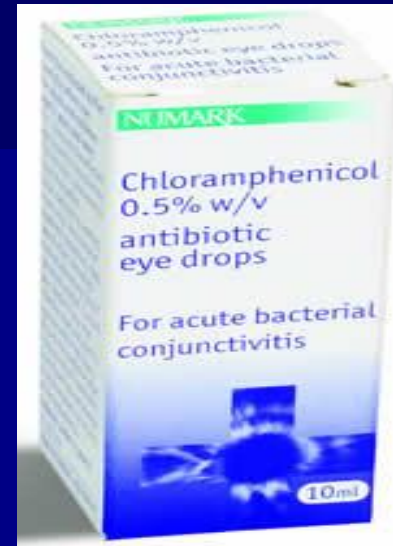


epimirolast,  
nisolone)



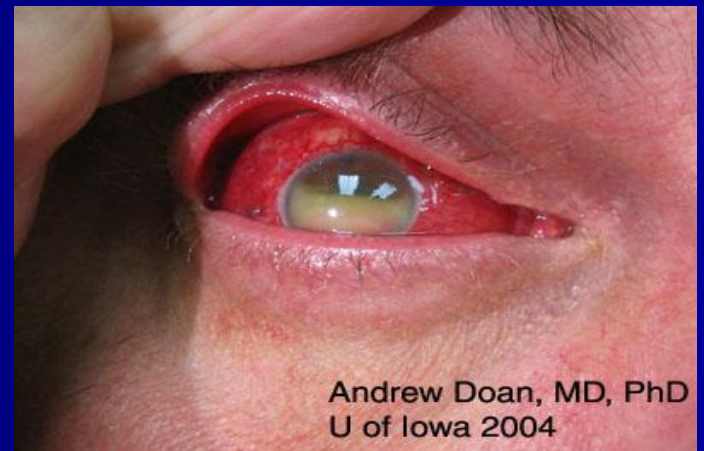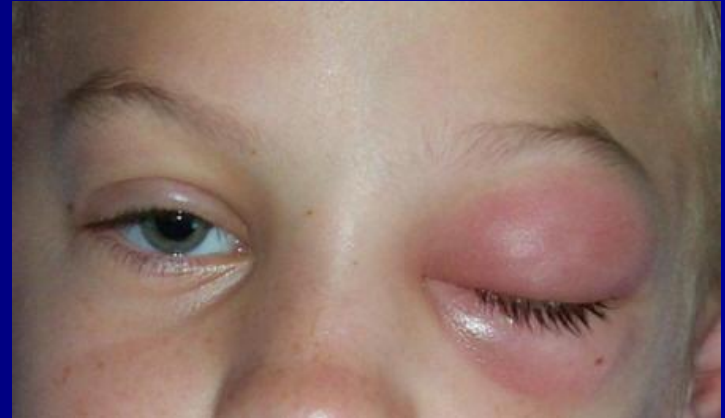# Antibiotics

- Penicillins
- Cephalosporins
- Sulfonamides
- Tetracyclines
- Chloramphenicol
- Aminoglycosides
- Fluoroquinolones
- Vancomycin
- macrolides



# Antibiotics

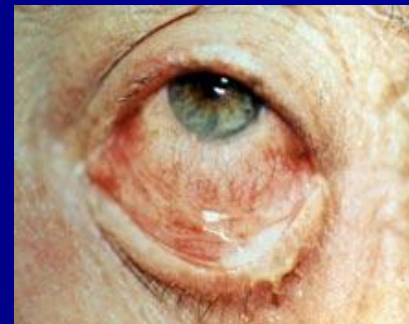
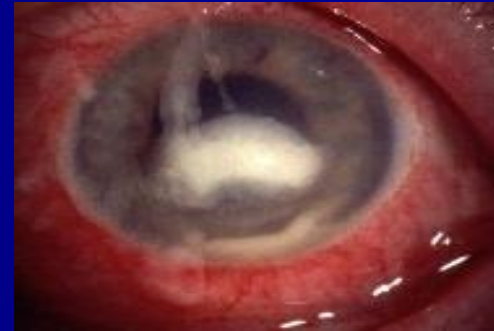- Used **topically** in prophylaxis (pre and postoperatively) and treatment of ocular bacterial infections.
- Used **orally** for the treatment of preseptal cellulitis e.g. amoxicillin with clavulonate, cefaclor
- Used **intravenously** for the treatment of orbital cellulitis e.g. gentamicin, cephalosporin, vancomycin, flagyl
- Can be injected **intravitally** for the treatment of endophthalmitis



Andrew Doan, MD, PhD  
U of Iowa 2004

# Antibiotics

- **Trachoma** can be treated by topical and systemic tetracycline or erythromycin, or systemic azithromycin.
- **Bacterial keratitis** (bacterial corneal ulcers) can be treated by topical fortified penicillins, cephalosporins, aminoglycosides, vancomycin, or fluoroquinolones.
- **Bacterial conjunctivitis** is usually self limited but topical erythromycin, aminoglycosides, fluoroquinolones, or chloramphenicol can be used



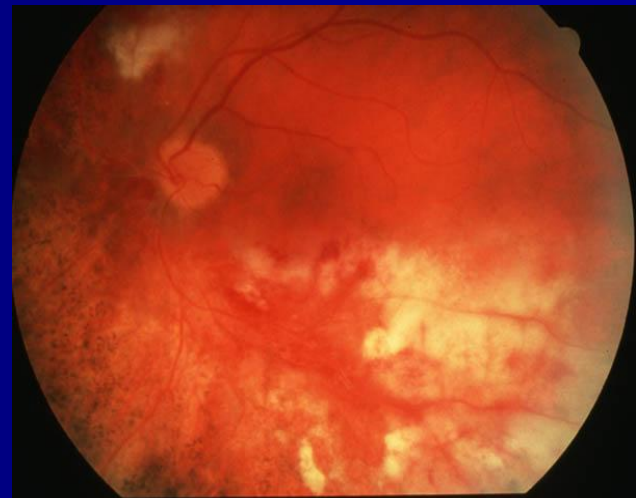
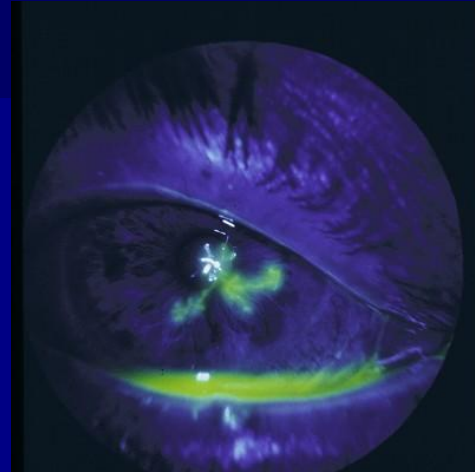


# Antifungals

- **Uses:** fungal keratitis, fungal endophthalmitis
- **Polyenes**
  - damage cell membrane of susceptible fungi
  - e.g. amphotericin B, natamycin
  - side effect: nephrotoxicity
- **Imidazoles**
  - increase fungal cell membrane permeability
  - e.g. miconazole, ketoconazole
- **Flucytocine**
  - act by inhibiting DNA synthesis

# Antivirals

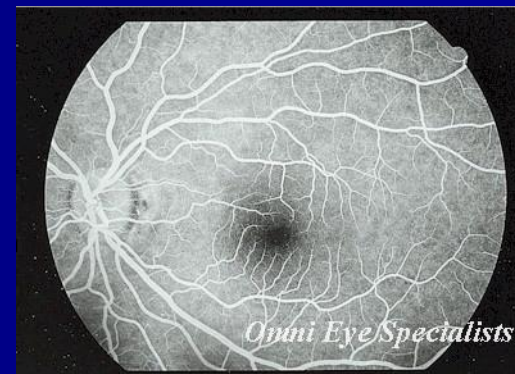
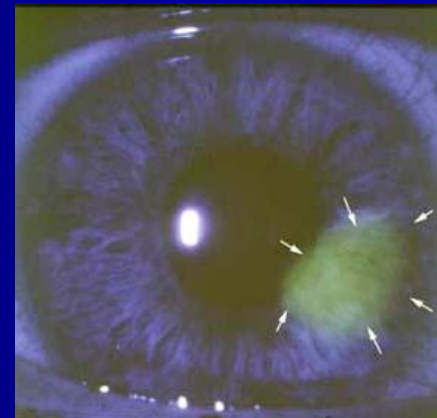
- **Acyclovir**  
interact with viral thymidine kinase (selective)  
used in herpetic keratitis
- **Trifluridine**  
more corneal penetration  
can treat herpetic iritis
- **Ganciclovir**  
used intravenously for CMV retinitis





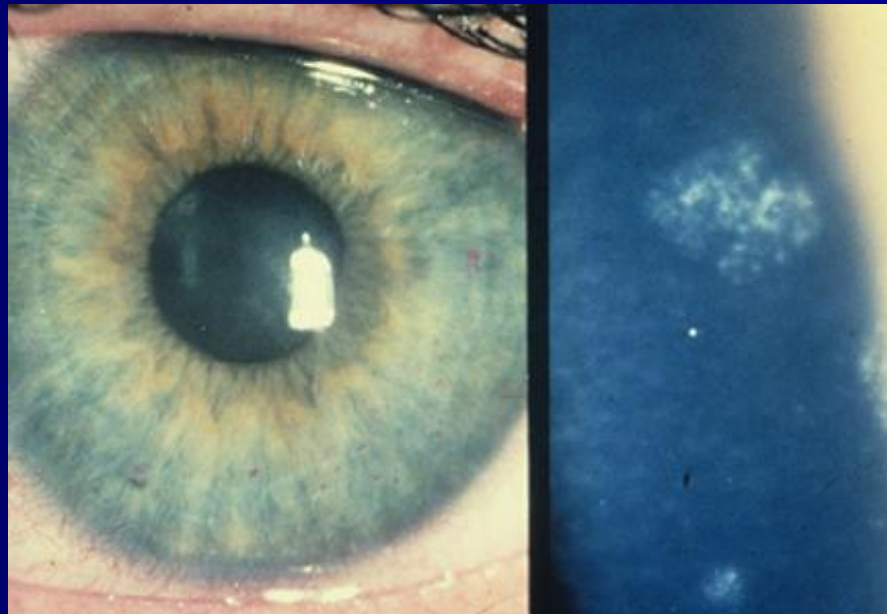
# Ocular diagnostic drugs

- Fluorescein dye
  - Available as drops or strips
  - **Uses:** stain corneal abrasions, applanation tonometry, detecting wound leak, NLD obstruction, fluorescein angiography
  - **Caution:**
    - stains soft contact lens
    - Fluorescein drops can be contaminated by *Pseudomonas* sp.



# Ocular diagnostic drugs

- Rose bengal stain
  - Stains devitalized epithelium
  - **Uses:** severe dry eye, herpetic keratitis

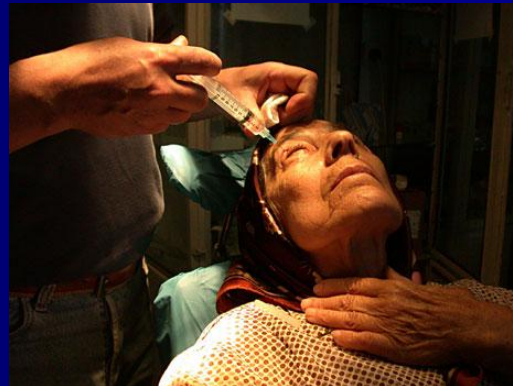

# Local anesthetics

- topical
  - E.g. propacaine, tetracaine
  - **Uses:** applanation tonometry, gonioscopy, removal of corneal foreign bodies, removal of sutures, examination of patients who cannot open eyes because of pain
  - **Adverse effects:** toxic to corneal epithelium, allergic reaction rarely

# Local anesthetics

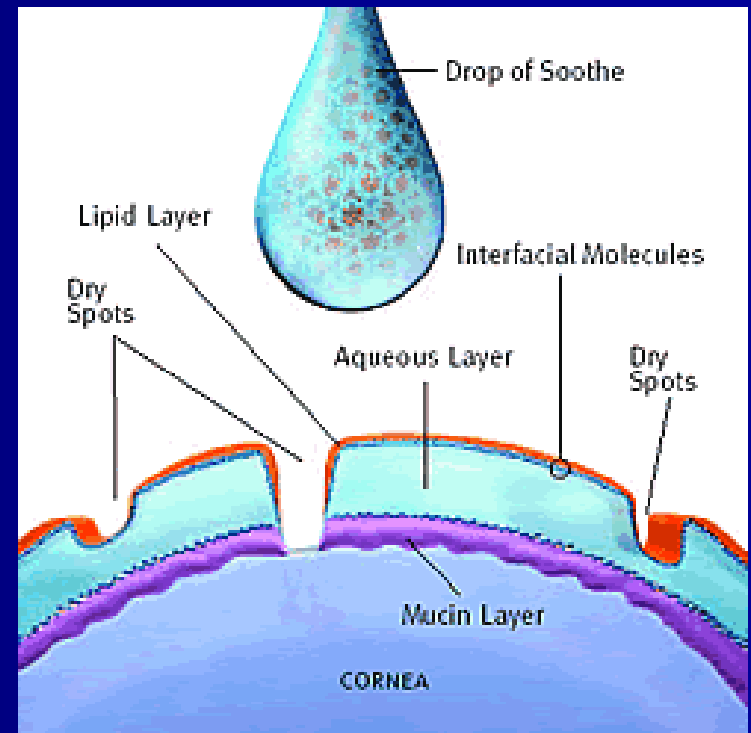
- Orbital infiltration
  - peribulbar or retrobulbar
  - cause **anesthesia** and **akinesia** for intraocular surgery
  - e.g. lidocaine, bupivacaine



# Other ocular preparations

## ■ Lubricants

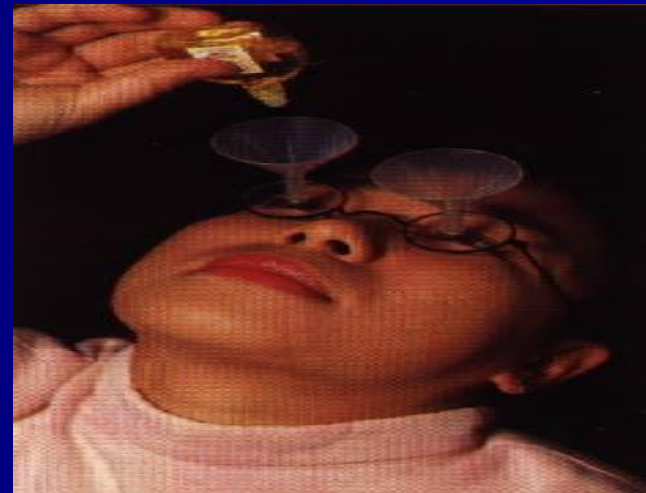
- drops or ointments
- Polyvinyl alcohol, cellulose, methylcellulose
- Preserved or preservative free



# Ocular toxicology

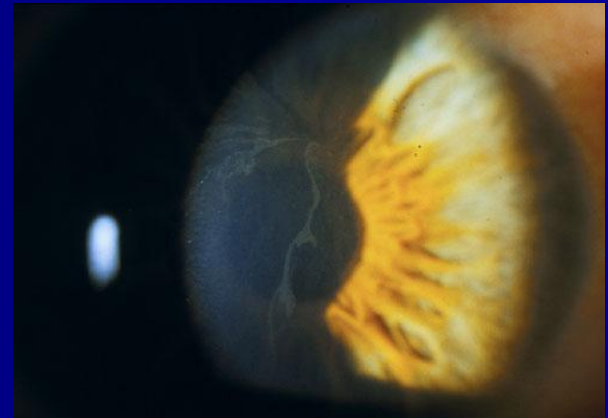
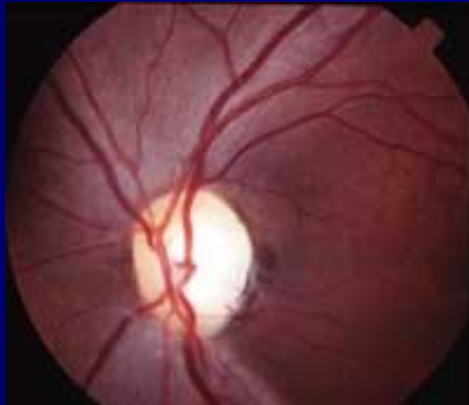# Complications of topical administration

- **Mechanical injury** from the bottle e.g. corneal abrasion
- **Pigmentation:** epinephrine-adrenochrome
- **Ocular damage:** e.g. topical anesthetics, benzylkonium
- **Hypersensitivity:** e.g. atropine, neomycin, gentamicin
- **Systemic effect:** topical phenylephrine can increase BP



# Amiodarone

- A cardiac arrhythmia drug
- Causes **optic neuropathy** (mild decreased vision, visual field defects, bilateral optic disc swelling)
- Also causes corneal vortex keratopathy (corneal verticillata) which is whorl-shaped pigmented deposits in the corneal epithelium





# Digitalis

- A cardiac failure drug
- Causes **chromatopsia** (objects appear yellow) with overdose



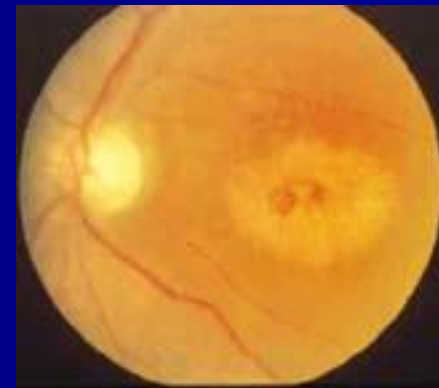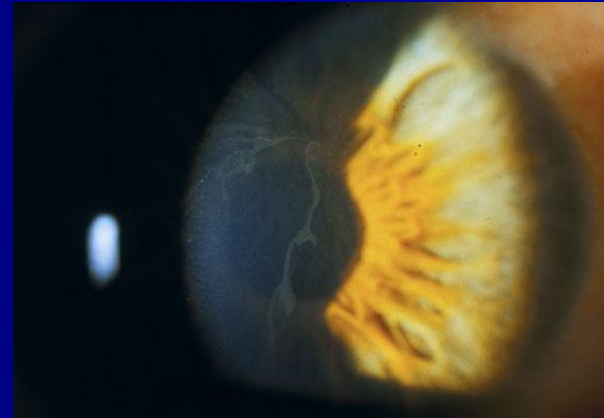
French market scene viewed with no color deficiency



French market scene viewed with xanthopsia

# Chloroquinines

- E.g. chloroquine, hydroxychloroquine
- Used in malaria, rheumatoid arthritis, SLE
- Cause vortex keratopathy (corneal verticillata) which is usually asymptomatic but can present with glare and photophobia
- Also cause **retinopathy** (bull's eye maculopathy)

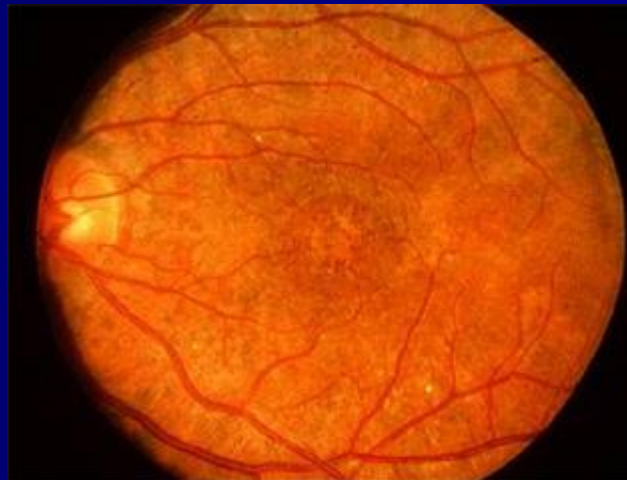


# Chorpromazine

- A psychiatric drug
- Causes **corneal punctate epithelial opacities, lens surface opacities**
- Rarely symptomatic
- Reversible with drug discontinuation

# Thioridazine

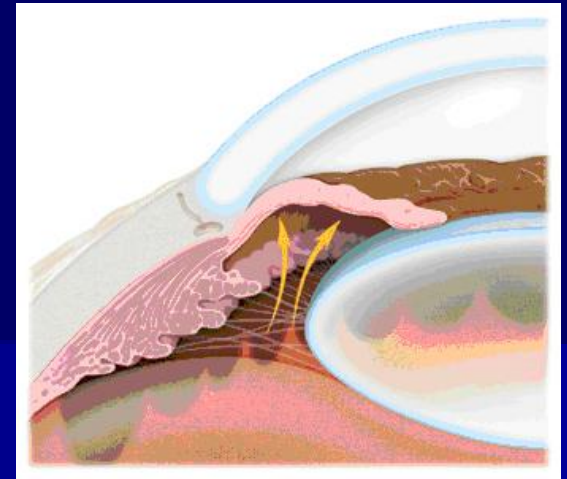
- A psychiatric drug
- Causes a **pigmentary retinopathy** after high dosage



# Diphenylhydantoin

- An epilepsy drug
- Causes dosage-related cerebellar-vestibular effects:
  - Horizontal **nystagmus** in lateral gaze
  - **Diplopia, ophthalmoplegia**
  - Vertigo, ataxia
- Reversible with the discontinuation of the drug

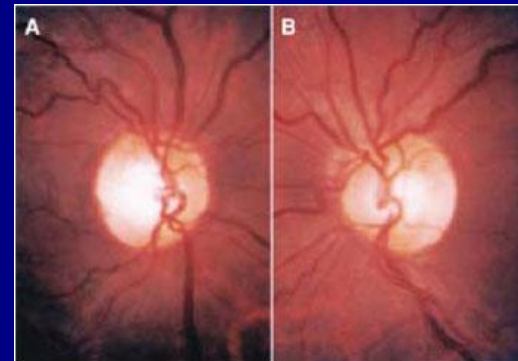
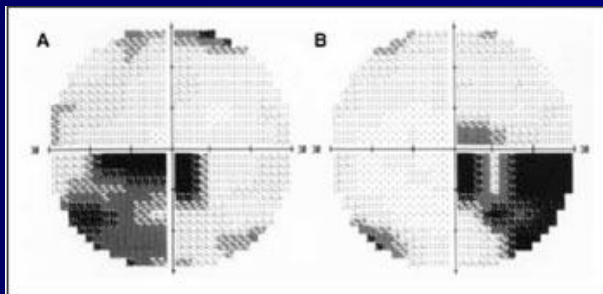
# Topiramate



- A drug for epilepsy
- Causes **acute angle-closure glaucoma** (acute eye pain, redness, blurred vision, haloes).
- Treatment of this type of acute angle-closure glaucoma is by **cycloplegia and topical steroids** (rather than iridectomy) with the discontinuation of the drug

# Ethambutol

- An anti-TB drug
- Causes a dose-related **optic neuropathy**
- Usually reversible but occasionally permanent visual damage might occur





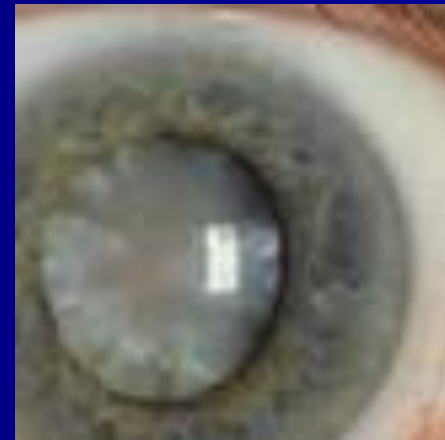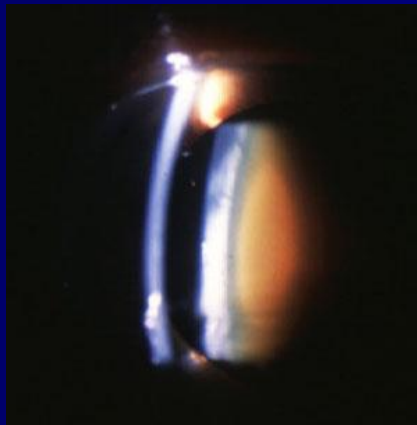
# Agents that Can Cause Toxic Optic Neuropathy

- Methanol
- Ethylene glycol (antifreeze)
- Chloramphenicol
- Isoniazid
- Ethambutol
- Digitalis
- Chloroquine
- Streptomycin
- Amiodarone
- Quinine
- Vincristine and methotrexate (chemotherapy medicines)
- Sulfonamides
- Melatonin with Zoloft (sertraline, Pfizer) in a
- high-protein diet
- Carbon monoxide
- Lead
- Mercury
- Thallium (alopecia, skin rash, severe vision loss)
- Malnutrition with vitamin B-1 deficiency
- Pernicious anemia (vitamin B-12 malabsorption phenomenon)
- Radiation (unshielded exposure to >3,000 rads).



# HMG-CoA reductase inhibitors (statins)

- Cholesterol lowering agents
- E.g. pravastatin, lovastatin, simvastatin, fluvastatin, atorvastatin, rosuvastatin
- Can cause **cataract** in high dosages specially if used with erythromycin



# Other agents

- **methanol** – optic atrophy and blindness
- **Contraceptive pills** – pseudotumor cerebri (papilledema), and dryness (CL intolerance)
- **Chloramphenicol** and **streptomycin** – optic atrophy
- **Hypervitaminosis A** – yellow skin and conjunctiva, pseudotumor cerebri (papilledema), retinal hemorrhage.
- **Hypovitaminosis A** – night blindness (nyctalopia), keratomalacia.

# Thank you

Any question?

