



PRINCIPLES OF FRACTURES (ADULTS)


OBJECTIVES

- Introduction.
- Basic science of fracture healing.
- Principles of evaluating patients with fractures.
- Principles of management.
- Common fractures in adults


introduction

- Fracture means literally broken bone.
- This can be described in different ways:
 - Extent
 - Location
 - Morphology
 - Mechanism
 - Associated soft tissue injuries

- **Extent:**
 - **Complete:** fracture extends 360° of bone circumference (all around)

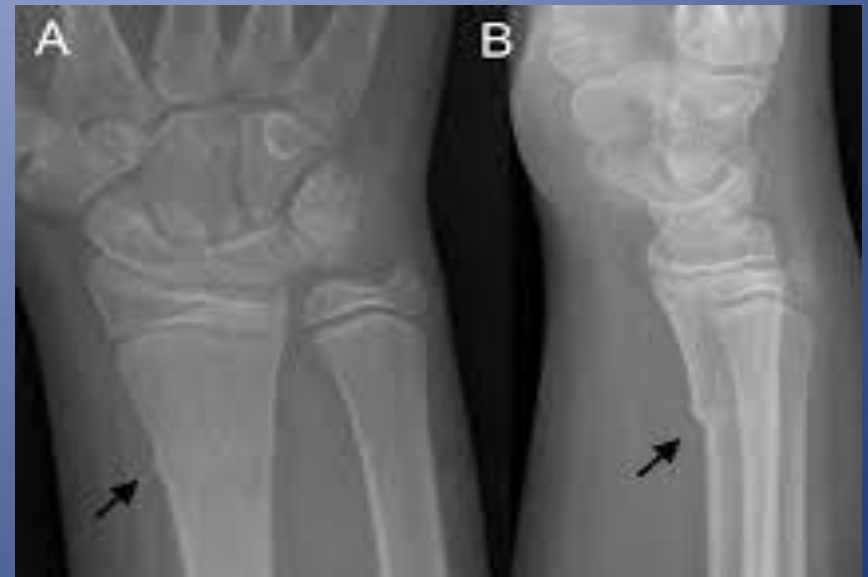

- **Extent:**
 - Complete: fracture extends 360° of bone circumference (all around).
 - Incomplete: seen almost only in children:
 - Greensick



- **Extent:**


- Complete: fracture extends 360° of bone circumference (all around).
- Incomplete: seen almost only in children:
 - Greensick
 - **Buckle fracture**



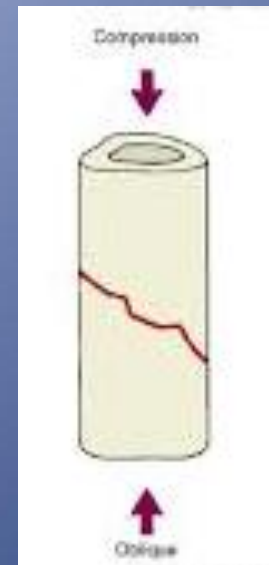
- **Location:**

- Name of bone
- Side
- Diaphysis, metaphysis or epiphysis
- Long bones (diaphysis): divide them in thirds (proximal, middle or distal third)
- Metaphysis: intra-articular v.s extra-articular


- **Morphology:**
 - **Transverse:** loading mode resulting in fracture is tension



- **Morphology:**
 - **Oblique:** loading mode is compression.



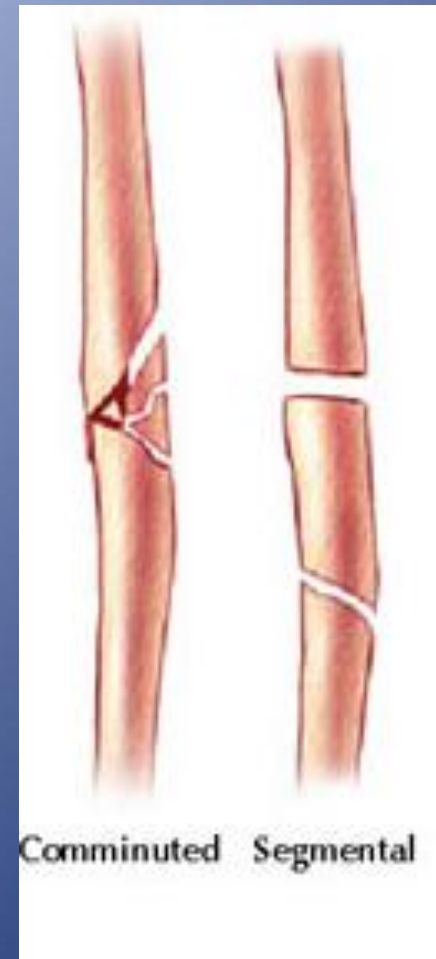
- **Morphology:**
 - **Spiral:** loading mode is torsion.



- **Morphology:**
 - Fracture with Butterfly fragment: loading mode is bending.
 - It also called a wedge fracture.



- **Morphology:**
 - **Comminuted** fracture: 3 or more fragments
 - **Segmental** fracture



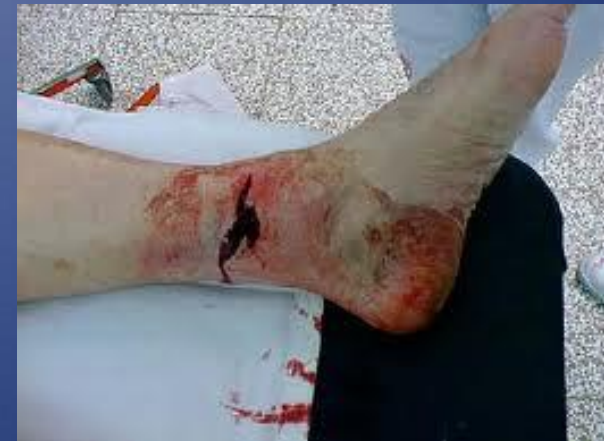- **Mechanism:**

- High energy vs. low energy.
- Multiple injuries vs. isolated injury.
- Pathological fracture: normal load in presences of weakened bone (tumor, osteoporosis, infection)
- Stress fracture: normal bone subjected to repeated load (military recruits).

- **Associated soft tissue injuries:**

- Close fracture: skin integrity is maintained.
- Open fracture: fracture is exposed to external environment .

Any skin breach in proximity of a fracture is an open fracture until proven otherwise.

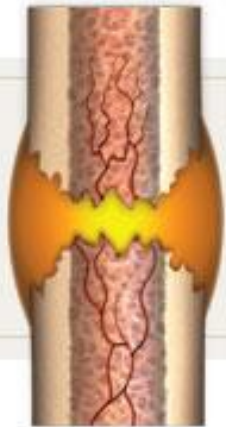

QUESTIONS ?

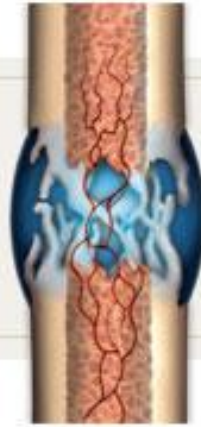FRACTURE HEALING

Natural Bone Healing

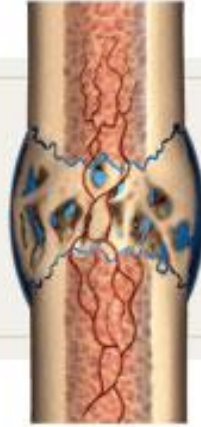- Indirect bone healing (endochondral ossification) occurs in nature with untreated fracture.
- It is called indirect because of formation of cartilage at intermediate stage.
- It runs in 4 stages:
 - Hematoma formation
 - Soft callus formation
 - Hard Callus formation
 - Remodeling



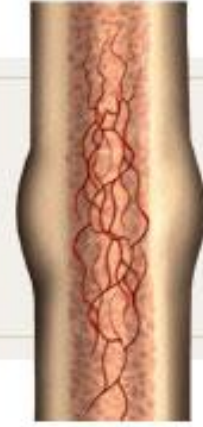Inflammation



Soft callus



Hard callus



Remodeling

PRINCIPLES OF EVALUATION

Diagnosis: History

- * Patients complain of pain and inability to use the limb (if they are conscious and able to communicate)
- * What information can help you make the diagnosis?

Diagnosis: History



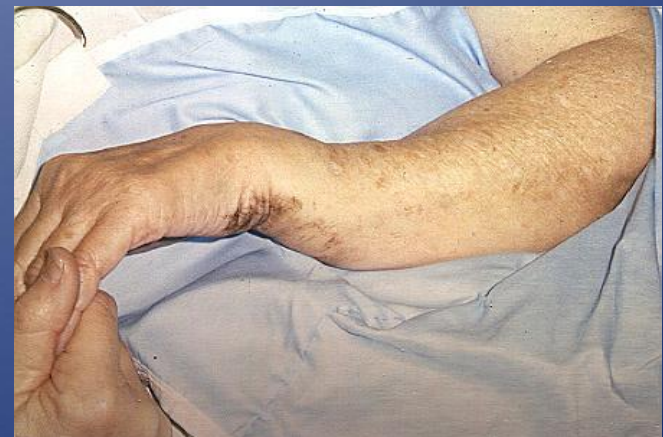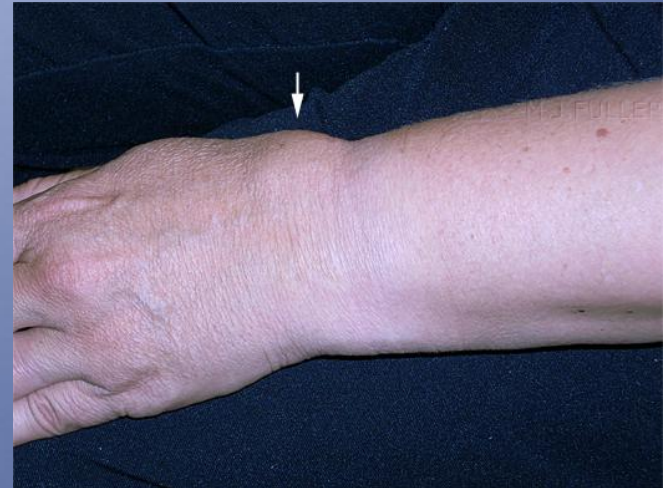* Onset:

- * When and how did the symptoms begin?
 - * Specific traumatic incident vs. gradual onset?
- * If there was a specific trauma, the details of the event are essential information:
- * **Mechanism of injury?**
 - * Circumstances of the event? Work-related?
 - * Severity of symptoms at the time of injury and progression after?

Diagnosis: Physical exam

* Inspection

- * Swelling
 - * Ecchymosis
 - * Deformity
-
- * If fracture is open:
 - * Bleeding
 - * Protruding bone



Diagnosis: Physical exam

- * **Palpation**

- * Bony tenderness

Diagnosis: Physical exam

- * If a fracture is suspected what should we rule out?
 - * Neurovascular injury (N/V exam)
 - * Compartment syndrome
 - * Associated MSK injuries (examine joint above and below at minimum)

Diagnosis: Imaging

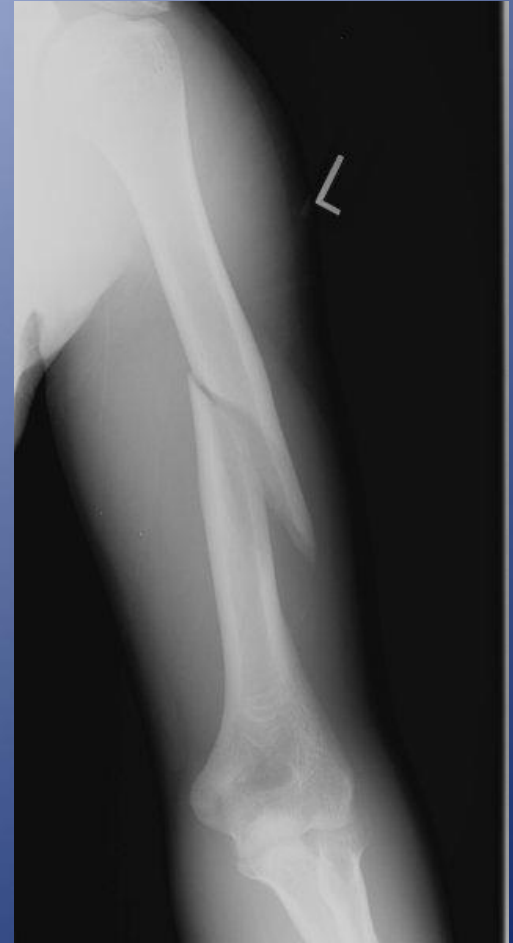- * X-rays are 2D: get minimum two orthogonal views!
- * Include joint above and below injury

Diagnosis: Imaging

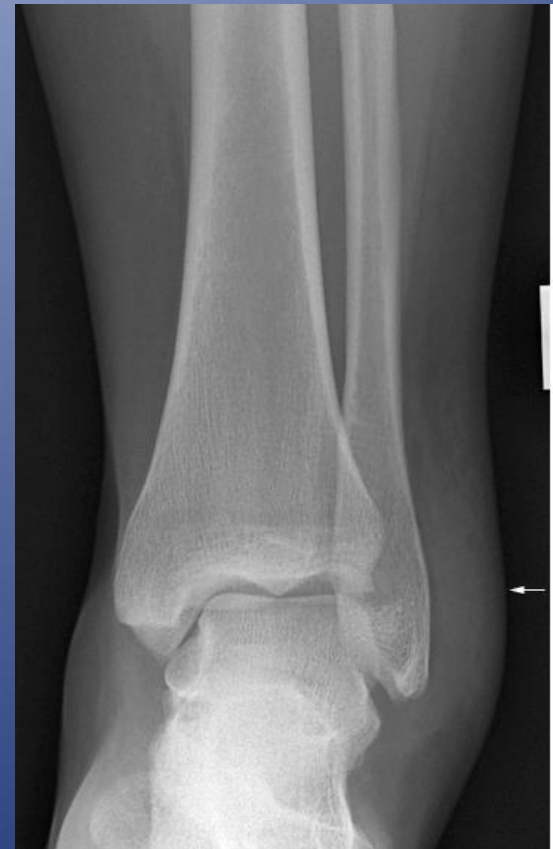- * NB: Fractures hurt, immobilization helps.
- * Immobilizing a patient in a backslab is the most effective way to relieve pain from a fracture and may be done BEFORE getting x-rays

Diagnosis: Imaging

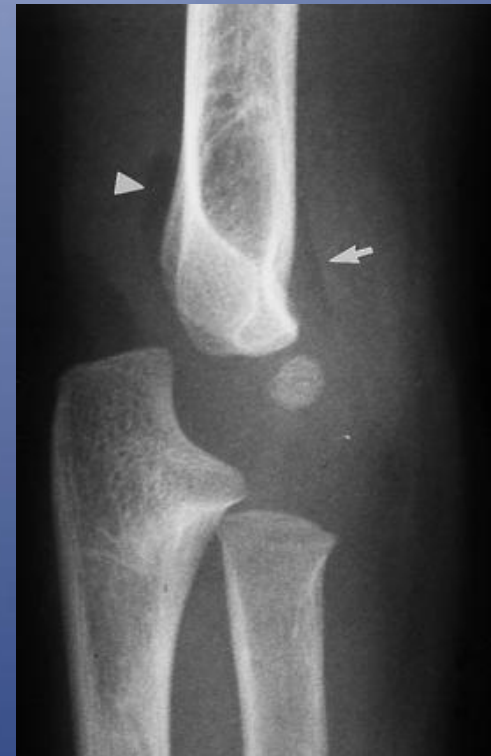- * Fractures may be obvious on x-ray
- * Undisplaced or stress fractures are sometimes not immediately apparent



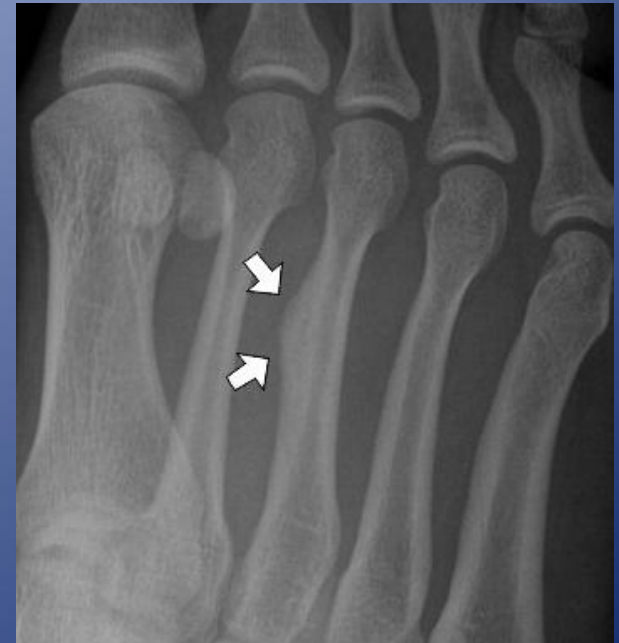- * Secondary signs of fracture on x-ray:
 - * **Soft tissue swelling**
 - * Fat pad signs
 - * Periosteal reaction
 - * Joint effusion
 - * Cortical buckle



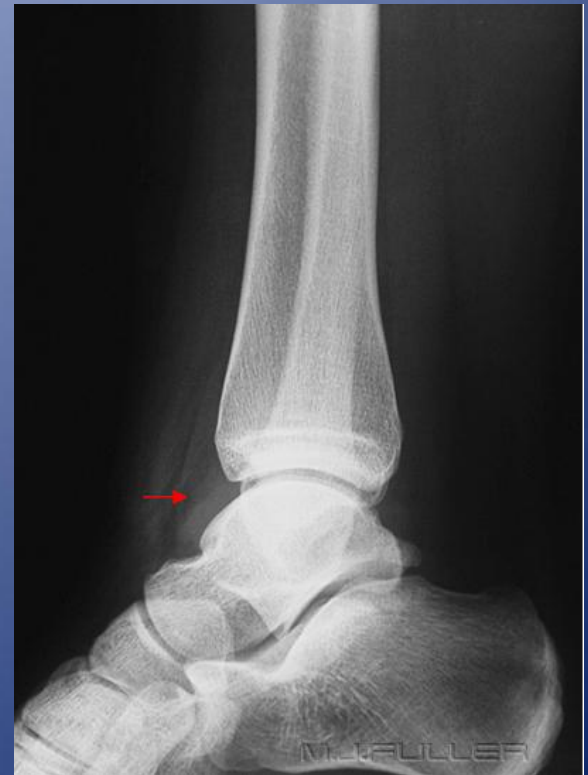- * Secondary signs of fracture on x-ray:
 - * Soft tissue swelling
 - * **Fat pad signs**
 - * Periosteal reaction
 - * Joint effusion
 - * Cortical buckle



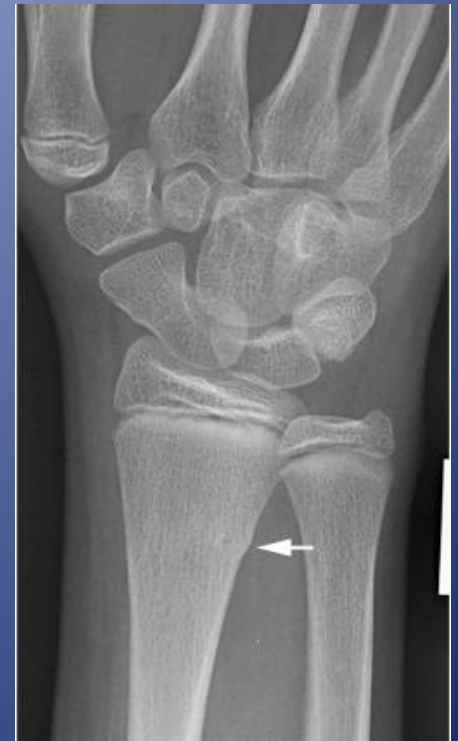- * Secondary signs of fracture on x-ray:
 - * Soft tissue swelling
 - * Fat pad signs
 - * **Periosteal reaction**
 - * Joint effusion
 - * Cortical buckle



- * Secondary signs of fracture on x-ray:
 - * Soft tissue swelling
 - * Fat pad signs
 - * Periosteal reaction
 - * **Joint effusion**
 - * Cortical buckle



- * Secondary signs of fracture on x-ray:
 - * Soft tissue swelling
 - * Fat pad signs
 - * Periosteal reaction
 - * Joint effusion
 - * **Cortical buckle**



How to describe a fracture

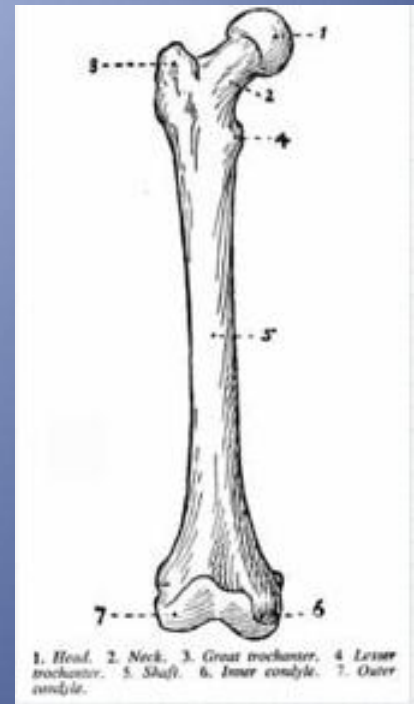
- * Clinical parameters
- * Radiographic parameters

Clinical Parameters

- * Open vs. closed
 - * ANY break in the skin in proximity to the fracture site is OPEN until proven otherwise
- * Neurovascular status
- * Presence of clinical deformity

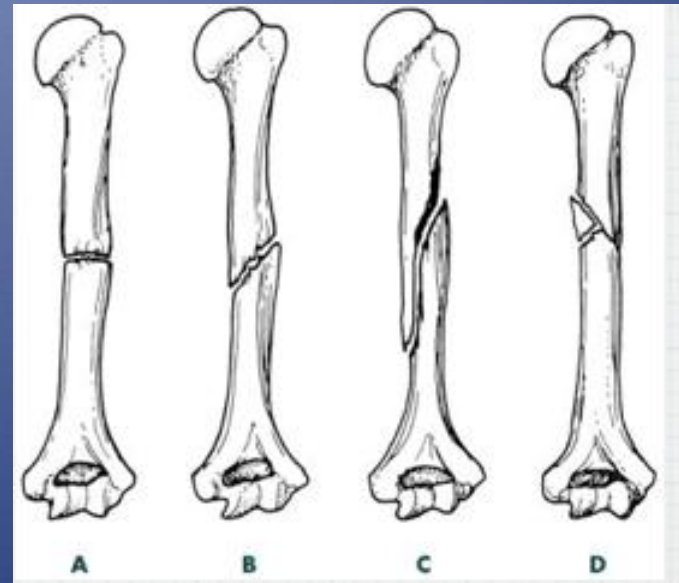
Location

- * Which bone?
- * Which part of the bone?
- * Epiphysis -intraarticular?
- * Metaphysis
- * Diaphysis -divide into 1/3s
- * Use anatomic landmarks when possible
 - * e.g. medial malleolus, ulnar styloid, etc



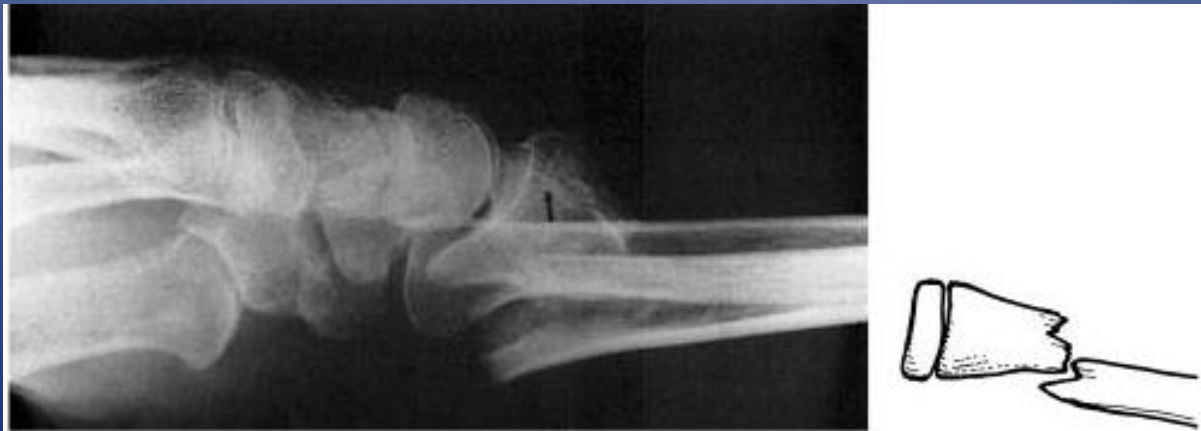Pattern

- * Simple vs. comminuted
- * Complete vs. incomplete
- * Orientation of fracture line
 - * Transverse
 - * Oblique
 - * Spiral



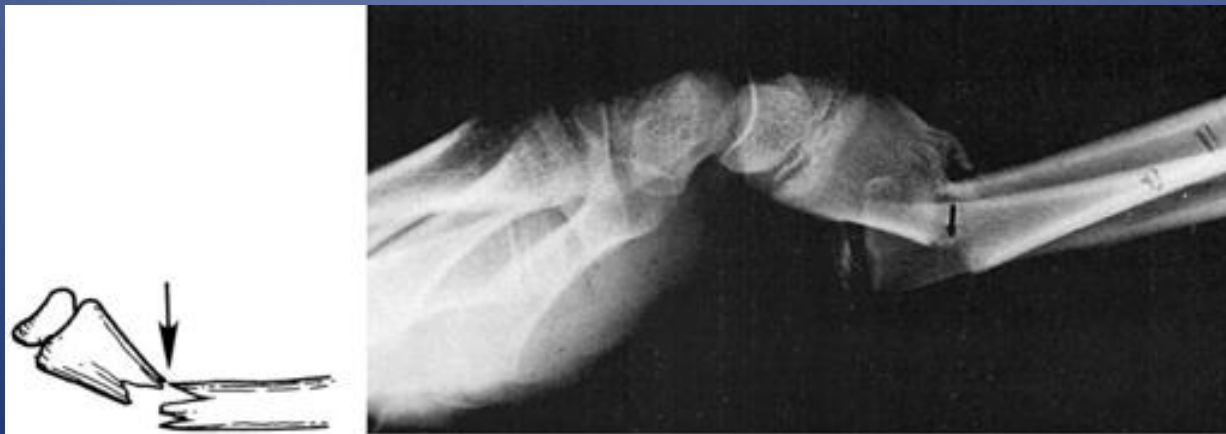Displacement

- * Displacement is the opposite of apposition
- * Position of distal fragment relative to proximal
- * Expressed as a percentage



Angulation

- * Deviation from normal alignment
- * Direction of angulation defined by apex of
- * Expressed in degrees



Fracture description: Summary

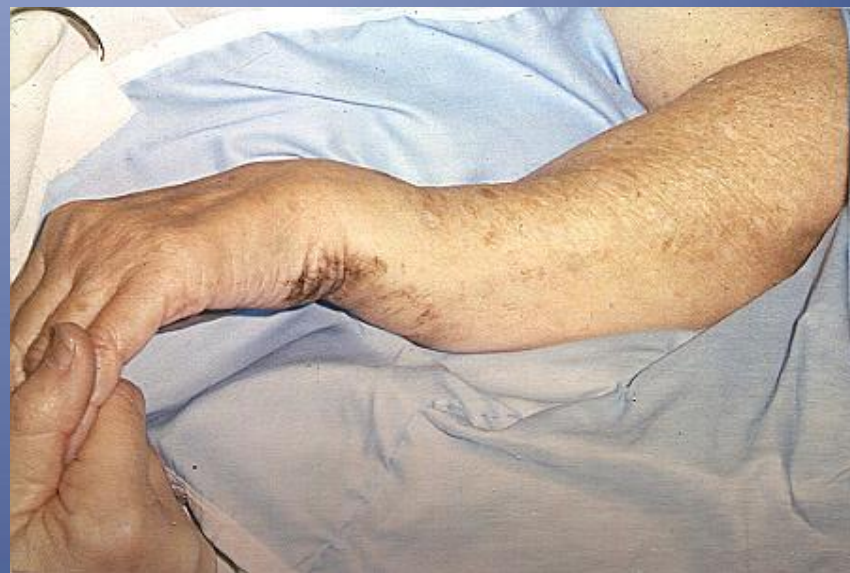- * Clinical parameters
 - * Open vs. Closed
 - * Neurovascular status
 - * Clinical deformity
- * Radiographic parameters
 - * Location
 - * Pattern
 - * Displacement
 - * Angulation
 - * Shortening

Treatment Principles

1. Reduction if necessary.
2. Immobilization (definitive or temporary).
3. Definitive treatment
4. Rehabilitation.

Initial (Reduction)

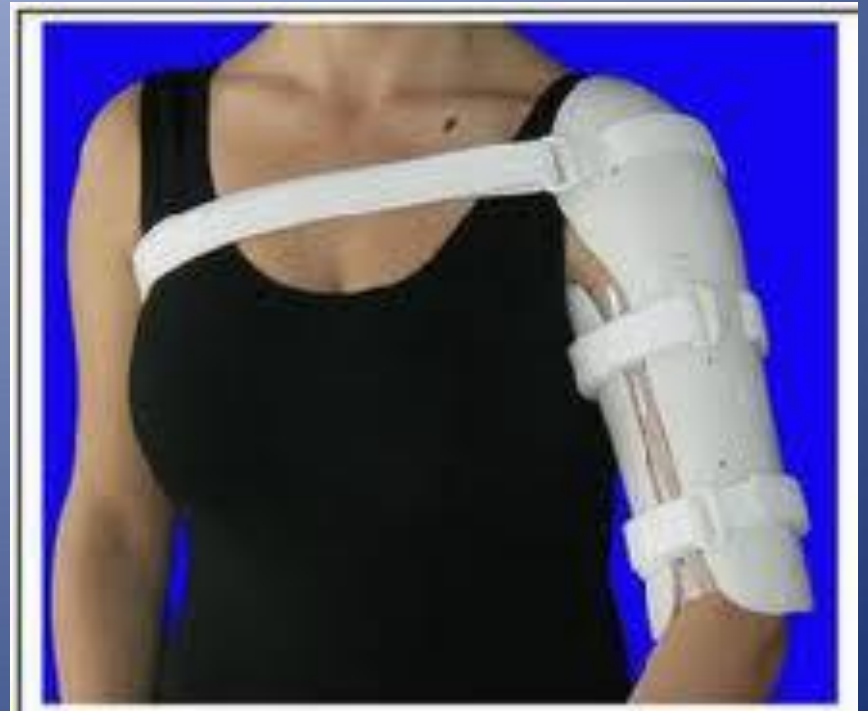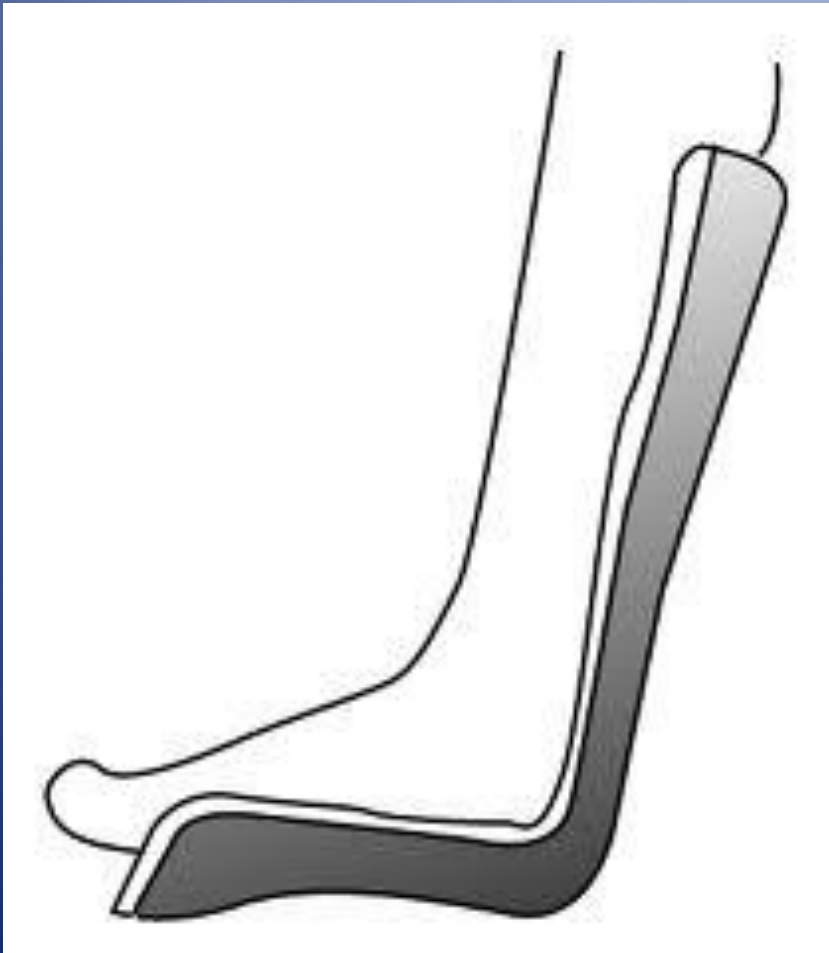
- IF fracture is displaced.
- Meant to re-align fracture fragments.
- To minimize soft tissue injury.
- Can be consider definitive if fragments' position is accepted.
- Should be followed by immobilization.

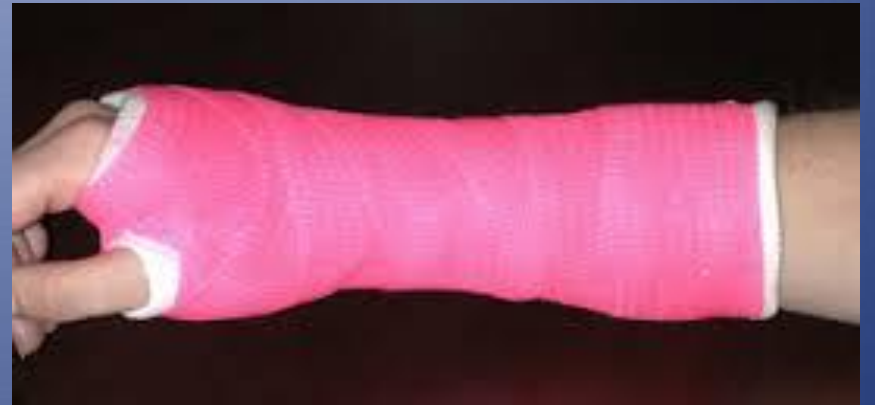
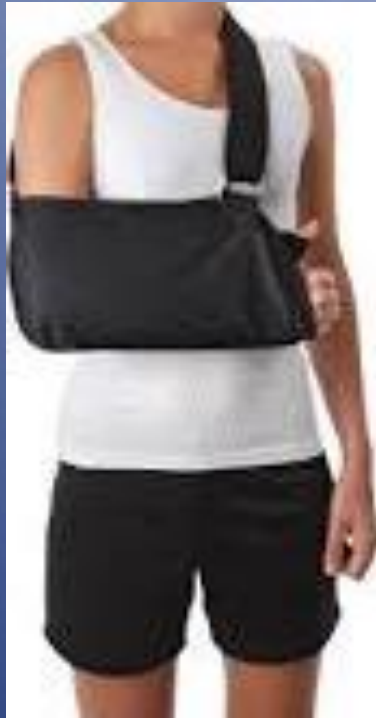
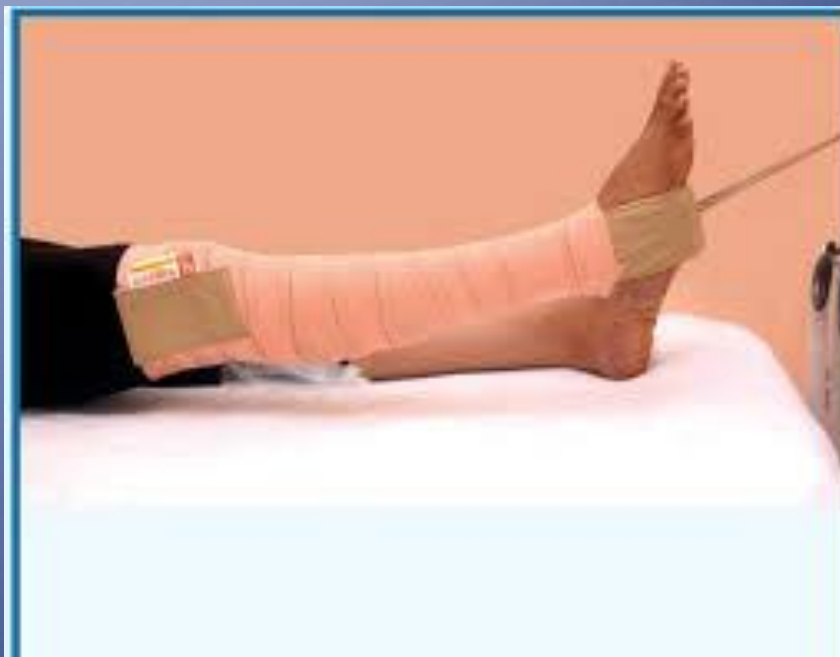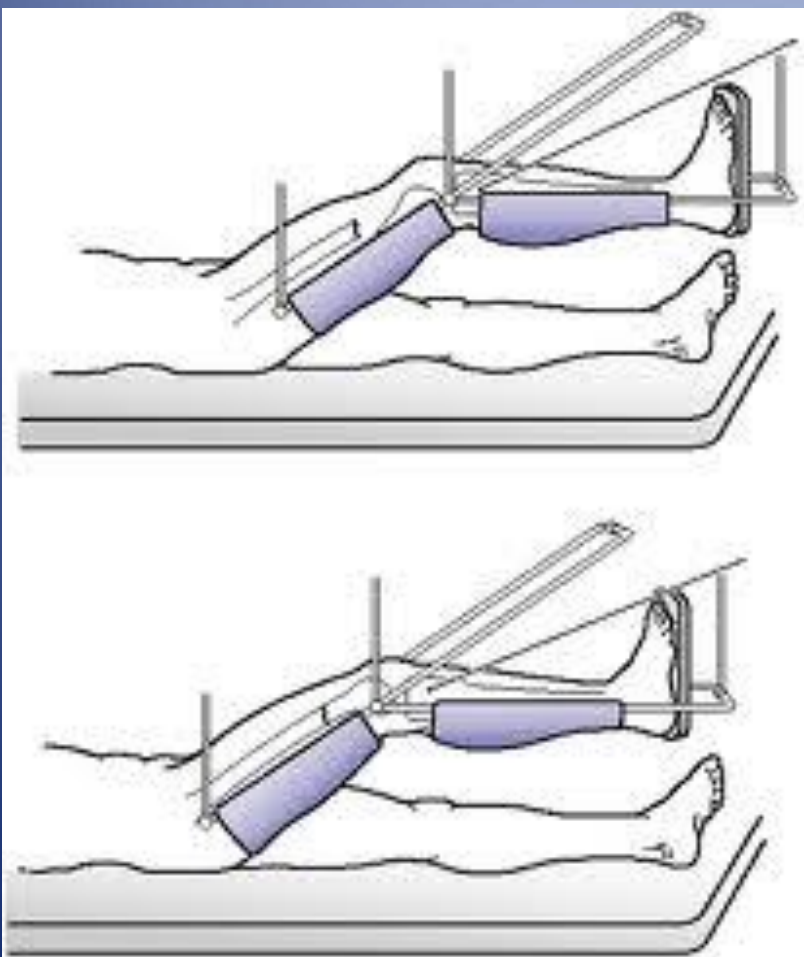
Initial (Immobilization)

- To hold reduction in position.
- To provide support to broken limb
- To prevent further damage.
- **Control the Pain**

Initial (Immobilization)



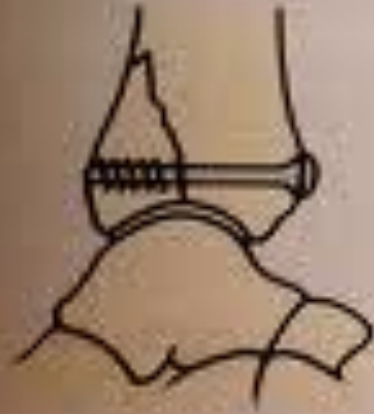



Definitive

- If satisfactory reduction can not be achieved or held at initial stage.
- Reduction can be attempted close or open (surgery)
- Immobilization can be achieved with:
 - Plate and screws.
 - IM nail
 - EX-fix

(a)



(b)



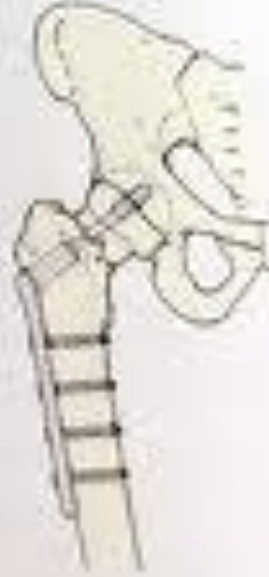(c)



(d)



(e)



Treatment: Principles

- Rehabilitation
 - Motion as early as possible without jeopardizing maintenance of reduction.
 - Wt bearing restriction for short period.
 - Move unaffected areas immediately

Treatment: Principles

- * Reduce (if necessary)
 - to maximize healing potential
 - to insure good function after healing
- * Immobilize
 - * to relieve pain
 - * to prevent motion that may interfere with union
 - * to prevent displacement or angulation of fracture
- * Rehabilitate
 - * to insure return to function

Multiple Trauma

- Multi-disciplinary approach.
- Run by Trauma Team Leader (TTL) at ER. Orthopedic is part of the team.
- Follow trauma Protocol as per your institution.
- Treatment is prioritized toward life threatening conditions then to limb threatening conditions.

Take home points

- * Fractures hurt –immobilization relieves pain.
- * R/o open fracture, Compartment syndrome and N/V injuries.
- * Principles of fracture treatment:
 - * Reduce (if necessary)
 - * Immobilize
 - * Rehabilitate

QUESTIONS?

THANKS