

# Spinal Injuries

Khalid A. AlSaleh, FRCSC

Associate Professor

Dept. Of Orthopedics

# Objectives

- The ability to demonstrate knowledge of the following:
  - Basic anatomy of the spine
  - Initial assessment and treatment of spinal injuries at the field
  - Management of Cauda equina syndrome
  - Principle of spinal stability
  - Basic understanding of neurologic syndromes caused by spinal trauma

# Spine Pathology Red Flag Conditions

- Cauda Equina/severe neurologic injury
  - perianal numbness, decreased rectal tone, loss of movement in the extremities
- Tumor weakening the vertebrae
  - causing cord compression or vertebral fracture
- Infection weakening bone
  - causing disc/vertebral destruction or cord compression.
- Traumatic Spine Fracture
  - causing vertebral angulation, pain, or neuro compromise.



# Incidence and Significance

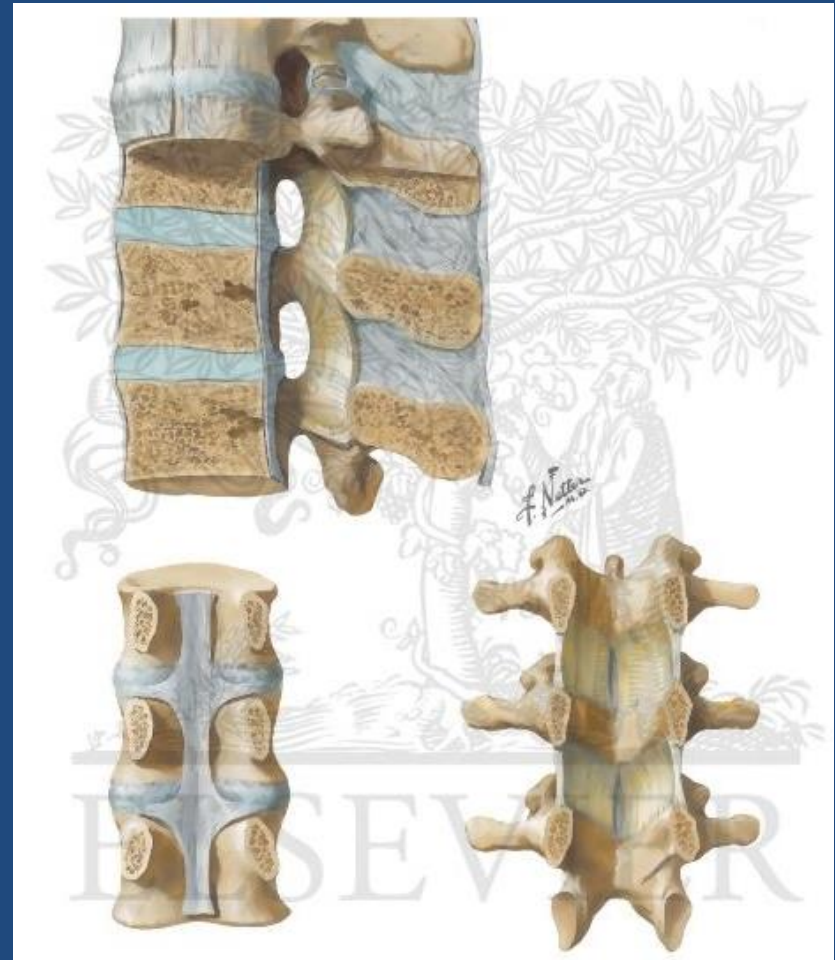- 50000 cases per year
- 40-50% involving the cervical spine
- 25% have neurologic deficit
- Age: mostly between 15-24 years
- Gender: mostly males (3:1)

# Mechanism of Injury

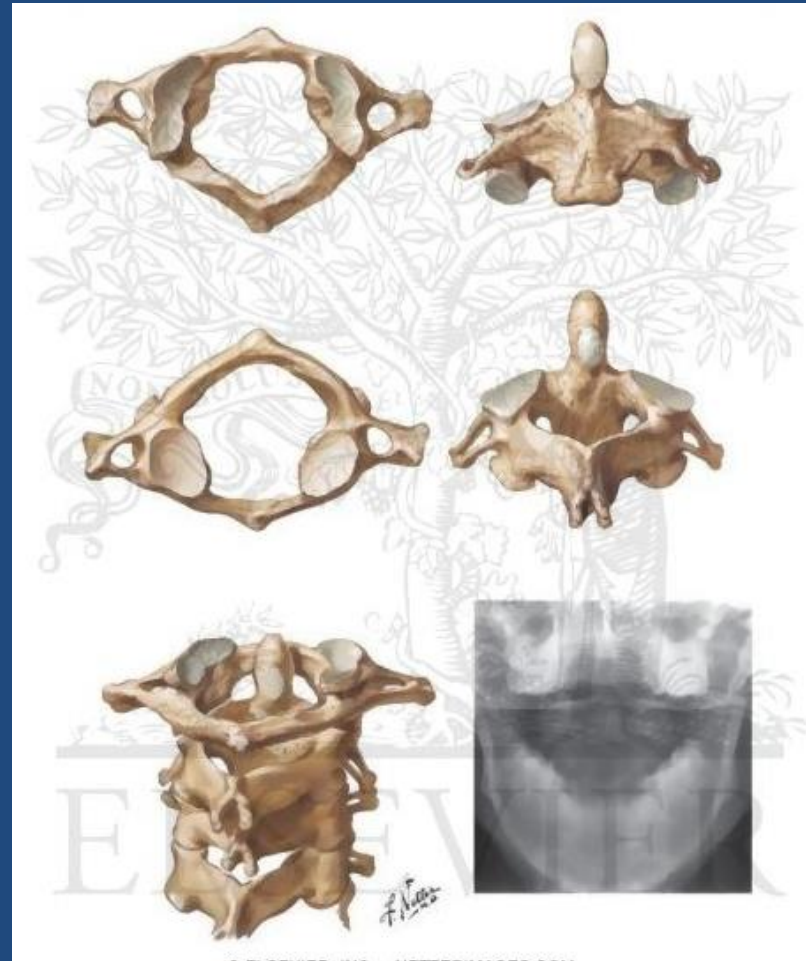- MVA: 40-55%
- Falls: 20-30%
- Sports: 6-12%
- Others: 12-21%

# Anatomy of the Spine

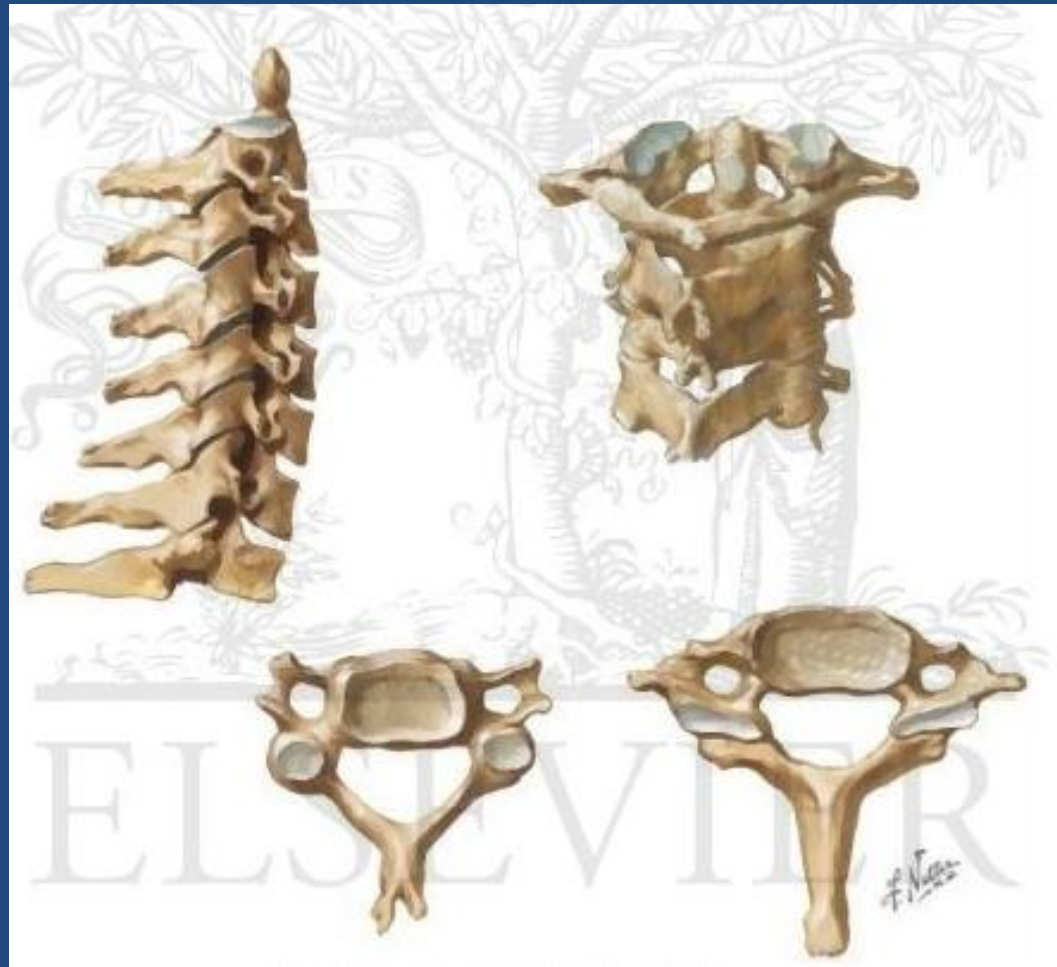- Bones
- Joints
- Ligaments
- muscles



# Cervical Anatomy: C1 & C2

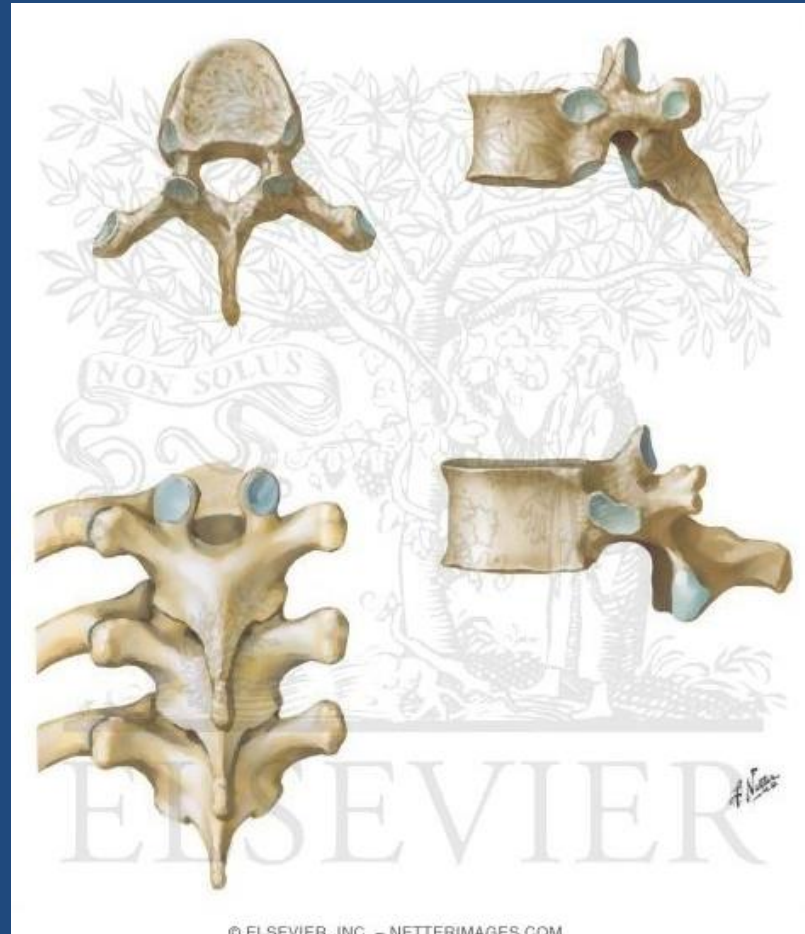


# Cervical anatomy: C3-C7

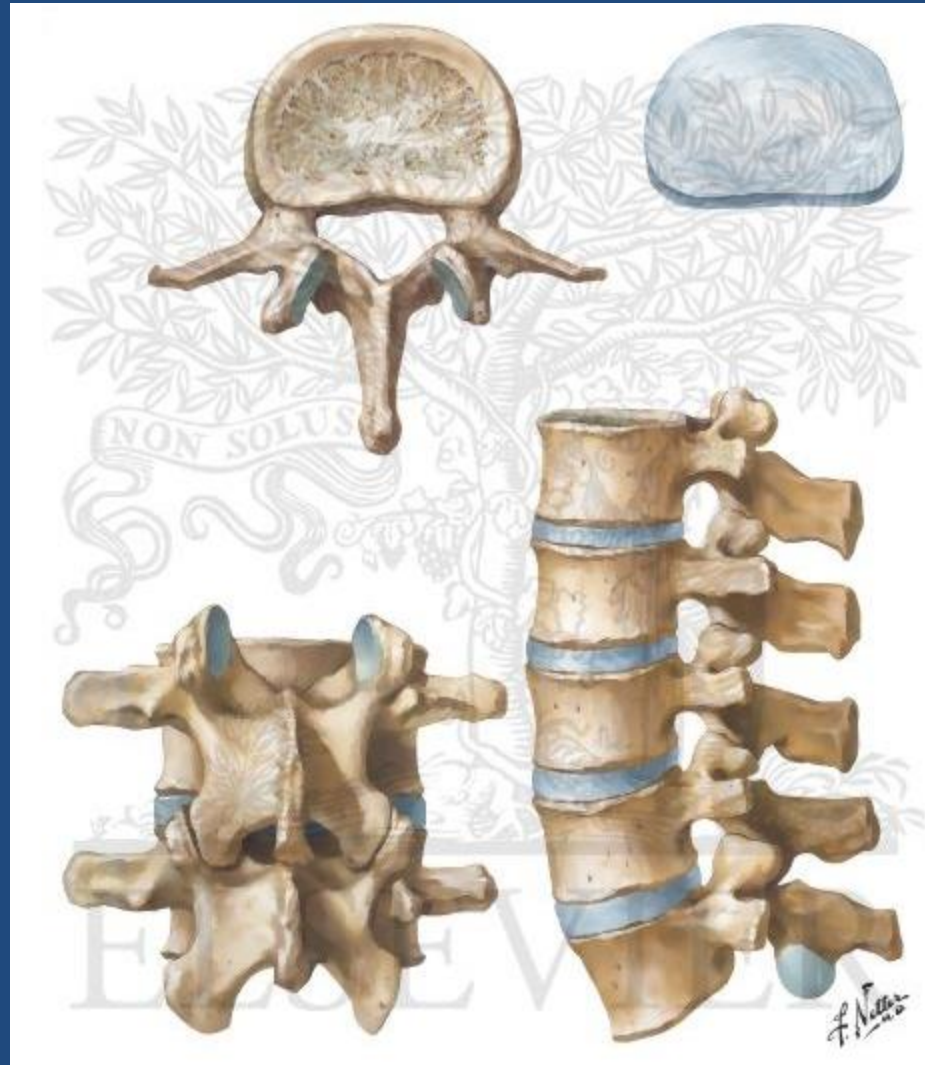




# Thoracic Spine



# Lumbar Spine

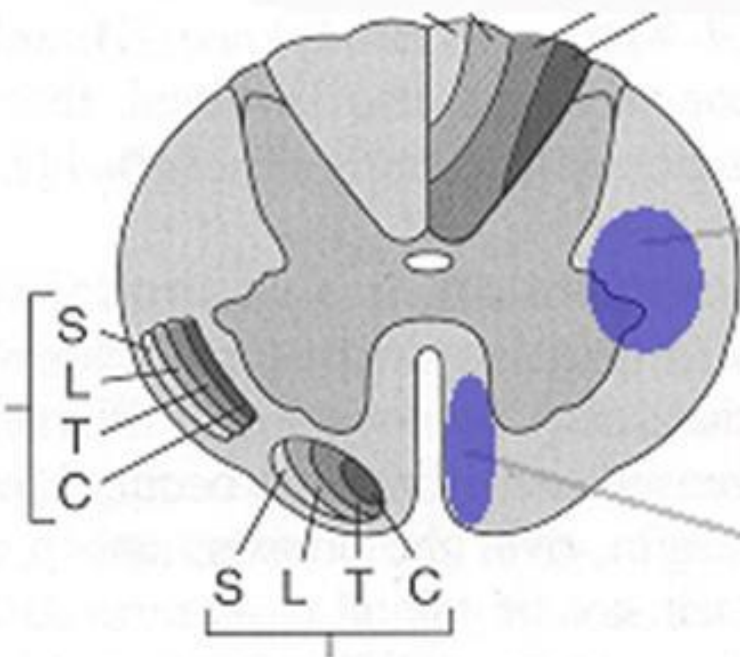


Posterior column  
(touch, pressure,  
vibration, joint position)

Lateral  
corticospinal  
tract

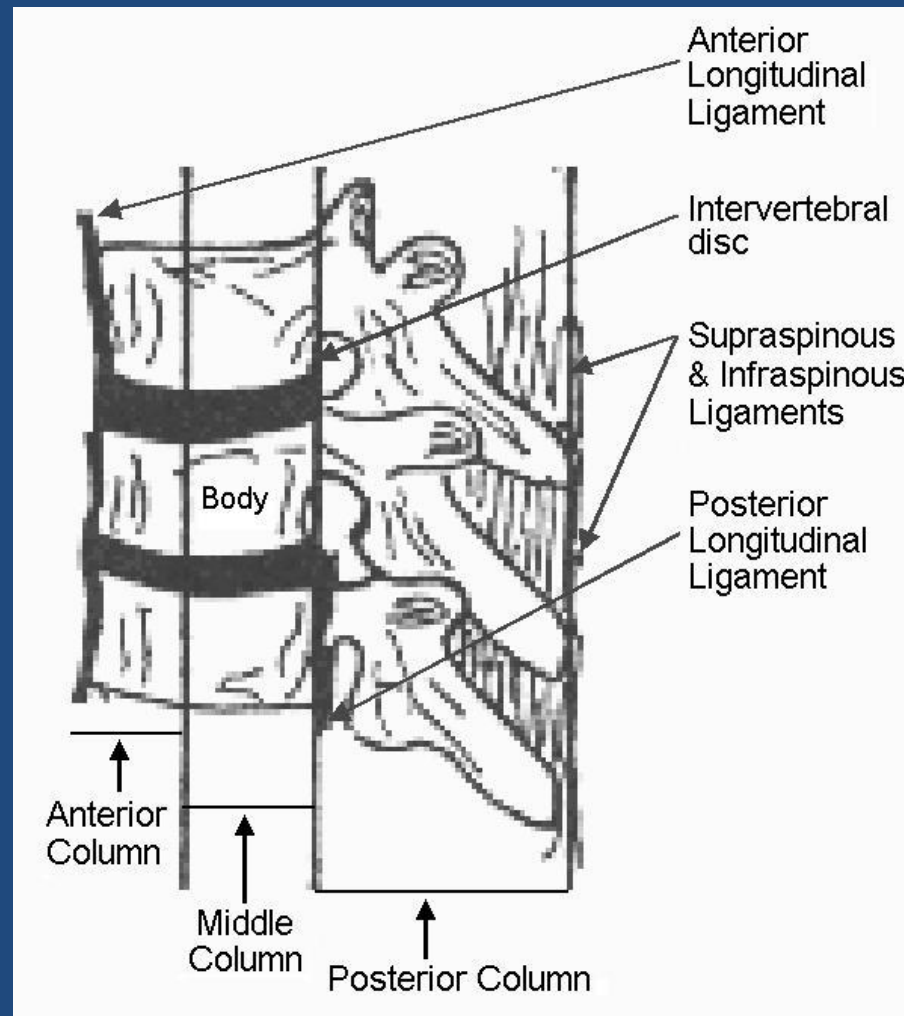
Lateral  
spinothalamic tract  
(pain, temperature)

Anterior  
corticospinal  
tract



Anterior spinothalamic tract  
(touch, pressure)

# The Three columns

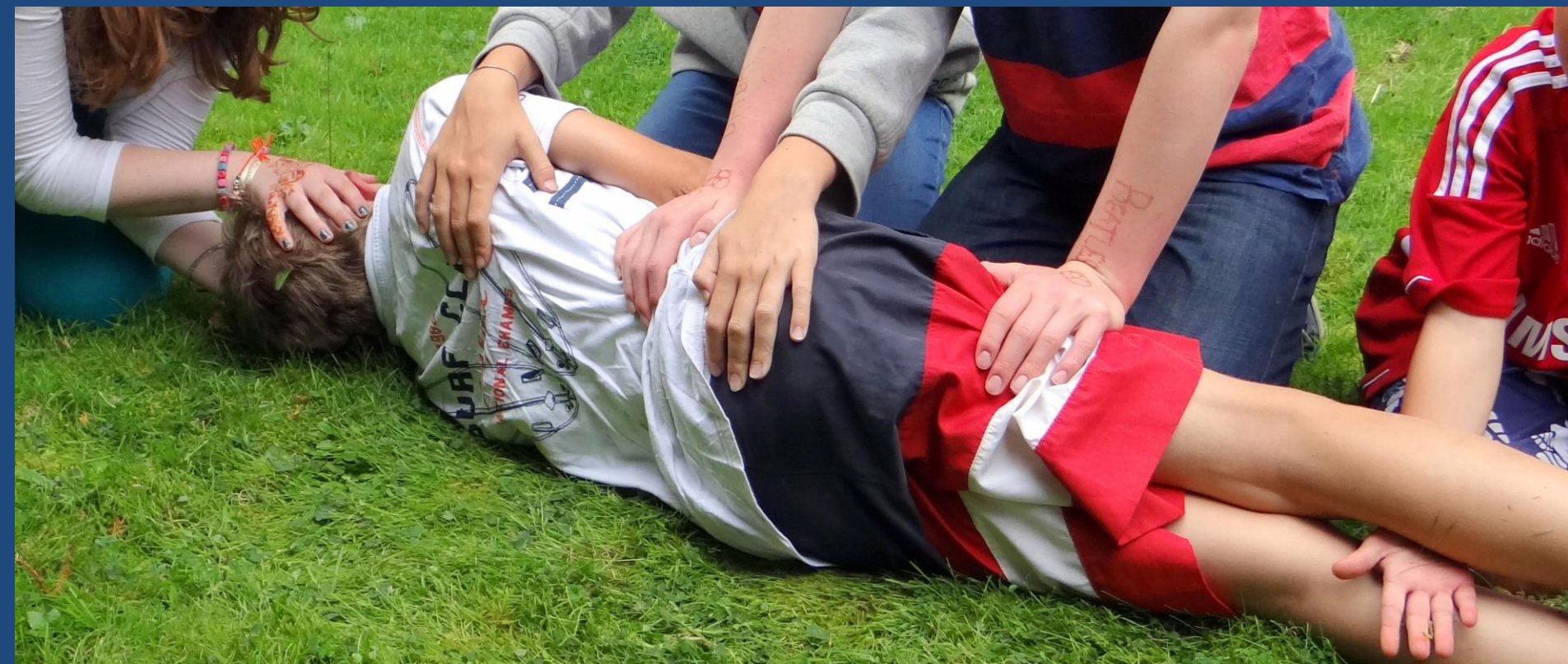

# Assessment of the spine injured pt.

- Immobilization
- History:
  - Mechanism of injury:
    - compression, flexion, extension, distraction
  - Head injuries
  - Seat belt injury
- Physical examination
  - Inspection, palpation
  - Neurologic examination

# Assessment

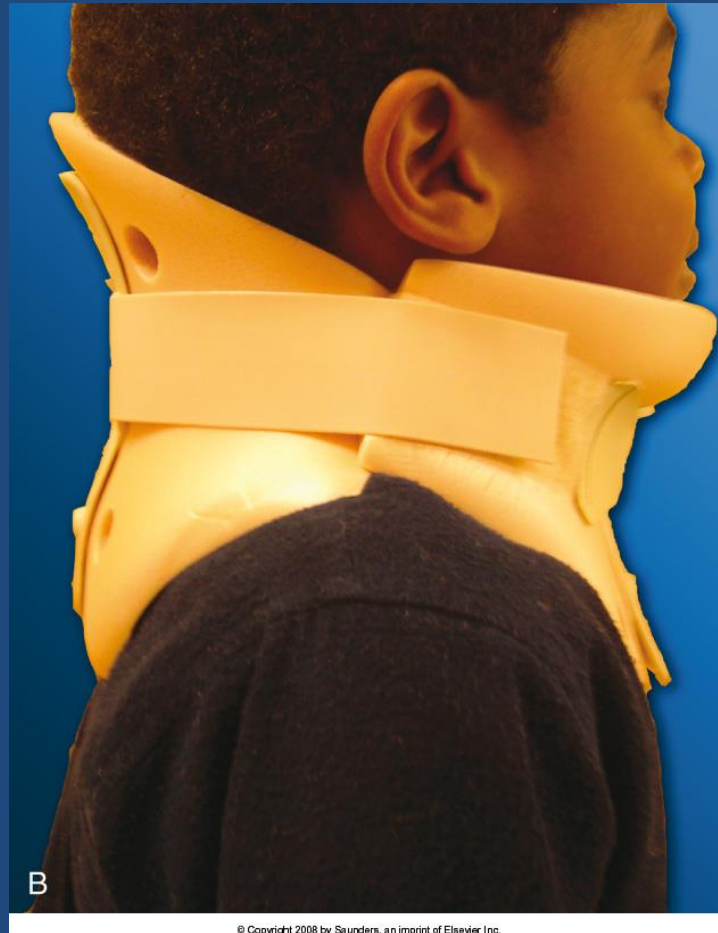- Immobilization.



inspection, palpation.

Neck injury assessment.

# Cervical collar

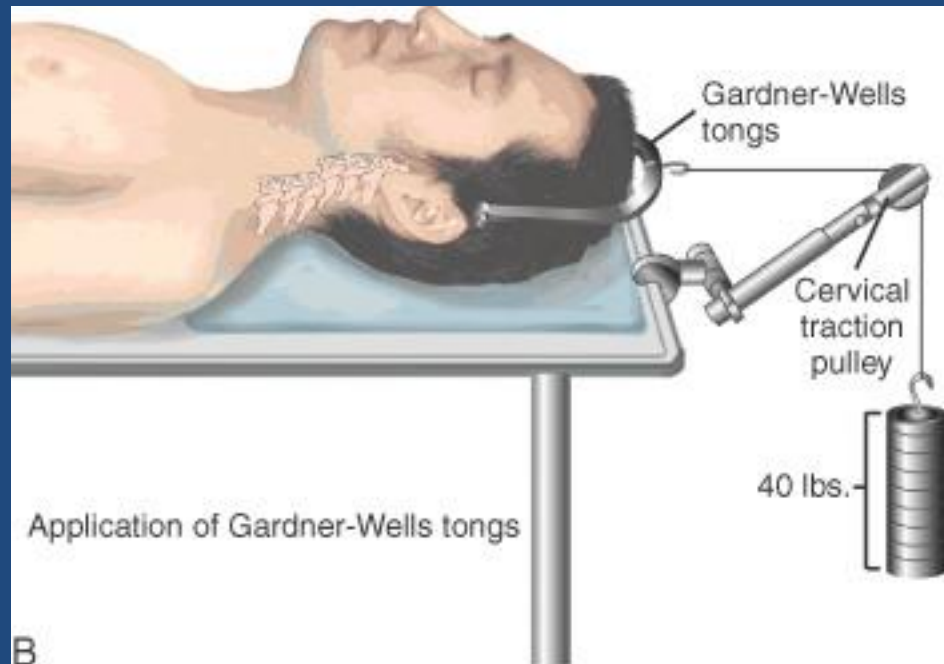


# Spine board





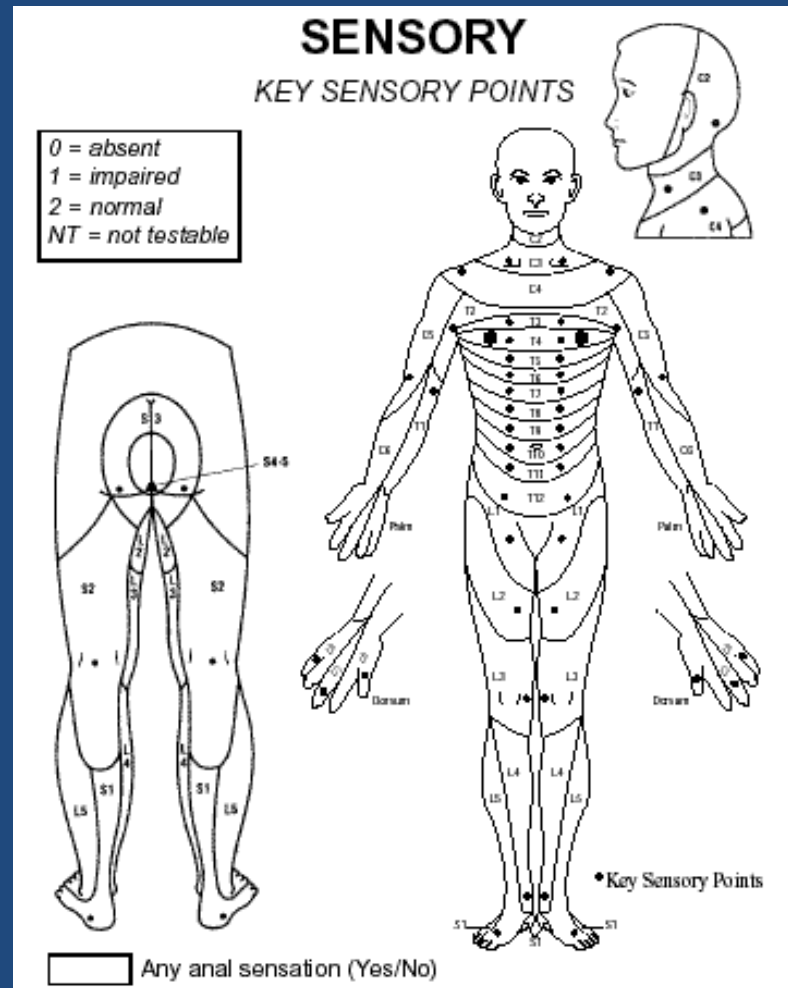
# Cervical traction



**Fig. 10-15B** A, Gardner-Wells tongs, a C-shaped ring with spring loaded pins that are placed approximately 1 cm above the pinna of the ear. B, Gardner-Wells tongs in place with weighted traction in an awake and alert patient.

© Copyright 2008 by Saunders, an imprint of Elsevier Inc.

# Dermatomes



# ASIA classification

## ASIA IMPAIRMENT SCALE

- A = Complete:** No motor or sensory function is preserved in the sacral segments S4-S5.
- B = Incomplete:** Sensory but not motor function is preserved below the neurological level and includes the sacral segments S4-S5.
- C = Incomplete:** Motor function is preserved below the neurological level, and more than half of key muscles below the neurological level have a muscle grade less than 3.
- D = Incomplete:** Motor function is preserved below the neurological level, and at least half of key muscles below the neurological level have a muscle grade of 3 or more.
- E = Normal:** motor and sensory function is normal

## CLINICAL SYNDROMES

- Central Cord
- Brown-Sequard
- Anterior Cord
- Conus Medullaris
- Cauda Equina

# Neurologic examination

- Spinal cord syndromes:
  - Complete SCI
    - Flaccid paralysis below level of injury
    - May involve diaphragm if injury above C5
    - Sympathetic tone lost if fracture above T6
  - Incomplete SCI: Good prognosis for recovery
    - Central cord syndrome
      - Upper limb > lower limb deficit.
    - Brown-Sequard syndrome
      - Also called: cord hemi-section

# Other neurologic syndrome

- Conus medullaris syndrome
  - Mixture of UMN and LMN deficits
- Cauda-Equina syndrome
  - Urinary retention, bowel incontinence and saddle anesthesia
  - Usually due to large central disc herniation rather than fracture
- Nerve root deficit: LMN

- Spinal Shock
  - Transient loss of spinal reflexes
  - Lasts 24-72 hours
- Neurogenic shock
  - Reduced tissue perfusion due to loss of sympathetic outflow and un-opposed vagal tone
  - Peripheral vasodilatation
  - Rx.: fluid resuscitation

# Imaging

- X-rays:
  - Cervical: 3 views
    - AP, lateral and open mouth
  - Thoraco-lumbar: 2 views
    - AP & lateral
  - Flexion-Extension views
- CT: best for bony anatomy
- MRI: best to evaluate soft tissue

# Management of Spinal Injuries

- Depends on:
  - Level of injury
  - Degree and morphology of injury: **STABILITY**
  - Presence of neurologic deficit
  - Other factors



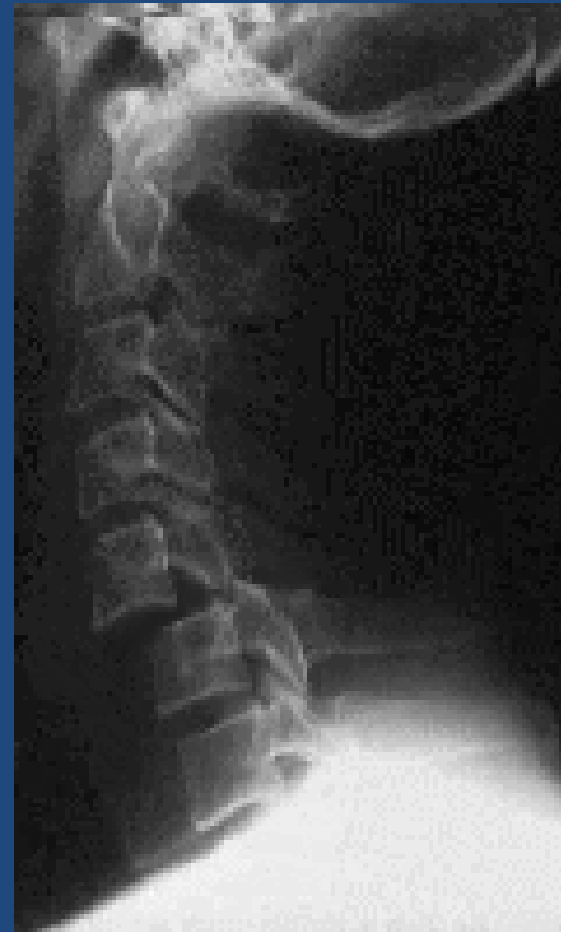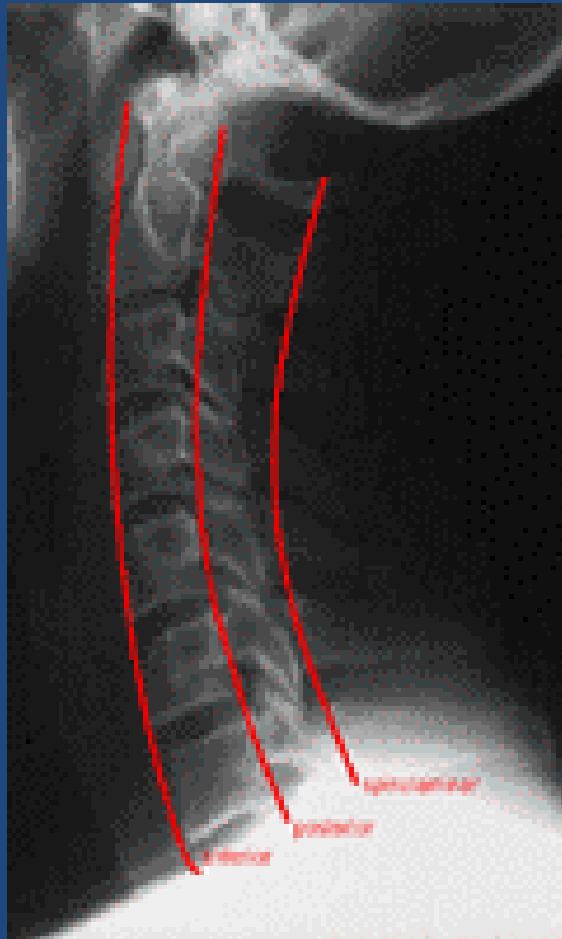- Some general rules:
  - **Stable** injuries are usually treated conservatively
  - **Unstable** injuries usually require surgery
  - Neurologic compression requires decompression

# Specific Injuries

# Cervical spine fractures

- Descriptive: depends on mechanism of injury
  - Flexion/extension
  - Compression/distraction
  - Shear
- Presence of subluxation/dislocation
- SCI:
  - high fracture results in quadriplegia
  - Low fracture results in paraplegia

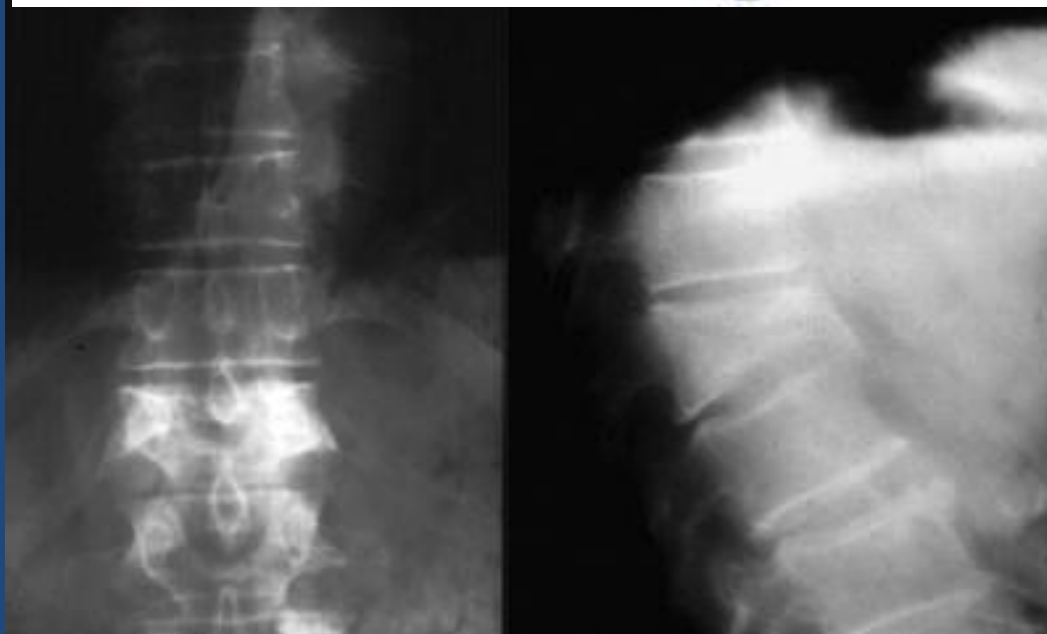
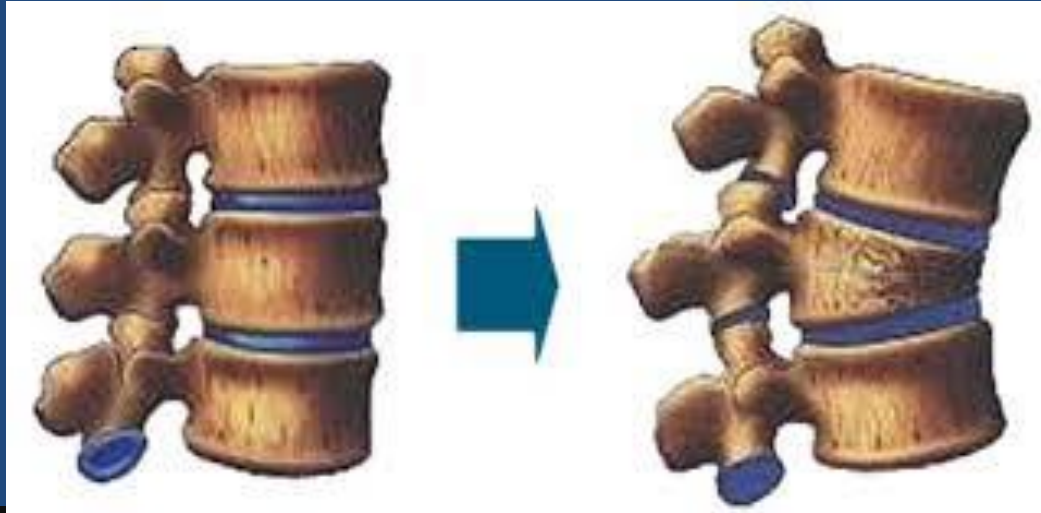
# Cervical spine fractures



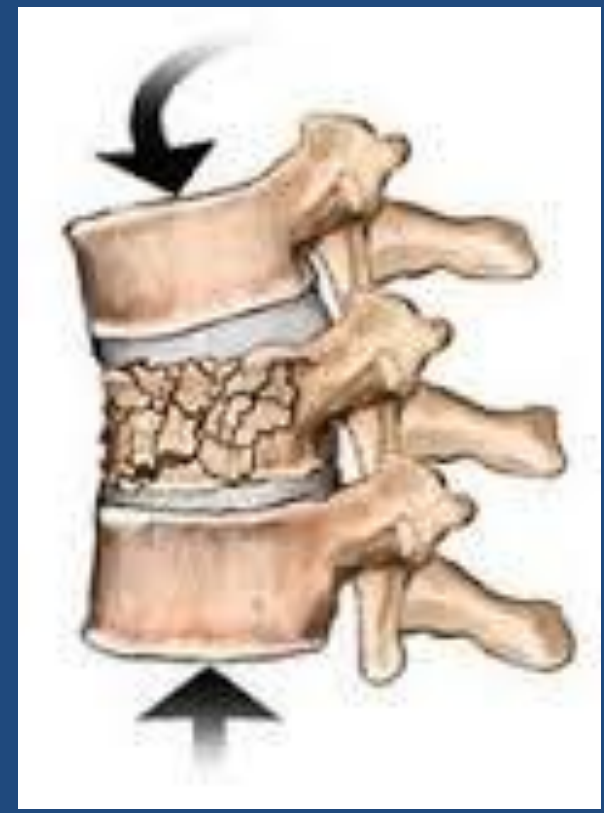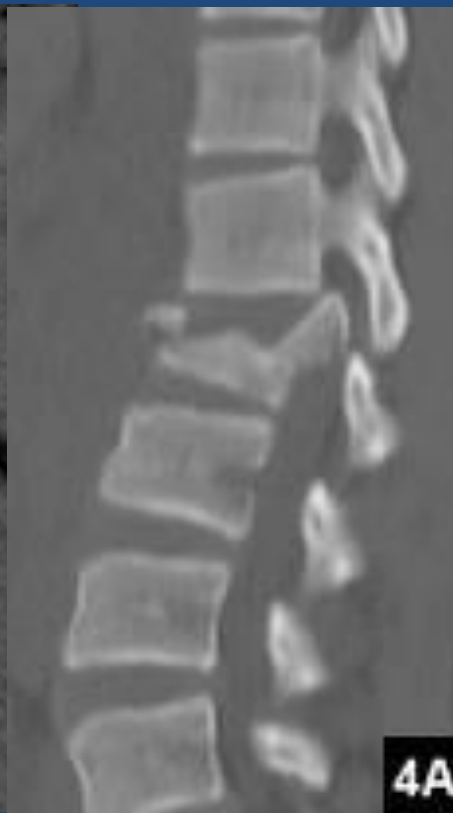
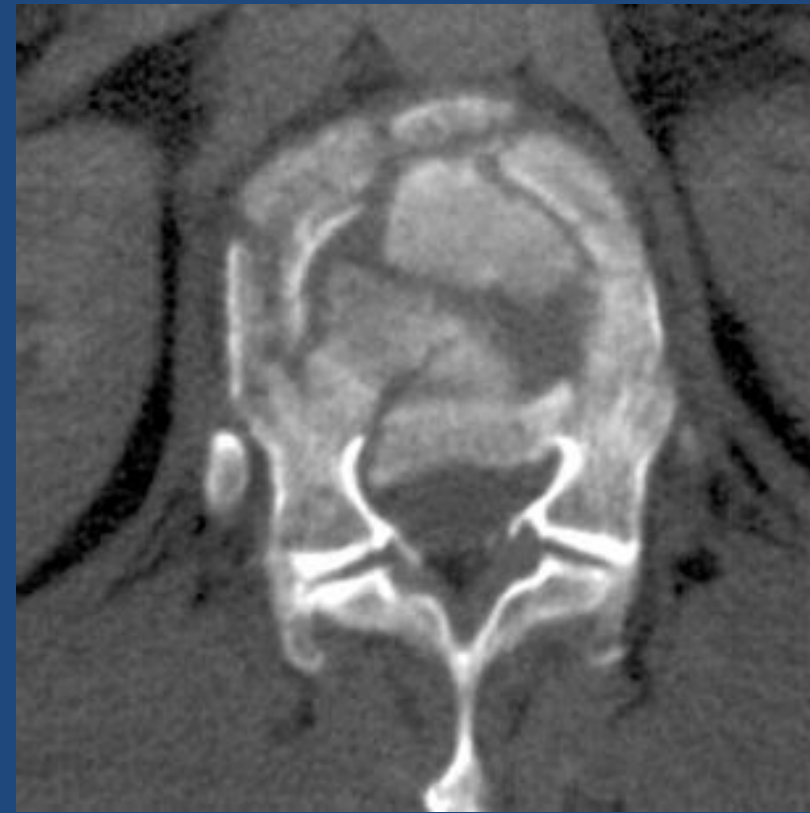# Thoraco-Lumbar fractures

- Spinal cord terminates at L1/2 disc in adult
  - L2/3 in a child
- 50% of injuries occur at Thoraco-lumbar junction
- Common fractures:
  - Wedge fracture (flexion/compression)
  - Burst (compression)
  - Chance (flexion/distraction)

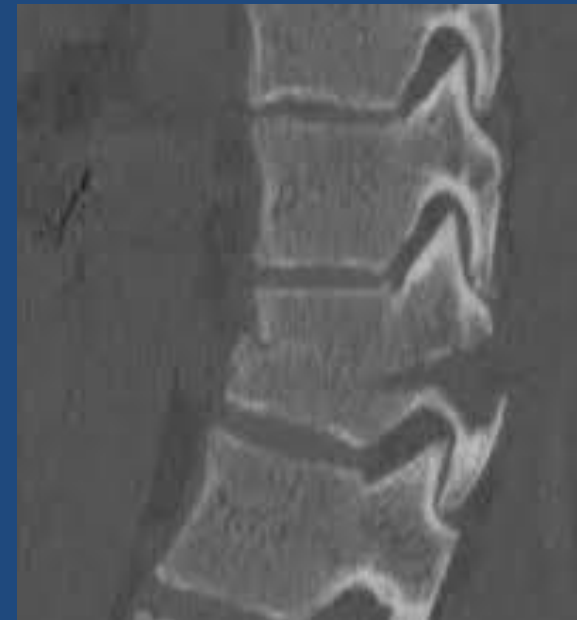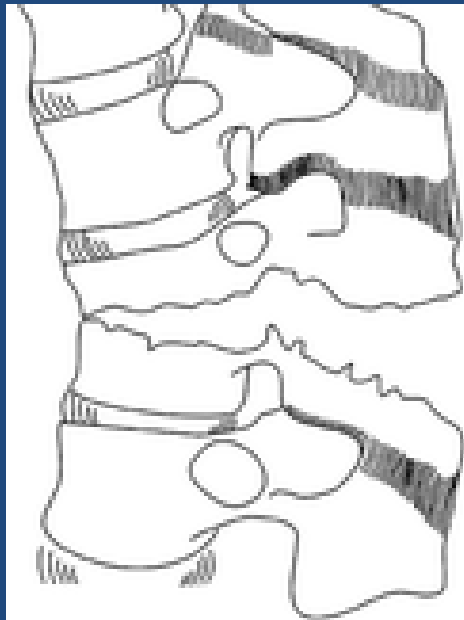
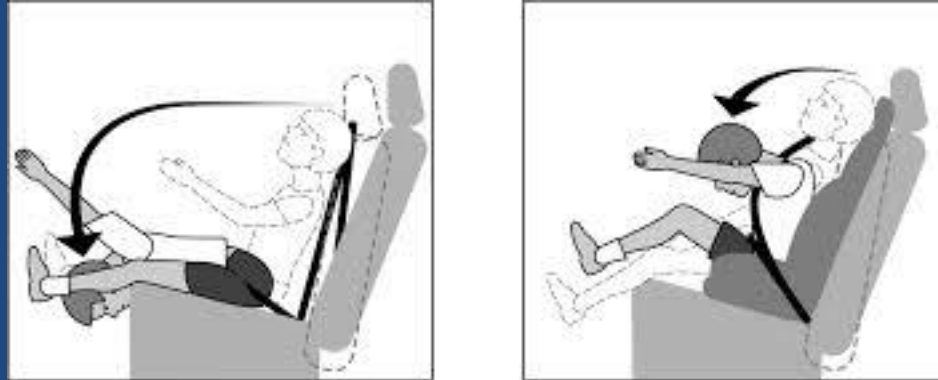
# Wedge Fracture



# Burst Fracture

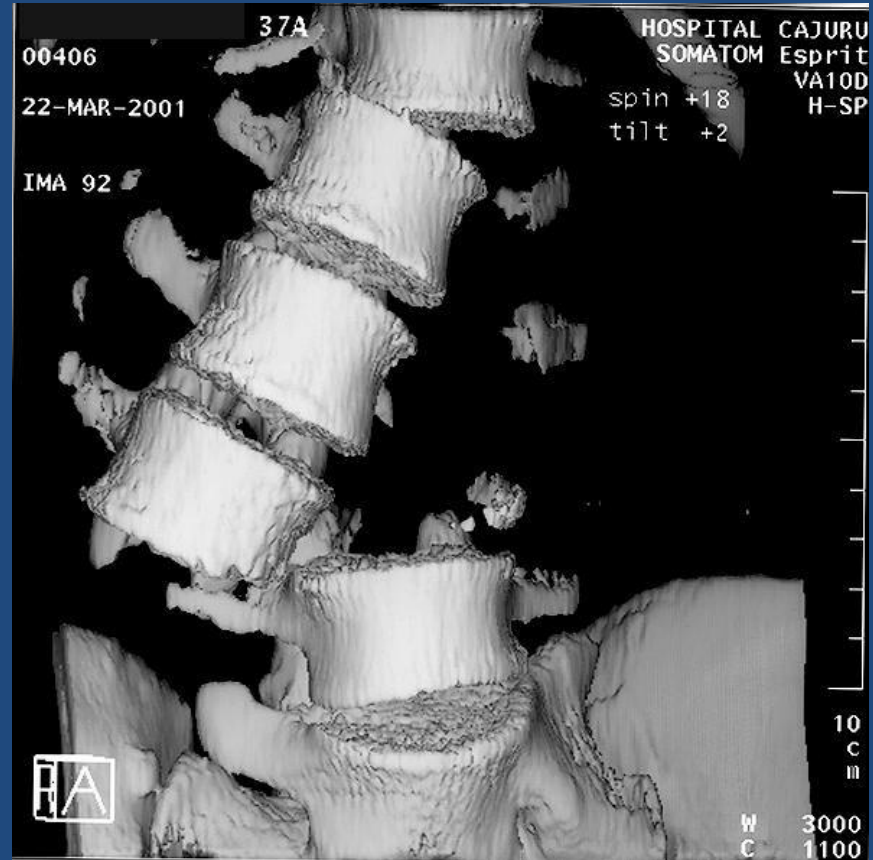
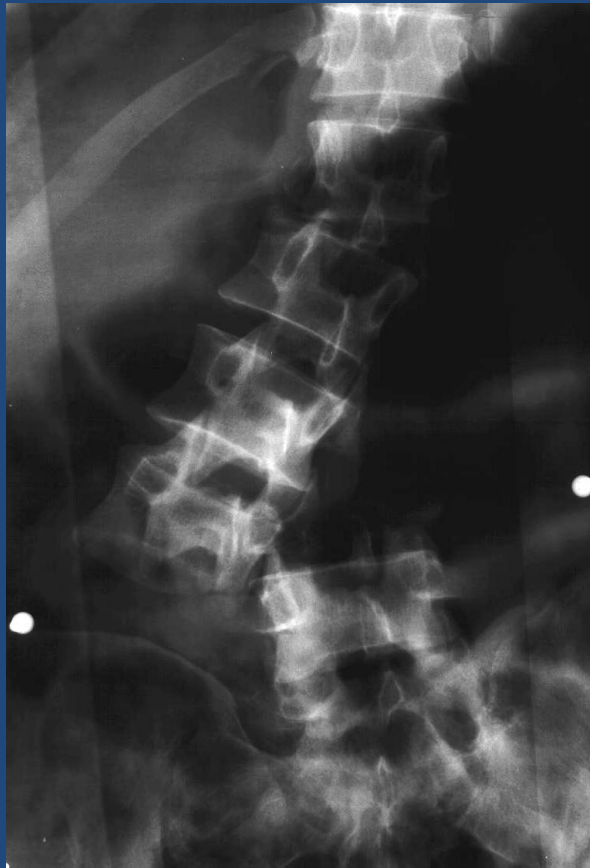

# Chance Fracture





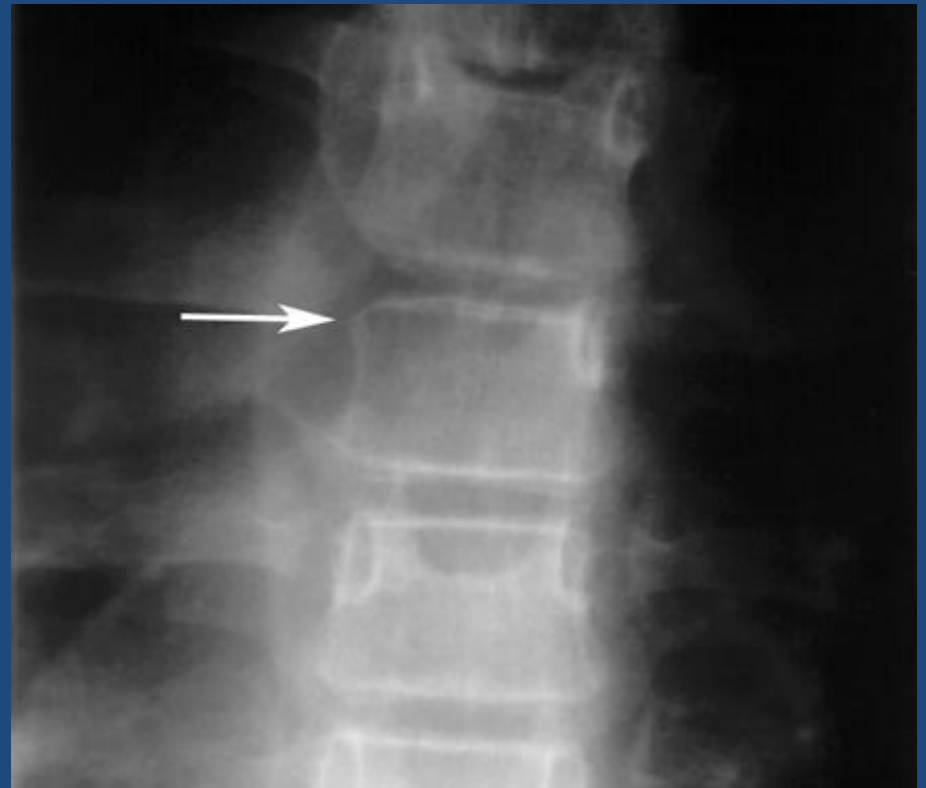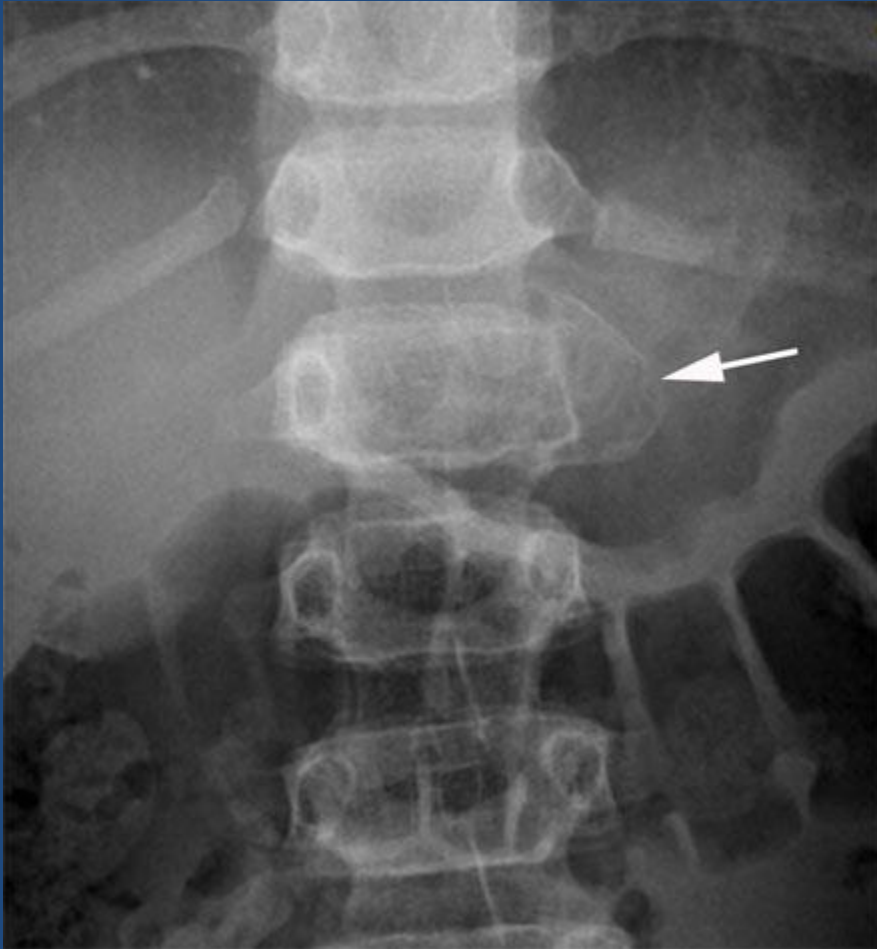# Fracture dislocation



# Pathologic fractures

- Usually due to infection or tumor
- Low-energy fractures
- Osteoporotic is common.
- X-rays: “winking owl” sign

# Winking Owl sign

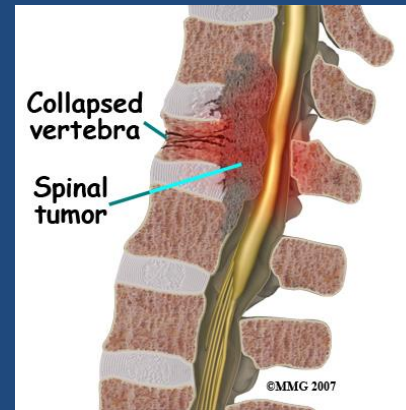


# Cauda Equina Syndrome

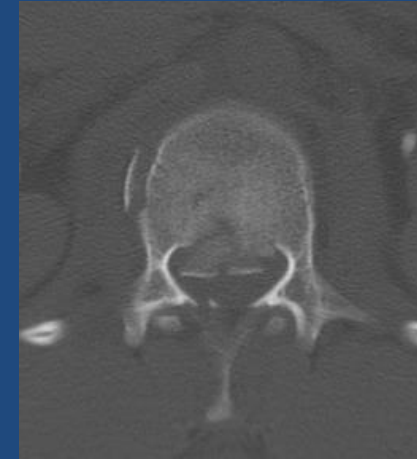
- A surgical emergency
- Requires full neurologic examination including rectal examination for anal tone
- Investigations: X-rays initially, but *MRI is mandatory as X-rays are usually unremarkable*
- Treatment: Emergency decompression-usually discectomy- within 24 hours.

# Causes of Cauda Equina Synd.

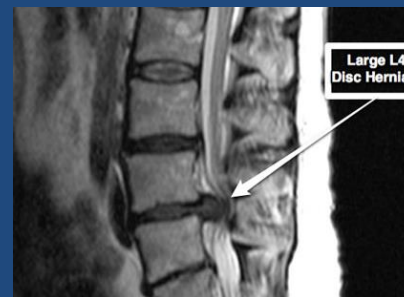
- Central disc herniation.
- Burst fractures of lumbar spine.
- Tumors compressing the lower spinal nerve roots.
- Penetrating injuries such as stab wounds or bullets.



Tumor



Burst fracture



Disc hernia

Thank You