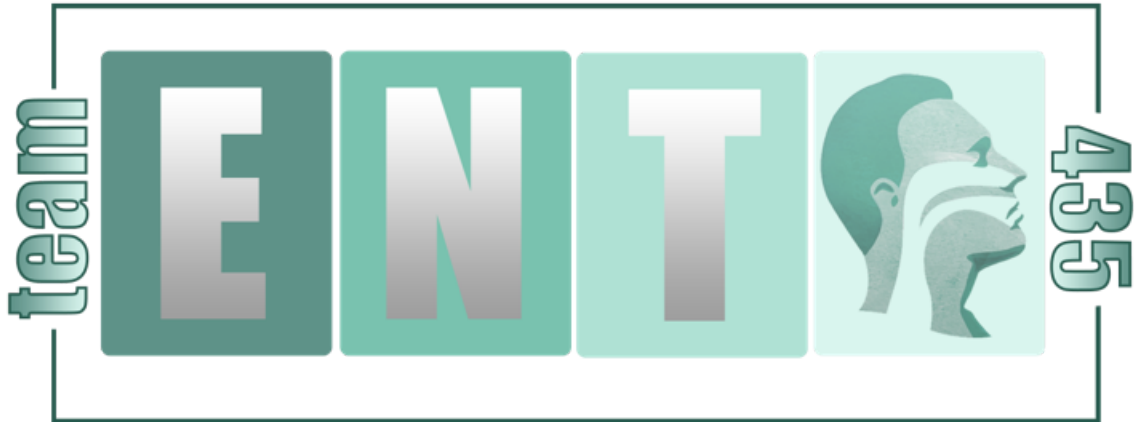



# Head & Neck I, II & III

Evaluation and Management of the Patients with a Neck Mass

## Objectives:

- Neck masses introduction, anatomy, diagnosis, differential diagnosis, examples.
- Thyroid anatomy, thyroid nodule evaluation, thyroid cancer, surgery and complications.
- Salivary glands anatomy, physiology (in brief), infections, autoimmune, and tumors.
- Tumors of oral cavity, introduction, premalignant lesions, leukoplakia, etc...
- Malignant lesions, SCCA.
- Tumors of pharynx, nasopharynx, oropharynx, and hypopharynx.
- Tumors of larynx (Laryngeal cancer and papillomatosis).
- **Most important: nasopharynx, history, thyroid, greater auricular nerve (what it supplies)**

[Color index: **Important** | [Dr's Notes & Handout](#) | [433 notes](#) | Extra | [MCQ's](#) ]

**Note: Don't panic** the 3 lectures end at page 24, from 25-35 only clinical cases, The last 8 pages "Other Neoplasms" not mentioned by the doctor, but included in the objectives, just read them! and the MCQ's are from QBank - The Dr's Handout all in this lecture. **Nobody will ask you about lymphoma , carotid body tumors.**

**Resources:** Slides + 434 team +Notes + Toronto notes + lectures notes ENT.

**Done by :** Faris AlMutairi & Samar AlOtaibi.

**Edited by:** Saleh Al Shawi & Nouf AlRushaid.

**Revised by :** Adel Al Shihri & Lina Alshehri.

## Introduction:

- ❖ Neck mass is a common complaint that requires systematic clinical approach in order to get a final diagnosis and set an appropriate management plan.
- ❖ The most effective and accurate screening tool is actually obtaining a good medical history and performing physical examination.

## Considerations:

- Age group: **any neck mass in a patient above 40, you have to rule-out malignancy.** (See the table)

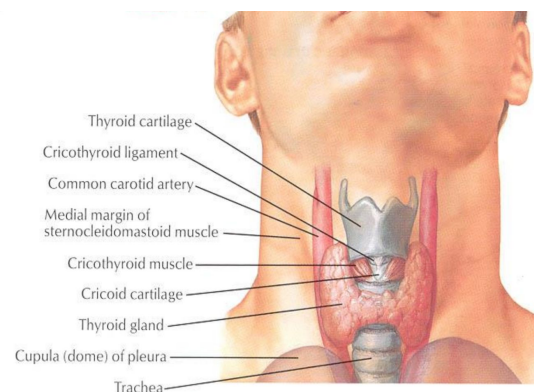
Age (yr)	Possible Causes of Neck Lump		
<20	1. Congenital	2. Inflammatory/Infectious	3. Neoplastic
20-40	1. Inflammatory	2. Congenital	3. Neoplastic
>40	1. Neoplastic	2. Inflammatory	3. Congenital

- **Location:** Any condition in ENT with **unilateral** manifestation (nasal obstruction, hearing loss, ear pain, neck mass etc.) **you have to rule out malignancy.** It is extremely important in order to have a clear DDX and clinical approach as a certain area of the neck has its own differential whether it is congenital or metastatic.
- **Duration:** **Week** or less think about **inflammatory**, **years** think of **benign** conditions, **months** to year think about **malignancy**.

## Anatomy:

**Anatomical landmarks:** Angel of **mandible and Clavicle and mastoid.** The **ONLY** obvious landmarks in every single patient including obese. Always look for bones!

- So, make sure you **locate them** before starting your examination.
- In the midline of the neck, there is a cricoid. Anything above the cricoid is called **upper midline** (your DDX will be B/W the carotids).
- Anything below the cricoid to the Suprasternal notch, we call it **lower Midline** (DDX related to thyroid lobes).

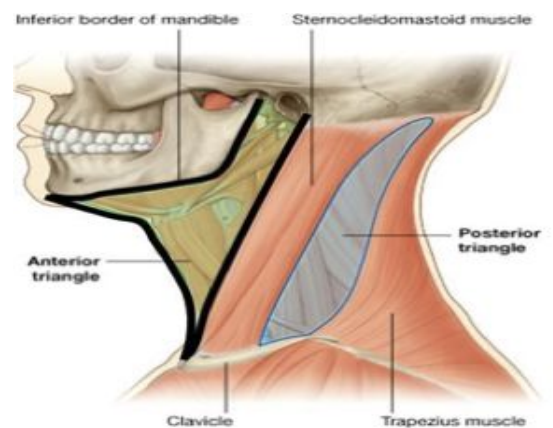
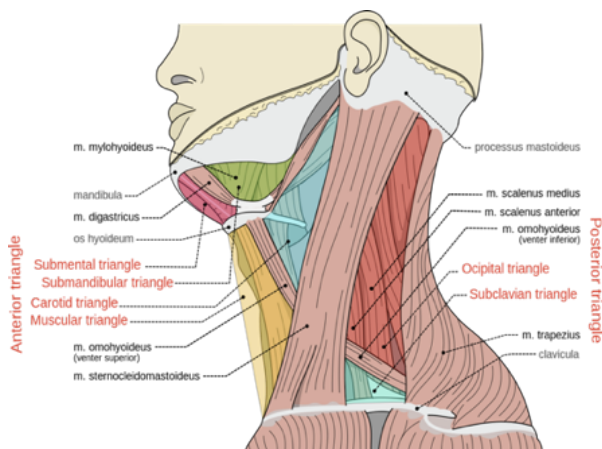


**Description of the picture in doctor's slides:**

- In the receding angle below the chin, the hyoid bone, situated opposite to the fourth cervical vertebra, can easily be made out. A finger's breadth below it is the laryngeal prominence of the thyroid cartilage; the space intervening between the hyoid bone and the thyroid cartilage is occupied by the thyrohyoid membrane.
- The outlines of the thyroid cartilage are readily palpated; below its lower border is a depression corresponding to the middle cricothyroid ligament.
- The level of the vocal folds corresponds to the middle of the anterior margin of the thyroid cartilage. **The anterior part of the cricoid cartilage forms an important landmark on the front of the neck; it lies opposite the sixth cervical vertebra, and indicates the junctions of pharynx with esophagus, and larynx with trachea.**
- Below the cricoid cartilage the trachea can be felt, though it is only in thin subjects that the separate rings can be distinguished; as a rule, there are seven or eight rings above the jugular notch of the sternum, and of these the second, third, and fourth are covered by the isthmus of the thyroid gland.

◆ **Neck triangles:**

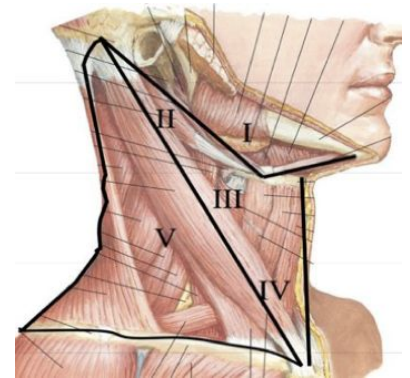
<u>Anterior triangle</u>	<u>Posterior triangle</u>
<p><b>Boundaries:</b></p> <ul style="list-style-type: none"> <li>➢ SCM posterior (<u>SCM separates A&amp;P triangles</u>).</li> <li>➢ Mandible superiorly.</li> <li>➢ Anteriorly the midline. It has 4 levels (L1-4, will be discussed down) of lymph nodes.</li> </ul> <p><u>Divided into:</u></p> <ul style="list-style-type: none"> <li>- <b>Submental triangle:</b> bounded by both anterior bellies of digastric and hyoid bone.</li> <li>- <b>Submandibular triangle:</b> bounded by anterior and posterior bellies of digastric and inferior border of mandible.</li> <li>- <b>Carotid triangle:</b> bounded by sternocleidomastoid, anterior belly of omohyoid, and posterior belly of digastric.</li> </ul>	<p>Bounded by sternocleidomastoid (anterior), trapezius, and middle third of clavicle.</p> <ul style="list-style-type: none"> <li>• It contains lymphatic level 5.</li> </ul> <p>Divided into:</p> <ul style="list-style-type: none"> <li>- Occipital triangle.</li> <li>- Subclavian triangle.</li> </ul>



- ❖ **Lymphatic triangles: anatomical point of view**
  - Anterior: lied by midline anteriorly and SCM posteriorly.
  - Posterior: lied by SCM anteriorly and Trapezius posteriorly.

- ❖ **Lymphatic levels:** The lymph nodes in the neck are divided clinically into 7 levels. **IMPORTANT (clinical point of view)**

- **Level 1:** Between the 2 bellies anterior and posterior of digastric muscle and hyoid bone (in **submental** and **submandibular triangle**). Anything in this level just considered it “High below the mandible” at the region of submandibular gland.
- **Level 2:** Deep cervical chain (from skull base to hyoid bone). Basically is the “Jugular digastric” you will feel it immediately behind the angle of mandible, but anterior to the SCM high up.
- **Level 3:** Deep cervical chain (between hyoid bone to the omohyoid muscle). It’s at the middle of anterior triangle behind the angle of mandible.
- **Level 4:** Deep cervical chain (below omohyoid muscle). Lower at the neck just above the sternal notch.
- **Level 5:** Posterior triangle (from SCM to the trapezius muscle).
- **1-4 are in anterior triangle, 5 is posterior.**
- Level 6 & 7 are not palpable; you don’t need to know them in this level”



### ➔ Metastasis Location according to Various Primary Lesions:

- Most of the lesions in the lymphatics usually metastasized from a another area (most common cause )except Lymphoma.
- **Submental lymph nodes (level I):** examine the oral cavity, anterior nasal cavity, mouth floor, buccal area, and gums.<sup>1</sup>
- **level II:** oral cavity, nasal cavity, **naso/oro/hypopharynx**, **larynx**, and parotid gland.
- **Level III:** **Naso/oro/hypopharynx**, **larynx**, and oral cavity.
- **Level IV:** **Hypopharynx**, **larynx**, and **thyroid**.
- **Posterior triangle (Level V):** think of **Naso/oropharynx**, cutaneous structures of the posterior scalp and neck.
- **Level VI:** think of **thyroid**.

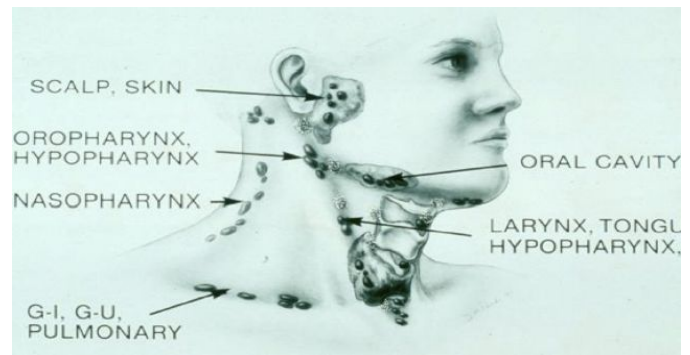
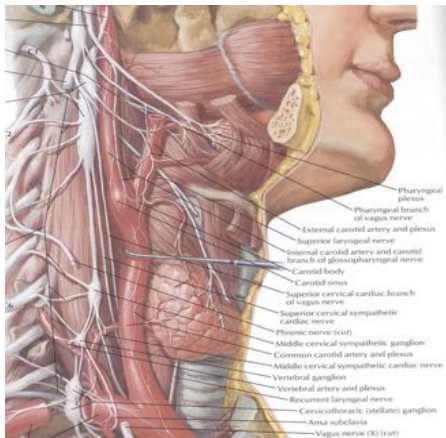
So basically relate the pathology to the level of lymph node , for ex: when you have lower neck cervical lymph node you won’t expect nasopharyngeal carcinoma , immediately will think about pathologies in that area.

Supraclavicular in the right side always think for tumors coming from the lung or gastrointestinal tract, or thyroid.

<sup>1</sup> when we have tonsillitis or tooth infection these are the lymph node that get swollen or tumor in oral cavity.

- Sometimes the carotid is prominent and appears as a pulsating mass it is just a normal vibration nothing to worry (**carotid bulb**) is an anatomical landmark always located at

the level of hyoid bone, so if you look for carotid body tumor it has to be around this area. It's extremely rare tumor.



## Diagnostic tests:

### History: IMPORTANT

1. **Duration and growth rate of mass(course):** malignant masses grow faster!

**Rule of 7's:** A mass that has been around 7 days is inflammatory, 7 months is malignant, and 7 years is congenital or benign!. Anything happen very quickly think of possibility of infection, or very slowly over months or weeks think about neoplastic lesions. something been there for long time most of the time this is either chronic infection like TB or benign lesion like Pleomorphic adenoma or branchial cleft cyst. The most common cause of cervical lymphadenopathy is upper respiratory tract infection(URTI).most of the time these can give u the dx.

2. **Age Group:** Pediatric patients (up to 15) generally have inflammatory related neck masses and developmental more than neoplastic masses. Consider neoplasia first in older patients!
3. **Location:** Esp. important when considering congenital and developmental masses because they occur in consistent locations. Spread of head and neck carcinoma is similar to an inflammatory disease and follows orderly lymphatic spread. Anything lower or posterior or very high in the neck think of something else rather than congenital.
4. **Inflammatory Hx:** Ask about recent fever, pain and tenderness. Any recent illness, URI, TB, sarcoidosis, fungal infection, dental problem, sinusitis or otitis?? Thyroiditis can occur post URI.
5. **Malignant Hx:** Ask about any previous Head & Neck malignancy. Also, **Risk Factors:**



#### Inflammatory vs. Neoplastic Neck Masses

	Inflammatory	Neoplastic
<b>History</b>		
Painful	Y	N
H&N infection	Y	N
Fever	Y	N
Weight loss	N	Y
CA risk factors	N	Y
Age	Younger	Older
<b>Physical</b>		
Tender	Y	N
Rubbery	Y	Occ.
Rock hard	N	Y
Mobile	Y	± fixed

- Night Sweats, Sun Exposure, Smoking, Alcohol (a consideration for Squamous Cell Carcinoma), Exposure to Radiation (Thyroid and Parathyroid Cancers) for medical/military and Otagia in elderly with normal ear exam suggestive of carcinoma.
- Dust exposure “النجارين يتنفسون نشارة الخشب والغبار كثير” They are at risk of sinonasal tumors.
- Previous burns or scar, especially irritated ulcer prone to have marginal ulcer like SCC or BCC.
- Immunodeficiency patients like HIV at risk of many cancers especially Kaposi sarcoma.
- Hx of other cancers. Almost 20% of head and neck cancers they will develop **metasynchronous cancer** “Means: Occurring at nearly the same time”!

## 6. Other Sx:

- Nasal Obstruction, Bleeding, Otagia, Odynophagia, Dysphagia, Hoarseness, Sore Throat of > 3 Weeks, Non Healing Ulcers, Hemoptysis, Wt Loss, Cervical Adenopathy, Hard Fixed Mass.
  - Hearing loss with blocked ear in adult and elderly – look for nasopharyngeal cancer.
  - If you have a patient with dysphagia and weight loss where is the tumor? cervical esophagus, pharynx, hypopharynx, tonsils.
  - A patient with otalgia with normal ears and have cervical lymph node mass > maybe in the nasopharynx, tonsils, base of tongue, oral cavity, even larynx can give you referred pain in the ear. **Keep in mind most of referred otalgia caused by TMJ or dental problems rather than tumors.**
  - Asymptomatic cervical mass account for about 12% for cancer and mostly it's SCC.
7. **Trauma:** Any recent history of trauma to the head or neck? In neonate ask about Forceps delivery (may cause hematoma mass in anterior neck or within the SCM muscle).
8. **Referred Pain:** Esp. to the ear because of referred pain via CN V, IX or XI can indicate an inflammatory or neoplastic process in any area in the upper aerodigestive tract mainly the oropharynx and hypopharynx.
9. **Speech Difficulties:** Voice Changes? Vocal cord paralysis suggests a thyroid carcinoma (**b/c of involvement of recurrent laryngeal nerve**) or primary laryngeal lesion.
10. **Family Hx:** Any history of head or neck malignancies? Medullary Thyroid Cancer runs in families. Consider MEN (rare).
11. **Past Medical History:** Diabetes, HIV, Malignancies? Cervical lymph node hyperplasia very common in HIV. Smoker? ETOH?
12. **Past Surgical History.**
13. **Nutritional Status:** Any history of iodine deficiency? Suggested by residence in a geographic area of endemic goiter.

#### 14. Hypo/Hyperthyroidism Sx:

- Hypothyroid Sx: Complaints of fatigue, cold intolerance, weakness, lethargy, weight gain, constipation, dry coarse skin, thin hair etc.
- Hyperthyroid Sx: Complaints of unexplained nervousness and sweating, heat intolerance, weight loss, palpitations, an enlarging neck mass, and ocular prominence (exophthalmos).

#### 15. Hyperparathyroidism Sx: "Bones, Stones, Abdominal Groans, Psychic Moans and Fatigue Overtones."

- **Bones**: aches and arthralgias result from fractures and structural changes.
- **Stones**: renal calculi because of hypercalcemia.
- **Abdominal Groans**: also b/c of hypercalcemia. Dehydration and constipation. Pancreatitis. PUD may worsen.
- **Psychic Moans**: hypercalcemia can cause anorexia, N/V, thirst and polydipsia, mood swings, psychosis.
- **Fatigue**: lassitude and muscular fatigability.

#### → Common clinical findings:

- **Dysphagia**: is something serious you should pay attention whether it is progressive and/or associated with Weight loss suspect malignancy. However sometimes it is totally different and unrelated – as simple as GERD- but it is always better being cautious than relaxed.
- **Hoarseness**: it is of particular importance when it comes to distinguish between a primary vocal cord pathology i.e. laryngeal mass or an infiltrating neoplasm invading the recurrent laryngeal nerve causing paralysis e.g. malignant thyroid carcinoma.
- **Aspiration**.
- **B-symptoms**: (fever, weight loss, night sweat).

---

#### Alarming signs & Symptoms:

- ❖ **Hoarseness**: That's mean there is a mass affecting the larynx, could be neural like recurrent laryngeal nerve and the commonest cause is "thyroid carcinoma". If we're talking about elderly smoker patient so, it's lung cancer.
  - Patient with recurrent laryngeal nerve injury and you examine his larynx and completely normal except vocal cords not moving, *How will present and what kind of hoarseness will has?* **Breathy voice!** Weak but not harsh. He speaks less number of words, because the vocal cord are paralysed so less air pressure.
  - Then, what you need to produce a normal voice? 1)Good vocal cords closure. 2)Good lung volume so, you can finish your sentence properly. 3)Good mucosal waves.

- If you have a COPD patient he can't generate enough pressure yet their voice quality is good but short sentence. Their phonation time is short.
- Normal Phonation time = 20-30 seconds.
- How to examine the phonation time? You ask them to take a deep breath and say "eeeeee" and count.
- Patient with vocal cords paralysis basically there will be a gap so the air escape too much and phonation time only 2 sec > Breathy voice And fragmental speech. كلامه يكون مقطع.
- What are the things that gives us a abnormal mucosal waves? Vocal cords nodules and polyps and cancer. So, why do they lose their voice quality? Because the mucosal waves are absent in that area with tumor or polyps.
- The first thing to have in vocal cords carcinoma is "Hoarseness"!!! And you can't roll out laryngeal carcinoma in any patient with hoarseness except by "**Direct flexible laryngoscope**".
- **We can see the mucosal waves by "Stroboscope".**
- ❖ **Unilateral nasal blockage.** In children most commonly a Foreign body. When you should worry about the blockage in children? Very rarely due to neoplasms, but most common due adenoids enlargement, sinusitis, foreign body and if you think of malignancy may be due to lymphoma or rhabdomyosarcoma. They will have other symptoms like eye proptosis, loss of vision, mass extending from the nose.
  - **In adults:** any unilateral nasal obstruction is probably due to tumor either in the nasal cavity or nasopharynx. You can't roll that out without endoscopy in the clinic.
- ❖ **Ears pain** with complete normal examination of it, you should think of possible causes in head and neck. The most common cause of otalgia with normal ear is TMJ and dental problems.
- ❖ Ipsilateral otalgia with normal otoscope direct attention to base of tongue, supraglottic, hypopharynx, larynx and nasopharynx.
- ❖ unilateral serous otitis media you should direct exam to nasopharynx why? eustachian tube blockage! one of the comment presentation.
- ❖ **Epistaxis** in children most commonly because of nasal picking, nasal dryness, adenoids enlargement. But in adults you have to make sure there is no nasopharyngeal carcinoma b/c epistaxis one of the classical presentation of it.
  - Classical presentation for nasopharyngeal carcinoma: Neck mass, slowly growing, Conductive hearing loss in the same side due to obstructed eustachian tube → effusion in middle ear, epistaxis.
- ❖ **Neck mass** Any neck mass it's an alarming sign.
- ❖ **Non healing ulcer** it's an indication of serious problems. Most likely tumors like SCC.
  - **Tongue ulcer** Whatever you see in the tongue just biopsy it and then look for the cause. Unless if it's an **aphthous ulcer** which usually last for 7 days with complete healing or if the patient known to be immunocompromised with recurrent ulceration it's okay don't rush to biopsy.
  - **Persistent ulcer** more than 2 weeks it's an indication of biopsy, if it came back negative and you still suspecting tumor! Repeat the biopsy.

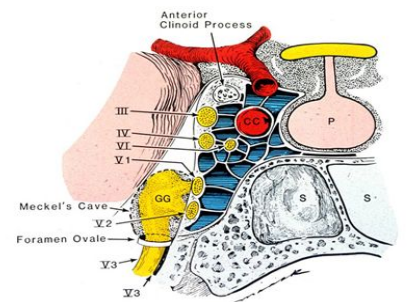


- ❖ **Facial weakness** What's the commonest cause of facial nerve weakness? **Bell's palsy**. It's a **diagnosis of exclusion**.

➤ So, **what's the criteria of bell's palsy?** 1) Acute in onset "Days, it doesn't happen over weeks or months". 2) Idiopathic. 3) It has to affect all facial nerve branches. 4) The recovery expected to be within 6 months.

- If it's only affecting the lower branch or has a clear cause like otitis media or if it's happening over weeks and if no recovery within 6 months >> **IT'S NOT BELL'S PALSYYY!!!** Look for possible skull base causes for example, do more investigation like CT & MRI.
- **I can't label any patient with bell's palsy if he has facial nerve paralysis due to otitis media or parotid mass**. Why? The acute treatment of Bell's palsy is steroids! so, you can't treat OM or parotid mass with it so no benefit to the patient. So, **ROLL OUT** them first!

- ❖ **Numbness:** Which nerve? Trigeminal nerve. What are the tumors can affect the 5th CN? Nasopharyngeal carcinoma. It can go up to the cavernous sinus > **Meckel's cave** "Is a dura mater pouch containing CSF" and then injure the trigeminal nerve.



- ❖ **Dysphagia or Odynophagia:** When you have to worry about dysphagia? 1) If it's progressive "First dysphagia to large bolus of food > small bolus > Fluids". 2) If it's associated with weight loss "If you have patient with dysphagia and gaining weight you can relax".
  - Other than this keep in mind 99% of people had dysphagia in their life.
  - **Odynophagia** "Painful swallowing" most of the time because of infections. Patients with base of the tongue, hypopharynx tumors they have the same pain as "لما تعض لسانك وأنت تاكل"!
- ❖ **Diplopia:** Always think of sinonasal tumors that invade the orbit. OR nasopharyngeal carcinoma invading the cavernous sinus and compressing the abducens nerve > Diplopia.
- ❖ **Pain with denture and poorly fitting denture:** If you have a patient coming with poorly fitting denture and painful, you have to examine that area very well!!! Make sure there's no mucosal ulceration no swelling that indicate submucosal tumor.
  - This is quite very common presentation in **elderly patients**.

### ❖ **Physical examination:**

- ➔ Complete head and neck exam (visualize & palpate).
- ➔ Emphasis on location, mobility and consistency.
- ➔ **It is important to examine 8 areas.** Because some patient may have synchronous tumors (thyroid cancer coexisted with parotid cancer in the same time).
  - **Neck:** midline of the neck and 5 levels of lymph nodes.
  - **Face:** included the parotid gland.

- **Oral cavity:** look and palpate all hidden areas (floor of tongue must be looked at to not miss base of tongue tumors especially in those who chew on tobacco). **Commonest area of cancer in patients taking “Shamma>Carcinogenic agents”** شي غريب يخلطونه ويعلقونه فجأة كانسر is oral cavity, and usually comes from south of KSA like Najran or Jazan.
  - **Nose** (with flexible scope).
  - **Nasopharynx** (with flexible scope): the commonest head and neck tumor after the thyroid, don't miss it they usually present with neck mass.
  - **Oropharynx** (with flexible scope).
  - **Hypopharynx** (with flexible scope).
  - **Larynx.**
    - Extra: Perform a full examination of the mass, including detailed characteristics: size, shape, surface, pulse number, skin attachment, skin changes, discharge, consistency ...etc. Perform an Indentation, transillumination, and fluctuation (Paget's sign) Tests. Check reducibility and compressibility ...etc.
1. **Survey:** Inspect the neck, noting its symmetry and any masses or scars. Look for enlargement of the parotid or submandibular glands, and note any visible lymph nodes.
  2. **Lymph nodes:** Palpate the lymph nodes:
    - Describe the location by levels( I, II , III , IV, V, VI) or by triangle.
    - Enlargement of a supraclavicular node, esp. on the left, suggests possible mets from a thoracic or an abdominal malignancy.
    - Tender nodes may (only may) suggest inflammation; hard or fixed nodes suggest malignancy. **Unless you suspect reactive cervical lymph nodes you should not give Antibiotics. So, What make you suspect that? 1- Age of the patient, 2- is it acute or chronic? e.g. cervical lymph node for the last 4 months what's the commonest infection cause it? TB!!**
    - **antibiotic is a treatment for specific diseases not masses! if they don't response in 2weeks don't give them another course! think about something else**
  3. **Trachea and thyroid gland:** Inspect the trachea for any deviation from its midline position, and then feel for deviation. Masses in the neck may push the trachea to one side. Inspect the neck for the thyroid gland, then palpate. Notes: size and shape of thyroid gland tells very little about thyroid function.
  4. **Full and details examination of the head and neck and the upper aerodigestive tract.**
    - Oral cavity and oropharynx:
      - Make note of any trismus.
      - Notice any ulcer, leukoplakia- white non removable discoloration.
      - Asymmetry of the tonsils.
      - Fallen or loose teeth.
      - Don't forget to examine the floor of mouth and the gingivobuccal sulcus.
      - Bimanual palpation is a must.
    - Nasal cavity:
      - Notice any bleeding, ulcers or masses.
      - Look for nasal blockage.
      - Any nasal deformity.
      - Don't forget the eye.

Case: a patient with a neck mass and decreased hearing in left ear, your next step? <sup>2</sup>

***Nasopharyngeal examination with fiberoptic scope (or biopsy).***

- ★ Do not give antibiotics immediately unless history pointing to infection and patient have fever.
- ★ Only infections that give long duration of fever are TB and EBV lymphadenitis, yet keep in mind that TB can present without fever with slowly growing neck mass.
- ★ Antibiotics course don't exceed 2 weeks.
- ★ Follow up after 2 weeks, delay treatment → change prognosis.

→ Ear:

- Look for any masses or lesions in the pinna or the canal
- Look for any middle ear effusion- may suggest nasopharyngeal cancer.

→ Scalp:

- Don't forget to examine the scalp for any lesions – look for BCC, or SCCA and chronic infection.

→ Cranial nerves:

- Look for any facial paraesthesia or numbness and any facial weakness.
- Look for all the other cranial nerves.

## Investigations:

1. Labs to be Considered as dictated by the DDX.
2. Radiographs:
3. You must have some kind of DxD before ordering any investigations.

### Fine Needle Biopsy:

- **Most important as the initial diagnostic procedure. Always Number 1!** What's the most important investigation you will do in patient with neck mass? FNA!!!
- This is the current standard of care for initial biopsy. Small gauge aspiration needle is used (25gauge) for multiple aspirations. "To reduces the bleeding, Seeding of tumor is not the concern when it comes to FNA"
- FNA biopsy is performed before surgical endoscopy but after a thorough head and neck exam and most of the time before any other studies done – **unless the mass is vascular.**
- **Single most important** study for diagnosing neck masses and thyroid cancer.
- Requires proper collection and minimum of 4 separate passes and a **skilled cytopathologist.**
- **Contraindicated** in vascular tumors (pulsatile mass) wait for radiological images. Like **hemangioma or aneurysm or Carotid body tumor (rare).** **it's a clinical diagnosis don't do FNA.**
- You have to have a good pathologist , and a good value for your investigation because having a result that you can't interpret is useless for example: If you have FNA done for thyroid and the pathologist said this is follicular lesion with atypia of undetermined significance class 3 what does that mean? it's very complicated to understand (at your level), -this lesion not benign or malignant and carry risk of 30-50% possibility of malignancy if you remove the thyroid-. The take home message from this: do not order a test that isn't significant for your dx and know how to interpret it and what to do about it. (الدكتور كل ما قلنا انفسيتيشن كان يقول ليش طلبتوه فلانم نعرف ليش طلبناه، هذا الكلام من ناحية المانجمنت مهم أو لا كمان كان يقول راندوم فايديتقز للتست و كان يقول وش يعني هذا الكلام من ناحية المانجمنت)

### Indications:

- **Any neck mass that is not an obvious abscess<sup>3</sup>.**
- **Persistence after 2 weeks course of antibiotics.**

<sup>2</sup> you must do nasopharyngoscope to pt with neck mass! it's the comments head & neck cancer in KSA.

<sup>3</sup> there is no clear indication , sometimes we use it to drain abscess.

### For thyroid:

- 5% false negative rate for FNA and thyroid nodules.
- Good for papillary, medullary and anaplastic thyroid carcinomas.
- But FNA cannot accurately distinguish b/t benign and malignant follicular thyroid tumors or Hürthle cell tumors.

### Special Considerations:

- FNA biopsy readily differentiates a cystic lesion from inflammatory lesion.
- FNA helpful in differentiating lymphoma from carcinoma. Helps avoid endoscopic exam, guided biopsies and general anesthesia for a diagnosis of lymphoma. Would just need to do a simple nodal excision under local for histologic confirmation of lymphoma (after the FNA).
- High risk pt with pos hx of chronic tobacco and/or ETOH who have a solid neck mass that is not obviously a mucosal tumor may have inconclusive or negative FNA. Endoscopy and open biopsy are still required in this group b/c you should have high index of suspicion.

### US:

- **Pulsatile neck masses require US prior to FNA.** It's the 2nd most important investigation for thyroid disease. So, if we talking about radiology it's US, if we talking about investigation say FNA. always complementable to each other's.
- **Less important now with FNAB.**
- Helps differentiate solid masses from cystic masses (especially useful for congenital and developmental cysts).
- Would help you distinguish a congenital branchial or thyroglossal cyst from solid lymph nodes, neurogenic tumors or ectopic thyroid tissue.
- U/S pretty accurate (90-95% differentiation success).
- Also helps assess size of a nodule and helps identify impalpable nodules.
- It is very helpful diagnostic tool in evaluating a thyroid and parathyroid tumors.
- Noninvasive in case of pregnancy and children.

### CT:

- **Single most informative radiologic test.** \*ex : pt present with neck mass scope : small bulge in the nasopharynx , CT scan : huge nasopharyngeal carcinoma extending laterally to retropharyngeal space Extremely helpful in this case.
- It is a diagnostic radiological image that tells you the **possibility of a diagnosis not a diagnosis.**
- Helps differentiate cysts from solid lesions, localizes masses inside or outside a gland or nodal chain and differentiates a vascular mass (with contrast). Recently we said avoid contract in thyroid masses, simply because if you give the patient a lot of iodine in the contrast you overload the thyroid with iodine in patient with borderline thyrotoxicosis may end up with thyroid storm. But now we give small dose so no risk.
- Cost limits its use.
- **Clinical judgment plus needle biopsy generally makes use of CT in diagnosing neck masses infrequent.**
- Consider for deep suspicious masses.
- Extension of lesion.
- Detection of unknown primary in case of metastatic masses.
- **Pathological nodes require further investigations:**

- 1.5 cm and more.
- Loss of shape, asymmetry.
- Necrosis and calcification
- Enhancement.

**NB: Avoid contrast in thyroid lesions, always start CT first except in pediatric and thyroid mass!**

**MRI:**

- Gives similar info as CT.
- Better for upper neck and skull base.
- Vascular delineation with infusion.
- Soft tissue details.

**Culture with Sensitivity Tests:** for inflammatory lesions after biopsy.

**Endoscopy and Guided Biopsy:** Helps identify primary tumor as source of a metastatic node.

**Panendoscopy:** it's examination under general anesthesia and doing multiple biopsies from pharynx, nasopharynx, tongue etc.

**Abx Trial:**

- If diagnosis after examination in younger pt remains uncertain but inflammatory adenopathy is suspected then give a trial of abx. therapy and observation for **2 weeks**.
- If mass still persists or has gotten larger, do a FNA biopsy with pathologic examination.
- (If doesn't improve>> do FNAB, never give another course of antibiotics) (IMP MCQ case).

**Open Excisional Biopsy:**

- It's not the 2nd or 3rd or not even the 10th choice! It's the choice when you have nothing left to do!
- Done after work-up is complete and if diagnosis is still not evident.
- Provide immediate specimen for histology frozen section.
- Simultaneous radical neck dissection may be necessary if diagnosis supports squamous cell carcinoma, melanoma, or adenocarcinoma (unless mass is supraclavicular).
- In lymphoma we do tissue diagnosis, you take all lymph nodes to be analysed. so, at that stage yes you can do open biopsy, we only do it if we suspect lymphoma or you can't reach any diagnosis. Why? because if the patient has malignancy by this you're reducing the survival by 20%! because in open biopsy we spread the cancer cells. It's a common malpractice. Do FNAB only. if you do FNAB and it was diagnostic (Only happens in 5% of patients), go for the open biopsy. if you open do frozen section, if inflammatory or adenocarcinoma or lymphoma there's nothing to do more, if SCC do a radical neck dissection. (Remove the SCM, jugular vein, lymphatics, accessory nerve)

**Radionucleotide scanning:**

- Salivary and thyroid masses.
- **Location:** glandular versus extra-glandular.
- Functional information. It's important after we diagnose the cancer and after surgery it's part of the radiation treatment for thyroid cancer and effective mostly in low risk and well circumscribed thyroid cancer like papillary.
- **FNAB now preferred for thyroid nodules:** Solitary nodules, Multinodular goiter with new increasing nodule and Hashimoto's with new nodule.
- **PET (photon emission tomography):** Detect the metabolic activity, pick up any tissue with increase metabolism → tumors and acute infections. (screening for metastasis not diagnostic).
- **PET scan:** only do it when you have diagnosis of cancer, not screening! and you want to stage it.

- it's helpful in locating the primary tumor and direct your biopsy here when we" have unknown primary tumor." entity.
- Doctor talked about radioactive iodine and being not significant nowadays for thyroid. only after surgery and after diagnosis of carcinoma. Very limited indication!
- Technetium scan only do it with warthin tumor of of parotid because the uptake there is quite intense.

**So what to do** when patient presents with a neck mass? There are many algorithms and what follows is very simplified!

1. **History.**
2. **Initial Physical Exam.**
3. Any Pertinent **Non-Invasive Lab and Radiographic Studies?** And how useful they are in getting me the diagnosis For example, CBC-P, TFT's, US, Thyroid Radionuclide Scan, Esophagrams, Abx Trial Therapy in younger patients, etc.
4. Update History and Repeat Physical Exam.
5. **More Invasive Tests as Warranted:** For example, FNA biopsy of cervical lymph node or mass then endoscopy (direct laryngoscopy, esophagogastroscopy or bronchoscopy) with guided biopsy if FNA reveals SCCa (to look for primary site).
6. **Consider CT** at this point if FNA biopsy is non confirmatory or for a suspicious lesion in a high-risk patient whose FNA is negative.
7. **Open Biopsy of Mass** if primary site still unknown. *Follow immediately with frozen section and removal of mass or radical neck dissection if the frozen show SCCA!*




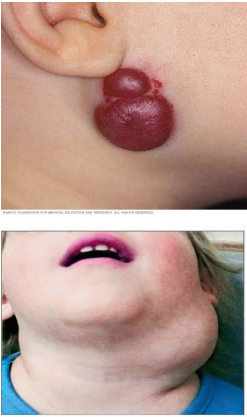
**Note: open biopsy is not the initial diagnostic test, if done for pt with SCCA the pt survival get compromise due to alteration of the lymphatic drainage.**

## Differential diagnosis of neck masses:

Neoplastic	Congenital/Developmental	Inflammatory
Metastatic Unknown primary epidermoid carcinoma	Sebaceous cysts	Lymphadenopathy
Primary head and neck epidermoid carcinoma or melanoma	Branchial cleft cysts	Bacterial
Adenocarcinoma	Thyroglossal duct cysts	Viral
Thyroid	Lymphangioma/hemangioma	Granulomatous
Lymphoma	Dermoid cysts	Tuberculous
Salivary	Ectopic thyroid tissue	Catcratch
Lipoma	Laryngocele	Sarcoidosis
Angioma	Pharyngeal diverticulum	Fungal
Carotid body tumor	Thymic cysts	Sialadenitis
Rhabdomyosarcoma		Parotid
		Submaxillary
		Congenital cysts
		Throtrast granulomas

- If you have a **clinical suspension** of an inflammatory cause (**redness, worm, tenderness, pus, tonsillitis, peritonsillar abscess**), start an **empirical trial of antibiotics for 2 weeks**.
- Follow the patient up and see if there is symptomatic relief and reduction of the swelling size by **at least 50%** then it is mostly inflammatory and is responding.
- If there is no response or partial response the condition requires further investigation.
- Remember that some tumors partially responds to Abs.

# Congenital and developmental masses:

<p><b>Epidermal &amp; sebaceous cyst</b></p>	<ul style="list-style-type: none"> <li>● The most common, older age group.</li> <li>● <b>Painless neck swelling.</b></li> <li>● Elevation and movement of overlying skin, Skin dimple.</li> <li>● CT followed by FNA. excisional biopsy confirms.</li> <li>● Tx: Excision.</li> <li>● <b>The most common congenital mass.</b></li> </ul>	
<p><b>Branchial cleft cyst</b></p>	<ul style="list-style-type: none"> <li>● Older children or young adult.</li> <li>● Lateral Neck swelling Following an URI. <b>always located at the mid 3rd of the neck covered by SCM.</b></li> <li>● Smooth, fluctuant mass underlying the SCM. Erythema may be present if infected.</li> <li>● Control the infection Surgical excision including tract.</li> <li>● 1st cleft may require a total parotidectomy.</li> <li>● <b>Types:</b> <ul style="list-style-type: none"> <li>○ <i>1st cleft:</i> less common close association with facial nerve.</li> <li>○ <i>2nd cleft:</i> commonest between external and internal carotid medial to CN VII.</li> </ul> </li> </ul>	
<p><b>Thyroglossal duct cyst</b></p>	<ul style="list-style-type: none"> <li>● 50% before 20.</li> <li>● Midline neck swelling.</li> <li>● Midline / near midline Just inferior to hyoid bone.</li> <li>● <b>Moves with swallowing and Tongue protrusion.</b></li> <li>● <b>Occurs when parts of the thyroglossal duct persist and form a cyst.</b></li> <li>● Surgical removal (sis trunk) after resolution of infection. <b>Sistrunk procedure – excision of the cyst with its tract and the body of the hyoid bone to prevent recurrence.</b></li> <li>● 75% midline 25%near midline. <b>always.</b></li> </ul>	
<p><b>Vascular tumors</b></p>	<ul style="list-style-type: none"> <li>● Usually within first year of life.</li> <li>● CT , MRI may be helpful.</li> <li>→ <b>Lymphangioma:</b> Surgical excision for easily accessible lesions affecting vital functions, high recurrence.</li> <li>→ <b>Hemangioma:</b> Surgical excision for those who have rapid growth affecting vital structures and/or associated with thrombocytopenia with failed medical therapy (<b>steroids, interferon</b>).</li> <li>● Hemangioma often resolves spontaneously while lymphangiomas remain unchanged.</li> <li>● Pics: Above (Hemangioma), Bellow Lymphangioma).</li> </ul>	

# Differential Diagnosis of Neck mass:

## ★ Inflammatory disorders: "Read it"

1-Lymphadenitis		2-Granulomatous lymphadenitis
<ul style="list-style-type: none"> <li>● Inflammation of a lymph node (nodes) due to a variety of infectious causes.</li> <li>● Deep neck infection.                             <ul style="list-style-type: none"> <li>● Very common, especially within 1st decade <b>first 10 years of life.</b></li> <li>● Tender node with signs of systemic infection.</li> <li>● Directed antibiotic therapy with follow-up.</li> </ul> </li> </ul> <p><b>FNAB indications (pediatric):</b></p> <ul style="list-style-type: none"> <li>○ Actively infectious condition with no response.</li> <li>○ Progressively enlarging.</li> <li>○ Solitary and asymmetric nodal mass.</li> <li>○ Supraclavicular mass (60% malignancy).</li> <li>○ Persistent nodal mass without active infection.</li> </ul> <p>→ Equivocal or suspicious FNAB in the pediatric nodal mass requires open excisional biopsy to rule out malignant or granulomatous diseases.</p> <p>→ Leukemia and lymphoma can present as acute infection.</p>		<ul style="list-style-type: none"> <li>● Infection develops over weeks to months</li> <li>● Minimal systemic complaints or findings</li> <li>● Common etiologies:                             <ul style="list-style-type: none"> <li>○ TB, atypical TB, cat-scratch fever, actinomycosis, sarcoidosis</li> </ul> </li> <li>● Firm, relatively fixed node with injection of skin.</li> <li>● <b>Typical <i>M. tuberculosis</i>:</b> <ul style="list-style-type: none"> <li>○ more common in adults.</li> <li>○ Posterior triangle nodes.</li> <li>○ Usually responds to anti-TB medications.</li> <li>○ May require excisional biopsy for further workup.</li> </ul> </li> <li>● <b>Atypical <i>M. tuberculosis</i>:</b> <ul style="list-style-type: none"> <li>○ Pediatric age groups.</li> <li>○ Anterior triangle nodes.</li> <li>○ Brawny skin, induration and pain.</li> <li>○ Usually responds to complete surgical excision or curettage.</li> </ul> </li> <li>● <b>Cat-scratch fever (<i>Bartonella</i>):</b> <ul style="list-style-type: none"> <li>○ Pediatric group.</li> <li>○ Preauricular and submandibular nodes.</li> <li>○ Spontaneous resolution with or without antibiotics.</li> </ul> </li> </ul>
3-Deep neck infection	4-Acute and subacute thyroiditis	5- Inflammation of a lymph node (nodes) due to a variety of infectious causes.



## ★ Thyroid Masses: Thyroid disease is so important.

➤ *Leading cause of anterior neck masses.*

### Children:

- Most common neoplastic condition.
- Male predominance.
- Higher incidence of malignancy.

### Adults:

- Female predominance.
- Mostly benign.

➤ **Lymph node metastasis:**

- Initial symptom in 15% of papillary carcinomas.
- 40% with malignant nodules.
- Histologically (microscopic) in >90%.

➤ **FNAB has replaced US and radionuclide scanning (Test of choice):**

- Decreases number of patients with surgery.
- Increased number of malignant tumors found at surgery.
- Doubled the number of cases followed up.
- Unsatisfactory aspirate → repeat in 1 month.

## ★ Diffuse Thyroid Enlargement:

### Definition of Goiter:

- A goiter is diffuse enlargement of the thyroid gland seen in Graves Disease, Plummer's Disease, Iodine Deficiency, Acute Thyroiditis, Subacute Thyroiditis, and Chronic Thyroiditis (Hashimoto's and Riedel's Diseases).
- Also, goiters are seen in Diffuse Multinodular Goiter. **So patient with a goiter can be clinically euthyroid, hyperthyroid or hypothyroid. (Most important test is TSH)**

### Grave's Disease

- Diffuse goiter with hyperthyroidism, exophthalmos, and pretibial myxedema.
- **Caused by** circulating antibodies that stimulate TSH receptors on follicular cells of the thyroid and cause deregulated production of thyroid hormones.
- **Diagnosed by** Increased T3 and T4 and very low TSH and global uptake of radioiodine.
- **Treated in 3 ways:** **medical blockade** (methimazole, PTU, propranolol, iodide), **radioiodine ablation**, **surgical resection.**

### Acute Thyroiditis

- Rare complication of septicemia. High fever, redness of overlying skin, tenderness.
- **Needle aspiration to identify organism.**
- Intensive Abx therapy.
- Occasionally, **incision and drainage.**

<p style="text-align: center;"><b><u>Subacute Thyroiditis</u></b></p> <ul style="list-style-type: none"> <li>● Secondary to <b>viral infection</b> and usually there is complete resolution within months.</li> <li>● Fever, goiter and anterior neck pain. Possible sx and signs of hyperthyroidism w exquisitely tender thyroid gland on palpation.</li> <li>● <b>"Cold" uptake</b> on scan distinguishes it from Graves b/c later in the course of the disease, pt becomes euthyroid and then hypothyroid.</li> <li>● <b>Treat with NSAIDS usually or prednisone if sx are bad.</b></li> </ul>	<p style="text-align: center;"><b><u>Chronic Thyroiditis</u></b></p> <ul style="list-style-type: none"> <li>● Hashimoto's Thyroiditis: lymphocytic infiltration and destruction of gland resulting in hypothyroidism and a diffuse goiter.</li> <li>● Hashimoto's common in women.</li> <li>● Most common cause of goiter and hypothyroidism in USA.</li> <li>● T3 and T4 either normal or low. TSH is elevated.</li> <li>● Tx: <b>thyroxine but then surgery if dominant mass is not suppressed by this therapy.</b></li> </ul>
<p style="text-align: center;"><b><u>Diffuse Multinodular Goiter</u></b></p> <ul style="list-style-type: none"> <li>● This is adenomatous hyperplasia of the thyroid gland that is asymptomatic (non-toxic/euthyroid).. R/O malignancy w FNA.</li> <li>● Multiple nodules suggest a metabolic rather than a neoplastic process, but irradiation during childhood, a positive family history, enlarged cervical nodes, or continuing <b>enlargement of one of the nodules raises the suspicion of malignancy.</b></li> </ul>	<p style="text-align: center;"><b><u>Iodine Deficiency:</u></b></p> <ul style="list-style-type: none"> <li>● Rarely a cause of goiter in the USA.</li> <li>● If seen, it is usually treated medically and only rarely surgically for compressive symptoms.</li> </ul>

## ★ Thyroid Neoplasms:

### **General Info about Thyroid Cancers:**

- **Risk Factors suggesting Carcinoma:** Hx of radiation therapy to neck, History of rapid development of nodule, vocal cord paralysis, and cervical adenopathy, hard fixed mass, elevated serum calcitonin.
- **Risk Factors suggesting Malignancy:** Hx of neck irradiation, young>old, cold nodule, solitary>multiple nodules.
- **Signs and Sx:** Mass/nodule, lymphadenopathy, most are euthyroid and usually asymptomatic masses in low midline ant. Neck.
- **Workup:** FNA and U/S, thyroid function test if there are symptoms or signs of hypo-or-hyperthyroidism.
- **After thyroidectomy,** you **MUST** follow Ca levels post-op (even give them supplemental Ca for a while to be on safe side): can be decreased 2ndary to parathyroid damage.

## Complications of thyroidectomy:

- **Recurrent laryngeal nerve injury:**
  - Unilateral: hoarseness.
  - Bilateral: airway obstruction (stridor).
- **Hematoma:** it may cause airway obstruction.
- **Hypothyroidism or/and hypoparathyroidism.**

### Benign Thyroid Nodule:

- Palpable nodules of thyroid occur in 5% of population. **15-30% of these prove to be malignant.**
- Usually benign nodules are solitary follicular adenomas, colloid nodules, benign cysts, or uni-nodular thyroiditis.
- Solitary toxic adenomas occur in older patients and are usually benign.
- These toxic adenomas reveal decreased TSH w increased T3 and T4.
- Thyroid scan show "**hot nodule**" and complete suppression of unaffected lobe.
- Usually managed with **radioactive iodine** or a **unilateral lobectomy** if the nodule is large.

### Malignant Thyroid Nodule:

#### Papillary carcinoma:

- Constitutes 80% of thyroid carcinomas.
- Spreads lymphatically and slowly.
- 10 yr. survival rate is 95%. Good 131 I uptake.

Treatment:

- ➔ Hemithyroidectomy (usually not enough).
- ➔ Or **Total Thyroidectomy most appropriate.**
- Post-Op need to give thyroid hormone replacement.
- Post-Op 131 I scan can diagnose and treat!
- **Can be metastasized.**

#### Follicular Adenocarcinoma:

- 10% of thyroid cancers. .
- Hematogenous spread (commonly to bone).
- More aggressive.
- Good 131 I uptake.
- 10 yr. survival is 90%.
- ***Dx cannot be made with FNA!!!***
- Tissue structure (capsule) needed for diagnosis.
- Malignancy if there is capsular or blood vessel invasion.
- Tx same as in papillary cancer.

#### Medullary Carcinoma:

- 5% of thyroid cancers.
- Associated with MEN type II.
- **Secretes calcitonin.**
- Diagnosis made w FNA.
- Poor 131 I uptake.
- **Lymph and hematogenous spread.**
- 10 yr. survival is 50%.

#### Anaplastic Carcinoma

- Undifferentiated carcinoma arising in 75% of previously differentiated thyroid cancers.
- 1-2% of all thyroid cancers.
- FNA helps diagnose.
- Major DDx includes lymphoma (much better prognosis).
- Treat small tumors: Total Thyroidectomy (possibly w external beam radiation).

<ul style="list-style-type: none"> <li>• Treat w total thyroidectomy and lymph node dissection.</li> <li>• <b>Hürthle Cell Thyroid Cancer</b> sub type of follicular cancer.</li> </ul>	<ul style="list-style-type: none"> <li>• If there is airway obstruction then do a <b>debulking surgery and tracheostomy.</b></li> <li>• <b>Dismal prognosis.</b> Most pt have stage IV (distant mets) at presentation.</li> </ul>
---	---

Malignant of thyroid cancer		
Type		Management
Well-differentiated	Papillary carcinoma	Total thyroidectomy + post-op Radioactive Iodine (I-131)
	Follicular carcinoma	
	Hurthle cell carcinoma (sub-type of follicular)	
Poorly-differentiated	Medullary carcinoma	Total thyroidectomy + Neck dissection “removal of level 2,3 & 4 lymph nodes”
	Anaplastic carcinoma	Surgery, Adjuvant radiation & Chemotherapy.

### ★ Non-Thyroid Neoplasms:

- Primary cervical neoplasms are rare!! Metastatic lesions represent up to 80% of all non-thyroid neoplastic neck masses.
- The initial management objective in these cases is always disclosure of site of origin of primary tumor (**aerodigestive endoscopy!!**).
- The other 20% represent **lymphomas or salivary gland tumors.**
- Of the metastatic lesions, up to 90% arise from clinically obvious primary neoplasms located **above the clavicle.**

### Metastatic Lesions:

- Be aware that the immediate removal of enlarged lymph node for diagnostic purposes is **NOT GOOD** for pt w metastatic cervical carcinoma. *Disruption of lymphatic drainage and manipulation of the mets decrease chance for clean excision and cure.*
- **Enlarged nodes high in neck or in posterior triangle suggest nasopharyngeal lesion.**
- Enlarged jugulodigastric nodes suggest tonsils, base of tongue or supraglottic larynx.
- If nodes are in supraclavicular area or lower 1/3 or neck then consider the whole digestive tract, lungs, breast, GU tract, and thyroid gland.
- Mets spread from chest or abdomen via **thoracic duct (left side mets more common than right).**

### Epidermoid (Squamous Cell) Carcinoma:

- Is a tumor of middle and late adulthood.
- Associated with smokers and ETOH.
- Primary tumor usually on a mucosal surface of upper aerodigestive tract.
- Neck mass represents mets.
- You must find primary site to treat successfully.
- Neck mass(es) can be unilateral, bilateral or multiple in number.
- HARD to palpation and may be fixed due to invasion of adjoining structures.
- **Treatment:** may include radical neck dissection Also, treat the primary site as warranted.
- Radiotherapy may be used.

### Malignant Lesions of Larynx:

- More common in men. Most common site is **glottis**.
- Risk factors: tobacco and alcohol. 90% are Squamous Cell Carcinoma.
- Sx: hoarseness, throat pain, dysphagia, odynophagia, neck mass, referred ear pain.
- **Treatment:** Total or supraglottic laryngectomy with neck dissection if there is nodal involvement. Radiation therapy or surgery for early lesions. Combination therapy for advanced disease.

### **Nasopharyngeal carcinoma “From 433”: IMPORTANT!**

- The incidence of nasopharyngeal carcinoma is two- to threefold higher in males compared with females.
- **The incidence peaks around 50 to 59 years of age and declines thereafter.**

**Risk factors: 1)Epstein-Barr virus. 2)Smoking**

#### **Histology & Staging:**

- Nasopharyngeal carcinoma arises from **the epithelial lining of the nasopharynx**.
- The current TNM staging system classifies nodal stage of nasopharyngeal carcinoma according to laterality, size and location of lymph node, and whether unilateral (N1), bilateral (N2), >6 cm (N3a), or extend to the supraclavicular fossa (N3b).

#### **Diagnostic Evaluation:**

- **A definitive diagnosis is made by endoscope-guided.**
- Biopsy of the primary tumor. (Incisional neck biopsy or nodal dissection should be avoided as this procedure will negatively impact subsequent treatment).
- Routine evaluation should include history and physical examination, including the cranial nerves, complete blood counts, and serum biochemistry, including liver function tests and alkaline phosphatase.
- Other studies should include chest radiograph, nasopharyngoscopy, and computed tomography (CT) or magnetic resonance imaging (MRI) of the nasopharynx, skull base, and neck.

### **Management:**

- Nasopharyngeal cancer has a propensity for early, bilateral spread to regional lymph nodes in the neck. Thus, all patients, including those with a clinically negative neck, are treated with bilateral neck irradiation.
- For patients without lymph node involvement (N0), it may be safe to omit RT to the lower neck.
- For patients with lymph node involvement, RT should encompass the whole neck.

### **Prognosis:**

- The five-year overall survival for nasopharyngeal carcinoma according to disease stage in a contemporary case series was 90, 84, 75, and 58 percent for stage I through IV, respectively.

### **Lymphomas:**

- Commonest in early and middle adulthood.
- Up to 80% of children with Hodgkin's have a neck mass.
- Masses are usually multiple but can be bilateral and/or unilateral.
- Range in size from one to ten centimeters.
- **SOFT and MOBILE.**
- Can be in anterior or posterior neck.
- Patient may be **asymptomatic** or possibly has low-grade fever, malaise, weight loss, night sweats. **Sx:** Lateral neck mass only (discrete, rubbery, non-tender), **Hepatosplenomegaly**, Diffuse adenopathy.
- Diagnosis is made via FNAB – first line diagnostic test. If suggestive of lymphoma do cervical node open excisional biopsy and histopath exam.
- **Reed-Sternberg cells are associated with Hodgkin's.**
- **Treatment for lymphoma is medical!**
- Full workup – CT scans of chest, abdomen, head and neck; bone marrow biopsy.

### **Salivary Glands Tumors:**

- **Most common is carcinoma!**
- **Benign** tumors are a mobile and non-tender and **Asymptomatic** except for the mass. While **malignant** tumors are Rapid growth, skin fixation, cranial nerve palsies, **painful and fixed.**
- **Benign salivary gland management is surgery and post op radiotherapy. Why? because there is 9-10% probability of becoming malignant.**
- Malignant tumors may involve lymph nodes (evidence of local metastasis) and/or facial paresis/paralysis. **(fast growing tumor and pressure symptoms depends on the site).**

### **Diagnostic tests:**

- ➔ Open excisional biopsy (submandibulectomy or parotidectomy) preferred.
- ➔ CT/MRI – deep lobe tumors, intra vs. extra-parotid.

#### **➔ FNAB:**

- ❑ Shown to reduce surgery by 1/3 in some studies.

- ❑ Delineates intraglandular lymph node, localized sialadenitis or benign lymphoepithelial cysts.
  - ❑ May facilitate surgical planning and patient counseling.
  - ❑ Accuracy >90% (sensitivity: ~90%; specificity: ~80%).
- Treatment is generally via adequate **surgical resection with neck dissection** for node-positive necks and radiation. **Be prepared for total parotidectomy with possible facial nerve sacrifice.**

### Parotid:

#### Role of 90%:

- 90% of all salivary glands tumors.
- 90% is benign.
- 90% is pleomorphic adenoma (mixed tumor).

**Role of the size:** When the size of the tumor is big the probability of it being benign increase.

- ➔ **Most common malignant tumor is mucoepidermoid carcinoma.**
- ❖ **Characteristic of pleomorphic:** High rate of malignant changes that why it is advisable to do the surgical resection quickly. Grow larger than **warthin's tumor** **“this tumor is imp and it's the most common benign tumor”**. Higher rate of recurrence because microscopically it has pseudopodia which penetrate the capsule leading to the recurrence.
- Parotid glands located at periocular and the facial nerve cuts between its superficial lobe and deep lobe.
- **Stinson duct (Parotid duct)** it emerges from the gland and runs forward along the side of the masseter muscles.
- Saliva of parotid is serous (its bacteriostatic factors is weak).
- **Complication of parotid : 1)Facial nerve injury. 2)Frey syndrome<sup>4</sup>.**
- Cystic bilateral parotid mass you have to roll out HIV!
- Surgical parotitis usually come with old, dehydrated and post op patient present parotid mass with tenderness.

### Submandibular glands:

- ➔ Involved in 10% of salivary gland tumors.
- ➔ 60% are benign, 40% are malignant.
- ➔ **Most common benign is pleomorphic adenoma.**

Most common malignancy in submandibular, sublingual and minor salivary glands is the **Adenoid Cystic Carcinoma** (Mucoepidermoid Carcinoma is 2nd).

- Submandibular gland related nerves: **Hypoglossal nerve, Mandibular nerve and Lingual nerve.**
- The most important muscle related to submandibular gland is **mylohyoid muscle.**
- It's the most gland prone to **stones** because of the anatomy, antigravity, its secretion is thick and has a lot of **fosforcalcium**.

### Sublingual gland:

- ➔ Rarely involved.
- ➔ 60-70 % is malignant.
- ➔ **Most common benign is pleomorphic adenoma.**

### Minor salivary glands:

- ➔ **90% is malignant.**
- ➔ Commonly involve the palatal region.

<sup>4</sup> Is a rare neurological disorder resulting from damage to or near the parotid glands. Sx:Redness and sweating on the cheek area adjacent to the ear.

## ★ Parathyroid Masses:

### General Points about Parathyroid Glands:

- After parathyroidectomy, watch out for recurrent nerve injury, neck hematoma and hypocalcemia.
- "Hungry Bone Syndrome" is severe hypocalcemia after surgery correction of hyperparathyroidism as bone aggressively absorbs Ca.
- Sx of this syndrome: perioral tingling, paresthesias, positive Chvostek's sign, carpal pedal syndrome.

<p><b><u>Primary Hyperparathyroidism: Adenoma</u></b></p> <p>Primary hyperparathyroidism is usually due to an adenoma (85%) which is <b><u>NOT usually palpable</u></b>.</p> <ul style="list-style-type: none"> <li>➤ Labs show elevated PTH and hypercalcemia. Check urine to R/O Familial Hypocalciuric Hypercalcemia.</li> </ul>	<p><b><u>Primary Hyperparathyroidism: Hyperplasia</u></b></p> <ul style="list-style-type: none"> <li>➤ All 4 glands affected. Seen in MEN type I and IIa (must R/O MEN if pt has hyperplasia).</li> <li>➤ Do a neck exploration and remove all of the parathyroid glands (leave 30 mg of parathyroid tissue behind placed in non dominant forearm).</li> </ul>
---	--

### ❖ Mucosal Tumors "Boys' Notes":

The table above + these 3 cases are basically what prof. Khalid Al Qahtani mentioned in the 3rd lecture.

	DDx	Risk factors	Presentation	Treatment
<b>Sinonasal</b>	★ SCC	Dust exposure (occupation)	★ Unilateral nasal symptom (maybe ocular or oral pain)	★ Early: Surgery Late: Surgery and radiation
<b>Oral</b>	SCC salivary minor glands.	Smoking, alcohol, multiple trauma, oral hygiene & HPV	Unilateral oral lesion	
<b>Pharynx</b>	SCC	★ Smoking, alcohol, HPV & GERD.	Unilateral neck mass (slowly growing).	Early: Surgery or radiation. Late: Surgery & Radiation
<b>Larynx</b>	SCC	Smoking, HPV & Laryngopharyngeal Reflux (LPR)	Unilateral neck mass (slowly growing).	Radiation & Chemotherapy.

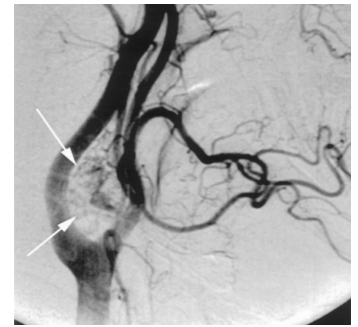
- ★ SCC = squamous cell carcinoma (is the most common mucosal tumor).
- ★ Including nasal obstruction, rhinorrhea, epistaxis, loss of smell etc.
- ★ GERD is not RF for nasopharynx tumors. GENETIC AND EBV play an important role in nasopharynx.
- ★ Early and late depending on TNM system. If the N is 1 or more > late e.i. if there is a lymph node involvement = late.
- Investigations for mucosal carcinoma: CT scan (staging) then biopsy.
- Surgical VS Non-surgical :
  - For oral & sinonasal: Surgical approach is better.
  - For pharynx & larynx: non-surgical is better.
- Stage (TNM) 1&2 are early, while 3&4 are late.



## Extra informations from Boy's slides "Just read them":

### ❖ Carotid body tumor:

- Rare in children.
- Pulsatile, compressible mass.
- Mobile medial lateral not superior inferior.
- Clinical diagnosis confirmed by angiogram or CT.
- **Treatment:**
  - ◆ Irradiation or close observation in the elderly.
  - ◆ Surgical resection for small tumors in young patients:



- Hypotensive anesthesia (a type of anesthesia that reduces the mean arterial pressure (MAP) to 50 mmHg and thus reduces blood loss during the surgery).
- Preoperative measurement of catecholamines.

### ❖ Lipoma:

- Soft, ill-defined mass, Usually >35 years of age.
- Asymptomatic.
- Clinical diagnosis
- Confirmed by excision.

### ❖ Neurogenic tumor:

- Arise from neural crest derivatives.
- Include schwannoma, neurofibroma, and malignant peripheral nerve sheath tumor.
- Increased incidence in NF syndromes.
- Schwannoma most common in head & neck.

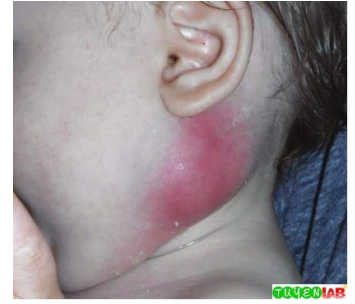### ❖ Schwannoma:

- Sporadic cases mostly.
- 25 to 45% in neck when extracranial.
- Most commonly between 20 and 50 years.
- Usually mid-neck in poststyloid compartment.
- Signs and symptoms (Depend on the site):
  - Medial tonsillar displacement.
  - Hoarseness (vagus nerve).
  - Horner's syndrome (sympathetic chain).

## Clinical Cases

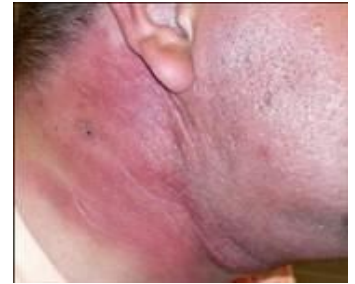**Case 1:** Young kid presented to you by his mum and he was well 4 days ago, and then developed high grade fever, chills, poor oral intake. Or Child presented with rapid growing neck mass, low oral intake, irritability, fever, and history of sore throat 5 days ago.

- **Dx:** Most likely **lymphadenitis** either abscess formation or just simple adenitis.
- **What's the management?** Do US first to see if it's abscess or not. OR CT which is better. **Tx:** Incision and drainage with antibiotics.



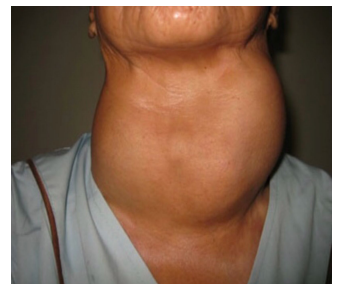
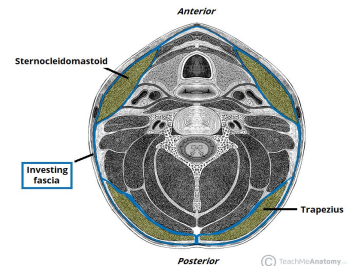
**Case 2:** A 65y/o Diabetic patient was well 5 days ago, then complained of something in his chin, redness, very hard mass in his lesion. Swelling in the submandibular area for 5 days, low grade fever, pain and he never had like this swelling before.

- **Dx: Cellulitis.** What're the signs of it? Diffuse over the skin, hard looks like tumor, painful, redness, Most of the time no fever.
- **What's the most important thing you have to examine in this patient?** Oral cavity. You have to make sure there is no floor of mouth infection, it's a life threatening infection. **Tx:** Antibiotics.



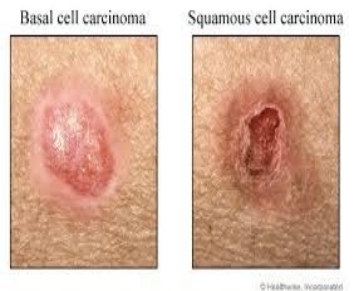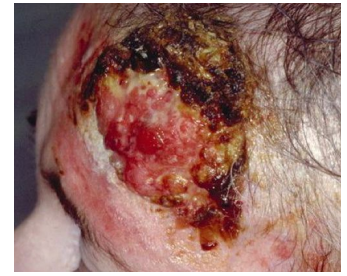**Case 3:** A 20+y/o presented with few months history of neck mass, completely asymptomatic, but he has this mass in his neck.

- **What you will do clinically for this patient?** Complete mass Examination. **By inspection?** Ask the patient to swallow and it's moving. **Why if it's moving with swallowing we think it's thyroid?** Because it's attaching the deep investing fascia.
- **What're the important points in history?** 1st degree Family thyroid history. Ask about thyroid surgery in the family and to know if it's benign or malignant "اسألهم بعد العملية هل رجعه المستشفى وعزلوه" If yes it means it's malignant and they took iodine radiation.
- **What's your next step? US. Next? TSH test"Is the most accurate evaluation of thyroid functions".** Shows multiple large nodules about 7 cm each side.
- **Next? FNA.** And came back as benign nodules. **Why we do FNA?** to help the physician and how to assess the patient intraoperatively. So, he knows how much should remove from the lesion. if it's malignant you have to remove every single piece, it's benign it's okay if you leave some. **What will be your management?** Surgery because the mass is big (>6 cm) although it is benign.



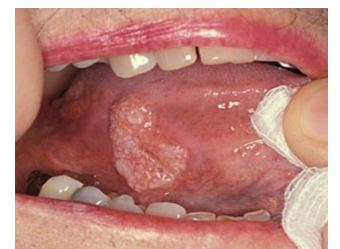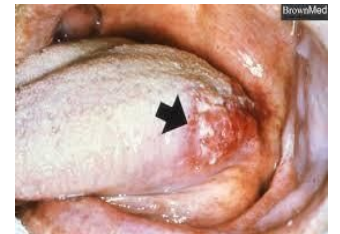**Case 4:** 80 years old Elderly lady has this lesion was a small dumpling in her left side on the temporal bone for the last six years slowly growing.

- **What's the most likely diagnosis?** Basal cell carcinoma.
- **Why BCC?** 1)Slowly growing. 2)Her age. 3)Skin lesion with long History.
- **If I tell you for the last 6 months, What's the Dx?** SCC.
- **If I tell you for 10 years as brown mall and over the last 6 months start to be ulcerated?** Melanoma.
- **If I tell you that this patient has large parotid carcinoma and now she's presented after treatment with temporal bone lesion?** Metastasis.
- **If I tell you this patient presents with 2 years History with same lesion, and for 2 months hx of parotid lesion at the same time. What?** Mets from SCC.
- Keep in mind BCC DOES NOT METASTASIS!!
- **What's the area you must examine in this patient?** Lymph nodes, eyes "Bc SCC & BCC locally invasive", Facial nerve.



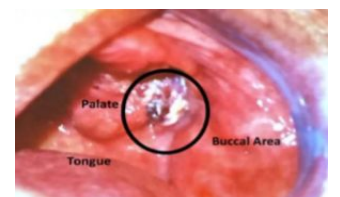**Case 5:** Heavy Smoker and drinker male presented with odynophagia and pain in the mouth for almost 6 months. Started as a small ulcer at the lower part of his tongue then slowly growing in size.

- **What you see?** Fungating well demarcated mass at the ventral portion of the tongue extending to the floor.
- **What's the most likely tumor in oral cavity?** SCC. "Keep in mind any mucosal lesion in the head and neck it's SCC until proven otherwise"
- **Investigation?** Biopsy. "Say FNA only for areas completely cover by tissue and skin" Also do, CT & MRI.
- **In general any mass in head and neck and tongue, what other areas I have to examine?** Lymph nodes. For staging TNM and mets.
- **Treatment?** Surgical hemiglossectomy "½ of tongue" and completely remove the floor of the mouth and post op radiation. "Not imp"
- Basal cell carcinoma is local and slowly growing tumor. With parotid or lymph node involvement, SCC (shorter duration compared with basal). If the patient present with lesion for 2 months, think melanoma or subcutaneous lymphoma.



**Case 6:** Elderly diabetic hypertensive lady has no teeth complaining of poorly fitting denture (تركيبية الأسنان) pain in putting it!

- **On exam:** Huge fungating mass in the side of the gum.
- **Dx:** Squamous cell carcinoma of the upper alveolar invading the maxillary sinus!

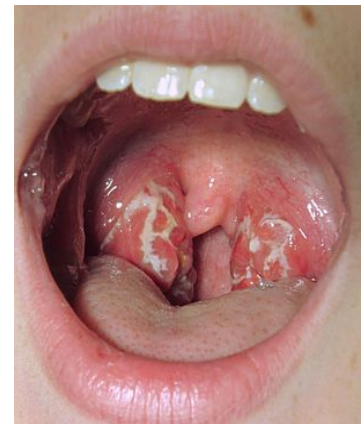
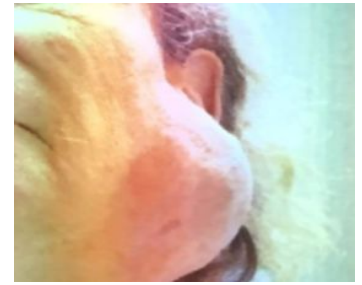
**Case 7:** 20+ Young lady not smoker, presented complaining of severe sore throat for almost 6-7 months, treated several times with antibiotics with no improvement. And now asking for tonsillectomy!

- **History?** low grade fever, dysphagia, odynophagia, ear pain, weight loss almost 15 Kg over 6 months period.
- **DDx?** Young with low grade fever immediately you should think of Lymphoma, if we change the scenario to 60 y/o with no fever you can say SCC.
- **Examination?** Lymph nodes, Spleen and Liver “**Hepatosplenomegaly**” this will confirm the dx even with no biopsy!
- Either you do LN biopsy or tonsillectomy and send the whole LN it to pathology.
- **If this is Carcinoma not lymphoma, What is Tx?** Chemo-radiation.

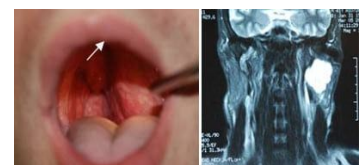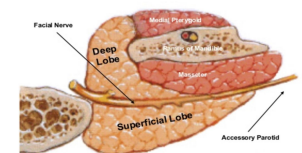
**Different scenarios:**

- ★ IF I give you the same history and tell you that the pt has 2 days history of sore throat and dysphagia and right ear otalgia and high grade fever. **Dx: Tonsillitis.**
- ★ Smoker patient otherwise healthy, he started having painful swallowing and pain in his ear for 2 months. NO FEVER (the tumor located on the tonsils) multiple lymph nodes in the neck on examination! **Dx: unilateral tumor of tonsils Tonsillar Carcinoma.** Investigation: Biopsy.
- ★ Lady with rapidly growing mass on her neck, tiredness, weakness, fever, weight loss over 4-5 months, pale, WBC 150, platelets 15-16. Hb 6-7. **Dx: Leukemia.**



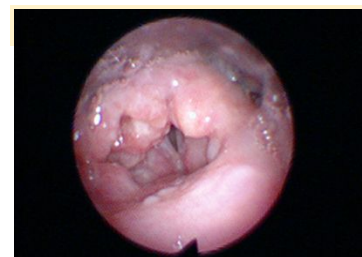**Case 8:** Patient went to dentist and he found a white patches in her mouth, on the hard palate specifically, mass from the tonsils itself. the uvula is pushed away not central.

- **Dx?** Deep lobe parotid tumor. Usually Completely asymptomatic.
- **Tx?** Parotidectomy, in parapharyngeal space.

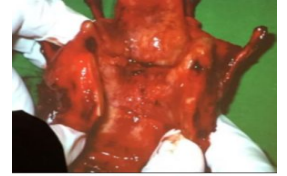

**Case 9:** 65 y/o heavy smoker man complain of hoarseness for 10 months. Upon examination: mild biphasic stridor, neck mass 5x4 cm.

- **How can you assess for the history the urgency of this patient?** Can't Breathing.
- **How u assess the severity of breathing?** This patient can't lye down, dysphasia and lost weight, can't walk.
- **Management?** Tracheostomy under local anesthesia.



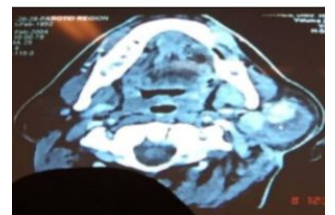
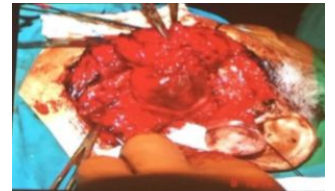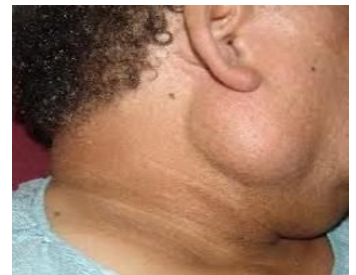- **Dx?** Advanced stage of Laryngeal carcinoma "SCC". No vocal cords completely replaced by the tumor.
- **Tx?** Surgery and radiotherapy.



Stage 4: The Tumor destroying all the larynx. No vocal cords with deep ulcers every where

**Case 10:** Lady with 10 years hx of left parotid mass slowly growing, no ear problems.

- **What's the most important structure to examine?** Facial nerve and lymph nodes.
- **Imp in History?** The duration, rapidly growing is very bad, Painful parotid mass are bad most of the time is malignancy, positive LM, facial nerve paralysis and attachment to other structures.
- **Most common tumor of parotid glands? 80% Pleomorphic adenoma.** 2nd most common is Warthin tumor "Both are Benign"
- **What's the difference between them clinically?** The natural hx, Warthin has no risk of malignancy while in pleomorphic adenoma has.
- In pleomorphic adenoma no matter what's the size you have to take it out.
- Warthin tumor associated with smoking while pleomorphic not.
- Warthin more common in men and 10% bilateral. While pleomorphic equally in both men and women and usually unilateral.



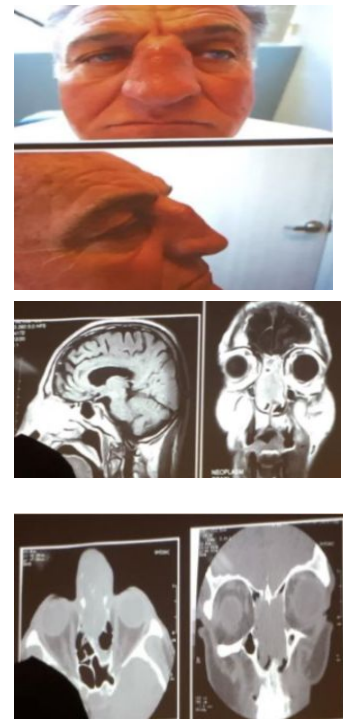
Warthin's tumor on Ct scan and grossly. Coming from and within the deep lobe of parotid gland

**Different scenario:** 6 months hx of rapidly growing left mass, painful and facial nerve paralysis.

- **Dx?** Most common malignant in parotid is **Mucoepidermoid** Because 90% of malignant salivary gland tumors occur in parotid > 2nd is Adenoid Cystic carcinoma, But in other salivary glands it is opposite!
- Submandibular: 60% benign 40% malignant.
- Sublingual: 40% benign 60% malignant.
- Minor salivary: 20% Benign 80% malignant.
- **"The larger the glands the more benign tumors, The smaller the glands the more malignant"**
- The primary treatment for minor salivary glands is surgery, they don't respond to radiation or chemo.
- **Rx:** Surgical excision.

**Case 11:** Carpenter man presented with very weird symptoms, he just presented because of his nose start getting bigger and can't see probably in mid gaze. The only symptoms he has that he started having difficulty looking at the sides.

- On exam the nasal hump was huge so you suspect something pushing the nasal ridge laterally and up.
- **CT** shows very aggressive lesion involving all nasal bones reaching the skull base (the bone which should appear white on CT is absent) No orbital invasion!
- **But on MRI:** clearly invading the skin ( fat which should appear black is gone!) and it is already going inside the dura.
- **Dx?** Sinonasal tumor secondary to wood dust exposure.
- **Tx?** Aggressive surgery "Total Rhinectomy". Complete resection of nasal cavity and skull base. With prosthetic nose placement.

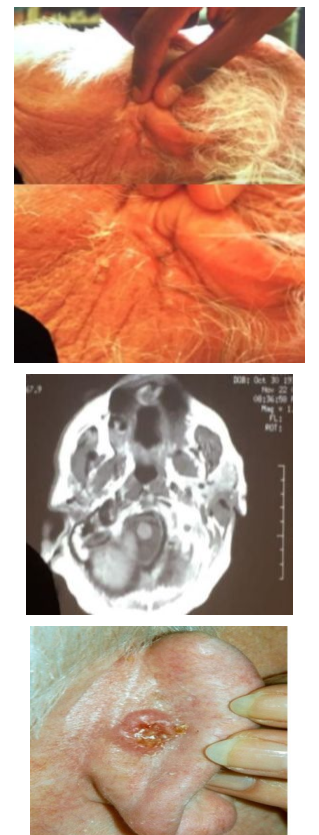


**Case 12:** Elderly patient, Post kidney & liver transplant complaining of post auricular draining sinus behind the ear for almost 3 weeks causing him a lot of pain! On exam the ear was completely normal!

- **Should we worry about it?** Yes, because he is immunocompromised!
- On MRI there was a mass with sinus through it and invading the parotid anteriorly!
- **Dx?** squamous cell carcinoma of the skin deeply invading to the parotid.
- **Rx:** underwent auricectomy with temporal bone resection + hearing Aid!

**Different scenario:** Post liver and kidney transplant patient, presenting with post auricular discharge for the last 6 months. Ear examination is normal, however you find a small ulceration in the skin.

- When you have auricular squamous cell carcinoma, you must resect the auricle. In this patient, the parotid, facial nerve, and mastoid process were also resected due to involvement.

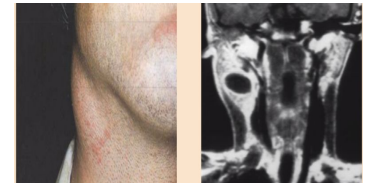
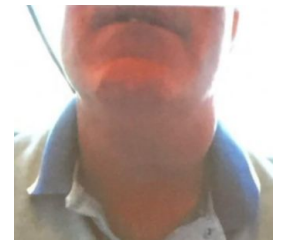


**Case 13:** 68 years Patient with mid third neck mass, mobile for 12 years, completely asymptomatic.

- **Dx: Branchial cleft cyst** in atypical age 68. Neck mass in the mid third of the sternocleidomastoid muscle, deep to it not invading any structures or causes any changes around with no lymphadenopathy!
- **Rx:** Surgical excision with following the tracts which extends to the tonsils, it usually has some tracts going deep. If you don't have the tracts completely out you make a chance for recurrent sinus prone to infections! we did biopsy for this patient because of his age to roll out malignancy.

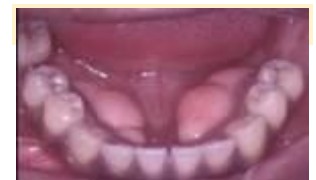**Another scenario:** A 24-year-old patient presents with level-2-neck mass. He had a history of tonsillitis. On examination: it looks red and tender. Face examination has shown changed in the appearance of the face (VII palsy).

- **What will you do next in this patient?** Examination and history are suggestive of inflammatory condition. So, empirical treatment.



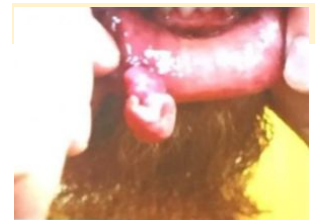**Case 14:** Patient asymptomatic presented with this benign disease "Pic".

- **Dx?** Torus mandibularis. "is a bony growth that develops on the lower jaw, beneath and on the side of the tongue"
- **Tx?** Recurrence.



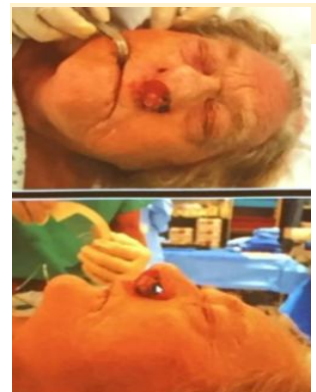**Case 15:** Young patient healthy, presented with this lesion for almost 6 months, pedunculated mass from the lip.

- **Dx?** Pyogenic granuloma. Traumatic lesion, He was biting the area and injured it which lead to overgrowth.
- **Tx?** Just cut it! simple excision with local anesthesia.



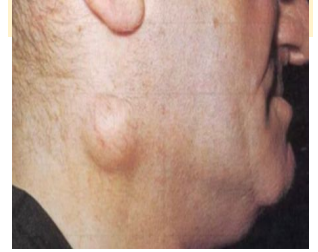**Case 16:** This is a rare case of an Lady came with fungating mass in her nose, invading the surrounding structures.

- **Investigations & Dx?** Biopsy reveals **sinonasal melanoma** it was invading the skin and the septum.
- Melanoma doesn't always happen in the skin, mucosal membranes can give rise to melanomas as well.
- **Tx?** There is no treatment for melanoma except for surgical resection. Skin melanoma has a bad prognosis. Mucosal melanoma has an even worse prognosis!



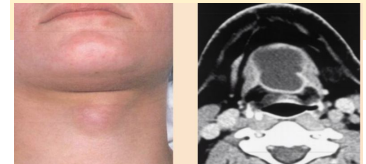
**Case 17:** A 70-year-old, he is healthy and not smoker. He has this neck mass (picture) in the level 2. It has been there for 10 years. He has no complaint. He just visited his son in Riyadh and his son brought him to you.

- **What is level 2 in the neck?** From skull base to the hyoid bone.
- **What will you do next in this patient?** Examination of the 8 areas to exclude other masses.
- **Everything was normal in the examination, what is the next step?** CT scan followed by FNA. FNA showed epidermoid cyst.



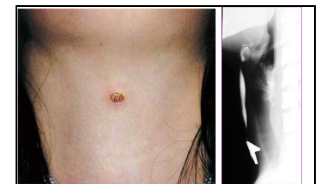
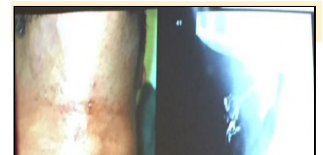
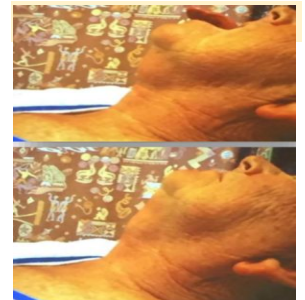**Case 18:** A 13-year-old patient presents with midline-neck mass. On examination it moves with swallowing.

- **What is the most likely diagnosis?** Thyroglossal Duct Cyst.
- **Mention other DDx seen in midneck?** Bulging granula (children). | Teratoma (children).



**Another scenario:** Old lady present with a mass in the midline of neck moves with tongue protruding!

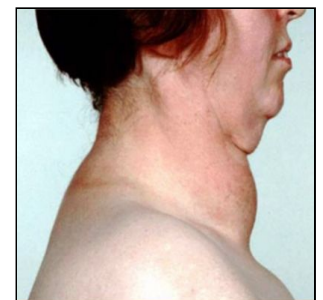
- **Dx:** Thyroglossal Cyst.
- **Rx:** Surgical excision (cyst Trunk procedure) remove the cyst along with the hyoid bone along with tract beyond the hyoid bone to prevent recurrent sinuses or Fistulas!
- Remnant of the tracts making a pus draining sinus from the base of the tongue.
- **CT:** Thyroglossal fistulography Methylene blue darning!



Case 18: Thyroglossal fistulography which shows extension of track to base of tongue.

**Case 19:** A female presented neck mass shown in the pic.

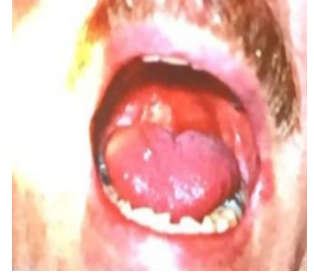- **Describe the image?** Diffuse neck swelling more prominent in the lower midline.
- **What further investigation you would order?** CT scan, We used CT in first place because we didn't know it was thyroid.
- **CT reported thyroid mass. What is the next step?** Ultrasound and Fine-needle aspiration.
- **Histopathologic report revealed benign tumor. What the management?** Surgery because the mass is big (>6 cm) although it is benign.





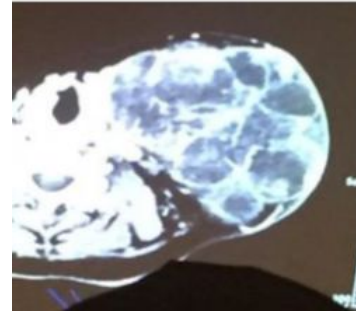
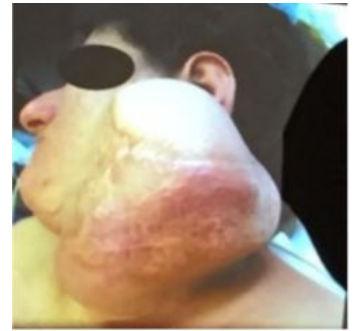**Case 20:** A patient presented with dysphagia. Treated with antibiotics as Adenotonsillitis for almost 2 months, when you examine him you clearly found ulcer in the soft palate. Endoscopy showed this pic.

- **What is the most common cancer seen in this area?** Squamous cell carcinoma.
- **What investigations you would order?** First CT, then biopsy.
- **Histopathologic report revealed late stage SCC. What the management?** Chemotherapy and radiation.



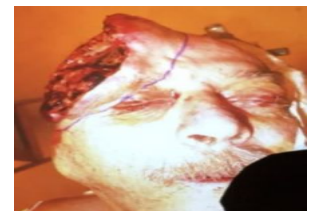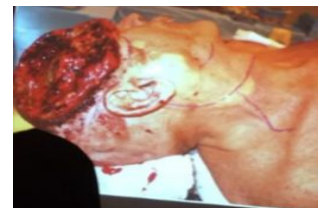**Case 21:** Lady with history of parotid tumor resected, and had three flaps, advised to have radiation therapy but refused!

- This is an unfortunate 36 year old lady who had parotid myoepithelial carcinoma which is not that common of a tumor in the parotid. She was treated with resection previously but had declined radiation therapy. She came with a massive recurrence of her parotid tumor.
- Her **MRI** shows that her tumor has reached her larynx and has replaced most of the neck.
- **Tx:** She underwent surgery and reconstruction, and had done quite well from a surgical point of view. However, she disappeared after surgery without undergoing radiotherapy. She has been seen 6 years after; she was blind at that time because the tumor recurred at the skull base and destroyed her optic canal, she was not able to eat or drink or even talk. She remained in the hospital for 6 months for pain management palliative treatment before passing away!.



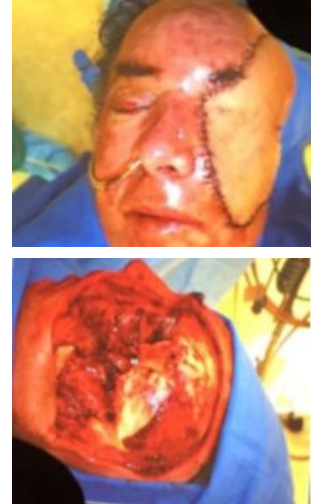**Case 22:** This is another example of ignorance. The patient has Histiocytic carcinoma of the scalp. The patient is demented and refuses any kind of treatment. Finally, his family brought him because they couldn't tolerate his smell.

- **Treatment:** complete resection with radical neck dissection (carotid, internal jugular, vagus nerve, sternocleidomastoid, lymph nodes..etc).
- This is the tumor in the dura, which was resected and grafted.



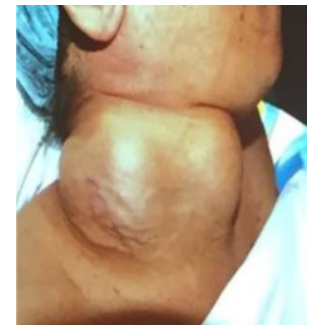**Case 23:** This is a patient with basal cell carcinoma of the temporal area.

- Treated with radiation 20 years earlier. The patient ignored himself completely and disappeared from follow up.
- He presented 20 years later with a massive tumor eating half of his face.
- Now he showed up because he can't see with his eye!
- **Investigations and Dx:** Biopsy reveals squamous-basal cell carcinoma i.e. transformation from basal to squamous cell carcinoma.
- **Treatment:** He underwent massive resection of the whole area. Keep in mind that in patient who received radiation cannot be given radiation again as the tissue would not be able to tolerate it.
- Reconstruction is usually done with anterolateral thigh flap; we take a free flap from the leg with its vessels and plug it into the area and reanastomosis the skin.



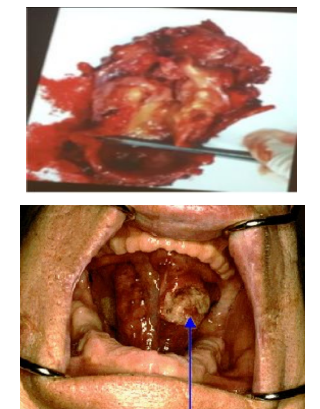
**Case 24:** Elderly lady presented with massive thyroid mass.

- **Investigations and Dx:** MRI shows huge thyroid mass, huge cervical lymph nodes compressing the airway.
- **Results:** Biopsy from the trachea showed anaplastic thyroid carcinoma. The rest of the tumor is papillary.
- Anaplastic thyroid carcinoma is worse than any type of cancer. 1 year survival rate is less than 2%. In contrast, papillary thyroid carcinoma is curable in more than 90%. The average survival even with metastasis is 22 years. This shows that with thyroid, you could have the best prognostic cancer (papillary) and the worst prognostic cancer (anaplastic).
- **Treatment:** She underwent radical neck dissection (carotid, internal jugular, sternocleidomastoid, thyroidectomy etc..)



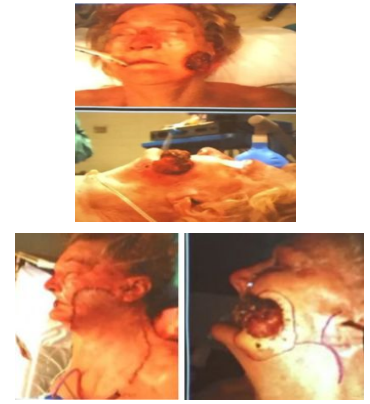**Case 25:** Lady 80+ heavy smoker(2packs/day for 40 years) presented with stridor and hoarseness for 10 months, dysphagia, weight loss and he sleeps on a chair.

- On examination there is neck mass about 4x5 cm in the posterior triangle.
- **Dx:** huge Laryngeal carcinoma destructive tumor invading the base of tongue invading all the surroundings tissues.
- **Rx:** Total laryngectomy, followed by Chemoradiation Stridor indicates airway obstruction and weight loss indicates severe cases! We created a new pharynx so that she can eat and swallow. She can speak by using special reconstruction.
- Severe stridor: breathless when they lay down, walk for short distance or eat!



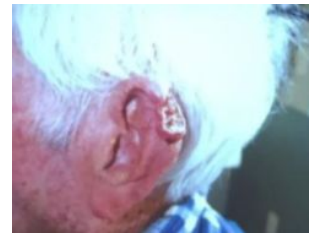**Case 26:** A neglected elderly lady in a nursing home presents with a growing mass on the left side of her neck.

- **Investigations:** Biopsy reveals squamous cell carcinoma. It was a local disease with no metastasis.
- **Treatment:** Patient underwent wide local excision with neck Dissection with parotid.



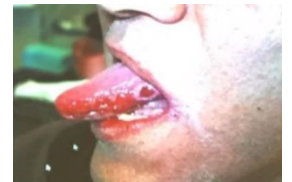**Case 27:** Typical basal cell carcinoma of the auricle.

- **Dx:** confirmed by biopsy!
- **Rx:** basically just resection in case of refusal you can go with radiation!



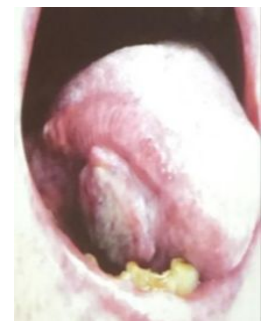**Case 28:** Pt with history of liver failure on the list for transplant, presented with painful ulcer on his tongue for 3-4 weeks.

- **Dx:** Biopsy showed sialadenitis which is just necrotizing part of the inflamed salivary gland!
- **Rx:** self limited.



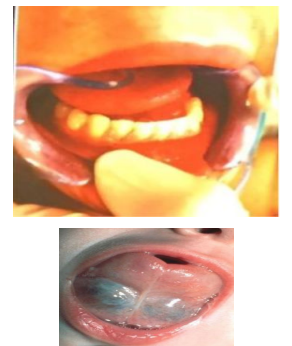
**Case 29:**(Oropharyngeal carcinoma responds very well to radiation therapy, while oral cavity tumors need surgery) Heavy smoker heavy drinker patient presents with painful mass in his right side of his tongue.

- **Dx:** Most likely not 100% sure! 90% is Squamous cell carcinoma of the tongue.
- **DDX:** benign pleomorphic adenoma, malignant salivary gland (minor salivary glands area), also could be sarcoma or lymphoma!
- **Investigation:** Biopsy to confirm and CT scan or MRI for metastasis (staging)
- **Tx:** Surgical excision followed by radiation or chemoradiation! (Up to half of the tongue you can excise without the need for reconstruction)



**Case 30( 433) :** Cystic lesion or cystic obstruction of salivary gland becoming like a balloon Called Ranula!

- Ranulas are mucoceles that occur in the floor of the mouth and usually involve the major salivary glands. Specifically, the ranula originates in the body of the sublingual gland, and, infrequently from the minor salivary glands.
- **Treatment:** marsupialization of the ranula with packing. The more traditional method of surgery for an oral ranula is complete excision of the ranula and associated major salivary gland.



## Other neoplasms: (From old slides but included in the objectives) “Not mentioned by Group F”

### Neoplasms of the Ear and Lateral Skull Base

- Lesions of the Pinna, EAC, Middle Ear, Mastoid, Petrous Apex and Clivus, IAC, CPA, and Skull Base.

#### Introduction:

- Generally classified by location, and occasionally by cell-type
- Causes of these neoplasms are largely unknown.

#### 1. Neoplasms of the pinna and external auditory canal:

- **Cutaneous carcinoma:** Squamous cell carcinoma and Basal cell carcinoma.
- Malignant melanoma.
- **Glandular neoplasm:** Ceruminous adenoma, Ceruminous adenocarcinoma, Pleomorphic adenoma and adenoid cystic carcinoma.
- **Osteoma and exostosis.**

#### 2. Lesions of the Petrous Apex and Clivus:

- Adenomatous neoplasm: Benign middle ear adenoma and Endolymphatic sac tumor.
- Chordoma.
- Congenital neoplasm: Dermoid, Teratoma and Choristoma.
- **Cholesterol granuloma.**
- Langerhans cell histiocytosis.

#### 3. Neoplasms of the internal auditory canal and cerebellopontine angle:

- **Schwannoma:** Vestibular, Facial nerve, Trigeminal schwannoma and Jugular foramen.
- Meningioma.
- Lipoma.
- Metastases.

#### 4. Neoplasms of the Pinna and EAC:

- **Basal cell carcinoma (BCC):** BCC (20% of ear / temporal bone neoplasms). Most on pinna. Sun exposure is initiator. Locally infiltrative, rolled border central crusting ulcer and May invade temporal bone if left untreated.
- **Squamous cell carcinoma (SCC):** Pinna and EAC are common. Sun, cold, radiation are all factors. Scaly irregular indurated maculopapular lesion, often ulcerated with serosanguinous discharge. Can be confused with OE. Other symptoms VII, CHL, SNHL (with invasion of temporal bone). Met. To LN more common than BCC.

#### Treatment:

- Mohs micrographic surgery for most scc and bcc pinna lesions.
- Temporal bone lesions require TB resection and RT. Don't forget to Address **LN in SCC.**
  - **Osteomata and Exostoses:** Benign bony growths in EAC.
    - **Osteoma** is solitary, pedunculated, smooth, round lesions arising from tympanomastoid and squamous suture.

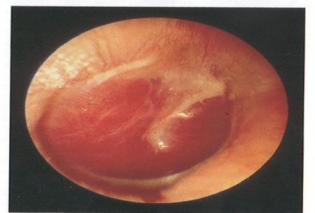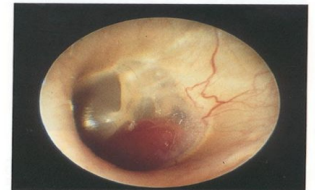- **Exostose** is broad, more medial, multiple, often bilateral. Related to cold water exposure.

## 5. Lesions of the Middle Ear and Mastoid:

➤ **Paragangliomas:** Most common neoplasm of middle ear but still rare.

- **Glomus tympanicum:** Originate on promontory of cochlea (Jacobson or Arnold's nerve), Fill ME space and ossicles involved and May extend to hypotympanum and expose jugular or petrous carotid. Present with HL and pulsatile tinnitus and ME mass.
- **Glomus jugulare:** Arise in jugular fossa and Become large before symptomatic (multiple CN).

- **Brown sign:** +ve pressure leads to blanching.
- **Aquino sign:** ipsilateral CA compression decreases pulsation.
- **Vernet syndrome** (or JF syndrome): paresis of CN IX, X, XI.
- **Villaret Syndrome** = JF syndrome plus Horner's.



**Treatment:** *Rx is complete surgical excision.*

- If secretory must address this (alpha or beta blockade).
- Transcanal, trans mastoid-lab, transcervical, infratemporal, intracranial.
- Pre-op embolization is a necessary.
- If you think it invades the ICA, balloon occlusion studies must be done.
- RT or stereotactic radiosurgery can halt disease in up to 90%.

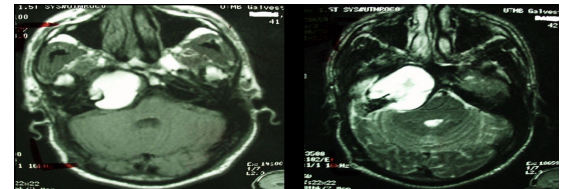
## 6. Lesions of the Petrous Apex and Clivus:

➤ **Cholesterol granulomas:** Most common lesion of the petrous apex. Negative pressure in lumen causes hemorrhage, Expansile lesion. Sx: Hearing loss, tinnitus, vertigo, facial twitching.

- HRCT.
- MRI diagnostic: T1 and T2 hyperintense.

**#Causes:** poor drainage of ME, hemorrhage, obstruction of ventilation, FB reaction to cholesterol crystals from HB catabolism.

**#Rx:** surgical drainage.



## 7. Lesions of the IAC, CPA, and Skull Base:

➤ **Schwannomas** (no longer acoustic): Arise from sheaths of cranial nerves.

- HRCT: Inhomogeneous enhancement and Smooth mass effect.
- MRI – **definitive diagnosis:** T1- low intensity and **Marked enhancement with gadolinium on T1.**

## Neoplasms of the Nose and Paranasal Sinus

- Very rare 3%. **Delay in diagnosis due to similarity to benign conditions.**
- **Nasal cavity:** 1/2 benign | 1/2 malignant.
- **Paranasal Sinuses:** Malignant.
- Multimodality treatment, Orbital Preservation and Minimally invasive surgical techniques.

**Epidemiology:** Predominately of older males | **Exposure:** Wood, nickel-refining processes, Industrial fumes, leather tanning. | Cigarette and Alcohol consumption (No significant association has been shown).

**Location:** Maxillary sinus 70% | Ethmoid sinus 20% | Sphenoid 3% | Frontal 1%.

**Presentation:**

- **Oral symptoms:** 25-35% | Pain, trismus, alveolar ridge fullness, erosion.

- **Nasal findings:** 50% | Obstruction, epistaxis, rhinorrhea.
- **Ocular findings:** 25% | Epiphora, diplopia, proptosis.
- **Facial signs:** Paresthesias, asymmetry.

**1. Squamous cell carcinoma:** Most common tumor (80%) | 90% have local invasion by presentation.

- **Location:** Maxillary sinus (70%) | Nasal cavity (20%).
- **Lymphatic drainage:** First echelon: retropharyngeal nodes. Second echelon: subdiaphragmatic nodes.
- **Treatment:** 88% present in advanced stages (T3/T4). Surgical resection with postoperative radiation.
- **Staging of Maxillary Sinus Tumors:**
  - T1: limited to antral mucosa without bony erosion.
  - T2: erosion or destruction of the infrastructure, including the hard palate and/or middle meatus.
  - T3: Tumor invades: skin of cheek, posterior wall of sinus, inferior or medial wall of orbit, anterior ethmoid sinus.
  - T4: tumor invades orbital contents and/or cribriform plate, posterior ethmoids or sphenoid, nasopharynx, soft palate, pterygopalatine or infratemporal fossa or base of skull.

**2. Olfactory Neuroblastoma (Esthesioneuroblastoma):** Originate from stem cells of neural crest origin that differentiate into olfactory sensory cells.

- Aggressive behavior. | Local failure: 50-75%. | Metastatic disease develops in 20-30%.
- **Treatment:** En bloc surgical resection with postoperative XRT.
- **Kadish Classification:** **A:** confined to nasal cavity. | **B:** involving the paranasal cavity. | **C:** extending beyond these limits.

## Benign Lesions of nose and paranasal sinuses

**1. Papilloma:** Three types: **A:** Fungiform: 50% nasal septum. | **B:** Cylindrical: 3% lateral wall/sinuses. | **C:** Inverted: 47% lateral wall.

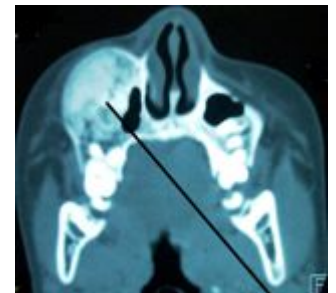
- ❖ **Inverted Papilloma:** 4% of sinonasal tumors. | Site of Origin: lateral nasal wall. | Unilateral. | Malignant degeneration in 2-13% (avg. 10%).
  - **Inverted Papilloma Resection:** Initially via transnasal resection >50-80% recurrence. | Medial Maxillectomy via lateral rhinotomy: (**Gold standard**) >10-20%. | Endoscopic medial maxillectomy: **Key concepts:** Identify the origin of the papilloma and Bony removal of this region.

**2. Osteomas:** Benign slow growing tumors of mature bone.

- Location: Frontal, ethmoid, maxillary sinuses.
- When obstructing mucosal flow can lead to mucocele formation.
- Treatment is local excision.

**3. Fibrous dysplasia:** Dysplastic transformation of normal bone with collagen, fibroblasts, and osteoid material. (Fibrous tissue develops in place of normal bone. This can weaken the affected bone and cause it to deform or fracture).

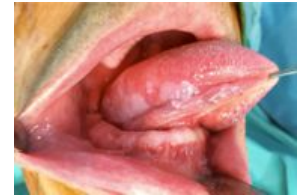- Monostotic vs Polyostotic (single bone vs multiple bones).
- Surgical excision for obstructing lesions
- Malignant transformation to rhabdomyosarcoma has been seen with radiation.



## Oral Cavity Cancer

**Epidemiology:** 95% are squamous cell carcinoma. | 75% of cases occur on 10% of mucosal surface area.

- Risk factors: Smoking (depends on dosage and type). | Alcohol. | Snuff dipping / tobacco chewing. | HPV (subtype 16). | Reverse cigar smoking (India). | Betel-nut chewing (Asia). | Poor dentition / mechanical irritation (dentures).
- Incidence 4% cancers in males, 2% in females (increasing in females).



**Evaluation and Diagnosis:** Lesions generally easy to see | Simple biopsy under local anesthesia.

- **Important goals:** Stage full extent of disease | Rule out synchronous primary | Evaluate for possible metastatic disease.
- CT or MRI for T2 or greater. | Staging endoscopy.

**AJCC TNM Staging:** Primary Tumor (T):

- Tx: unassessable.
- T1: tumor 2 cm or less in greatest diameter.
- T2: tumor 2-4 cm.
- T3: tumor > 4 cm.
- T4: tumor invades adjacent structures (Cortical bone, deep tongue musculature, maxillary sinus, skin).

**Differential Diagnosis:** Minor salivary gland neoplasm (Adenoid cystic, mucoepidermoid, adeno-ca). | Sarcomas (rhabdo, lipo, MFH, leiomyo) | Hodgkin and NH lymphoma | Malignant melanoma | Hairy leukoplakia, Kaposi sarcoma (HIV, immunocompromised).

**Premalignant Lesions:**

- 1. Leukoplakia:** Hyperkeratosis, dysplasia. | Malignant transformation greater in non-smokers.  
→ **Treatment:** Surgical or laser excision | Topical bleomycin, retinoids.
- 2. Erythroplasia:** Greater risk of malignancy!

**Prognostic Factors:** Poor prognostic tumor factors include:

- Tumor thickness (3mm FOM, 5mm tongue). | Stage. | Perineural invasion. | Lymphatic invasion. | Vascular invasion. | Neck/distant mets. | DNA ploidy. | Pathology.

**Treatment and post-treatment follow-up: SURGERY!**

- ★ **Primary:** Resection with adequate margins; frozen section as needed | Tracheostomy as needed | Feeding tube (optional) | Surgical orientation of specimen for pathologist.
- ★ **Neck:** Modified/radical dissection for unilateral metastatic disease and bilateral dissections for metastases in both necks | Suction drainage.
- ★ **Perioperative care:** Antibiotics | Hospitalization for 3–10 days | Tube feedings | Suction drainage for neck(s)—remove when output <25–30 mL/24-h period | Suture removal 5–10 days postoperatively.

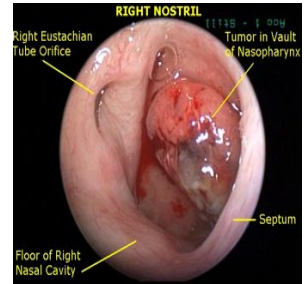
## Tumours of Pharynx

**Nasopharyngeal Carcinoma:** Rare in the US, more common in Asia.

- High index of suspicion required for early diagnosis.
- Nasopharyngeal malignancies: SCCA (nasopharyngeal carcinoma). | Lymphoma. | Salivary gland tumors. | Sarcomas.

**Classification:** WHO classes: Based on light microscopy findings. | All SCCA by EM.

- Type I (SCCA)
- Type II (non-keratinizing carcinoma)
- Type III (undifferentiated carcinoma)



**Epidemiology:** Chinese native (esp. Guangdong province) > Chinese immigrant > North American caucasian.

**Environmental factors:**

- ➔ Viruses: EBV - well documented viral “fingerprints” in tumor cells and also anti-EBV serologies with WHO type II and III NPC. | HPV - possible factor in WHO type I lesions.
- ➔ Nitrosamines - salted fish.
- ➔ Others - polycyclic hydrocarbons, chronic nasal infection, poor hygiene, poor ventilation.

**Clinical Presentation:** Often subtle initial symptoms: unilateral HL (SOM). | painless, slowly enlarging neck mass (70%): “Lymphatic channels cross midline in NP, bilateral disease common.”

- Larger lesions: Nasal obstruction. | Epistaxis. | Cranial nerve involvement.

**Staging EUCC:**

- ★ T1 – tumor confined to NP
- ★ T2 – tumor extends to soft tissue.
- ★ T3 – Tumor invades bony structures and/or paranasal sinuses.
- ★ T4 – intracranial extension, involvement of cranial nerves, infratemporal fossa, hypopharynx, orbit or masticator space.

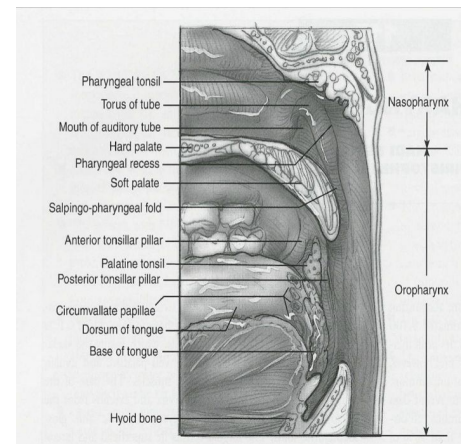
**Treatment:** External beam radiation and | Adjuvant Chemotherapy: Standard of care, Cisplatin (hematologic side effects therefore not overlapping toxicity).

## Oropharyngeal Cancer

Relatively uncommon. | 6th and 7th decades mainly. | Increasing in 4th and 5th decades. | Male predominance. | SCC = 90%. | Tobacco and alcohol. | Complex, multimodal treatment. | Team approach.

**Anatomy:** Connects nasopharynx to hypopharynx.

- **Anterior:** Circumvallate papillae. | Anterior tonsillar pillars. | Junction of hard and soft palates.
- **Pharyngeal walls:** Mucosa, submucosa, pharyngobasilar fascia, constrictor muscles, buccopharyngeal fascia.
- **Tonsils sit in tonsillar fossa.**
- **Soft Palate:** Palatine aponeurosis. | Tensor veli palatini. | Levator veli palatini. | Uvular muscle. | Palatoglossus. | Palatopharyngeus.





**Etiology:** SCC arise from the accumulation of multiple genetic alterations to genes important to the regulation of cell growth and death.

- Cells have selective growth advantage: Genetic. | Environmental. | HPV and EBV. | Dietary factors. | Immunosuppression.

**Histopathology:** Premalignant lesions: (Leukoplakia, Erythroplakia, Lichen planus)

- SCC and variants > 90%.
- Spindle cell – clinically and biologically similar to SCC.
- Verrucous – fungating and slow growing, with well differentiated keratinizing epithelium and rare cellular atypia or mitosis. Both invade deeply with rare mets.

1. **Lymphoepithelioma:** Grow rapidly and readily mets. | Tonsillar region. | Younger patients without risk factors.
2. **Adenoid squamous, adenosquamous, and basaloid SCC are rare and highly aggressive (latter two have early mets).**

**Treatment:**

- Team approach: Surgeons and Radiation Oncologists. | SLP. | Oral Surgeon.
- T1 and T2 – surgery or radiation.
- T3 and T4 – combined modality.
  - **Neck:**
    - N0 and N1 – surgery or XRT.
    - N2 and N3 - combined modality.
    - Both necks treated with central lesions.
    - Retropharyngeal nodes are always treated.

## Hypopharyngeal Cancer

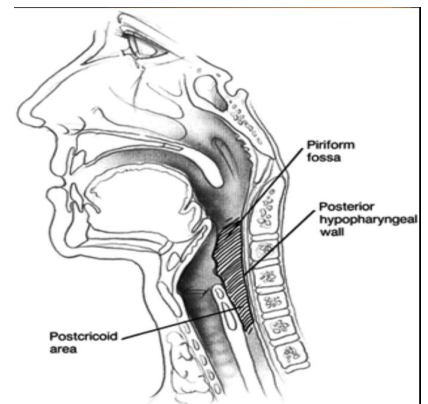
- Incidence – 5-10% of all upper aerodigestive cancers (0.5% of all malignancies). M>F: males have 8X increased risk. | Females with Plummer-Vinson.
- Risk Factors: Smoking. | EtOH.(ethanol) | Chronic reflux disease.

**Treatment Challenge:** Patients often present with advanced disease.

- May be complicated by severe malnutrition.

**Hypopharynx Anatomy:**

- Abuts the oropharynx at the level of the hyoid, extends to the level of the inferior border of the cricoid.
- 3 sub-sites: piriform fossa, post-cricoid region, posterior pharyngeal wall.
- Piriform apex – junction between postcricoid area and the inferior aspect of the pyriform fossae.



**Staging Endoscopy:**

- Most important component of procedure (secondary to obtaining Bx samples for diagnosis) is determining the inferior limit of the tumour
- Common site: pyriform fossae, post pharyngeal wall, post-cricoid region.

**Pathology:** ~95% of cancers of the hypopharynx are SCC.

- Lymphomas.
- Adenocarcinomas: May originate in the minor salivary glands of the hypopharynx.
- Benign lesions: Lipoma: < 1%, usually resected due to risk of airway obstruction.

### Surgical Tx Options:

- Hypopharynx: Based on Site of Involvement.
- Piriform Fossa (64%).
- Posterior Pharyngeal Wall (30%).
- Post-cricoid (4%): Treating the Neck.

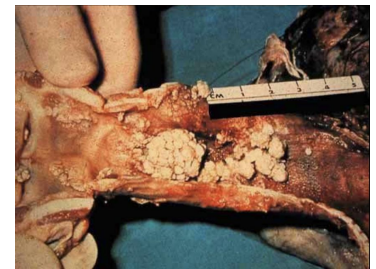Procedure	T stage	Reconstruction
Partial Pharyngectomy	T1, T2	Primary closure
Partial Laryngopharyngectomy	T1, T2, T3	Regional or free flap
Supracricoid hemilaryngectomy	T1, T2, T3	Primary closure
Endoscopic CO2 laser resection	T1, T2 (possibly T3, T4)	Secondary intention
Total Laryngectomy with partial-total pharyngectomy	T3	Primary closure vs. regional or free flap
Total Laryngo-Pharyngo-esophagectomy	T4	Gastric pull-up

## Laryngeal Tumours

**Etiology:** EtOH – supraglottic | Tobacco – glottic | GERD – chronic laryngeal irritation | Viral infection | Asbestos | Nickel | Wood | Isopropyl alcohol | Radiation.

### Laryngeal Papillomatosis:

- Most common benign laryngeal tumor, HPV etiology.
- Vocal folds and subglottis most common laryngeal sites.
- More prevalent in children, less common in individuals over 30 years of age: HPV is transmitted to child through birth canal from cervix.
- Papillomas appear multinodular, and may be either sessile or exophytic: May resemble carcinoma-in-situ or even invasive SCC.



**Picture:** Exophytic, warty, friable, tan-white to red growths.

- Most common viral subtypes are 6 or 11, but 16 or 18 have higher potential for malignant change.
- Hoarseness is common early symptom followed by airway obstruction and respiratory difficulty.
- Laryngeal papillomas presenting in adults seem to be less aggressive than juvenile form but remission rate unpredictable.
- In adults, growth may be rapid during periods of hormone change such as during pregnancy.
- Malignant degeneration of laryngeal papillomas rare and usually associated with history of radiotherapy, tobacco abuse or both.

### Treatment:

- ❖ **Surgery:** Laser microlaryngoscopy. | Always biopsy before remainder of case proceeds.
- ❖ **Interferon:** Bad chronic side-effects (myalgias, flu-like symptoms) | Lesions tend to return after interferon finished.
- ❖ **Intralesional cidofovir** (acyclic nucleoside analogue)
- ❖ **Indole-3-carbinol** (found in cruciferous vegetables, works via inhibition of estrogen metabolism).
- ❖ **Acyclovir.**
- ❖ **Photodynamic therapy.**

## Supraglottic vs Glottic Disease

- North America glottic cancer > supraglottic (2:1).
- France supraglottic > glottic (2:1)

### Anatomy of glottis:

- True vocal cords
- Anterior and posterior commissures
- Superior limit – apex of ventricle
- Inferior limit – 1 cm inferior to line through apex

### Staging (Early Glottic):

- Tis → no invasion beyond basement membrane.
- T1 → confined to glottis with normal mobility.
  - T1a → tumor limited to one vocal cord.
  - T1b → tumor involves both cords, no limitation in mobility.
- T2 → extend into supra- or subglottis without complete vocal cord fixation.
  - T2a → involve supra- or subglottis but do not impair movement.
  - T2b → impair movement of vocal cords, but not complete fixation.

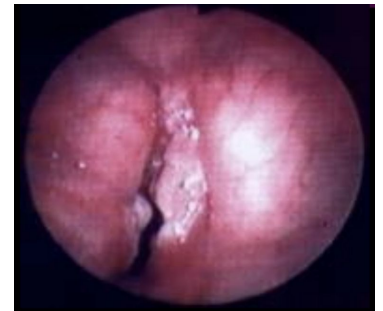### Staging (Advanced Glottic):

- T3 – complete vocal cord fixation, ± paraglottic space, ± minor thyroid cartilage erosion (inner cortex).
- T4 – extends beyond larynx, into thyroid cartilage.

**Symptoms:** Hoarseness > 4 weeks → investigate. | Occasionally may present without hoarseness. |

Dysphagia. | Hemoptysis.

- Early: irregular area of mucosal thickening.
- Advanced: exophytic, fungating, endophytic, ulcerated mass.
- More commonly keratinizing, well to moderately differentiated.
- In situ component.
- Invasive component predominantly infiltrative.
- Up to 20% of T1 cancers have some degree of vocal cord ligament invasion.
- Most tumors originate on free surface of vocal cord. Anterior ⅔.



### Treatment:

- Early Stage: Laser or Radiation.
- Advance Stage: Chemo. + Radiation or Surgery + Radiation.

