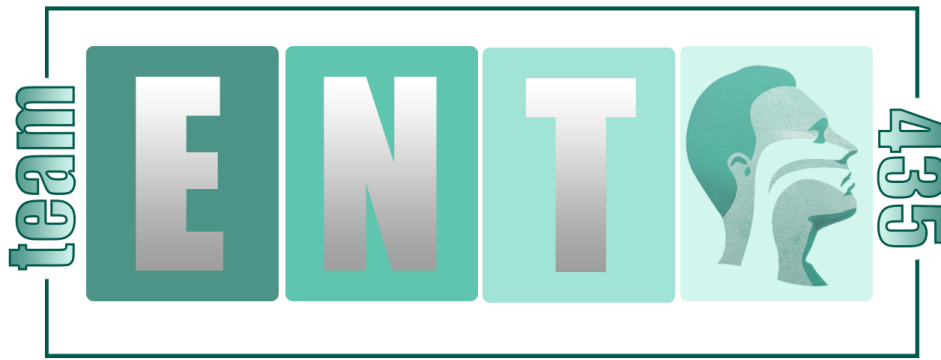



# Trauma and Foreign body I & II

## Objectives:

- Discuss the presentation of patients with trauma to the nose, ear or the larynx and patients with ingested or inhaled FBs or with FBS in the nose or the ear.
- Discuss the management of those patient with emphasis on the emergency treatment.
- The dr did not allow us to take the slides ,even though he completely changed the slides from those of the previous years.The team included the important pictures from his slide and his important notes
- This year the lecture is quite different from the previous years and the doctor did not allow us the take the slides.  
However, shahad Al- Jraiba was able to take pictures of the important images while the dr was explaining.

So we included in the team:

1-Team 433

2-The important notes from the dr's slides(blue)

3-The important images that the dr focused on

[ Color index: Important | Notes | Extra ]

**Done By :** Mohammed J. Alsahil, Rifan Hashim, Alanoud Alsalman.

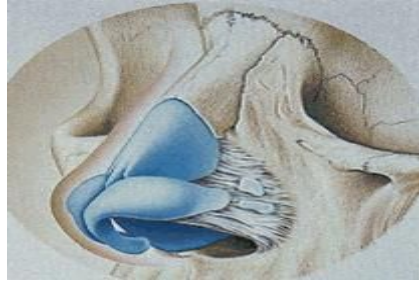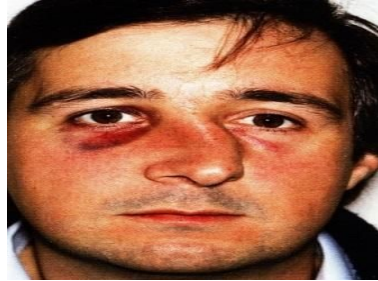**Edited By:** Sara Alkhalifah.

**Revised By:** Lina Alshehri.

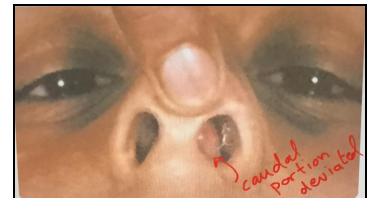**Resources:** Slides+433team+Notes+Toronto notes +lectures notes ENT  
+ Oxford handbook of otolaryngology.

The most important thing you must do in a trauma patient is to **localize the bleeding!!**

### Nasal trauma



- The bones of the nose are the most frequently broken bones in the face as they are the most prominent. A nose break will affect the patient's appearance.
- **Complications of nasal trauma:**
  - Deviation which may lead to nasal obstruction → caudal septal deviation
  - Distortion and swelling over the nasal bridge
  - **Septal hematoma**
  - **Septal abscess** (septal abscess and hematoma may end with septal perforation and nasal collapse if not treated properly)
- Immediate evaluation is necessary to **make sure there is no septal hematoma** (blood between the septum and cartilage).
- If septal hematoma develops (it should be drained), it might be complicated by an infection, and 5 days later it might progress to an abscess. This may lead to **cartilage necrosis and the patient might end up with a saddle nose** deformity because of supportive cartilage loss.
- The swelling and edema may interfere with proper evaluation. Therefore, re-examine for any deviation or fracture after 3-4 days for children and after one week in adults (children heal faster than adults).
- Do a nasal bone reduction if patient presents early: pediatrics within 10 days and adults up to two weeks.
- Indications of septorhinoplasty in nasal fracture: (in children wait until the age of 18)
  - If the bone has healed alone
  - Complicated fracture
  - Hematoma
- **Nasal fracture**
  - Very common
    - **MOST COMMON** facial fracture
    - 3rd most common fracture in the body
  - High index of suspicion for fracture
    - Mechanism, change in appearance
    - Epistaxis, nasal obstruction
  - Examine and palpate the nose carefully
    - Instability, mobility, crepitation
    - Lacerations, septal hematoma
  - Nasal x-ray-variable reliability
  - Early ENT referral (<5days)
    - Closed/open reduction-Early treatment can avoid cosmetic deformity and chronic nasal airway obstruction (<10-14days)
    - Septorhinoplasty
  - **Causes of cosmetic defects**



- 1-Poor initial management of a fracture
- 2-Secondary infection
- Most important aspect: fracture of the nasal bones
- Two types of nasal bone fractures:
  - 1-Depressed → use elevator to elevate the depressed bone
  - 2-Deviated → blow came from the side → return the nose to the midline
  - Put external cast in both cases because bone is unstable
  - Fractured in contact sports or during fights
- Important:
  - How do you know that there is fracture? **If there is epistaxis**
  - If the patient informs you that he had trauma to the nose and blood came out, even if it was a small amount → bone is fractured → **Immediately look for septal hematoma**

### Causes

1. Traumatic most commonly.
2. Iatrogenic (surgical).
3. Foreign bodies: If it stayed for long time, it will lead to necrosis of the cartilage.

### Manifestations of Nasal Trauma

- Main complaints of a patient with nasal trauma: 1-Deformity (if not obvious compare with a past picture or with the driver's license) 2-Nasal obstruction 3-Bleeding
- Fracture of the nasal bone
- Septal injury: (Displacement, Hematoma, Perforation)
- Synechia
- CSF rhinorrhea
- Epistaxis
- What is the most common area of epistaxis (95%)? little' area (or Kiesselbach area of the nose), **VESSELS** forming little's area: **superior labial artery, sphenopalatine artery, anterior ethmoidal artery, greater palatine.**
- Management of epistaxis:
  - You manage epistaxis with cauterization with electrical cautery or chemical cautery (chemical cauterization is easier!!)
  - Or manage it by anterior nasal packing --> by merocel
  - If after 24 hours the bleeding not stop--> use anterior posterior nasal packing
  - If after 24 hours the bleeding still did not stop> surgical ligation of sphenopalatine, anterior ethmoidal artery, posterior ethmoidal ARTERY.
  - Why is cauterization risky? **One of the most common causes of septal perforation is cauterization**

### Diagnosis

"MedScape" **Doctor's notes in red**

- **Most nasal fractures are diagnosed by history and physical examination. Most important thing in nasal fractures : EXAMINATION (nasal cavity) **TO EXCLUDE SEPTAL HEMATOMA****
- History usually includes a preexisting trauma, which may be followed by epistaxis. Typically, the epistaxis has resolved by the time the patient presents for intervention.
- Patients usually present with swelling over the nasal bridge and a difference in the appearance or shape of the nose.
- Physical examination findings include swelling over the nasal bridge, grossly apparent deviation of the nasal bones, and periorbital ecchymosis.
- **Plain radiographs are not helpful in the diagnosis or management X-ray is not necessary ( does not add anything to the management), but can be used for medicolegal purposes** of nasal fractures in isolated nasal injury.
- **Nasal bone CT scan is helpful** if the patient has associated facial fractures.
- Be sure to ask the patient how the external shape of the nose has changed since the fracture. This

helps determine what corrective maneuvers should be taken to restore the patient's appearance through reduction of the nasal fracture.

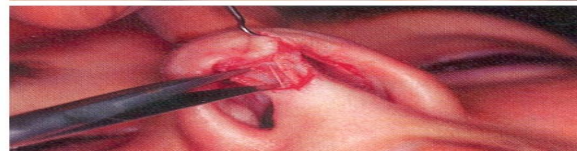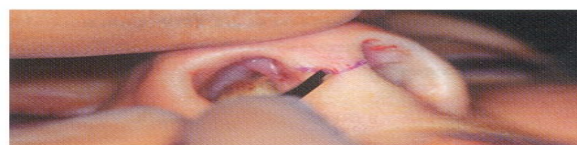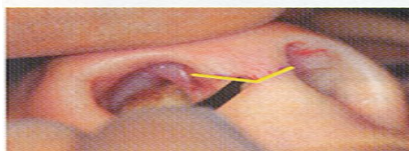

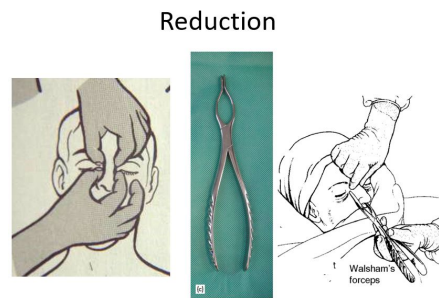
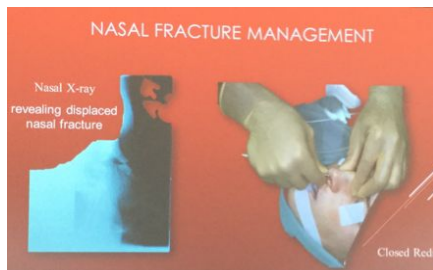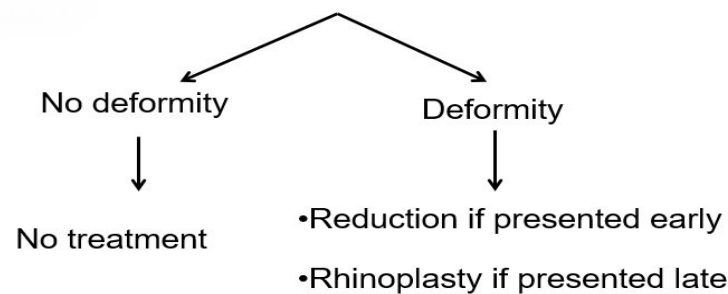
## Management

Depends upon the presence or the absence of nasal deformity (for proper assessment of the "shape" of the nose you may wait "few" days for the edema to subside)

### Repair time is limited

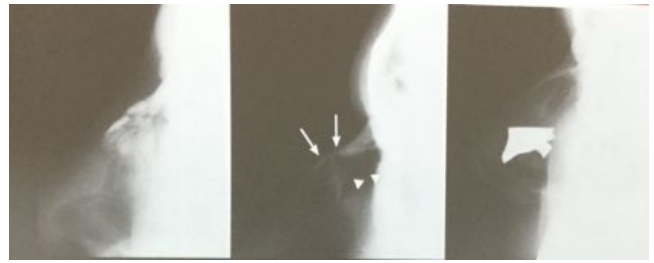
Nasal bone reduction: 1-Pediatric within 10 days. 2-Adult up to two weeks if more it will need septorhinoplasty

- Patient without significant swelling or deformity may be discharged
- For those with significant swelling:
  - Give advice on using ice/simple analgesia to decrease the oedema and pain
  - Discharge review in five days
- Patient with significant and nasal deviation should be referred to ENT within 7-10 days of the injury.
- Adhesions to surrounding soft tissue can occur in as few as 5-10 days.
- Fracture reduction can be performed when it is possible to assess and manipulate the mobile nasal bones.
- Usually within 5-10 days in adults and 3-7 days in children.
- Patient with little swelling may be suitable for immediate reduction.
- Closed reduction is preferred by most surgeons.
- Antibiotics are indicated if there is laceration overlying the fracture, or if a septal haematoma has been incised.

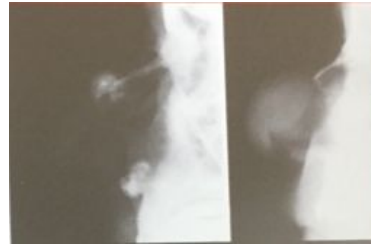

## Important pictures


Picture 1,2: Depressed nasal fracture  
 Picture 3: Metal piece within nose (nasal bone normal)



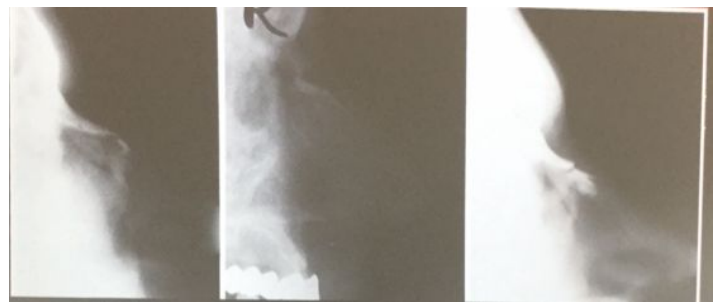
Picture 1: Calcifications post rhinoplasty  
 Picture 2: Hemangioma



Picture 1: Rhinoplasty with silicone  
 Picture 2: Nasal surgery was done for this patient after fracture (a lot of implanted material "augmentation" in the nose, thus it appears like this on X-Ray)  
 Picture 3: Nasal bone has metastasis( small round at the beginning of nasal bridge)

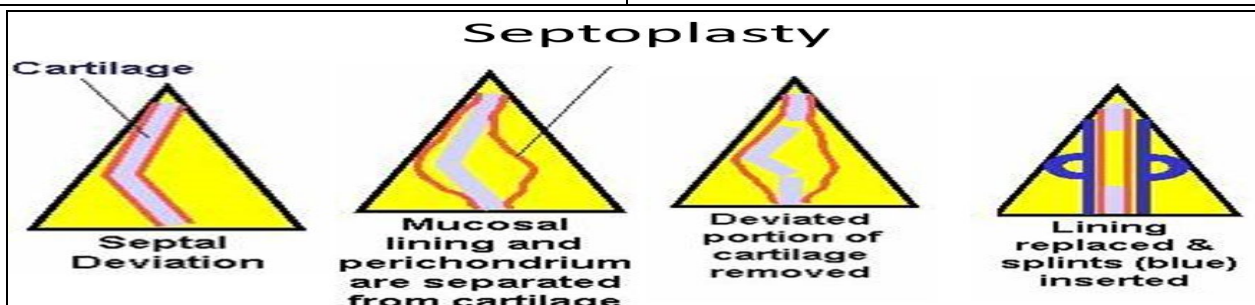


Depressed bone fracture



## Nasal Septum Injuries

Presentation of Displaced NS	Treatment
<ul style="list-style-type: none"> <li>May be asymptomatic</li> <li>Nasal obstruction</li> <li>Cosmetic</li> </ul>	<ul style="list-style-type: none"> <li>No symptoms: no treatment</li> <li>Symptomatic:                             <ul style="list-style-type: none"> <li>- Early presentation: Reposition</li> <li>- Late presentation: Septoplasty</li> </ul> </li> </ul>

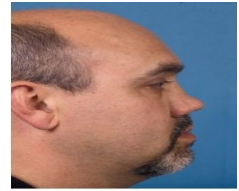



## Septal Hematoma

### Complications

- Necrosis of the cartilage: Deformity (saddle Nose)
- Infection:
  - Septal abscess
  - Spread to the intracranium



### Diagnosis "Medscape"

A careful examination is important for anyone who sustains nasal trauma. Signs of external trauma, such as nasal deformity, epistaxis, or significant pain, are associated with a septal hematoma. However, a septal hematoma may be present without any signs of external trauma. A septal hematoma can usually be diagnosed by inspecting the septum with a nasal speculum or an otoscope. Asymmetry of the septum with a bluish or reddish fluctuance may suggest a hematoma. Direct palpation may also be necessary, as newly formed hematomas may not be ecchymotic.

- Nasal Hematoma is very painful

### Treatment

#### The dr focused on the following points :

1-**Immediate** Incision and Drainage.

\*Note that the hematoma usually occurs in both sides of the nasal septum (bilateral)  
So when you want to do the incision ,you have to do it on both side

**BUT YOU HAVE TO MAKE THE INCISION ON DIFFERENT LEVELS** (ما يكونوا على)

(استقامة واحدة: واحد فوق و الثاني أنزل منه)

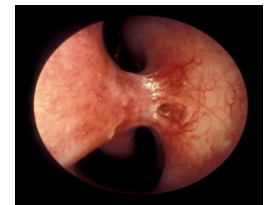
Why? To avoid perforation of the nasal septum

2-Pressure application

3-Antibiotics

## Synechia

- Usually follows surgery
- May be asymptomatic
- May cause nasal obstruction
- If symptomatic, treatment is by division and insertion of Silicone silastic sheets (for 10 days).

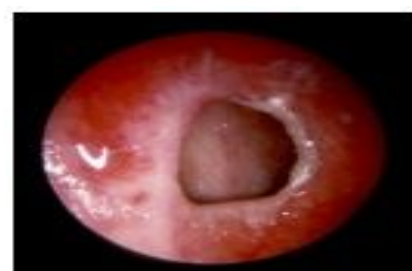
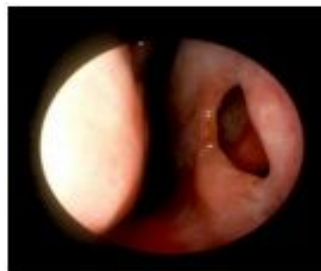
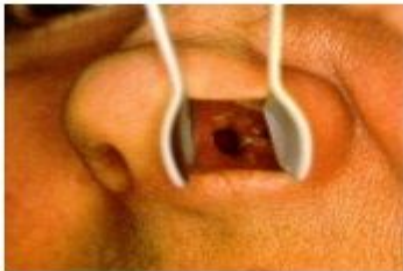## CSF Rhinorrhea

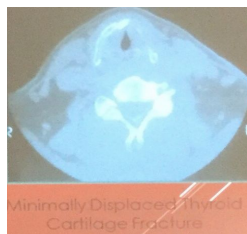
- Due to injury of the roof of the nose and the dura
- Unilateral watery rhinorrhea increases by bending forward, exertion and coughing
- Halo sign
- Diagnosis is confirmed by biochemical analysis (Beta-2-transferrin) and by radiology
- Most cases resolve with conservative treatment
- Surgical repair may be needed in minority of cases
- **Complications:**
  - Meningitis
  - Tension pneumocephalus

## Traumatic Septal Perforation

Causes	<ul style="list-style-type: none"> <li>- Mostly Surgical Trauma</li> <li>- May be due to self-inflicted Trauma</li> <li>- <b>Common causes of septal perforation "in general":</b> <ul style="list-style-type: none"> <li>- Iatrogenic</li> <li>- Repeated "aggressive" nose picking</li> <li>- Idiopathic</li> <li>- repeated cauterization</li> <li>- cocaine sniffing--&gt; SEVERE vasoconstriction --&gt; decreased blood supply --&gt;necrosis of cartilage--&gt; perforation</li> <li>*all of the above causes lead to anterior septal perforation</li> </ul> </li> <li>- Syphilis (the only one that occurs in the posterior part of nasal septum)</li> </ul>
Symptoms	<ul style="list-style-type: none"> <li>- Might be asymptomatic</li> <li>- Whistling sound during breathing (in small perforation)</li> <li>- Crusting 90% of patient complain of crusting and epistaxis we worry when the patient have recurrent epistaxis especially if it was unusual epistaxis</li> <li>- When you found that the patient is having septal perforation don't tell the patient because he will be symptomatic even if he's not!</li> </ul>
Treatment	<ul style="list-style-type: none"> <li>- No Treatment if treatment is indicated do surgery silicone is very bad</li> <li>- Nasal wash</li> <li>- Surgical Repair</li> <li>- <b>Silicon Button</b> its very bad it the patient will complain of crusting and feeling of foreign body in there nose</li> </ul>



## Laryngeal Trauma

Clinical presentation	Investigation
<ul style="list-style-type: none"> <li>● Stridor</li> <li>● Hoarseness</li> <li>● Subcutaneous emphysema</li> <li>● Hemoptysis</li> <li>● Laryngeal tenderness, swelling and edema</li> </ul>	<ul style="list-style-type: none"> <li>● Laryngoscopy</li> </ul> <div style="text-align: center; margin-top: 10px;">  <p style="font-size: small; color: red;">Minimally Displaced Thyroid Cartilage Fracture</p> </div>
Management	
<ul style="list-style-type: none"> <li>- Tracheostomy if Bleeding or Respiratory Distress.</li> </ul>	

- Explore and Repair

### Blunt Laryngeal Trauma:

- Laryngeal trauma is uncommon
- Mechanism: MVA, Sports, assault(strangulation)
- Secure airway
  - Oral intubation-problematic
  - Tracheotomy (not cricothyrotomy)
- Cervical spine injury may be present

## Orbital Floor Fractures (blowout)

- Trauma will affect the weakest part of the orbit: Floor of the orbit (roof of maxillary sinus).
- It can occur as an isolated injury Or in combination with zygomatic arch fractures, Le Fort type II or III mid-face fractures, medial wall or orbital rim fractures.
- When it is an isolated injury the object is usually intermediate in size. Not small enough to perforate the eye but not large enough to reach or affect the eyebrow or other areas of the face. The commonest example is a **tennis ball**.
- The force may lead to inferior rectus entrapment and fat herniation inferomedially leading to enophthalmos due to the break in the floor of the orbit.
- Patient should be referred to ophthalmologist for vision examination.
- Orbital floor fracture results from blunt injury directed to the globe causing the orbital floor to blow out into the maxillary sinus
- Entrapment of the extraocular muscle may result in diplopia especially on upward gaze
- Ophthalmologic evaluation is recommended as these injuries are commonly associated with ocular injury (up to 10%)
- Ct provides a very accurate determination of the orbital floor injury
- Limitation of upward gaze in the eye due to entrapment of the ocular muscles which requires **exploration and reconstruction of the orbital floor**.

### Etiology

- Pure orbital floor fractures result from an impact injury to the globe and upper eyelid.
- The object is usually small enough to not fracture the orbital rim but large enough not to perforate the globe.

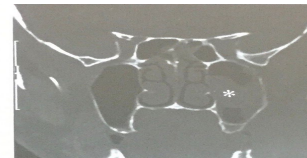
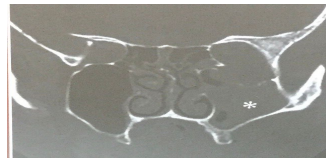
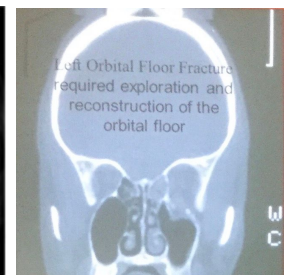
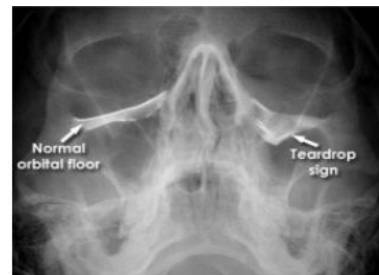
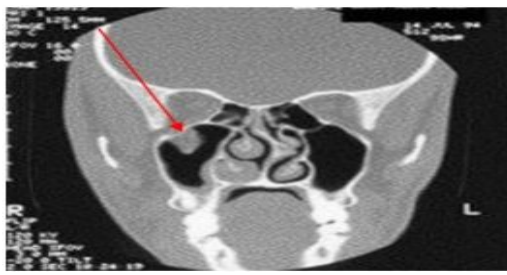### Presentation

1. **Limitation of movement**. Due to entrapment of fibrous septa in orbital fat, or the inferior rectus MS
2. **Diplopia** and restriction of upward
3. Decreased visual acuity.
4. Blepharoptosis: drooping or abnormal relaxation of the upper eyelid.
5. **Enophthalmos** (posterior displacement of the eyeball within the orbit). Due to orbital herniation
6. Patients may complain of epistaxis
7. The globe can be ruptured
8. Subconjunctival hemorrhage
9. **Infraorbital nerve sensation disorder**

## Imaging studies

- AP X-ray views of the orbit.
- The most common views are the Caldwell (occipitofrontal) and Water's Projections (occipitomenital)
- **CT scanning** (you should always look at the orbital rim) (**the best**): obtains both axial and direct coronal to properly evaluate the orbit and its floor.
- Blowout fracture on CT Scan:
- Coronal CT scan is showing an orbital floor fracture posterior to the globe; a fracture of the lateral maxillary sinus wall is also present.





### Treatment

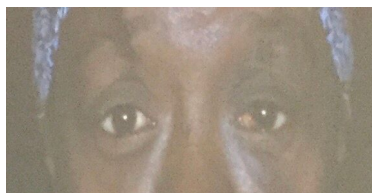
Cosmetic as well as to explore and release the displaced soft tissue, and to repair the bony deficit by removing or repositioning the bony fragment. **We take from the septal cartilage and we put it in the floor.**

No need for intervention in small, non-entrapped, non-infected fracture.

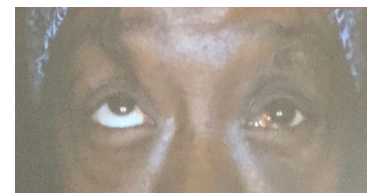Surgical Treatment (Repair) for the orbital floor to be carried out through:

- Transconjunctival approach
- Cutaneous approach
- Transmaxillary approach
- Endoscopically: enter through maxillary sinus and push up the roof.

**Keep in mind** that it is rare to have an isolated injury so always look for other fractures and injuries.



Neutral gaze



Upward Gaze due to entrapment of the ocular MS

## Ear trauma

Ear trauma can be divided to External (Auricular), Middle and inner ear trauma. It could be a laceration, avulsion (completely cut off). It could also be a burn, radiation or Hematoma.

### 1. External ear trauma

#### 1. Auricular hematoma: Very common

- a. collection of blood between the perichondrium and the cartilage usually in the anterior part of the auricle hematoma are considered as an **emergency** case to prevent cauliflower ear.
- b. The cartilage feeds directly from the perichondrium (no direct blood supply). Hematoma between the perichondrium and the cartilage → blocks the blood supply to the cartilage → infection /necrosis/abscess → cauliflower ear or atresia of the meatus.  
\*note that the same thing can happen in the nasal septum : a hematoma will block blood supply → necrosis → abscess → septal perforation which may result in collapse
- c. Usually as a result of BLUNT trauma to the ear (in contact sport, fights)
- d. Examination: ear will be soft and boggy, with loss of normal contour.
- e. Management : incision and drainage (may be done under GA because its painful) + compressive dressing (compression to prevent recollection of blood) + antibiotics (antistreptococcal antibiotics: clindamycin, dicloxacillin, cephalexin) (for both auricular and nasal hematoma)

- f. aspiration must be avoided because it is inadequate because it will likely recollect. Repeated aspiration may lead to superinfection and seroma.

**2. Auricular laceration:**

- a. Pinnacle has a very good blood supply → easy to suture
- b. You have an **8 hour window** to suture
- c. Human bites: perichondritis can be prevented by dressing the wound and delaying closure for 2-3 days
- d. The ear lobe may split by avulsion by an earring (you have to know that this is one a common type of trauma to the ear , can occur if someone pulls on someone's earring!) → repair by step incision with a suture loop to reconstruct the hole
- e. IT IS IMPORTANT TO KNOW THAT CLOSURE OF ANY LACERATION IN THE EAR OCCURS BY PRIMARY INCISION, then put the patient on antibiotics)
- f. If there is a separation of any part of the ear (EVEN IF THE ENTIRE EAR SEPARATES) → you can graft if you are still in the eight our window
- g. Complications of ear trauma: bacterial infection, cauliflower ear which may lead to atresia of the external meatus
- h. If you have piercings in the cartilage part it will always end up with infection and end up with cauliflower you have to clean it and put fucidin all the time.

**3. Laceration external meatus:**

- a. It's easy to make laceration in the external meatus usually result of foreign body, cotton swab, keys, عود كبريت, suction of the ear.
- b. It happens in the narrowest part of the ear (isthmus) usually it happen in the lateral part of the isthmus can extend to the tympanic membrane and causes dislocation of the ossicles and facial nerve injury.

4. Cancer

- a. Ear can be affected by squamous cell carcinoma or basal cell carcinoma

5. Frostbite

- a. In cold countries. Causes necrosis of the cartilage.

6. Ear piercings

- a. Specially ones in the cartilage can cause: infection, abscess, keloid (risk factors: non sterile technique, dark skin) hematoma and cauliflower ear.
- b. Treatment: drain if abscess or hematoma, steroids if keloid.

**2.Traumatic TM Perforation**

Patient might present with history of trauma, earache, deafness, bloody otorrhea

★ **Management of traumatic TM perforation:**

- Observation: Most cases heal spontaneously. Avoid Suction, ear drops and water
- Elective myringoplasty

**3.Middle Ear Trauma**

1.Hemotympanum	2.Traumatic Ossicular disruption
<ul style="list-style-type: none"> <li>- Usually is asymptomatic</li> <li>- May cause conductive hearing loss</li> <li>- Treated by observation because most cases resolve spontaneously</li> </ul>	<ul style="list-style-type: none"> <li>- Suspected if trauma followed by CHL with intact TM</li> <li>- Diagnosis is confirmed by CT and/or by surgical exploration (tympanotomy)</li> <li>- Treatment is by surgical repair</li> </ul>

**3.Otitic barotrauma**

- Pathological condition of middle ear due to failure of the Eustachian tube to equalize an increasing atmospheric pressure
- Occurs most commonly during descent from high altitudes in aircraft or during descent in underwater

- diving
- Pathology: the negative middle ear pressures causes transudate in the middle ear, rupture of superficial vessels, retraction of TM, and may cause perforation



Symptoms	Treatment
Discomfort, pain & deafness	<ul style="list-style-type: none"> <li>- Prophylactic</li> <li>- Decongestant, analgesic and auto inflation (Valsalva maneuver)</li> <li>- Myringotomy ± VT insertion</li> </ul>

## Temporal Bone Fracture

- Temporal bone area contains the middle and the inner ear. Fractures can be due to trauma to frontal, occipital or side head Injury.
- It could be due to a **Blunt trauma (Most Common)** Ex. RTA or a **penetrating injury (Less Common)**
- **Temporal bone fracture types: Direct (localized): seen with gunshot wounds (penetrating perforating with brain injury) Indirect (diffused) (مطالين فيها!!): in blunt trauma → in this type the damage is in the petrous pyramid of temporal bone (either longitudinal fracture, or transverse fracture)**
- YOU HAVE TO EVALUATE THE C-spine
- Must know the status of the facial nerve (traumatized or not)
- Note that if the facial nerve is affected then the temporal bone must also be fractured by the accident
- Must ask yourself if the facial nerve palsy occurred immediately or this patient has a long standing facial WEAKNESS even before the trauma (why? Because if it occurred immediately you have to go in surgically and reconstruct)
- And if the patient started to have facial weakness some time after the trauma (slow onset), then this is due to post traumatic edema → NON SURGICAL conservative treatment (protect the eye from dryness and close it, STEROIDS, patient follow up is necessary)
- Conclusion:
  - Immediate onset of facial nerve injury → direct trauma to the nerve
  - Slow onset of facial nerve palsy → only post traumatic edema

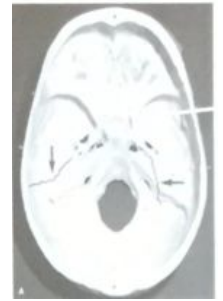
### Types of Temporal bone fractures

- Longitudinal: 70%-80% of the cases, Conductive hearing loss (rupture drum, hemotympanum or ossicular disruption) Facial nerve paralysis is not common
- Transverse: 20% of the cases SNHL & vertigo (Labyrinthine injury) Facial nerve paralysis is common
- Mixed: 10% of the cases worst prognosis

Manifestations	Diagnosis
<ul style="list-style-type: none"> <li>● Battle sign</li> <li>● TM perforation</li> <li>● Hemotympanum (on otoscopy) </li> <li>● CSF otorrhea or rhinorrhea</li> <li>● Laceration of external auditory canal</li> <li>● Ossicular disruption</li> <li>● SNHL</li> <li>● Vertigo </li> <li>● Facial nerve paralysis</li> <li>● Raccoon eyes</li> </ul>	<ul style="list-style-type: none"> <li>- The golden standard is High Resolution CT!</li> <li>- Brain injury, a fine cut temporal bone CT, bone window evaluates the extent of the fracture</li> <li>- Assess hearing by: tuning fork, audiometry</li> <li>● <b>How to differentiate between basal skull fracture and temporal bone fracture ?</b> <ul style="list-style-type: none"> <li>○ Signs and symptoms: if the patient complains of hearing loss or vertigo → temporal bone fracture</li> <li>○ CT scan</li> </ul> </li> </ul>

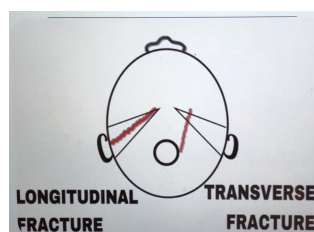
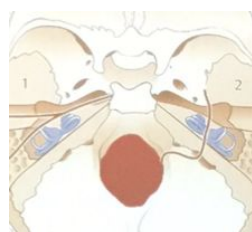
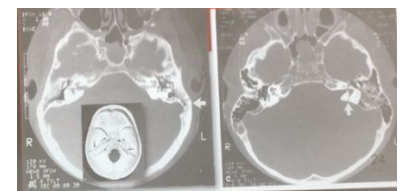
- KEY points to focus on in the management of temporal bone fracture (regardless of the type)
- Did the facial nerve get injured?

- Was it immediate or slow onset (because if immediate → INTERVENE, if slow → supportive management because the cause is mostly post traumatic edema)
- Is there a CSF leak? Close spontaneously with conservative management
  - bed rest +lumbar drain
  - more than 90% will resolve in 2 weeks
- Hearing ?
  - If conductive hearing loss → tympanoplasty or ossiculoplasty (according to injury)
  - If sensory neural → hearing aid or cochlear implantation (but usually not necessary because temporal bone fractures are usually unilateral, so the patient can depend on the other ear)
- Vertigo?
  - Spontaneously resolves on its own, but you can try vestibular suppressants for symptomatic relief



Transverse pyramidal fracture	Longitudinal fracture
Sensorineural deafness (due to 8th CN injury)	Conductive hearing loss: either due to ossicular damage or due to tympanic membrane perforation
Limited intervention, unless if there is facial trauma you can intervene	Passes through middle ear and external ear. Treatment with tympanoplasty or reconstruction of ossicle (according to the injured structured)
<ol style="list-style-type: none"> <li>1. Intact external auditory meatus</li> <li>2. intact tympanic membrane</li> <li>3. Vertigo</li> <li>4. Deafness</li> <li>5. Spontaneous nystagmus</li> <li>6. With or without hemotympanum or CSF</li> <li>7. 50% facial nerve paralysis</li> <li>8. Eustachian tube leaks CSF to the nasopharyngeal</li> </ol>	<ol style="list-style-type: none"> <li>9. Hemotympanum or CSF</li> <li>10. TM TEAR</li> <li>11. Annulus tympanicus</li> <li>12. bleeding to the external auditory meatus</li> <li>13. middle ear deafness</li> <li>14. 20% facial paralysis</li> </ol>

- Note that in this image, the longitudinal fracture will pass from the external ear canal to the middle ear then outward → thus the symptoms will be associated with middle ear structures (facial nerve injury, tympanic perforation, ossicular disruption, otorrhea)
- But in the transverse fracture → no structures are harmed (Intact tympanic membrane, external ear canal)
- What are the two structures that may be injured in transverse fracture?
  - Facial nerve and 8th CN (sensory neural loss)



1-Longitudinal 2-Transverse

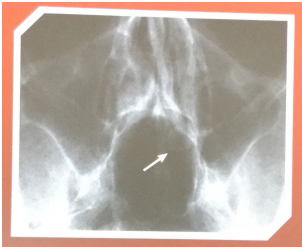
## 2. Foreign bodies

### Nasal Foreign Bodies

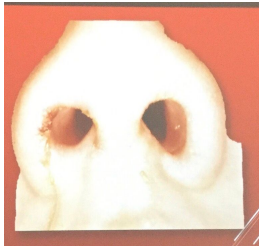- The most common site is between the inferior turbinate and the nasal septum.
- It differs from the ear in that the nose is part of the airway tract.
- Painful
- If the foreign body stays in the nose for a long time it will cause perforation. Or chemical burn of the skin around the nose – especially with leakage from ‘button batteries’
- Organic materials soon decompose and become infected, causing symptoms more quickly.

Clinical presentation:	Treatment
<ul style="list-style-type: none"> <li>- May be asymptomatic</li> <li>- Unilateral nasal obstruction</li> <li>- Bad odor blood stained unilateral nasal discharge</li> <li>- Unilateral nasal obstruction</li> <li>- Chronic purulent rhinitis or sinusitis</li> <li>- Unilateral fetid secretions</li> <li>- Rhinolith (calcium and magnesium salts)</li> </ul>	<ol style="list-style-type: none"> <li>1. The most important thing is to secure the airway.</li> <li>2. If the foreign body is located anteriorly and the child is cooperative we can remove it by forceps in the clinic.</li> <li>3. If it is <b>positioned posteriorly</b>, at the level of the nasopharynx; or if the child is struggling or uncooperative the foreign body could be pushed further back when attempting to remove it and might lead to further complications such as: foreign body inhalation or reaching the lungs. In these cases, take the patient to <b>the O.R</b> and remove it <b>under G.A.</b></li> </ol>

- common in children or adult (psychiatric patient) (papers is the commonest foreign body )
- If you leave the foreign body for long time there will be Rhinolith formation and the patient will have bleeding if it was removed under GA
- you will diagnose the patient without extensive examination!
- You will find unilateral offensive discharge + foul smell (diagnostic) + eczema around it
- Anterior rhinoscopy, nasal endoscopy, speculum of a fiberoptic auriscope
- We do radiology only when we suspect radiopaque foreign body
- No need for radiology if it is not radiopaque (you will not find anything)
- When you remove the foreign body make sure it doesn't go to lower respiratory tract for it will cause aspiration



- this foreign body is inside the posterior end of the nasal cavity.



- unilateral offensive, purulent nasal discharge in a child

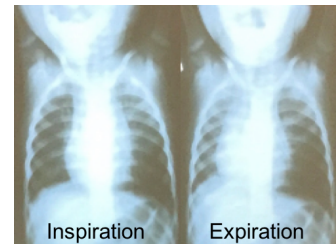


## Foreign Body in the Pharynx and Oropharynx

- Oropharyngeal foreign bodies:
  - larger ex bite of toys, flat bones, coins, buttons, large fish, bite of false teeth (site of impaction will be in the piriform sinus and the hypopharynx → endoscopy to remove it
  - Small pointed foreign body (mainly fish bones the commonest, bristles, needles, nails, bits of wood and glass) always get impacted in the tonsils, vallecula, lingula, base of the tongue and the lateral wall of the pharynx → remove it by forceps
- Usually sharp Ex. Fish Bone is the most common and might also be Dentures or vegetable matter
- Common sites: tonsils, base of tongue and vallecula
- Diagnosis is by physical examination
- Treatment is by removal
- Less common than in the esophagus
- All pharyngeal foreign bodies are medical emergencies that require airway protection.
- Patients with non-obstructing or partially obstructing foreign bodies in the throat often present with a history of choking, dysphagia, odynophagia, or dysphonia.
- Pharyngeal foreign bodies should also be suspected in patients with undiagnosed coughing, stridor, or hoarseness.
- Parents and caregivers of children with symptoms of partial airway obstruction should be asked whether choking and aspiration have occurred.
- Diagnosis is often complicated by delayed presentation.
- Case reports describe foreign bodies in the throat that were misdiagnosed and treated as croup. Thus, physicians must have a high degree of suspicion in patients with unexplained upper airway symptoms, especially in children who have a history of choking.

## Foreign body aspiration


- 3 thousand child die annually because of fb aspiration and its common in children under 12 years 75% under 3 years there is signs the patient has attack of coughing
- Foreign body aspiration is a life threatening childhood emergency
- History very important (may be impossible)
- Young child-75% <4years old
- Paroxysms of coughing unexplained fever or toxemia
- Its type and location in the laryngo tracheobronchial tree
- Inspiratory and expiratory chest films as well as fluoroscopy
- Bronchoscopy provide definitive diagnosis and treatment
- Complications:
  - Pneumonia and pulmonary abscess
  - Impaction in larynx(fatal) complete respiratory obstruction
- Once detected should be immediately removed
- Vegetable material: peanuts,seeds and popcorn(severe mucosal reaction)
- Inorganic material: coins, buttons, plastic toy
- Approximately 40%-50% will have decreased breath sounds or wheezing on the affected side
- Chest x-ray can be suggestive
- Atelectasis air trapping and pneumonitis
- One-third of chest x-ray will be negative in the early post-aspiration period.
- Coins are common in children
- Food impaction in adult (bones and chewed meet) common adult



## Foreign body in the larynx

Clinical picture	Treatment
<ul style="list-style-type: none"> <li>● Dyspnea</li> <li>● Cough</li> <li>● Hoarseness or aphonia                             <ul style="list-style-type: none"> <li>- Always suspect the sudden onset of stridor in a previously healthy child is due to a foreign body until proven otherwise.</li> <li>- Dangerous if the foreign body is big.</li> </ul> </li> </ul>	<ul style="list-style-type: none"> <li>- Heimlich Maneuver</li> <li>- Slapping the back with the patient's head down</li> <li>- Manual removal</li> <li>- Removal by laryngoscopy</li> <li>- Tracheostomy or laryngostomy (cricothyrotomy)</li> </ul>

## Foreign Body in the Esophagus

<ul style="list-style-type: none"> <li>- Most of the foreign bodies are found at the level of the cricopharyngeus muscle. Aorta/left mainstem bronchus, Gastroesophageal junction</li> <li>- Coins – 75% <b>children</b>, meat, dentures, disc batteries etc.</li> <li>- <b>More common than the pharynx</b></li> <li>- X ray showing coin at the cricopharyngeus</li> </ul>		
<ul style="list-style-type: none"> <li>● <b>Children</b> <ul style="list-style-type: none"> <li>○ Symptoms often subtle</li> <li>○ Drooling, vomiting, sore throat, odynophagia or airway symptoms</li> </ul> </li> <li>● The ingestion may not be witnessed</li> </ul>	<ul style="list-style-type: none"> <li>● <b>Adult</b> <ul style="list-style-type: none"> <li>○ Diagnosis straightforward</li> <li>○ Associated esophageal pathology</li> <li>○ Fishbone,meat,denture</li> </ul> </li> </ul>	
Diagnosis	Treatment	
<ul style="list-style-type: none"> <li>- Symptoms: (Dysphagia, odynophagia, choking &amp; cough)</li> <li>- Physical exam: (Drooling, refuses oral intake).</li> <li>- Radiology <b>not recommended except if the FB was radiopaque</b></li> <li>- Esophagoscopy <b>it will show you the site of obstruction and also the site of impaction if there is tumor be aware! Aspiration risk if total obstruction</b></li> <li>- You can diagnose with hx and barium swallow esophagram <b>it will show you the site of obstruction and also if there is impaction if there is a mass or tumor you can demonstrate the pathology of any mass)</b></li> </ul>	<ul style="list-style-type: none"> <li>- Removal via esophagoscopy</li> <li>- Disc batteries and sharp objects removal are emergencies because of the risk of perforation</li> </ul>	

## Esophageal perforation:

\*not mentioned by the Dr (team 432)

- 50% mortality rate
- The most common cause of an esophageal perforation is injury during placement of a nasogastric tube or a medical procedure such as esophagoscopy.
- A tumor, gastric reflux with ulceration, violent vomiting, or swallowing a foreign object or caustic chemicals or dentures.
- Injuries that hit the esophagus area (blunt trauma) and injury to the esophagus during an operation on another organ near the esophagus.
- Rare cases have also been associated with childbirth, defecation, seizures, heavy lifting, and forceful swallowing.

### Signs and Symptoms

- The main symptom is pain, but the condition can progress to shock even death – if untreated.
- Signs include fast breathing, rapid heart rate, low blood pressure, and fever.
- Patient with a perforation in the uppermost portion of the esophagus (cervical part) may complain of neck pain or stiffness and air bubbles underneath the skin.
- Patients with a perforation in the middle portion or lowermost portion of the esophagus may have difficulty swallowing, chest pain, and difficulty in breathing.

### Investigations

- A chest x-ray may reveal that there is air in the soft tissues of the chest, fluid that has leaked from the space around the lungs, or a lung collapse. Do before CT
- A chest CT scan may show an abscess in the chest or esophageal cancer. X-rays taken after you drink a non-harmful dye can help pinpoint the location of the perforation. Definitive

### Treatment could be either:

#### A. Initial Phase:

- It includes diagnostic studies to determine the location and cause. Administer IV fluids and IV Antibiotics to prevent or treat the infection. Fluids that have collected around the lungs may be treated by a chest tube to drain it away.

#### B. Definitive Phase:

- It is to repair perforation. Early surgery is appropriate for almost all patients. Every effort should be done to have surgery within 24 hours of perforation.
- Repair the perforation, for some patients with perforation in the uppermost part of the esophagus (neck region), the perforation may heal by itself if the patient does not eat or drink for a period of time. In this case nutrition must be provided by another source, such as a stomach feeding tube.
  - For perforation in the mid-portion and lower-most portions of the esophagus, an operation is usually required for repair. Depending on the size and location of the perforation, the leak may be treated by simple repair or by removal of the esophagus.

### Complications

- 50% of the patients deteriorate.
- Possible complications include:
  - Permanent damage to the esophagus (narrowing or stricture).
  - Abscess formation in and around the esophagus, lungs and abdomen.
  - Infection of the lungs.

## Foreign bodies in the tracheobronchial tree

- It is more serious than ingestion.
- Sometimes parents do not notice the child eating something that caused him/her to choke, or the patients were not around when it happened. Example: popcorn.

### History

- Parental suspicion in pediatrics
- Choking
- Gagging
- Wheezing: if prolonged in the chest, might be mistaken with bronchial asthma.
- Hoarseness
- Dysphonia.
- Pneumonia, foreign body can lead to infection.
- A positive history must never be ignored, while a negative history may be misleading.
- The commonest site of ingestion injury is in the **cricopharyngeal fossa**
- Because the cricopharyngeal sphincter has a protective role. Ingestion injury is common among neurological disease affecting swallowing. It is not serious unless the object is very large.

### Clinical presentation

- Choking, coughing, gagging & cyanosis:
- Caused by laryngeal reflexes.
- Asymptomatic phase: due to fatigue of cough reflex
- Wheeze, intractable cough, persistent or recurrent chest infection: due to emphysema, atelectasis or infection

### Physical exam and investigations:

- Larynx/cervical trachea: Inspiratory or biphasic stridor.
- Intrathoracic trachea: Prolonged expiratory wheeze.
- Bronchi: Unequal breath sounds.
- Location: Mostly in the right side ( 60%)
- Diagnostic triad - <50%
  - 1. Unilateral wheeze
  - 2. Cough
  - 3. Ipsilaterally diminished breath sounds.
- Assess nares/choanae.
- Assess adenoid and lingual tonsil.
- Assess TVC mobility.
- Assess laryngeal structures.

### Investigation

- Fiberoptic laryngoscopy (golden standard)
- Bronchoscopy if laryngoscopy is not available.
- Proper equipment.
- Plain films: Not all foreign bodies are radio-opaque therefore will not be visualized. In these cases, we go by the history even in the absence of +ve radiographs. Radiolucent bodies such as food like popcorn or vegetables
- Chest and airway AP and lat.
- Expiratory films.
- Fluoroscopy if foreign body stayed for long and you are suspecting an injury.
- Barium swallows.
- CT, MRI, Angiography.
- Note: inhalation injury is more serious than ingestion, but ingestion is more common.

### Treatment

- To be initiated on clinical suspicion
- Bronchoscopy: in most cases
- Bronchotomy
- Pulmonary resection

## Foreign bodies in the ear

- It's a common problem especially in toddlers.
- The vast majority of the items are lodged in the ear canal.
- Most cases of the foreign bodies in the ear are not serious.
- Common objects found in the ears include: Food material, beads, toys, and insects.
- Children may deny the history of foreign body insertion
- Diagnosed using careful otoscopy and a careful history (the object inserted and the length of timing is important)
- After examining the ear, you must examine the nose (if a child inserts a foreign body in his ears, he is likely to also insert objects in the nose)
- Adults may have foreign bodies:
  - Psychiatric patients
  - Cotton bud is accidentally lodged while cleaning the ear
- Note: Many patients use their keys to clean their ears → mild trauma to external ear → this could be dangerous especially if the patient is diabetic (why?) malignant otitis externa
- What is the causative organism ? Pseudomonas aureginosa
- Foreign body removal is preferably done under GA (safer)
- Common site of foreign bodies in the ear:
  - Narrowest area: isthmus or lateral to the isthmus
- Always check both ears
- Check the nose!

## Signs and symptoms

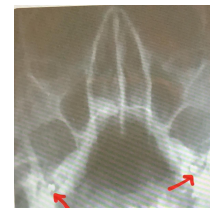- If the foreign body in the ear goes undetected it can cause an infection in the ear, the patient will present with:
  - **Discharge.** (Foul discharge if infected, swelling, erythema)
  - **Pain.**
  - **Decrease in hearing.** (rare, occurs if tympanic membrane is affected, or if the FB is in insect "scratching and irritating membrane")
  - **Bleeding** is also common but is not urgent: does not require immediate intervention.
- A live insect in the ear. The insect's **movement can cause a buzzing the ear.**

## Treatment

- Removal of the foreign body is done in the clinic, if uncooperative child we remove it microscopically under minor sedation; it is usually not urgent.
- Urgent removal is indicated if the object is **causing significant pain or discomfort**. Also if it was a food or a plant material such as beans **because they will swell** when they are moistened and if swollen will affect the external canal and might lead to otitis externa. If it enlarges the physician will no longer be able to remove it. Therefore, we remove it under **GA in children and give antibiotics**.
- **Remove BUTTON BATTERIES immediately** as they can decompose within 25 hours in the body, allowing the chemicals to leak out and cause chemical burns. Urgent removal is required and it cause extensive granulation tissue.
- Small insects such as ants are removed by simply putting baby oil or water (contraindicated in tympanic membrane is perforated). Ticks: put some local anesthetic, they will release themselves and be easily removed.
- **Most of the foreign body cases in the ear are asymptomatic**
- Requirements of foreign body removal
  - Skill
  - Instrumentation
  - adequate lighting
  - GA is safer( to avoid trauma to external ear and middle ear



- Repetitive attempts to remove the foreign body may cause trauma, so caution is necessary
- The only time you will have a middle ear FB with an intact tympanic membrane: if you inserted a grommet previously to drain an effusion but the grommet moved inside the middle ear instead of outside.
  - Treatment: removal of grommet by exploratory tympanotomy
- There are 2 types of VENTILATION tubes:
  - Grommet
  - T- tube (but its downside is that it leaves a permanent perforation in the tympanic membrane after removal)
- Xray: bilateral grommet insertion



## Methods of FB removal

- **Crocodile forceps:** removes cotton wool, paper, and foam sponges, not smooth round object (because the crocodile forceps cannot grip it firmly, FB may go deeper into the ear canal causing damage)
- **Blunt hook:** the only way to remove **smooth, round objects**
- **Suctioning apparatus:** removes cosmetic beads
- **Syringe:** in non vegetable FB (Syringe cannot adequately remove swollen vegetables in the ear such as peas ..etc)
- How to remove insect FB? Kill it first by alcohol then suction
- Contraindications of using a syringe to remove FB
  - perforated tympanic membrane
  - history of surgery to the tympanic membrane
  - vegetable FB

