



## Orientation, History Taking, Examination

[ **Color index:** **Important** | **Notes** | Extra ] [EDITING FILE](#)

### Objectives of the course:

- To know the basic ophthalmic anatomy and physiology.
- To recognize assessment and management of common ophthalmic diseases.
- To know how to handle common ophthalmic emergencies.
- To handle simple ophthalmic diagnostic instruments.
- To be aware of common ophthalmic operations.

**Done by:** Reema Allhidan, Kayan Kaaki.

**Edited & revised by:** Lamyia Alsaghan, Munerah alOmari.

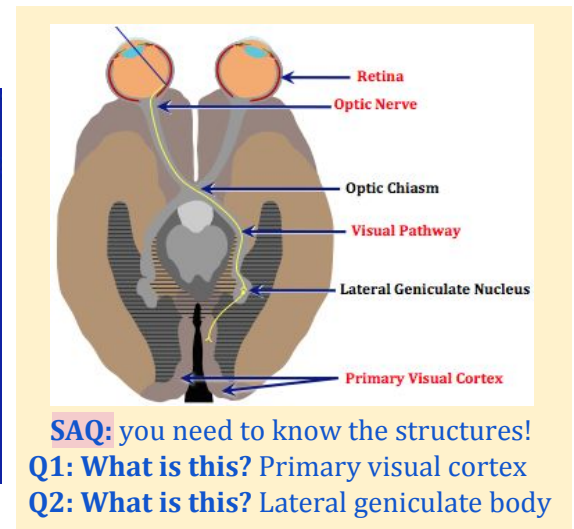
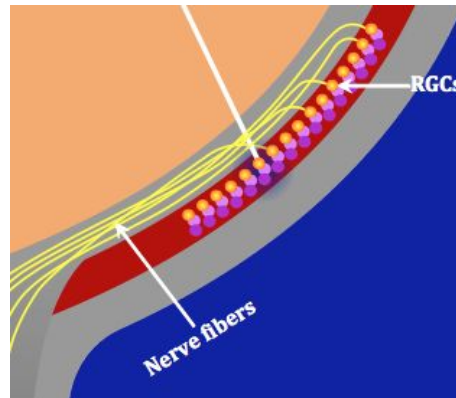
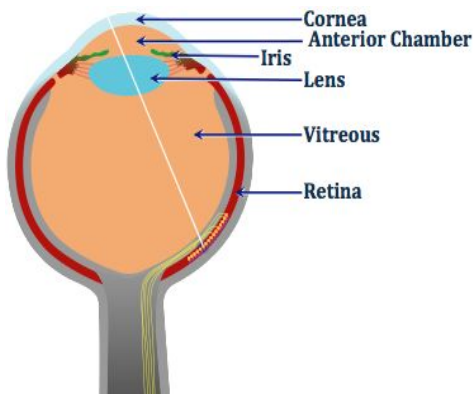
**Resources:** Slides + Notes + 434 / 435 Team + Lecture Notes Ophthalmology.

# The Visual Pathway & Importance of the Eye

## ● Visual Pathway:

- **Brief idea of the mechanism of vision:** Light → cornea → anterior chamber → pupil → lens → vitreous → retina: stimulation of photoreceptors → bipolar cell (1<sup>st</sup> order neuron) → **retinal ganglion cells (2<sup>nd</sup> order neuron)** → decussation of fibers in the chiasm → lateral geniculate body (3<sup>rd</sup> order neuron nucleus) → perception of light in visual cortex (3<sup>rd</sup> order neuron axons)

1	2	3
<p>- Light enters the eye via the refractive media, namely the cornea, anterior chamber, lens, and vitreous, and stimulates the retina posteriorly.</p> <p>- The <b>start of the visual pathway: light striking the eye.</b></p> <p>- You should have a <b>clear media</b> to have a good image. What is meant by "clear"?</p> <p>For example some patients have corneal scars "سحابة على القرنية" or vitreous hemorrhage he will not see.</p>	<p>Light stimulates the photoreceptors, ie., the rods and cones. Through a series of other retinal nerve cells, the end result is that the RGC is stimulated. The RGC sends its axon, or fiber, in the nerve fiber layer to the optic disc and then down the optic nerve.</p> <p><b>*Phototransduction:</b> by photoreceptors (rods and cones)</p> <p><b>*Image processing:</b> by horizontal, bipolar, amacrine and RGCs</p> <p><b>*Output to optic nerve:</b> via RGCs and nerve fiber layer.</p>	<p>From the optic nerve, about half of the fibers cross over at the chiasm to the opposite optic tract, and the other half remain on the same side. The fibers in the optic tract synapse in the lateral geniculate nucleus of the thalamus. Neurons in the lateral geniculate nucleus then project to the occipital lobe, to the primary visual cortex. From there, there is further processing with projections to other cells in the visual cortex and elsewhere, resulting in conscious visual perception. Now that we know how visual information is normally transmitted to the brain, what happens with a disease like glaucoma.</p>



## ● Importance of eyes:

- Diagnostically and functionally, it is the most important square inch of the body surface.
- The eye is so intimately connected with the rest of the body that it reveals enormous amount of general information: **vascular and neurological connections.**
- Eye is the only part of the body where blood vessels and central nervous system tissues can be viewed directly.
- 90% of our information reaches our brain via sight.
- Unfortunately, of all the parts of the body, the eye is the most vulnerable to minor injury.

Extra from 435 team

- In order to see, you need **clear media**, but if it's not clear it called **media opacity** (so in **OSCE** the absence of **red reflex** in ophthalmoscopic exam is called **media opacity**) **Media opacity** caused by (hyphema , scar , cataract , vitreous haemorrhage , retinal detachment).

# Pathology of the Eye

## ● Neurological connections:

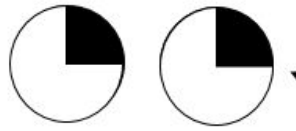
- The 12 **cranial nerves** provide us with a large part of our information about the brain. Of these, the eye examination evaluates CN II, III, IV, V, VI, VII, VIII (7 CNS). [you'll have a lecture about it!](#)
- Provides information about the autonomic pathways. (Sympathetic/parasympathetic).
- **The best known connection between the brain and the eye is the optic nerve.**
- Visual pathways, which extends from front to back across the brain can be studied easily and safely using perimeter<sup>1</sup>. It can differentiate accurately between lesions of the **temporal, parietal, and occipital lobes.**

### SAQ/OSCE: lesions in:

#### Temporal lobe:

Pie in the sky (upper quadrantic hemianopia)

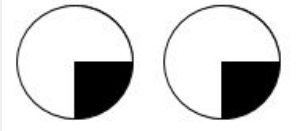
Lesion at **temporal lower** optic radiation:  
Contralateral homonymous **superior quadrantanopia**



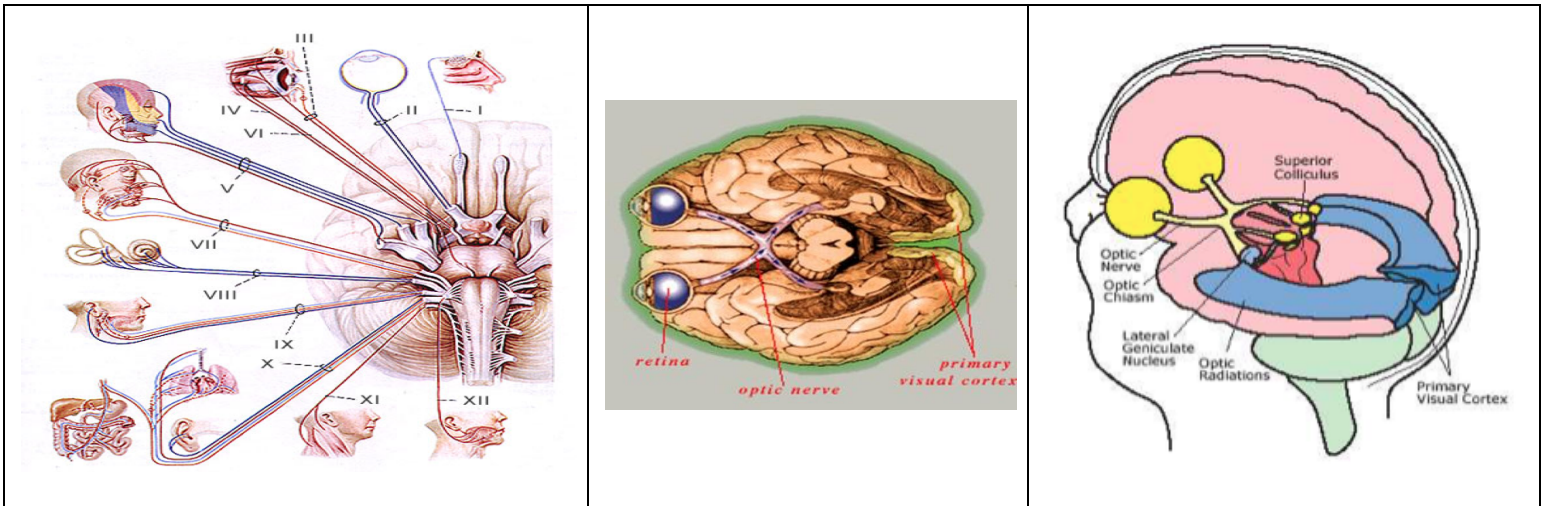
#### Parietal lobe:

Pie on the floor (lower quadrantic hemianopia)

Lesion at **parietal upper** optic radiation:  
Contralateral homonymous **inferior quadrantanopia**



- **Optic nerve** has important clinical relationships to the pituitary gland, the middle ventricles, the venous sinuses, the meningeal and Bony structures of base of the skull.

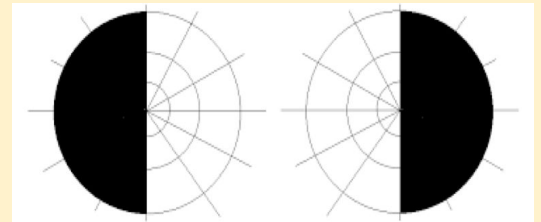


### SAQ/OSCE:

**Q1: What is this?** Visual field defect, **bitemporal hemianopia**

**Q2: What is the reason, give one example?** **pituitary adenoma**

**Explanation:** "Nasal fibers decussate at the optic chiasm while temporal fibers stay on the same side. When this discussion is touched by the pituitary gland due to an enlargement because of a tumor it will lead to bitemporal hemianopia"

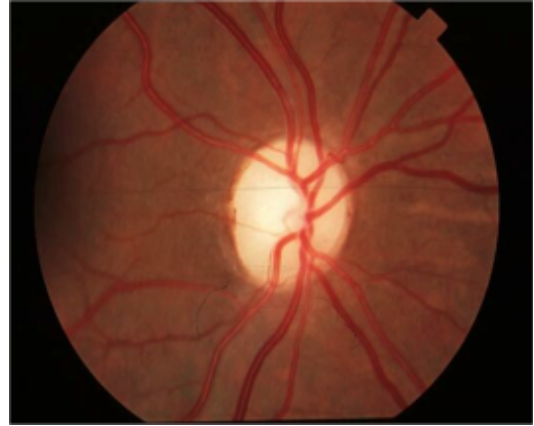
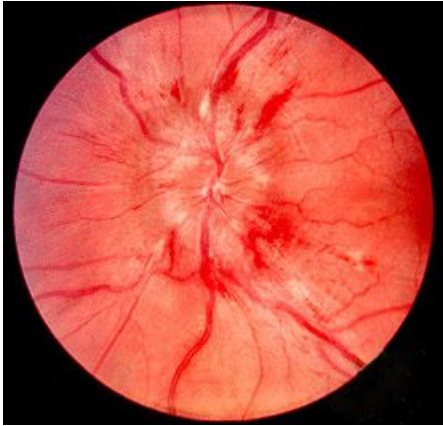

<sup>1</sup> Perimetry is the systematic measurement of visual field function.

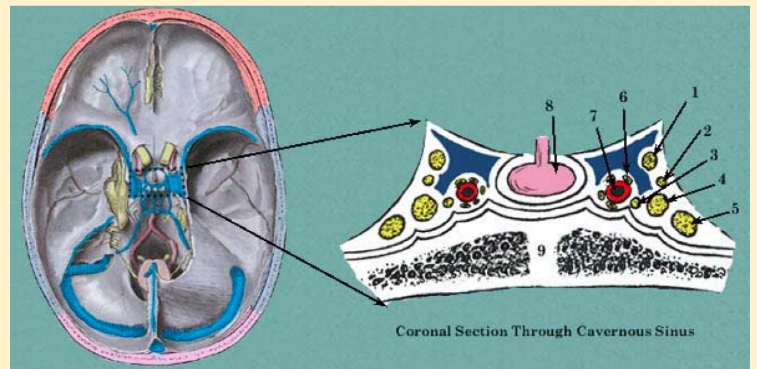
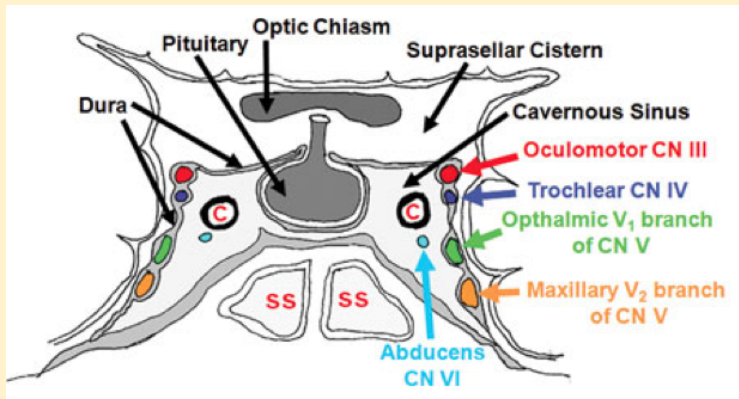


Optic disc edema	Optic atrophy
Optic nerve has the diagnostically useful capability of <b>congested veins + disc swelling and enlargement away from the retina</b> with $\uparrow$ ICP (papilledema)	Optic nerve could be visibly <b>pale</b> بهتان when its nerve fibers damaged at any point from Retina $\rightarrow$ LGB.

**You have to differentiate between the two pictures!**



- Study of CN III, IV, V, VI can evaluate the brain stem, cavernous sinus, apex of orbit.



“هذي الصور لازم تحفظوها صم بكل التفاصيل” SAQ

**Question: What are the structures in the cavernous sinus?**

**- In the wall: THREE nerves**

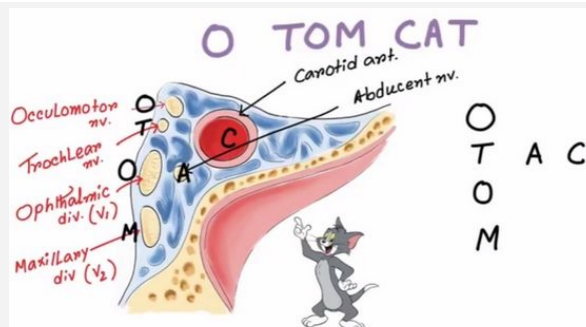
- Superior & inferior divisions of CN III (Oculomotor nerve)
- CN IV (Trochlear nerve)
- Ophthalmic and maxillary divisions of CN V (Trigeminal nerve)

**- Inside the cavernous sinus: ONE artery + ONE nerve**

- Carotid artery.
- CN VI (Abducens nerve)

“هذي أهميتها لما يجيك سؤال عن cavernous sinus thrombosis”

Cavernous Sinus Components  
Mnemonic:  
**O TOM CAT**



- Unilateral dilated pupil after head injury can occur due to pressure on pupil constrictor fibers of CN III.
- CN VI involved in mastoid infection (petrous ridge)
- CN VII involved in Parotid gland, Inner ear disease
- CN VIII involved in nystagmus.

**Very important: third cranial nerve, oculomotor nerve:**

Fibers	Innervation	Function
<b>Somatic motor</b> (general somatic efferent)	Supplies four of the six extraocular muscles of the eye <b>and</b> the levator palpebrae superioris muscle of the upper eyelid.	controlling the muscles responsible for the precise movement of the eyes for visual tracking or fixation on an object.
<b>Visceral motor</b> (general visceral efferent)	Parasympathetic innervation of the constrictor pupillae and ciliary muscles.	Involved in the pupillary light and accommodation reflexes.

- Supplies all the muscles of the eye **EXCEPT** lateral rectus and superior oblique.
- **Paralysis** will lead to: ptosis and squint (eye deviated out and little down). Pupil might be affected.
- **It has two fibers.**
  - 1) Inside the nerve: deep fibers responsible for the muscles.
  - 2) Surface of the nerve (periphery): superficial parasympathetic fibers.
- **Muscles only paralysis** is always due to medical reasons. Example: If CN III is affected due to ischemia because of DM or HTN, the fibers supplying the muscles will be affected.
- If there is a tumor compressing the periphery it will affect peripheral and central part of the nerve. There will be **muscles paralysis & pupil dilation** (loss of parasympathetic activity → unopposed sympathetic). It is an emergency situation. (surgical)
- **The difference between medical & surgical third nerve palsy is pupil affection.**

<p><b>Figure III-13</b> Appearance of the eyes in right third nerve palsy. The right side of Werner's face illustrates: a wrinkled brow due to the inability to raise the eyelid; ptosis of his right eye lid due to the inactivation of the levator palpebrae superioris muscle; dilation of his right pupil due to the decreased tone of the constrictor pupillae muscle; and downward and outward movement of his right eye due to the unopposed action of the right superior oblique and lateral rectus muscles.</p> <p><small>From Cranial Nerves, 3rd Ed. ©2010 Wolters-Kluwer, Stewart, Abington, Spacing, PMPH-USA</small></p>		

- **Focal brain lesion like:** vascular occlusions, hemorrhage, neoplasm.
- **Diffuse brain lesion like:** Infections, demyelinating disorders (nerve damage).



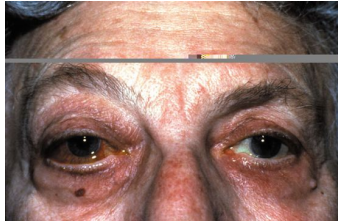

Extra from 435 team

- Cranial nerve: CN II(Optic): Visual Acuity, CN III(Oculomotor): Eye Movement + Pupil Examination, CN IV(Trochlear): Superior oblique Muscle, CN V(Trigeminal): Sensation, CN VI(Abducent): Lateral Rectus muscle, CN VII(Facial): Facial Nerve paralysis (they can not close their eyes), CN VIII(Vestibulo-cochlear): Nystagmus.
- Remember: sympathetic: dilatation of the pupil/Parasympathetic: constrict the pupil.
- **Binasal hemianopia happens if there is compression in the carotid due to pressure on the temporal fiber.**
- Optic disc edema (**unclear disc margin** best answer will be disc edema in OSCE, rather than Papilledema) to detect increase in ICP help to diagnose **brain tumor**.
- Brain Herniation, Hemorrhage, Aneurysm of posterior communicating artery can compress CN III.
- Mandibular nerve or third division of trigeminal nerve pass through foramen ovale.
- Phacomorphic glaucoma (cataract induced glaucoma by increase lens size that lead to increased IOP) > so severe pain.
- Commonest cause of abducens nerve palsy? TRAUMA. Why? because it has a very long course and each course is perpendicular to each other
- **QUESTION:** investigation if you have a patient with 3rd nerve palsy with dilated pupil? Order a CT ANGIO or MRA (**angio**)
- How do we know if CN IV is involved in addition to CN III ? Patient will not be able to **look down** (damaged CN III) and Eyes will **not intort** (damaged CN IV).

● **Vascular connections:**

- **Venous flow disorder:**

- **Cavernous sinus thrombosis. (occlusion).** Cavernous sinus is the venous drainage of the eye. The eye will be **bulging, injected, congested** sometimes with paralysis because the nerves are in the cavernous sinus
- **Carotid – cavernous fistula (orbital congestion)** eye will be **bulging, injected, congested**, same as cavernous sinus thrombosis. The **difference** is that the **eye is pulsating (bruit)**
- Arterial emboli can reach the retina from carotid artery, heart valves, subacute endocarditis and traumatic bone fracture.
- **Neoplasm.**

<p>Cavernous sinus thrombosis (CST) OR Carotid-cavernous fistula (CCF)  <b>Difference:</b> pulsation of the eye with CCF</p>	<p style="text-align: center;"><b>SAQ</b></p> <div style="display: flex; align-items: center;"> <div style="margin-right: 10px;"> <p><b>Cherry-red spot</b></p>  </div>  </div> <p style="text-align: center;"><b>Q: Diagnosis?</b> Central Retinal Artery Occlusion  <b>Q: What do you see?</b> Pale retina in the center + cherry-red spot          “the fovea should not be red like this”</p>
<div style="display: flex;">   </div>	

- **Specific disease of the vessels like:**

- Polyarteritis nodosa (PAN)
- Hypertension
- **Temporal arteritis**, “very important and you have to know it in details”
  - Also known as **Giant cell arteritis (GCA)**: it affects the ophthalmic artery not retinal.
  - Autoimmune vasculitis that occurs in old age (>60 years, other sources: >50), common in females.
  - **Signs & symptoms:**
    - \* **Visual symptoms:** irreversible and usually painless<sup>2</sup> **sudden loss of vision**, diplopia.
    - \* **Polymyalgia rheumatica symptoms:** headache, pain in the shoulders and hips, malaise
    - \* **Others:** jaw and tongue **claudications** (pain on chewing), **pulsating** pulseless **superficial temporal arteries**, scalp/temporal tenderness (eg. on combing),
    - \* **Fever and constitutional symptoms.**
  - **Diagnosis:** elevated erythrocyte sedimentation rate (ESR) & C-reactive protein (CRP), temporal artery biopsy. **If you miss the diagnosis the patient will have loss of vision in the other eye.**
  - **Management:** IV Steroids to protect the other eye. Steroids will not reverse the visual loss but can prevent the fellow eye being affected. Unfortunately, there is no treatment for GCA.

Extra from 435 team

- Carotid-cavernous fistula (orbital congestion) (it has the same clinical presentation (proptotic, retinal edema) of cavernous sinus except that it has increased IOP, and Thrill+pulsating **eyes (Bruit)** orbital congestion.
- Bilateral carotid artery aneurysm Binasal Hemianopia.
- **Came in the exam:** central retinal artery occlusion/ history: of multiple bone fracture, what is the diagnosis? Retinal central artery fat embolism.
- Case: a 60 year old pt w/ heart disease and using penicillin injections (meaning that he has bacterial endocarditis and might have a possibility of embolism manifestations leading to central retinal artery occlusion)
- **Best initial investigation in temporal arteritis is ESR, followed by C-reactive protein, then Biopsy (a negative biopsy does not rule out the dx due to the focal and segmental nature of the infiltrates).**
- **When a patient complain of any changes in vision, rule out DM first!**

<sup>2</sup> It is certainly **painless** but some references might say **painful** because it might be associated with headache and jaw claudications.



- **Hematological disorders**

- All types can manifest in the fundus.

Extra from 435 team

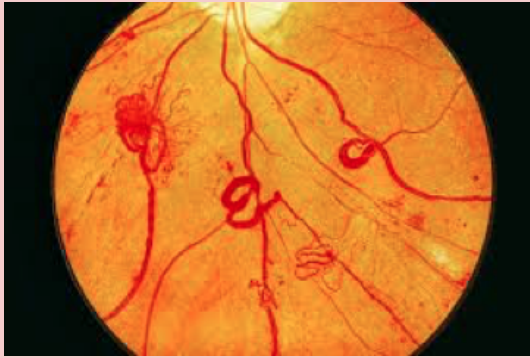- Anemia, leukemia, AIDS (diagnosed by cotton wool spots in the retina, ischemia of the nerve fiber in the retina)

- **Metabolic disorders**

- Almost all metabolic disorders can affect the eye:

- **Diabetes Mellitus:** Diabetic Retinopathy (proliferative & non-proliferative), Cataract, Refractive Error, Ophthalmoplegia. The commonest cause of third and fourth nerve palsy is DM.

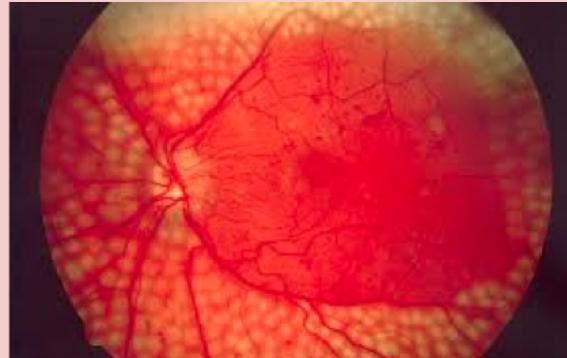
Exam: "الصورة دي مهمة قدا"



**Proliferative Diabetic Retinopathy (PDR)**

New vessels in the retina due to diabetes. The vessels are fragile and can bleed. If it bleeds it will lead to vitreous hemorrhage and retinal detachment.

(New dilated tortuous proliferative vessel in the retina)



**Pan-retinal Photocoagulation (PRP)**

Laser treatment of the other picture.

Early detection and treatment will change the ischemic retina to anoxic retina. New vessels will be destroyed and central vision will be saved. There will be visual field defect, but the macula will be saved and the vision will be maintained.

(Retinal scars)

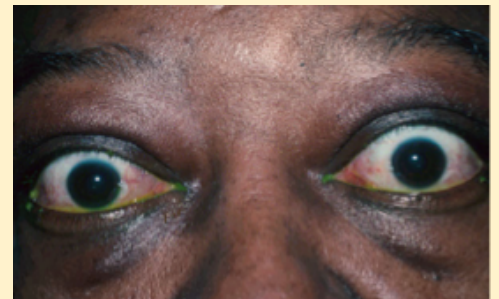- **HYP**oparathyroidism: Cataract "انتبهوا مش هايبر"
- **Wilson's disease.** copper abnormality, deficiency of  $\alpha$ -ceruloplasmin. Causes cataract and corneal changes (Kayser-Fleischer, corneal ring: a brownish-yellow ring around the cornea of the eye)
- **Thyroid eye disease:**
  - Exophthalmos, Lid retraction (upper part of sclera is seen)
  - The **commonest** cause of **unilateral & bilateral proptosis** is thyrotoxicosis.

"بعض الاقزام يجي يقولك unilateral proptosis بتقولوا خلا ده مش thyroid، لأ! thyroid"

Exam

**Manifestation of exophthalmos**

"أحياناً في السيناريو questions يجي يقولك the upper part of the sclera is seen  
 يعني ايه؟ طبعا normally أي حد يبص في حد عندكو تلاقوا الـ lid عندكو مغطي الـ upper part of the cornea لو نزل شويه اسمها ptosis لو طلع شويه اسمها lid retraction  
 or exophthalmos، فالتعبير في السيناريو بيختلف محد حيجي يقولك lid retraction محد حيقولك lid lag sign لأ! حيقولك wide part of the sclera is seen  
 طول أن ده thyrotoxicosis"



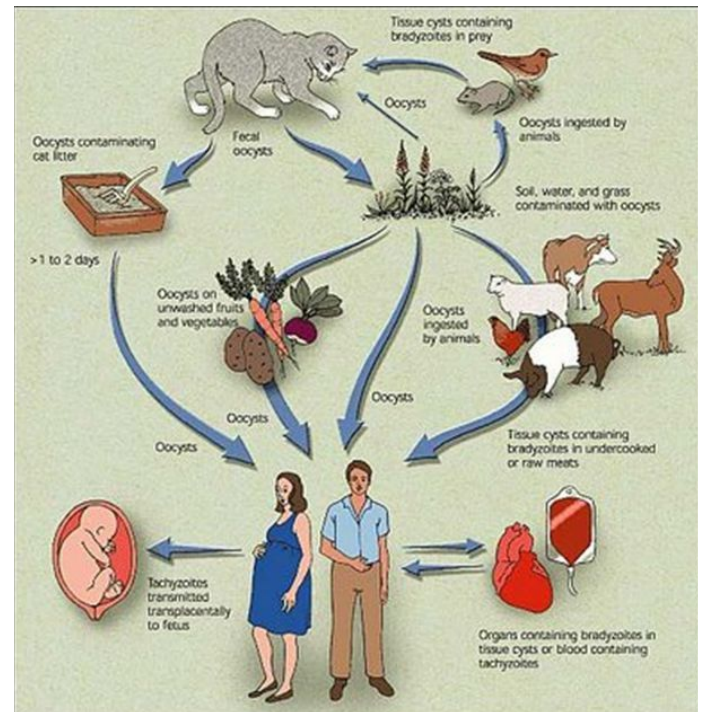
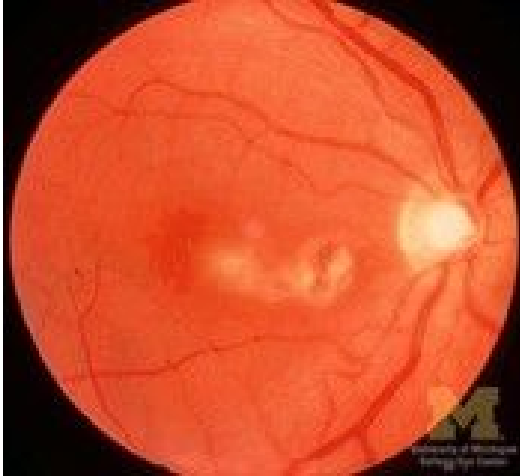
Extra from 435 team

- Thyroid eye disease, also known as **infiltrative ophthalmopathy** "Graves ophthalmopathy". Since they have **increased IOP** we perform visual field exam.

- **Infections**

- Syphilis, Toxoplasmosis, Rubella. Syphilis and Rubella also can cause retinitis (inflammation of the retina)

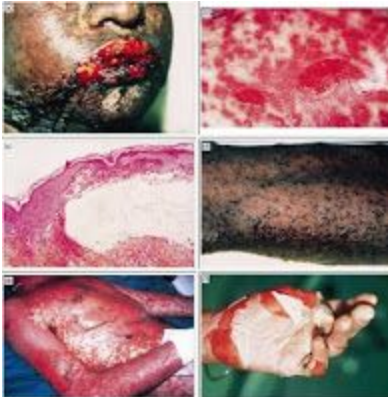### Toxoplasma infection



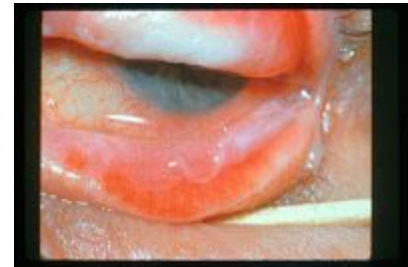- **Mucocutaneous disorders**

- Steven-Johnson Syndrome (SJS), Pemphigus.

#### Mucosal Lesions In Stevens-Johnson Syndrome



#### Eye Lesions of Stevens-Johnson Syndrome



- **Elastic tissue**

- Pseudoxanthoma elasticum: degeneration of the retina in which the patient can develop neovascularization.

- **Chromosomal abnormalities**

- Trisomy: 13, 15, 21.

- **Eye poisoning** the eye is a delicate indicator of poisoning

- **Morphine addict:** lead to meiotic pupil.

Constricted pinpoint pupil = morphine overdose or pontine hemorrhage

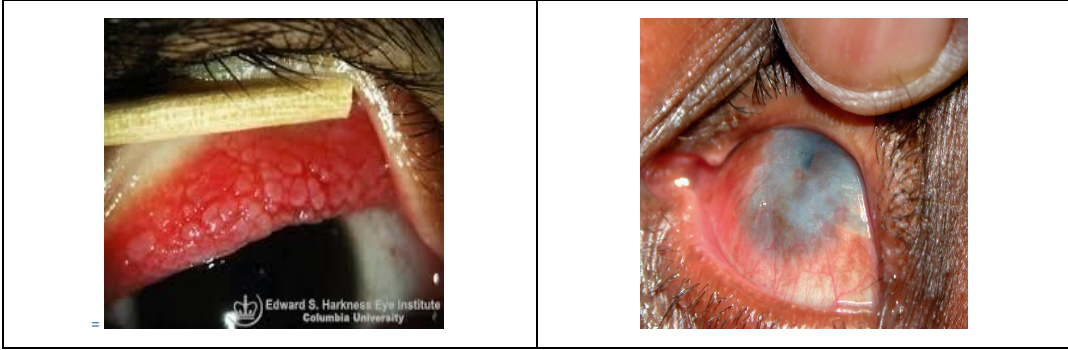
They have the same presentation the only difference is **hyperpyrexia with pontine hemorrhage.**

- Lead poisoning, vitamin A (example for acne treatment) intoxication lead to papilledema.

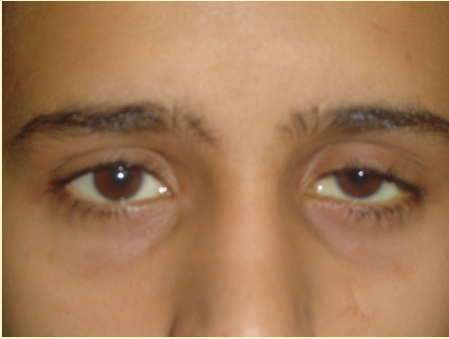

● Allergy

- **Vernal keratoconjunctivitis (VKC)**: causes cobblestone papillae. حساسية الرمى الربيعى  
 "مشهورة فى نجران وجيزان، و it is a dusty area، most of the children have allergy و spring أو vernal catarrh اسمها فتجيلهم حاقة اسمها  
 catarrh، للأسف معظمهم بيروحوا يشتروا steroids من نفسهم، فيجيلهم حاقة اسمها، cataract و glaucoma. هذا الموضوع مهم جداً و لازم تذاكروا  
 فى الـ drugs الـ steroids و الـ complications، طبعاً سواء كان drops أو tablet أو injections أو inhaler "even"



**Exam:** important



An example of steroids overuse with VKC

**Q1: What do you see?**

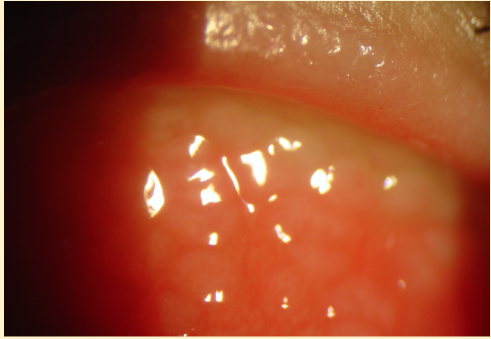
Unilateral ptosis in left eye.

**Q2: Cause?**

Mechanical ptosis (not paralytic) due to cobblestone papillae.

**Q3: Spot diagnosis?**

**Vernal keratoconjunctivitis (VKC)**  
 or vernal catarrh or spring catarrh.



**Q1: Name of the lesion?**  
 cobblestone papillae.

**Q2: Type of glaucoma may develop and why?**  
 Steroid- induced glaucoma (Secondary glaucoma).  
 Chronic use of topical steroids lead to increased IOP

Extra from 435 team

- We start the treatment of VKC with Antihistamine and cold water and leave steroid as the last resort although it is the best treatment for them but can lead to glaucoma and cataract.

# Ophthalmic Evaluation

---

## ● Objectives of the comprehensive ophthalmic evaluation

- Obtain an ocular and systemic history.
- Determine the optical and health status of the eye and visual system.
- Identify risk factors for ocular and systemic disease.
- Detect and diagnose ocular diseases.
- Establish and document the presence or absence of ocular symptoms and signs of systemic disease.
- Discuss the nature of the findings and the implications with the patient.
- Initiate an appropriate response. e.g. further diagnostic tests, treatment, or referral.

## History Taking

---

### - Ocular and systemic history.

- It is a gathering information process from the patient guided by an educated and active mind.
- It is a selective guided and progressive elicitation and recognition of significant information.
- History by skilled person can arrive at the proper diagnosis in 90% of patients.
- It gives vital guidance for: physical examination, laboratory work and therapy.
- Failure to take history can lead to missing vision or life threatening conditions.

## ● Chief complaint "Patient's own words"

- "She cannot see with the right eye", you should not come to conclusion that her problem is nearsightedness and write down "Myopia of right eye (RE)".
- The patient needs will not be satisfied until he/she has received an acceptable explanation of the meaning of the chief complaint and its proper management.

## ● History of presenting illness

- Detailed description of the chief complaint to understand the symptoms and course of the disorder.
- Listen and question and then write down in orderly sequence that make sense to you.

### - Questions to ask:



- **The time sequence when, How fast, what order did events occur?**
- **Frequency, intermittency.**
- **Location, Laterality.**
- **Severity.**
- **Associated symptoms.**
- **Documentation (old records, photo) e.g ptosis, proptosis, VII N palsy.**

### - Examples:

- Gradual painless decrease vision both eyes for 1 year.
  - Sudden painless decrease vision of right eye for 10 minutes.
  - "cannot see with my right eye"!!
    - Only distance vision blurred?
    - Blind spot is present in the center of visual field?
    - Right side of visual field of the right eye lost?
    - Right visual field of both eyes lost?
    - A diffuse haze obscures the entire field of right eye?
  - Each of these has different diagnostic implication.
- Most patients. have difficulty providing precise and concise description

Disturbances of vision	Ocular pain or discomfort
<ul style="list-style-type: none"> <li>- Blurred or decreased central vision.</li> <li>- Decreased peripheral vision.</li> <li>- Altered image size: micropsia زغيرة, macropsia معوجة <b>metamorphopsia</b> كبيرة</li> <li>- Diplopia (monocular, binocular) double vision</li> <li>- Floaters الذبابة الطائرة (like with myopia)</li> <li>- Photopsia (flash of light)</li> <li>- Color vision abnormalities.</li> <li>- Dark adaptation problems.</li> <li>- Blindness: ocular, cortical.</li> <li>- Oscillopsia (shaking of images).</li> </ul>	<p>- Important question to differentiate between mild and severe pain:</p> <p>“حسأل سؤال واحد: أنت صليت الفجر ولا ما صليت؟، بيقولك أنا ما بنامش لغاية الفجر، شوفوا الكلام هنا مهم ما بيقولك أنا ما بيجيليش نوم إنما بيقولوك آه الحمد لله أنا نمت وصحيت وصليت الفجر، معنى ده ما بيكونش pain خالص يكون itching أو foreign body sensation أو حرقان في العين، وفيه ناس بتعمل مشاكل عشان الـ sick leave، بس أنا عايز أعرف هو mild ولا severe”</p> <ul style="list-style-type: none"> <li>- Foreign body sensation</li> <li>- Ciliary pain: aching, severe pain in or around the eye, often radiating to the ipsilateral forehead, molar area.</li> <li>- Photophobia.</li> <li>- Headache, like migraine.</li> <li>- Burning.</li> <li>- Dryness.</li> <li>- Itching: patient rub the eye vigorously (allergy)</li> <li>- Asthenopia (eye strain)</li> </ul>
<p><b>MCQs:</b></p> <p>(1) <b>metamorphopsia</b> is a sign of age-related macular degeneration.</p> <p>(2) 23 years old male with high myopia complaining of <b>photopsia &amp; floaters</b>. <b>Diagnosis?</b>  <b>Retinal detachment (RD)</b> [RF: young &amp; myopic]</p>	

**Abnormal ocular secretions like with conjunctivitis**

Lacrimation, epiphora	Discharge	Dryness
	 <ul style="list-style-type: none"> <li>● Purulent</li> <li>● Mucopurulent</li> <li>● Mucoïd</li> <li>● watery</li> </ul>	

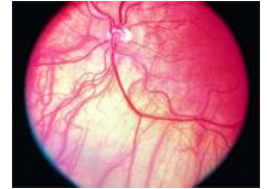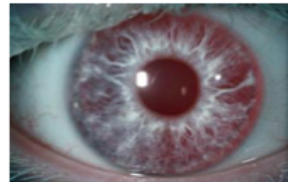
Redness, opacities, masses	<b>Anisocoria</b>	
		<ul style="list-style-type: none"> <li>* <b>Anisocoria:</b> different pupil sizes Occurs with third nerve palsy, topical medications or trauma to the eye.</li> <li>* <b>Anisocoria:</b> different corneal sizes Occurs with congenital glaucoma “One cornea is big and the other is small”</li> </ul>

● **Family history**

- Many eye conditions are inherited: RE, glaucoma, strabismus, retinoblastoma, neoplastic, vascular disorders.
- Familial systemic disease can be helpful in ophthalmic evaluation and diagnosis: Atopy, thyroid diseases, DM, certain malignancies.
- Ask about any eye problem in the family background? specifically about corneal diseases, glaucoma, cataract, retinal diseases or other heritable ocular conditions.
- Ask questions designed to confirm or exclude your tentative diagnosis. “Significant is equal to expected”
  - Significant positive.
  - Significant negative.
- Predict the physical and lab. finding likely to be present.
- Any discrepancy between the history and physical examination requires explanation



## Albinism (family history is important)



**OSCE:** you might have a history station with an SP. "لا قدر الله"

**Example:** a case of chronic visual loss, how to approach the patient?

1. Always start with "Hello, I'm a fourth year medical student, can I take history from you?"

2. Start asking questions about the causes of chronic visual loss, example:

- What is your **age**? (why? To exclude or if it goes with age-related macular degeneration)
- Did your vision decreased **suddenly** or **gradually**? (why? To differentiate **acute** from **chronic**)
- Are you diabetic (why? To exclude or if it goes with diabetic retinopathy)
- Are you taking any antiglaucoma medication? Do you have family history of glaucoma? (To exclude or if it goes with chronic glaucoma)

**Note:** if the answer to all the above mentioned questions is no then **cataract** is the most likely diagnosis is .

- Are you taking steroids?

### - Don't take patient's words literally.

"لو نزلتوا الطوارئ! مشاكل، بيجي المريض يقولك أنا مش شايف! تجي تكشفه تلاقيه بيشفوف 6/6، ال patient كان في البيت ما بيشفوفش، بيقولك قعدت ربع ساعة ما شوفنتش بس بعديها شوفت فلازم تاخذ منه التفاصيل!"

### - Questions to ask:

- **Duration:** was it all day? In 2 days? 1 week? 1 year?
- Is it **temporary**?
- Do you have blurry vision?
- Is there a zigzag line? (sometimes it starts in one eye then it goes to the other eye. The patient close her/his eye for 20 minutes and every 5 minutes she/he opens her eyes to see if it disappears)

### - Examples of transient visual loss (amaurosis fugax):

- Transient ischemic attack.
- Migraine:
  - Not a disease at all and does not interfere with life but يخلي نفسيتك زي الزفت
  - Luckily it goes away. The attacks com daily when you're young → weekly → monthly by age 30 → decreases by age 40 → once in a year by age 50 → goes away by age 60.
  - More common in females
  - **Pathophysiology:** vasoconstriction of cerebral and retinal blood vessels followed by vasodilation.
  - **Example of typical history of migraine:**

"واحد قاعد يز اكر ومرهق وبعدين عينو بتز غل بعدين ما بيشفوفش كويس وبعدين بيشفوف أو لما يجي وقت ال exam بيجي في آخر ال exam يقولك عيني زغللت ومش شايف وأبتدي أصدع عاوز أرجع"

- When they have attack they: close their eyes, dim the light or keep away from people.
- "بيقولوا ده ما بيكلمناش ده انسان مش كويس، هذا ال impression للي بيجي الناس اللي حواليه، بيقولوا دي على طول كذا بتتغير، لا هيا مش بتتغير دي جالها migraine ومش قادرة تتكلم مع حد ويتقلل النور، الغالب لو أنو غسل راسو بميه ساقعه (باردة) بيبقي أفضل"

**Advice from doctor:** if you have a migraine take Inderal 10 mg before the exam to prevent the attack.

### - It is important to differentiate between **vision loss** & **blurry vision!**

"بيقولك أنا مش شايف وهو في الحقيقة شايف وبيسوق بس بيخبط عمال يعمل accident لأن عندو فيه defect في ال periphery في ال visual field زي الناس with advanced glaucoma ال visual field بتاعو مضيع ما يشوفش الناس اللي حواليه فيعمل accident"

- **Example** of pt who has acute loss of sight or blurred vision for 20 minutes only or less? Migraine is the best example of a patient who will come complaining of loss of sight(blurred vision) with headache and nausea.

- **Important Terms:**

- Asthenopia is tired and fatigue eye
- Red eye has two types: one around the limbus called ciliary injection PAINFUL and one in the periphery called conjunctival injection NON-painful
- Anisometropia different refractive errors between both eyes

- Floaters (pt see something moving around and nobody else see it. this is because that there is an object in vitreous chamber when crosses the central part of vision > pt see it. pt with DM or have hemorrhage in eyes will have floaters).

- **If the patient can't see ask about distant or near because the patient might be more than 40 years old and cannot see near which is normal for this age which is called Presbyopia.**

- **DDx of Acute Visual Loss**

1. Age related macular degeneration(AMD).
2. Vascular occlusion(DM,HTN).
3. Retinal detachment.
4. Acute glaucoma.
  - **Morning** visual disturbances > Eye **dryness**.
  - **Blurring** of vision for **20 min** > Migraine aura .
  - Patient still complains of problems with his\her vision although all his exams and investigation are **normal** > Do visual field exam (could be stroke!).
  - There are two types of color blindness. complete and partial (most common), both are diagnosed by ishihara's test.
5. A "Convergence insufficiency" is a condition that can cause pain especially in pediatric patients.

- Refractive errors never cause pain Ciliary injection (red eye) is mainly caused by 4 things:

1. Acute conjunctivitis
2. Acute iritis
3. Acute glaucoma
4. Acute keratitis (corneal ulcer; a combination of conjunctivitis and iritis)

- Foreign body sensation (ask pt about to have hair or sand in their eyes)

# Physical Examination

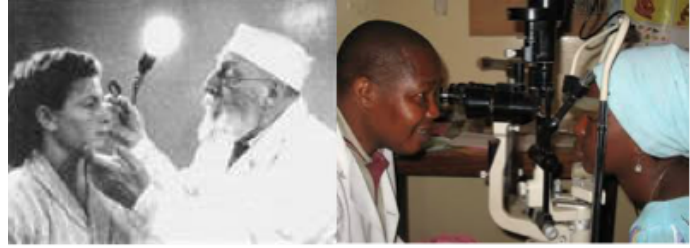- **The purpose is to evaluate:**

1. **Function:**

- Visual.
- Non-visual:
  - Eye movement.
  - Alignment.

2. **Anatomy.**

- The adnexa (lid and periocular tissues )
- The globe.
- The orbit.



The picture illustrates how ophthalmic examination changed over the years from a simple torch exam to the slit-lamp.

- **Ophthalmic examination:**

1. Visual acuity.	2. External examination.	3. Motility and alignment.
4. Pupil examination	5. Slit lamp biomicroscopy.	6. Tonometry
7. Ophthalmoscopy	8. <b>Gonioscopy</b> "don't forget it"	9. Retinoscopes

1. **Visual acuity:** subjective

- **Vital sign (MUST)** first thing the nurse checks in the clinic: blood pressure, temperature & visual acuity.


Sometimes the optometrist checks the ocular alignment, example: child with a squint. Sometimes measuring the intraocular pressure (IOP) with air-puff Tonometry.

- **Good vision:**

- Intact neurological visual pathology.
- Structurally healthy.
- Proper focus.

- **How to test vision?** You'll take it in details later on.

- Display of different-sized targets shown at a standard distance from the eye.
- Snellen chart. | 20/20, 6/6 | Uncorrected, corrected




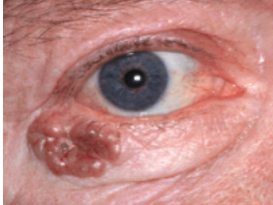




- **How to test poor vision?**

- If the patient is unable to read the largest letter < (20/200), Move the patient closer e.g. 5/200.
- **If patient cannot read:** "هذي تحفظونها صم! ومحد يسألنا في الامتحان يعني ايه"
- **Count fingers (CF)**
- **Hand motion (HM)**
- **Light perception (LP)**
- **No light perception (NLP)**



## 2. External examination

- Evaluate by gross inspection and palpation.

<p><b>Ocular adnexa. (lid periocular area), Skin lesions, growths, inflammatory lesions</b></p>	<p><b>Palpation of bony rim, periocular soft tissue</b></p>	<p><b>General facial examination</b> e.g. enlarged preauricular lymph node, temporal artery prominence</p>
 <p><b>Retinoblastoma</b> It is important to check the red reflex, if white (leukocoria) you need to exclude retinoblastoma</p>	 <p><b>Rodent ulcer</b> (basal cell carcinoma)</p>	 <p><b>Oculoglandular syndrome:</b> Eye infections + enlarged preauricular lymph node</p>
<p><b>Ptosis "drooping of the eyelids"</b></p>	<p><b>Proptosis, exophthalmos, enophthalmos "مهمة"</b></p>	
 <p><b>Right:</b> severe ptosis (might be mechanical or aponeurotic ptosis)</p>	 <p><b>Exophthalmos:</b> العين خارجة برا</p>	 <p><b>Enophthalmos:</b> عين طبيعية و عين داخلة على جوه</p>

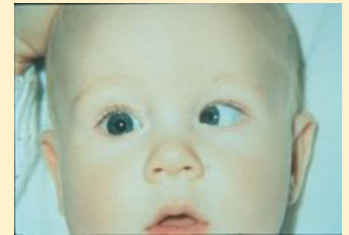## 3. Motility and alignment

- **Alignment**, misalignment of the eyes:

**SAQ/OSCE: Q: What is this?**

**Esotropia (convergent squint)**

“لو بنكتبي squint بس في الـ exam بتاخدي ZERO، ولو بنكتبي medial squint = ZERO مفيش حاجة اسمها medial، عيب! لو جبت واحد فراش بيقول medial squint، لازم تعرفوا الـ terms الحول الوحشي | **Exotropia:** divergent الحول الأنسي | **Esotropia:** convergent



- **Movements**

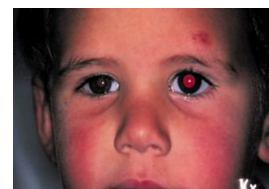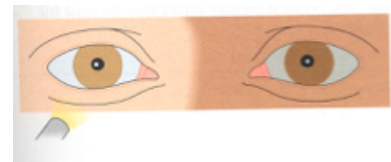- Follow a target with both eyes in each of the four cardinal directions of gaze.
- **Note:** speed, smoothness, range, symmetry, unsteadiness of fixation (e.g nystagmus)

## 4. Pupil examination

- Examine for size, shape reactivity to both light and accommodation.

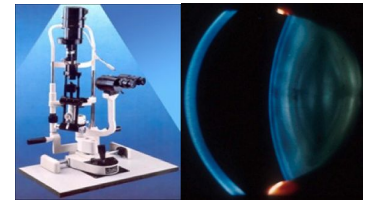
- Direct response and consensual response.
- Afferent pupillary, defect (Marcus Gunn pupil)
- Efferent pupillary defect.

- **Pupillary abnormalities:** Neurologic disease. previous inflammation- adhesion, acute intraocular inflammation, spasm, atony, prior surgical trauma, effect of systemic or eye medication, benign variation of normal



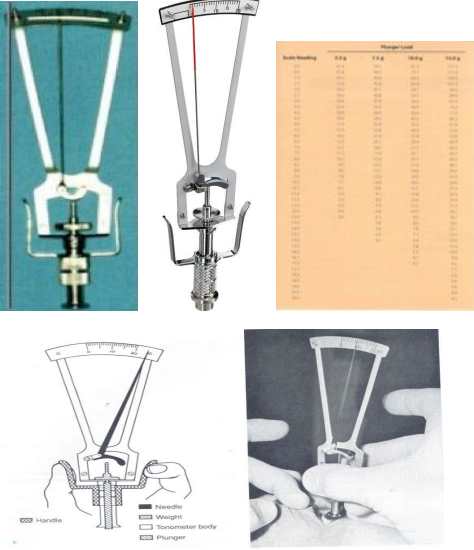


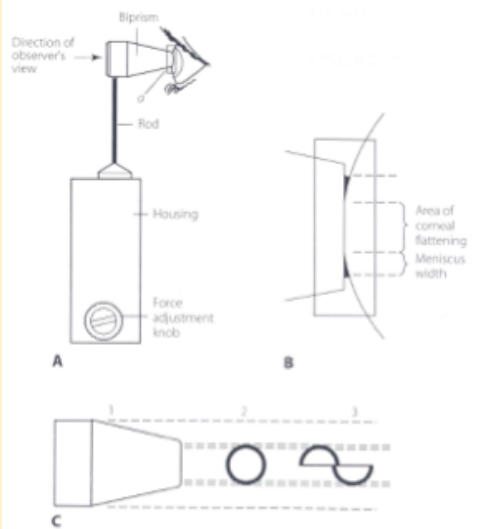


## 5. Slit Lamp Examination:

- Is a table-mounted binocular microscope with special illumination source.
  - A linear slit beam of light is projected onto the globe – optic cross section of the eye.
  - Slit lamp alone, the anterior half of the globe (anterior segment) can be visualized.
- You should know what you're looking at! You'll see Cornea → anterior chamber → lens

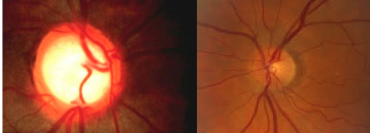
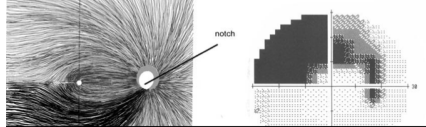


## 6. Tonometry: important





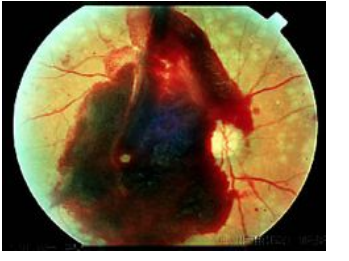
- The globe is a closed compartment with constant circulation of aqueous humor.
- This maintains the shape, and relatively uniform pressure within the globe.
- **Normal pressure 10 - 21 mmHg.**

Types of Tonometry		
<p><b>Schiotz Tonometer depends on ocular indentations</b></p>	<p><b>Digital Tonopen Tonometer Used with children.</b></p>	<p><b>SAQ: Identify? + Use? Measures IOP</b> <b>Goldmann Applanation Tonometry</b></p>
 <p>Diagram labels: Needle, Weight, Tonometer body, Plunger.</p>		
<p><b>Perkin Tonometer</b></p>	<p><b>Air-puff Tonometer</b> في استقبال العيادة</p>	
		

- **Glaucoma:** intraocular pressure (IOP), disc, visual field defect (VFD). **Optic nerve disorder manifested by VFD.**


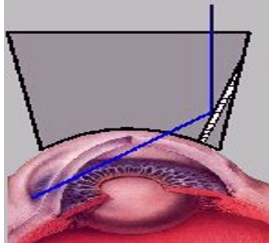
Optic cupping	Retinal nerve fiber layer & VF
	

## 7. Ophthalmoscopy you should know the difference between direct & indirect.

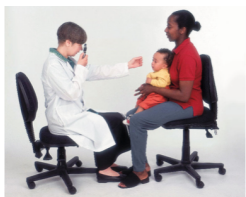Direct you'll take it in details later on	Indirect			
<ul style="list-style-type: none"> <li>- Handheld instrument.</li> <li>- Standard part of the general medical examination.</li> <li>- Portable</li> </ul> <p>“بتقولوا طبيب ما درستونا الـ indirect بس "!you should know the difference</p> <p><b>Direct vs indirect:</b></p> <ul style="list-style-type: none"> <li>* Large image   Small image</li> <li>* Monocular   Binocular</li> <li>* Virtual Erect   Real Inverted</li> </ul> 	<ol style="list-style-type: none"> <li>1. Provide much wider field of view.</li> <li>2. Less magnification (3.5X with 20D lens)</li> <li>3. Brighter light source – better view.</li> <li>4. Binocular – stereoscopic view.</li> <li>5. Allow entire retina examination till the periphery.</li> </ol> <p><b>Disadvantage:</b></p> <ol style="list-style-type: none"> <li>1. Inverted retinal image.</li> <li>2. Brighter light is uncomfortable to the patient.</li> </ol> 			
				
<p><b>Central vein occlusion</b></p>	<p><b>Optic disc edema</b></p>	<p><b>Proliferative diabetic retinopathy</b></p> <table border="1" data-bbox="813 1163 1572 1226"> <tr> <td data-bbox="813 1163 1192 1226">Hemorrhage (vitreous)</td> <td data-bbox="1196 1163 1572 1226">New vessels in the dic</td> </tr> </table>	Hemorrhage (vitreous)	New vessels in the dic
Hemorrhage (vitreous)	New vessels in the dic			

## 8. Gonioscopy important

- lens to test anterior chamber angle to differentiate between open/closed angle - acute/chronic glaucoma.
- Special lenses: gonioleins.
- Other lenses allow evaluation of the posterior segment.

IMPORTANCE OF GONIOSCOPY		
		

## 9. Retinoscopy refraction بنعمل بيه الـ





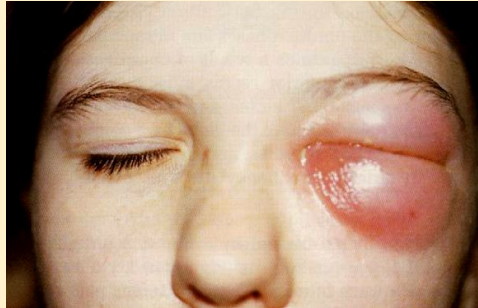# Questions

**MCQ:** A 10-year-old boy came for his annual eye check-up. Upon examination, the doctor noticed cherry red spot in the macular area. What could this sign represent?

- A. Hydroxychloroquine toxicity.
- B. Niemann pick disease.
- C. Recurrent Optic neuritis
- D. Severe Central Retinal Vein Occlusion.

**Answer: B**

**SAQ:** 34 year old lady with history of sinusitis “هزا بالزيط اللي يجيلكم”



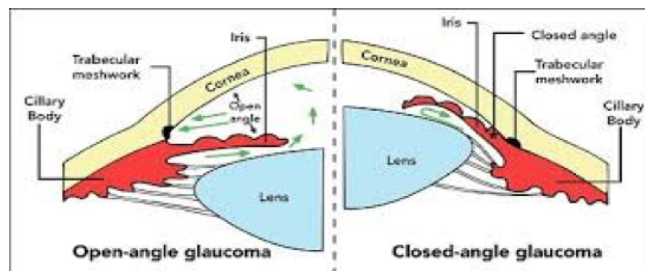
**Q1. What is your diagnosis?**

**Orbital cellulitis** (if no history of sinusitis → preseptal cellulitis)

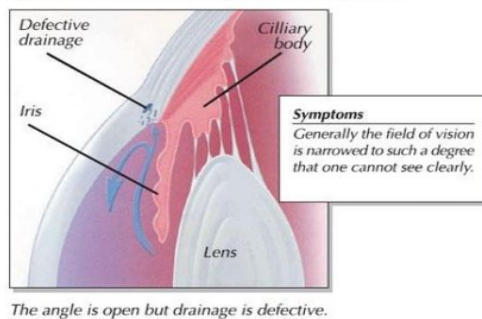
**Q2. What is the treatment? IV antibiotics**

A patient with hx of sinusitis will get **orbital cellulitis** (limited ocular motility) and the treatment is **IV Antibiotics**.  
If she **didn't** have sinusitis then its **preseptal sinusitis** (full ocular motility) and treatment is **oral Antibiotics**

## Extra from Slides



### OPEN ANGLE GLAUCOMA



### CLOSED ANGLE GLAUCOMA

