



Chronic Visual Loss

[**Color index:** Important | Note: F1 & F2 | Extra] **EDITING FILE**

Notes:

- Don't skip any picture it is very important for exam
- **Yellow highlights** are Exam Question.
- Doctor notes are very helpful for better understanding.
- In exam it is a MUST to have picture of:
 - Glaucoma "cupping"
 - Diabetic Retinopathy DR
 - Pallor of Disc

Done by: Afnan AlMalki.

Revised by: Rawan Aldhuwayhi

Resources: Slides + 435 team + Notes + ophthobook.

INTRODUCTION TO CHRONIC VISUAL LOSS

Definition: Slowly progressive painless visual loss.

Vision: So how can we assess the vision? ←

- Quantity: VA (Visual acuity)
- Quality: VF (Visual Field), clarity of vision, color vision

Causes:

Always be systematic

1. **Refractive** the most common
2. Cornea
3. Lens
4. Vitreous
5. Retina
6. Optic Nerve
7. Neurologic

Now let's discuss each of them one by one

لما نتكلم عن البصر والرؤية بشكل عام هو مو بس شيء نقيسه بالأرقام هذا مفهوم خاطئ فيه ناس نظرتهم بالأرقام سليم كامل سته على سته لكن عندهم مشاكل في نوعية النظر مثلا اللي عندهم عمى الألوان أو الأشخاص اللي يشوفون الشكل ويقدرن يتعرفون عليه مثلا يعرفون ان هذا مربع بس عليه غباش او مثلا يقدرن يشوفون الصورة بالوسط بس حوافها مايشون زين فمهم جدا نقيس النظر من وجهين النوع والكم

1. REFRACTIVE

Occurrence:

- Mostly in young patients

Causes:

- Myopia, hyperopia or astigmatism. ←
- Amblyopia: كسل العين
→ Patient who developed refractive error earlier in life and they don't treat it they might develop Amblyopia. Simply: brain tends to ignore the weak eye, brain will be confused, thus can't fuse images

Myopia: image will be anterior to Retina. So, why they are wearing negative glasses? it will bring the image to the Retina. What is the cause of myopia? check Refractive error lecture

Hyperopia: image will be posterior to Retina. Opposite to myopia

Astigmatisms: اللابؤرية في هذه الحالة بدل أن يتجمع الضوء الداخلى إلى العين في نقطة واحدة واقعة على الشبكية فإنه ينتشت ويتجمع في عدة نقاط مسببا تشويشا غير منتظم للرؤية ، سبب هذه الحالة عدم تساوي تحدب القرنية

Signs:

- Normal exam (however Sometimes patient with astigmatisms have **corneal scar** in examination)
- Refraction needed to show errors (everything will be normal except for visual acuity)

Treatment:

- Glasses, Contact Lenses, Refractive surgery (lesser or PRK)
✎ **NB:** lenticular causes needs cataract surgery.

2.CORNEA

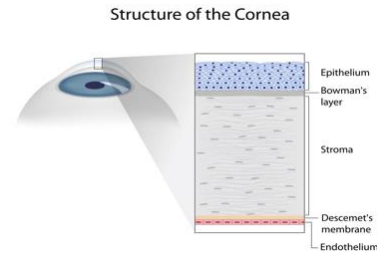
“Cornea is Avascular tissue”

Cause:

- Scar: trauma, infection
- Hereditary: corneal **dystrophies**, keratoconus القرنية المخروطية

Why there is **scar** whenever you have trauma or infection? Because the collagen fiber intercalated with each other instead of being parallel it will cross each other causing scarring.

We suppress the scarring event by **Steroid** اغلب عمليات العيون يعطونهم ستيرويد بعد العملية لان الجراحة بحد ذاتها تعتبر تروما=عشان كذا



Signs:

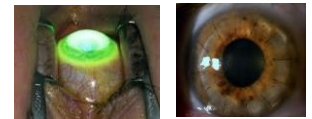- corneal scar, bulging corneal, stromal opacities. Might have some conjunctival injection with chronicity

Treatment:

- Refraction, Contact lens (soft or hard), corneal cross linking, **keratoplasty** زراعة القرنية

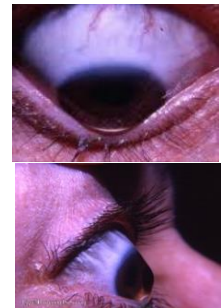
You will treat the underlying conditions. If you have patient with corneal dystrophy or significant corneal scar → simply replaces the scars corneal tissue with another tissue = keratoplasty “multiple options”

- Penetrating keratoplasty: ناخذ القرنية كاملة ونزرعها
- Lamellar keratoplasty: Corneal Stroma and epithelium transplant and leave the Descemet's وظيفة الاندوثيليل سيل تعمل زي المضخه تعمل انها تخلي الستروما نظيفة مافيها فلويد عشان تكون القرنية شفافة خالية من الشوائب تخيلوها نفس قزاز السيارة لما يجي مطر مانشوف ونحاول ننظفه بالمساحة عشان تتضح الرؤية *الدكتور قال لاتدخلون بتفاصيل العمليات*



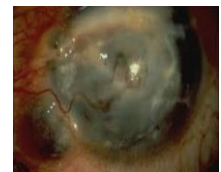Keratoconus

- What is the sign? **Munson's sign** is a V-shaped indentation observed in the lower eyelid when the patient's gaze is directed downwards بس خلي يطالع تحت Develop In advance keratoconus
- Can patient with keratoconus develop scar? Yes, the cornea is coning anteriorly so once its cones anteriorly you know that you are having a layer within the cornea called Descemet's membranes once this break the aqueous will go within the corneal stroma and will accumulate there → with chronicity it will end up with scarring



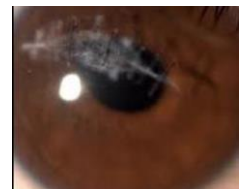Chronic inflammatory process → chronic vascularization → scarring = Stromal opacities

- Usually the cornea is Avascular tissue so once you have vascularity reaching the cornea you will have leakage of inflammatory mediators → scarring and lipid deposit



Corneal scar

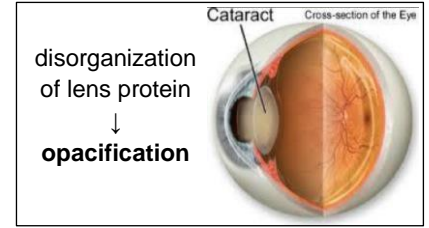
- Penetrating globe injury → underwent primary repair → suturing the wound → ended up by corneal scar
- this patient has trauma penetrating globe injury the scarring isn't the issue here you need to maintain the integrity of globe
 - لأن فيه احتمال لو ماتخيط زين ممكن يفتح وندخل في مشاكل الانفكشن مثل الاندوفتلمايتس اللي ممكن تنتهي بفقدان البصر



3.LENS “CATARACT” الماء الأبيض

Pathophysiology:

- At **age of 40 or more** the lens will lose its elasticity “less accommodation” because of disorganization of lens protein → **opacification** they will start to wear eyeglasses or complaints of loss of near vision
- Why do we have development of cataract, gray hair and wrinkling of skin start at the age of 40? Same embryological origin.



Cause:

- **Age related** the most common
- Metabolic DM
- Traumatic
- Congenital: Unilateral or bilateral You need to rule out another pediatric syndrome
- Drugs: **Steroid** (The problem not only develop posterior sub capsule cataract they will develop **Glaucoma** as well)
- Inflammation Uveitis
- Ocular: Patient with **Retinitis pigmentosa**

Clinical Classification:

According to The Maturity		
Immature	Mature	Hyper-Mature
<ul style="list-style-type: none"> • you can see the posterior pole “fundus” 	<ul style="list-style-type: none"> • you will never see the posterior pole “fundus” • The whole lens is opaque white • The anterior chamber is shallow(narrow) → Risk of glaucoma, so do a prophylaxis which is iridotomy. 	<ul style="list-style-type: none"> • The lens protein starts to leak through the capsule • It is advance part of mature cataract • causing open angle glaucoma
According the Anatomic location *IMPORTANT*		
Nuclear	Sub capsular	Cortical
<p>Nuclear Cataract in Cross-Section</p> <p>Nuclear Cataract</p>	<p>Posterior Subcapsular Cataract in Cross-Section</p> <p>Posterior Subcapsular Cataract</p>	<p>Cortical Cataract in Cross-Section</p> <p>Cortical Cataract</p>
According to the Age		
Congenital	Infantile	Pre-senile & Senile

✧ Focus only in the first two classification!

Clinically:

- Painless loss of vision gradual onset
- **Visual acuity:** worsening of existing myopia, correction of hyperopia
 - Especially patient with **nuclear sclerosis**, why? Because refractive power of lens will increase, and the image will become more anterior to Retina→worsen of myopia and correction of hyperopia
- Loss of contrast sensitivity in low light
- Glare in bright light (scatter of light): **Especially in posterior subcapsular cataract. most of the time this is the complain of patient who drive at the night.**


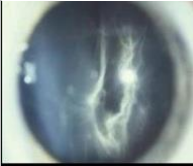


Treatment:

Medical Treatment isn't effective! So Simply you have a cataract you need to remove it by extraction

- **Congenital:** lens aspiration ± IOL (intraocular lens) remove the optical lens→replace it with new one and keep the capsule
- **Acquired:**
 - ECCE(Extracapsular cataract extraction) + PCIOL(posterior chamber intraocular lens): “very severe cataract”
 - or Phaco (Phacoemulsification) + PCIOL
Phaco is modified ECCE: small opening and putting a foldable lens.

4.VITREOUS

Causes:

<ul style="list-style-type: none">○ Vitreous hemorrhages:<ul style="list-style-type: none">→ <u>Causes:</u> trauma, PDR(Proliferative diabetic Retinopathy)DM is the most common cause, uveitis, PR	
<ul style="list-style-type: none">○ Vitreous condensation, opacification:<ul style="list-style-type: none">→ <u>Causes:</u> Chronic inflammation, Other cause is posterior vitreous detachment (PVD),the vitreous is a jelly like transparent structure once it detached from its insertion it will shrink and cause condensation. sometimes it will affect the vision.	 
<ul style="list-style-type: none">○ Vitritis:<ul style="list-style-type: none">→ <u>Causes:</u> uveitis (Pic: Vitreous haze because of inflammation)	

Treatment:

- Treat the underlying causes
- Most of the time you will do vitrectomy= removal of vitreous

5. GLAUCOMA الماء الأزرق أو السويق

The significance: [video](#)

- **Second** leading cause of blindness! Early diagnosis is crucial to prevent loss of vision
- **Why it is important? Because it's common, cause irreversible blindness and Silent disease**

ليه اسمه الماء الأزرق هل لأن العين زرقاء؟ ممكن لكن هذا فقط اذا كانت من الولادة الأصح بأن المرضى المصابين بيرون حلقات زرقاء على الضوء

Signs:

- **High IOP** + Characteristic **optic nerve head changes** + visual field loss secondary to nerve fiber layer loss + Gonioscopy: open or closed angle "will be discussed next page"

Symptoms:

- Initially Asymptomatic. usually pts will come in later stages when they lose their sight or incidentally by follow up. مهم تفهمون ان ارتفاع ضغط العين ممكن بيبي بالأم شديد جدا بالعين وحواليها ومعه صداع وممكن بيبي بدون أعراض وللان محد يعرف السبب بس لو فيه ألم بالعكس جدا مهم لي كطبيب بيكون مندر لي عشان انتبه وايدا علاج لكن المصابة اللي ما يحسون بشيء أبدا
- Usually detected on routine examination
- Glaucoma starts with **peripheral (navigational) vision involvement**. No central vision problem that why Most of the patient comes late!



NORMAL VISION



EARLY GLAUCOMA



ADVANCED GLAUCOMA

Risk factors:

- Age, **Family history**, IOP, Medication "**Steroids**", DM / HTN and **Myopia**
- ✧ IOP is the single factor to be controlled. **Normal is 10-21mmHg**

Aqueous humor: [video](#)

Active secretion:

- 1- Na/K ATPase.
- 2- Cl secretion.
- 3- Carbonic anhydrase.

Passive secretion:

- 1- Ultrafiltration.
- 2- Diffusion

Optic Nerve Head (ONH) complex evaluation:

In clinic do detailed optic nerve exam because you might have:

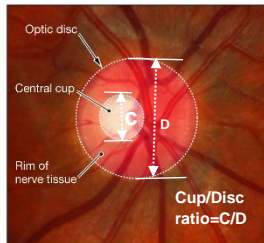
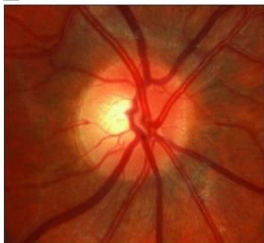- glaucomatous optic nerve head damage
- Anomalous disc
- Disc pallor because of CNS or DM

What to evaluate:

- **Disc margin and disc diameter**
- **Cup/disc ratio:**
 - How to estimate it? Take the vertical ratio if more than 0.3 we should worry
 - normal value is 0.3, bigger cup=more nerve tissue loss! Cause for large cups: glaucoma
- Neuroretinal rim: area of axon
- Disc size
- PPA: peripapillary atrophy
- NFL defect (nerve fiber layer)
- Optic disc hemorrhage

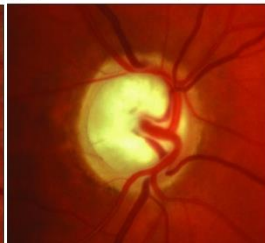Empty central part = cup يجب لكم بالاختبار صورة للجكوما ركزوا بالفايندينق

A Healthy optic disc

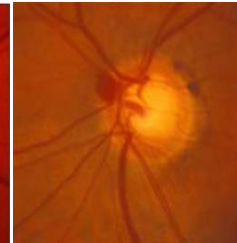
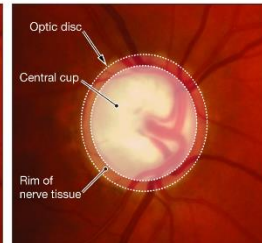


Normal optic disc

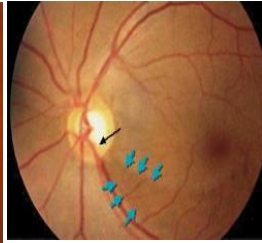
B Optic disc with increased cup-to-disc ratio (0.9)



Notice: increase cupping, thinning of neuroretinal rim



Optic disc hemorrhage



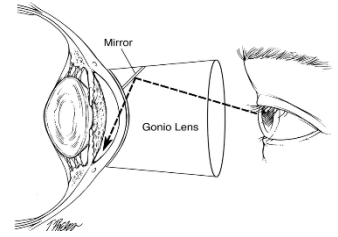
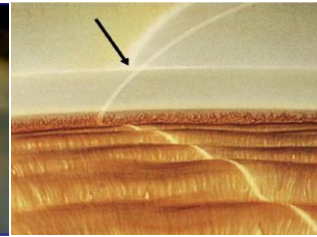
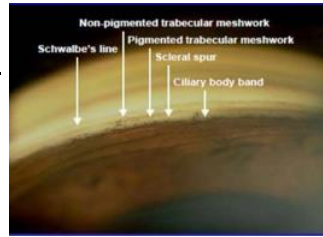
Blue arrows: wedge shape NFL loss

Gonioscopy or zeiss gonioscopy lens:

Why we use gonioscopy We need to check the angle between the iris and cornea **to classified Glaucoma** either open angle or closed.

Norma Angle structures: "احفظوها"

- Schwalbe's line (**SL**)
- Trabicular meshwork (**TM**)
 - Non pigmented
 - Pigmented
- Sclera spur (**SS**)
- Ciliary body



Classification of glaucoma:

It is important to know the classification because different management

According to the angle:	
It can be: open, closed or combined mechanism	
Open = Iris Not covering TM	Closed = Iris covering TM
<p>In open angle you can see the angle structure, The problem with the pores in the TM</p> <p>التبيركولر ميشورك شبكه فيها فتحات يطلع من الاكويس فلويد , بالاوين انقل جلوكونا مشكلتنا مع الفتحات انها انسدت فماعاد تلطع السوائل, ايش ممكن السبب ممكن مع التقدم بالعمر اومع استخدام الستيرويد بيصير فيه ترسب لماده امينوقولايكائن فتسد البورز</p>	<p>You will not able to see the angle structures unless you press the lens the structures will</p> <p>Mcq's or SAQ: in peripheral anterior synechiae there will be adhesion between iris and angle</p>
<p>Laser Rx: SLT= selective lesser trabeculoplasty → burns TM → capability of drainage of aqueous increased.</p>	<p>Laser Rx: PI = peripheral iridotomy → laser opening behind the iris → aqueous goes behind the iris → pressure will decrease.</p>
According to the etiology:	
Primary	Secondary
No detectable reason and often bilateral	Predisposing factor and often unilateral

Treatment:

Treatment is aimed at reducing intraocular pressure by 3 modalities available

1. Antiglaucoma medications
2. Laser treatment: discussed above according to the angle
3. If no improvement do surgery, Surgical treatment either:
 - a. incisional: trabeculoplasty, iridotomy, Canaloplasty and Ahmad implant
 - b. Non incisional

6. MACULAR DEGENERATION (MD)

AGE RELATED MACULAR DEGENERATION

Introduction:

- Impaired **central** vision, Peripheral vision preserved. Opposite to glaucoma
- Leading cause of **legal blindness**¹ in developed world.
- Classical presentation of those patient: Many RTA Or he will till you I cannot park my car

Symptom: احفظوها زين

- **Metamorphopsia**: distorted vision الرؤية مطعوجة كأني أشوف اللي قدامي مكسر
- **Micropsia**: reduction of size of objects
- **Macropsia**: enlargement of size of objects
- **Scotoma**: visual field loss

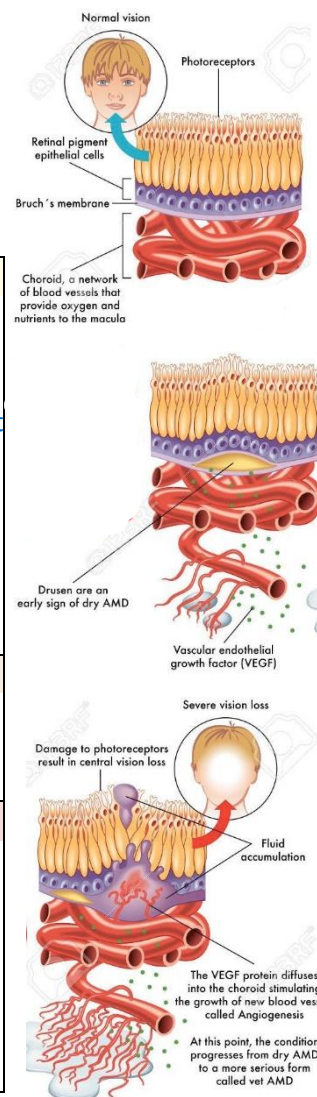
Etiology:

- **Multifactorial**: age, smoking, vascular disease, UV light, diet, and FHx.

Pathogenesis:

- **Macular involvement**: أول شي نتعرف على ابطال القصة-الطبقات الي بتتأثر-
 - ✓ Outer retinal layer “**photoreceptors**”
 - ✓ Retinal pigment epithelium (RPE)
 - ✓ Bruch’s membrane
 - ✓ Choriocapillaris

1	<p>Drusens</p> <p>Drusens (yellowish discoloration): lipid products from photoreceptor outer segments, found under retina.</p> <ul style="list-style-type: none"> ▪ EXPLANATION: photoreceptors will secrete lipids “Drusens” → accumulates under bruch’s membrane, once the RPE can’t clear them it will accumulate in larger amount → irregularity in RPE → raising the choroid and the RPE → <u>could lead to</u>: <ul style="list-style-type: none"> ✓ separation of photoreceptors → small object “micropsia” ✓ or Accumulations of Photoreceptors → Macropsia ○ With chronicity of disease the photoreceptors will Atrophied → start to loss vision ○ When there is area atrophied, area small objects and area large objects these called Metamorphopsia
2	<p>Neovascularization</p> <p>MCQ: With ischemia new vessels from choroid grow into the subretinal space forming subretinal neovascular membrane or preching the Bruch’s membrane</p> <p style="text-align: center;">-any new blood vessels in abnormal place are ABNORMAL-</p>
3	<p>Hemorrhage</p> <p style="text-align: center;">-the new vessels are very fragile can bleed easily-</p> <ul style="list-style-type: none"> ▪ New vessels is bad Either it continues to vitreous causing vitreous hemorrhages or it will bleed under the RPE causing sub RPE hemorrhages or it will bleed under the internal limiting membrane and causes subhyaloid hemorrhage. ▪ Hemorrhage into subretinal space or even through the retina into the vitreous (significant loss of vision).

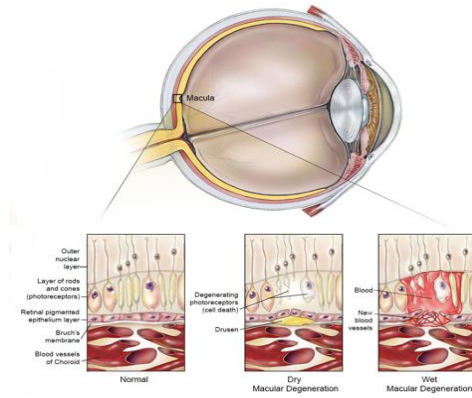


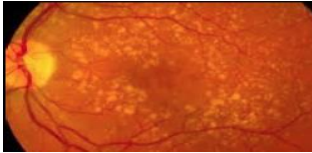
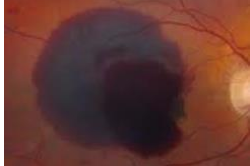
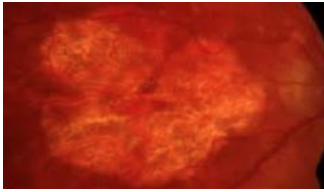

باختصار تجمعت الدهون تحت منعت التغذية و الدم صار فيه اسكيميا جاء الكورويد فزرع وسوا او عية جديدة اللي احنا ما نبغاها لانها بسرعة بتقطع من اتفه شيء وتدخلنا في مشاكل النزيف بالشبكية وفقدان البصر بالذات لو جاء النزيف في الفيتروس

¹ When we call someone legally blind? If the Central visual acuity of 20/200 or less


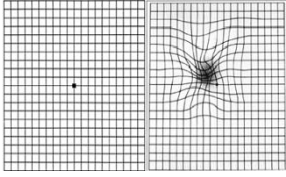
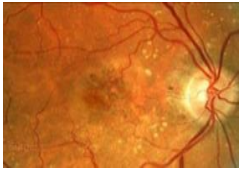
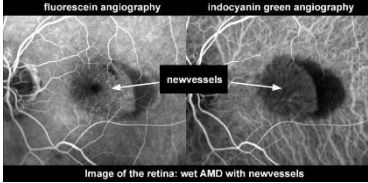
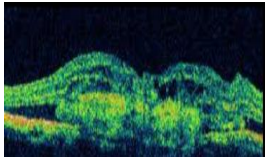
Types:

Macular Degeneration



Atrophic = dry	Exudative = wet
<p>Most benign, often asymptomatic. Gradual over years</p> <p>Signs:</p> <ul style="list-style-type: none"> • Drusen • Geographic atrophy • Photoreceptor degeneration • scotoma when light adapting 	<p>Rapidly progressive (weeks)</p> <p>Signs:</p> <ul style="list-style-type: none"> • Choroidal (subretinal) neovascularization • Preretinal hemorrhage • Elevation of retina • Subretinal fibrosis • Metamorphopsia • <u>Central</u> scotoma² pic→
<p>Drusen With time will causes RPE atrophy</p> 	<p>Preretinal hemorrhage 2 hemorrhages:</p> <ul style="list-style-type: none"> ○ grayish: under RPE ○ Bright: above RBE <p>الدكتور يقول لو جنكم بالاختبار الي تحلها صح تستاهل (:ميه على طول</p> 
<p>Geographic atrophy: Once you lost your photoreceptors that lead to this Disappearance</p> 	<p>Subretinal fibrosis: The yellowish structures is fibrosis replaced the photoreceptors لكم ان تتخيلو اذا تبدلت الفوتوريستور بالفايبروزيز ايش ممكن يصير اكيد بيروح النظر فيها</p> 
<p>What's the difference between dry and wet age-related macular degeneration? Dry ARMD is when you have drusen and macular RPE atrophy. Wet ARMD implies choroidal neovascularization that has grown up through Bruch's membrane and bleed into the retina. "Wet" essentially means "bloody" in this instance.</p>	

Diagnosis:

Visual acuity	Amsler grid	Ophthalmoscopy	Fluorescein angiography	ICG (Indocyanin Green)	OCT(Optical Coher Tomography)
	 <p>If the patient saw wavy lines, then the macula is abnormal</p>	 <p>Pic:discret scattered yellowish subretinal drusens "dry MD"</p>	 <p>Image of the retina: wet AMD with newvessels inject IV fluorescein\or ICG to visualize the retinal vessels.</p>	 <p>OCT shows subretinal fibrosis and hemorrhages</p>	

² Irreversible visual loss , same as glaucoma but MD less common

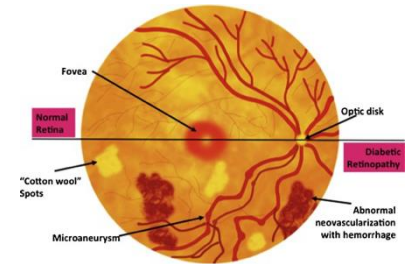
Treatment:


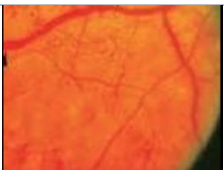


- If dry:
 - **Lifestyle:** Stop smoking, reduce UV exposure, Zinc & antioxidants
 - Low-vision aid
 - Monitoring with Amsler chart
- If advanced, you cannot do anything there is already fibrous tissue:
 - Observation
 - Laser photocoagulation, for neovascular membrane especially for the wet type.
 - Anti - VEGF agents. Wet type
 - **You don't need to know this:** Verteporfin photodynamic therapy (PDT): injection of photosensitizer into systemic circulation followed immediately by laser targeting new vessels in macular area

7. DIABETIC RETINOPATHY

Pathophysiology:

- **Microangiopathy**³ which involves precapillary arterioles, capillaries and postcapillary venule. Have 2 mechanisms:
 1. Microvascular occlusion
 2. Microvascular leakage



1. Microvascular occlusion	
A. Thick capillary basement membrane. Mean lumen is smaller. Picture show: Abnormal blood vessels like fan new vascularization "NV"	
B. Capillary endothelial cell damage ⁴⁵ → Retinal ischemia ⁶ → AV shunt and NV	
C. Change in blood cell	
2. Microvascular leakage	
Loss of pericytes between endothelial cells → leakage into retina → exudates and edema	
Exudate of lipid in Retina	Retinal Edema
	

Risk factor:

Duration, Pregnancy, Nephropathy, Poor metabolic control, Smoking, HTN, Obesity and hyperlipidemia

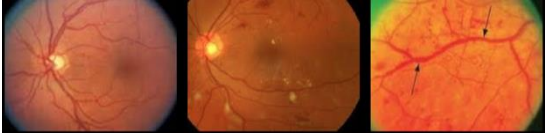
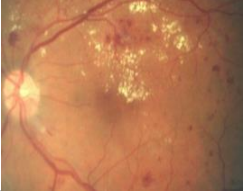

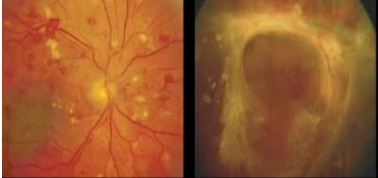
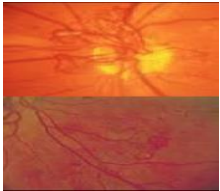


³ Microangiopathy= small blood vessels. Most if it presents in Retina, kidney, heart, and the brain هنا اغلب مضاعفات السكر تَلقونها هنا

⁴ Mean lumen narrower and narrower

⁵ increased viscosity of RBC > clot formation > lumen closed > ischemia

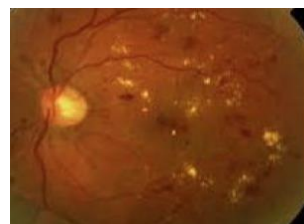
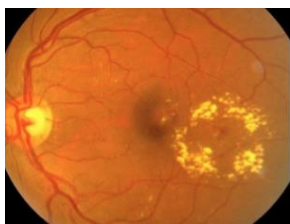⁶ Abnormal new vascularization because of vascular endothelial growth factor from ischemic tissue, this new vessels is fragile and easily bleed and causes fibrosis

Clinical classification: بجيب منها في الاختبار

<p>Non proliferative diabetic retinopathy :</p> <p>1. Non proliferative DR: mild , moderate and severe. Pic show macular Edema and the arrow show ischemia</p> <ul style="list-style-type: none"> • Asymptomatic • Decreased visual acuity : Clinical significant macular edema & macular Ischemia 			
<p>Hemorrhagic spots</p> 	<p>florican angiography for a very ischemic Retina “you cannot see the small blood vessels”</p> 		
<p>Proliferative diabetic retinopathy :</p> <p>2. Proliferative DR : early and advance Treat as soon as possible!</p> <ul style="list-style-type: none"> • Symptomatic • Can causes macular edema and or ischemia 			
<p>A. Neovascularization</p> <p>a. NVD: neovascularization of the disc pic above واضحة جدا تشوفون او عية كثير متشابكة وتكون حول الديسك</p> <p>b. NVE: neovascularization elsewhere pic below تشوفون او عية كثير متشابكة بعيد عن الديسك</p>			
<p>B. Fragile (intra-retinal or vitreous hemorrhage) tractional retinal detachment⁷</p>			
<p>C. Associated with fibrous proliferation TRD Fibrous tissue</p>			

Diabetic Macular Edema:

- Retinal edema threatening or involving the macula
 - Evaluate: location of retinal thickening relative to the fovea and the presence and location of exudates
- | | |
|---|---|
| <p>FOCAL Clinical significant macular edema:
 ring pattern and leaking in center.
 Treat. focal lesser</p> | <p>Diffuse hemorrhages and exudate all over
 no specific pattern
 Treat. Grid lesser</p> |
|---|---|



⁷ Recall the types of RD:

- **Rhegmatogenous** RD: you have break ثقب صغير يدخل من خلاله الفلوييد ويفصل الريتينا
- **Tractional** RD^{in “DR”}: you have fibrous tissue once its contract it will pulling the Retina
- **Exudative** RD: inflamed choroid layer -> accumulation of fluids under Retina -> detachment

Treatment:

- Laser
- intravitreal steroid injection
- intravitreal anti-VEGF injection
- Pars plana vitrectomy

8. RETINITIS PIGMENTOSA (RP) - العشى الليلي

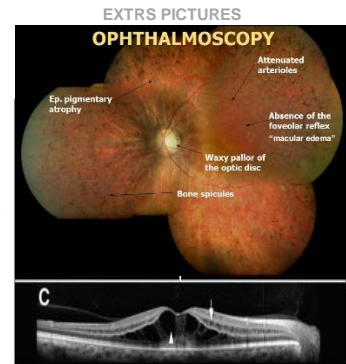
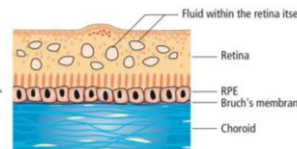
General characteristic:

- Group of **genetic disorders** affect the retina ability to respond to light يشوف بالنهار افضل
- **Symptoms** Slow loss of vision:
 - **Nyctalopia**: loss of night vision.
 - **Tunnel vision**⁸ "loss of peripheral vision"
 - **blindness**
- Most are legally blind (Central visual field of less than 20 degrees) by 40s.
- **X linked recessive**: males: more often and more severe, females: carry the genes and experience vision loss less frequently
- **Target photoreceptors** and Associated with pigmentary changes in the RPE, which may be primary or secondary to the photoreceptor loss.

Rods important for night vision and cons in day vision but it will affect both of them

Signs:

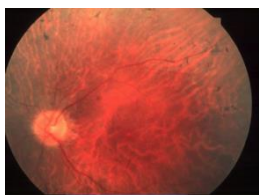
- Visual acuity varies from :20/20 to no light perception at all.
- +-APD (afferent pupillary defect)
- PSCC (posterior sub capsular cataract)
- RPE hyperpigmentation (**bone spicules**) alternate with atrophic regions.
- **Attenuation of the arterioles** "thinning".
- **Waxy pallor** of the optic nerve head.
- cystoid macular edema (severe cases of RP) Extra pic →.



RP stages and signs

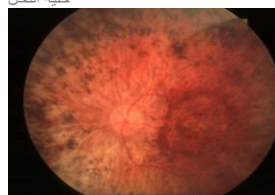
Early stage

faint black spots in periphery "bone Spicules"



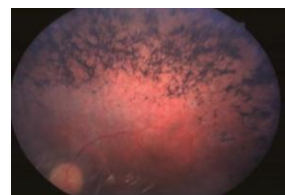
2nd stage

- bone spicules Increased more and more
- Start to loss photoreceptors
- Waxy disc appearance نفس لون الشمع حق خليه النحل



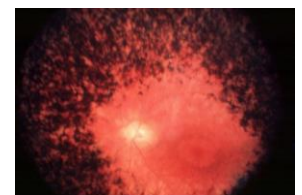3rd stage

- more loss of photoreceptor
- More clumping of RPE



4th stage severe

- Severe photoreceptors loss
- Tunnel vision
- Severe RPE loss and clumping
- Bone spicules
- Waxy pallor



⁸ Glaucoma have high IOP but in RP not

Investigation:

- VF test tunnel
- Color testing (mild blue-yellow axis color defects)
- Dark adaptation study (reduced contrast sensitivity relative to VA)
- Genetic subtyping
- OCT (CME) **Very important to check for cystoid macular edema**
- FFA **florican angiography**
- ERG Electroretinography is an eye test that detects function of the retina including photoreceptors
- EOG Electrooculography to record eye movement

Systemic Associated: همه اللي يتخصص منكم بيديا او نيورو او حتى ميدسن *ارجعولها*

- **Hearing loss and RP:**
 - **Usher syndrome (MOST IMP THING FOR US)** Usher syndrome is a condition characterized by partial or total hearing loss and RP.
 - **Alport syndrome** is a genetic condition characterized by RP, kidney disease, and hearing loss.
 - **Refsum disease** is an autosomal recessive neurological disease that results in the over-accumulation of phytanic acid in cells and tissues.
- **Kearns-Sayre syndrome:**
 - External ophthalmoplegia مايقدر يحرك عينه
 - Lid ptosis
 - Heart block
 - Pigmentary retinopathy
- **Abetalipoproteinemia** is a disorder that interferes with the normal absorption of fat and fat-soluble vitamins (↓vitamin A →RP)
- **Mucopolysaccharidoses**
- **Bardet-Biedl syndrome** genetic disorder characterized principally by obesity, RP, pigmentosa, hypogonadism, and kidney failure in some cases
- **Neuronal ceroid lipofuscinosis** lysosomal storage disorders characterized by dementia , RP, and epilepsy .

Treatment:

Unfortunately, nothing can be done to prevent the progression of the disease, associated ocular problems can be treated:

- CAI: CME “Carbonic anhydrase inhibitor work will in patient with RP and CME”
- Vitamins
- Cataract: surgery
- Low vision aids
- Gene therapy!! خز عيالات

- THE END -

Extra

What's the difference between a PCO and a PSC cataract?

- PCO: posterior capsular opacification. This is an “after cataract” that forms on the back surface of the posterior capsule after successful cataract surgery. This opacity can be cleared with a YAG laser.
- PSC: posterior subcapsular cataract. This is a cataract that forms on the back portion of the lens. These tend to occur more often in diabetics and those on steroids, and tend to be visually significant because of their posterior position.

What drops are given after a cataract surgery? Usually an antibiotic, such as ciprofloxacin or vigamox. Also, a steroid is given to decrease inflammation.

What retinal findings do you see with glaucoma? You see increased cupping of the optic disk, usually in a vertical pattern that goes against the ISNT rule. You can sometimes see hemorrhages at the disk and “undermining” of the blood vessels as they exit the disk.

What's the difference between open-angle and closed-angle glaucoma? How about chronic versus acute glaucoma?

- Open angle is a common, chronic condition where aqueous drainage is impaired.
- Closed-angle glaucoma is caused by acute closure of the iridocorneal angle leading to blockage of ALL aqueous drainage – an ophthalmologic emergency that can quickly lead to blindness.

What are the retinal signs of diabetic retinopathy. How do they compare to, say, hypertensive retinopath? With diabetic retinopathy you typically see a lot of dot-blot hemorrhages, cotton-wool spots, and hard exudates. Hypertension usually has more flame hemorrhages and vascular changes such as arterial-venous nicking and copper/silver wiring.

How do we categorize diabetic retinopathy? As either NPDR (nonproliferative diabetic retinopathy) or PDR (proliferative diabetic retinopathy) depending upon the presence of neovascularization.