



Neuro-ophthalmology

[**Color index:** Important | Notes: **F1**, **F2/A** | Extra] [EDITING FILE](#)

Objectives:

➤ Not given.

Done by: Samar AlOtaibi, Luluh Alzeghayer, Feras Al-Tukhaim

Edited & revised by: Lamyia Alsaghan, Munerah AlOmari, Abdulrahman Alshammari

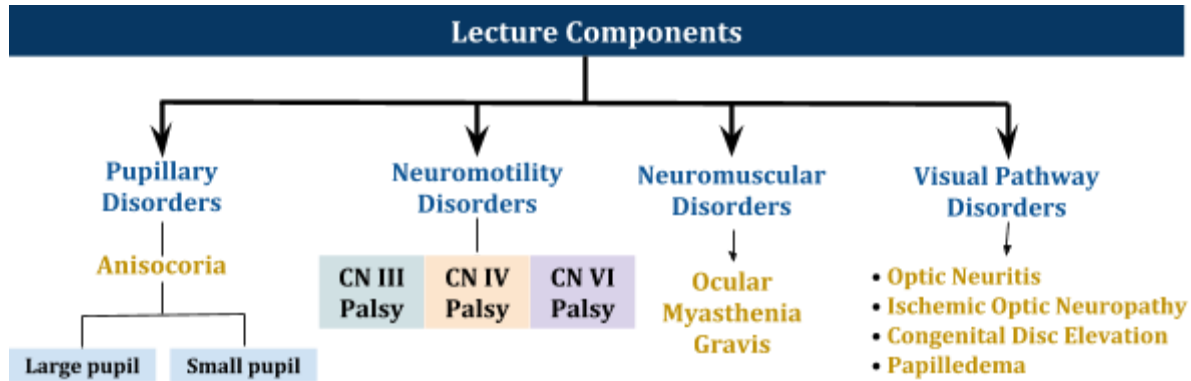
Resources: Slides (old version) + Notes + Lecture Notes of Ophthalmology + OphthoBook.

**The secretary did not send the updated student version slides from
Dr. Daniah Alshowaier despite repeated demands!**

Last pages are extras!

Introduction

- **Neuro-ophthalmology** deals with visual problems that affect the optic nerve and its connection to the brain.
- Our eyes simply receive visual information and we actually see with our brain. In turn, the brain controls the position and focus of the eyes, directing our visual attention.

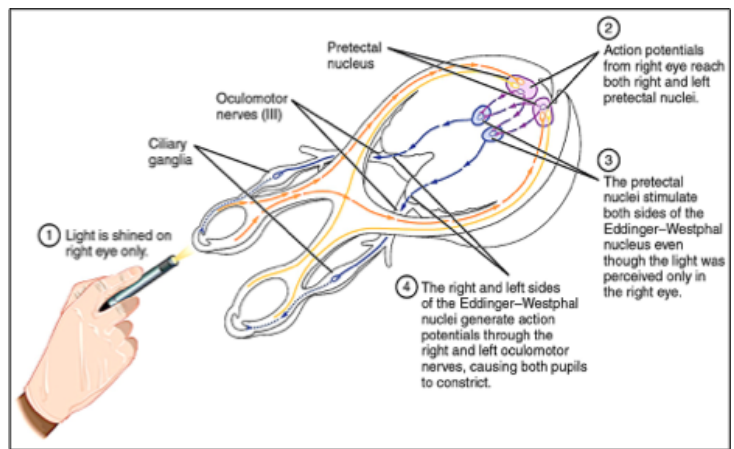
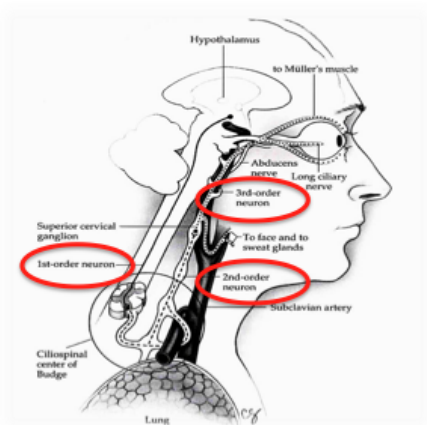


Pupillary Disorders

● Anatomy & physiology

- Pupil size is controlled by a balance between:
 - **Parasympathetic** with illumination (miosis: pupil constriction by sphincter muscles)
 - **Sympathetic** innervation in the dark (mydriasis: pupil dilation by iris dilator muscles.)
- Pupil (reacts) constricts to: Light | (2) Near stimuli: triad of: accommodation, convergence & miosis. This is why on examination we ask the patient to look away to eliminate the near reflex.

Sympathetic (adrenergic) pathway	Parasympathetic (cholinergic) pathway
<p>*very important*</p> <ul style="list-style-type: none"> - The first-order neuron descends from the hypothalamus to the first synapse, which is located in the cervical spinal cord (levels C8-T2, also called ciliospinal nucleus of Budge). - The second-order neuron travels through the brachial plexus, over the lung apex (that is why a tumor in the apex of the lung "Pancoast tumor" lead to horner's syndrome -or any cut of the sympathetic pathway-). It then ascends to the superior cervical ganglion located near the angle of the mandible and the bifurcation of the common carotid artery. - The third-order neuron then ascends within the adventitia of the internal carotid artery, through the cavernous sinus, where it is in close relation to the <u>sixth cranial nerve</u>. The oculosympathetic pathway then joins the ophthalmic (V1) division of the fifth cranial nerve (trigeminal nerve). In the orbit & the eye, the oculosympathetic fibers innervate the: <ul style="list-style-type: none"> ○ Iris dilator muscle: group of muscles in the peripheral 2/3 of the iris ○ Müller's muscle: a small smooth muscle in the eyelids responsible for a <u>minor</u> (around 2-3 mm) portion of the upper lid elevation (main eyelid muscle elevator is <i>Levator palpebrae superioris</i>, supplied by 3rd nerve) ○ Lower lid retractors. Some patients might tell you they feel that their eyes are getting smaller and that is actually because the lowers lids are going back. This is called [REVERSE PTOSIS]. 	<ul style="list-style-type: none"> - Stimulation starts when you shine the light and that is important when you do the pupillary reflex. - When you generate action potential with the light stimulation, it will go back to the Pretectal nucleus then to the Edinger-westphal nucleus bilaterally [important: both nuclei will be innervated with the same amount that is coming from one eye (this is why shining light at one eye will constrict both pupils)] from there joining the parasympathetic fibers of the oculomotor nerve and it will go back to the eye causing miosis. Parasympathetic fibers are divided into superior and inferior division. Inferior division go to ciliary ganglia (parasympathetic ganglia) and finally reaching Sphincter pupillae muscle to constrict the pupil.



● Examination of the pupil

OSCE: pupil examination is done either with an ophthalmoscope or a penlight. [Check this video](#)

- Best conducted in dim light room using a bright light.
- The patient should be relaxed and fixing on a distant object to relieve/eliminate the near reflex.
- The **size, shape, position** of **each pupil** should be noted in **light & dark** conditions. equally round & symmetrical.
- Check light reflex looking for a relative afferent pupillary defect (RAPD).

1) Test light reflex: when shining light to one eye both pupils will constrict because it will stimulate both pretectal nuclei. When moving to the other eye normal reaction is either the same size or slightly constricted but never dilated. If there is dilation = relative afferent pupillary defect (RAPD): Pupils are equal and of normal size, but the response to light from affected side is reduced, while the near reflex is intact.

~ **Illuminated eye** → **direct (reflex)** constriction response.

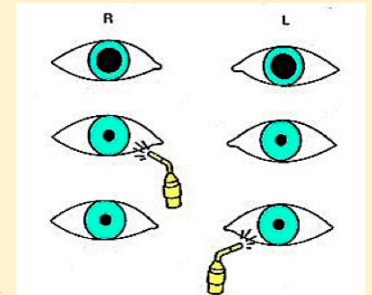
~ **Other eye** → **consensual/ indirect (reflex)** response.

2) Swinging light reflex: looking for (RAPD) to assess the optic nerve function. Pupil constricts (C) → dilates (D) a fraction as the light passes over the nose → constricts again.

~ C → C → C → C = two normal eyes.

~ C → D → C → D = “**Marcus Gunn pupil**” There will be constriction when shining light on the good eye. But, when crossing to the bad eye, both eyes seem to dilate a little. The bad eye still senses light and constricts but not as well.

+ **Test near vision:** accommodation → constriction.



● **Anisocoria** it is not the same as afferent pupillary defect (RAPD)! It is not related to the optic nerve

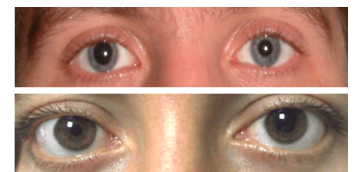– **Anisocoria:** difference in pupil size. Always ask yourself which is affected? is it the large or small pupil? In order to answer that you need to examine the patient in **light & dark (dim light)** conditions, and measure in millimeter (mm)

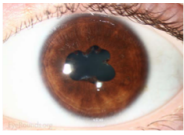


– Small pupil does not dilate as well as the large pupil in dim light → **small pupil is abnormal**.

– Larger pupil does not constrict as well as the small pupil in response to a light stimulus → **large pupil is abnormal**.

– **Normal physiological anisocoria:** 20% of patients will have some difference between the size of pupils.

- Difference should be **less than 1 mm** and **same amount in the dark and light** (important to examine the patient in both conditions).
- **Hallmark: Intermittency or variability**, which is a reassuring sign. (with pediatric patients the mother says “sometime it’s the left eye sometimes I can’t differentiate, sometimes it goes to the other side”)
- With every patient take full history and do examination to rule out **sympathetic & parasympathetic lesions**.



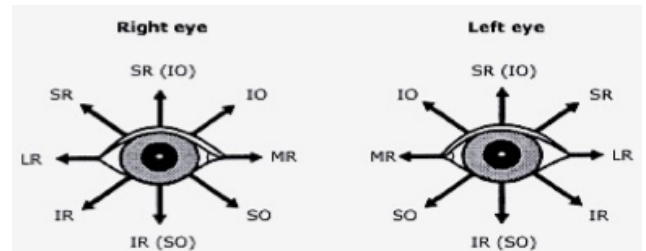
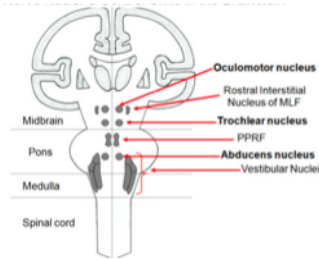
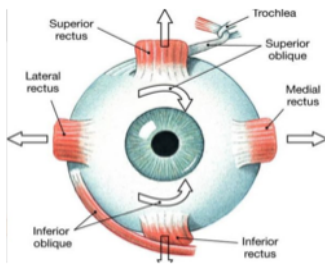
Large pupil is abnormal rule out by hx	Small pupil is abnormal
<ul style="list-style-type: none"> - Previous ocular surgery. - Ocular trauma. - Use of medications, like cycloplegics e.g. atropine, cyclopentolate. Sometimes we prescribe a drug to a child, the mother uses the drops, then touches her eyes. - Third nerve palsy. Fixed dilated fixed pupil, not responding to light (usually associated with severe ptosis, sometimes it covers the whole eye) will be discussed in details 	<ul style="list-style-type: none"> - Previous ocular surgery. - Ocular trauma or inflammation. - Use of medication: ex.pilocarpine/ glaucoma medications <p>Picture: small irregular pupil due to adhesions between the iris and the lens (posterior synechiae) caused by trauma or chronic inflammation. While adhesions between the iris and the cornea are termed (anterior synechiae).</p> 
Tonic pupil (Adie's pupil)	Horner's syndrome
<ul style="list-style-type: none"> - Benign condition no need for further investigations. - Young female Unilateral (80%). - Sluggish, segmental pupillary responses to light. - Better response to near (it will be intact) followed by slow redilation. Called "light near dissociation" - Diagnosis: instillation of weak cholinergic agents (0. 1% pilocarpine) will cause constriction (briskly) of the tonic pupil and will give you "reverse anisocoria" it will be even smaller than the one without any medication because of (denervation hypersensitivity). Normally there will be no changes. + slow, sustained miosis on accommodation. - Holmes-Adie syndrome: (1) Tonic pupil (2) Diminished deep tendon reflexes (3) Orthostatic hypotension. 	<ul style="list-style-type: none"> - Includes a triad of: (1) Small pupil (miosis) (2) Ptosis mild (3) Anhidrosis. + enophthalmos, heterochromia, loss of ciliospinal reflex. - Causes: lesion anywhere along the sympathetic pathway (central, para (peripheral), preganglionic, postganglionic). Carotid dissection, carotid aneurysm & tumor can be associated with Horner.  <p>Scenario: 18-year-old female presented to the clinic saying "I noticed my right eye got smaller after neck surgery". Anisocoria wasn't clear in the light so we examined her in the dark. The difference was around 2 mm. She also had mild ptosis. There is also lower retraction. What is the diagnosis? Horner's syndrome</p>

Most important life threatening cause that you can't miss, a young patient comes with history of trauma with **PAINFUL HORNER**, you have to rule out internal carotid artery dissection, the internal carotid is within the adventitia thus horner's may be the first sign. if you miss the diagnosis, patient might go into stroke shortly after. You need MRI/MRA.

Neuromotility Disorders

- **Anatomy & physiology** main nerve supplying extraocular muscles is oculomotor (third nerve)

EOM	Primary action	Innervation	Nucleus
Superior rectus	Elevation (maximal on lateral gaze)	Third cranial nerve, oculomotor	Midbrain
Inferior rectus	Depression (maximal on lateral gaze)	Third cranial nerve, oculomotor	
Medial rectus	Adduction	Third cranial nerve, oculomotor	
Inferior oblique	Excyclotorsion	Third cranial nerve, oculomotor	
Superior oblique	Incyclotorsion	Fourth cranial nerve, trochlear	
Lateral rectus	Abduction	Sixth cranial nerve, Abducens	Pons

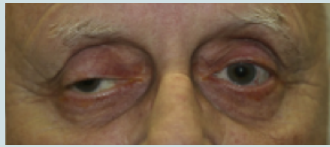


This picture is very important!

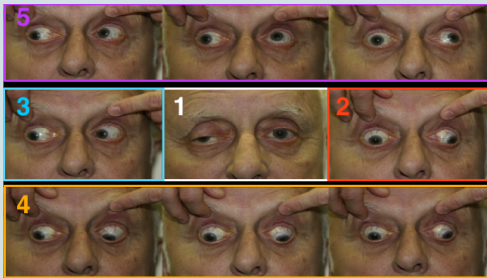
Keep this image in your head when examining **EOM movement**
 SO: Down & In | IO: Up & Un | IR: Down | SR: Up | MR: In | LR: Out

Third nerve palsy

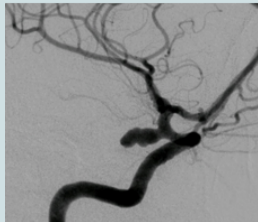
Case



65 years old presented to ER complaining of double vision.
Typical presentation of CN III palsy always keep it in your head!
Ptosis and Eyes are (down & out) pupillary dilatation & no accommodation.
 The eye rests in a position of abduction, slight depression, and intorsion.



Next step: examination of extraocular movement:
1. Primary position: looking straight ahead.
2. Looking to his left: abnormal. | **3. Looking to his right:** normal.
4. Mild infraduction limitation. | **5. Mild spraduction** limitation.
Next step: check for pupillary involvement:
 To differentiate between **surgical** (urgent, compression, pupil involved, needs neuroimaging) and **medical** (pupil sparing) third nerve palsy. Absence of pupillary involvement suggests a benign process that can be observed over a couple of weeks. A fixed, dilated pupil requires extensive neurologic evaluation



Diagnosis: posterior communicating artery aneurysm (life threatening)
 (right internal carotid artery injection reveals a right posterior communicating artery aneurysm with a tubular configuration. A very small anterior communicating artery aneurysm is also identified) **Magnetic resonance angiography (MRA) is the best investigation for PCA aneurysm**
You always have to rule out aneurysm, why? Usually parasympathetic fibers goes on the outside (superficial) with CN III pathway so any compression will lead to CN III palsy with pupil involvement.


Anatomy & physiology

- Begins as a nucleus in the **midbrain** that consists of several subnuclei. **Multiple nuclei**
- Innervate:
 - o **Most extraocular muscles:** eye deviates **down & out**
 - o **Eyelids:** main lid retractor: **Levator palpebrae superioris** so paralysis will lead to severe ptosis
 - o **Pupils:** innervated by parasympathetic fibers which is not part of oculomotor nerve, they run together and have **the same pathway**. The parasympathetic pupil-constrictor fibers from Edinger-Westphal nucleus travel within CNIII, and their loss gives you a "blown pupil"


Etiology

- Microvascular ischemia (DM, HTN, DLP). **If risk factors are controlled, the palsy will resolve by itself.**
- Intracranial aneurysm (posterior communicating artery) **Not the most common but to ophthalmologists YES**
- Trauma. **Neuroimaging is indicated**
- Brain tumor. **Neuroimaging is indicated**

Fourth nerve palsy

	<p style="text-align: center;">Clinical presentation</p> <ul style="list-style-type: none"> - Vertical diplopia. Characteristic unlike CN III (can have different types.) They mostly complain about actions that require downgaze vision, like: going down the stairs, eating, reading and writing. - Head tilt: to the opposite shoulder. (1) You might think the kid is shy and he doesn't want to interact, but actually he is just trying to avoid his double vision . (2) If you try to correct his head you'll notice some hypertropia. (3) if you move his head to the same side of the affected nerve it will be worse.
<p style="text-align: center;">Etiology</p>	<p>Trauma even minor ones not only severe, Idiopathic, Congenital (commonest)</p>

Sixth nerve palsy

	<p style="text-align: center;">Clinical presentation</p> <ul style="list-style-type: none"> - Horizontal diplopia: two images beside each other (worse at distance) "يقولك لما أمسك خط، لما أكون مسافر أو سابق السيارة تكون "ليه؟" Because with near vision you need convergence you don't need CN VI, but when looking far you need it for divergence (taking the eye out) - Esotropia. when you do cover-uncover test video (0.25 to 0.50), esotropia is more at distance than near. - Face turn in the direction of the paralyzed muscle. To avoid its action - Limited Abduction on the side of the lesion. (1) Primary position (2) Looking to his right, right lateral rectus is affected. Diagnosis: right sixth nerve palsy
<p style="text-align: center;">Etiology</p>	<p>You have to rule out: Intracranial tumors, Trauma, Microvascular diseases (most commonly) and Increased intracranial pressure: we call it false localizing sign because you don't know exactly where is the lesion. The nerve passes through the Dorello canal at 90 degree angulation, this makes it susceptible to pressure due to any lesion in the brain. ex. a frontal tumor will cause pressure on this canal leading to 6th nerve palsy</p>

Neuromuscular Disorders

● Ocular myasthenia gravis (OMG)

- **Definition:** chronic autoimmune disease affecting the neuromuscular junction.

- **Clinical presentation:**

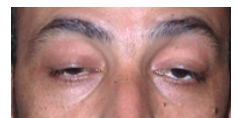- **Symptoms:** **PAINLESS** ptosis, diplopia (can present alone or together), **fatigability and variability** are characteristic (usually worse at the end of the day unlike other palsies which are constant. Ask the patient if symptoms are worse early in the morning or at the end of the day?). Ask about systemic weakness, difficulty in swallowing or breathing. majority present with ocular MG then eventually convert to general MG.
- **Examination:** **pupil is not affected**, Assess orbicularis strength (Ask patient to close eyes strongly & open them)

If: painful ptosis or there is pupil involvement don't say myasthenia gravis with your differential diagnosis

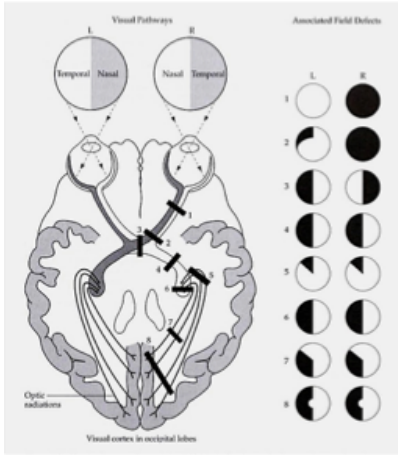
- **Investigations:**

- Blood test for acetylcholine receptor antibodies. 50% present in OMG
- **Tensilon test:** inhibits acetylcholinesterase and can transiently reverse signs of weakness due to OMG, such as ptosis and extraocular muscle paresis. Look for improvement in symptoms. Diagnostic but we don't have it here.

- **Treatment:** you don't need to know the details but we can give steroids or Acetylcholinesterase inhibitors.



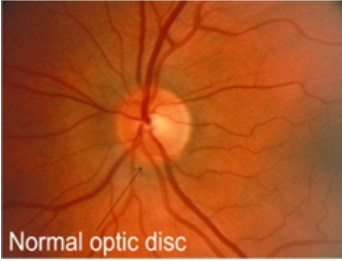


Visual Pathway Disorders



- Lesions anywhere in the visual pathway will produce visual field defect.
- **Important to know:** any lesion before or in front of the chiasm will give you one eye lesion, and if it is beyond the chiasm will give you bilateral VFD.
- Usually VFDs are opposite to the site of lesion.
- **Picture #3:** bitemporal hemianopia due to pituitary tumor compressing optic chiasm.
- **Picture #5:** pie in the sky indicating temporal lobe lesion (superior quadrantic hemianopia)
- **Picture #7:** pie on the floor indicating parietal lobe lesion (inferior quadrantic hemianopia)
- **Picture #8:** occipital lobe lesion because of macular sparing (dual blood supply, if one affected the other will supply the macula).

● Optic nerve disease

- Usually unilateral | Afferent pupillary defect | Central visual loss common, but can present with any visual field defect. | Loss of color vision. use ishihara test or look for any red led of any medication & simply ask to compare. Patients with optic nerve disease will tell you the color isn't as bright (washed out) as the other eye "مطفي، متغير"
- How to assess the optic nerve in the clinic: visual acuity, visual field, color test and afferent pupillary defect.
- Can present with optic disc edema or atrophy depending on the pathology & the time of your examination.
- Learn how to do direct ophthalmoscope exam. whether you want to be ER physician, neurologist, internist..etc [Link](#)

 <p>Normal optic disc</p>		
<p>Normal</p>	<p>Optic disc edema</p>	<p>Optic atrophy</p>
<p>Learn the normal to know the abnormal. There has to be sharp distinct margins, a pinkish rim and, usually, a central, pale, cup, cup-to-disc ratio and blood vessels are all intact, central retinal artery and vein enter the globe slightly nasally in the optic disc.</p>	<p>There is fluid all around the margins, blood vessels are especially small and not very clear.</p>	<p>Not to be confused with cupped disc (glaucoma), which comprises: enlarged cup, blood vessels nasally pushed and a healthy rim.</p>

● Typical optic neuritis "disease of the young"

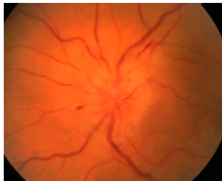
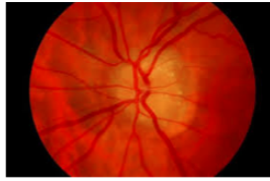
- Inflammatory demyelinating condition associated with multiple sclerosis. not always associated with MS!
- Most common type in young adults. most commonly females.
- **Clinical presentation of typical optic neuritis:** sudden visual loss, pain with eye movement (inflamed optic nerve which is in close proximity with medial rectus muscle. If they look horizontally they will feel minimal pain "discomfort", if pain is severe, this is "atypical optic neuritis") and visual field loss (commonly central, but can present with any VFD).
- 20% of MS patients have optic neuritis as a first manifestation. Patient with optic neuritis needs an MRI of the brain and orbits to look for enhancing lesions for risk of MS. If MRI is normal, risk of MS within the next 10-15 years will drop to 25%. It won't eliminate it but at least it will make it less!
- IV steroids may speed up the recovery process but does not influence the final outcome. It is important to let the patients know that we give them steroids not to improve the visual outcome. Patients who take or do not take steroids will eventually improve if it is typical optic neuritis. Oral is contraindicated because of high recurrence rates [RCT: optic neuritis treatment trial]
- Good recovery.

● **Ischemic optic neuropathy (ION)** “disease of the old”

Non-arteritic ION	<ul style="list-style-type: none"> - Patients often have DM, HTN and other vascular risk factor. - Most common cause in older patients. above 40 years to 50. - Altitudinal visual field loss. Superior or inferior. - Treatment: no treatment, ask them to control the risk factors to protect the other eye.
Arteritic ION important	<ul style="list-style-type: none"> - (> 55) years old, associated with giant cell arteritis. Older than non-arteritic ION. - Present with severe irreversible visual loss (counting finger) more than non-arteritic (20/200) - Check: jaw claudication, proximal myalgia & arthralgia, scalp tenderness/pulseless, headache. - Elevated erythrocyte sedimentation rate (ESR) and C-reactive protein (CRP). - Temporal artery biopsy is the gold standard for diagnosis. - Treatment: systemic steroids, given immediately if suspected even before the biopsy, patient should not leave the ER without it to protect the other eye (within the first day they will go blind) - Binocular involvement occurs in third of cases, often within the first day.

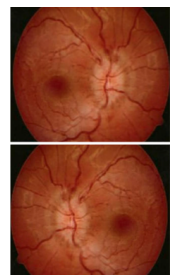
● **Congenital disc elevation (< 1 %)** *missing pictures from new slides*

- Optic disc margins blurred and the cup is absent but **NO** edema or hemorrhage can be observed.
- May be associated with hyperopia or drusen (**high reflective calcium salts**)
- You have to differentiate between congenital disc elevation & optic disc swelling (which requires neuroimaging, invasive investigations...etc looking for a reason)

Image		
Diagnosis	Optic disc swelling/edema (pathological)	Congenital disc elevation (pseudopapilledema)
Margins	Unclear. Hue around the disc (fluids)	Unclear without edema (fluids)
Blood vessels	Untraceable. Not clear because of fluids.	Very clear sharp vessels.
Drusen		Present
Abnormal branching		Present
Hemorrhage	Peripapillary hemorrhage	NO hemorrhage

● **Papilledema very important, an emergency**

- **Causes:** send all patients for neuroimaging: MRI + MRV (to rule out cavernous sinus thrombosis)
 - Intracranial mass you have to rule it out.
 - Severe systemic hypertension. **check blood pressure for malignant HTN, controlling BP will make it subside.**
 - If MRI is normal (no lesion) → Idiopathic intracranial hypertension (previously known as pseudotumor cerebri).
Common in: young, slightly obese, female, **OCPs, tetracyclines** | **Presentation:** headache, tinnitus and visual obscuration she says “لما أسجد الدنيا تسود ثواني” | **Treatment:** Diamox (Acetazolamide: carbonic anhydrase inhibitor) it works by suppressing the production of the CSF **NOT** by its diuretic effect.

<ul style="list-style-type: none"> - Bilateral swelling of the optic discs secondary to increased intracranial pressure. - Hyperemia of the disc. Tortuosity of veins & capillaries. Blurring & elevation of disc margins. - Peripapillary flame shaped haemorrhages. Sign for acute papilledema. - Examination: take your time to look for spontaneous venous pulsations. It will be seen with the majority of normal patients. If visualized, the CSF pressure is typically less than 200 mm H₂O. (good & reassuring sign) [ICP cut point in adult: 250 mm H₂O or 25 cm H₂O] If you don't see it that doesn't mean it is papilledema, 20% of the normal population don't have it. If you're following-up with the patient and it was present at first then it disappeared → increased ICP 	
---	---

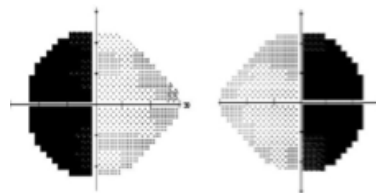
● Other causes of optic neuropathy

- Infection: viruses, **TB**, cryptococcus and **syphilis**.
- Systemic connective tissue disease: **SLE**.
- Genetics : **Leber's optic neuropathy** (through a **mitochondrial** DNA mutation) If a male patient with Leber's optic neuropathy asked you about the risk of having a child with the same disease since it is heredity, what will be your answer? **0%** because of **maternal** inheritance, it is passed to both males and females the same. However, it shows on males more than females.
- Toxic and nutritional deficiencies. especially with young patients.
- Trauma.

MCQ

A patient presented with this visual field defect. Which one of the following diagnosis is the most Likely?

- a) Optic neuritis
- b) Tilted discs
- c) Pituitary tumor
- d) 6th nerve palsy



Answer: C

Extra from 435 team

- **Neuro-ophthalmology** also deals with ocular problems caused cranial Nerves and pupil pathway.
- **The key to diagnosis of pupillary disorders is to:** determine which pupil is abnormal & search for associated signs.
- **Disorders of the pupil may result from:** Ocular disease, Disorders of neural pathway, Pharmacological action.
- **Several diseases of the eye can cause pupil irregularity and alter pupil reactions:** Anterior uveitis, Intraocular surgery - Direct muscle injury, Blunt trauma. Rupture the sphincter muscle, causing irregularity or fixed dilation (Traumatic mydriasis), Acute or chronic High IOP - Acute glaucoma.
- **Tonic pupil:**
 - Is due to ciliary ganglionitis which denervates the parasympathetic supply to the iris and ciliary body. On recovery from the ganglionitis, reinnervation is incomplete and the partially denervated receptors of the iris and ciliary body become super sensitive to muscarinic stimulation.
 - Sluggish, segmental pupillary responses to light. Poorly reactive to light – because few of the innervating fibres were originally destined for the sphincter. Also, because of the irregular fibre distribution, pupil movement in response to light consists of a slow, worm-like (vermiform) contraction, on biomicroscopy.
- Parasympathetic pathway is much shorter than the convoluted sympathetic pathway, so potential causes for damage are more benign. Parasympathetic plexus sits behind the eye and can be damaged after a benign viral infection.
- **Holmes-Adie syndrome:** is a diagnosis of exclusion. Patient most of the time will be asymptomatic. However they might complain of photophobia because of dilated pupil. Sometimes they will have abnormality of accommodation in near vision. We can provide them pilocarpine will release the photophobia and help them with the accommodation It takes few months and the pupil will go back and constrict.
- **Horner's syndrome**
 - May be congenital, in which case the iris colour may be altered when compared to the fellow eye (heterochromia).
 - **Anhidrosis:** when the sympathetic pathway is affected proximal to the base of the skull. This catches fibers travelling with the branches of the external carotid, which innervate the skin of the face.
 - **Enophthalmos** (posterior displacement of the eyeball): due to paralysis of levator palpebrae muscle.
 - **Ptosis:** due to paralysis of muller's muscle.
 - **The sympathetic pathway may be affected by multitude of pathologies like:**
 - Syringomyelia, expanding cavity within the spinal cord.
 - Small cell carcinoma at the lung apex. Involvement of the brachial plexus cause shoulder and arm pain and to T1 wasting of the small muscles of the hand (Pancoast's syndrome).
 - Neck injury, disease or surgery.
 - Cavernous sinus disease - catching the sympathetic carotid plexus in the sinus.

○ **Do we need to image the patient urgently or give him the next available appointment?**

- Acute or chronic: Acute within 2 weeks: immediate neuroimaging. | Chronic within several months or he has a surgery: follow up.
- Painful or painless: Painful: immediate neuroimaging.

Table 13.1 Drugs having a pharmacological effect on the pupil.		
Agent	Action	Mechanism
Topical agents		
Dilates	Muscarinic blockade	Cyclopentolate
		Tropicamide
	Alpha-adrenergic agonist	Atropine (long-acting)
		Phenylephrine
Constricts	Muscarinic agonist	Adrenaline
		Pilocarpine
Systemic agents		
Dilates	Muscarinic blockade	Atropine
	Alpha-adrenergic agonist	Adrenaline
Constricts	Local action and action on central nervous system	Morphine

Table 15.1 The causes of isolated nerve palsies.	
Orbital disease	e.g. neoplasia
Vascular disease	Diabetes (a 'pupil sparing' third nerve palsy, i.e. there is ptosis and extraocular muscle palsy but no mydriasis)
	Hypertension
	Aneurysm (most commonly a painful third nerve palsy from an aneurysm of the posterior communicating artery. Mydriasis is usually present)
	Carotico-cavernous sinus fistula (also causes myogenic palsy)
	Cavernous sinus thrombosis
Trauma	Most common cause of fourth and sixth nerve palsy
	Meningioma
	Acoustic neuroma
Neoplasia	Glioma
Raised intracranial pressure	May cause a third or sixth nerve palsy (a false localizing sign)
Inflammation	Sarcoidosis
	Vasculitic (i.e. giant cell arteritis)
	Infection (particularly herpes zoster)
	Guillain-Barré syndrome

- Medial and lateral rectus muscles have only horizontal actions.
- Superior and inferior rectus muscles are the primary vertical movers of the eye.
- **2 Oblique muscles:** Superior and Inferior oblique muscles.
- This vertical action is greatest with the eye in the abducted position.
- The secondary action of vertical rectus muscles is torsion. The superior rectus is an incyclotorter (inwards rotator), and the inferior rectus is an excyclotorter (outwards rotator). The tertiary action of both muscles is adduction.
- Yoke muscles are the primary muscles in each eye that accomplish a given version (eg, for right gaze, the right lateral rectus and left medial rectus muscles). Each extraocular muscle has a yoke muscle in the opposite eye to accomplish versions into each gaze position.

- **Quick introduction to Isolated nerve palsy: "u can skip it if u want"**

- **Pathogenesis:**
 - Disease of the third, fourth and sixth nerves and their central connections gives rise to a paralytic strabismus.
 - Each nerve may be affected at any point along its course from brainstem nucleus to orbit.
- **History and examination:**
 - The patient complains of diplopia. There may be an abnormal head posture to compensate for the inability of the eye to move in a particular direction.
 - A sixth nerve palsy results in failure of abduction of the eye.
 - A fourth nerve palsy results in:
 - * Defective depression of the eye when attempted in adduction.
 - * It produces the least noticeable eye - movement abnormality.
 - * Patients may notice vertical double vision with some torsion of the image, particularly when going downstairs or reading.
 - A third nerve palsy results in:
 - * Failure of adduction, elevation and depression of the eye.
 - * Ptosis.
 - * In some cases, a dilated pupil due to involvement of the autonomic fibres.

- **Fourth nerve palsy:**

- **If you want to rule out 4th cranial nerve palsy along 3rd nerve palsy what will you do?** Ask the patient to look down, if the eye intorted the 4th cranial nerve is intact.
- The fourth cranial nerve is the skinniest nerve and runs the longest distance inside the cranial vault. This long passage makes it more susceptible to injury and neoplasm. The fourth nerve is also susceptible to being pulled from the root where it exits from the back of the brainstem. Trochlear paralysis is the hardest cranial nerve palsy to diagnose.

- More fourth palsies occur in elderly males from trauma and more congenital palsies are found in the pediatric population.

- Ocular myasthenia gravis (OMG), other tests:

- **Ice test:** ask the patient to put an ice pad over the ptosis for two minutes and then check for any improvement (measure the degree of ptosis after) may be helpful in establishing that ptosis is due to ocular myasthenia gravis, since cold improves neuromuscular transmission.
- **Sleep test:** measure the degree of ptosis then ask the patient to sleep and re-measure after the patient awakes (improvement = positive test)

- Visual pathway disorders:

- Visual field defects: if unilateral then think about optic nerve pathology, if bilateral then the pathology is at the optic chiasm or beyond.
- Chiasmal defects are always bitemporal.
- Homonymous visual defects could be due to stroke or tumors.
- Left eye blindness due to Left optic nerve damage
- Binasal hemianopia due to bilateral carotid artery aneurysm compressed optic chiasm
- Bitemporal hemianopia due to pituitary tumor compressing optic chiasm
- Right Homonymous hemianopia due to Left optic tract damage
- Right superior quadrantic hemianopia due to Left optic radiation at temporal lobe lesion (pie in the sky)
- Right inferior quadrantic hemianopia due to Left optic radiation at parietal lesion (pie in the floor)

- Optic neuritis:

- Is termed **papillitis** if the optic nerve head is affected and **retrobulbar neuritis** if the optic nerve is affected more posteriorly with no disc swelling.
- Patient will come with sudden visual loss/ visual field loss/ color vision loss which may progress over a few days and then slowly improve.
- Signs: positive afferent pupillary defect. Optic disc edema (**Normal disc in retrobulbar neuritis; a swollen disc in papillitis.**) Ocular pain while moving the eye. **Why ocular pain happened?** Because **optic nerve sheath is attached to medial rectus muscle sheath.** In retrobulbar neuritis because rectus muscle contraction pulls on the optic nerve sheath.
- Vision slowly recovers over several weeks, although often it is not quite as good as before the attack. Repeated episodes may lead to optic atrophy, a decline in vision and a persistent scotoma.

- Relative Afferent Pupillary Defect (RAPD, Marcus Gunn Pupil):

- An RAPD is a defect in the direct response. It is due to damage in optic nerve or severe retinal disease.
- It is important to be able to differentiate whether a patient is complaining of decreased vision from an ocular problem such as cataract or from a defect of the optic nerve. If an optic nerve lesion is present, the affected pupil will not constrict to light when light is shone in the that pupil during the swinging flashlight test. However, it will constrict if light is shone in the other eye (consensual response). The swinging flashlight test is helpful in separating these two etiologies as only patients with optic nerve damage will have a positive RAPD.

- Ischemic optic neuropathy:

- The anterior optic nerve may become ischemic if the posterior ciliary vessels are compromised as a result of degenerative vaso-occlusive or vasculitic disease of the arterioles, which result in an **anterior ischemic optic neuropathy.**
- Is the usual cause of blindness in the disease.

- Arteritic optic neuropathy:

- Signs: Reduction in visual acuity, Field defect, Swollen and hemorrhagic disc with normal retina and retinal vessels – in AIOP the disc is swollen and very pale. (unlike NAIOP where the disk is swollen but it is not pale), (Remember the blood supply to the anterior optic nerve and retina are different), Tender temporal artery, suggestive of giant cell arteritis, Binocular involvement occurs in third of cases, often within the first 2 days, small normal fellow disc with a small cup in non arteritic disease.
- Autoimmune vasculitis: It affects arteries with an internal elastic lamina, which therefore includes the ophthalmic artery, but NOT the retinal artery.
- Scalp tenderness “e.g. on combing”, pain on chewing “jaw claudication”..
- GCA can also present as a central retinal artery occlusion when the vessel is affected secondarily to arteritis of the ophthalmic artery.
- **Investigations:** Platelets may also be raised. If NAIOP; do CBC to exclude anemia, check BP and blood sugar. “Both hypertension and diabetes may be associated with the condition”.

- Temporal artery biopsy is the gold standard for diagnosis. But again may not lead to a diagnosis. (it should be long enough because it has skipping lesion criteria (2.5 length))
- **Drusens:** "yellow deposits under the retina made up of fatty proteins". B-scan ultrasound can discover drusen (lipid collections)
- **Papilledema:**
 - **Symptoms:** Headache, worse on awakening and made worse by coughing, Nausea and vomiting if the raise in ICP is severe, may be followed by loss of consciousness, pupillary dilatation and death, Pulsatile tinnitus, visual symptoms often are absent [In the short term there is no visual loss. However, in some patients with advanced papilloedema, a fleeting visual loss may occur, lasting seconds, when posture is altered from lying to standing (*obscurations of vision*)], Diplopia (Double vision), due to 6th nerve palsy.
 - **Signs:** There is no spontaneous venous pulsation of the central retinal vein: This has a physiological basis. The central retinal vein is exposed to CSF in the subarachnoid space of the optic nerve, as it leaves to join the veins of the orbit. Normally, venous pressure in the retinal veins at the nerve head is just above ocular pressure. Venous pulsation occurs because the vein collapses briefly with each rise in ocular pressure caused by arterial inflow during systole. When the CSF pressure is higher than the ocular pressure, as in papilloedema, the pressure in the veins at the disc rises above the ocular pressure and spontaneous venous pulsation is lost.
 - **DDx:** Adult optic neuritis, Hypertension, Idiopathic intracranial hypertension, Pseudopapilledema (Some normal optic nerve heads appear to be swollen, due a crowding of nerve fibres entering the disc. This is termed pseudopapilledema and occurs particularly in small, hypermetropic eyes where the nerve entry site is reduced in size)
 - **Investigations:** CT or MRI followed by lumbar puncture (to measure the ICP and rule out meningitis, Papilledema is a diagnosis of exclusion should be confirmed by lumbar puncture), B-scan ultrasonography to rule out buried disc drusen. Fluorescein angiography.
 - **Treatment:**
 - Medical: Diamox, diuretics
 - Surgical:
 - * Optic nerve fenestration: slit cut of optic nerve sheath > fluid will come out and release the compression
 - * Shunt: for patient who has severe headache and blurred vision.
- Papillitis: edematous or inflamed optic dist.
- Important signs in optic nerve disease: blurring of the margins, splinter hemorrhage in the peripapillary area, edema and elevation of the disc.
- The presence of hemorrhage = acute raise in the pressure.