



History and Examination

Objectives

- To know the basic ophthalmic anatomy and physiology.
- To recognize assessment and management of common ophthalmic diseases.
- To know how to handle common ophthalmic emergencies.
- To handle simple ophthalmic diagnostic instruments.
- To be aware of common ophthalmic operations.

Done by: Abdulrahman Al-Shammari & Kayan Kaaki

Edited by: Munerah alOmari.

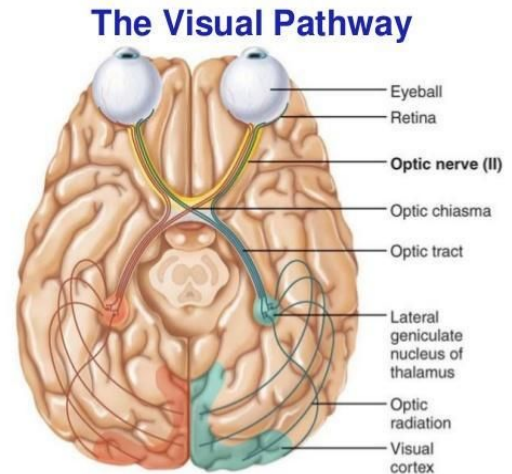
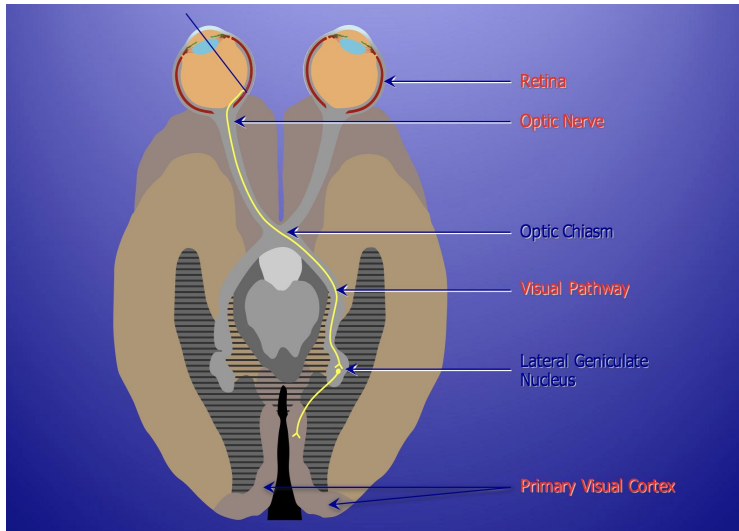
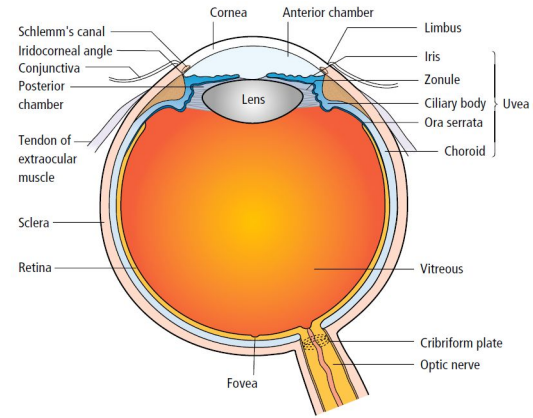
Revised by: Adel Al Shihri, Lina Alshehri.

Resources: Slides + 434 Team + Notes

[**Color index:** **Important** | **Notes** | Extra]

The Visual Pathway

Light enters the eye via a refractive media called cornea, then pass's through anterior chamber, lens, and vitreous then stimulates the retina photoreceptors(1st order neurons) posteriorly (Rods and cones). Through a series of other retinal cells, the end result is that the RGCs¹(2nd order neurons) stimulated, then it will send it's axon(to the Lateral geniculate ganglia then lateral visual cortex) or fibers, in the nerve fiber layer to the optic disc and then down to the optic nerve. In order to see, you need clear media, but if it's not clear it called media opacity(so in OSCE the absence of red reflex in ophthalmoscopic exam is called **media opacity**) **Media opacity** caused by (hyphema, scar, cataract, vitreous haemorrhage, retinal detachment).



(Pictures may come in saq and ask you to identify for example: The Primary visual cortex or the Lateral Geniculate nucleus)

From the optic nerve, about half (55%) of the fibers cross over at the chiasm to the opposite optic tract, and the other half remains at the same side. the fibers in the optic tract synapse in the lateral geniculate nucleus of the thalamus. neurons in the lateral nucleus projected to the occipital lobe to the primary visual cortex. From there, there is further processing with projections to other cells in visual cortex and elsewhere. result in conscious visual perception

¹ (retinal ganglion cells)


Importance of Eyes

- Diagnostically and functionally, it is the most important **square inch** of the body surface.
- The eye is so intimately connected with the rest of the body (vascularly and neurologically) that it reveals enormous amount of general information.
- Eye is the only part of the body where blood vessels and central nervous system tissues can be viewed directly.
- 90% of our information reaches our brain via sight
- Unfortunately, of all the parts of the body, the eye is the most vulnerable to minor injury.

Neuronal Connection:

- The 12 cranial nerves provide us with a large part of our information about the brain. Of these, the eye examination evaluates CN II, III, IV, V, VI, VII, VIII (7 CNs).
 - CN II(Optic): Visual Acuity **best connection**.
 - CN III(Oculomotor): Eye Movement + Pupil Examination
 - CN IV(Trochlear): Superior oblique Muscle
 - CN V(Trigeminal): Sensation
 - CN VI(Abducent): Lateral Rectus muscle
 - CN VII(Facial): Facial Nerve paralysis (they can not close their eyes)
 - CN VIII(Vestibulo-cochlear): Nystagmus.
- Provides information about the autonomic pathways.(sympathetic/parasympathetic)
Remember :sympathetic : dilatation of the pupil /Parasympathetic : constrict the pupil.
- Best known connection between the brain and the eye is the optic nerve (ON).
- Visual pathway, which extends from front to back across the brain can be studied easily and safely using perimetry². It can differentiate accurately between lesions of the temporal, parietal and occipital lobes.
 - In SAQ there was question> visual field with quadrantic defects. so it will be either temporal or parietal lobe. if there is lesion in the temporal lobe = pie in the sky(upper quadrantic hemianopia). If the lesion in the parietal lobe = pie in the floor(lower quadrantic hemianopia)
- Optic **Nerve** has important clinical relationships to the pituitary gland, the middle ventricles, the venous sinuses, the meningeal and bony structures of base of the skull

Pituitary gland and Visual Field

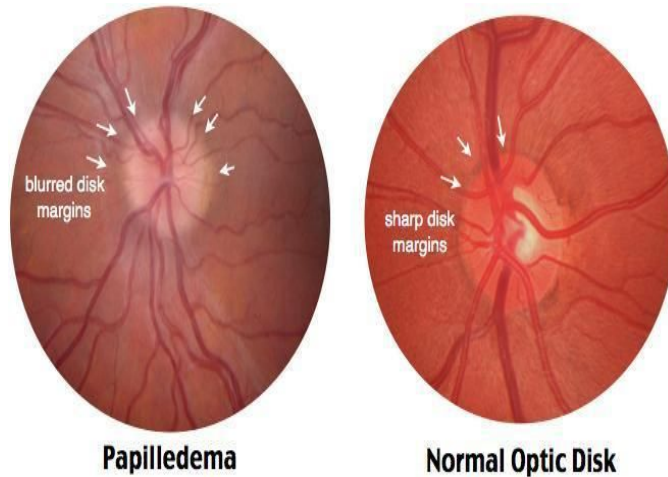
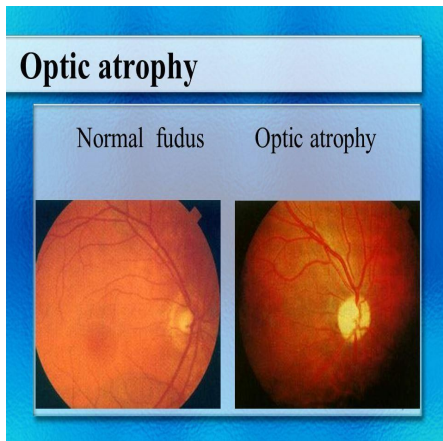


It may come in SAQ :

you know that the fiber decussate in optic chiasma so if the lesion was pituitary gland Adenoma so the defect will be **bitemporal hemianopia**. and what will give me **Binasal hemianopia**? If there is compression in the **carotid due to pressure on the temporal fiber**


² Perimetry is the systematic measurement of visual field function.

- **Optic Nerve** has the diagnostically useful capability of swelling with \uparrow ICP (papilledema) optic discs edema (unclear disc margin best answer will be disc edema in OSCE, rather than Papilledema) to detect increase in ICP help to diagnose **brain tumor**.
- **Optic Nerve** could be visibly pale (**optic atrophy**) when its nerve fibers damaged at any point from Retina \rightarrow LGB.



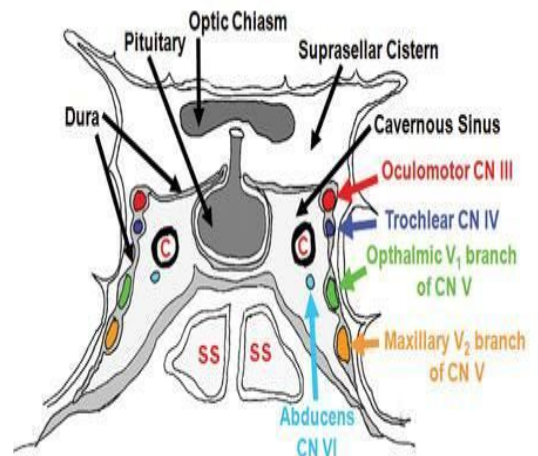
What's the difference between papilledema and pale disc pallor? the color, if color is pale=optic atrophy if eye is congested, bleeding or blood around the edematous optic nerve=papilledema

- Study of the cranial nerves III, IV, V, VI can evaluate the brain stem, cavernous sinus, apex of orbit (B/c they are close to each other)
- Unilateral dilated pupil after head injury can occur due to pressure on pupil constrictor fibers of CN III. (*Brain Herniation, Hemorrhage, Aneurysm of posterior communicating artery that compress CN III*)
- CN VI involved in mastoid infection (petrous ridge)
- Parotid gland, Inner ear disease \rightarrow CN VII.
- Nystagmus \rightarrow CN VIII

Very important pic: content of cavernous sinus ([Click Here](#)) 

- mandibular nerve or third division of trigeminal nerve pass through foramen ovale.
- Abducens nerve is longest and important in trauma so in (six nerve palsy) you have to ask about trauma.
- phacomorphic glaucoma (cataract induced glaucoma by increase lens size that lead to increased IOP) > so severe pain.
- optic neuritis (demyelinating inflammation of the optic nerve).

Commonest cause of abducens nerve palsy? TRAUMA. Why? because it has a very long course and each course is perpendicular to each other



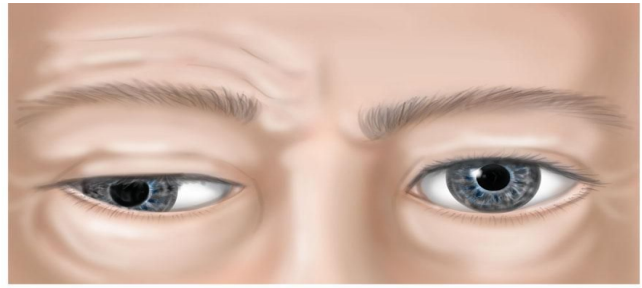
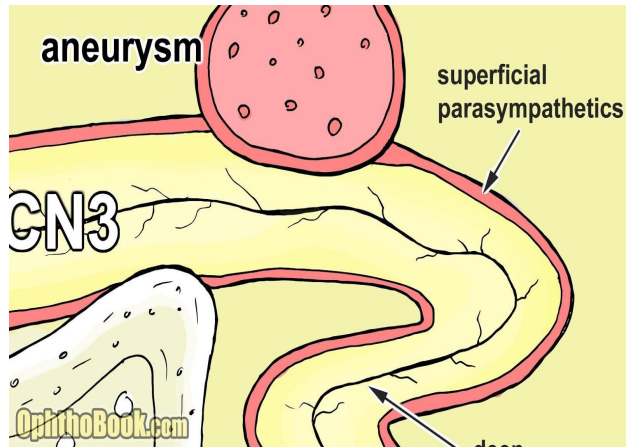


Figure III-13 Appearance of the eyes in right third nerve palsy. The right side of Werner's face illustrates: a wrinkled brow due to the inability to raise the right eyelid; ptosis of his right eye lid due to the inactivation of the levator palpebrae superioris muscle; dilation of his right pupil due to the decreased tone of the constrictor pupillae muscle; and downward and outward movement of his right eye due to the unopposed action of the right superior oblique and lateral rectus muscles.

From Cranial Nerves 3rd Ed. ©2010 Wilson-Pauwels, Stewart, Akesson, Spacey, PMPH-USA

- remember all the muscle of the eye are supplied by third cranial (it has motor and sensory fibers) nerve except lateral rectus (CN6) and superior oblique (CN4), so there will be restriction in all eye movement except Lateral rectus(Horizontal lateral movement/Abduction) and superior oblique (obliquely downward & lateral), that will be represented in **lateral movement of the eye and ptosis** .
- CN III is composed of 2 parts **very important the difference between them**:
- Superficial parasympathetic pupillomotor Usually affected by compression. (aka dilated surgical 3rd nerve palsy)third nerve palsy **with** dilated pupil mean the lesion affect superficially the parasympathetic then its affects the muscle so that mean there is tumor or posterior complicated artery aneurysm(very dangerous.. can rupture causing death) >> emergency condition

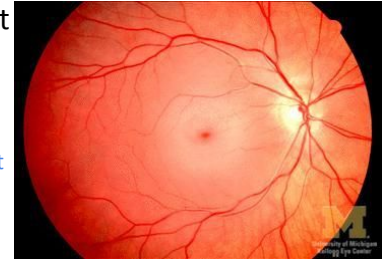
****QUESTION: What to order for investigation if you have a patient with 3rd nerve palsy with dilated pupil? Order a CT ANGIO or MRA (angio)**

- Deep motor(muscular abnormalities) Usually affected by medical causes like DM\HtN causing vascular occlusion (aka medical 3rd nerve palsy) third nerve palsy **without** dilated pupil >> the lesion affected the blood supply, like in blood, systemic disease (hypertension , diabetes ..)
- **How do we know if CN IV is involved in addition to CN III ?**
 - Patient will not be able to **look down** (damaged CN III)
 - Eyes will **not intort** (damaged CN IV)
- **Focal brain lesions**
 - Visual Field defect
 - Vascular occlusions
 - Hemorrhage
 - Neoplasm
- **Diffuse brain lesions**
 - Infections
 - Demyelinating disorders → nerve damage

Venous Flow Disorders:

- **cavernous sinus thrombosis**
- **carotid – cavernous fistula** (it has the same clinical presentation (proptotic, retinal edema) of cavernous sinus except that it has increased IOP, and Thrill+pulsating eyes (Bruit)
 - Bilateral carotid artery aneurysm Binasal Hemianopia.
- **Arterial emboli** can reach the retina from carotid artery, heart valves, subacute endocarditis.also traumatic bone fracture.
Came in the exam: central retinal artery occlusion/ history: of multiple bone fraction , what is the diagnosis? Retinal central artery fat embolism.
- Case: a 60 year old pt w/ heart disease and using penicillin injections (meaning that he has bacterial endocarditis and might have a possibility of embolism manifestations leading to central retinal artery occlusion)

Central artery occlusion: PALE retina with Cherry Red spots



Specific Diseases of vessels

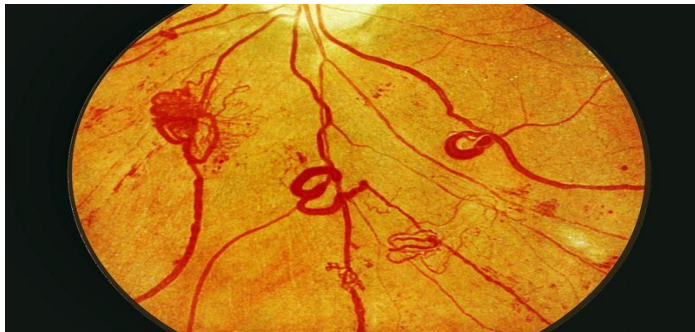
- PAN, HTN, temporal arteritis (Giant cell Arteritis)
- investigate the patient with ESR, CRP, BIOPSY. (Best initial investigation is ESR, followed by C-reactive protein, then Biopsy(a negative biopsy does not rule out the dx due to the focal and segmental nature of the infiltrates)
- When a patient complain of any changes in vision, rule out DM first!

Hematological

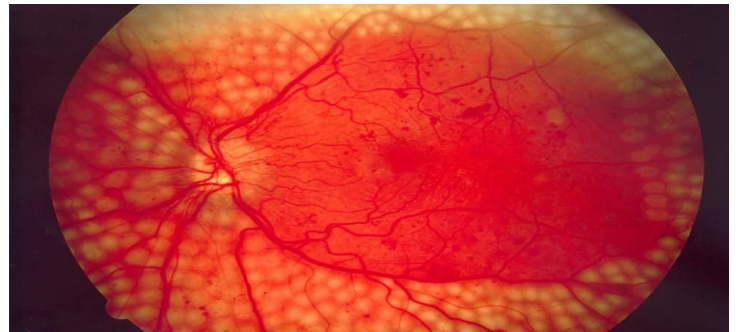
- All types can manifest in the fundus. (Anemia, leukemia, AIDS)
 - AIDS you can also diagnosed by cotton wool spots in the retina (ischemia of the nerve fiber in the retina)

Metabolic disorders

- **DM** :Diabetic Retinopathy , cataract, Refractive Errors, ophthalmoplegia.(PDR)
treated with pan-retinal laser photocoagulation
- **Hypoparathyroidism** : cataract
- **Wilson's disease**. Kayser-Fleischer corneal ring (a brownish-yellow ring around the cornea of the eye).



A



B

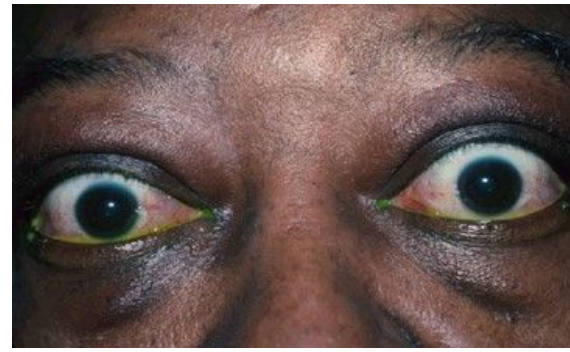A: New dilated tortuous proliferative vessel in the retina in diabetic retinopathy

B: Retinal Scars from retina lesser (this pic is after treat above condition)

(WE NEVER GET AN EXAM WITHOUT DIABETIC RETINOPATHY we might change the picture to another one but with the same diagnosis)

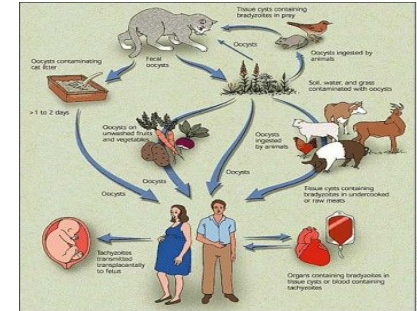
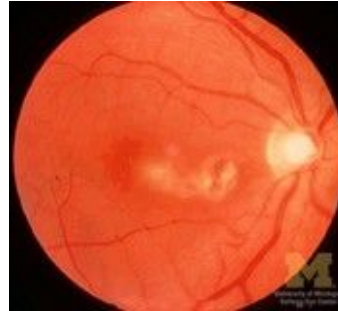Thyroid eye disease:

- Also known as **infiltrative ophthalmopathy** "Graves ophthalmopathy" or thyroid eye disease.
- Since they have **increased IOP** we perform visual field exam.
- Commonest cause of **unilateral and bilateral proptosis, Exophthalmos, Lid retraction.**



Infections:

- Syphilis
- Toxoplasmosis
- Rubella

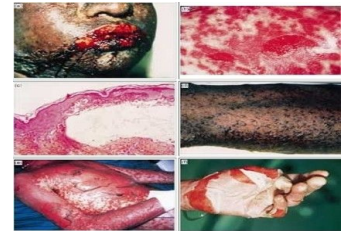

Elastic Tissue

- (Pseudoxanthoma elasticum)

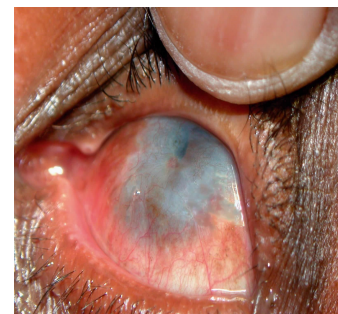
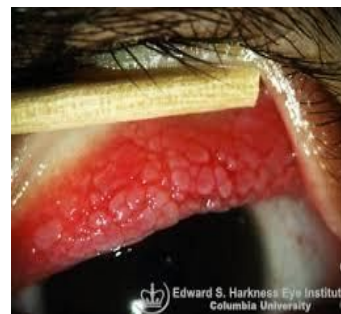Mucocutaneous Disorders

- Steven-Johnson Syndrome, pemphigus



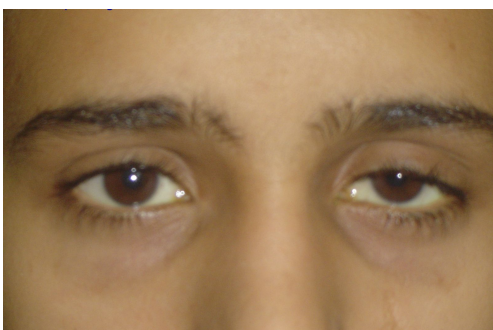Allergy

- Vernal keratoconjunctivitis (VKC)(will have allergy and cobblestone papillae)
known by Spring catarrh الرمد الربيعي "Commonest eye allergy in KSA Treat with steroids and antihistamines. Can cause blindness. Why? Chronic use of topical steroids lead to increased IOP (steroid induced glaucoma)
-we start the treatment with Antihistamine and cold water and leave steroid as the last resort although it is the best treatment for them but can lead to glaucoma and cataract



Chromosomal Abnormalities

- Trisomy:13,15,21.



What's the abnormality? Unilateral Ptosis
What the diagnosis? Amblyopia (most common cause of unilateral ptosis in pediatrics)

Eye Poisoning

- Morphine addict lead to meiotic pupil.
- Lead poisoning, vitamin A intoxication lead to papilledema
Coma+pinpoint pupil = Morphine overdose or Pontine hemorrhage
(Differentiate between them by hyperpyrexia with Pontine hemorrhage).

History and Physical Examination

- Example of pt who has acute loss of sight or blurred vision for 20 minutes only or less? Migraine is the best example of a patient who will come complaining of loss of sight(blurred vision) with headache and nausea

Important Terms:

- Age related Macular degeneration they complain of altered image ملخبطة will complain of Metamorphopsia
- Diplopia is double vision - Floater is خيالات قدام العين - Photopsia is seeing flashes of light
- Oscillopsia is shaking of the eye - Asthenopia is tired and fatigue eye
- Red eye has two types: one around the limbus called ciliary injection PAINFUL and one in the periphery called conjunctival injection NON-painful
- Anisocoria is different size of pupils
- Anisocornea is different size of the cornea
- Anisometropia different refractive errors between both eyes

MCQ: Myopic patient -12, he got retinal detachment, what is his symptoms? Mainly floaters and flashes

History:

- It is gathering information process from the patient guided by an educated and active mind.
- It is a selective guided and progressive elicitation and recognition of significant information.
- History by skilled person can arrive at the proper diagnosis in 90% of patient.
- It gives vital guidance for -physical examination -laboratory work -therapy.
- Failure to take history can lead to missing vision or life threatening conditions.

◆ Chief Complaint

(The patient's own words) **“She can not see with right eye”** (ask about distant or near because the patient might be more than 40 years old and cannot see near which is normal for this age which is called Presbyopia)

- You should not come to conclusion that her problem is nearsightedness and write down(Myopia of RE).
- The patient needs will not be satisfied until he\she has received an acceptable explanation of the meaning of the chief complaint and its proper management.

◆ History of presenting illness

- Detailed description of the chief complaint to understand the symptoms and course of the disorder.
- Listen and question and then write down in orderly sequence that make sense to you.
- The time sequence (when, how fast, what order event occur?).
- Frequency and intermittency.
- Location and laterality.
- Severity.
- Associated symptoms.
- Documentation (old record and photo indicate ptosis, proptosis and VII N palsy).

■ Examples

Gradual painless decrease vision both eyes for 1year, Sudden painless decrease vision RE for 10 min.

Cannot see with right eye(RE)!!

- Only distance vision **blurred**?
- **Blind spot** is present in the center of visual field (VF)?
- Right side of visual field of the RE lost?
- Right **VF** of both eye lost?
- A diffuse **haze** obscures the entire field of RE?
- Each of these has different diagnostic implication
- Most patient has difficulty providing precise and concise description

■ Disturbance of Vision

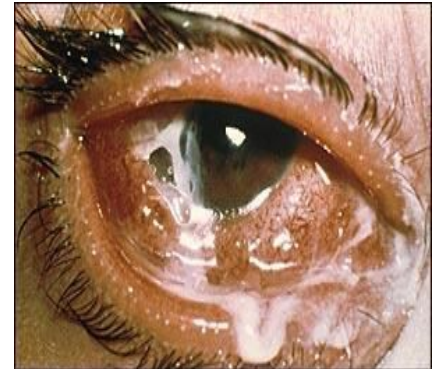
- Blurred or decreased central vision.
- Decreased peripheral vision (glaucoma).
- Altered image size(micropsia, macropsia and metamorphopsia).
- Diplopia(monocular and binocular).
- **Floater** (pt see something moving around and no body else see it. this is because that there is an object in vitreous chamber when crosses the central part of vision > pt see it. pt with DM or have hemorrhage in eyes will have floaters).
- **Photopsia**(flash of light).
- Color vision abnormalities.
- Dark adaptation problems.
- **Blindness**(ocular and cortical).
- **Oscillopsia**(shaking of images).

● DDX of Acute Visual Loss

1. Age related macular degeneration(AMD).
2. Vascular occlusion(DM,HTN).
3. Retinal detachment.
4. Acute glaucoma.
 - **Morning** visual disturbances > Eye **dryness**.
 - **Blurring** of vision for **20 min** > Migraine aura
 - Patient still complains of problems with his\her vision although all his exams and investigation are **normal** > Do visual field exam (could be stroke!).
 - There are two types of color blindness. complete and partial (most common), both are diagnosed by ishihara's test.
5. A"Convergence insufficiency" is a condition that can cause pain especially in pediatric patients.
 - Refractive errors never cause pain Ciliary injection (red eye) is mainly caused by 4 things:
 1. Acute conjunctivitis
 2. Acute iritis
 3. Acute glaucoma
 4. Acute keratitis (*corneal ulcer; a combination of conjunctivitis and iritis*)

■ Ocular Pain/discomfort

- Foreign body sensation (ask pt about to have hair or sand in their eyes)
- Ciliary pain (*aching, severe pain in or around the eye, often radiating to the ipsilateral forehead, molar area*) Photophobia
- Headache
- Burning
- Dryness
- Itching: *patient rub the eye vigorously (allergy)*
- Asthenopia (*eye strain*)
- Abnormal ocular secretions
- Lacrimation, epiphora
- Dryness
- Discharge (purulent, mucopurulent, mucoid, watery)

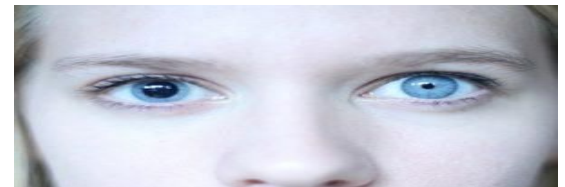

■ Abnormal Ocular Sensation

- Lacrimation, epiphora
- Dryness
- Discharge (purulent, mucopurulent, mucoid, watery) Redness, opacities, masses

■ Anisocoria

- One dilated, one constricted



❖ Family History:

- Many eye conditions are inherited .Examples: RE, glaucoma, strabismus, retinoblastoma, neoplastic, vascular disorders
- Familial systemic disease can be helpful in ophthalmic evaluation and diagnosis. Examples: Atopy, thyroid diseases, DM, certain malignancies
- Ask about any eye problem in the family background?
- Ask specifically about corneal diseases, glaucoma, cataract, retinal diseases or other heritable ocular conditions.

❖ Systematic Review:

- Ask questions designed to confirm or exclude your tentative diagnosis
 - significant positive/significant negative “Significant is equal to expected”
- Predict the physical and lab findings likely to be present
- Any discrepancy between the history and physical examination requires explanation

Ophthalmic Examination:

◆ Visual Acuity

- Vital sign (MUST)
- Good vision: intact neurological visual pathway, / structurally healthy eye, / Proper focus
- Subjective

□ How to test it?

- Display of different- sized targets shown at a standard distance from the eye
- **Snellen chart**
- 20/20, 6/6
- Uncorrected,corrected

□ Testing poor vision


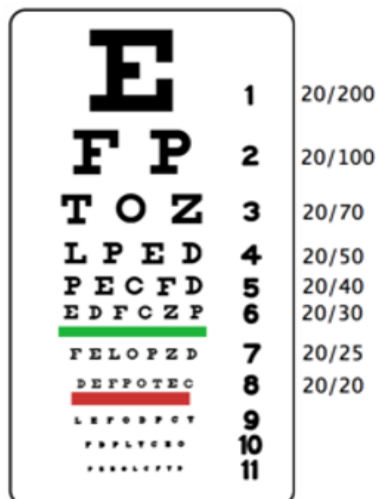
If the patient is unable to read the largest letter <(20/200)

- Move the patient closer e.g.5/200

If patient cannot read:

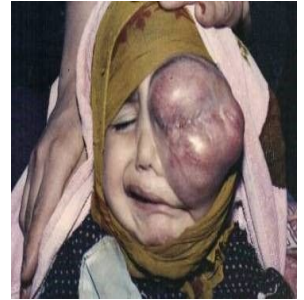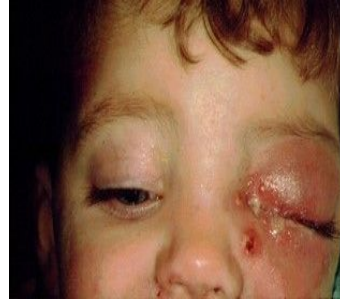- Count fingers (CF)
- Hand motion (HM)
- Light perception (LP)
- No light perception (NLP)

Must know abbreviations because it will come in the scenario and you're not allowed to ask what does it mean



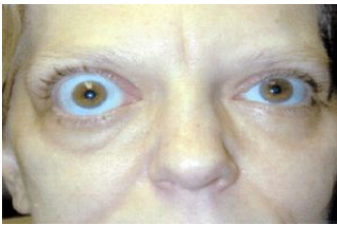◆ External Examination

- Evaluate by gross inspection and palpation
- Ocular adnexa. (lid, periorcular area)
- Skin lesions, growths, inflammatory lesions
- Ptosis
- Proptosis, exophthalmos, enophthalmos

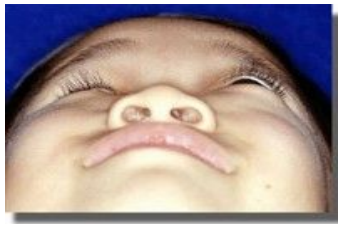

Retinoblastoma is a malignant disease must be caught early. Once you have leukocoria and you catch it early it will be treated either with laser treatment or cryotherapy or enucleate the eye before it turns into retinoblastoma

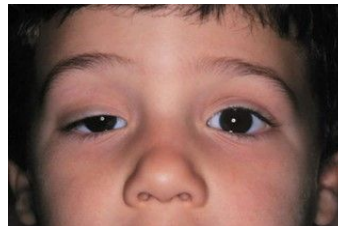- Palpation of bony rim, periorcular soft tissue
- General facial examination e.g. enlarged preauricular lymph node, temporal Retinoblastom. Very artery prominence.



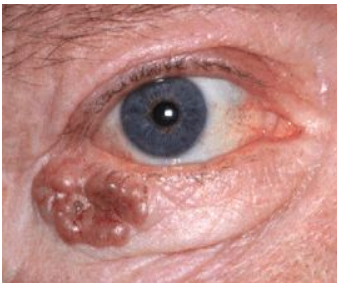
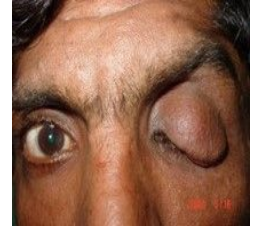Exophthalmos & proptosis
Ptosis



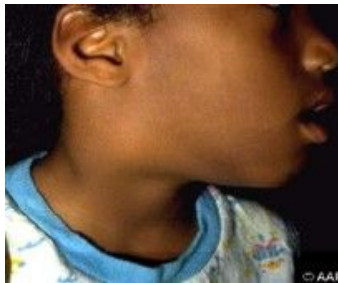Enophthalmos



Partial Ptosis



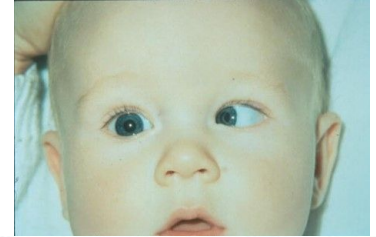Periocular Soft tissue



Lymph nodes

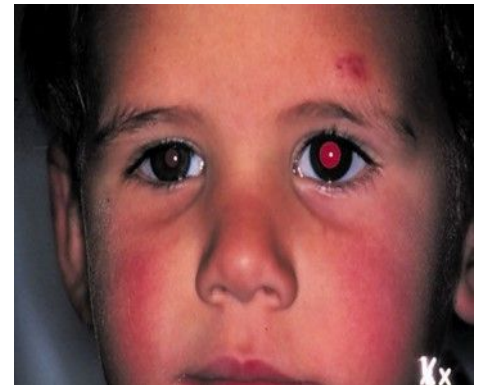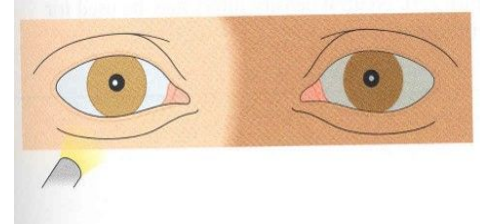
❖ Ocular Examination

- Evaluate: 1-Alignment 2-movement
- Follow a target with both eyes in each of the four cardinal directions of gaze.
 - Alignment:
 - Towards Nose > Esotropia
 - out > Exotropia
- Note:
 - speed /smoothness
 - range
 - symmetry
 - unsteadiness of fixation (e.g nystagmus)



➤ Pupils

- Examine for size, shape, reactivity to both light and accommodation.
- Direct response and consensual response
- Afferent pupillary defect **optic neuritis**(lesion in optic nerve caused by glaucoma , optic nerve compression , diabetic retinal detachment)(APD/Marcus Gunn pupil). you should know exactly how to do it for OSCE!
- Efferent pupillary defect: **third nerve palsy**
- Causes Pupillary abnormalities:
 - neurologic disease
 - previous inflammation—adhesion -acute intraocular inflammation
 - spasm
 - atony
 - prior surgical trauma
 - effect of systemic or eye medication
 - benign variation of normal



❖ Slit Lamp Examination

- Is a table-mounted binocular microscope with special illumination source.
- A linear slit beam of light is projected onto the globe – optic cross section of the eye

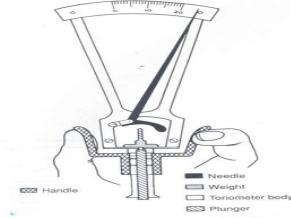
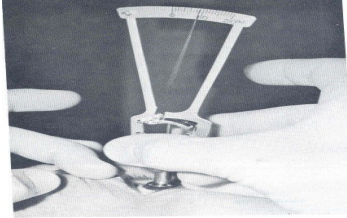


❖ **Tonometry** لا يخلو اختبار من التونومتري


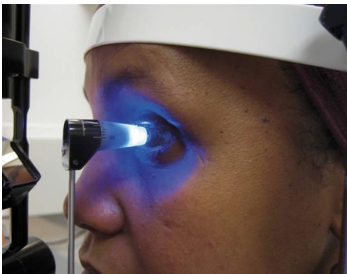
- Tonometry is a procedure performed to determine the intraocular pressure(IOP). It is an important test in the evaluation of patients at risk from glaucoma. Most tonometers are calibrated to measure pressure in millimeters of mercury(mmHg).
- The globe is a closed compartment with constant circulation of aqueous humor.
- This maintains the shape, and relatively uniform pressure within the globe
- Normal pressure 10–21 mmHg

■ **Types of Tonometry:**

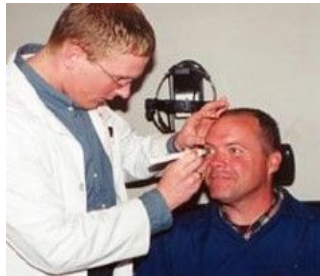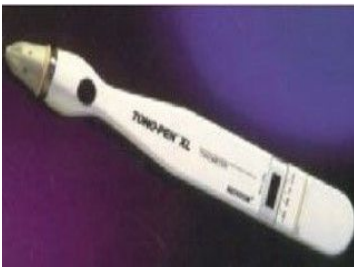→ **Schiotz tonometer** Very important for SAQ! Please make sure you spell the full name right.



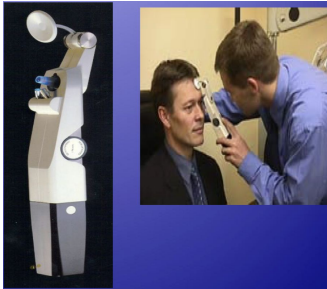→ **Goldmann applanation tonometer** (used to measure intraocular pressure)



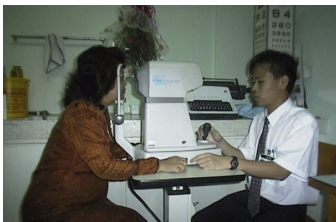→ **Tonopen tonometer**



→ **Perkin Tonometer**



→ **Air-puff tonometer**



❖ Ophthalmoscopy:

- **Direct ophthalmoscopy:**(one eye, big image, no binocularity, small visual field)
 - handheld instrument.
 - standard part of the general medical examination
 - Portable
- **Indirect ophthalmoscope:**(two eyes, large visual field)
 - provides much wider field of view
 - less magnification (3.5X with 20D lens).
 - brighter light source – better view.
 - Binocular – stereoscopic view.
 - Allow entire retina examination till the periphery.

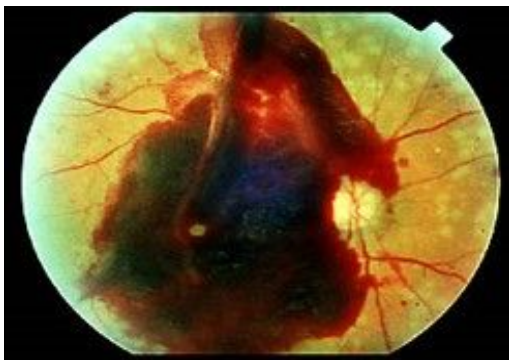

Disadvantage:

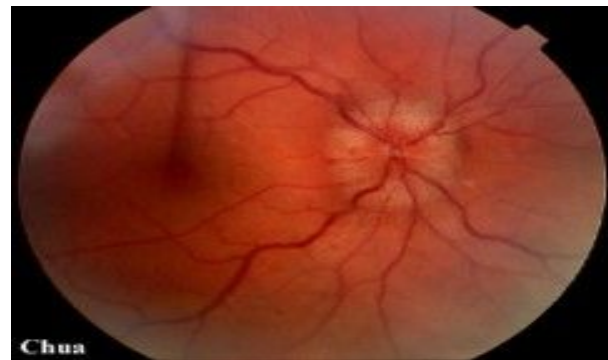- Inverted retinal image.
- Brighter light is uncomfortable to the patient.

Magnification :

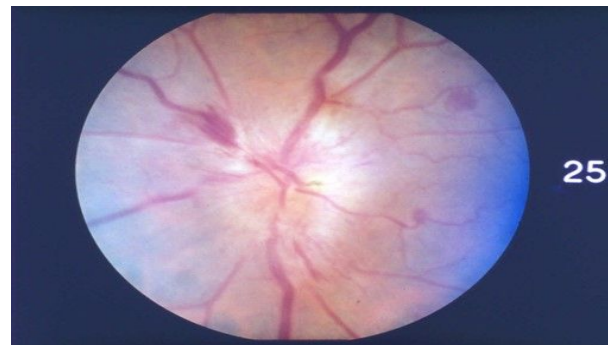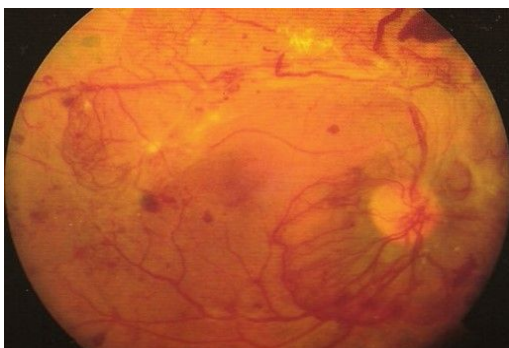
- Direct : 3-5
- Indirect : 15



Vitreous Hemorrhage



Disc Edema

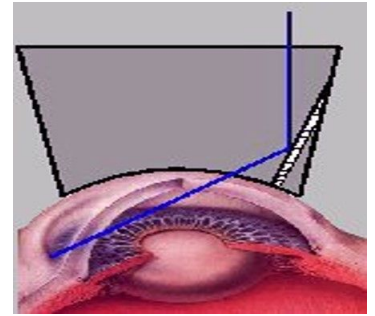



◆ Special Lenses

- Goniolens
- Other lenses allow evaluation of the posterior segment

Importance of Gonioscopy:

important in evaluating anterior chamber : Open angle in chronic glaucoma, Closed angle in acute glaucoma.



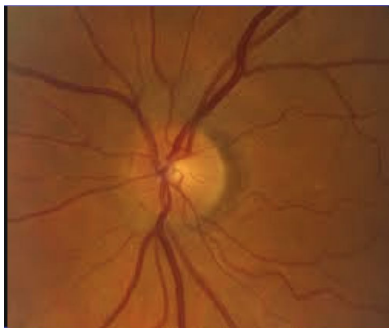◆ Retinoscopy

- Better in children

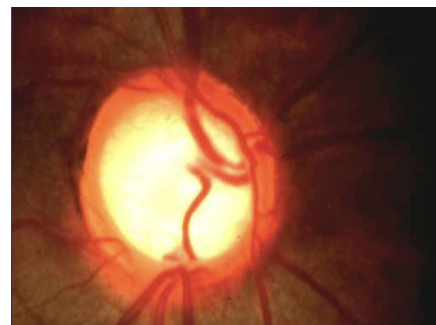


What is Glaucoma? Glaucoma is optic nerve damage and is the commonest cause of optic nerve damage with visual field change with or without increased IOP

What is disc cupping? Disc cupping is pale area in center of optic disc in which the vessels come out. Increasing of it indicates sometimes glaucoma and sometimes could be physiological. So how will differentiate whether it's glaucoma or physiological? based on the 3 other presentations of glaucoma (the IOP, visual field and Disc)



Normal Disc cupping (0.1 0.2 normally)



Abnormal disc cupping (0.7)

Exam • MCQ

A 10-year-old boy came for his annual eye check-up. Upon examination, the doctor noticed cherry red spot in the macular area. What could this sign represent?

- Hydroxychloroquine toxicity
- Niemann pick disease
- Recurrent Optic neuritis
- Severe Central Retinal Vein Occlusion

SAQ34y old lady with h/o of sinusitis. What's the diagnosis and treatment?

a patient with hx of sinusitis will get orbital cellulitis (limited ocular motility) and the treatment is IV Antibiotics. If she didn't have sinusitis then its preseptal sinusitis(full ocular motility) and treatment is oral Antibiotics

