



Basic Anatomy And Physiology

Objectives:

- Not given.

[Color index : **Important** | **Notes** | Extra]

Resources: Slides+Lecture Notes of ophthalmology+Notes+ 434 team

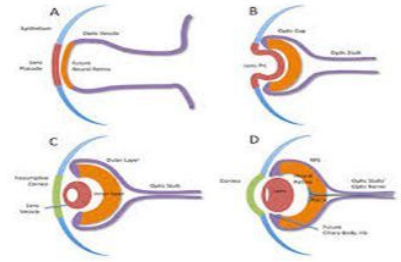
Done By : Ibrahim Alkhodair & Razan alSabti

Edited By: Abdulrahman Al-shammari & Munerah alOmari

Revised By : Adel Al Shihri, Lina Alshehri.

Embryology of the eye

- ❖ This highly specialized sensory organ is derived from neural ectoderm, mesoderm and surface ectoderm.
- ❖ The eye is essentially an outgrowth from the brain (neural ectoderm).
- ❖ the optic nerve started as Optic vesicle connected to the forebrain by Optic stalk.
- ❖ **Surface ectoderm** gives cornea and lens.



Endoderm does not contribute in the eye embryology

Neuroectoderm Neural retina & Retinal pigmented epithelium (risk of detachment), Iris epithelium, Conjunctiva epithelium

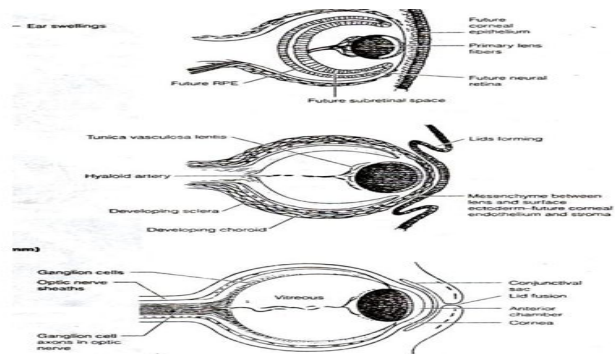
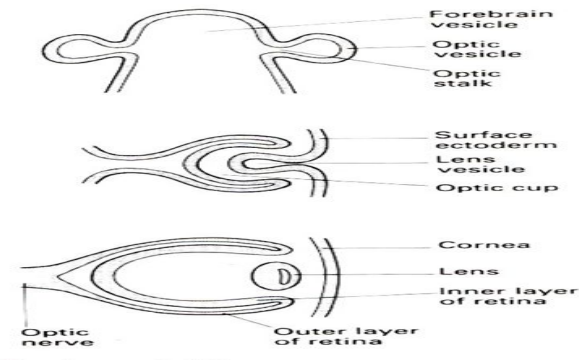
Surface ectoderm Lens and corneal epithelium.

- lens and cornea both from ectoderm. that's why when someone has atopic dermatitis he will get cataract also. "same origin"
- that is why epithelial defect in cornea is so painful.
- cornea and lens are the only 2 things in eye that can be change.

Mesoderm Extraocular muscles, Vascular coat of the eye

Neural ectoderm Everything else

- ❖ Invagination of both the optic vesicle to form Optic cup and the optic stalk to form Choroidal fissure inferiorly.
- ❖ Surface ectoderm invaginate to form the lens vesicle.
- ❖ Mesodermal tissues invade the developing eye to share in vascular, muscular and supportive tissues of the eye.



Coloboma: congenital malformation in the eye, that results from a defect in fusion in inferionasal part. any defect in any other place (superionaa, lateral temporal ...) is NOT a congenital problem.

❖ Development of Eye after Birth:

- At birth, the eye is relatively large in relation to the rest of the body.
- The eye reaches full size by the age of 8 years to 13. Usually the baby by age of 2 he will have adult globe eye size, but full maturation is in 8 years old.
- The lens continues to enlarge throughout the life. that's explain why glaucoma occur, because it will cause pupillary block. In 40 years old two things happen: 1- loss of elasticity of lens capsule 2- increase refractive index (presbyopia)
- The iris has a bluish color due to little or no pigment on the anterior surface.
- During early infant life, the cornea & sclera can be stretched by raised IOP → enlargement of the eye due to the high elasticity of the globe. (unlike in adult eyes they don't enlarge)
 - important to know that :if congenital glaucoma happened before 2 years old the eye size will be big, but after 2 years the eye size will not change.



Anatomy:

❖ The Orbit:

- The eye lies within the bony orbit, which has the shape of a **four - sided pyramid** (Figure below) :
 - At its **posterior apex**: the **optic canal** , which transmits the optic nerve to the chiasm, tract and lateral geniculate body.
 - The **superior and inferior orbital fissures**: allow the passage of blood vessels and cranial nerves which supply orbital structures.
 - The **lacrimal gland**: lies anteriorly in the superolateral aspect of the orbit.
 - On the **anterior medial** wall: lies the fossa for the lacrimal sac.
- As a socket contains and protect the eye.
- **The weakest parts** is the floor (because it has many openings), then the medial wall. that is why when someone has sinusitis he will have orbital cellulitis
- Seven bones contribute the bony orbit (Frontal, zygomatic, maxilla, ethmoid, sphenoid, lacrimal, palatine). important u have to them
- Surrounded by nasal sinuses.
- Floor is the most easily part to get fractured. cause blow out fracture.
- zygomatic bone is the strongest, because it's the most likely to get trauma.
- Nasal bone fracture is the most common facial fracture.
- **"This is a common Q" Fracture of the floor is called orbital blowout fracture** and is due to blunt trauma which causes increased IOP and fracture of the orbital floor. This fracture causes impaction of inferior rectus muscle so the eye will be displaced inferiorly "defective elevation" and posteriorly "enophthalmos" and the inferior orbital nerve will be paralyzed. The patient will complain of diplopia "**vertical diplopia**". when u ask pt to look up and one of the eye did not move upward + hx of trauma think of blowout fracture
- Ethmoid bone is very thin, so it is known as Lamina Papyracea "**thinnest part of the orbit**". Patient with a **sinusitis** → invasion of the Infection from the ethmoidal sinus to the orbit results in **orbital cellulitis**, which is a serious complication.

- **Orbital margin** : Formed by the frontal, maxilla, and zygomatic bones.
- **Orbital cavity** : The orbital cavity is pyramidal, with its base in front and its apex (cone) behind.
 - Roof**: Formed by the orbital plate of the frontal bone, which separates the orbital cavity from the anterior cranial fossa and the frontal lobe of the cerebral hemisphere.
 - Floor**: Formed by the orbital plate of the maxilla, which separates the orbital cavity from the maxillary sinus.
 - Lateral wall**: Formed by the zygomatic bone and the greater wing of sphenoid.
 - Medial wall**: Formed from before backward by the frontal process of the maxilla, the lacrimal bone, the orbital plate of ethmoid (which separates the orbital cavity from the ethmoid sinuses), and the body of sphenoid.

Important:

• Structures Passing Through the Optic Openings:

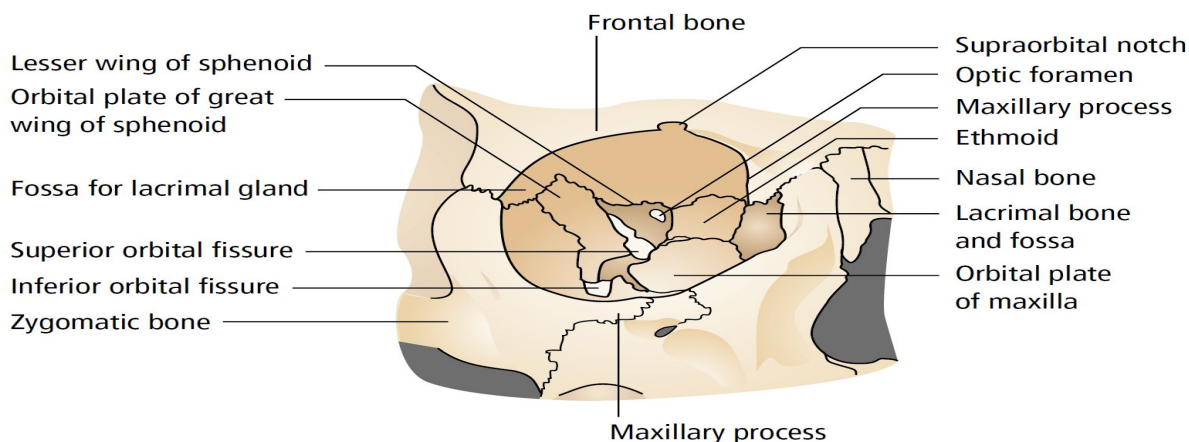
Optic foramen (canal)	1. Optic nerve 2. Ophthalmic artery 3. Central retinal vein
Inferior orbital fissure	1. Infraorbital nerve (part of the maxillary nerve) 2. Inferior ophthalmic vein 3. Infraorbital artery & infraorbital vein 4. Zygomatic nerve, 5. Parasympathetic to lacrimal gland
Superior orbital fissure	Any structure that was not mentioned above including: III, IV and VI cranial nerves, lacrimal nerve, frontal nerve, nasociliary nerve, orbital branch of middle meningeal artery, recurrent branch of lacrimal artery, superior orbital vein, and superior ophthalmic vein.

- Infraorbital nerve: supply the skin of the lower area of the lid. so when get scenario says: pt with paresthesia of the lower lid, what nerve is affected? infraorbital nerve

***Note: both upper and lower divisions of oculomotor nerve(CN III) pass through Superior orbital fissure.**

● Other openings:

- Supraorbital notch**: Situated in the superior orbital margin, transmits the supraorbital nerve and blood vessels.
- Infraorbital groove and canal**: Situated in the orbital plate of the maxilla, the transmit the infraorbital nerve (a continuation of the maxillary nerve) and blood vessels.
- Nasolacrimal canal**: Located anteriorly in the medial wall; it communicates with the inferior meatus of the nose, and transmits the nasolacrimal duct.



❖ The ExtraOcular Muscles:

- Four recti: “**superior, inferior, medial, and lateral**” and two oblique muscles “**superior and inferior**”.
- All are supplied by Oculomotor nerve except superior oblique muscle (Trochlear n. = 4th CN) and lateral rectus muscle (Abducent n.= 6th CN).
- **medial recti are the largest**

● Notes:

1. Superior oblique is the most superior muscle in the orbit.
2. Medial recti are strong muscles that keeps the eye in its normal position. During sleep, the eye tends to move laterally due to the relaxation of the medial recti. It's important that during preoperative assessment of a patient with strabismus. Check the angle of deviation before injecting anesthetic drugs; the eyes changes angles during sleep.
3. **Abducens nerve** is the **only** nerve passing through the **cavernous sinus** (around internal carotid), other nerves pass in the wall of cavernous (not through it). A trauma at this structure will cause: **medial squint**.

❖ Attachment of the Recti Muscles to the Eye

- The **recti** are attached **in front** of the equator¹, unlike the obliques which are attached behind the equator.
- All muscles are originated from behind the eye, except inferior oblique (anatomically and physiologically), and superior oblique(physiologically only)²

❖ Patient with a 3rd nerve palsy, how can you rule out 4th nerve palsy? **Important OSCE question**

The clinical manifestations of 3rd nerve palsy:

- **Ptosis**.
- All muscles are paralyzed **except** the LR, so the eye will be abducted and little down
- The patient can not look downward because the **IR** is paralyzed.

To know if the 4th nerve is intact or not, ask the patient to look downward and if the 4th nerve is intact, then the eye will be intorted due to the action of SO.

Muscle Action : **very very important**³

- **When eye is adducted:**⁴
 - **SO** is almost a pure depressor.
 - **IO** is almost a pure elevator.
- **When eye is abducted:**
 - **SR** is almost a pure elevator.
 - **IR** is almost a pure depressor.

¹ equator: the largest diameter of the eyeball.

² SO: is originated from behind the eye (anatomically), BUT the function of the muscle is like its originated from anterior because of the rounded tendon.

³ All obliques are abductors, All recti are adductors(except lateral rectus).

⁴ SO action is depression and abduction, but to test it, patient should attempt depression on adduction

- to test a pure muscle action, the eye must be in the same long axis as the muscle's so, to test for obliques (eye should be looking inward), and to test superior and inferior recti (eye should be looking outward)

◆ Field of action : to test the muscle alone

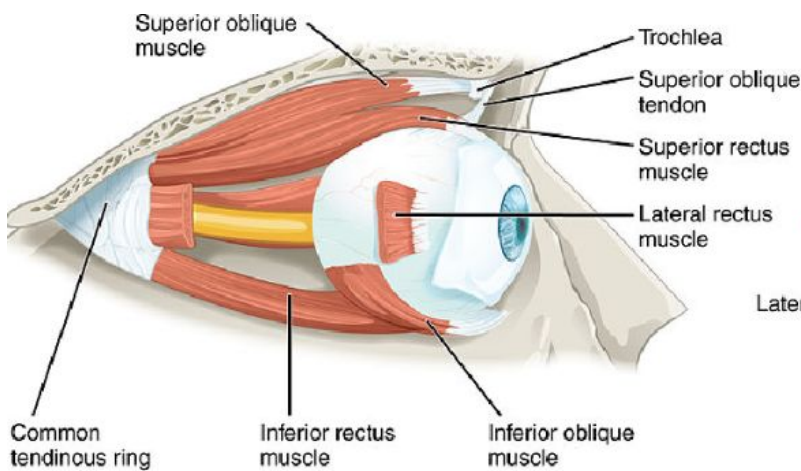
Muscle	Primary Action	Secondary Action	Tertiary Action
Superior rectus	Elevation (transverse axis)	Medial rotation or adduction (vertical axis)	Intorsion or incycloduction (sagittal axis)
Inferior rectus	Depression (transverse axis)	Medial rotation or adduction (vertical axis)	Extorsion or excycloduction (sagittal axis)
Lateral rectus	Lateral rotation or abduction (vertical axis)	—	—
Medial rectus	Medial rotation or adduction (vertical axis)	—	—
Superior oblique	Depression (transverse axis)	Lateral rotation or abduction (vertical axis)	Intorsion or incycloduction (sagittal axis)
Inferior oblique	Elevation (transverse axis)	Lateral rotation or abduction (vertical axis)	Extorsion or excycloduction (sagittal axis)

Direction to look

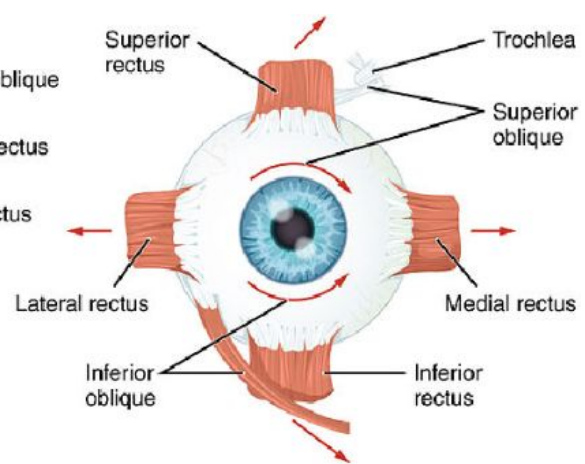
- SO
- IO
- SR
- IR

Down and in
Up and in
Up +/- out
Down +/- out

Muscle	Primary	Secondary	Tertiary
Medial rectus	Adduction	—	—
Lateral rectus	Abduction	—	—
Inferior rectus	Depression	Extorsion	Adduction
Superior rectus	Elevation	Intorsion	Adduction
Inferior oblique	Extorsion	Elevation	Abduction
Superior oblique	Intorsion	Depression	Abduction

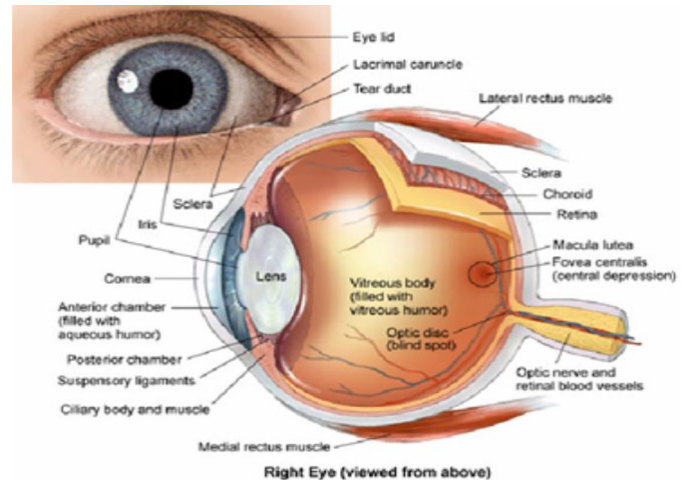
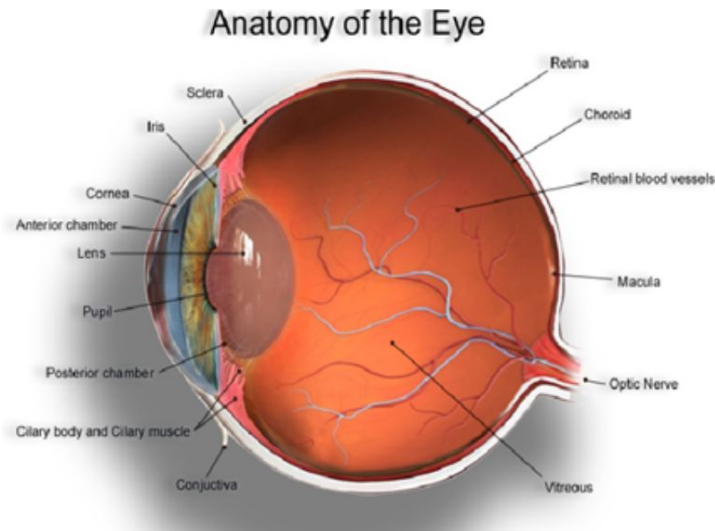


Lateral view of the right eye



Anterior view of the right eye

◆ The Globe

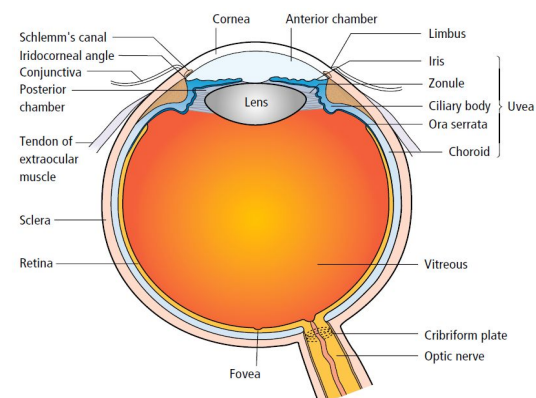


“The eye measures approximately 21-24 mm in all its main diameters”

- Eye consist of globe (eyeball, extraocular muscles) and adnexa (lacrimal gland and sac)

• Coats of the Eye:

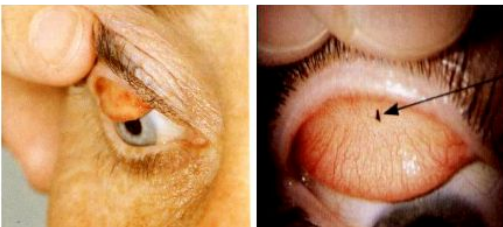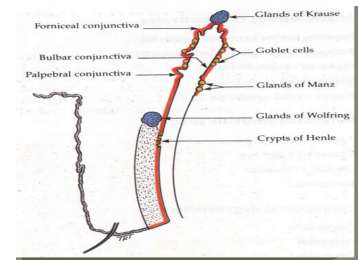
1. **Fibrous coat “outer protective coat”:** Made up of a posterior opaque part, the sclera, and an anterior transparent part, the cornea. Both are formed of collagenous fibers with different arrangement. Lamina cribrosa is the area of the sclera that is pierced by the nerve fibers of the optic nerve. Cornea is in contact posteriorly with the aqueous humor. **“the cornea is stronger than the sclera”**. functions are: protection and vision “ cornea clear and sclera white that is because of the arrangement of collagen in cornea some horizontal and some vertical while in sclera is random”.
2. **Vascular pigmented coat “middle vascular coat”:** Consists from behind forward, of the choroid, the ciliary body “ mainly”, and the iris. The choroid is composed of an outer pigmented layer and an inner, highly vascular layer. The ciliary body is continuous posteriorly with the choroid, and anteriorly, it lies behind the peripheral margin of the iris. It is composed of the ciliary ring, the ciliary processes, and the ciliary muscles. **“The ciliary body has pigmented and non-pigmented epithelium, the non-pigmented one secretes the aqueous”** if ciliary body affected (uveitis) will cause atrophy of the eye.
3. **Inner layer:** composed of the optic nerve and the retina. The retina extends forward to within 6 mm of the limbus.
 - between lens and iris is the posterior chamber.
 - glaucoma happened because of problem in absorption not because of increase secretion.
 - when there is pupillary block the aquos will not pass through so the iris will curve -> increase IOP (acute angle closure glaucoma. Treatment is constrict pupil for short treatment, because the problem happened only when pupil is SEMI dilated. long term treatment is clear lens extraction or laser iridotomy.



◆ Conjunctiva:

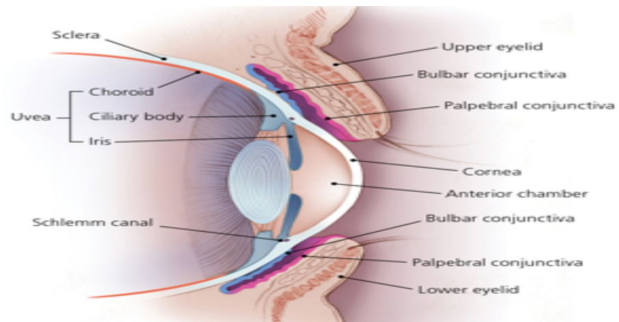
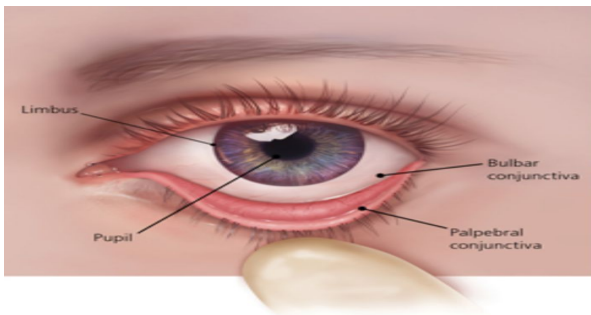
- It is the transparent membrane covering the sclera, its the outer cover of the eye, normally it has vessels and sometimes they are prominent, but if there are no vessels or redness, then the patient might be anemic.
- divisions:
 1. **Bulbar conjunctiva:** covers the eye. In a case of vernal keratoconjunctivitis, the bulbar conjunctiva may have **tranta's spots**. **“discrete whitish raised dots along the limbus”**
 2. **Palpebral conjunctiva:** covers the eyelid from inside. **accessory lacrimal gland is responsible for lacrimation, and the lacrimal gland only will work with emotion reflex** . **SAQ Q:** patient came complaining of foreign body sensation in the conjunctiva.
What is the diagnosis? Palpebral foreign body
What is the treatment? Removal and topical antibiotic
 3. **Forniceal conjunctiva:** between the bulbar and palpebral conjunctiva.
 - **it has a structure called Cul-de-sac, which serves as a reservoir for tears and drugs.**
- The stroma : divided into **adenoid** layer and **fibrous** layer (**no adenoid tissue until 3 months after birth**).⁵
- **Diseases:**

- Follicles and Papillae
- Injection : is peripheral hyperemia of the **anterior ciliary vessels** which produces a **deep red or rose color** of the corneal stroma
 - Causes of ciliary injection: keratitis, Uveitis, Acute glaucoma.
- Chemosis : It is a swelling of the conjunctiva due to abnormally permeable capillaries



pic could come in SAQ: Palpebral conjunctiva foreign body

⁵ inflammation of adenoid is called (Follicular Conjunctivitis), and inflammation of fibrous layer is called (Papillary Conjunctivitis)

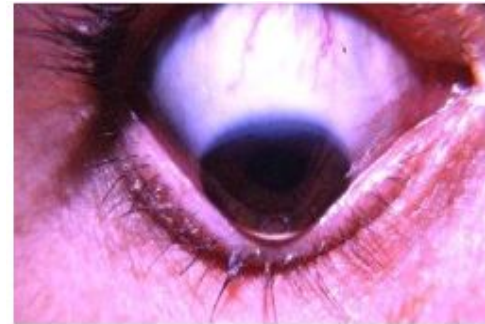

aqueous drainage:

trabecular meshwork (85%), uvia\sclera(15%).

◆ Cornea

- The cornea is 500-530 micron(0.5mm) in thickness. It consists of **five layers: epithelium, bowman's layer** "called anterior limiting membrane", **corneal stroma, descemet's layer** "called posterior limiting membrane", and **corneal endothelium**.
- It protects the internal ocular structures. Together with the lens, it refracts and focuses light onto the retina.
- nutrition of the cornea is supplied almost entirely by the aqueous humour.
- It is transparent because: it is **avascular** and it has **regularly arranged collagen fibers**.
- The epithelium is from surface ectodermal origin, thus it is very sensitive and also it **can regenerate** after being injured.
- **The thickness of the cornea affects the IOP reading**. After Lasik, the cornea becomes weak and a false low reading of IOP could occur, so the diagnosis of glaucoma might be missed. **One possible risk of Lasik is keratoconus**, which is central thinning and plugging of the cornea. This might end with corneal scarring and keratoplasty "corneal transplantation"
- The patient with keratoconus when he looks down, his lower eyelid becomes V shaped because of the plugging, and this is called **Munson's sign**. **"important"** (Keratoconus is a strong contraindication of Lasik.)
So, When bowman's membrane gets injured, it will heal with a scar "opacity".



SAQ: corneal abrasion usually does not cause scars unless the **bowman's** layer or the stroma are injured.

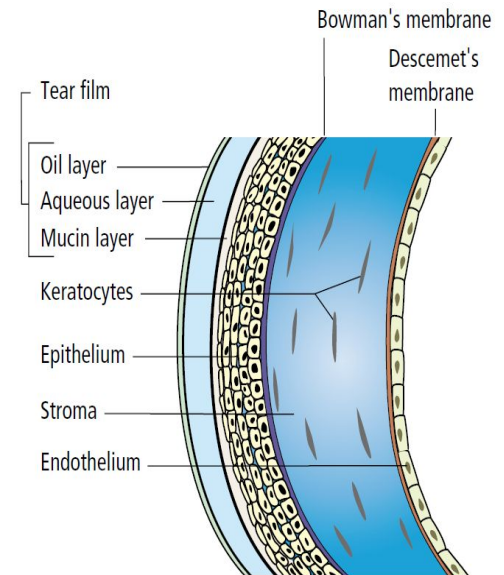
- The descemet's membrane is a very strong membrane, but in case of congenital glaucoma, it will be stretched and the aqueous will invade the cornea, which will disturb corneal fibers arrangement and cause corneal edema. If congenital glaucoma doesn't get corrected early, the condition will worsen and end up with corneal scarring and keratoplasty might be needed. **So the treatment of congenital glaucoma is surgical.**

Important Q: When the patient got blunt trauma in the eye, which one is more susceptible to injury, cornea or sclera? **The answer is sclera**

- Actually, both Cornea and sclera are made up of collagen fibers but they differ in the arrangement. The corneal fibers are arranged in vertical and horizontal planes, making it more clear and 100 times stronger than sclera. The fibers of the sclera are arranged in haphazard fashion, which make them weaker and more opaque.

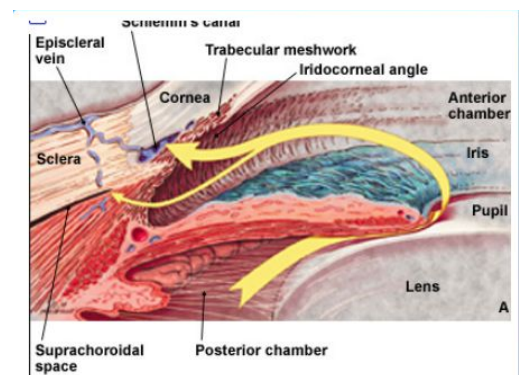
It has 5 layers

Layer (anterior to posterior)	condition
Epithelium <ul style="list-style-type: none"> > continuation of the bulbar conjunctiva > ectodermal origin 	Abrasion. Treatment by covering the eye for 24hrs and defect will heal without scarring . Never use topical anesthesia in this case.
Bowman's membrane	Abrasion. Risk of scarring
Stroma	
Descemet's membrane	Disturbance of this layer is common in congenital glaucoma. Management is surgical via keratoplasty
Endothelium	Single layer It end in the angle, we have to know if it's open or closed which is about schwalbe's line , trabecular meshwork , scleral spur , ciliary body and iris if all structures are seen that mean open angle glaucoma while if all structures closed that mean closed angle .



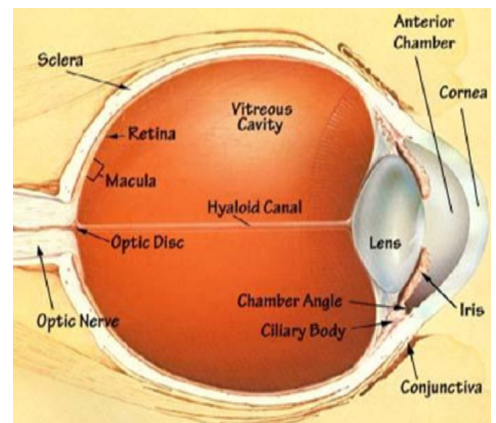
❖ Eye Chambers:

- 1. The anterior chamber:** between the cornea and the iris.
 - It should be always clear, abnormal blood collection in it is known as **hyphema** and it is mainly due to trauma.
 - Collection of pus in the anterior chamber is known as **hypopyon**.
- 2. The posterior chamber:** immediately behind the iris, between the iris and zonule fibers.
 - These two chambers which communicate through the pupil are filled with clear aqueous humor.
 - **The vitreous cavity:**
 - filled by gel-like structure, the vitreous.



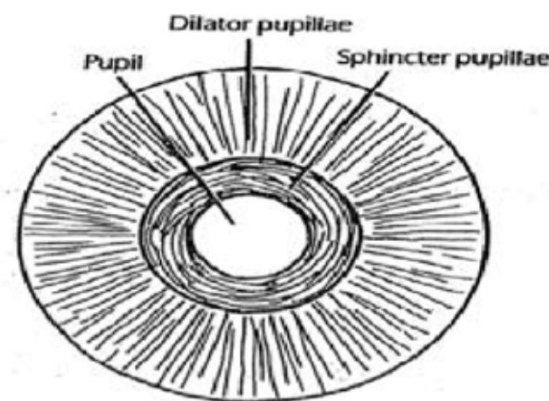
➤ **434 notes:**

- The non-pigmented ciliary epithelium covering the ciliary body secretes the aqueous with the help of **carbonic anhydrase enzyme**. It circulates in the posterior chamber between the iris and the lens, then it enters the anterior chamber to be drained through the **trabecular meshwork into the schlemm's canal (85%)**, and the other 15% got drained through the uveoscleral outflow (absorbed by the iris and the ciliary body to the suprachoroidal space).
- If the patient has a predisposing factor of glaucoma (e.g. hyperopia) and the pupil remained mid-dilated for a long period, the iris will adhere to the lens, and this will cause pupillary block, which in turn leads to accumulation of the aqueous in the posterior chamber and hence raising of IOP leading to the development of acute glaucoma. **The initial treatment of acute glaucoma is carbonic anhydrase enzyme inhibitors** to reduce the volume of accumulated aqueous like: **Acetazolamide "Diamox" and Sulfonamide**. These drugs act mainly on the trabecular pathway. Prostaglandins found to be active on the other pathway and has cosmetic side effects, it elongates and thickens eyelashes. **The initial intervention is laser iridotomy.**
- **Anterior segment is anything in front of the lens including anterior chamber, cornea, iris, and lens itself.** Posterior segment is anything behind the lens including vitreous, retina and optic nerve. When the patient complains of decreased vision but has normal anterior and posterior segments, then he might have **amblyopia "lazy eye"**.



◆ **Iris And Pupil**

- The iris is a thin, contractile, pigmented diaphragm attached peripherally to the anterior part of the ciliary body.
- It forms the pupil at its centre, the aperture of which can be varied by the circular sphincter and radial dilator muscles to control the amount of light entering the eye.
- The iris has two muscles:
 - **Dilator pupillae: dilation of pupil (mydriasis)** supplied by sympathetic fibers
 - **Sphincter pupillae: constriction of pupil(miosis)**, supplied by parasympathetic fibers from the oculomotor nerve. **predominant**



➤ **434 notes:**

- In patients with 3rd nerve palsy and spared pupil like in diabetes, or in patients with semi dilated\fully dilated pupil and 3rd nerve palsy, what is the recommended investigation?
- The answer is **MRA "magnetic resonance angiography"** because the most common cause of surgical 3rd nerve palsy is aneurysm, which can be detected using MRA.

◆ The Lens:

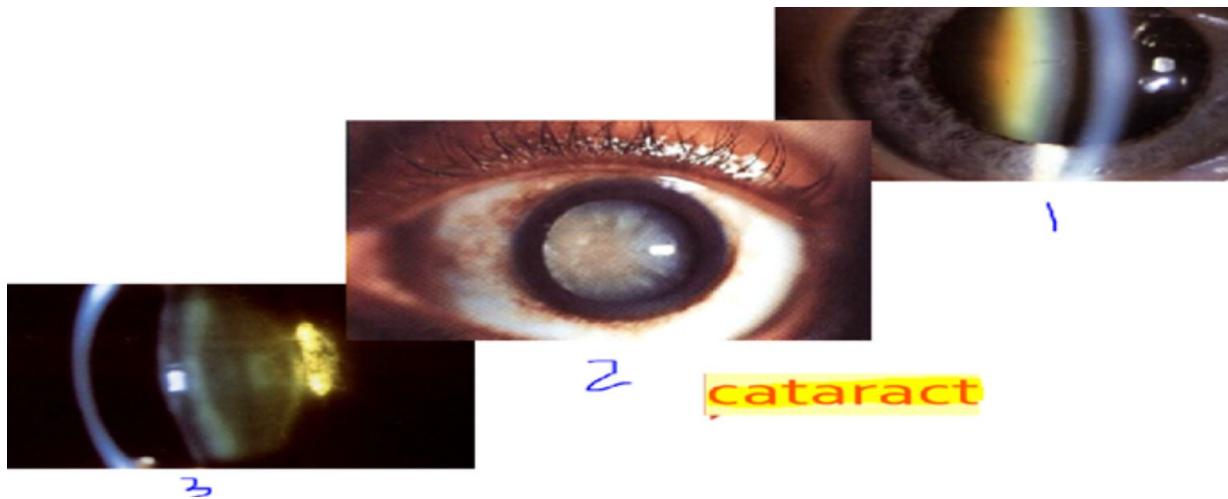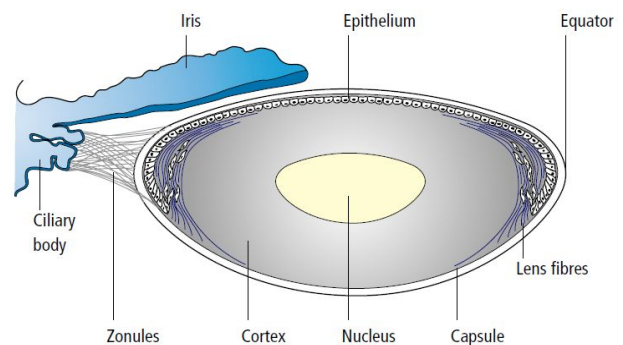
- It is a transparent, biconvex structure enclosed in a transparent capsule. It is situated behind the iris and in front of the vitreous body and is encircled by the ciliary processes.
(It's a changeable refractive media).
- The lens consists of an **elastic capsule**, which envelops the structure; a **cuboidal epithelium**, which is confined to the anterior surface of the lens; and **lens fibers**, which are formed from the cuboidal epithelium at the equator of the lens ⁽¹⁾.
- **Crystalline lens is the only structure continuously grow throughout life.**
- It is mainly ectodermal in origin, so it is very sensitive to pain.

➤ Diseases of the lens:

- Congenital anomalies and effect of systemic diseases.
- Cataract

➤ Lens structure:

- **Anterior capsule: attack of high pressure cause destruction of the epithelium under anterior capsule cause opacity.**
- **Cortex**
- **Nucleus**
- **Posterior cortex**
- **Posterior capsule**



Pic.1: this is a **nuclear sclerosis** representing a manifestation of early stage cataract. with age

Pic.2: cortical cataract.

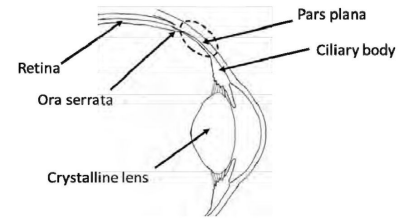
Pic.3: posterior subcapsular cataract, Possible causes: steroids and trauma

➤ 434 Notes :

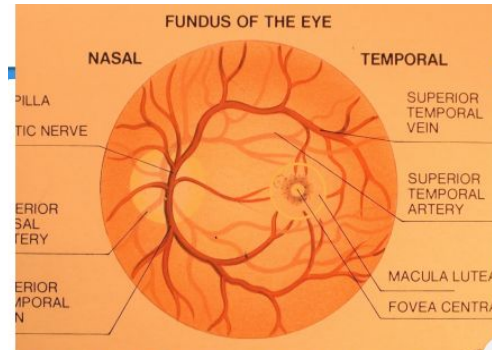
- **Important question:** Post kidney transplant patient **on steroids** came complaining of decreased vision, what is the possible cause? The answer depends on the IOP, if it is normal, then he might have posterior subcapsular cataract. If his IOP is elevated, then he might have glaucoma.
- Two approaches of cataract surgery: **phacoemulsification** and standard extracapsular cataract extraction (ECCE).

Retina And Vitreous:

- The retina consists of an outer pigmented layer and an inner nervous layer (it has 10 layers in total). Its **outer** surface is in contact with the choroid and its inner surface is in contact with the vitreous body.

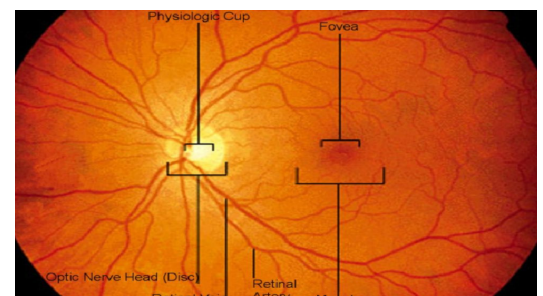
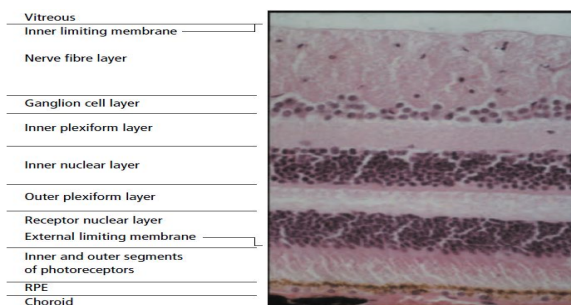


- pars plana:** has no blood vessels so all retina surgery occurs here.
- At the center of the posterior part of the retina is an oval, yellowish area, the **macula lutea**, which is the area of the retina for the most distinct vision. It has a central depression, the **fovea centralis**.



- Optic nerve head, macula, fovea, retinal background, Ora serrata, and retinal vasculature**

- The optic nerve leaves the retina about 3 mm to the **medial** side of the macula lutea by the optic disc. **The optic disc** is slightly depressed at its center, where it is pierced by the **central retinal artery**. At the optic disc, is a complete absence of rods and cones, so that the optic disk is insensitive to light and is referred to as the **"blind spot"**.
- Photoreceptors contains visual pigment which consists of a large protein (opsin) attached to retinal (**vitamin A aldehyde**).
- Light splits the opsin from the retinal with initiation of a graded electrical potential → Transmitted through the visual pathway to be processed in the visual cortex (occipital lobe) → vision sense.
- Macula:** An area of the eye near the center of the retina where visual perception **is most acute**. "oval yellowish area surrounding the fovea"
- Fovea:** The fovea is the region in the center back of the eye that is responsible for acute (central) vision. **The fovea has a high density of cones.** (while periphery of retina has higher density of rods).
- Rods is used for night vision and cones for day vision
- Vitreous humor:**
 - It is a gel-like substance occupied the space behind the lens and in front of the retina at the back of the eye, it comprises a large portion of the eyeball.
 - It consists of water, collagen, salt and sugar. It maintains the shape of the eye, and it is a clear solution to the light can easily pass through it.



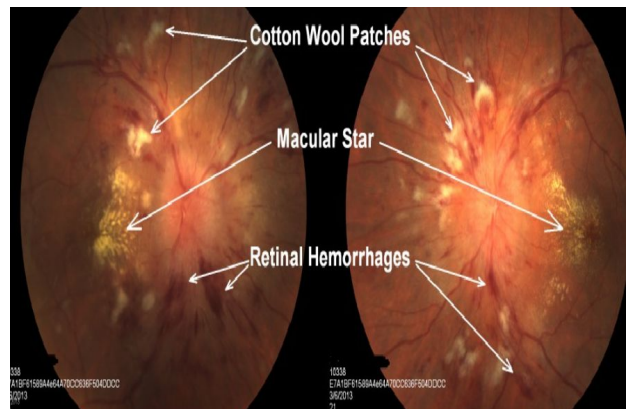
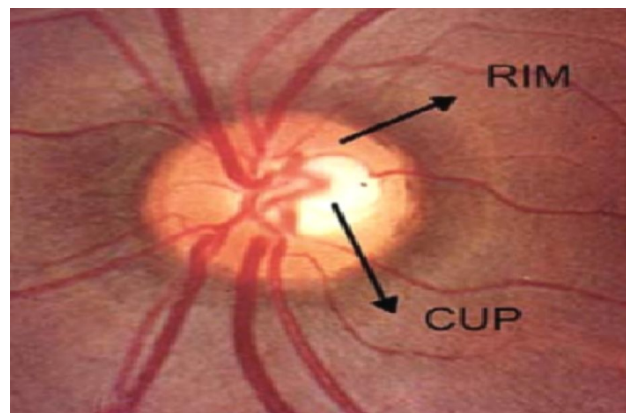
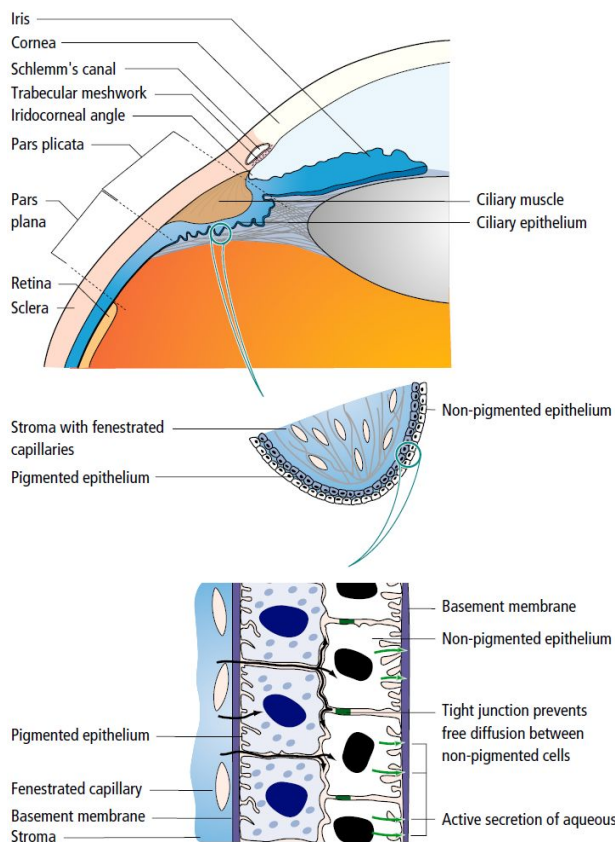
Retina Structure

◆ Ciliary Body:

- The structure of the ciliary body is triangular in cross-section, and it encircles the inside of the eye behind the colored iris. It connects posteriorly with the choroid and anteriorly with the iris.
- The ciliary body is subdivided into three parts:
 - The ciliary muscle (responsible for changes in lens thickness and curvature during **accommodation**)
 - The ciliary processes at the front (pars plicata):They are responsible for the secretion of **aqueous humour**.
 - The pars plana at the rear.
- Pars plicata has the ciliary processes, and the zonular lens fibers from the crystalline lens pass deep into the valleys between them. **Pars plana is a relatively avascular area, so it is important surgically in the approach to vitreous space.**

➤ 434 notes:

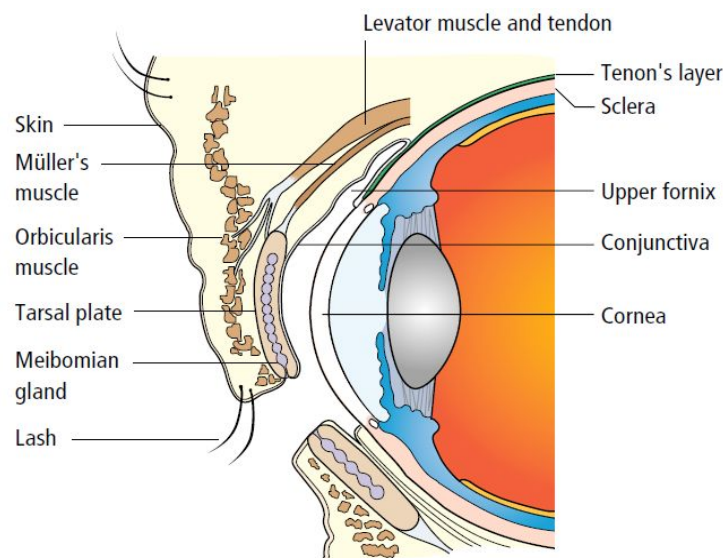
- In fundus examination, you should comment on: **the optic disc, the retinal vessels, and the macula.**
- Patient with chronic visual loss + the fundus is not seen = **do B-scan ultrasound. "Gold standard"**



◆ The Eyelids:

- They provide a protective covering for the eye.
- It spreads the tears, and keeps ocular surface wet all the time.
- The lids are closed by **Orbicularis Oculi** (supplied by **CN.7**), and opened by **Levator Palpebrae (CN.3)**, Muller's muscle (Sympathetic innervation), and Lower lid retractors. **Tarsus is the skeleton of the eyelid.**
- Contraction of the peripheral fibres of the orbicularis muscle results in a protective, forced eye closure, while that of the inner, palpebral muscle results in the blink.

- Orbital septum is a strong fibrous tissue, that serves to separate some eye structures from other structures, and it's an important barrier against infection.⁶
- It has special meibomian glands (modified sebaceous glands) which secrete oily material that retards tear and makes it stay longer in front of the cornea. divided into:
 - Anterior lamella: Skin and orbicularis (fibrosis of this leads to ectropion).
 - Posterior lamella: Tarsus and levator and conjunctival (fibrosis leads to entropion).
- Eyelashes are important as a protective to the eye (because the hair which is directed outward gives the orbicularis more time to close). the area where eyelashes get out is called lid margin.
- Inflammation of lid margin is called Blepharitis>
- With entropion, upper eyelashes will be directed inward, and may damage cornea with time, with ectropion, lower eyelashes will be directed away from the eye, and this will lead to tearing and eye will become dry.



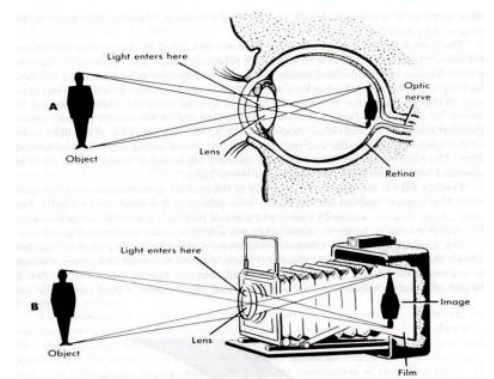
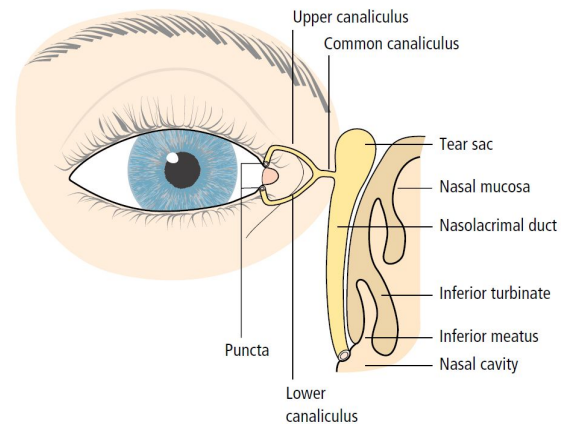
⁶ infection anterior to orbital septum (preseptal cellulitis), behind septum (orbital cellulitis, very dangerous).

◆ The Lacrimal apparatus: pic important

- consist of two part bulbar and palpebral, connect by duct and then open in superior conjunctival fornices

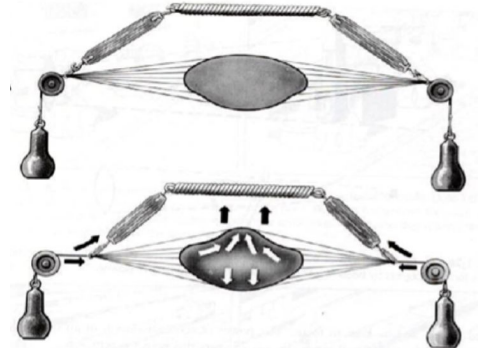
- Tears drain into the upper and lower puncta and then into the lacrimal sac via the upper and lower canaliculi (Figure). They form a common canaliculus before entering the lacrimal sac.
- The nasolacrimal duct passes from the sac to the nose.
- Lacrimal gland secretes tears into the upper fornix of the conjunctival sac which are spread over the surface of the cornea as a tear film by blinking of the lids.
- Tears accumulate at the inner canthus and drain into the lacrimal sac via the puncta and canaliculi.
- the sac is continuous inferiorly with nasolacrimal duct which opens into the nasal cavity just beneath the inferior turbinate.
- Function:
 - Tear secretio
 - Layers of precorneal tear film.
 - Drainage of tear.
- The cascade : punctum (the start of the drainage system) > canaliculi> nasolacrimal sac > nasolacrimal duct > Inferior meatus (valve of Hasner is at the meatus).
- **Notes:**
 - For the lacrimal gland, normally it's not palpable.
 - The canaliculi connect the punctum to the nasolacrimal sac, not the duct.
 - Blinking help tear drainage into the system by creating negative pressure.
 - Infection of the lacrimal gland is called (Adenitis), and of lacrimal sac (Dacryocystitis).
 - **running eye and nose means intact nasolacrimal duct.**
 - Tear film. 3 layers consists of:
 - Mucin gel layer.
 - Aqueous layer: produced by lacrimal gland.
 - Oil layer: Meibomian glands.

tears does not stay



❖ Optics Of The Eye:

- The eye is like a camera. Light must have a clearly pathway to be clearly focused on the sensory receptors of the retina, i.e., Clear cornea, anterior chamber, lens and vitreous cavity.
- The Refractive power of the eye is about 58 -62 diopters.
- The cornea is the major refracting element of the eye with a power of approximately 40 diopters. If the curvature is greater in one meridian than the other → Astigmatism.
- The refractive power of the lens is about 17-21 diopters at rest. Accommodation can change the power of the lens markedly depending on the age.



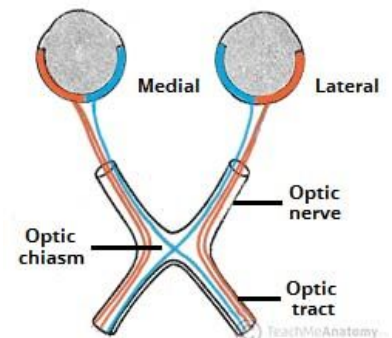
➤ 434 notes:

- Young kids have a strong accommodation up to 30 diopters as their lenses has 70.000 zonule fibers.
- When ciliary body contracts → relaxation of the zonules → plugging of the lens and thus increased depth of focus and you will be able to see near objects.
- When ciliary body relaxes → contraction of the zonules → thinning of the lens, so you will be able to see far objects clearly.
- **Important:** *With increased age, usually from 40s, people experience a problem with near vision "Presbyopia", why?

■ Because of:

1. Loss of elasticity of the lens.
2. Increased in the refractive index of the lens due to nuclear sclerosis.

- **Presbyopia is treated with convex lens.**
- **Hyperopia "farsightedness"** → treated with convex lens.
- **Myopia "nearsightedness"** → treated with concave lens.
- Patient with big eyes ">25 mm in diameter" the image will be reflected in front of the retina leading to myopia, to correct it we give the patient a concave lens, thus causes a diversion of light rays.
- Patient with small eyes "<21 mm in diameter" the image will be reflected behind the retina leading to hyperopia, to correct it we give the patient a convex lens that causes a conversion of light rays.

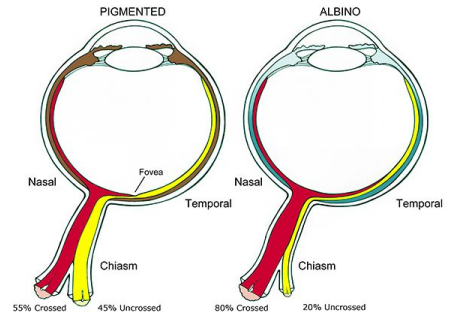


❖ Optic Nerve

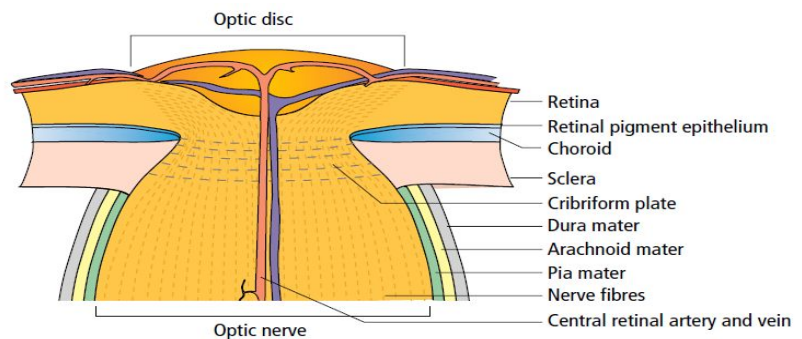
- (optic nerve > optic disc > rim and cup (when increased is sign of glaucoma, or could be physiological and we differentiate two types by measuring IOP and visual field)).
- contains around 1.2 million nerve fibers, which are axons of the retinal ganglion cells.

the length of optic nerve in these structures: **important to know**

- 1 mm in the globe.
- 25 mm in the orbit.
- 9 mm in the optic canal.
- 16 mm in the cranial space
- Partial decussation occurs and about 53% of the fibers cross to form the optic tracts (if pt have carotid lesion will develop binasal hemianopia).
- The optic nerve leaves the retina about 3 mm to the medial side of the macula lutea by the optic disc. The optic disc is slightly depressed at its center, where it is pierced by the central retinal artery. At the optic disc, is a complete absence of rods and cones, so that the optic disk is insensitive to light and is referred to as the “blind spot”.
- Optic disc: the terminal part of the optic nerve where ganglion cells fibers leaves the eye.
- Optic cup: a central depression within the optic disc.
- The normally cup-disk ratio is **3/10 (0.3)** Measurement is crucial to diagnose certain diseases like glaucoma.

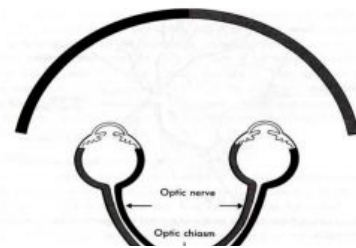


Structure of CN.2



❖ Intraocular Pressure:

- The pressure within the eye is maintained at a steady level by continuous formation and drainage of aqueous.
- Aqueous is secreted by the ciliary epithelium → posterior chamber → anterior chamber (through the pupil) → drained through the anterior chamber angle.
- **The intraocular pressure (IOP) is normally between 10 – 22 mmHg;** increased IOP causes ocular hypertension.
- High IOP almost always due to an obstruction of aqueous outflow.
- Corneal thickness affect the readings of IOP.
- Some people have glaucoma with normal IOP.



❖ Vision \ visual pathway:

- The central retina contains yellow pigment, Xanthophyll, the so called macula lutea (yellow spot).
- It is divided into retinal pigment epithelium & neurosensory retina
- Photoreceptors contains visual pigment which consists of a large protein (opsin) attached to retinal (vitamin A aldehyde).
- Light splits the opsin from the retinal with initiation of a graded electrical potential → Transmitted through the visual pathway to be processed in the visual cortex (occipital lobe) → vision sense.
- Visual Pathway: Three order neurons:
 1. Bipolar cell, lies within the retina.
 2. Ganglion cell, synapse in lateral geniculate body.
 3. Third neuron terminates in visual cortex

❖ Questions from Dr slides:

- 1- The socket that contains the eye called **ORBIT**.
- 2- The orbit is **formed** by **Seven** Bones.
- 3- The optic nerve pass through **Optic foramen or canal**.
- 4- The eye has **Six** Extraocular muscles, **4** Recti and **2** obliques.
- 5- All extraocular muscles are supplied by **Oculomotor nerve except SO4 and LR6**.
- 6- When we test a patient 4th nerve we should ask him to look **Down and in**.
- 7- The space that lies behind the cornea & in front of the iris called **Anterior chamber**.
- 8- The fluid that fills the chambers of the eye called **Aqueous humors**.
- 9- The cavity that lies behind the lens called **Vitreous cavity**.
- 10- The main refractive structure in the eye is **The cornea**.
- 11- The second refractive structure in the that can change its power **The lens**.
- 12- The structure that determines the color of the eye is **The iris**.
- 13- when the lens get opacified this condition called **cataract**
- 14- The central part of the retina called **The macula**.
- 15- The central part of the macula called **Fovea**.
- 16- The central part of the fovea called **foveola**.
- 17- The optic nerve lies in **Nasal** part of the retina.
- 18- The percentage of the decussating fibers is **53%**