

[Color index : **Important** | **Notes** | Extra] Editing file [link](#)

Inflammatory and degenerative joint disorders

Objectives

- To be able to specify the symptoms, signs, and predisposing factors; outline the assessment and appropriate investigation; propose a limited differential diagnosis and; outline the principles of management of a patient with :
 - Degenerative OA.
 - Inflammatory arthritis (doctor didn't discuss it).
 - Rheumatoid Arthritis.
 - Gout.
 - Seronegative spondyloarthropathy.

Done by: Mohammad Alfadhel.

Edited: Saleh Alkhalifa.

Revised by: Adel Al Shihri.

Sources: Slides+Notes+433Team.

Background

- **Articular Cartilage:**

- Avascular, aneural hyaline cartilage that has some viscoelastic material with variable load bearing properties. It is essential in decreasing joints friction.
- It is mainly composed of water (70%), type II collagen (15%) confers tensile strength to cartilage, proteoglycans (10%) negatively charged proteins hold water within the matrix and chondrocytes (5%) the only cell type in articular cartilage.
- It has poor repairing properties, **mostly repaired with fibrocartilage which is less effective than hyaline cartilage.**
- If the collagen network is disrupted, the matrix becomes **waterlogged and soft.** Followed by **loss of proteoglycans, cellular damage and splitting ('fibrillation')** of the articular cartilage.
- Damaged chondrocytes begin to release matrix-degrading enzymes inside the joint cause further damage.

- **Capsule:**

- Fibrous structure with tough condensations on its surface (ligaments).
- Together with the overlying muscles, they help to provide stability.

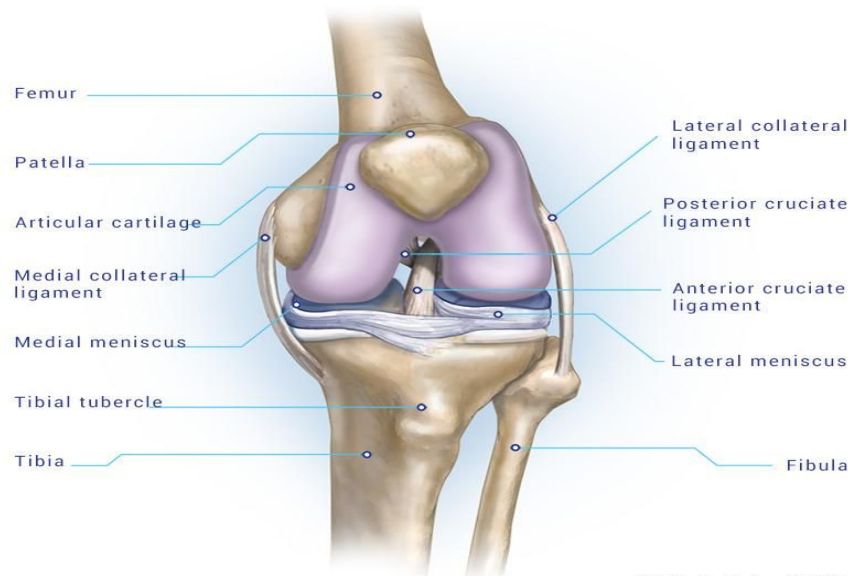
- **Synovium:**

- Thin membrane that is **richly supplied with blood vessels, lymphatics and nerves.** It provides a non-adherent covering for the articular surface and produces synovial fluid.
- **It is the target of autoimmune reactions in joint infections (septic arthritis) and autoimmune disorders such as rheumatoid arthritis and SLE.**

- **Synovial fluid:**

- Have several functions: Nourishes the avascular articular cartilage, plays an important part in reducing friction during movement, it also has slight adhesive, properties, which help in maintaining joint stability.
- The volume remains fairly **constant**, regardless of movement. Unless the **joint got injured it increases resulting in joint effusion.**

Please watch this 5 minutes video before start studying the lecture. **It will help to understand some points:** https://youtu.be/41IMR_Dp5bs



Terminology

- **Osteoarthritis (OA)** is also known as degenerative arthritis or degenerative joint disease or osteoarthritis.
- **Hemarthrosis**: bleeding into joint spaces.
- **CPPD**: Calcium pyrophosphate deposition disease.
- **Reiter's syndrome**: an inflammatory syndrome (etiology unknown) predominantly in males; characterized by arthritis, conjunctivitis and urethritis.
- **Tabes dorsalis**: a progressive deterioration of the spinal cord and spinal nerves associated with tertiary syphilis.
- **Loose bodies**: is a fragmented osteophyte.
- **Spondylolisthesis**: forward displacement of a vertebra over a lower segment

Osteoarthritis

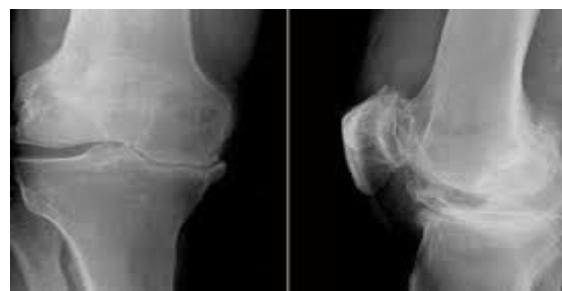Osteoarthritis (OA) is a chronic, non-inflammatory, degenerative joint disorder in which there is progressive softening and disintegration of articular cartilage followed by new growth of cartilage and bone at the joint margins (osteophytes), **because there is no cartilage any more bones exposed to more pressure lead to** Subchondral bone sclerosis and cyst formation, mild **(compared to the inflammatory)** synovitis and capsular fibrosis.

It has two types : Primary (idiopathic) and secondary (table 1)

Etiology

OA results from a disparity between the stress applied to articular cartilage and the ability of the cartilage to withstand that stress. This could be due to one or a combination of **two processes**:

- **Weakening of the articular cartilage** (due to a genetic defect or enzyme activities).
- **Increased mechanical stress** in some part of the articular surface. Which can be caused by overuse or joint instability.

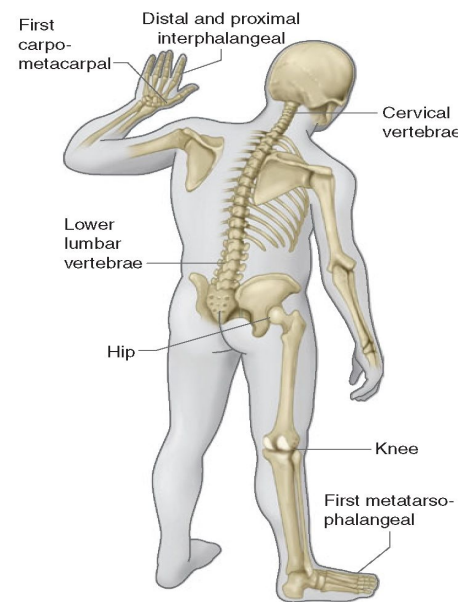


The initial trigger for OA appears to be the damage to the cartilage collagen network and loss of proteoglycans from the matrix, giving rise to deformation and gradual structural disintegration. **Varus deformity** of the knee. **Medial side** is the most affected.

cause	examples
Metabolic	Crystalline deposition disease (GOUT, CPPD), Paget's disease
Inflammatory	RA, SLE, Reiter's syndrome
neuropathic	DM, Tabes dorsalis
Hematology	Sickle cell disease , hemophilia (due to recurrent hemarthrosis)
Endocrine	DM, acromegaly
Trauma	Osteochondral, malunion, sport injury
Congenital/developmental	Hip dysplasia, multiple epiphyseal dysplasia
Necrosis an infection	Perthe's disease, osteonecrosis , steroids

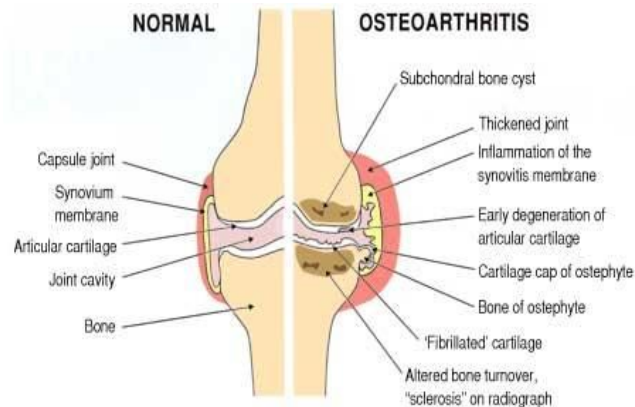
Prevalence

- Osteoarthritis is **the commonest** of all joint diseases.
- Osteoarthritis is much more common in some joints (hip, **knee**, spine and the fingers) than in others (the elbow, wrist and ankle).
- Commonest joints are knee, hip, Cervical spine & Lumbar Spine, 1st Carpometacarpal, 1st Metatarsophalangeal and Interphalangeal joints.
- Common in our community especially **knees**.
- Much more in females and more joints are affected in **women**.
- Presents earlier than in West.
- About 90% of those over 40 have asymptomatic degeneration of weight bearing joints.



Pathology

- The cardinal (major) features are:
 - Progressive loss of articular cartilage thickness.
 - Subarticular cyst formation and sclerosis.
 - Osteophyte formation.
 - Synovial irritation (synovitis).
 - Capsular fibrosis.



- Subarticular cyst could arise from local areas of osteonecrosis or from the forceful pumping of synovial fluid through cracks in the subchondral bone plate.
- Osteophytes arise from proliferation and remodeling of the adjacent cartilage at the edges followed by endochondral ossification of that cartilage.
- OA at the beginning is **asymmetrically** distributed, often **localized to only one** part of a joint.
- In the area of greatest stress in the joint, cysts appear and the surrounding trabeculae become thickened or sclerotic.
- There are vascular congestion and the intraosseous pressure rises. Meanwhile, as the disease progresses, cartilage in peripheral, unstressed areas proliferate and ossifies, producing bony outgrowths (osteophytes).
- OA shows features of both destruction (cartilage erosion) and repair (osteophytes).
- Although OA is not primarily an inflammatory disease, shedding of fragments from the fibrillated articular cartilage, as well as release of enzymes from damaged cells, may give rise to a low-grade synovitis that may produce local signs of inflammation.
- In the late stages, capsular fibrosis is common and may account for joint stiffness.

Risk factors

- Age
- Obesity
- Excessive joint loading (manual labor, athletes, etc)
- Trauma
- Repeated microtrauma—in many cases, a patient's occupation or athletic activities require repetitive motions (such as repeated knee bending) that predispose the patient to degenerative joint disease in later years
- Macrotrauma (fractures, ligament injuries)—fractures that are intra-articular can cause OA.
- Genetic predisposition.
- Altered joint anatomy or instability (developmental hip dysplasia, dislocation due to trauma, rheumatoid arthritis, gout, pseudogout).
- Deposition diseases cause chondrocyte injury, or make the cartilage more stiff (hemochromatosis, ochronosis, alkaptonuria, Wilson disease, Gaucher disease, gout, CPPD).
- Hemophilia (hemarthrosis).

Clinical features

Cartilage changes start 10 or even 20 years before symptoms.

OA has two clinical variants :

- **Monarticular and pauciarticular OA:** characterized by **pain, limited range of motion (in late stage)**. The pain (due to **Bone pressure** caused by vascular congestion and intraosseous hypertension **most important**, **mild synovial inflammation and capsular fibrosis and muscle fatigue**) **Causes of pain are important!**
- **Polyarticular (generalized) OA:**
 - Characterized by pain, swelling and stiffness of the distal finger joints.
 - The first carpometacarpal, big toe metatarsophalangeal joints, knees and lumbar facet joints, may be affected as well.
 - common (but useless) "pimp" information
 - Heberden's nodes: Bony overgrowth and significant osteoarthritic changes (i.e., osteophytes) at the DIP joints
 - Bouchard's nodes: Bony overgrowth and significant osteoarthritic changes (i.e., osteophytes) at the PIP joints
 - Pain may disappear but stiffness and deformity can be disturbing.
 - **Boutonniere's deformity: PIP flexion with DIP hyperextension Caused by subluxation of the extensor mechanism.**

- OA pain starts insidiously and increases slowly over months or years.
- It is aggravated by exertion and relieved by rest.
- Stiffness is worst after periods of rest.
- Typically symptoms follow an intermittent course, with periods of remission sometimes lasting for months.
- Night pain or pain at rest, swelling, deformity, tenderness, crepitus on movement, loss of mobility, muscle wasting, and joint instability (because the tissues contracted on one side and they are stretched on the other side and the muscles are fatigued) are features of advanced disease.
- OA is unassociated with any systemic manifestations.
- OA is uncommon in the shoulder, elbow, wrist and ankle. If any of these joints is affected you should suspect a secondary cause or previous injury to that joint. Muscular fatigue, Mild synovial inflammation.

433Team's NOTE: Hip osteoarthritis causes pain in the groin (not lateral hip or buttock). If patient is tender over the lateral aspect of hip, suspect greater trochanteric bursitis.

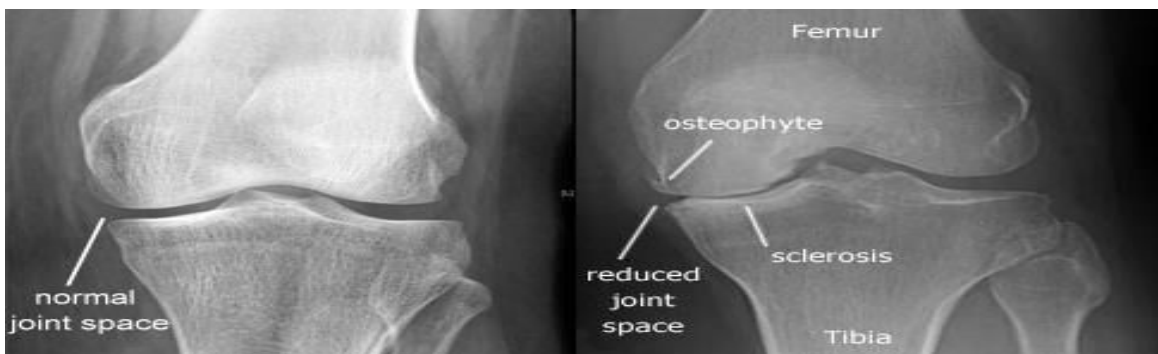X-ray finding:

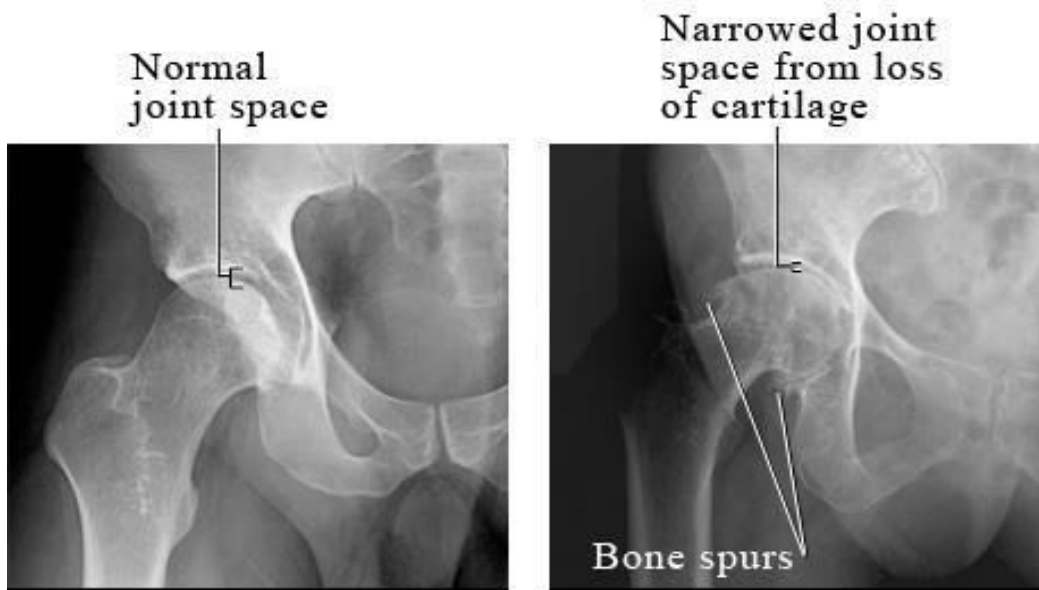
- Asymmetrical narrowing of the joint space (Symmetric narrowing indicate inflammatory OA like RA).
- Subarticular cyst formation and sclerosis.
- Osteophyte formation at the margins.
- Evidence of previous disorders that may have increased OA risk.

Late features: Malalignment, Joint subluxation, Bone loss, Loose bodies.

433Team's NOTE: Although x-rays are diagnostic of OA, not all patients with x-ray findings of OA have symptoms. There is no consistent correlation between symptoms and severity of x-ray findings.

Osteoarthritis x-ray finding Mnemonic : LOSS	Rheumatoid arthritis x-ray finding Mnemonic : LESS
L : Loss of joint space (asymmetric)	L : loss of joint space (symmetrical)
O : osteophyte formation	E : erosion of joint
S : subchondral sclerosis	S : synovial thickening
S : subchondral cysts	S : subluxation and joint deformities





Complication

- Capsular herniation: Knee OA, marked effusion and herniation of the posterior capsule (Baker's cyst).
- Rotator cuff dysfunction: acromioclavicular (AC) joint OA.
- Spinal stenosis.
- Loose bodies.
- spondylolisthesis: severe segmental instability; at L4/5.

Management

*Depends on several factors:

- Joint (or joints) involved.
- Age of the patient.
- Stage of the disorder.
- Functional need.
- Severity of the symptoms

❖ Early stage of the disease: **There are three principles:**

- **Relieve pain;** by Acetaminophen, NSAIDs, rest periods and modification of activities (avoiding activities like climbing stairs, squatting and praying on the floor), application of warmth, massage.
- **Increase joint mobility;** by physiotherapy, even a small increase in range and power will reduce pain, prevent contractures and improve function.
- **Reduce load;** by using a walking stick, unloading brace, wearing Shock-absorbing shoes, avoiding prolonged stressful activity and by **weight reduction**.
(For left knee or hip pain, the cane should be held in the right hand)

◆ Intermediate stage of the disease:

- **Arthroscopic joint debridement** (removal of interfering osteophytes, meniscal or labral tears and loose bodies (that cause blocking of the movement or cracking), for OA of the knee.
- **Corrective osteotomy** (redistribution of loading forces towards less damaged parts), it provides a significant pain relief because it provided vascular decompression, usual candidates are young, active patients with mild OA (you still have articular cartilages that you want to save). Nowadays the advances in joint replacement surgery have superseded it especially partial joint replacement.

◆ Late stage of the disease:

Joint replacement (Arthroplasty) is the procedure of choice for OA in patients with severe and advanced symptoms. Can be total for old patients with painful deformed stiff joint in or partial for young active patients with mild OA.

Arthrodesis (Fusion of the two ends of the bones) is sometimes indicated for joints in which permanent stiffness is not a drawback. Relieve only pain and cause permanent stiffness (in small joints e.g. in hand, foot and spine).

433TeamNotes:

- Injection is not recommended (usually they inject steroids), because we should repeat the injection every 6 weeks and if we decide to do joint replacement we should wait for 6 months at least +it carries a high risk of infection.
- Intra-articular Hyaluronic Acid injection (not recommended since December 2015).
- Stem cells also are not recommended and nothing can reproduce the cartilage after it is damaged. (It is about the biomechanics of the joint).
- Baker's cyst aspiration is wrong because it may lead to infection and it will be occur again after aspiration.