



[Color index : **Important** | **Notes** | Extra] Editing file [link](#)

Common Pediatric Fractures & Trauma

Objectives:

- ★ Introduction.
- ★ Difference between pediatric and adult.
- ★ Physis fracture, Salter-Harris classification, treatments and complications.
- ★ Indication of operative treatment.
- ★ Methods of treatment of pediatric fractures & trauma and there indications.
- ★ Common pediatric fractures:
 - U.L (clavicle, humeral supracondylar,distal radius)
 - L.L (femur shaft)
- know the mechanism of injury, evaluations (clinical & radiological), treatments and complications.
- ★ Examples.

Done by: Reema Allhidan, AlAnoud AlOmair

Edited By: Bedoor Julaidan, Ola AlNuhayer, Shahad Alanazi

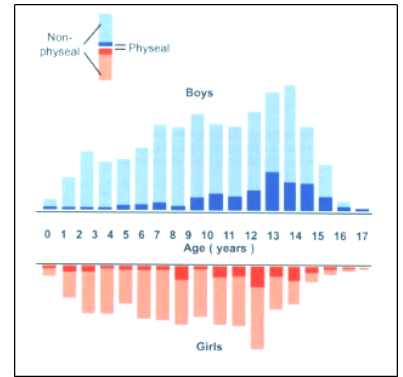
Revised by: Dalal Alhuzaimi

References: 435 Lectures And Notes, 434 Team, Group A Team, 433 Team Qs, ~Toronto notes

Pediatric Fractures

Introduction:

- Neonate (birth – 1 month)
- Infant (1 month- 2 years)
- Child (2 years – 12 years)
- Fractures account for ~15% of **all** injuries in children.
- Boys are prone to break their bones more than girls *شقاوة it's that simple*
- Rate increases with age
- Pediatric patient classification is arbitrary
- Type of fractures vary in various age groups (infants, children, adolescents).
- Pediatric fractures have **great remodeling potentials, growth plates** and **periosteum** are important in remodeling.
- A good number of cases can be treated conservatively, operative fixations aid in avoiding complications.



Adults are skeletally mature/ pediatrics are skeletally immature. **In Saudi Arabia pediatric age range is 14 “18 in the west” and below.**

Difference Between a Child and Adult’s Fracture

Why Children’s Fractures Different?

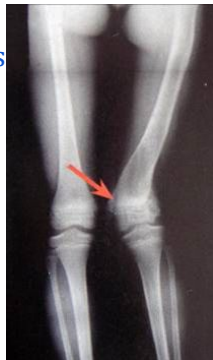Children have different physiology and anatomy

1- Growth plate:

- Have perfect remodeling power.
- Injury of growth plate may cause: **Angular deformity or leg length inequality (LLI)**
- A fracture might lead to overgrowth.
The **growth plate** gives the **length** in long bones, while the **periosteum** increase the **width** of a bone.

In the picture lateral side is arrested and medialis continue to grow "genu valgus deformity"

- If there is an injury to the **medial growth plate** and the lateral side is normal and the bone continues to grow we will have **varus deformity**
- If the injury is in the **lateral growth plate** we will end up having **valgus deformity**.
- If there is destruction to **both side the whole bone** will shorten (**leg length discrepancy**).

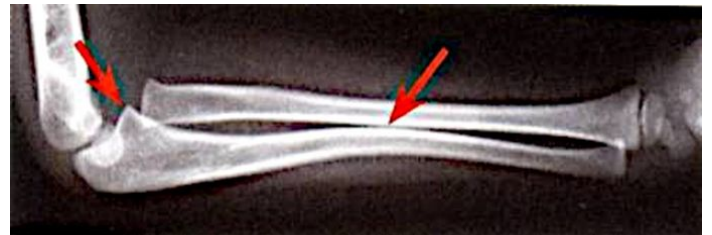


2- Bone ¹

Increased (collagen:bone) ratio

- Less brittle
- Deformation

The bone itself has more collagen than bone → do not fracture easily and it can bend sometimes, this is what we call **plastic deformation**.



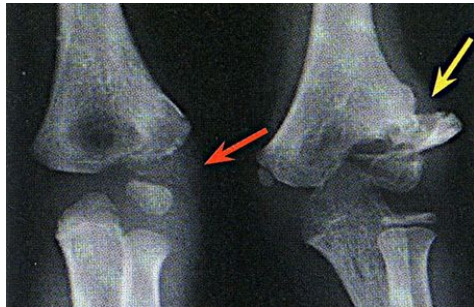Picture shows the cortex and periosteum are intact, It's not a fracture it's called **plastic deformation this is not the normal bowing of ulna**. The younger the patient the more you will see this.

¹ we know that greenstick fractures are more likely to occur in children and that's because of the bone composition, osteoid density is lesser in comparison with adults, and is loosely attached to tissue beneath. Juvenile bone has more **haversian canals** (forms a network in bone which contains blood vessels). As we mentioned that the children's bones have more haversian canals, which means better blood supply rare delayed and non-union in case of fractures (upside).

3- Cartilage

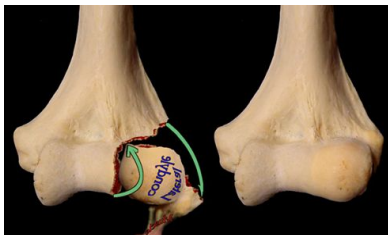- Difficult X-ray evaluation. Size of articular fragment often underestimated.
- We always operate if it involves the lateral condyle because the size of fracture is underestimated.

Children and adolescents have more cartilage that's why in an X-ray we see spaces .



Right picture (red arrow): Left elbow joint. You might think that the elbow has fracture without displacement (less than 2mm) so we can go conservative. the red arrow is pointing to the ossification center (this is not the radial head). this child is so young that the ossific nucleus of radius did not appear yet. this is the ossific nucleus of the **capitulum** and it should be higher up.

Left picture (yellow arrow): This is an elbow of an older child, the whole epicondyle is fractured and rotated → we call it fracture of necessity² (always going intra- articular) we don't go with conservative it should be **anatomical reduction** to prevent the risk of premature osteoarthritis .



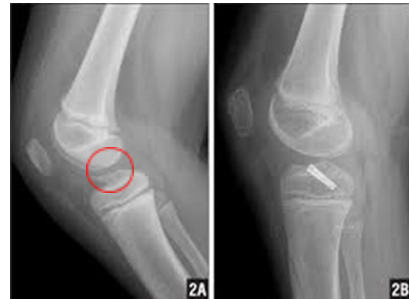5- Periosteum

- Metabolically active: More callus, rapid union, increased remodeling³.
- Thickness and strength: May aid reduction. Intact periosteal hinge effects fracture pattern.
- We don't see it in adult only pediatric.

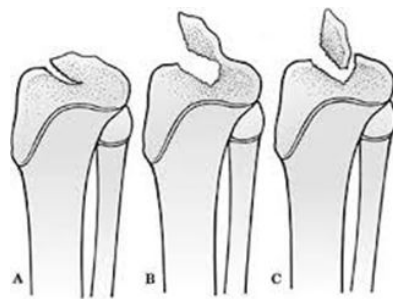
In adults, it becomes thinner but it's very strong in pediatric , where we need scalpel to cut it . We can't resuture it but we can bring back the two ends close to each other .

4- Ligaments

- Functionally **stronger than bone**, which means that an injury in the ligaments will most likely cause a bone fracture (avulsion fracture). **They will fracture the bone that they are attached to, but they won't tear.**
- Higher proportion of injuries that produce sprains in adults result in fractures in children.
- You'll never hear a child with ACL tear



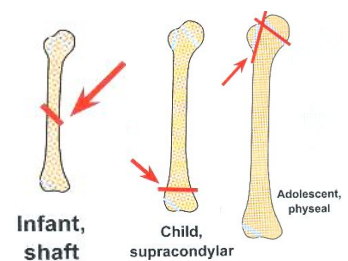
ACL is attached to the tibial eminence, tibial spine fracture is not normally see in adults. X-ray shows abnormal knee (tibial plateau should be smooth), we use a headless screw to stabilize it (arthrotomy or arthroscopy). ACL is intact, the injury happened in the epiphysis.



These are the degrees of displacement (not important)

6- Age related fracture pattern

Infants → **diaphyseal** fractures
 Children → **metaphyseal** fractures (close to physis)
 Adolescents → **epiphyseal** fractures



² in reference to the frequent need for surgical intervention

³ Plate often mistaken for fracture on x-ray and vice versa (x-ray opposite limb for comparison especially in the elbow.

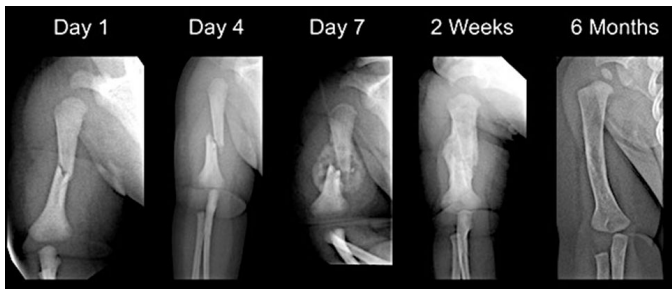7. Physiology

- Better blood supply. because they have the normal blood supply for the muscles and the joint + the periosteum which is super thick.
- The **periosteum** has nerve endings while the bone itself doesn't have nerve endings, so in any fracture the pain felt is due to the movement of the periosteum not because of the fracture itself. That's why the first line in management and the first line of analgesia for any fracture is **immobilization**.
- Rare incidence of delayed and non-union. (why? remodelling) In pediatrics we can go with **conservative** more than operative because the remodeling is very high.

Examples of Remodeling in children: هذا اللي يميز الأطفال

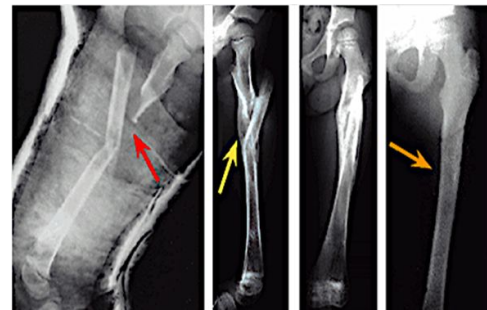
This is more evident the younger the child. Don't expect this in child aged 13-14 year old.

We only realign the bone then apply casting. Fractures near to a joint that moves everywhere (shoulder) and near to epiphysis → Better for remodeling.



This radiograph shows diaphyseal humeral fracture

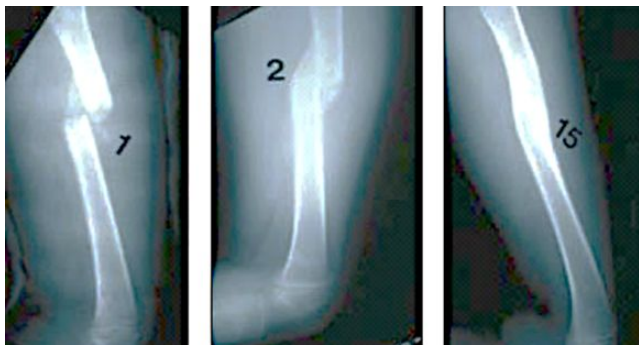- Note the tremendous amount of callus at day 7
- 6 months → almost normal



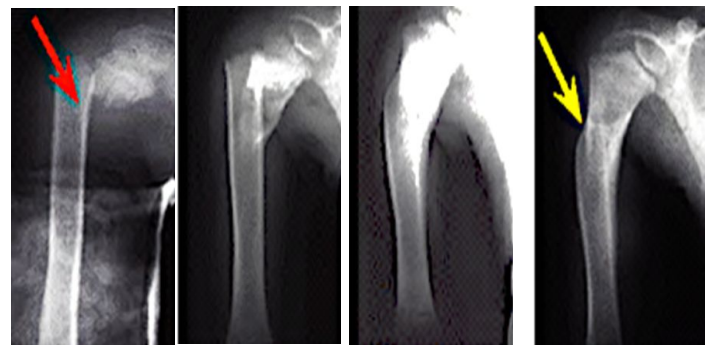Femur fracture Big callus forms Remodelling

3 segments fracture

You can see the POP cast in the first pic



100% translation of femur bone fracture Union happened at 15 weeks



Fracture in the humerus surgical neck with remodeling.

Physis injuries

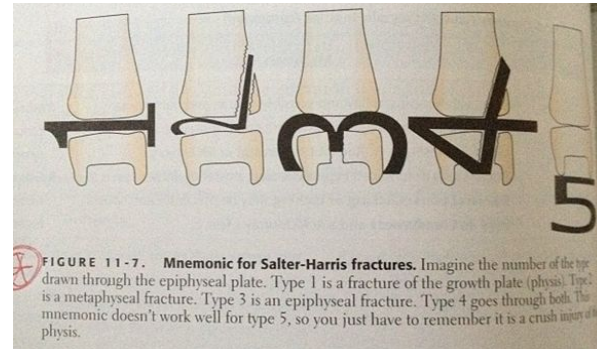
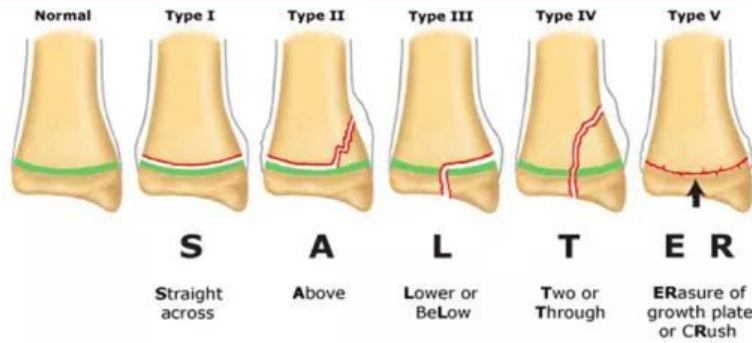
Introduction:

The growth plate, or physis, is the translucent, cartilaginous disc separating the epiphysis from the metaphysis and is responsible for longitudinal growth of long bones.

- ★ Account for ~25% of all children's fractures
- ★ More in boys شقاوة, more in **upper limb**. more in the dominant hand.
- ★ **Most** heal well rapidly with good remodeling but growth **may** be affected
- ★ Classified by Salter-Harris classification.

Salter-Harris Classification: مهم جدًا ولا يخلو اختبار منه

Salter-Harris classification of physeal fractures



<p>Type I:</p>	<p>Through the growth plate. It doesn't appear on the x-ray, so usually request an x-ray to the other side. In type 1, you go with history and examination mainly (A Child fell down and he is crying and holding his knee, he can't weight bear (femur)) sometimes in X-ray you see a fracture slightly translated but don't forget your history and examination in which you can reach a diagnosis up to 70 % just by proper history. A transverse fracture through the hypertrophic or calcified zone of the plate. Even if the fracture is quite alarming displaced, the growing zone of the physis is usually not injured and growth disturbance is uncommon.</p>
<p>Type II:</p>	<p>Growth plate with metaphysis. بالعاده نشوف مثلث صغير احيانا تقوته. This is similar to Type 1, but towards the edge the fracture deviates away from the physis and splits off a triangular piece of metaphyseal bone. Growth is usually not affected. This is the commonest type</p>
<p>Type III:</p>	<p>Growth plate with epiphysis. "Intra-articular", needs anatomic reduction, usually it will go to surgery. This fracture runs partly along the physis and then veers off through all layers of the physis and the epiphysis into the joint. Inevitably the reproductive zone of the physis is damaged and this may result in growth disturbance. one of the complication is premature osteoarthritis.</p>
<p>Type IV:</p>	<p>Growth plate with metaphysis and epiphysis. needs anatomic reduction, usually it will go to surgery. As with Type 3, this fracture splits the epiphysis, but it continues through the physis into the metaphysis. The fracture is particularly liable to displacement and a consequent misfit between the separated parts of the physis, resulting in asymmetrical growth. (corrected with K-wires and screws).</p>
<p>Type V:</p>	<p>A longitudinal compression injury of the physis. sometimes you have to do X-ray for both limbs to compare. There is no visible fracture but the growth plate is crushed and this may result in growth arrest. The worst Type.</p>

In the exam you will be asked about **the type of Salter Harris**. Usually we don't bring type 5 bc we need to give you a comparison X-ray of the other limb. We do comparison X-ray only when we need it. We don't want to expose the child to unnecessary radiation. If you find Type 5 you are justified to take a comparison x-ray

Complications of Physeal Injuries:

Physeal bridging or bar shutdown of the factory < 1%

As we know you can't fracture the whole physeal plate, so the healthy part will keep growing and that will result in either **valgus or varus**. Statistically small bridges and central bridges are more likely to lyse. While peripheral bridges are more likely to cause deformity.

- This will affect growth (varus, valgus, or even leg length inequality).
- Keep in mind:
 - Small bridges (about <10%) → may lyse spontaneously.
 - Central bridges → more likely to lyse.
 - **Peripheral bridges → more likely to cause deformity.** مشكلتنا الكبيرة هنا
- Take care with physeal injuries: غالباً هذه الحالات ما تسلم إلا للسينيرز أو الرجسترازز
 - **Avoid** injury to physis during fixation.
 - **Monitor** growth over a long period (18-24 month) varus or valgus will not appear immediately, it will take time to appear. Bc in the period of 18-24 months, the body is still healing.
 - When suspecting physeal bar do **MRI**. cause you are looking for soft tissue (growth plate).




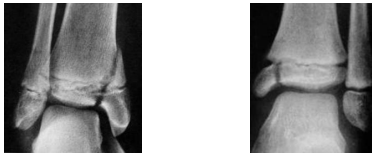
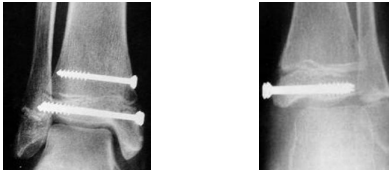

In the questions bank we have MCQs about the early and late complications




Indication of Operative Treatment **MCQ** golden slide !

1. **Open fractures**
2. Severe soft-tissue injury to do debridement
3. Fractures with vascular injury actual cut of the vessels
4. Compartment syndrome "it depends when patient came to hospital (6 golden hours)"
5. Multiple injuries
6. **Displaced intra articular fractures (Salter-Harris III-IV)**
7. **Failure of conservative means (irreducible or unstable fractures)**
8. Malunion and delayed union **very rare** "when you see **nonunion** in MCQs don't choose it". One of the causes of nonunion is exposure to smoking.
9. **Adolescence** we tend to treat them as adult, bc the remodeling potentials are really low.
10. **Head injury** in RTA. When the patient loses consciousness the body starts healing. At the beginning catabolic stage caused by the injury → they'll develop a lot of callus" what happen in week 4 can happen in weeks 2 that's why we should fix it as soon as possible before it **malunite**. Except if the fracture is nondisplaced and immobilizes properly → we don't need surgery.
11. **Neurological disorder** cerebral palsy, myelomeningocele pts. (they're not normal and sometimes their bones don't heal in a normal way)
12. **Uncooperative patient** like pts with ADHD.

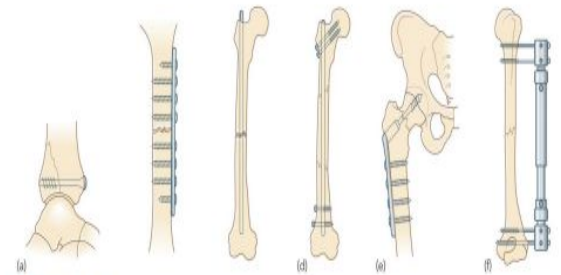
Methods of Treatment of Pediatric Fracture & Trauma

Never forget to check **neurovascular status** before and after any kind of management whether it's reduction or casting.

Type	Indication	
<p>Casting</p> 	<p>Acute fractures or sprains, or for initial stabilization of reduced, displaced, or unstable fractures before orthopedic intervention. Used to correct deformities especially in pediatrics</p>	<ul style="list-style-type: none"> ● Still the commonest ● casting is the first option of treatment ● In infants we don't use cast, instead we use tongue depressor.
<p>K-wire</p> 	<ul style="list-style-type: none"> ● Fractures in epi-/metaphyseal areas. ● Fractures of small bones (e.g. hand and foot). ● Small bony fragments. ● For fragment reposition in multifragmentary fractures in addition to stable fixation. 	<ul style="list-style-type: none"> ● Most commonly used internal fixation (I.F). ● Usually used in metaphyseal fractures supracondylar fractures. ● Inserted percutaneously in OP under GA
<p>Intramedullary wires (Elastic nails) MCQ</p> 	<p>When you bend a K wire it will bend but elastic wire will recoil. The elastic wire uses the technique of 3-points fixation (2C shaped wires, they come straight and we bend them to give a push in the center. Usually used in mid-shaft diaphysis → stabilizes the fracture (3 points: upper crossing/ lower crossing/ central push). In the radius and ulna we don't have enough space in the medulla to put 2 wires so we put 1 wire. Used mainly in pediatrics but can be used in adults</p>	
<p>Screws</p>	<p>Before</p>  <p>salter harris 4 salter harris 3</p> <p>After</p> 	<p>We usually treat it with 2 screws In salter harris 4: one for epiphysis and the other for metaphysis) In salter harris 3: two screws in the medial malleolus (you can see 2 heads and 2 tips) We NEVER cross a physis with a screw cause it will destroy the growth plate, with a k-wire yes cause it's smooth. Remember in SCFE (salter harris 1) we put a screw for in situ fixation but we won't fuse it into the growth plate.</p>
<p>Plates</p> 	<p>In multiple trauma</p> <p>Comminuted fracture and we use bridging plate. In comminution we don't search for each single piece to fix but what is important is to keep length to prevent LLD</p>	

<p>Intramedullary Nailing (I.M.N)</p> 	<p>Only in adolescents (> 12y) MCQ</p> <p>There is growth plate for head of femur and other for greater trochanter. The area between the greater trochanter and the neck is called piriformis fossa (blood supply of the growth plate of the greater trochanter) if I go there with an IM nail I will interfere with the blood supply "AVN" of the greater trochanter, it will affect the growth plate and it will grow into valgus and if it goes into too much valgus it will dislocate.</p> <p>IF I give you MCQ and the options are IM nail, K wire, Elastic nail, traction please look at the age: If it's 14 year old pt chose IM nail / If it's 4 year old pt chose elastic nail</p>
<p>External-Fixation</p> 	<p>Usually in open fractures</p> <p>Valid in pts who have skin conditions. "crush injury"</p> <p>Used as a temporary treatment for fractures. Because they are easily applied, external fixators are often put on when a patient has multiple injuries and is not yet ready for a longer surgery to fix the fracture.</p>
<p>Combination of the above</p>	

- Usually in pediatrics we remove the screws
- We always remove Plate and screws in pediatrics once it heals bc later on it will grow on top of it through which I will have to cut the cortex for removal → potential area for pathological fracture. That's why we use wires which can be removed very easily. Plates and screws has limited use.
- In adults : upper limb we don't remove the screws cause there is a lot of nerves and blood vessels.
- In the lower limb we have to remove, cause after it heals we will have something called shear force (breaks in the sites of the screws)
- Fellow level info: if the pt have some sort of handicap and walks on the upper limb then we have to remove it




12.2 Bone fixation Several methods of fixation are used, depending on site and circumstances. (a) A lag screw for interfragmentary compression. (b) Plate and screws. (c) Intramedullary nail. (d) Locked intramedullary nail. (e) Dynamic hip screw. (f) External fixator.

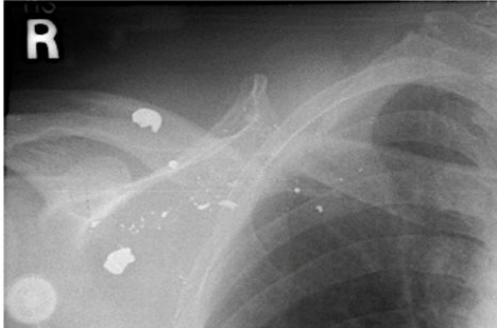
Common Pediatric Fractures

Common Pediatric Fractures:

- Upper Limb: Clavicle / Humeral supracondylar / Distal radius (most common) (phalanges second)
- Lower Limb: Femur shaft (diaphysis).

1) Clavicle Fractures:

Incidence	Mechanism of Injury
<ul style="list-style-type: none"> 8-15% of all pediatric fractures 0.5% of normal SVD 1.6% of breech deliveries 90% of obstetric fractures (use of forceps) 80% occur in the shaft of clavicle The periosteal sleeve always remains in the anatomic position hematoma is contained and thus callus is contained so healing is rapid (remodeling is ensured) 	<ul style="list-style-type: none"> Indirect: Fall onto an outstretched hand. Direct: The most common mechanism, has highest incidence of injury to the underlying: either he/she felt directly on their neck area or direct blow with an object. This has highest incidence of injury to the underlying: N.V & Pulmonary structures. Birth injury.
Clinical Examination	Reading X-Ray: AP view
<p>Look: Ecchymosis, swelling, bruises, tenting of the skin</p> <p>Feel:</p> <ul style="list-style-type: none"> Extreme tenderness at fracture site As a palpable mass along the clavicle (as in displaced fracture) when presented late you can feel the callus You feel crepitus of fracture (when lung is compromised) <p>Special tests must assess for any:</p> <ul style="list-style-type: none"> Neurovascular (N.V) injury. examine the brachial plexus, subclavian vessels Pulmonary injury. If the fracture went downward 	<ul style="list-style-type: none"> Location: (medial, middle, lateral) 1/3, commonest middle 1/3 Commonest fracture site: junction of middle and lateral 1/3. Open or closed see air on XR it's skin on bone, you have to exclude open fracture Displacement %. how much displaced or angulated Fracture type: segmental, comminuted, greenstick. if pneumothorax you will see air in the x-ray. <div style="display: flex; justify-content: space-around;">  </div>

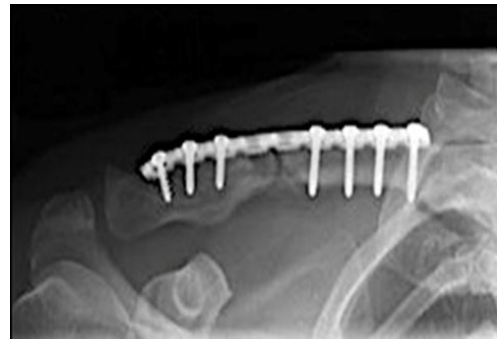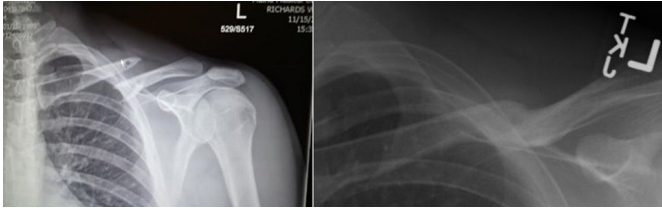
Treatment: ⁴	Indications of operative treatment
<p>Newborn (<28 days):</p> <ul style="list-style-type: none"> No orthotics, Unite in 1 week. Bc the sensory nervous system is not fully developed, we just tell the mother handle him with care⁵ <p>1 month to 2 years:</p> <ul style="list-style-type: none"> Figure-of-eight it just help in realignment for 2 weeks. <p>2 years to 12 years:</p> <ul style="list-style-type: none"> Figure-of-eight or sling for 2-4 weeks. 	<ul style="list-style-type: none"> Open fractures (tinting of the skin) Neurovascular, pulmonary compromise <div style="text-align: center;">  </div>

⁴ The periosteal sleeve always remains in the anatomic position (remodeling is ensured)

⁵ Any fracture to heal take 6-8 weeks, the first 3 weeks (after 3 weeks it becomes sticky) we are afraid of displacement in cast, like in colle's we tend to see them weekly in the beginning bc we are afraid of displacement. Here in newborn, in 1 week it's already sticky



Remodeling



Complications

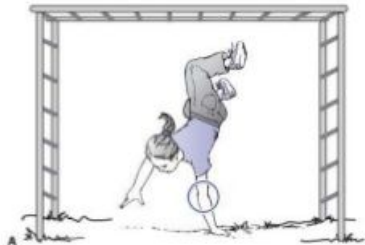
From the fracture

- Malunion
- Nonunion
- Secondary from healing:
Neurovascular compromise
Pulmonary injury

From the wound of surgery MCQ

- Bad healed scar **major indication not to do surgery, keloid in this area is very bad bc we are crossing the fibers → heals very bad**
- Dehiscence
- Infection

2) Humeral Supracondylar Fractures: it's so common it's so common it's so common !!!

Incidence	Mechanism of Injury
<ul style="list-style-type: none"> ● 55-75% of all elbow fractures ● M:F 3:2 incidence ● Age: 5-8 years can present in younger or older ages ● Left (non-dominant) side is most frequently fractured its an observation not a rule. 	<ul style="list-style-type: none"> ● Indirect (95%): Extension type. see the pic ● Direct (<3%): Flexion type. when the child falls into the elbow نفس المصارع لما يطيح على خصمه 

Clinical Examination

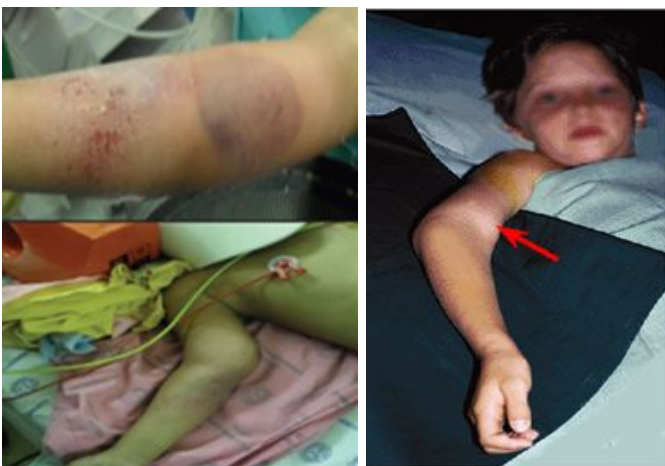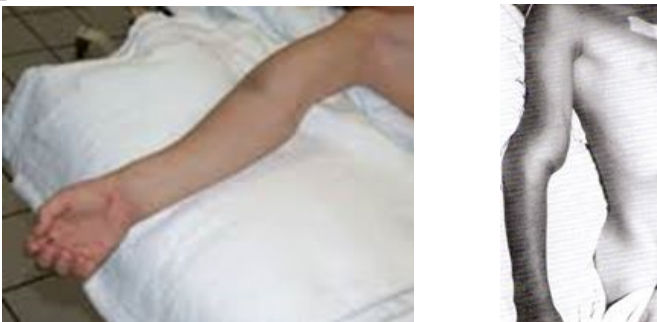
Look: Swollen **all over**, S-shaped angulation fractured then went posteriorly, Pucker sign (dimpling of the skin anteriorly), may have bruises. pucker sign (dimpling of the skin anteriorly same as tethering)

Feel: Tender elbow. You want to feel the tissues in the compartment are they soft or not (check for compartment syndrome), bc up to 15-20% are missed injuries

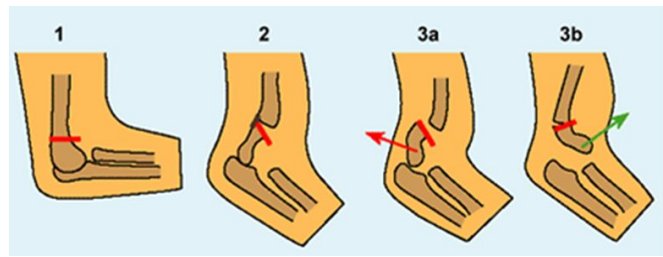
Move: Painful and can't really move it. **please don't move a suspected fracture !!!** you can shift a non displaced fracture to a displaced fracture. If displaced → NV injury.

Neurovascular examination: You want to check all the nerves: Median, radial, and ulnar nerves as well as their terminal branches. You are moving to check the neurovascular not the fracture itself
The commonest nerve to be injured is: Anterior interosseous nerve, which is branch from the median nerve. The way to assess: ask the patient to do (ok) sign.

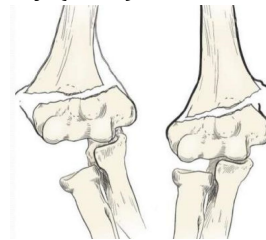
Vascular: Brachial. Capillary refill and distal pulses should be documented.



Gartland Classification⁶ for supracondylar fractures



- **Type 1:** No displacement.
- **Type 2:** Minimal displacement. posterior cortex and posterior periosteum intact. Anterior is open.
- **Type 3:** Complete displacement, if it's going backward (**3a**): Extension fracture "indirect Trauma" ... Forward (**3b**): Flexion fracture "direct trauma".
- Type-III Complete displacement (extension type) may be (3a) can be: displaced Posteromedially (75%), or Posterolaterally (25%)



- If the **distal** fragment went **posteromedially** → it will **strip** the periosteum in the same side → the blood vessels in the same side got injured with formation of micro-hematoma which is good → contained callus formation. But bc this is a sharp end it will **cut** the periosteum on the opposite side → not a stabilizing factor any more in the opposite side. **when I want to reduce this fracture I want to maintain the periosteum to help me in the healing. So incision will be in the lateral side.**

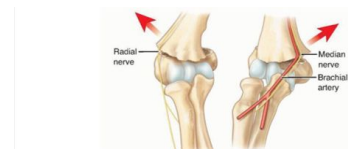

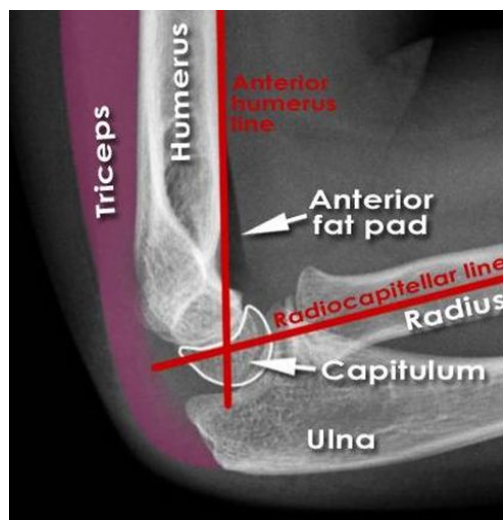
FIG 2 • Relationship to neurovascular structures. The proximal metaphyseal spike penetrates laterally with posteromedially displaced fractures and places the radial nerve at risk. With posterolaterally displaced fractures, the spike penetrates medially and places the median nerve and brachial artery at risk.

- Posteromedial displacement → you think about the structures that run laterally → radial nerve injury
- posterolateral displacement → you think about structures that run medially → median nerve (anterior interosseous) + brachial artery
- Ulnar injury is seen in flexion fracture (3b)

⁶ The Gartland classification is a system of **categorizing** supracondylar humerus fractures, clinically useful as it predicts the likelihood of **associated** neurovascular injury, such as anterior interosseous nerve neuropraxia or brachial artery disruption.

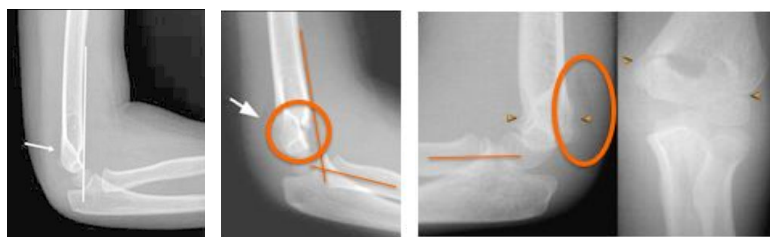Reading X-Ray AP + Lateral view & treatment

Normal X-Ray Lines: **IMPORTANT**



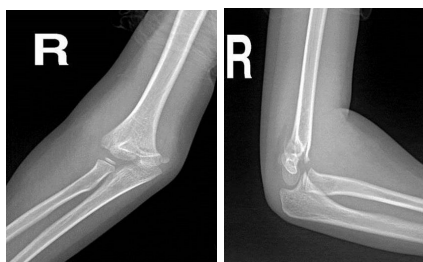- Always Anterior Humeral Line should cross the capitulum⁷
- Hour-glass appearance
- Fat-pad sign
- Radio-capitellar line

Type-I



- Anterior Humeral Line is intact
- Hourglass is partially disrupted
- Fat pad sign. Triceps is attached to olecranon and with fracture there is hematoma. The hematoma will elevate the triceps under periosteum → you see fat pad sign (posterior not anterior)
- Radiocapitellar line is intact → (Radiocapitellar joint is intact) bc supracondylar fracture is just a fracture above the elbow joint (the elbow joint is ok). This line should be intact always in the supracondylar fractures
- **Management:** Above elbow cast (or splint) for 2-3 weeks. غالبًا يكون التأم بس راح نتابع زيادة

Type-II



They can't do full AP cause they are in pain. Diagnosis is always with lateral X-ray. posterior cortex is still in contact with each other

- Displaced anterior humeral line
- Disrupted hourglass (you don't see the 2 bellies and neck)
- Fat pad sign is present

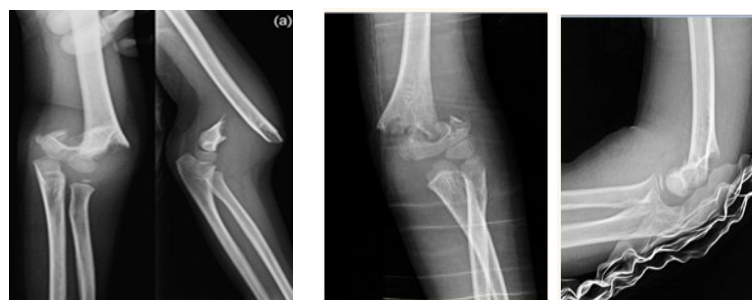Management:

1- Closed reduction and above elbow casting we give the patient conscious sedation and we try to reduce fracture.

If it fails → close reduction with K-wire fixation

2- closed reduction with percutaneous pinning (if there is unstable or severe swelling), and above elbow cast (splint) for 4-6 weeks

Type-III



First 2 pics (Extension type)

Loss of contact (posterior and medial displacement) type 3A.




Last 2 pics (Flexion type) What is seen in the x-ray is a type of temporary immobilizer.

Management:

1- We attempt Closed reduction (in younger age) & percutaneous pinning, If fails ORIF (open reduction & pinning) for 4-6 weeks When they are older we usually have to go in for surgery, we still do the close reduction and we do our K-wire. If we did the close reduction and it's not stable we need an open reduction

2- Direct open reduction and internal fixation (ORIF) if open fracture (ORIF)

⁷ the capitulum is 40 to 45 degrees angulated forward

		
<p>In the pic → milking of fracture fragments (we try to push it in front)</p>	<p>The classic treatment → 2 crossing smooth k-wires (from the 2 epicondyles and we cross). but what is the problem here? ulnar nerve, sometimes the fracture itself didn't injure the ulnar nerve but when you went through the epicondyle you injured the nerve. the treatment now is 2 lateral 1 medial. If we're obligated to remove medial wire bc of iatrogenic ulnar nerve injury → at least we have 2 lateral good wires holding the fracture</p>	<p>In this open fracture → median nerve and brachial artery are injured</p>

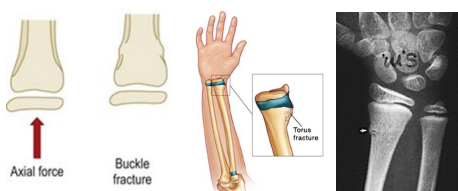


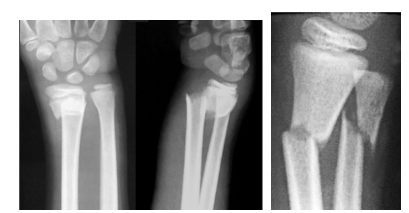


Complications

<p>Neurologic injury (7% to 10%):</p>	<p>Others:</p>
<p>Median and anterior interosseous nerves (most common) Most are neuropraxias requiring no treatment. نبدأ نقلق بعد 6 شهور</p>	<ul style="list-style-type: none"> ● Loss of motion (stiffness) ● Myositis ossificans specifically to the muscles unlike the heterotrophic ossification "Ossification that occurs in muscles. Bone in muscles ---> Complete stiffness" Ca deposit in the muscle around the elbow joint → at the beginning there is little bits of movements → when this becomes mature. خلاص انتهى الموضوع. ● Angular deformity (cubitus varus) the body tends to remodel it
<p>Vascular injury (0.5%):</p>	
<p>Direct injury to the brachial artery Secondary injury due to swelling (compartment syndrome) we tend to go in quickly to prevent compression.</p>	<div data-bbox="678 1276 1365 1434" data-label="Image"> </div> <p>26.16 Supracondylar fractures – complications (a) Varus deformity of the right elbow following incomplete correction of the varus displacement in a supracondylar fracture. (b) The 'gun-stock deformity' becomes more obvious when the arms are raised. (c) X-ray showing the malunion.</p> <ul style="list-style-type: none"> ● Compartment syndrome we do fasciotomy <div data-bbox="672 1520 1435 1776" data-label="Image"> </div>

⁸ Volkmann's contracture is a permanent flexion contracture of the hand at the wrist, resulting in a claw-like deformity of the hand and fingers. Passive extension of fingers is restricted and painful.




3) Distal Radius Fracture

A) Metaphysis:

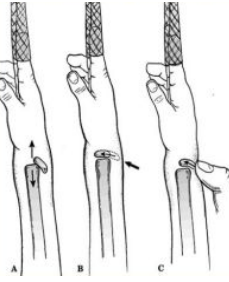


Classification ⁹		
Torus (buckle)	Incomplete (greenstick)	Complete
<p>only one cortex is involved while periosteum is intact either one side or both sides <i>بعجة</i> They are stable. so you depend on history and examination in order to know its location</p>   <p>Treatment: Immobilized for pain relief in below elbow cast for 2-3 weeks. Bicortical injuries should be treated in long arm cast.</p>	 <p>Intact one cortex and minimally displaced (depending on the force direction) other cortex Greater ability to remodel (why?) 1- The periosteum is still intact 2- It's incomplete fracture 3- It's close to the growth plate</p> <p>Treatment: Closed reduction and above elbow cast for 4-6 weeks with supinated forearm "Anatomical position" to relax the brachioradialis muscle. We do above elbow cast to prevent supination/pronation. It happens in both the proximal and distal radioulnar joint.</p>	 <p>Fracture of both bones Treatment: 1- We always attempt Closed reduction (we pull the distal fragment until cortex come in contact then <i>تنزل</i>) + well molded above elbow cast for 6-8 weeks</p>  <p>2- Or open reduction if we cannot achieve closed reduction or we can do closed reduction but it's not stable and fixation (internal or external)</p>  <p>Indications for ORIF: Irreducible fracture, open fracture, compartment syndrome. internal fixation with 2 crossing wires (no place for plates and screws → you need 3 screws above and 3 below fractures)</p>
Complications		
<ul style="list-style-type: none"> - Malunion: Residual angulation (more than 20%) may result in loss of forearm rotation - Nonunion (rare) - Refracture: With early return to activity (before 6 weeks) "needs surgery" If a fracture went conservatively and healed then the patient came back with refracture within 6 months <i>Have to go for surgery</i> - Growth disturbance: Overgrowth or undergrowth (3mm/9-12yrs) - Neurovascular injuries: With extreme positions of immobilization 		

⁹ The usual injury is a fall on the outstretched hand with the wrist in extension; the distal fragment is usually forced posteriorly (this is often called a 'juvenile Colles' fracture'). Lesser force may do no more than buckle the metaphyseal cortex (a type of compression fracture, or torus fracture).

B) Physis:¹⁰

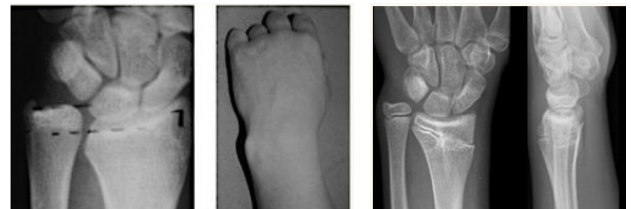"S.H" Type I	"S.H" Type II	"S.H" Type III
	 <p data-bbox="548 499 992 646">fracture and it's displaced It's not intraarticular → not SH 3 once you see small triangle (orange arrow) → this is type 2</p>	 <p data-bbox="1036 552 1544 632">There could be SH 1 in the distal ulna (growth plate is wider than usual)</p>

Treatment: (Majority treated with closed reduction and casting) Toronto

For Type I and II	For Type III
<ul data-bbox="74 835 964 1276" style="list-style-type: none"> - Closed reduction followed by above elbow cast with the forearm pronated - We can accept deformity: 50% translation, with no angulation or rotation - Complication: Growth arrest can occur in 25% with repeated closed reduction manipulations - Open reduction is indicated in: Irreducible fractures and open fractures - In the pic: 2 parallel wires (we can use crossing, according the available space "there are a lot of tendons and NV structures") - In the pic: open fracture type 1  	<ul data-bbox="1008 835 1549 982" style="list-style-type: none"> - Anatomic reduction necessary intra-articular - ORIF with smooth pins or screws in the epiphysis  <p data-bbox="1040 1255 1516 1289">For Type IV and V (rare injuries)</p> <p data-bbox="1003 1325 1555 1430">Need ORIF Type 5 is really rare. Sometimes we pick it up only with complications: LLD</p>

Complications of Distal Radial Physeal Fractures:


- Physeal arrest:** (MRI to assess)
 - Shortening ulna should be shorter than radius
 - Angular deformity (see the pic)
- Ulnar styloid nonunion**
- Carpal tunnel syndrome**





Calcified bar in the center. Growing from the sides and tethered in the center. The body couldn't lyse this one

¹⁰ Physeal fractures are almost invariably Salter–Harris Type 1 or 2, with the epiphysis shifted and tilted backwards and radially

4) Femur shaft Fractures (diaphysis):

Incidence	Mechanism of Injury
<ul style="list-style-type: none"> ● 1.6% of all pediatric fractures ● M > F ● Age: (2-4) years old, mild-adolescence 2 peaks ● Adolescence >90% due to RTA. ● In children younger than walking age, 80% of these injuries are caused By child abuse; this decreases to 30% in toddlers 	<ul style="list-style-type: none"> ● Direct trauma: RTA, fall or child abuse ● Indirect trauma: Rotational injury ● Pathologic fractures: Osteogenesis imperfecta, nonossifying fibroma, bone cysts or tumors <p>How to know if it's direct or indirect from x-ray? Transverse and Comminuted fractures are direct; the spiral is indirect.</p>
Clinical Examination	Reading X-Ray: AP and lateral view
<p>Look: Pain, swelling of the thigh, inability to ambulate and variable gross deformity Careful O/E of the overlying soft tissues to rule out the possibility of an open fracture (puncture wound)</p> <p>Feel: Tenderness at fracture site Careful neurovascular examination is essential</p>	 <p>This is usually how they appear “like a spike” → risk of open fracture</p>

Treatment:

< 6m	6m – 6y
<ul style="list-style-type: none"> ● Pavlik Harness. ● Closed reduction and immediate hip spica casting ● Or traction (a lot of overlap) 1-2w, then hip spica casting 	<ul style="list-style-type: none"> ● Closed reduction and immediate hip spica casting (>95%) ● Or traction in the pic: 90-90 “hip is 90 and knee is 90” skeletal traction to disimpact the fracture. we almost never do this. 1-2w, then hip spica casting 

6 - 12y

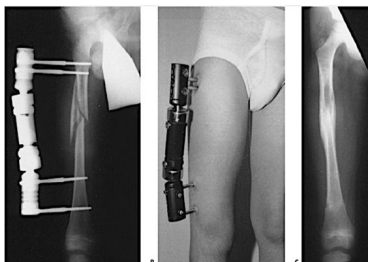
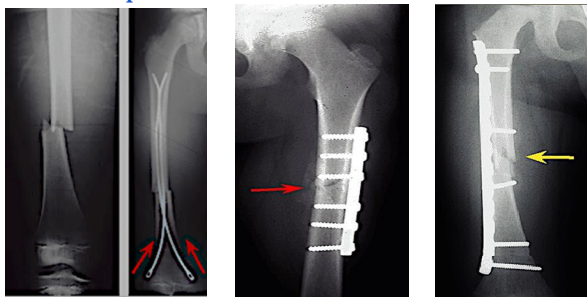
- **Flexible I.M.N** it must be diaphyseal fracture
- **Bridge Plating** bridging plate is when we use the most proximal and most distal screws. Direct plate when we use all the screws
- **External Fixation:**
 1. multiple injuries
 2. open fracture
 3. comminuted fractures
 4. unstable patient

first pic: IM nail

second pic: Direct plate

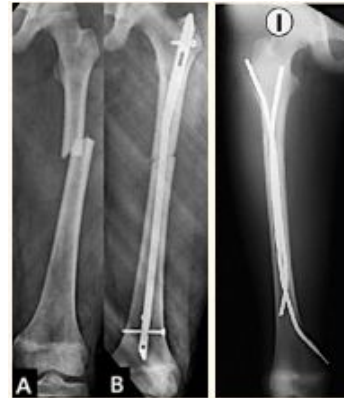third pic: Bridging plate (there is comminution so we used bridging plate)

forth pic: EX fix



12y to skeletal maturity

Intramedullary fixation with either: **flexible nails** or **locked I.M nail**



Operative indications:

1. **Multiple trauma** including head injury
2. **Open fracture**
3. **Vascular injury**
4. **Pathologic fracture**
5. **Uncooperative patient**

Complications:

1. **Malunion:** remodeling will not correct rotational deformities **with comminution, the distal femur goes into rotation**
2. **Leg length discrepancy:** secondary to shortening or overgrowth of 1.5 to 2.0 cm is common in 2-10year of age.
3. **Muscle weakness**
4. **Nonunion** (rare)
5. Osteonecrosis with antegrade " it means from knee and above" IMN <16 year.

MCQS

Q1- Which of the following is true regarding Physis injury?

- A. Common in dominant lower limb
- B. Common in dominant upper limb
- C. Common in non-dominant lower limb
- D. Common in non-dominant upper limb

Q2- Which of the following is true regarding Supracondylar injury?

- A. Common in dominant limb
- B. Common in non-dominant limb

Q3- Which of the following is NOT an indication for surgery?

- A. Non-union of the fracture
- B. Malunion of the fracture
- C. Delayed union of the fracture
- D. Uncooperative patient

Q4- Which of the following is the most common method of fixation?

- A. Plates
- B. Cast
- C. Screws
- D. I.M.N

Q5- Which of the following methods of fixation is commonly used in metaphyseal fractures? ??

- A. Screws
- B. Plates
- C. I.M.N
- D. K-wires

Q6- Which of the following methods of fixation is suitable for a 13y old boy who had a femur diaphysis fracture?

- A. Intramedullary fixation with flexible nails
- B. K-wires
- C. Screws
- D. Cast

Q7- Which of the following methods of fixation is suitable for a 7y old boy who had an open femur diaphysis fracture?

- A. K-wires
- B. External fixation
- C. Casting
- D. I.M.N

Q8- What are the common fracture pattern in Infants?

- A. Infants: diaphyseal fractures
- B. Infants: metaphyseal fractures
- C. Infants: epiphyseal injuries

Q9- What are the most important systems you have to check in Clavicle Fracture?

- A. Neurovascular
- B. Pulmonary function
- C. a & b

Q10- What are the most common type of Clavicle Fracture?

- A. Type I: Middle third
- B. Type II: lateral third
- C. Type III: Medial third

Q11- What is the cause of Femoral Shaft Fractures in children younger than walking age?

- A. Child abuse.
- B. RTA.
- C. Birth injury.

Q12- Bicortical injuries should be treated as?

- A. In a long arm cast.
- B. Closed reduction followed by percutaneous pinning.
- C. Reduction.

Q13- Which of the following methods is the most suitable for multiple trauma fixation?

- A. Cast
- B. Screws
- C. K-wires
- D. Plates

