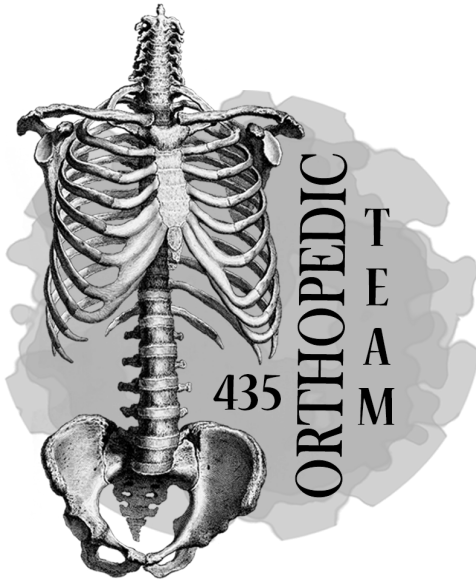



[ Color index: **Important** | **Notes** | Extra ] Editing file [link](#)

## Common Hip Pediatric Problems

### Objectives:

★ Not Given :(

**Done by:** Norah Ibrahim Alromaih

**Edited By:** Bedoor Julaidan

**Revised by:** Dalal Alhuzaimi

**References:** 435 Lecture, Notes and Toronto notes

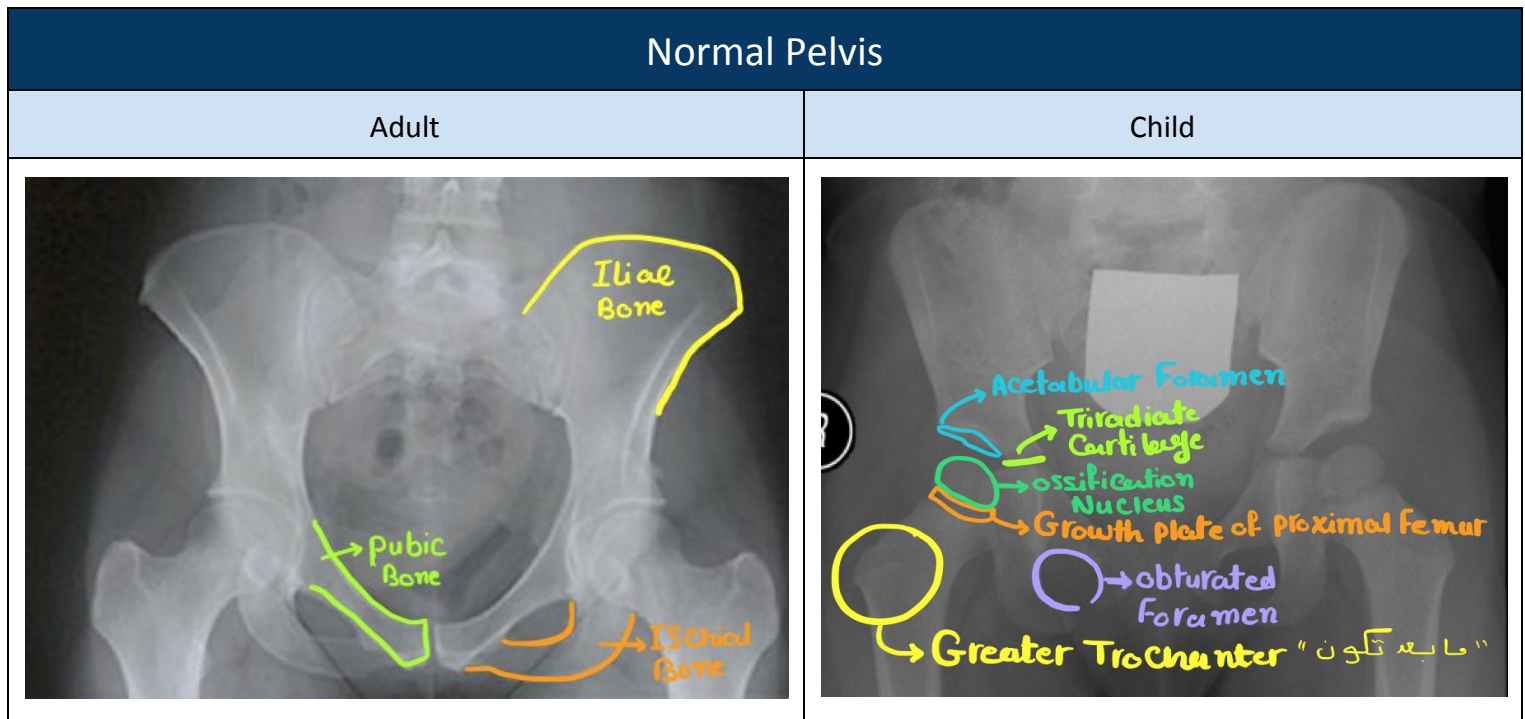
# Overview

## Pediatric patients are different from adult patients!

- ★ **How?** Pediatric patients bones have **growth plate** so they are still growing, their bones are **smaller** and **elastic** and they have their **own diseases**.
- ★ **For example:** did you hear about pediatric knee or hip replacement? **NO**, because they are still growing so they need to grow until full growth (being adult) to do these surgeries.
- ★ **Common pediatric hip problems:**

1. **Developmental Dysplasia of the Hip (DDH).** “most common orthopedic disorder in newborns”
2. Slipped Capital Femoral Epiphysis (SCFE). القروث بليت ضعيف، مثل الغراء لما يكون ضعيف ما يمسك الشيء مع بعض head عن neck. “growth plate of the proximal femur”
3. Perthes **only in the femoral epiphysis**

The doctor focused mainly on **DDH** and he said: “ just know the important things in SCFE and Perthes.”



Triradiate cartilage: y-shaped epiphyseal plate at junction of ilium, ischium and pubis

# Developmental Dysplasia of the Hip (DDH) "الخلع الولادي"

## Nomenclature:

### Congenital Dislocation of the Hip (CDH) OR Developmental Dysplasia of the Hip (DDH)?

CDH is the **old name** of DDH, and they change it because of:

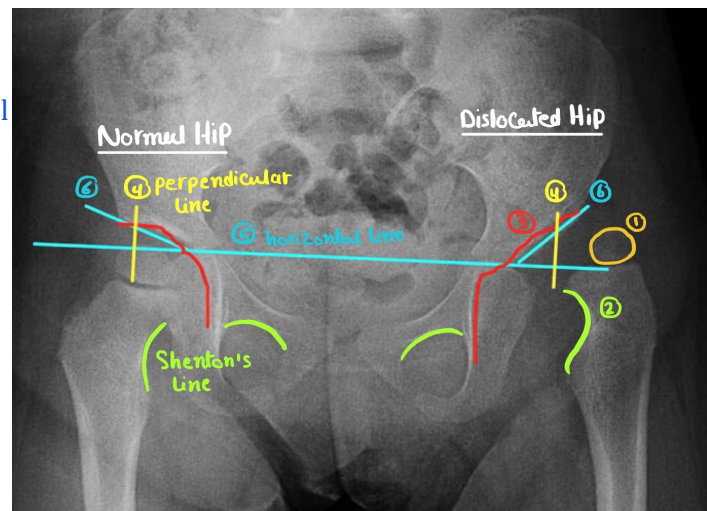
- ★ DDH is **not** only dislocation it could be subluxation and other...
- ★ DDH is **not** always congenital it could occur later on in life.

Patterns of disease "The main problem is between the head of the femur and acetabulum."

Complete Dislocated	<b>Difference between Dislocated and Subluxated:</b> <ul style="list-style-type: none"> <li>★ Dislocated: complete separation. completely out of acetabulum.</li> <li>★ Subluxated: إزاحة المفصل لكن فيه كوميونيكاشين بين الكارتيليجز / the head subluxates out of joint when provoked</li> </ul>
Subluxated	
Dislocatable	means <b>unstable</b> المفروض لما أحاول أطلع femoral head يتحرك بس ما يطلع بس في حالة dislocatable يصير يطلع بالكامل ولما ادخله يدخل بالكامل. ال head موجود داخل ال acetabulum بس laxed. وإذا ما تعالج ومشى الطفل راح يصير فيه خلل ويكون عنده unstable hip ونحتاج نعمل له stability. dislocatable head in socket.
Acetabular dysplasia	everything is normal except for acetabulum " <b>shallow</b> " more shallow and more vertical than normal

## DDH on X-ray<sup>1</sup>: **Very Important!**

1. Head of the femur (ossification nucleus \ center): is **small**, **above** the horizontal line and **lateral** to the perpendicular line. **Normally** the femoral head should be below horizontal line and medial to the perpendicular line.
2. Disrupted **Shenton's line**. Normally upper head of obturator foramen مع ماشي neck of femur. In DDH the obturator foramen is separated from the neck of femur.
3. Acetabulum is opened and we call it "**Shallow Acetabulum**". The problem happened in the relationship b/w the head of femur and the acetabulum **that's why it's DDH**.
4. 2 Perpendicular "Perkin's" lines at the edge of acetabulum
5. **Horizontal line**: is between two triradiate cartilages.  
Hilgenreiner's Line
6. From base to the tip of the acetabulum: the **normal** angle is between **18-22 degree**, in **DDH** it's **30, 40 degree and more**.



In this image, we have both **Dislocation** and **Acetabular Dysplasia**, but in case of **pure Acetabular Dysplasia**: the femoral head will be inside and everything else is normal **except** for acetabular shape.

<sup>1</sup> Very helpful pic from Toronto notes

**SAQs: a scenario of a patient, 9 or 10 months and she has DDH. What are the signs you will see on X-ray?**

1. Small femoral head (ossification nucleus/center).
2. Disrupted Shenton's line.
3. Femoral head above the horizontal line (normally it's below)
4. Femoral head lateral to the perpendicular line (Pline). (normally it's medial to it)
5. Shallow Acetabulum or high acetabular index.

## Causes:

**Unknown but it's multifactorial, such as:** we cannot prevent it, but we can do early screening, diagnosis and intervention.

- ★ **Hormonal:** Relaxin, oxytocin. These hormones are given to the mother during delivery but it's not true that these hormones cause DDH because DDH happened during development in utero.
- ★ **Familial:** Ligamentous laxity diseases
- ★ **Genetics:** Female 4 X male, twins 40%
- ★ **Mechanical:** pressure pushes the hip outside **Very Important in MCQs!**
  - **Prenatal:** Breech, oligohydramnios, primigravida (1st Child), twins, abnormality like torticollis<sup>2</sup>+ metatarsus adductus<sup>3</sup> هذه علامات خارجية ممكن تدل على الخلع
  - **Postnatal:** any thing that cause adduction such as Swaddling<sup>4</sup>, Strapping.

**Adduction makes DDH worse! such as swaddling, especially in dislocatable**

## The infant at risk: Very Important in OSCE!

- ★ Positive family history: **10X**
- ★ A baby girl: **4-6 X**
- ★ Breech presentation: **5-10 X**
- ★ Torticollis: CDH in **10-20%** of cases
- ★ **Foot deformities:** Calcaneo-valgus<sup>5</sup> and metatarsus adductus.
- ★ **Knee deformities:** hyperextension and dislocation.
- ★ **Lt hip more than Rt hip**



**5 Fs that Predispose to Developmental Dysplasia of the Hip**  
Family history  
Female  
Frank breech  
First born  
LeFt hip

**MCQs: Which of the following is high-risk DDH patient?**

- A. Jaundice.
- B. Twins/Primigravida.
- C. Heart Diseases.
- D. Lung Diseases.
- E. Kidney Diseases.

**OSCE: History Taking of DDH patient. (the most important thing is to ask about the risk factors that are mentioned above)!**

- أول مولود؟ ولد ولا بنت؟
- هل فيه احد بالعائلة مصاب بخلع الورك؟
- الولادة كانت طبيعية ولا قيصرية؟ ليه < Breech/twins/ ICU
- لما انولد كان فيه انحراف في الرقبة، القدم، الركبة؟
- ايش الأشياء اللي سويتها قبل ما تجوني؟
- بعدين نكمل باقي الهيستوري وركز الدكتور على Vaccination.
- الدكتور قال أنهم ١٢ سؤال [Click here](#)

<sup>2</sup> Shortened Neck Muscle ([Pic](#))

<sup>3</sup> Is a common foot deformity noted at birth that causes the front half of the foot, or forefoot, to turn inward ([pic](#))

<sup>4</sup> [Pic](#) المهاد

<sup>5</sup> [Pic](#)

## When risk factors are present:

The infant should be reviewed **Clinically** and **Radiologically**.

Case: **primigravida** mother gave birth of 2 (**twins**) baby **girls**. (this case is **not** like a case of a boy with (-)ve family Hx). We do a clinical examination if it's **abnormal** then we do X-ray or if the clinical examination is **normal** but the Pt is a **high risk** we do X-ray. **So we do X-ray if the clinical examination is abnormal or high-risk Pt.**

إذا طلعت نورمال اخليهم بجوني بعد شهرين علشان أكشف عليها مره ثانية، لأنها هاي ريسك بيشينت.

### Does this increase risk of DDH?



No, It will decrease the risk because it's an abduction NOT adduction.

**REMEMBER: Adduction makes DDH worse! such as swaddling.**

This is used as a treatment!

## Clinical Examination: Look, Feel, Move, and Special tests. Diagnosis is clinical

The infant should be quiet and comfortable (if she/he is not, then the clinical examination will be inaccurate).

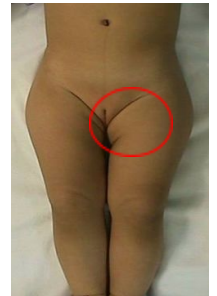
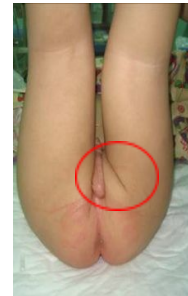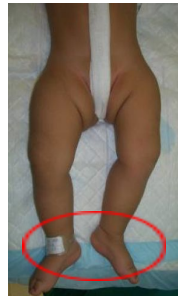فالحل اننا نعطيهم الملهيات و المسليات زي حلاوه المصاص (:

There is No complaint! only if he/she walks! الورك المخلوعة يكون فيها dimpling, that's why we depend on clinical examination. if we diagnose it after the complain it will be considered as late diagnosis

### Clinical Examination

#### Look

- ★ External rotation.
- ★ Lateralized contour **asymmetry**.
- ★ Shortening.
- ★ Asymmetrical skin folds **caused by shortening of affected limb** --> تكون أكثر وأعمق (Anterior – posterior).

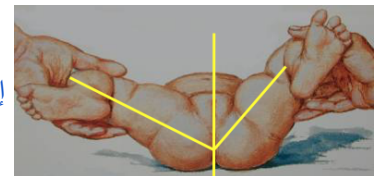


#### Move

- ★ Limited abduction (< 60 degrees)

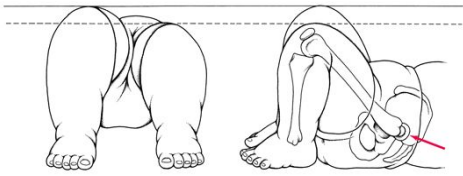



The affected side is the Lt one.

إذا انخلع ال Hip تقصر الرجل (لأن العضلة أقوى فترفع الرجل)، وإذا انخلع الكتف تطول اليد (لأن عظمه الكتف أثقل).





## Special test

<p style="text-align: center;"><b>Galeazzi Test</b> "Difficult if the child &lt;1 year"</p>	<p>It is performed by flexing an infant's knees when they are lying down so that the feet touch the surface and the ankles touch the buttocks. If the knees are not at the same level then the test is positive.</p> <p>It will distinguish whether the shortening of limb from <u>femur or tibia</u>. If the tibia is shorter → not DDH.</p> <div style="text-align: right;">  </div>
<p style="text-align: center;">Ortolani, Barlow test<sup>6</sup> <b>"IMP."</b></p>	<p><b>Pt should be less than 6 months old and specialized for diagnosis of DDH.</b></p> <p><b>Ortolani test</b> (for dislocated hip): Doctor elevate his/her hand then do abduction to pt hip → jerky movement (clunk or click), it's <b>not</b> a sound you feel the movement. so if there is Limited abduction we do t.</p> <p><b>Barlow test</b> (for dislocatable hip): to check the <b>stability</b> of the hip joint. (+)ve: hip unstable/dislocatable → need treatment. (-)ve: hip stable. How? by doing adduction to the hip. fully adducted hips, push posteriorly to try to dislocate hips</p> <p> <a href="#">Video</a></p>
<p style="text-align: center;">Trendelenburg sign and gait</p>	<p>We do this test if the pt is <b>walking</b>. Age older than 2 years.</p> <p> <a href="#">Video</a></p>
<p style="text-align: center;">Limping (waddling gait if bilateral)</p>	<p>We do this test if the pt is walking and it's <b>painless</b>. caused by <b>short limb</b> Age older than 2 years.</p> <p> <a href="#">Video</a></p>

If the patient is an 8 months and he/she can walk don't choose Ortolani, Barlow test instead choose limping or trendelenburg sign. If cannot walk choose limited abduction or Galeazzi test

### Investigations: Very Important in **MCQs!**

- ★ 0-3 months (to 89 days): Ultrasound.
- ★ > 3 months (from 90 days): pelvic X-ray (AP + abduction), **After 6 months X-ray is reliable.**

below 6 months , the head of femur is not seen , but there are other signs we can look for by opening the leg completely and taking a perpendicular line along the shaft of femur, if the end of line was within acetabulum >> intact

انتبهوا هنا للعمر ترى يحوسون فيها في الام سي كيز!

<sup>6</sup> [Ortolani, Barlow test](#) & [Pic from Toronto](#)

## Treatment:

The treatment depends on the **age**, the **earlier** started, the **easier** and better the results (**so should be detected EARLY**) and it could be **surgical** or **nonsurgical**.

### Aim:

- ★ Obtain concentric reduction (**REDUCE**).
- ★ Maintain concentric reduction (**STABILIZE**). *by cast.*
- ★ In a non-traumatic fashion (**SAFELY** to blood supply)
- ★ **Without** disrupting the blood supply to the femoral head.

**Way:** Refer to the pediatric orthopedic clinic.

Age	Treatment <b>Very Important in MCQs!</b>
Birth – 6 m	<b>Reduce + maintain</b> with Pavlik harness <sup>7</sup> or hip spica <sup>8</sup> (H.S). <i>in the clinic and pt is awake. first 6 weeks with Pavlik harness then abduction splint for 3 months then we follow up the patient</i>
6-12 m	<b>GA</b> <sup>9</sup> <i>Why we give GA even though we will do closed reduction? because we have to do arthrogram in the OR under GA to check for the presence of fibers + Closed reduction + maintain with hip spica if it fails we do an open reduction.</i>
12 - 18 m	<b>GA + Open</b> reduction + <b>maintain</b> with hip spica
18 – 24 m	<b>GA + Open</b> reduction + <b>Acetabuloplasty</b> + <b>maintain</b> with hip spica <i>18 months is here</i>
2-8 years	<b>GA + Open</b> reduction + <b>Acetabuloplasty</b> + <b>femoral shortening</b> + H.S
Above 8 years	<b>GA + Open</b> reduction + <b>Acetabuloplasty</b> (advanced) + <b>femoral shortening</b> + H.S

- الدكتور قال ما راح نجيب ال cut point.
- **متى نسوي Opened ومتى Closed?** إذا فيه ألياف أسوي الاوبن وإذا ما فيه ألياف أسوي الكلوز، طيب كيف أعرف إذا فيه ألياف أو لا عن طريق arthrogram and under anesthesia.

## Late complications if not treated: **Very Important in MCQs!**




- ★ **If not treated:** OA (early osteoarthritis) → Stiffness → Erosion of cartilage → Severe Pain → Limping → Spine problems (Early Lumbar spine degeneration) → Difficult life. *here the treatment is a total hip replacement in the future. So So So IMP.*
- ★ **Other complications:** Leg Length Discrepancy (LLD), Pelvic inequality.

الدكتور قال انهم يركزون مررره على كومبليكاشين!

<sup>7</sup> Pic

<sup>8</sup> Pic

<sup>9</sup> General Anesthesia

Lt DDH		Bilateral DDH
Before treatment	After treatment	
		

**If the image on the Lt is a case of 19 months girl, What is the treatment for her?**

See the table above: (GA + Open reduction + Acetabuloplasty + maintain with hip spica).



# Slipped Capital Femoral Epiphysis (SCFE) & Perthes

CFE and Perthes are the same except for the age group and the diagnosis!

SCFE	Perthes “Legg-Calvé-Perthes Disease”
<p><b>Where:</b> at the level of the growth plate (Between head and neck of femur).</p> <p><b>Why:</b> It could be Hormonal, <b>Metabolic</b>, Mechanical, obesity, Trauma, Unknown.</p> <p>The big number of patients have a metabolic cause, so we have to do a test for growth, thyroid, and parathyroid hormones.</p> <p><b>High-risk patients are:</b> Males, black, obese and <b>8-12 years old</b>. Also, increase if other side affected.</p> <p><b>History:</b> Hip pain/referred knee pain (only), Minor trauma or no trauma, Limping (<b>painful</b>).</p> <p>If the pt come complaining of knee pain and I did X-ray and it was normal, <u>What is the next step?</u> pelvic X-ray.</p> <p><b>Clinical Examination:</b> they will come in a scenario</p> <ul style="list-style-type: none"> <li>★ Hip in ER → decreased external rotation.</li> <li>★ Decrease internal rotation (IR).</li> <li>★ Decrease Abduction.</li> <li>★ Usually painful ROM.</li> <li>★ Limping (painful).</li> </ul> <p>If the pt coming complaining of painful ROM &amp; painful Limping with SCFE risk factors, here we suspected that the pt has SCFE.</p> <p><b>Investigations:</b></p> <ul style="list-style-type: none"> <li>★ <b>X-ray:</b> <ul style="list-style-type: none"> <li>○ Pelvis:           <ul style="list-style-type: none"> <li>■ <u>Early:</u> could be normal or increase growth plate space [pre slip phase].</li> <li>■ <u>Late:</u> slippage <b>positive</b>.</li> </ul> </li> <li>○ Knee.</li> </ul> </li> <li>★ <b>MRI:</b> can help if X-ray is <b>not clear</b> or <b>doubtful</b>.</li> </ul> <p>If the Hx and PE suggest SCFE and X-ray is normal we do MRI.</p> <p>Early Vs Late SCFE:</p> <p>كل ما تزحلق الهيد كل ما قطعت عروق أكثر فيزيد avascular necrosis و قلت نسبة الشفاء، أما إذا كانت العروق المتقطعة أقل، فنسبة الشفاء تكون أعلى.</p>	<p><b>Where:</b> at the level of head of the femur.</p> <p><b>Why:</b> vascularity of head of the femur (avascular necrosis).</p> <p><b>Cause:</b> Unknown</p> <p>So we can prevent it? Nobody knows</p> <p>الأوعية تقفلت وتسببت في موت الخلايا، ويبدأ الجسم يتصرف مع هذه الخلايا الميتة resorption then replacement الميته ل remolding أنه يكون بشكل طبيعي</p> <p><b>High-risk patients are:</b> <b>4-8 years</b>, males &amp; obese.</p> <p><b>The severity of the disease depends on:</b> the amount of femoral head involvement.</p> <p><b>History:</b> Hip pain/knee pain (only), Minor trauma or no trauma, Limping (<b>painful</b>).</p> <p><b>Clinical Examination:</b></p> <ul style="list-style-type: none"> <li>★ Decrease Abduction.</li> <li>★ Decrease internal rotation (IR).</li> <li>★ Usually painful ROM. (↓↓↓)</li> <li>★ Limping (painful).</li> </ul> <p>If the patient comes with painful limping and a history of minor trauma. What is your DDX?</p> <p>If you tell me fracture, SCFE and Perthes (كثير الله خيركم المريض يجي يشكي من ألم ولا يقدر يدعس على رجليه.)</p> <p><b>Investigations:</b></p> <ul style="list-style-type: none"> <li>★ <b>X-ray:</b> <ul style="list-style-type: none"> <li>○ Pelvis: ↓ head size (irregular shape).           <ul style="list-style-type: none"> <li>■ <u>Early:</u> X-ray might not show anything.</li> </ul> </li> <li>○ Knee.</li> </ul> </li> <li>★ <b>MRI:</b> can help if X-ray is <b>not clear</b> or <b>doubtful</b>.</li> </ul> <p>If the Hx and PE suggest Perthes and X-ray is normal we do MRI.</p> <p><b>Treatment:</b></p> <ul style="list-style-type: none"> <li>★ Very controversy</li> <li>★ Refer to pediatric orthopedics as an <b>urgent</b> case</li> <li>★ Guidelines of treatment:           <ul style="list-style-type: none"> <li>○ Control pain.</li> <li>○ Maintain ROM.</li> <li>○ <b>Hip containment inside the acetabulum. If outside we do surgery</b></li> </ul> </li> </ul>

**Treatment:** Refer to orthopedic as an **emergency** (not to the clinic!) case. **What they will do?**

- ★ In situ pinning – to prevent further damage to the vascularity.
- ★ Protected weight bearing for 3-4 weeks then full weight bearing.
- ★ No sport for 6 months.

**Late complications: Very Important in MCQs!**

- ★ Femoral Acetabular Impingement (FAI)<sup>10</sup>.
- ★ Early arthritis.
- ★ Leg Length Discrepancy (LLD).
- ★ Pelvic inequality.
- ★ Early Lumbar spine degeneration.

We follow up the patient and make sure that the head of the femur is inside the acetabular.

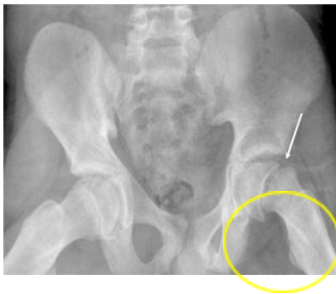هنا العلاج ما يحتاج تدخل جراحي، الفيسيز المسكره تفتح من الله بدون عملية أو أي شيء ثاني.

**Late complications: Very Important in MCQs!**

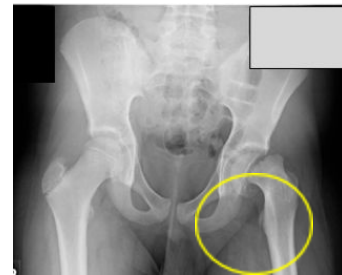
- ★ Early arthritis.
- ★ Leg Length Discrepancy (LLD).
- ★ Pelvic inequality.
- ★ Early Lumbar spine degeneration.

### Which Image is the worse, Rt or Lt?

Lt

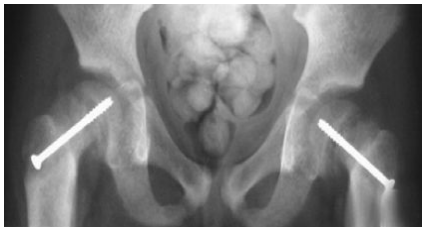

Rt



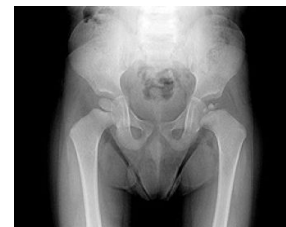On the Lt side, there is widening of growth plate (pre-slipped stage) → needs MRI  
The Rt one is the worse (there is slippage) which increases the risk of Arthritis

### Treatment of SCFE



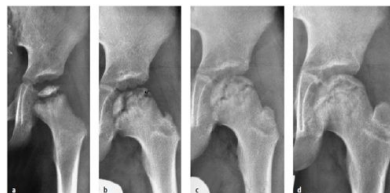On the right side only wide growth plate (we put screw for prevention)  
on the left side both widening and slipping

### Perthes Disease on the Lt



Perthes on the left side (small head of femur with fragmentations)

### Healing phases of Perthes Disease



<sup>10</sup> A condition in which extra bone grows along one or both of the bones that form the hip joint — giving the bones an irregular shape.

# MCQs

1. 8-month-old patient with DDH. What is the best test to use?

- a. Barlow
- b. Ortolani
- c. Trendelenburg
- d. limited abduction

Answer: D

2. Which of the following is a risk factor for DDH?

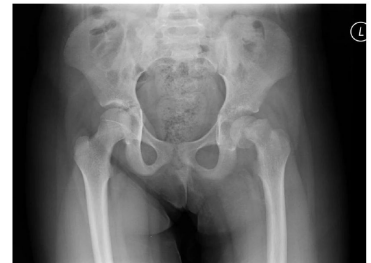- a. Oligohydramnios
- b. Negative family history
- c. 3rd child
- d. Baby male

Answer: A

3. An 8 year old child came to the ER with painful limbing x-ray was done in the picture below, what is the dx?

- a. Perthes disease.
- b. DDH.
- c. SCFE.
- d. Septic arthritis.

Answer: C



4. A 4 months old baby has a DDH, which one of the following is the management?

- a. Pavlik harness.
- b. open reduction and internal fixation (ORIF).
- c. Hip spica.
- d. Skeletal traction.

Answer: A & C

5. A 15 months old infant was managed with closed reduction and hip spica. (Pic of DDH x-ray) Which one of the following is a likely complication of this case?

- a. Growth arrest.
- b. Osteoarthritis.
- c. Avascular necrosis.
- d. Infection.

Answer: B

