



[Color index : **Important** | **Notes** | Extra] Editing file [link](#)

Principles of Fracture

Objectives:

- ★ Basic science of fracture healing
- ★ Principles of evaluating patients with fractures
- ★ Principles of management

Done by: Aljohara Almazroua

Edited By: Bedoor Julaidan

Revised by: Dalal Alhuzaimi

References: 435 Lectures and Notes, Toronto Notes, 433 Team

Basics review -you can skip this part if you want-

Bone structure, types & composition:

1. Lamellar Bones: (Dense):

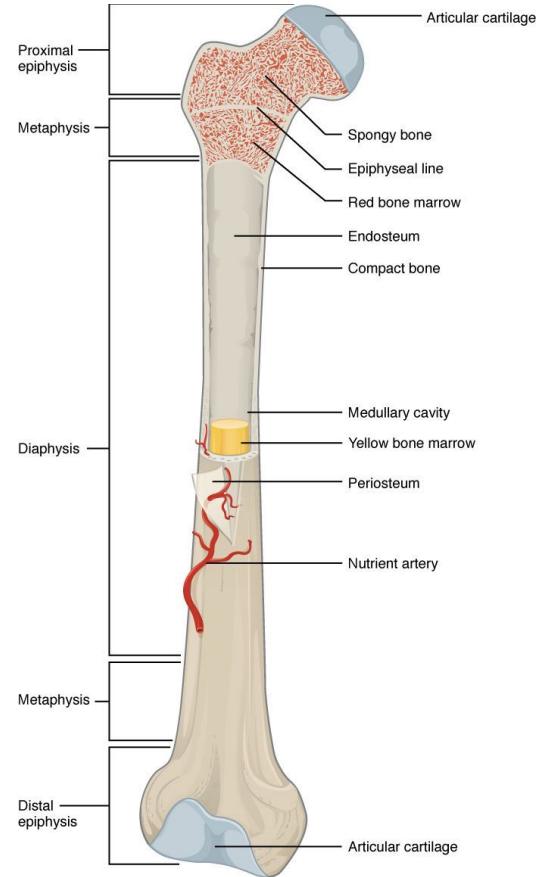
They're composed of collagen fibers arranged in parallel layers and they're found in the **diaphysis** part of normal adult long bones. The basic functional unit of lamellar bones is called an Osteon or "Haversian System".

2. Cancellous Bones (trabecular or spongy bone):

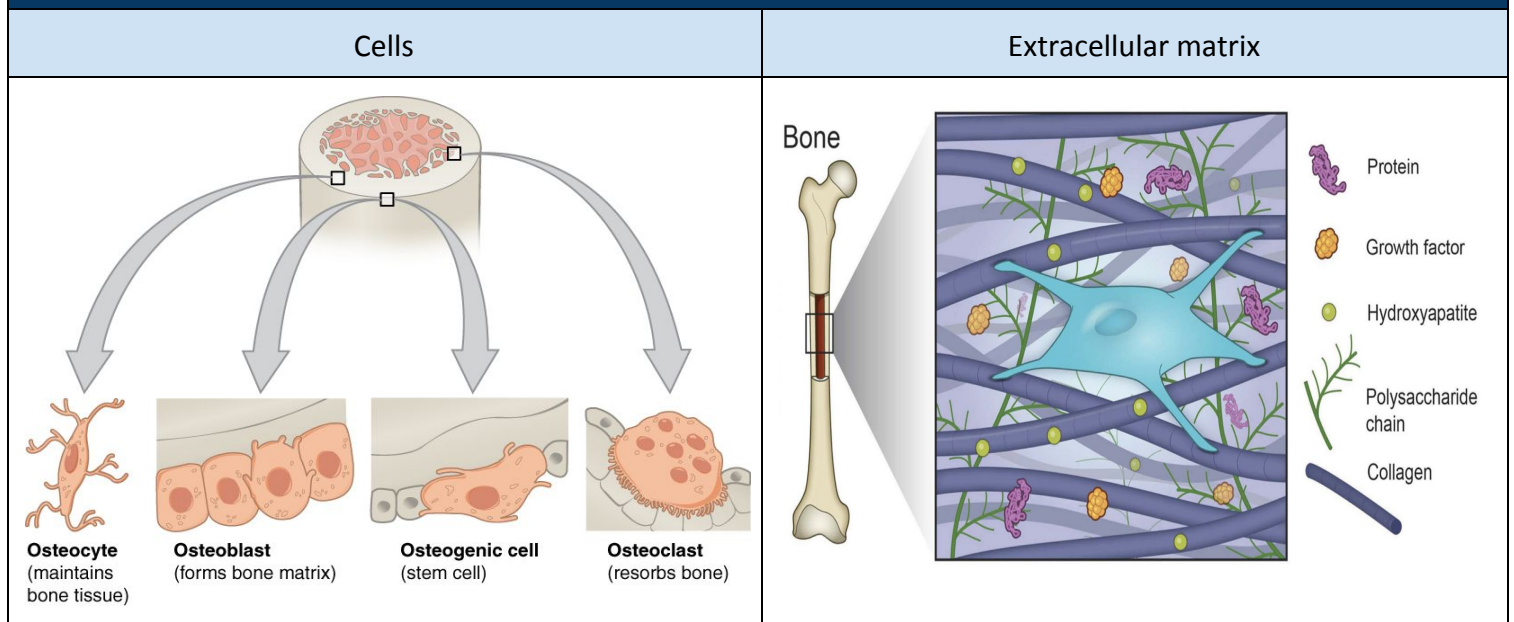
They're less dense and more elastic than lamellar bones. They're found in the **metaphysis** part of small bones.

3. Woven Bones

They're coarse bones with random orientation. They're also weaker than lamellar bones. **In bone healing, they're eventually remodeled to lamellar bones.**



Bone Composition



Introduction




Fracture Definition & Description:

Definition: Fracture means literally broken bone.

Description: This can be described in different ways:

- A. **Extent** complete or incomplete
- B. **Location**
- C. **Morphology** shape of the fracture
- D. **Mechanism** high energy (suspicion of other injuries) vs low energy
- E. **Associated soft tissue injuries** open or closed fracture

A. Extent

Complete	Incomplete	
Fracture that extends 360° of bone circumference (all around).	Seen almost only in children such as: because they have elastic bone	
	Greenstick fracture if you try to break greenstick it will not break bc it's elastic = children have elastic bones. still can happen in adults if there is certain mechanism of injury	Buckle (torus) fracture طعجه، التواء Not a complete break just a deformity. it's also common in children
		

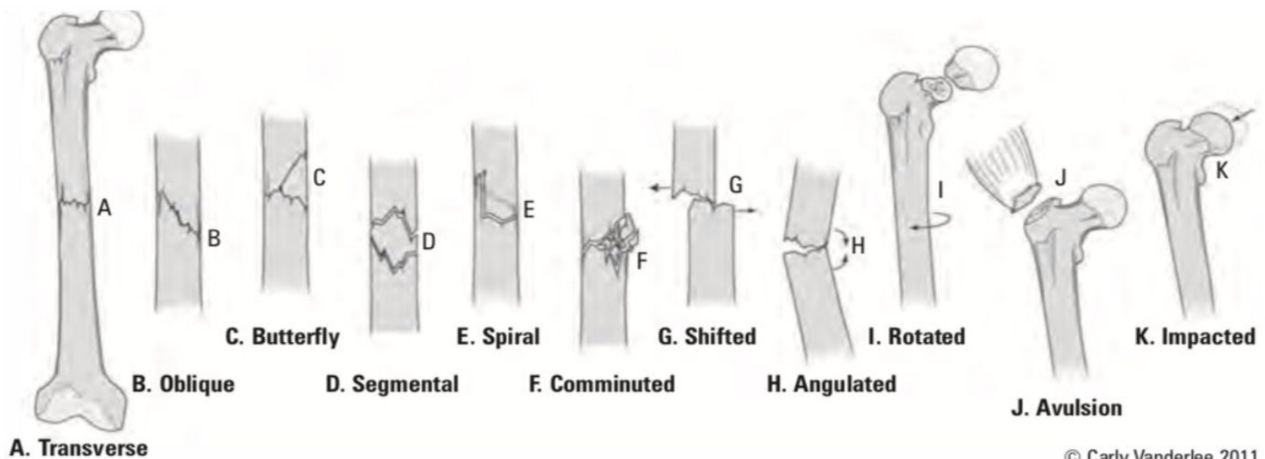
B. Location

- Name of bone
- Side (Right or Left)
- Diaphysis (shaft), metaphysis (=flare or Cancellous Bones) or epiphysis
- Long bones (diaphysis): divide them in thirds (proximal, middle or distal third)
- Metaphysis: intra-articular v.s extra-articular depending how far the fracture goes. Sometimes it includes epiphysis and metaphysis and this has special classification you will take in pediatrics

C. Morphology

- ★ **Transverse:** loading mode resulting in fracture is **tension**. Avulsion results in transverse fracture (the bone fails under tension)
- ★ **Oblique:** loading mode is **compression** from both ends
- ★ **Spiral:** loading mode is **torsion or rotation**. (Usually occurs in sports & pediatric age group)
- ★ **Wedge (fracture with butterfly fragment):** loading mode is **bending**. (1 piece)
- ★ **Comminuted:** 3 or more fragments, usually results from **high energy trauma**.
- ★ **Segmental:** a fracture in two parts of the same bone.

Segment is a big piece of bone that is broken from above and below and disconnected from the rest. Segment can be comminuted if there is comminution around the fracture site or can be a simple segmental fracture. Wedge is broken but there is contact on one side. These 2 fractures represent high energy trauma. Segmental, wedge or any other fracture can be comminuted also



D. Mechanism

- ★ **High energy vs. Low energy** (In high energy accidents, soft tissue injuries are expected e.g. RTA)
- ★ **Multiple injuries** Usually high energy can cause multiple injuries or polytrauma and then low energy can cause isolated injury but still even if you're exposed to high energy you can end up with isolated injury vs. isolated injury
- Pathological fracture:** Normal load in presence of weakened abnormal bone density (tumor osteolytic lesion (osteoclast activity) if dense lesion → osteoblastic lesion less likely to break but still pathological so it might break, osteoporosis, infection).
- ★ **Stress fracture:** Normal bone subjected to **repeated** load (military recruits/athletes) usually it will be incomplete small fractures. They run on a daily basis for long distances. Seen in runners and professional dancers.

E. Associated soft tissue injuries - most important is skin integrity-

- ★ **Closed fracture:** skin integrity is maintained.
- ★ **Open fracture:** fracture is exposed to external environment. The clinical significance of opened fracture is infection bc the bone is exposed to the non-sterile external environment. And this makes it an emergency.
- ★ signs: **continuous bleeding** "the blood source is the bone marrow which is highly vascular" from puncture site or **fat droplets** in blood are suggestive of an open fracture
(Any skin breach in proximity of a fracture is an open fracture until proven otherwise)

Fracture Healing

Types:

★ Indirect bone healing

In **indirect bone healing**, the process occurs in nature with untreated fracture through endochondral ossification (occurs in fractures with gap). It is called indirect because of formation of cartilage at an intermediate stage. It runs in **4 phases**:

1. Hematoma formation (Inflammation phase) (1-2 weeks)

In this phase, there is disruption of the blood vessels, migration of cells occurs, and coagulation begins.

2. Soft Callus (2-3 weeks)

In this phase, cascade of cellular differentiation occurs, angiogenesis takes place, and **fibroblasts** produce granulation tissue that eventually evolves into **fibrocartilage**.

the most important cells: fibroblasts, cartilage cells and with time they will calcify resulting in hard callus. You see a patient with fracture; on x-ray you don't see anything, but clinically there is a firm lump on the fracture site, which stage of healing? → soft callus. If you start seeing calcification or ossification so this is hard callus

3. Hard Callus (3-12 weeks)☑

In this phase, endochondral **ossification** converts soft callus into **woven bone**. The process starts at the periphery and then moves centrally. It continues until there is no more movement.

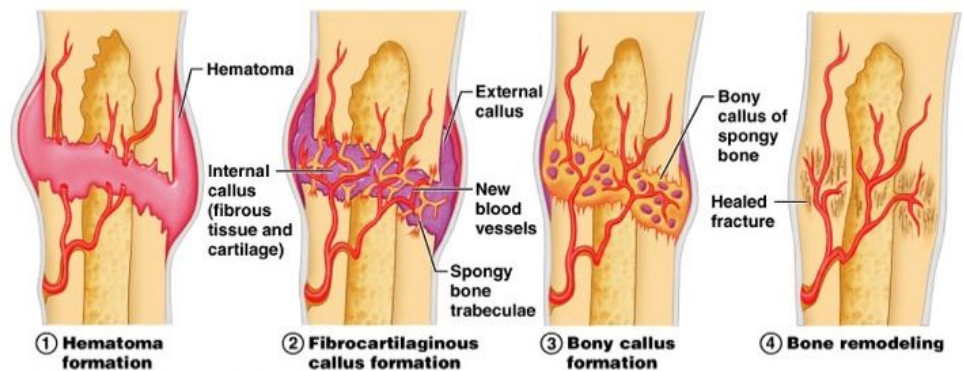
4. Remodeling (Years) (reshaping the bone)

In this phase, the **woven bone** that was formed is converted into **lamellar bone**.

it's the process of reshaping of bone. if the bone is broken and healed in wrong position with time it will remodel and will correct, remodeling depends on how much left of the patient growth so it is more in pediatric patient (takes a year to year and a half. If you have significant deformity and the pt. is 4 y/o After 2-3 years the deformity will disappear). In other words, Is there a difference between remodeling in pediatrics and adults? Yes, if you're an adult you're not growing anymore. If you are 18 years old or older there wouldn't be any remodeling potentials. You might have local remodeling: the cortex will thin out and the canal might recanalize but the deformity itself will not be corrected. So if you see a pediatric patient with a fracture that is angulated or malaligned there is certain angulation that you accept bc you know that the body will take care of by remodeling.

★ Direct bone healing:

It can happen if no motion takes place. Bone is formed without intermediate stage through the "Cutting cone mechanism". This mechanism works only if the fracture is < 1mm gap. (No gap must be in fracture site).



Principles of Evaluation

★History:

Patients complain of **pain and inability to use the limb** (if they are conscious and able to communicate)

What information can help you make the diagnosis? pain >> SOCRATES

- ★ Onset:
 - When and how did the symptoms begin?
 - Specific traumatic incident vs. gradual onset?
- ★ If there was a specific trauma, the details of the event are essential information:
 - Mechanism of injury?
 - Circumstances of the event? Work-related? **Was it in the farm? Street?**
 - Severity of symptoms at the time of injury and progression after?
- ★ If you suspect a pathological fracture, you must:
 - Ask about prior pain before event happened?
 - Ask about constitutional symptoms?
 - Ask about history of cancer?
- ★ If you suspect stress fracture, ask about:
 - recent increment of activities?

★Physical exam:

★ look :

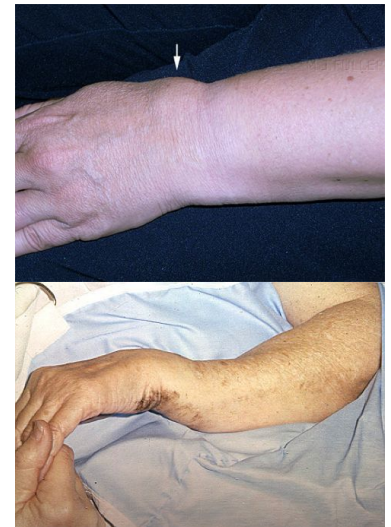- Swelling
- Ecchymosis
- Deformity **Muscle wasting/ wounds/ Skin changes**
- If fracture is open:
 - Bleeding
 - Protruding bone

★ Feel :

- **Bony landmarks, temperature and pulses**
- Bony tenderness
- Examine joint above and below.

★ Move :

- ROM (Can not be assessed in acute fracture).
Move is not important in fractures → painful. However, if there is subtle fracture like stress fracture we need to ask the patient to move but in general if there is obvious fracture it's not done. There is no special tests for trauma



If a fracture is suspected what should we rule out?

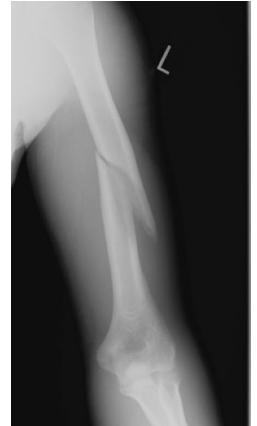- Neurovascular injury (N/V exam)
- Compartment syndrome
- Associated MSK injuries (examine joint above and below at minimum)
- **Open fracture/ infection is too early to happen, it happens later on**
- **Cauda equina syndrome in spine fracture**

- Pelvic fracture in cases of polytrauma (can cause life-threatening bleeding). Patient can lose 2 L of blood if he has femur fracture/ he can lose his whole blood in pelvic fractures. What are the life threatening injuries in the pelvis? Open book injury → symphysis is disrupted. In normal pelvis, it can take up to 3 liters however in an open book pelvis, it can take up to 6 or 7 liters. So you have to close it down to minimize the volume.

★Investigations:


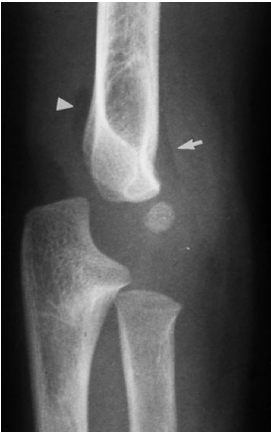



★ Imaging:

- X-rays are 2D: get minimum two orthogonal views
- Include joint above and below injury
- NB: fractures hurt, immobilization helps.
- Immobilizing a patient in a back slab is the most effective way to relieve pain from a fracture and may be done BEFORE getting x-rays
- If the patient has an obvious fracture, Do you send the patient to X-ray before you splint or after you splint? **We splint it before.** What is the most important function of splint? Immobilize and stabilize the fracture, prevent vascular injury and prevent further soft tissue damage. If you have motion at the fracture site and you don't stop it, it will cause more soft tissue injury and therefore more swelling
- Fractures may be obvious on x-ray
- Undisplaced or stress fractures are sometimes not immediately apparent



X-ray pic: Left side mid shaft humerus spiral in morphology.

Secondary signs of fracture on X-ray

Soft tissue swelling you can differentiate between subcutaneous tissue, muscles and bones (3 have different densities)	Fat pad signs (Capsule filled with blood)	Periosteal reaction chronic process	Joint effusion you can see swelling in front or behind the joint. You should always correlate clinically	Cortical buckle*
				

- ★ If there is high suspicion of fracture that you cannot see. So what you can do in this case? More views → still you don't see anything? Cast then CT or MRI or follow up (another X-ray after 10 weeks > sclerotic line in the fracture site)
- ★ Fat pad sign is seen in pediatrics. Piece of fat placed in anatomical location around the joint to protect it. If the patient is exposed to injury and there is bleeding in joint the blood will push the fat pad outside. High index of suspicion of fracture
- ★ periosteal reaction indicates tumor, infection, healed fracture and stress fracture (no clear fracture line but thickening in the cortex or periosteal reaction).
- ★ *In buckle fracture you will not see thickening in the cortex. Buckle fracture happens usually in a thin part of bone around the metaphysis. It's very hard to buckle a thick cortex

Advanced radiological images should be considered:

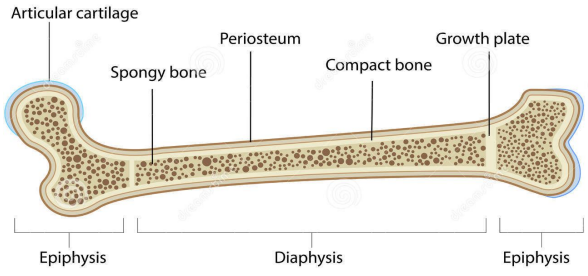
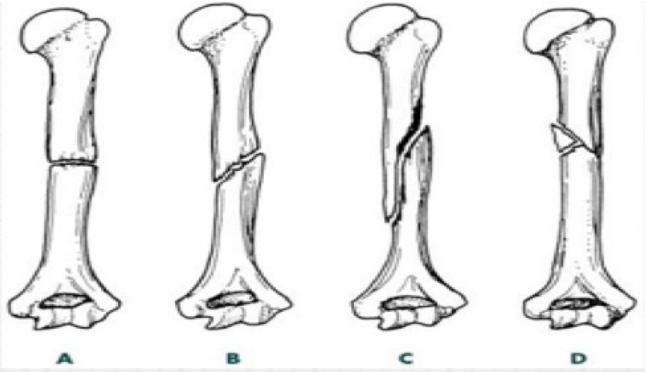
- If fracture extends to joint -> obtain CT scan
- If fracture is suspected but not seen on x-ray -> MRI



HOW TO DESCRIBE A FRACTURE **Important**

1. Clinical parameters

- ★ Open vs. closed
 - ANY break in the skin in proximity to the fracture site is OPEN until proven otherwise
- ★ Neurovascular status
- ★ Presence of clinical deformity
- ★ Compartment syndrome

2. Radiographic parameters

<p>Location</p>	<ul style="list-style-type: none"> ● Which bone? ● Which part of the bone? ● Epiphysis -intraarticular? ● Metaphysis ● Diaphysis -divide into 1/3s ● Use anatomic landmarks when possible ● e.g. medial malleolus, ulnar styloid, etc 	
<p>Pattern</p>	<ul style="list-style-type: none"> ● Simple vs. comminuted. ● Complete vs. incomplete. ● Orientation of fracture line. <p>(A: transverse, B: oblique, C: spiral)</p>	

<p>Displacement</p>	<ul style="list-style-type: none"> ● Displacement “الإزاحة” is the opposite of apposition “contact” ● Position of distal fragment relative to proximal. we describe distal because the proximal fragment is fixed to the body ● Expressed as a percentage. 100% displacement = no bone contact. You can use percentage just better to describe the distance. Sometimes you have displacement with no angulation. 
<p>Angulation</p>	<ul style="list-style-type: none"> ● Angulation is the deviation from normal alignment. ● It 's described depending on its apex (The apex of both fragments defines direction of angulation). ● It's expressed in degrees. ● If you have AP view you can see medial or radial angulation/ if you have lateral view you see either anterior “volar” or posterior angulation “dorsum”  <p>pic:Volar angulation</p>

Treatment

★ Treatment Principles:

A. Reduction:

- IF fracture is displaced.
- Meant to realign fracture fragments.
- To minimize soft tissue injury.
- Can be considered definitive if fragments' position is accepted. If reduction is acceptable, we can put a cast and that would be a definitive treatment. If not, we can put a temporary splint and later on we can treat the patient in a definitive way.
- Should be followed by immobilization.
- To maximize healing potential
- To ensure good function after healing

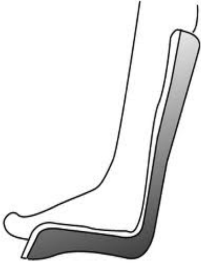


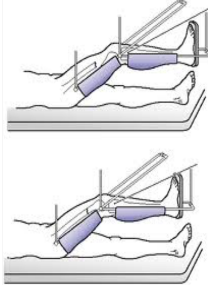


Important points to remember:

1. Take consent from patient prior to reduction (1st & most imp step).
2. Patient must receive adequate analgesia prior to reduction.
3. Most reductions occur under conscious sedation at emergency.
4. Reduction must be followed by immobilization.
5. Nerve/Vascular status must be documented before and after reduction and immobilization (before and after reduction).

B. Immobilization: Immobilization is a broad word. Can be anything from cast all the way to hardware and surgery

- ★ To hold reduction in position.
- ★ To provide support to broken limb
- ★ To prevent further damage.
- ★ **Control the Pain**
- ★ to prevent motion that may interfere with union
- ★ to prevent displacement or angulation of fracture

Examples of immobilization methods

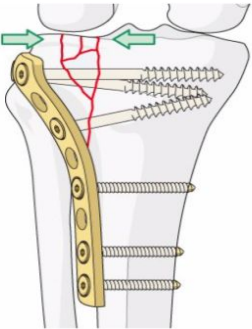
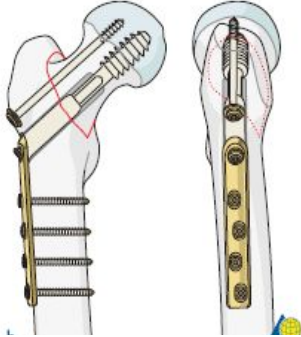


Back Slab	Brace	Skin Traction	Skeletal Traction	Sling	Complete Cast
					

Skeletal Traction: Attached to skeleton → (used for long time)

Skin Traction: Attached to skin (short time) b/c if u use it for long time it may cause skin sloughing, necrosis and ulcers.

C. Definitive treatment:

- ★ **When do you do definitive fixation?** If satisfactory reduction can not be achieved or held at initial stage → **the definitive treatment will be ORIF (surgery)**
- ★ Reduction can be attempted close or open (surgery)
- ★ Immobilization can be achieved with:
 - Plate and screws.
 - IM nail
 - EX-fix

Plate and screws	Dynamic head screw	IM -intramedullary- nail	EX-fix
			

D. Rehabilitation:

- ★ To ensure return to function.
- ★ Initiating motion (**improve range of motion**) should be attempted as early as possible without jeopardizing maintenance of reduction.
- ★ Weight bearing restriction for short period (6-8 weeks). **Especially if the fracture is not stable. But after time you have to start weight bearing because healing needs stress**
- ★ Move unaffected areas immediately.

Multiple Trauma:

- ★ Multidisciplinary approach.
- ★ Run by Trauma Team Leader (TTL) at ER. Orthopedic is part of the team.
- ★ Follow trauma Protocol as per your institution.
- ★ Treatment is prioritized toward life threatening conditions then to limb threatening conditions. **Then functions**

Complications

If fracture extends into joint or close:

- ★ OA (osteoarthritis)
- ★ Stiffness

Fracture healing:

- ★ Nonunion: Doesn't heal after double the expect time
- ★ Malunion: Healed with Malalignment

Fracture specific: AVN (Avascular necrosis) after femur neck fracture.

Medical complications: Lower limbs fractures may be associated with venous thrombus event (VTE).

Surgical related: Infection, hardware failure.

Toronto notes:

Table 2. General Fracture Complications

	Early	Late
Local	Compartment syndrome Neurological injury Vascular injury Infection Implant failure Fracture blisters	Mal-/non-union AVN Osteomyelitis Heterotopic ossification Post-traumatic OA Joint stiffness/adhesive capsulitis CRPS type I/RSD
Systemic	Sepsis DVT PE ARDS secondary to fat embolism Hemorrhagic shock	

Orientation/Fracture Pattern:

- **transverse**:fracture line perpendicular(<30°of angulation)to long axis of bone;result of direct high energy force
- **oblique**:angular fracture line(30°-60°of angulation);result of angulation and compressive force,high energy
- **butterfly**:fracture site fragment which looks like a butterfly
- **segmental**:a separate segment of bone bordered by fracture lines;result of high energy force
- **spiral**:complex,multi-planar fracture line;result of rotational force,low energy
- **comminuted/multifragmentary**:>2 fracture fragments
- **intra-articular**:fracture line crosses articular cartilage and enters joint
- **avulsion**:tendon or ligament tears/pulls off bone fragment; often in children, high energy
- **compression/impacted**: impaction of bone; typical sites are vertebrae or proximal tibia
- **torus**:a buckle fracture of one cortex,often in children
- **greenstick**:an incomplete fracture of one cortex,often in children
- **pathologic**:fracture through bone weakened by disease/tumour

MCQs

Which ONE of the following makes you have a high index of suspicion that a certain fracture is an open?

- A-Site of wound is near the fracture.
- B-Inability to move the limb.
- C-Not broken layer of dermis.
- D-Wound active oozing blood.

Answer: D

A 20-year-old male, who is fall down from 2 steps stair and fractured his ankle. The parents report that their son's personality has been changed since the past weeks, which one of the following describe the patient situation?

- A-Pathological fracture.
- B-Psychological factors.

Answer: A

SAQs

What are the 4 stages of indirect healing:

- I. Hematoma.
- II. Soft callus.
- III. Hard callus.
- IV. Remodeling

Mention 4 description of the relationship of fracture fragments:

1. **Non-displaced:** fracture fragments are in anatomic alignment
2. **Displaced:** fracture fragments are not in anatomic alignment
3. **Distracted:** fracture fragments are separated by a gap (opposite of impacted)
4. **Impacted:** fracture fragments are compressed, resulting in shortened bone
5. **Angulated:** direction of fracture apex (e.g. varus/valgus)
6. **Translated/shifted:** percentage of overlapping bone at fracture site
7. **Rotated:** fracture fragment rotated about long axis of bone

