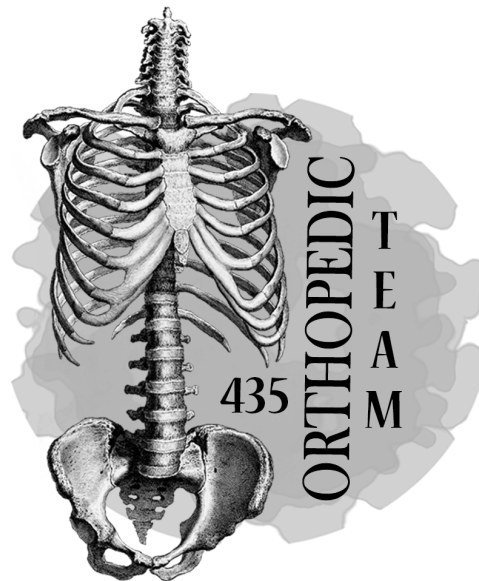

Reduction Skills

Goal:

The students to know the principles of diagnoses, reduction, and maintain the reduction for an acutely dislocated joint (e.g. shoulder) or a displaced closed long bone fracture (e.g. distal radius), and to be competent in doing it.

Objectives:

- The students will be able to apply the principles of diagnosis, reduction, and immobilization when they actually perform it on simulated patients (or on each other) with a dislocated joint or a displaced long bone closed fracture.
- That students should be able to perform the different types of shoulder joint reduction from the common type of anterior dislocation, and to know how to immobilize the shoulder joint to maintain the reduction till soft tissue healing.
- To be able to perform a closed reduction of a Colles distal radial fracture, and to know how to immobilize the reduced fracture in an above elbow cast to maintain the reduction till bone and soft tissue healing.

Done by: Saleh Alkhalifa

Edited & Revised by: Adel Al Shihri

References: Department handout,Notes, 433 OSCE Team.

Principles of Reduction

- Conform the clinical diagnose of a joint dislocation or a displaced fracture by an orthogonal X-rays, joint above and below as needed (AP + Lateral or axillary view).
- Assess distal neurovascular status before and after reduction.
- A dislocated joint is an acute emergency that needs immediate reduction.
- A displaced long bone closed fracture:
 - If intra-articular: it needs anatomical reduction, which might necessitate surgery, but displaced intra-articular fracture need realignment and splinting prior to surgery.
 - If extra-articular: can be treated by closed reduction in the emergency department.
- Reduction needs a calm and comfortable patient, that is done by one of or both:
 - “Conscious sedation”: I.V sedation with a narcotic.
 - “Hematoma block”: with local anesthesia injection.
- Reduction done by:
 - A two-person job, each on a side of the dislocation/displacement.
 - The person at the distal segment does a gentle gradually increasing sustained traction, and the people at proximal segment remains stationary, to counteract each other.
- Each type of dislocation/displacement has its own method of reduction; will be discussed in next.
- Maintain the reduction in an immobilization, then:
 - Check again the distal neurovascular status.
 - Obtain a post reduction X-ray.
 - Once satisfactory: instruction and follow up given to patient.

Reduction of anterior Shoulder Dislocation

there are two type of shoulder dislocation:

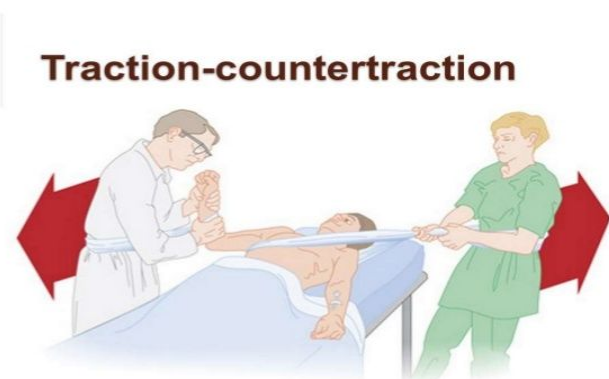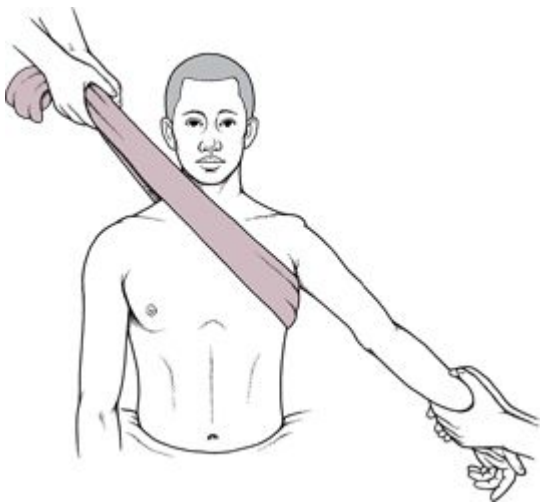
1. **TUBS** (Traumatic Unilateral lesion with Bankart lesion and usually requiring surgery)
2. **Habitual dislocation** : **AMBRI** (Atraumatic, Multidirectional, Bilateral, responds to Rehabilitation and rarely requires an Inferior capsular shift) they can reduce themselves, **don't need surgery**

- Distal neurovascular status as well as axillary nerve sensation.
- Evaluate X-ray prior to reduction (**AP, Lateral and axillary view**):
one contra-indication of shoulder reduction at ER is fracture at humeral neck.
- Analgesia and muscle relaxant.
- Expose both shoulder and perform physical exam
- ★ Look: **findings**: (asymmetry , loss of contour , anterior bulging , attitude e.g. pt holding his arm)
- ★ Feel: empty shoulder
- ★ Move : restricted movement
- ★ Special test : + apprehension test

Patient supine in bed with the affected limb towards its edge. Perform traction-counter traction maneuver.

- A pop of reduction is felt and heard.
- Check the reduction's stability, and distal neurovascular status.
- Check X-rays post reduction.
- Apply an upper limb immobilizer (as shown in the figure below) for three weeks.
- To outline the patient care after the immobilization ends.

Helpful Video : https://www.youtube.com/watch?v=qOkV_a3AwWM



Reduction of Colles Distal Radial Closed Fracture

- Analgesia and **distal neurovascular check**
- Patient supine in bed with the affected limb towards its edge.
- Identifying bony landmarks of the wrist joint and distal forearm.
- **Perform traction then reversal of deformity.** (traction then >downward> upward)
- **A pop of reduction can felt and heard, if not maneuver the fracture by the milking the distal fragment during the traction.**

Helpful Video: <https://youtu.be/cy6f7he2e4w>

- Apply a below elbow full P.O.P cast with three points of preture.
- **Check distal neurovascular**, and do a post reduction X-ray.
- **If reduction achieved and satisfactory, then extend the cast to above elbow in pediatric and below elbow for adults.**
- Post casting distal neurovascular status and post reduction orthogonal X-rays.
- To outline the patient care during the cast and after the immobilization ends.

