

# Basic ECG interpretation

**NOTE:** This ECG interpretation approach to help to diagnose some most common disorders. It is important to note that there are many other helpful approaches to interpret ECG and there are many disorders **not covered** in this approach.

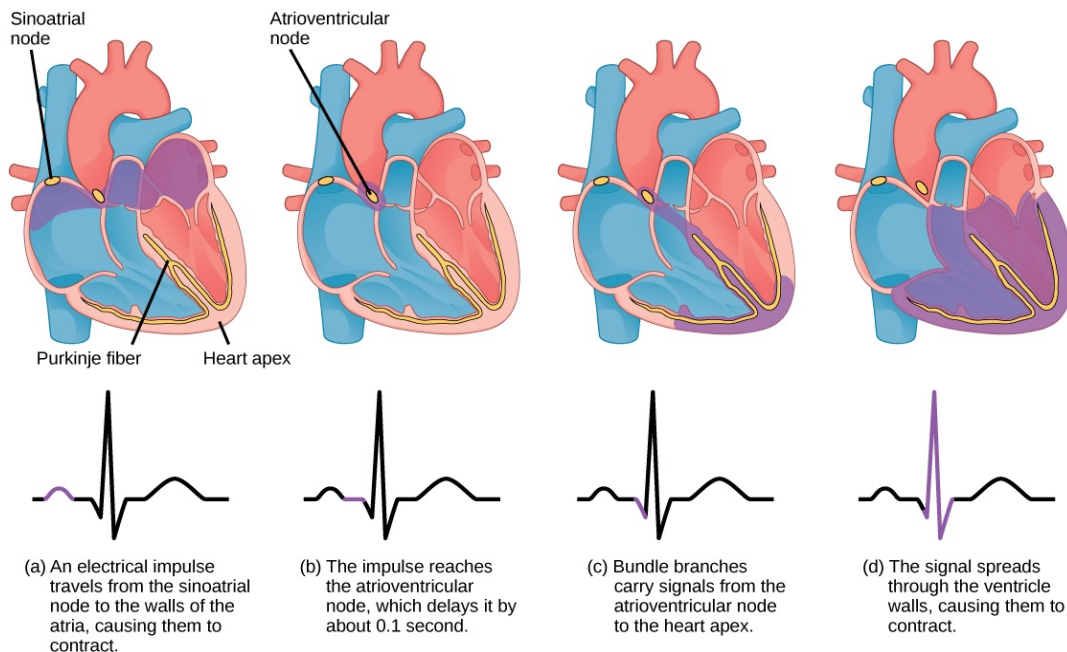
Recall the approach

1. **Take a deep breath**
2. **Analyze rate**
3. **Analyze rhythm**
4. **Look at axis**
5. **Look for injury/strain/ischemic patterns**
6. **Look for conduction deficits (RBBB, LBBB)**
7. **Hypertrophy, meds, toxic effects**
8. **Make your measurements (PR, QT/QTc, QRS)**

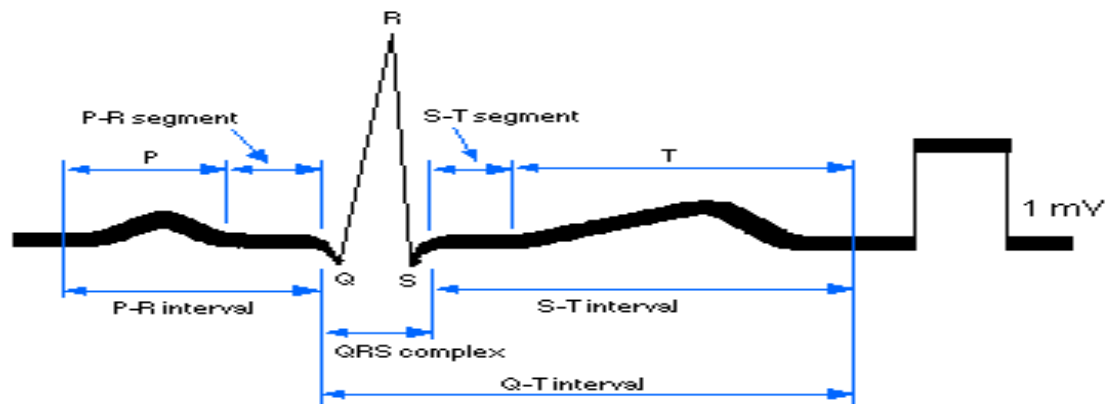
Another approach (which I prefer for Basic level)

Look at:

1. Rhythm
2. Rate
3. Axis
4. P wave, P-R interval, Q wave, QT interval, QRS complex, ST segment, T-wave.
5. LBBB, RBBB or LVH



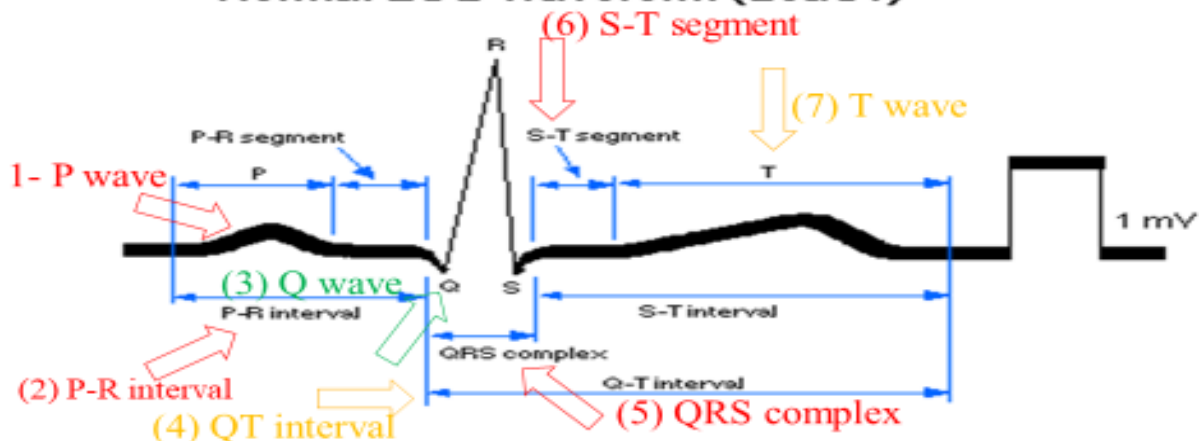
### Normal ECG Waveform (Lead I)



Normal Values for Amplitudes and Durations of ECG Parameters:

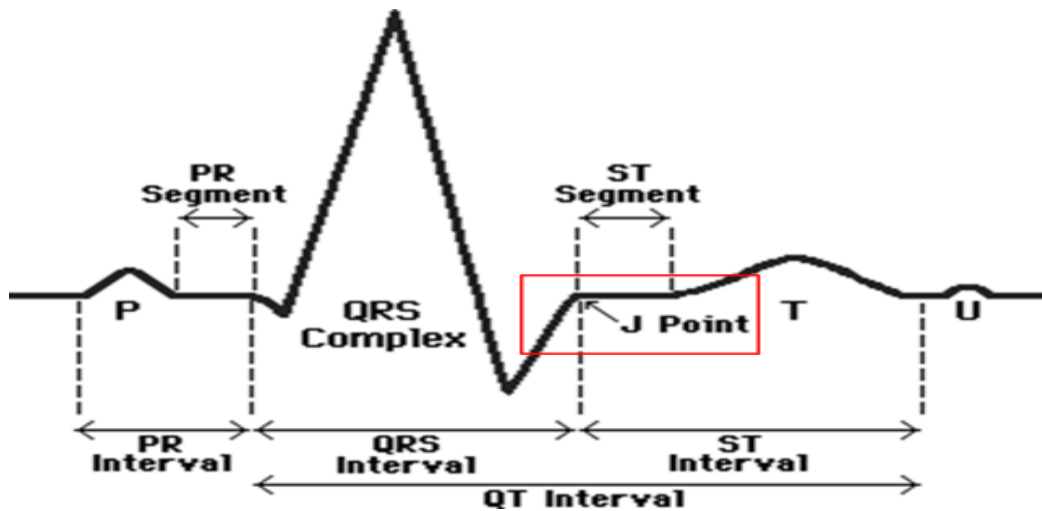
Amplitude:	P wave	0.25 mV	Atrial Depolarization
	R wave	1.60 mV	
	Q wave	25% of R wave	
	T wave	0.1 to 0.5 mV	Ventricular Repolarization
Duration:	P-R interval	0.12 to 0.20 sec	
	Q-T interval	0.35 to 0.44 sec	
	S-T segment	0.05 to 0.15 sec	
	P wave interval	0.11 sec	
	QRS interval	0.09 sec	Ventricular Depolarization

### Normal ECG Waveform (Lead I)



Normal Values for Amplitudes and Durations of ECG Parameters:

Amplitude:	P wave	0.25 mV	Atrial Depolarization
	R wave	1.60 mV	
	Q wave	25% of R wave	
	T wave	0.1 to 0.5 mV	Ventricular Repolarization
Duration:	P-R interval	0.12 to 0.20 sec	
	Q-T interval	0.35 to 0.44 sec	
	S-T segment	0.05 to 0.15 sec	
	P wave interval	0.11 sec	
	QRS interval	0.09 sec	Ventricular Depolarization



### Irregular rhythm

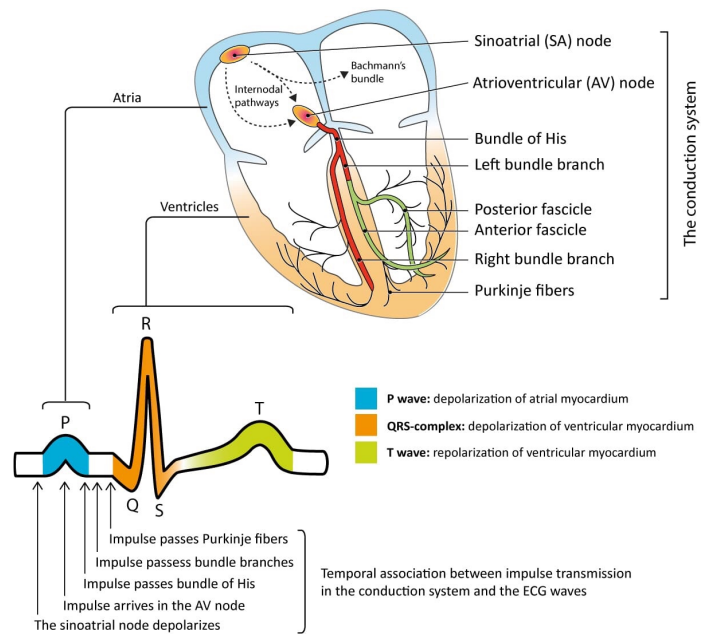
● there are many causes but the most important and common are:

1. Atrial Fibrillation
2. Atrial flutter
3. Second degree heart block Type I (Mobitz I)
4. Second degree heart block Type II (Mobitz II)
5. Sinus arrhythmia

### Rate:

● if regular rhythm:

1. calculate big square between R-R:
  - if > 5 big square (bradycardia)
  - if < 3 big square (tachycardia)
  - if between 3 and 5 big squares (normal heart rate)
2. calculate the big squares between R-R



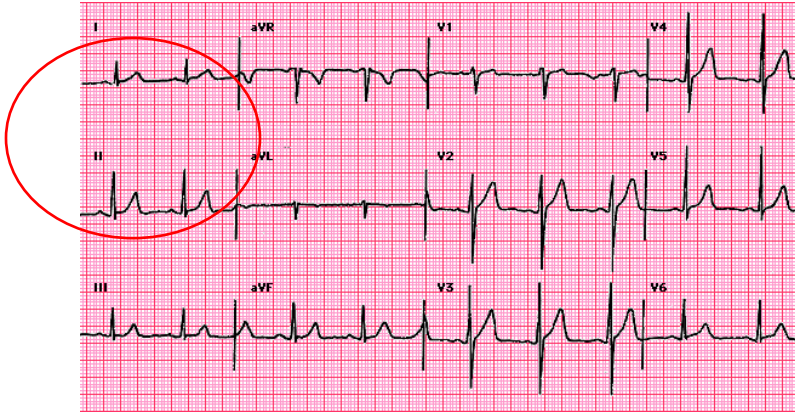
Number of squares	1 square	2 squares	3 squares	4 squares	5 squares	6 squares
Heart rate	300	150	100	75	60	40

3. in standard ECG: calculate the number of QRS complex in ECG and multiply by 6 = HR

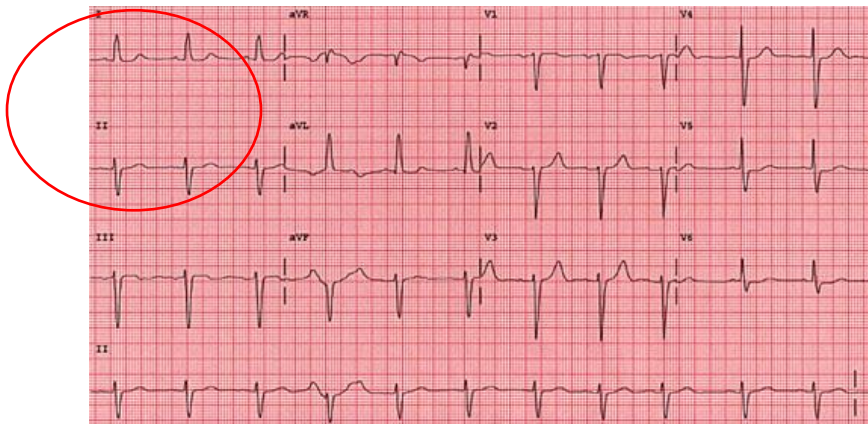
4. Method working for regular and irregular rhythm:

measure 30 big square on ECG strip, then calculate how many QRS complex within this 30 big square, then multiply the number of QRS complex by 10 then you will get the heart rate.

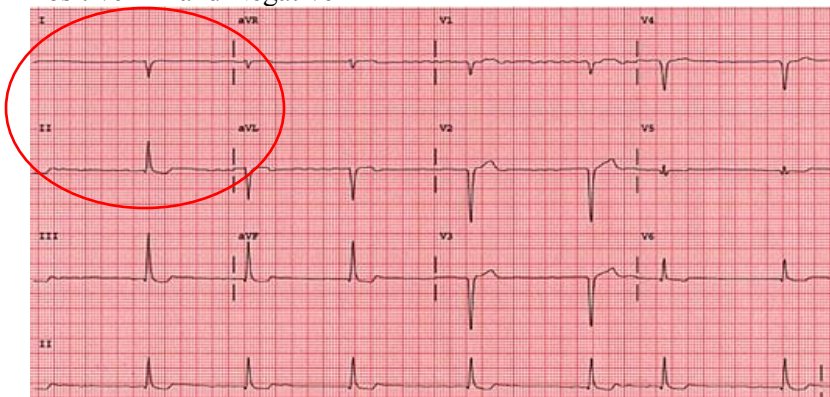
### Axis trick



Positive in I and II = normal



Positive in I and Negative in II = LAD



Negative in I Positive in II = RAD

## P-Wave

- **P wave**: better seen in lead II.
- **absent P wave** can be seen in many disorders, the most important and common causes are:
  1. **Atrial Fibrillation**: (if absent P wave + irregular rhythm = consider it as Atrial Fibrillation)
  2. **SVT (supraventricular tachycardia)**: regular narrow complex tachycardia with absent P wave.
  3. **VT (V tach) (Ventricular tachycardia)**: any wide QRS complex tachycardia is considered VT until proven otherwise.
  4. **VF (V fib) (ventricular Fibrillation)**: An ECG finding of a rapid grossly irregular ventricular rhythm with marked variability in QRS cycle length, morphology, and amplitude.

## P-R interval

- Prolong PR interval **>0.2 sec (> 200 ms) (>5 small boxes)** = AVB ( 1<sup>st</sup>, 2<sup>nd</sup> type1, 2<sup>nd</sup> type2 or 3<sup>rd</sup> degree heart block) or hyperkalemia
- Short PR interval **<0.120 sec (120 ms) (< 3 small squares)** = most important cause is WPW which is associated with delta wave. Remember 3<sup>rd</sup> degree heart block causing Variable P-R interval length, So it will cause short and prolong P-R interval.

## Q-Wave

- Q waves: **>1** small square in width and **>25%** height of R wave in **≥2** contiguous leads suggest old MI

## Q-T interval

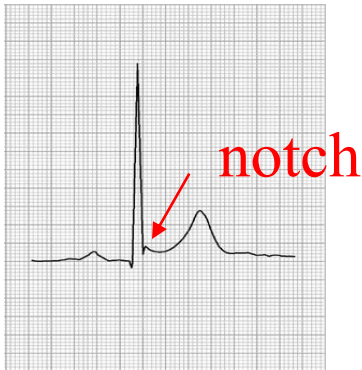
- It is the time between the start of the **Q wave** and the end of the **T wave**
- normal value for the QTc in men is **≤0.44 sec (440 ms)** and in women is **≤0.45 (450 ms)**
- if QT interval > half the RR interval; then consider prolonged QT interval.
- Q-T interval is a marker for the potential of ventricular tachyarrhythmias like Torsadesdepointes and a risk factor for sudden death.

## QRS complex

- Wide QRS if more than **0.12 sec (120 ms) (more than 3 small squares)**
- Most important causes of wide QRS complex:
  1. Ventricular tachycardia
  2. Hyperkalemia
  3. Bundle branch block (Rt or Lt)
  4. Some drug toxicity like TCA
  5. WPW (not always wide QRS complex)
  6. 3<sup>rd</sup> degree heart block (not always wide QRS complex)

## S-T segment

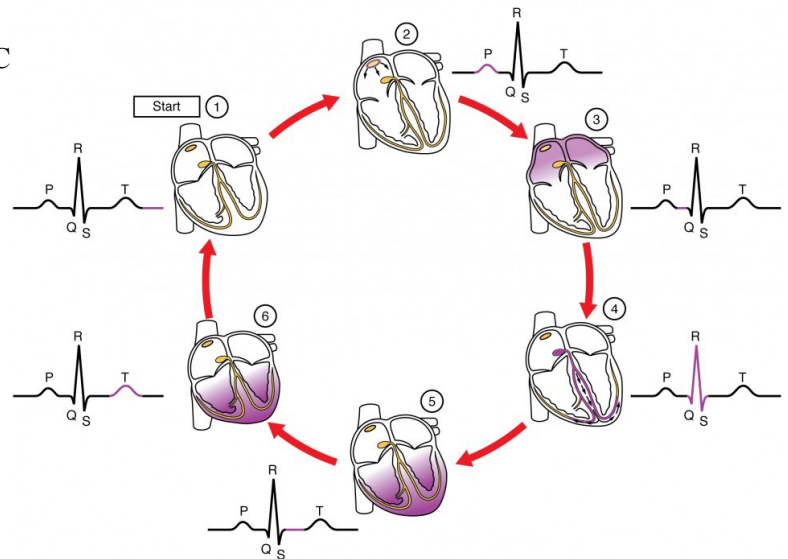
- Either elevated or depressed.
- Better determined by J point.
- The best isoelectric line to measure the ST segment elevation or depression is TP.
- Most important and common causes of **ST-elevation**:
  1. Acute STEMI
  2. Acute pericarditis (Widespread ST elevation and PR depression in most leads, expect lead AVR will be ST depression and PR elevation)
  3. LBBB
  4. Benign early repolarization
- **If you find a notch in ST-segment, then very less likely to be ischemia**



- Most important cause of **ST segment depression**:
  1. Ischemia (either as part of non STEMI or as a reciprocal changes)
  2. LVH with repolarization abnormality

## T-wave

- Peaked, Inverted, biphasic or flattened.
- may be ischemia / injury but **NONSPECIFIC**



## Bundle Branch Block

- - LBBB: terminal deflection in lead I (+); bunny ears in V5-V6 (WiLLiaM)
- - RBBB: terminal deflection in lead I (-); bunny ears in V1-V2 (MaRRoW)

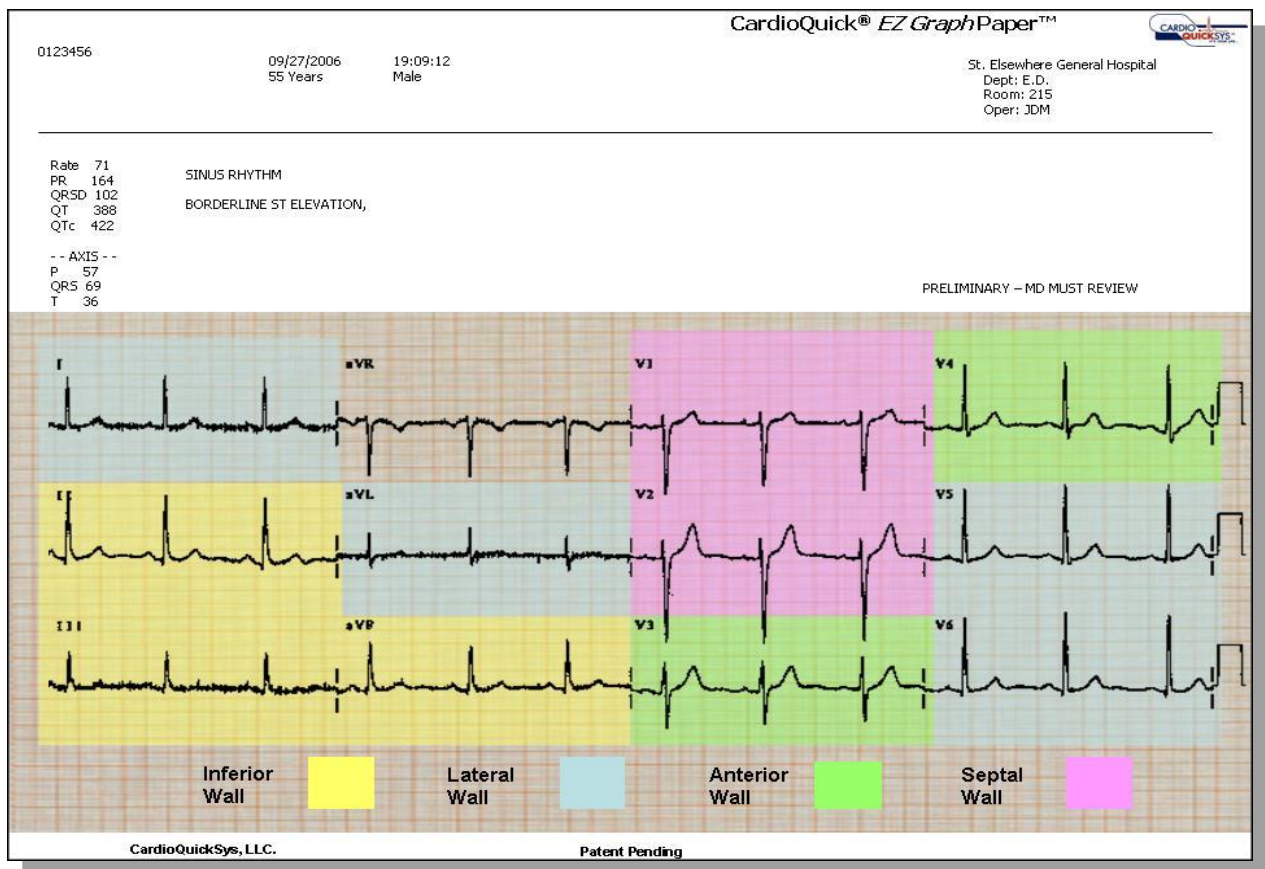
i.e., with LBBB, there is a W in lead V1 and an M in lead V6, whereas, with RBBB, there is an M in V1 and a W in V6.

## Left Ventricular Hypertrophy

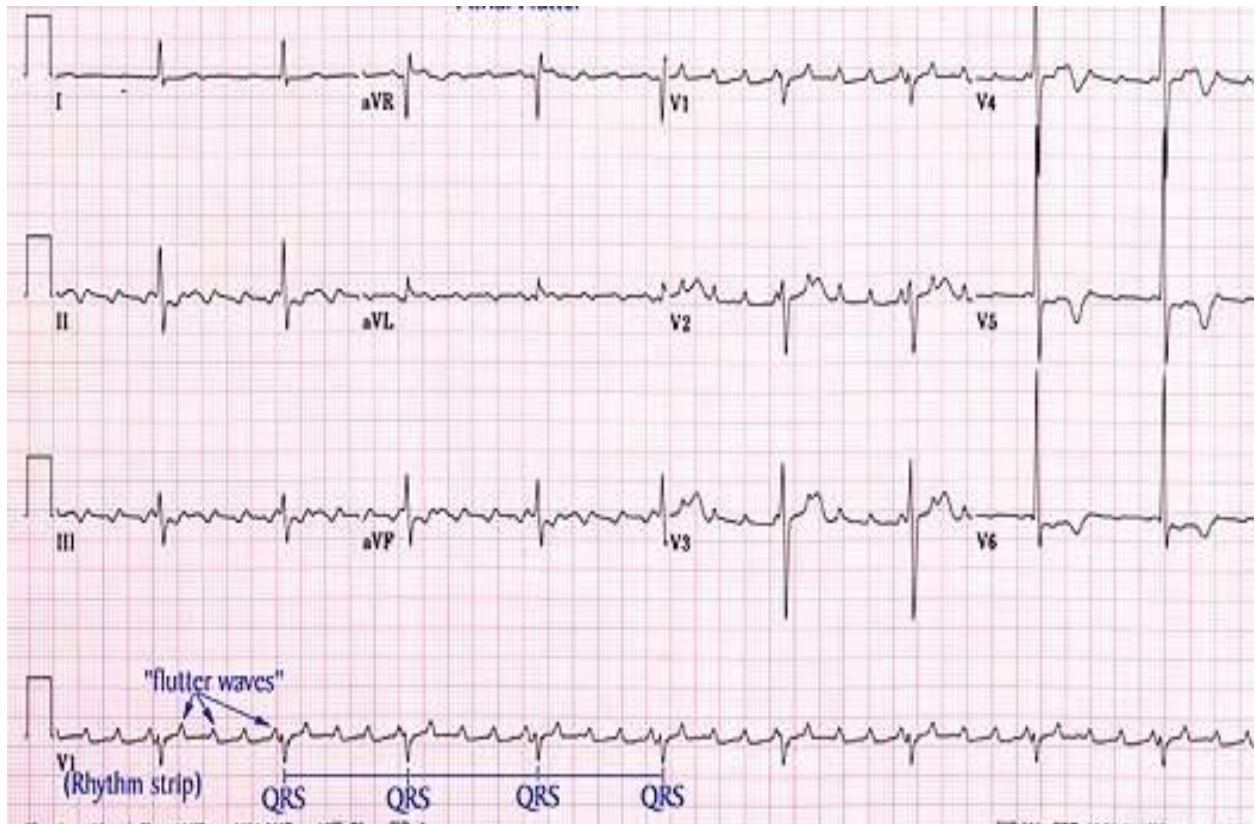- Hypertrophy (more muscle -> more voltage)

LVH =  $SV1 + (RV5 \text{ or } RV6) > 35$  small squares ( $> 7$  big boxes)

## *Viewpoints of the heart:*



## Let's interpret the following ECGs:



### Interpretation:

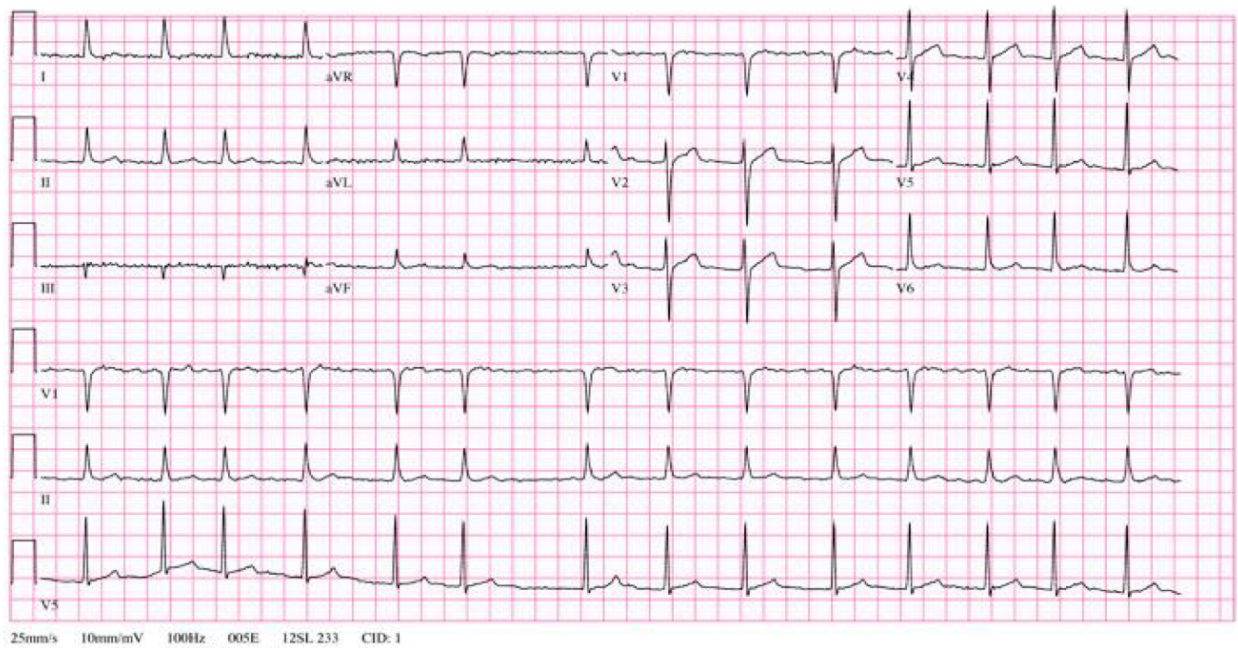
- Important findings:

Flutter waves (“saw-tooth” pattern)

- Diagnosis:

Atrial Flutter



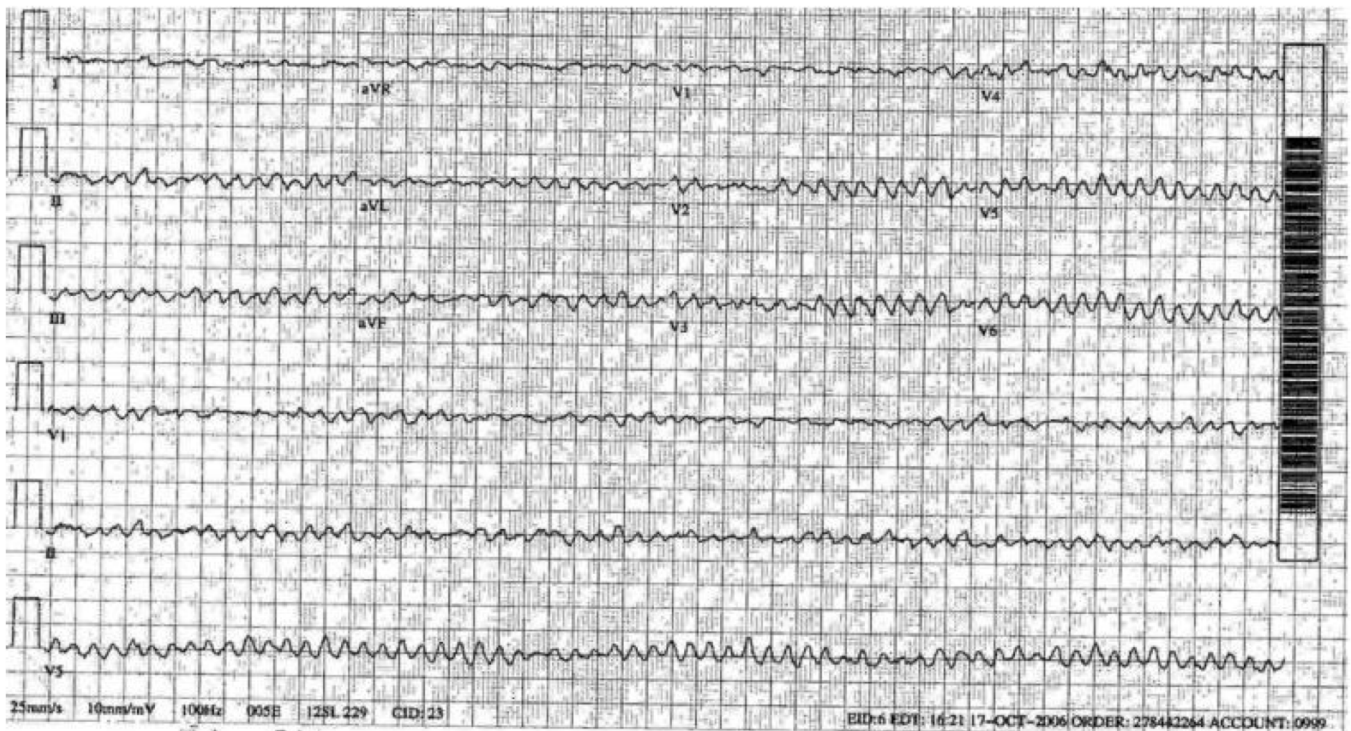


- Important findings:

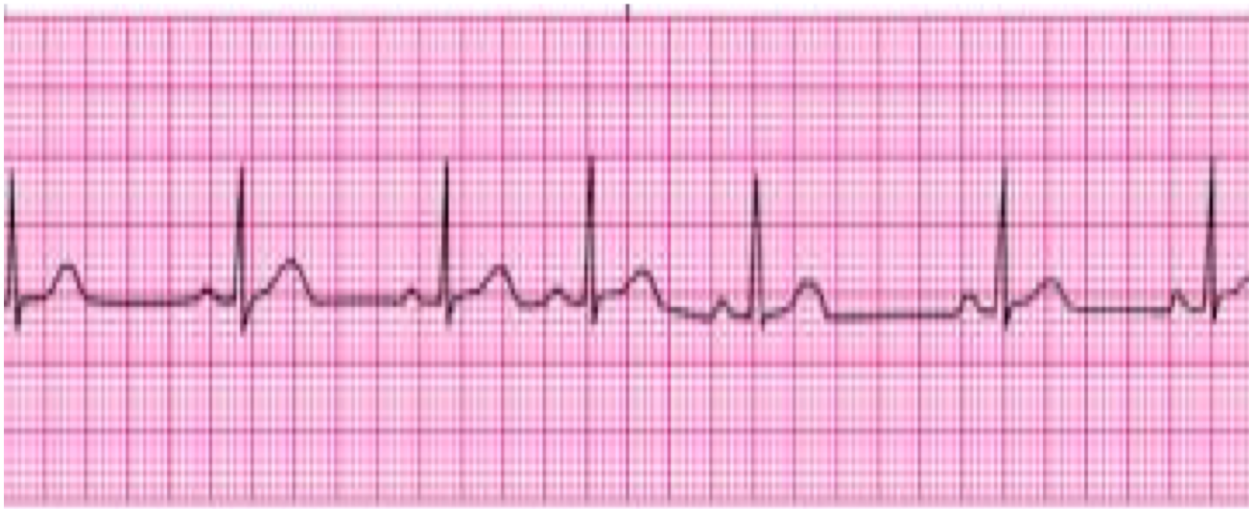- Irregular rhythm
- Absent P-wave

- Diagnosis:

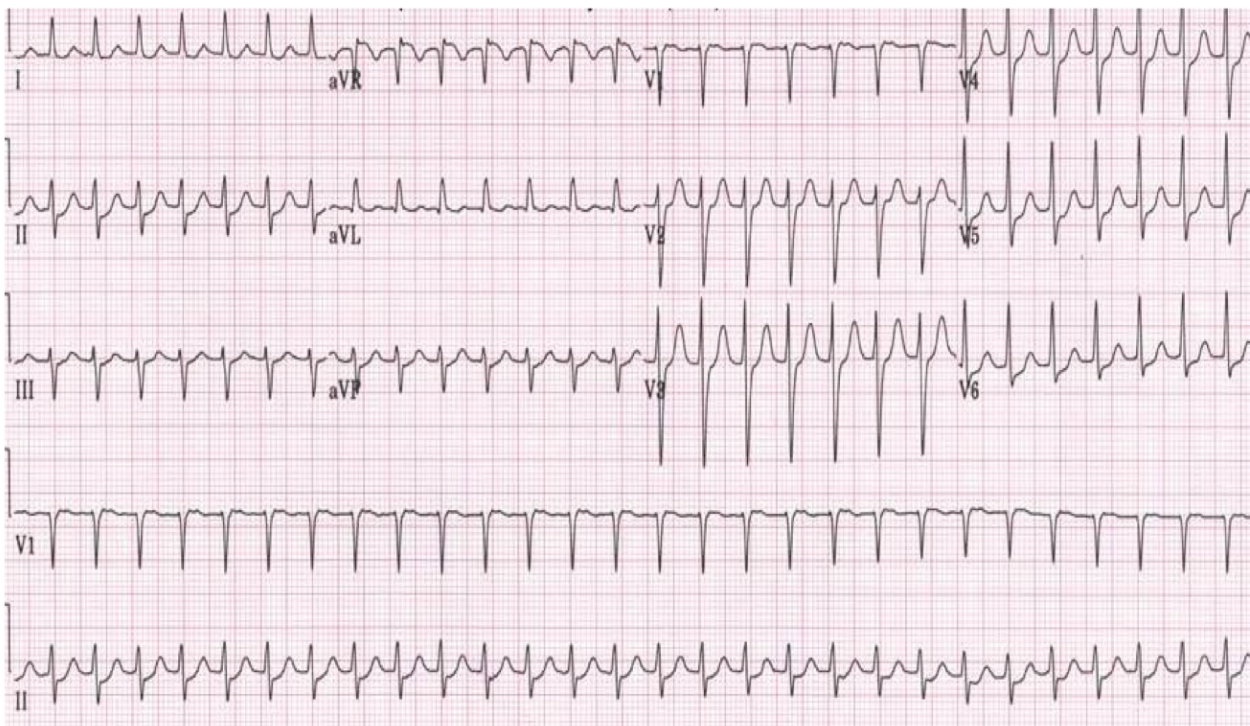
- Atrial Fibrillation



## Ventricular Fibrillation



- Important findings:
  - Irregular rhythm
  - Present P-wave with normal PR interval
- Diagnosis:
  - Sinus arrhythmia



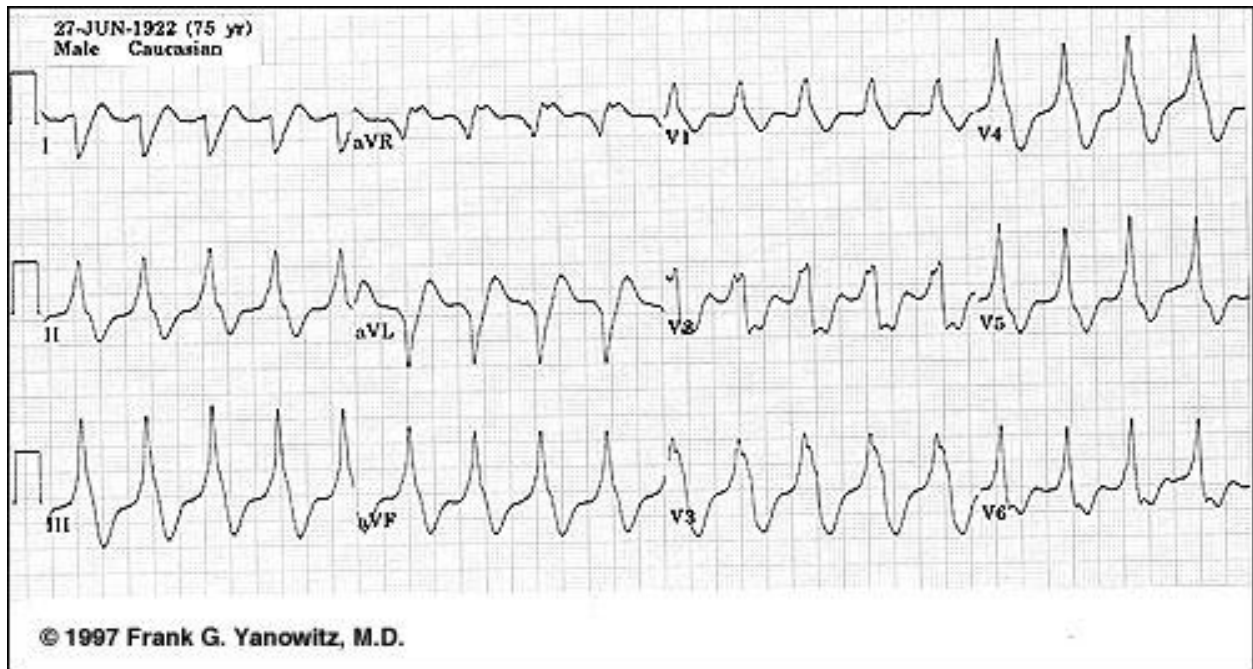
Important findings:

- Regular tachycardia
- Absent P wave
- Normal QRS complex

Diagnosis:

- SVT

## ECG



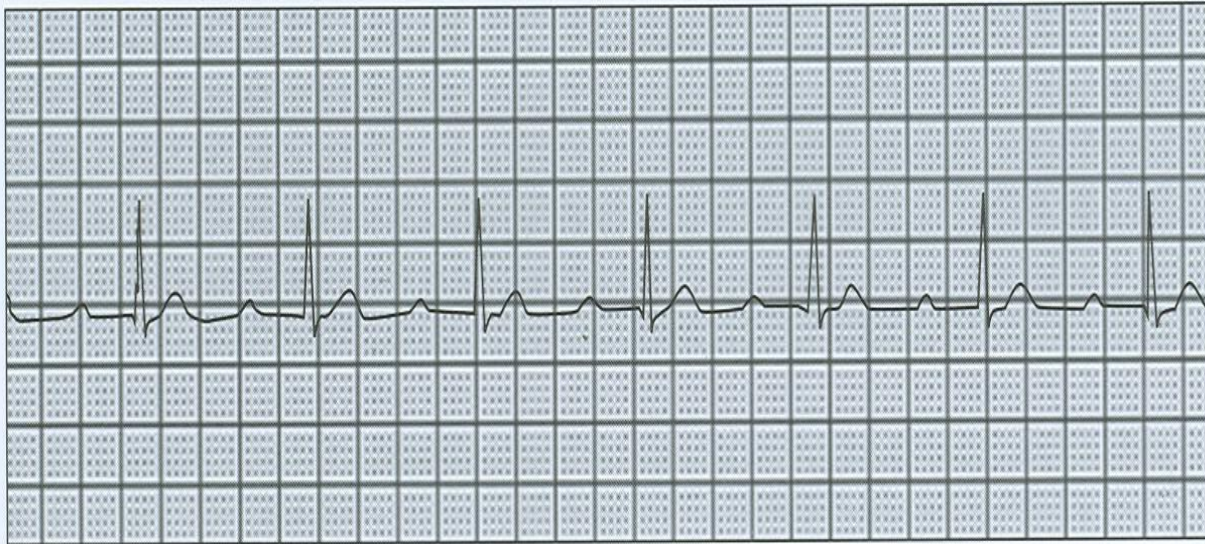### Important findings:

- Regular tachycardia
- Absent P- wave
- Wide QRS complex

### Diagnosis:

- Wide QRS complex tachycardia most likely: Ventricular Tachycardia

## ECG

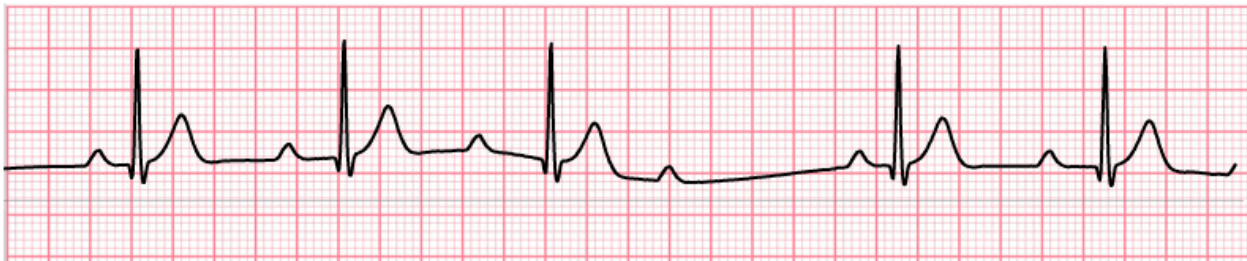

### Important findings:

- Regular rhythm
- Fixed prolonged PR interval without QRS complex drop

### Diagnosis:

- 1<sup>st</sup> degree heart block



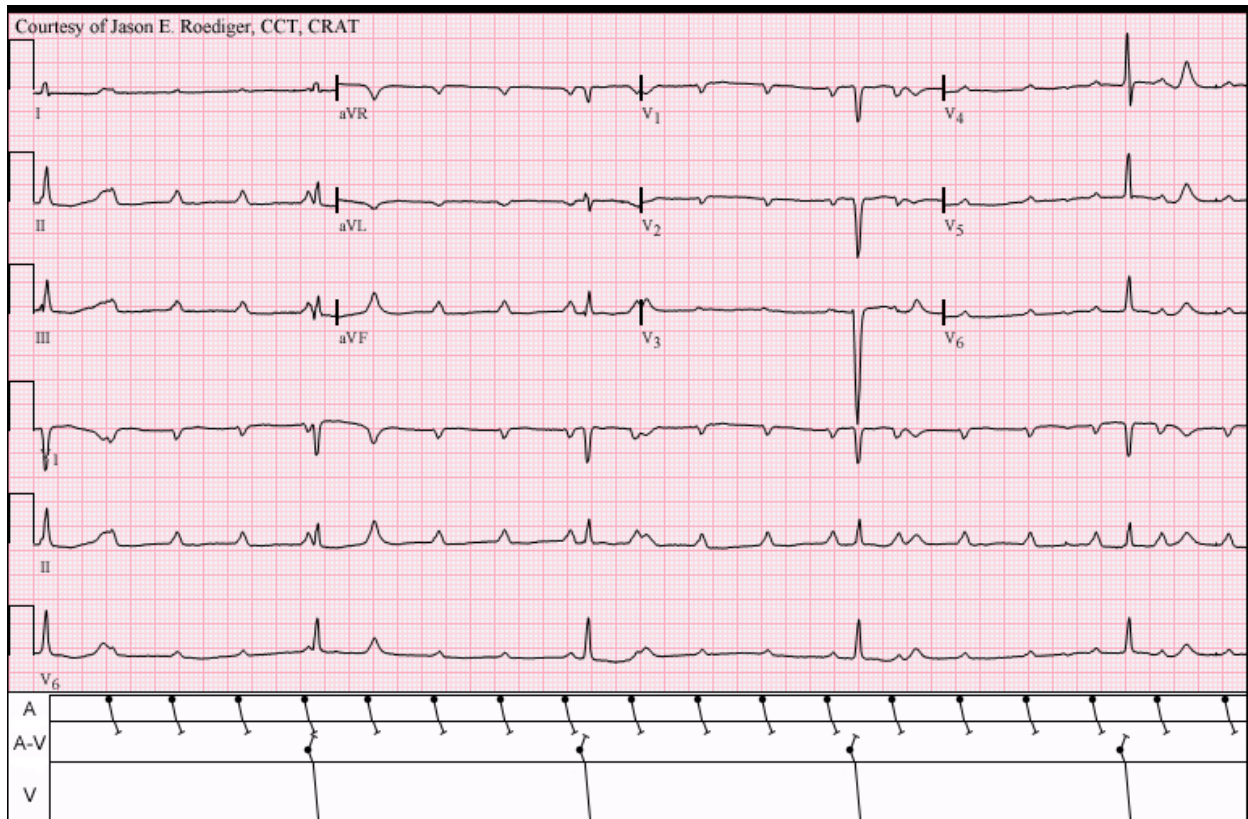
### Important findings:

- Irregular
- Progressive prolongation of PR interval followed by a drop in QRS complex

### Diagnosis:

- 2<sup>nd</sup> degree heart block type 1 (mobitz I)

## ECG

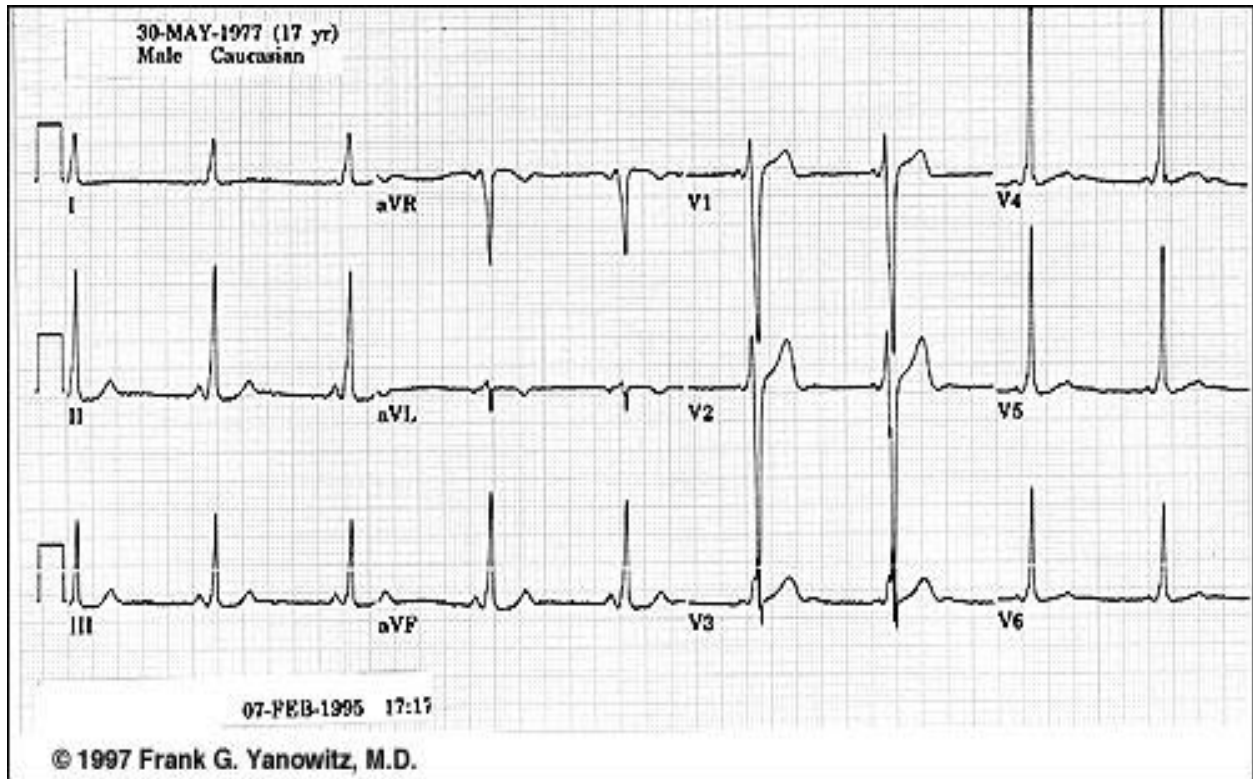


### Important findings:

- Regular rhythm
- bradycardia
- The P wave with a regular P-to-P interval
- The QRS complex with a regular R-to-R interval.
- The PR interval will be variable
- As the hallmark of complete heart block is lack of any apparent relationship between P waves and QRS complexes.

Diagnosis: 3<sup>rd</sup> degree heart block (complete heart block)

## ECG



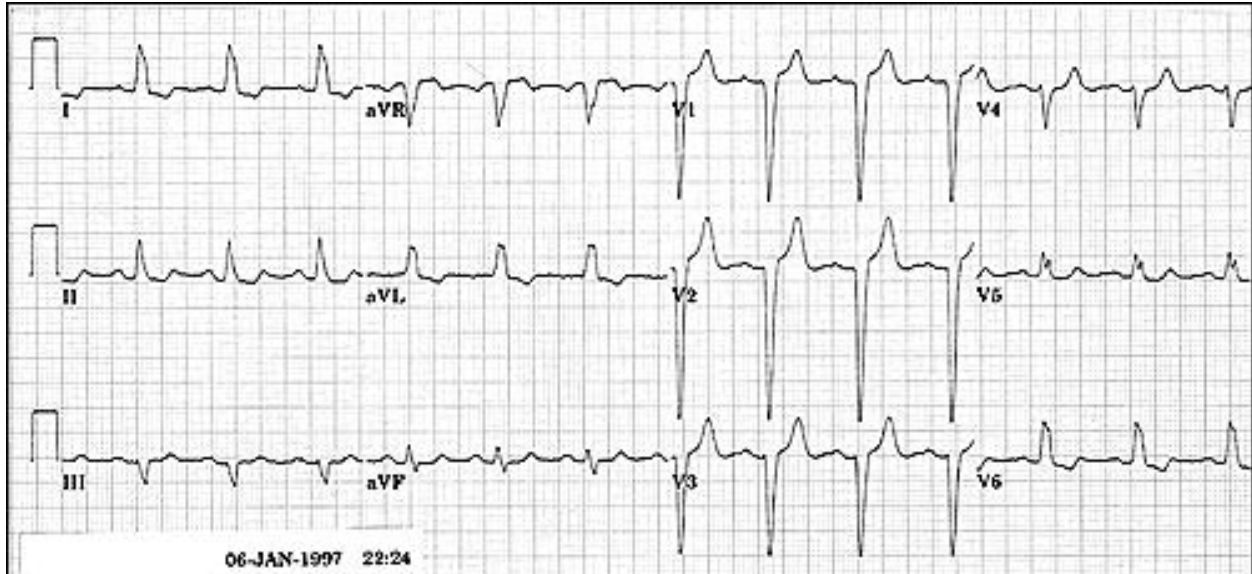
### Important findings:

- Short PR interval
- Delta wave

### Diagnosis:

- WPW

## ECG



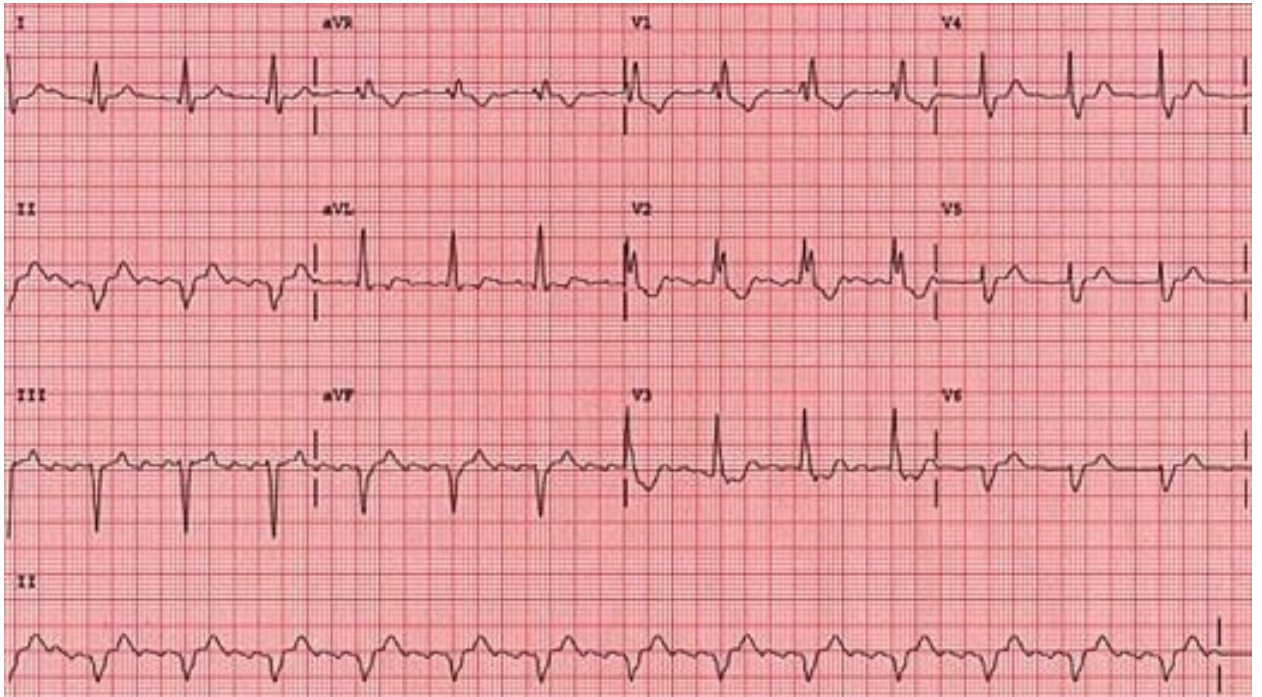
### Important findings:

- Wide QRS complex
- ST elevation V1-V2
- notched ('M'-shaped) R wave in lead V6.

### Diagnosis:

- Left Bundle Branch Block

## ECG

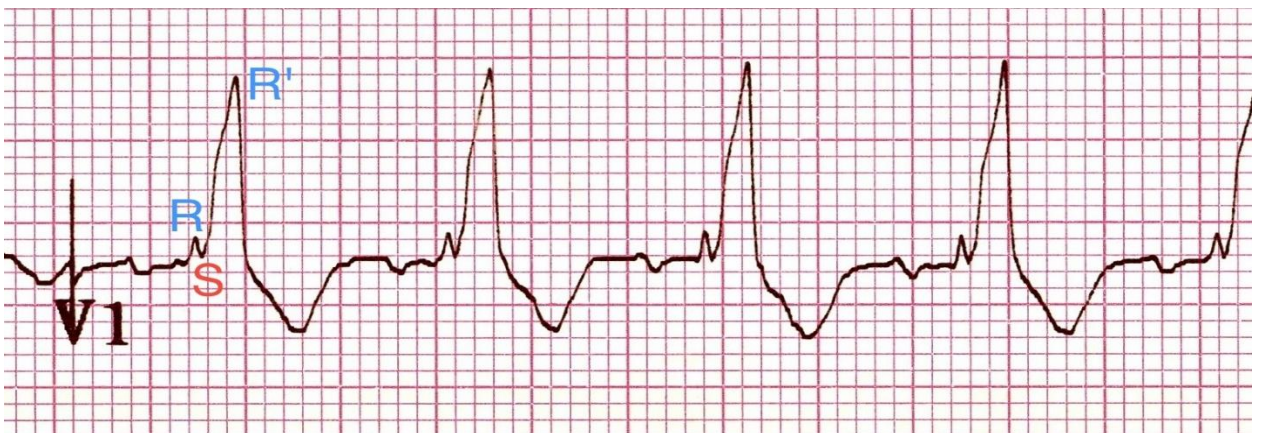


### Important findings:

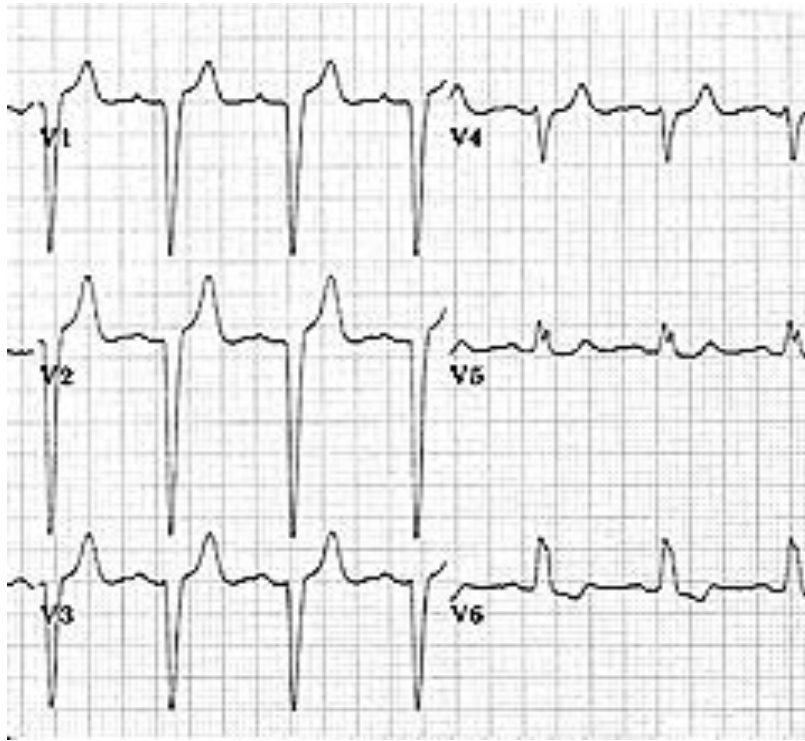
- Wide QRS complex
- notched ('M'-shaped) RSR wave in lead V1.

### Diagnosis:

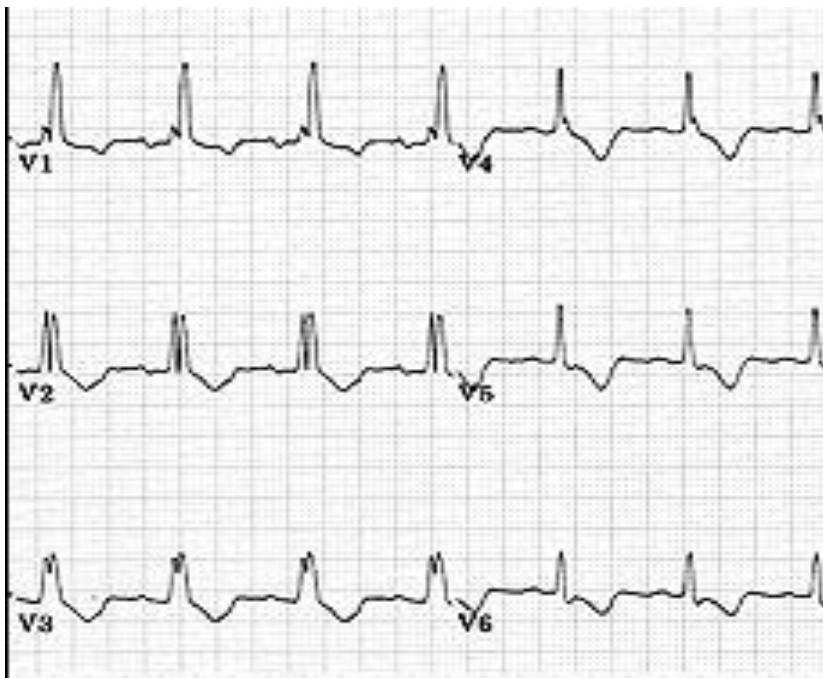
- Right Bundle Branch Block





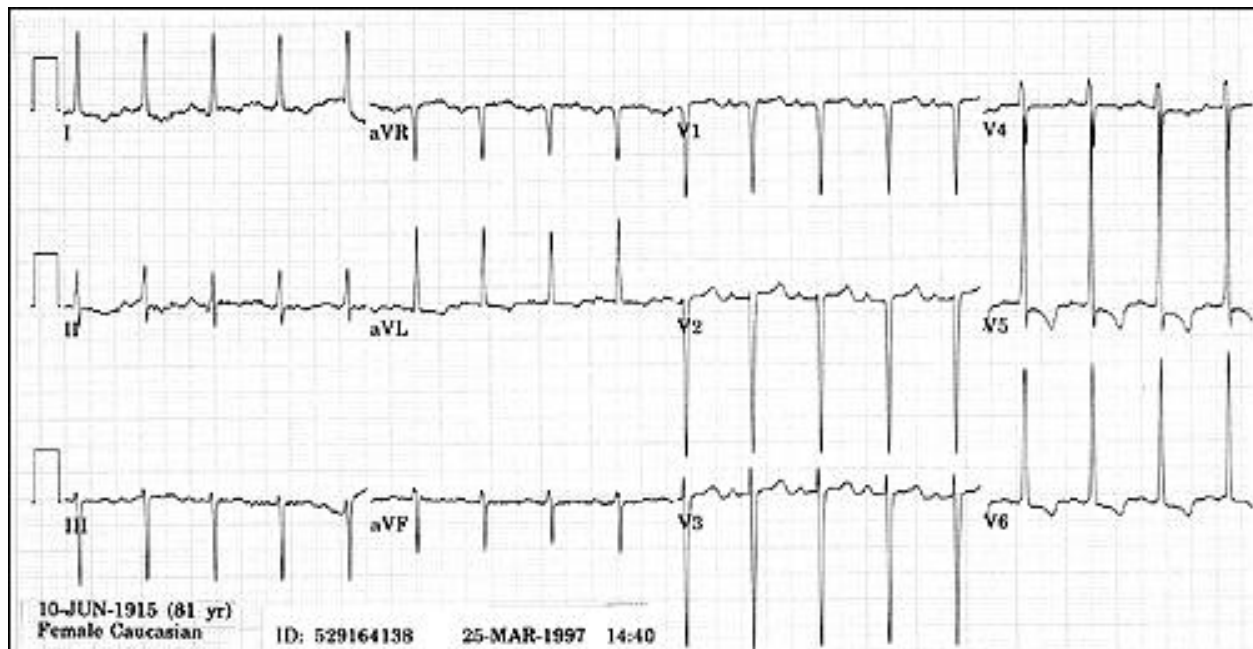

↑ LBBB



↑ RBBB

## ECG

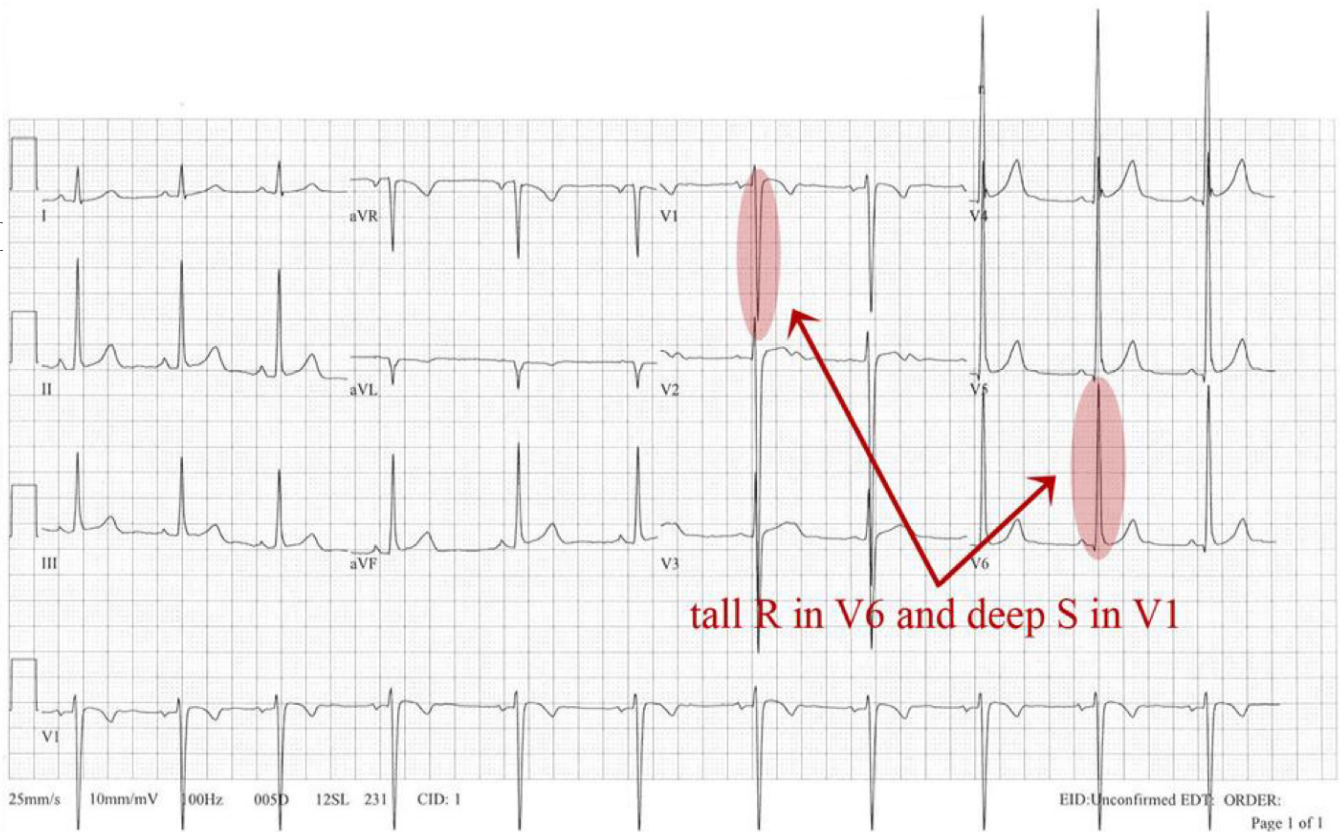


### Important findings:

- $SV1 + RV5$  or  $6 > 35$  small squares ( $> 7$  big squares)
- ST segment depression with T wave inversion in V5-V6 (not always present)

### Diagnosis:

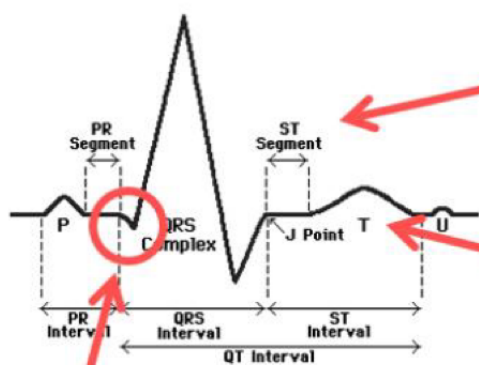
- Left Ventricular Hypertrophy (LVH)



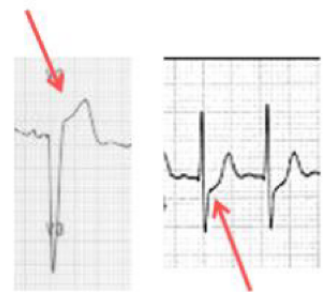● Left Ventricular Hypertrophy (LVH)

Ischemic ECG Changes

Ways the ECG can change include:



ST elevation & depression



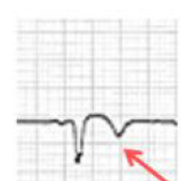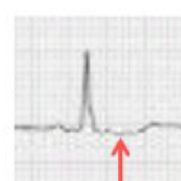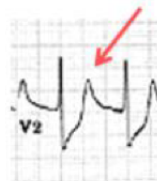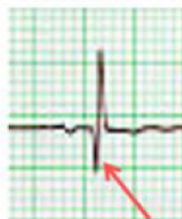T-waves

peaked

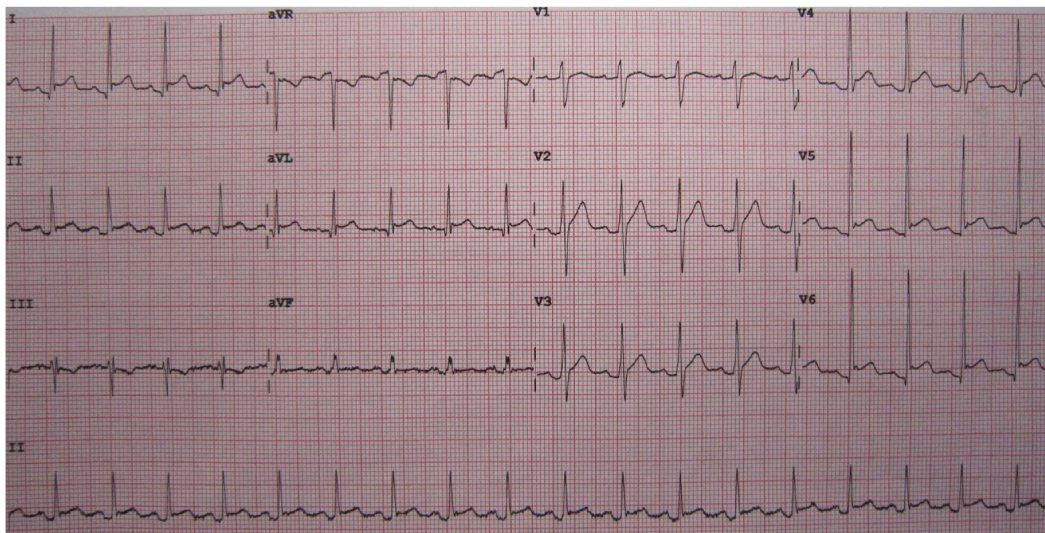
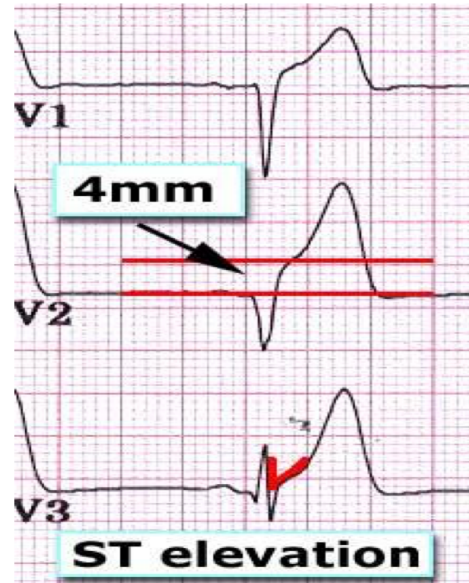
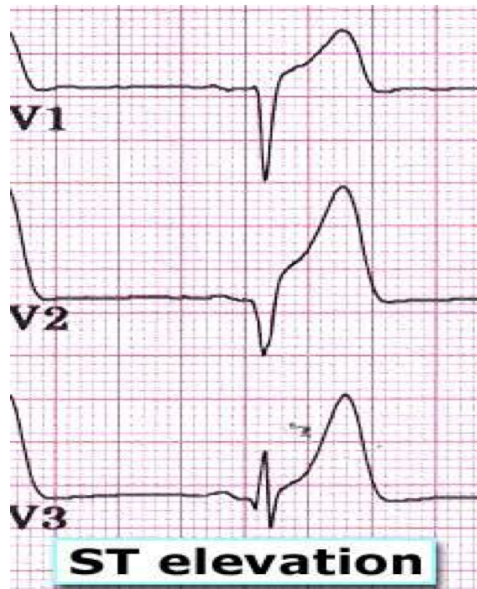
flattened

inverted

Appearance of pathologic Q-waves



## ST elevation



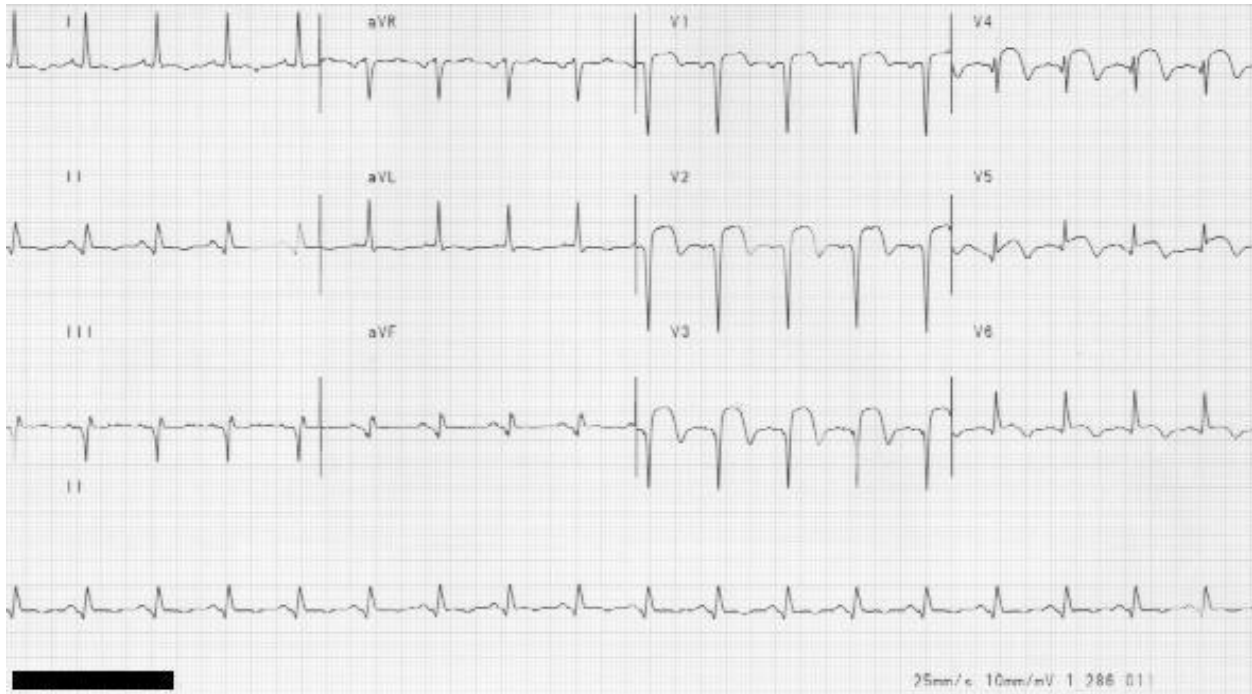
## Important findings:

- Widespread ST elevation with
- In aVR lead there is reciprocal changes (ST depression+ PR segment elevation)

## Diagnosis:

- Acute pericarditis

ECG



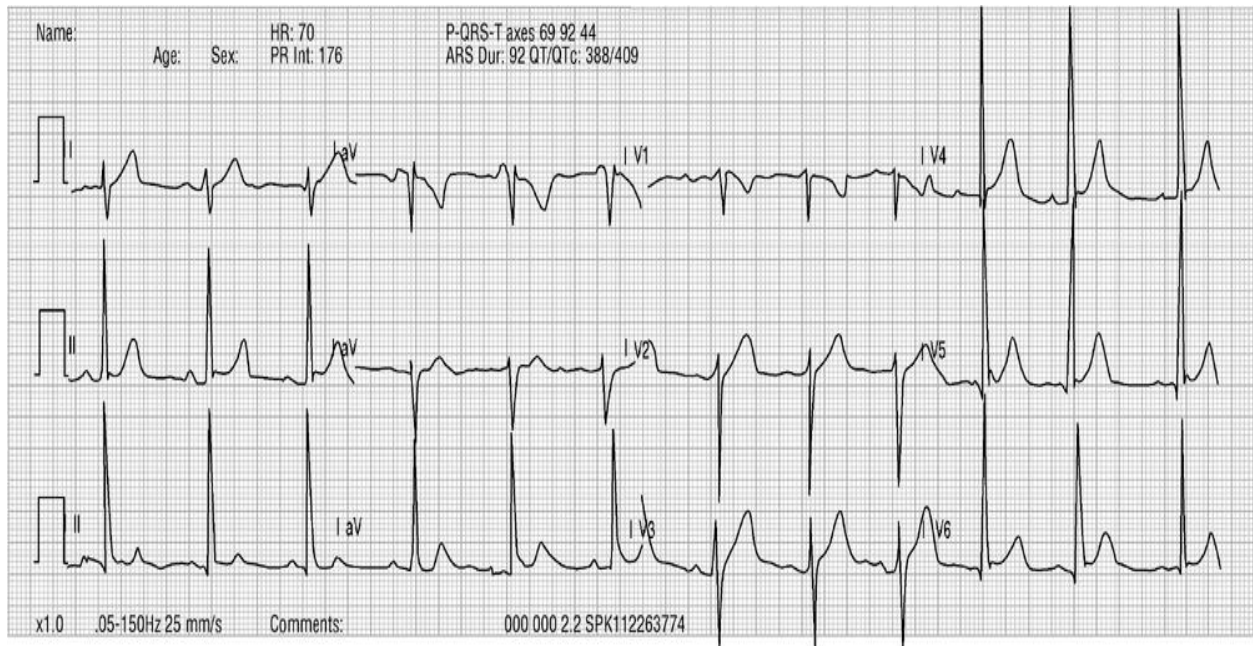
#### Important findings:

- ST segment elevation in V1-V6
- Flattened T wave in inferior Lead

#### Diagnosis:

- Most likely anterior MI (based on the Hx and complete picture)

## ECG



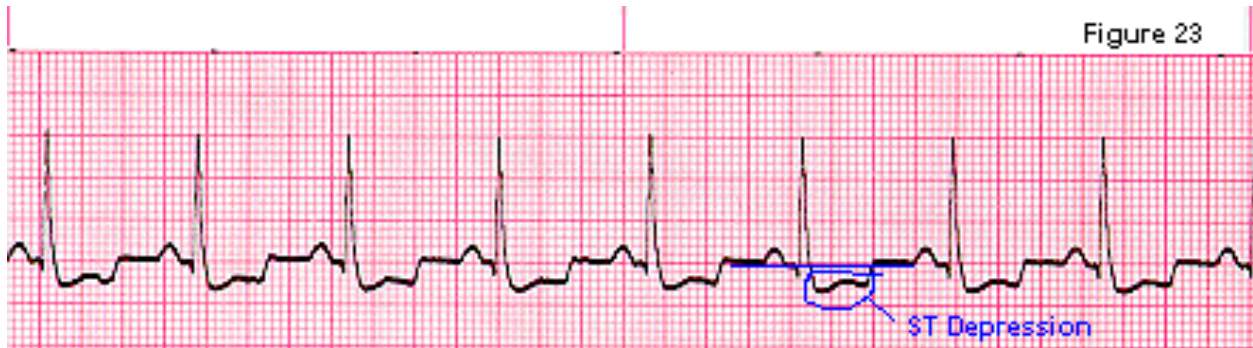### .Important findings:

- Widespread ST elevation
- There is a notch in ST segment which make it less likely to be ischemia.

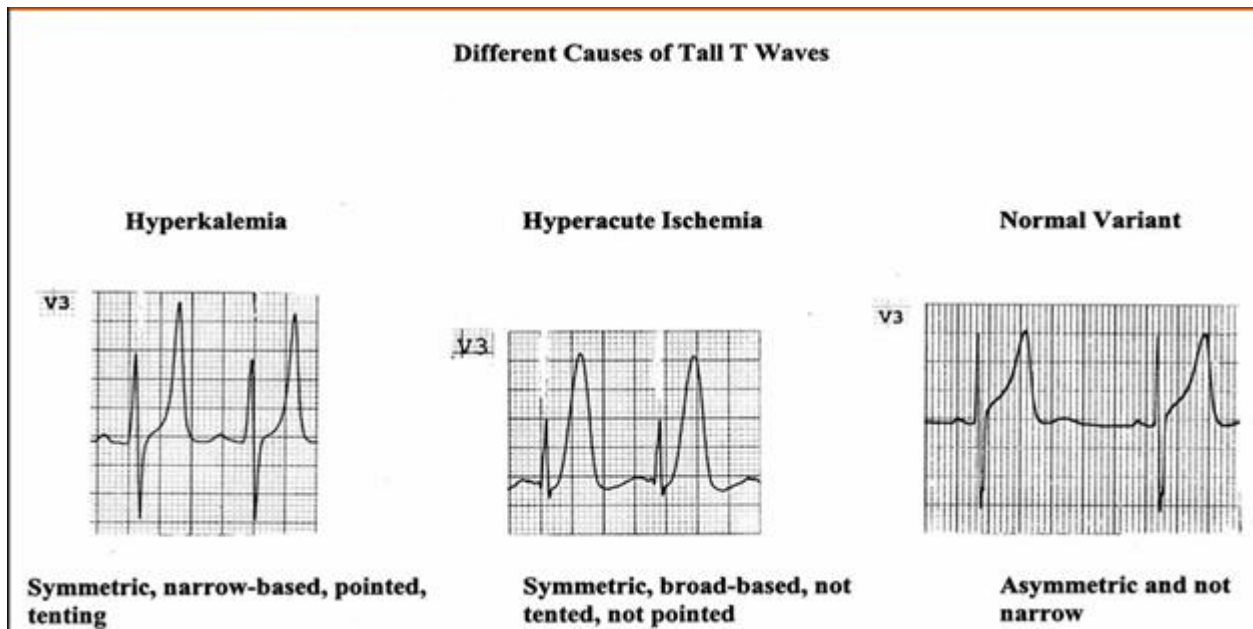
### Diagnosis:

- Benign early repolarization

## ST depression

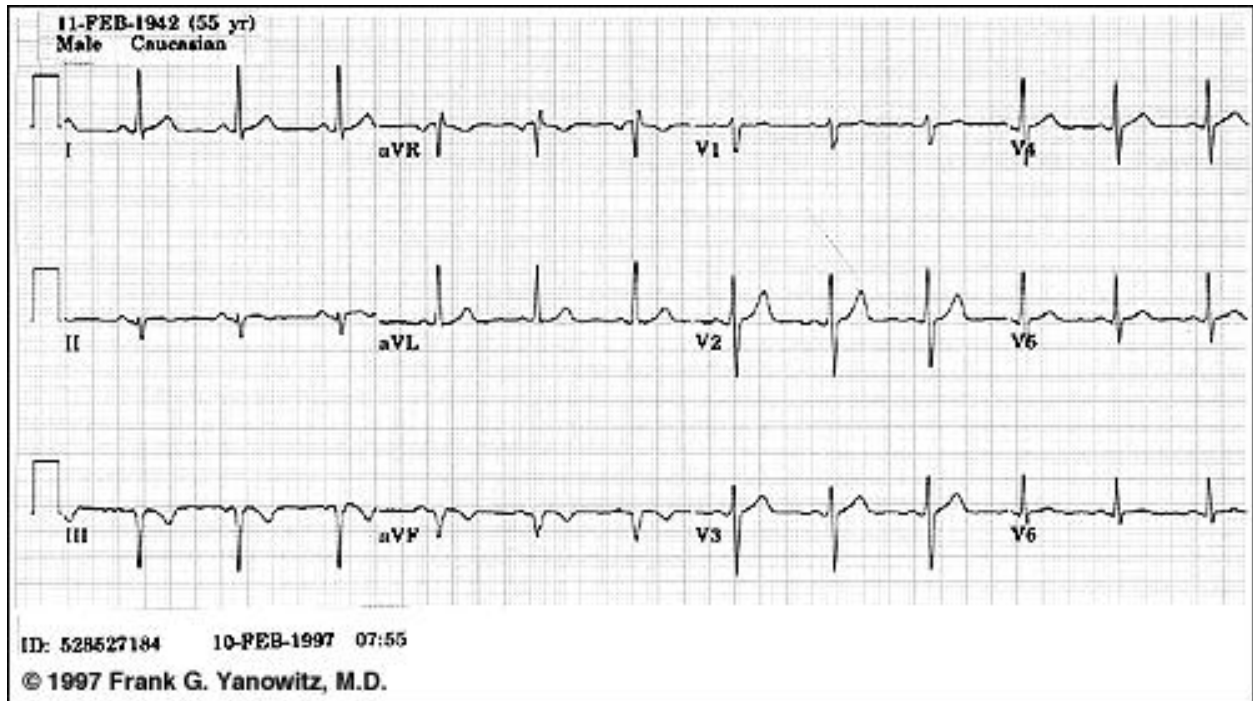


## hyper acute T waves



*adapted from Medscape.*

## ECG



### Important findings:

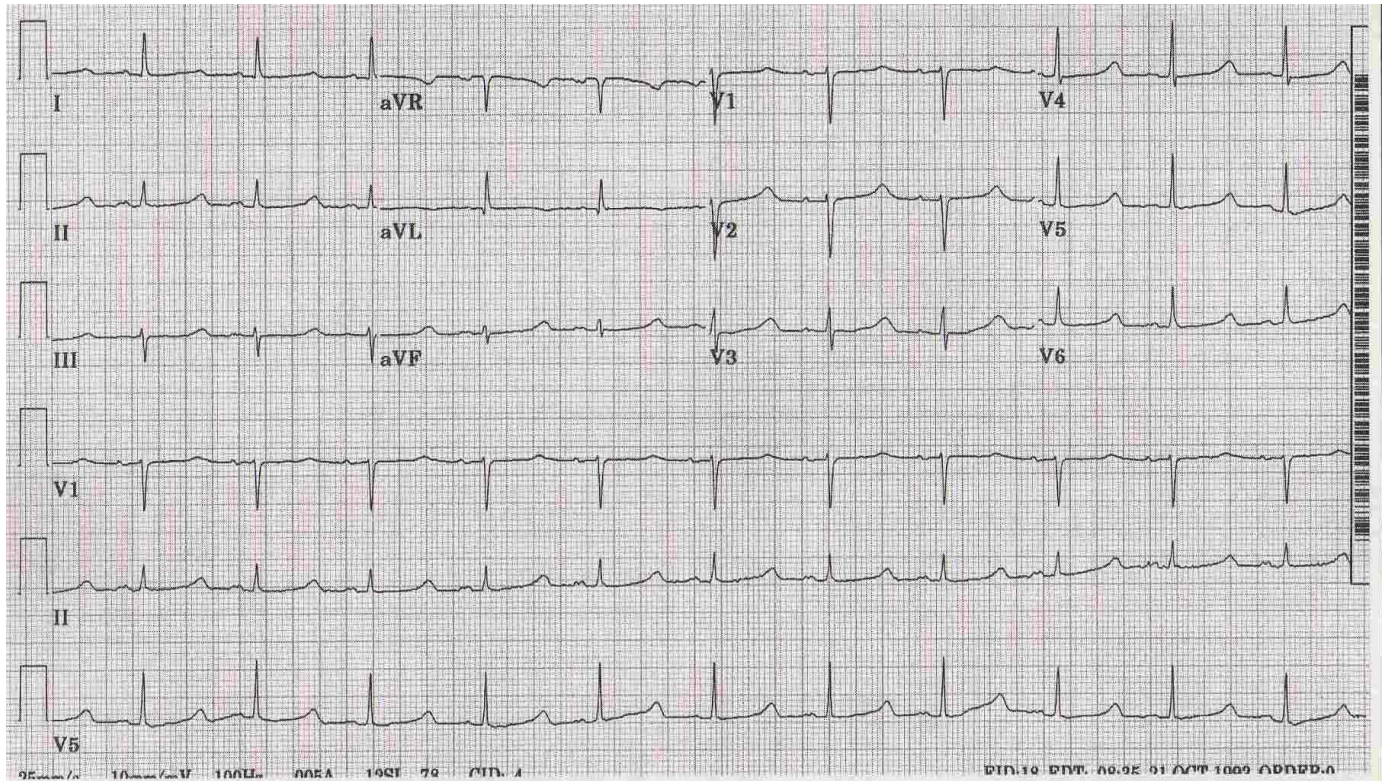
- There is T wave inversion in inferior leads

### Diagnosis:

- Ischemia (most likely NON STEMI which depend on Hx and complete picture)



## ECG



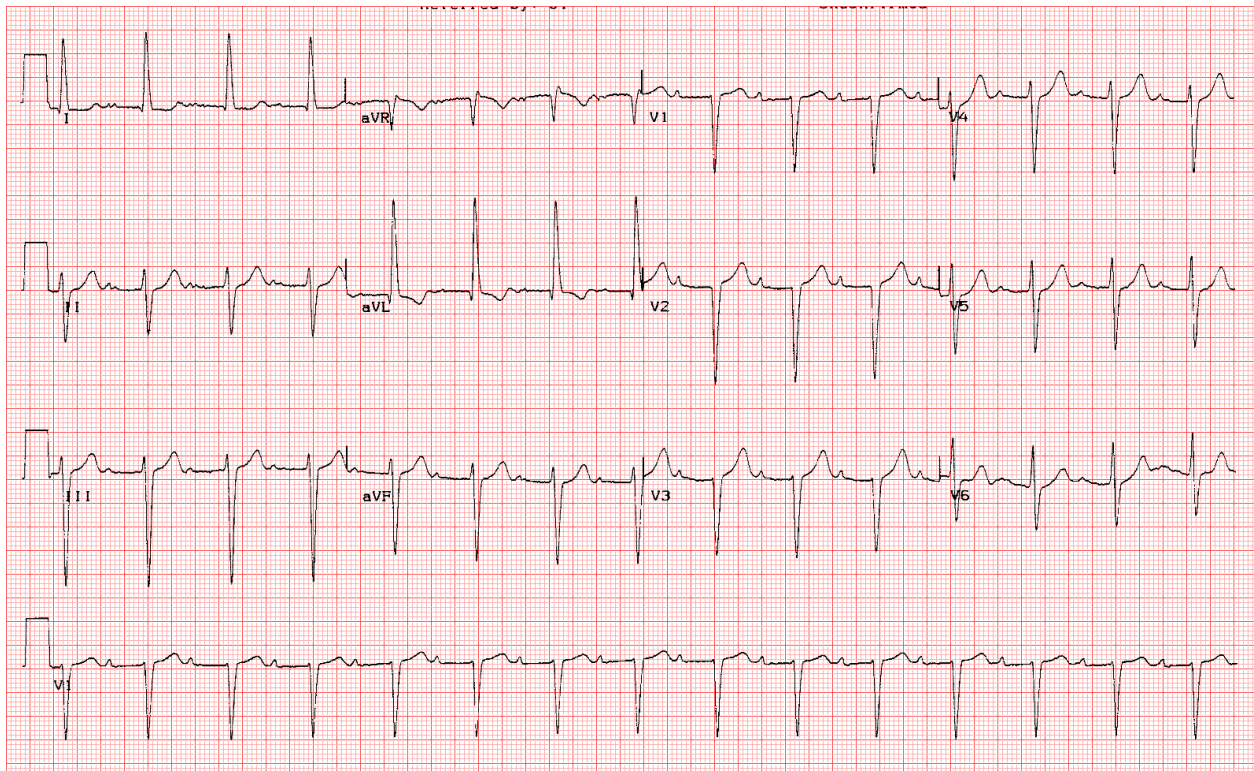
### Important findings:

- QT interval in  $> 50\%$  of R-R interval.

### Diagnosis:

- Prolonged QT interval

we done with ECG approach and most important ECG diagnosis, now try to interpret the following ECGs:

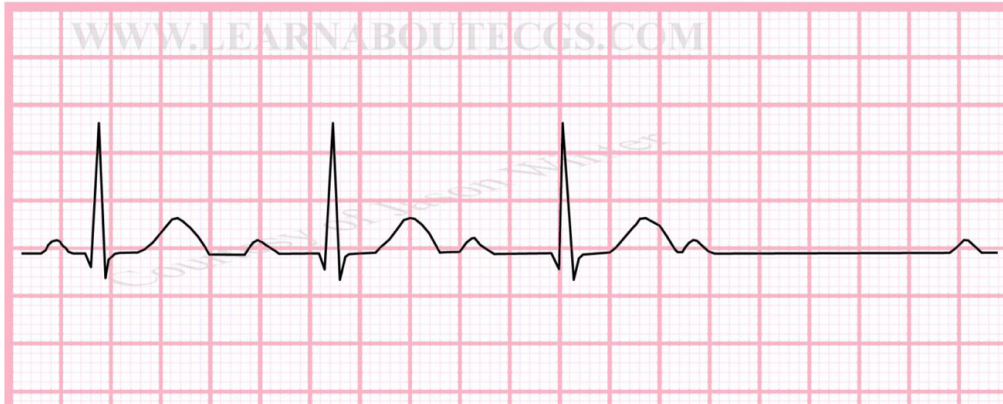


#### Important findings:

- Regular rhythm
- Fixed prolonged PR interval without QRS complex drop

#### Diagnosis:

- 1<sup>st</sup> degree heart block

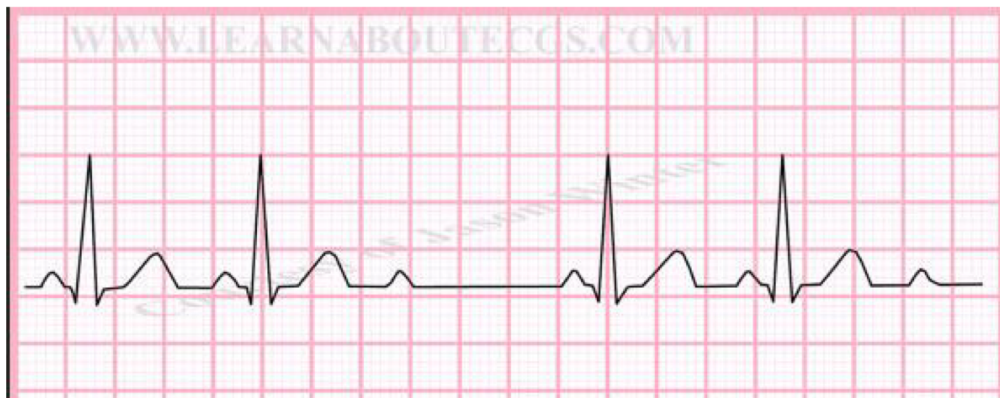

**Important findings:**

- Irregular
- Progressive prolongation of PR interval followed by a drop in QRS complex

**Diagnosis:**

- 2<sup>nd</sup> degree heart block type 1 ( mobitz I)



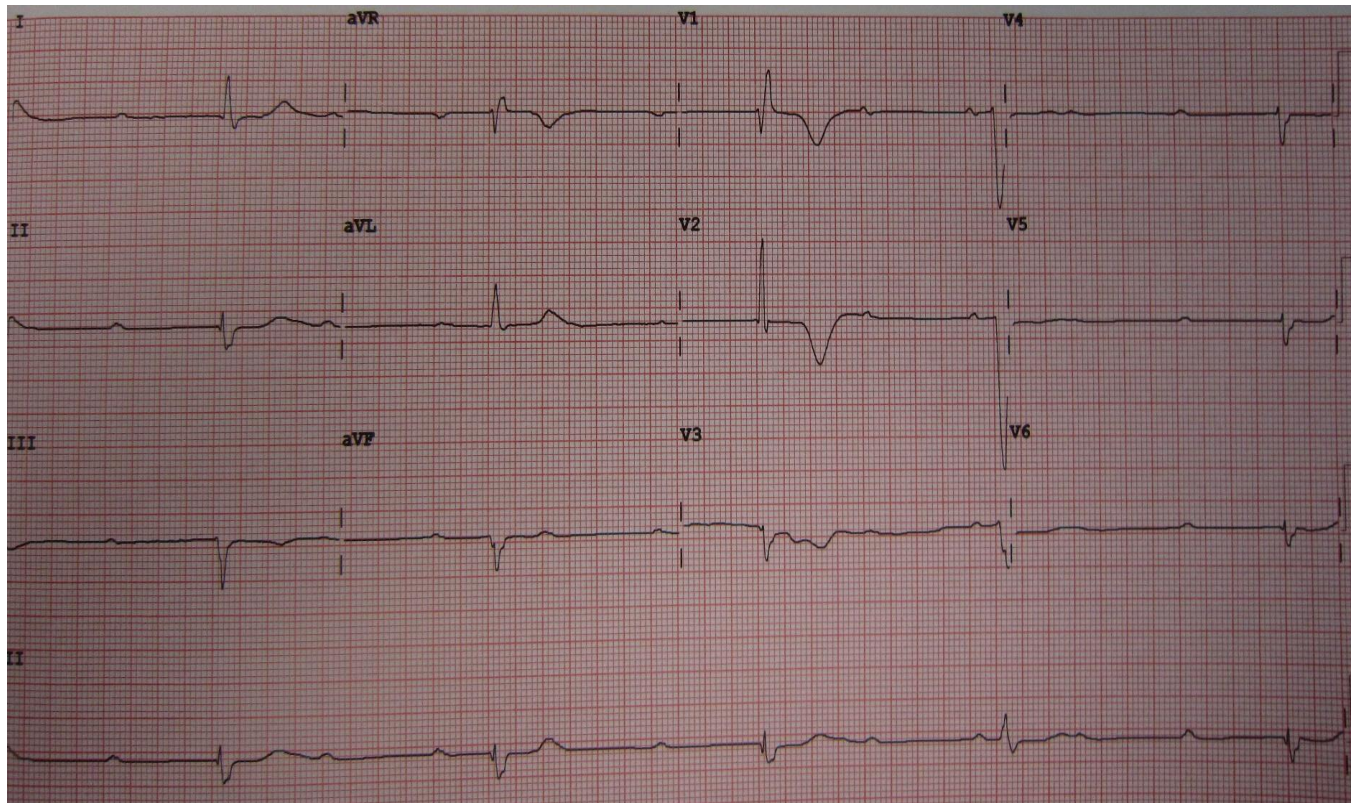
**Important findings:**

- Irregular
- Fixed prolonged PR interval followed by a drop in QRS complex

**Diagnosis:**

- 2<sup>nd</sup> degree heart block type 2 (mobitz II)

## ECG

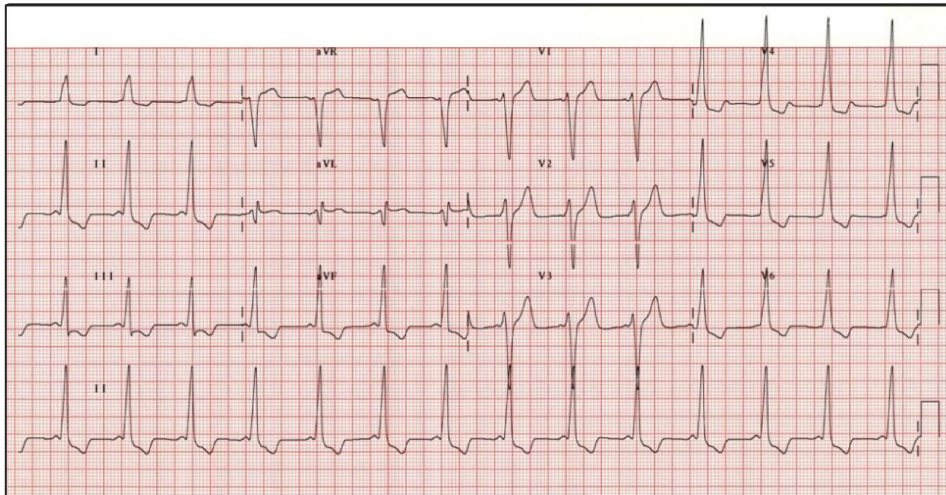


### Important findings:

- Regular rhythm
- Bradycardia
- Wide QRS complex
- The P wave with a regular P-to-P interval
- The QRS complex with a regular R-to-R interval.
- The PR interval will be variable
- As the hallmark of complete heart block is lack of any apparent relationship between P waves and QRS complexes.

### Diagnosis:

- 3<sup>rd</sup> degree heart block (complete heart block)

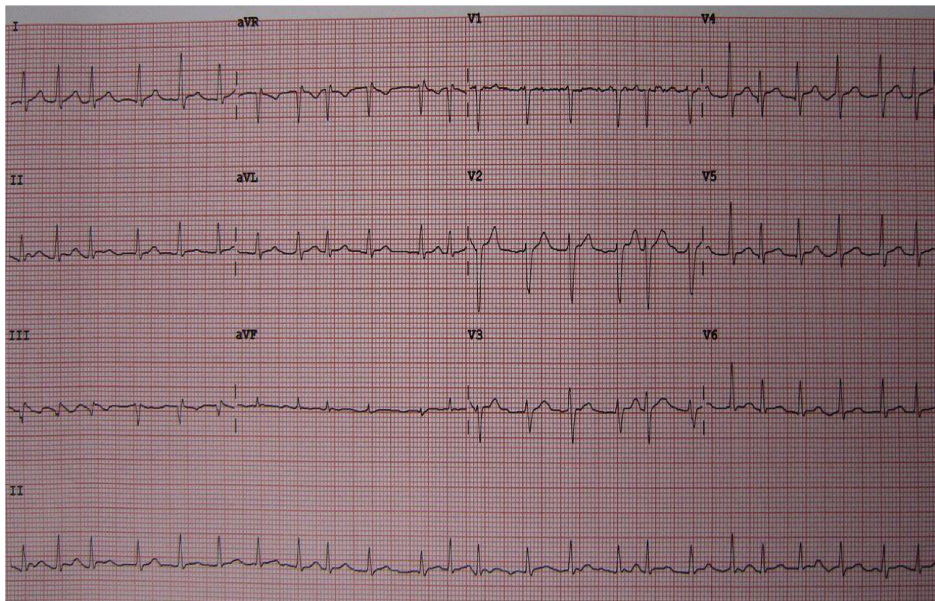


Important findings:

- Short PR interval
- Delta wave

Diagnosis:

- WPW



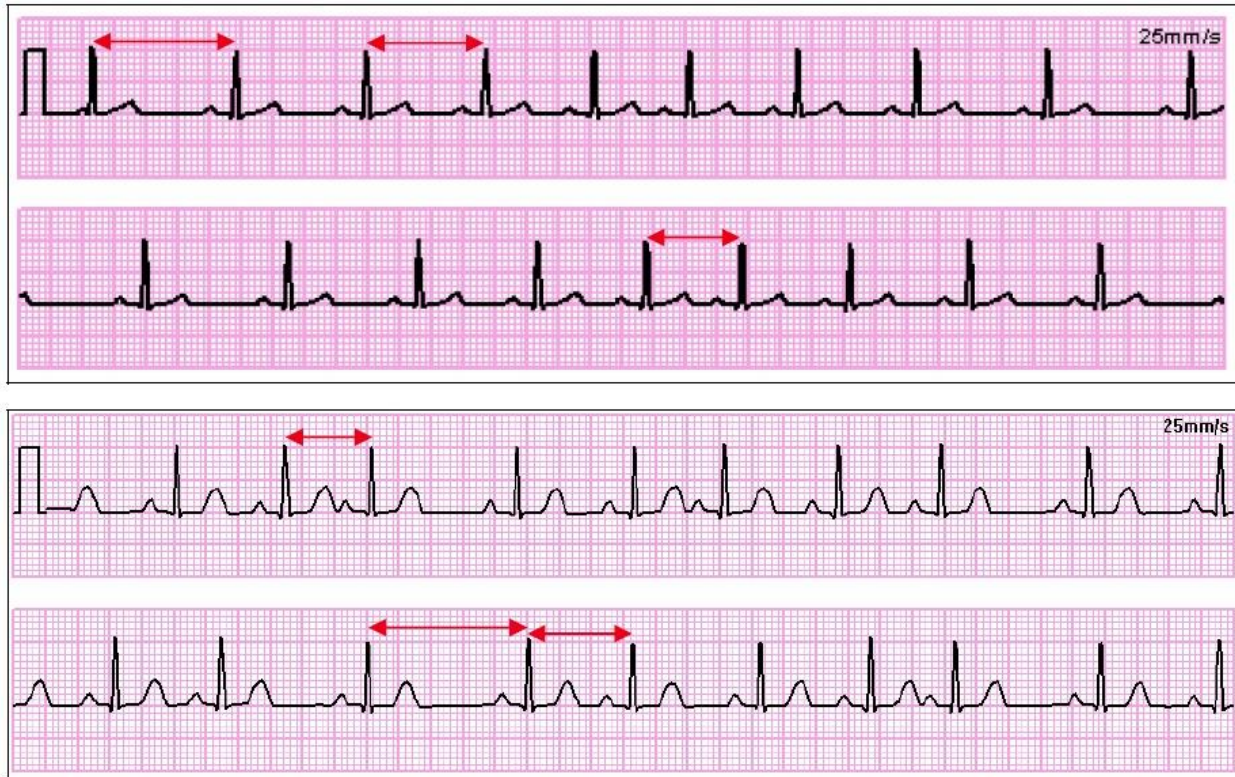
● Important findings:

- Irregular rhythm
- Absent P-wave

● Diagnosis:

- Atrial Fibrillation

## ECG

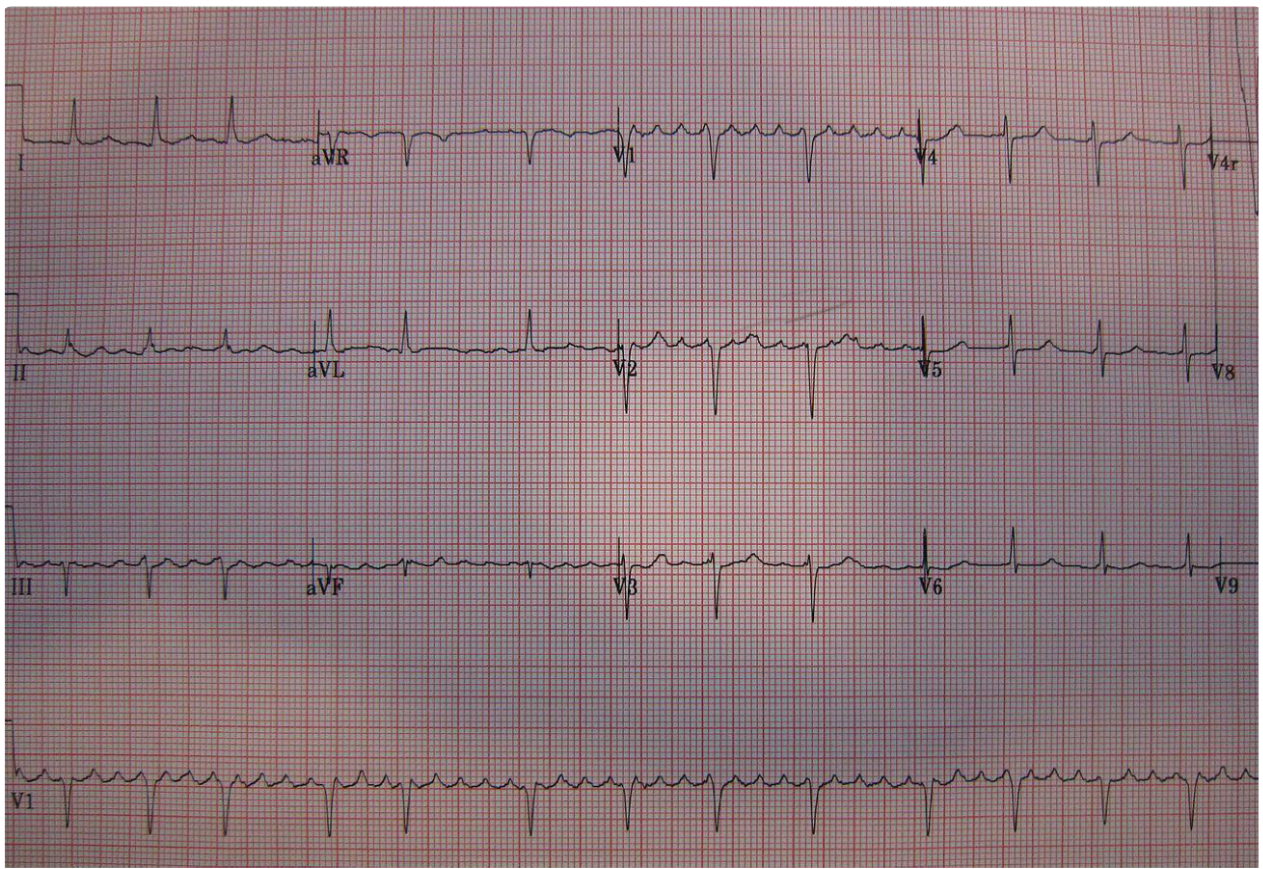


### Important findings:

- Irregular rhythm
- Present P-wave with normal PR interval

### Diagnosis:

- Sinus arrhythmia



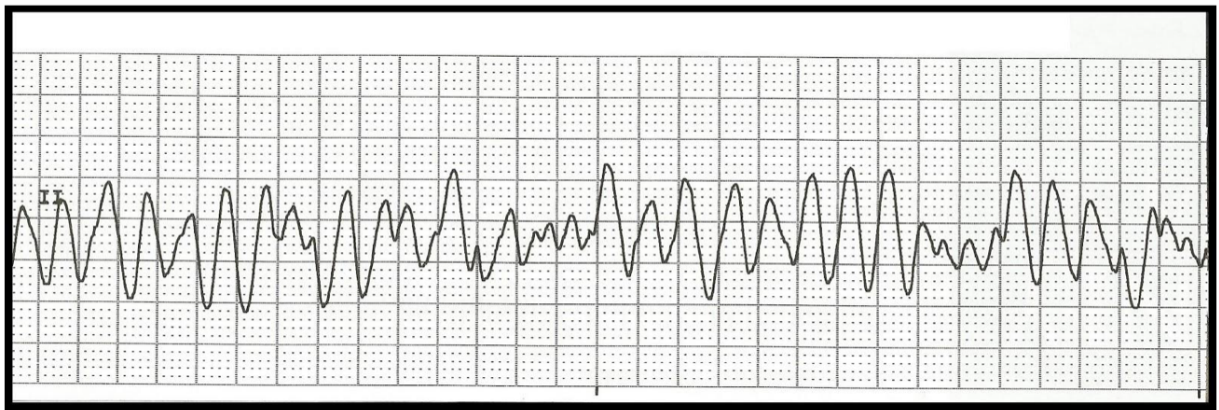
- Important findings:

flutter waves “Saw tooth appearance”

- Diagnosis:

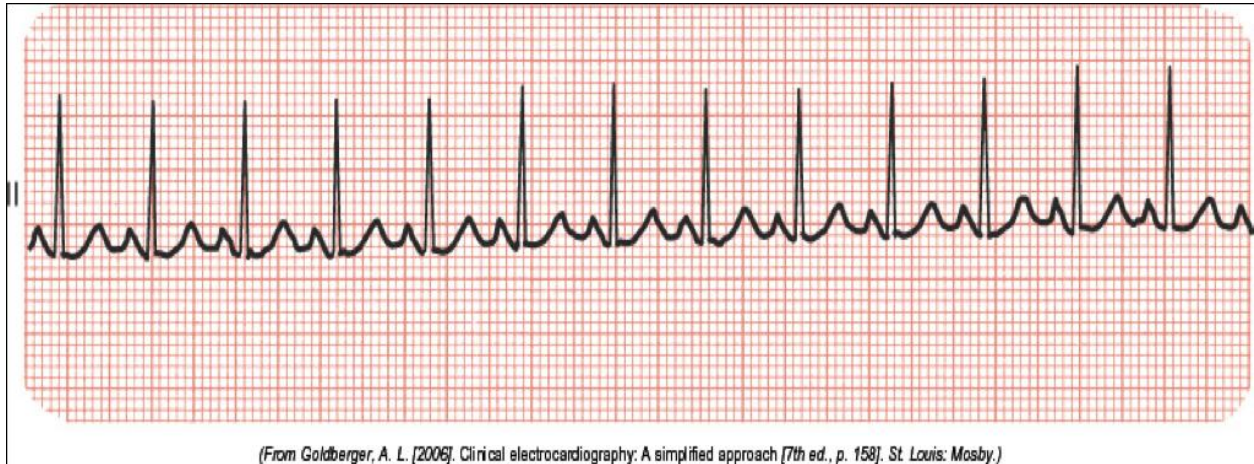
Atrial Flutter

flutter waves “Saw tooth appearance”



Ventricular Fibrillation.

## ECG



- Important findings:

- regular rhythm
- Sinus rhythm (present P-wave)
- Tachycardia
- Normal QRS complex

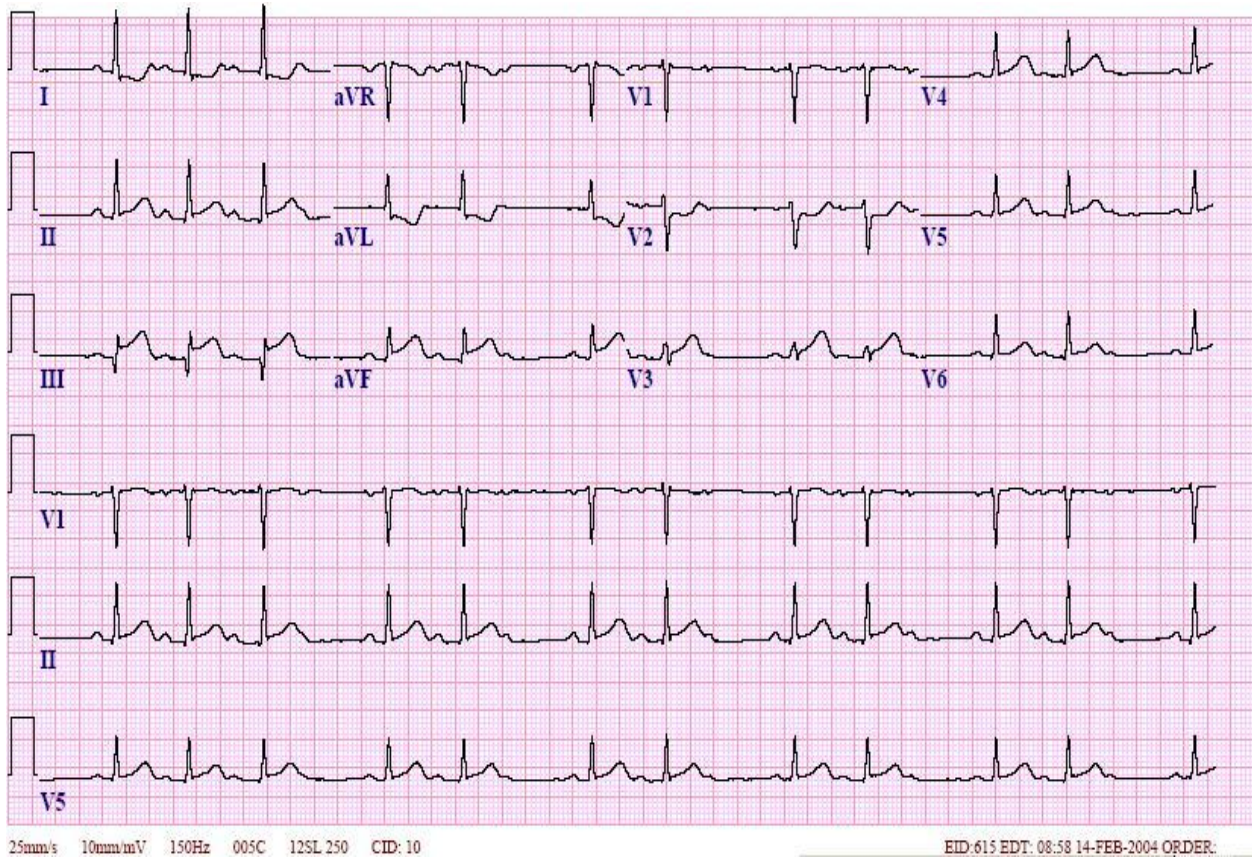
- Diagnosis:

- Sinus tachycardia

\*if there is no P wave in this ECG the diagnosis will be SVT



55 Years old with heavy retrosternal chest pain for 3 hours



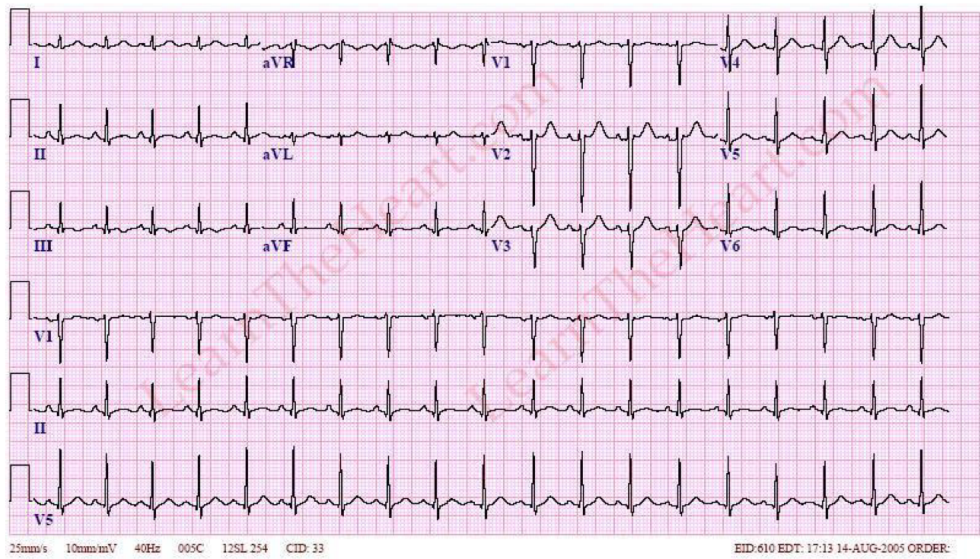
### Findings:

- 1) progressive prolongation of PR interval with a drop of QRS complex.
- 2) Inferior ST segment elevation MI (leads II, III, and aVF) with reciprocal ST depression (leads I and aVL)

### Diagnosis:

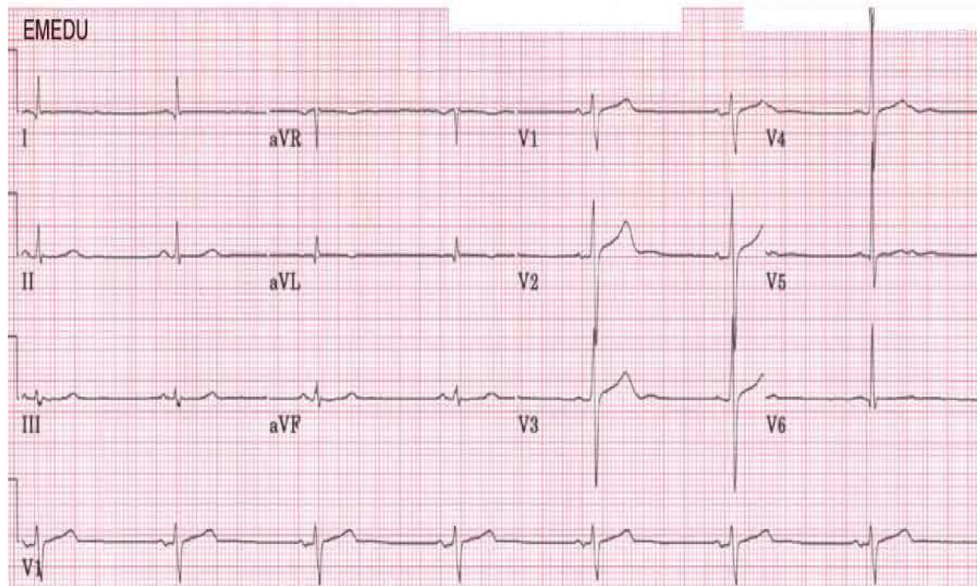
Acute inferior STEMI with 2<sup>nd</sup> degree type 1 heart block.

61 years old with Hx of SOB for 2 days



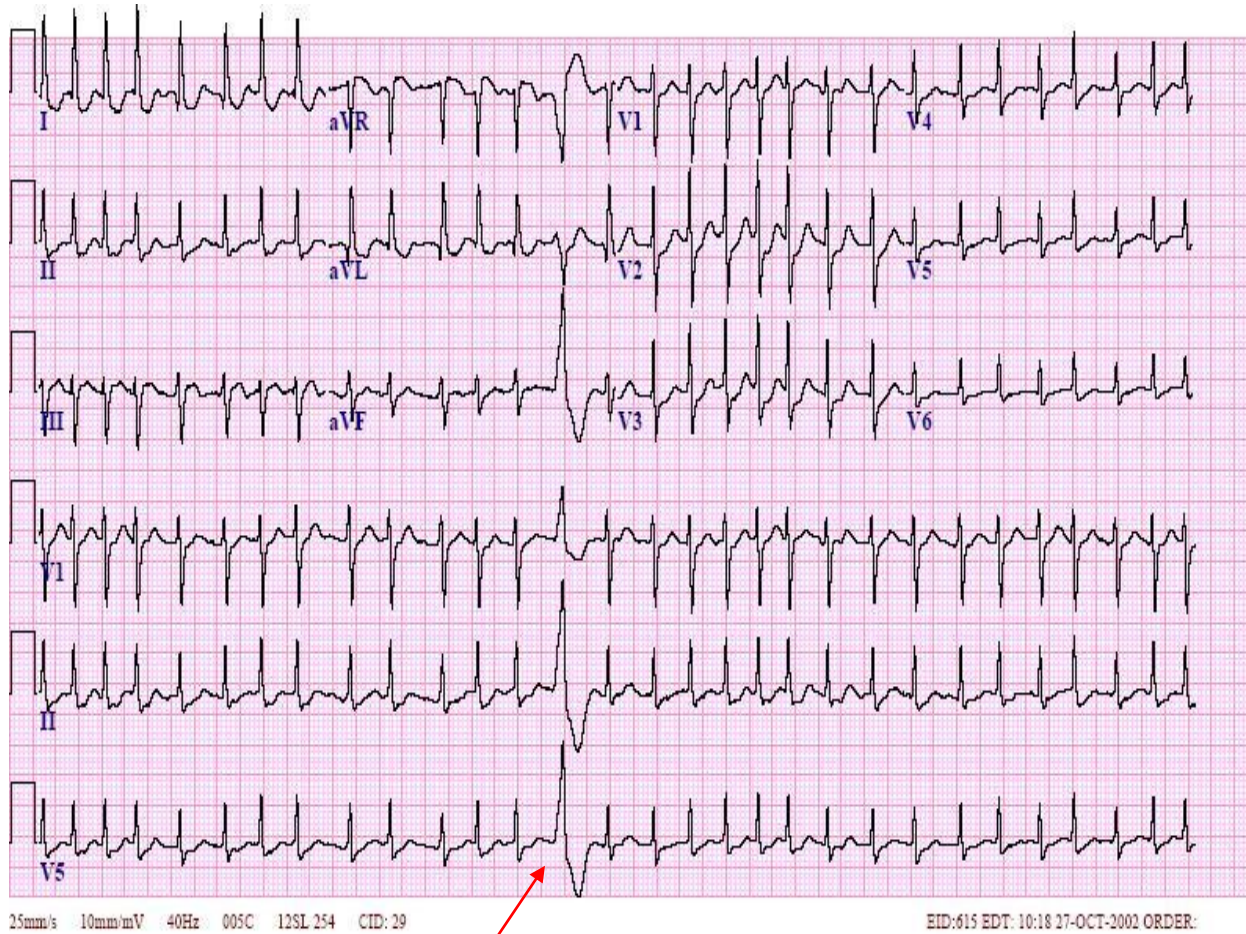
Sinus Tachycardia

64 years old with Hx of Dizziness for 6 Hours



Sinus bradycardia

48 years old with Hx of palpitation and SOB for 3 hours



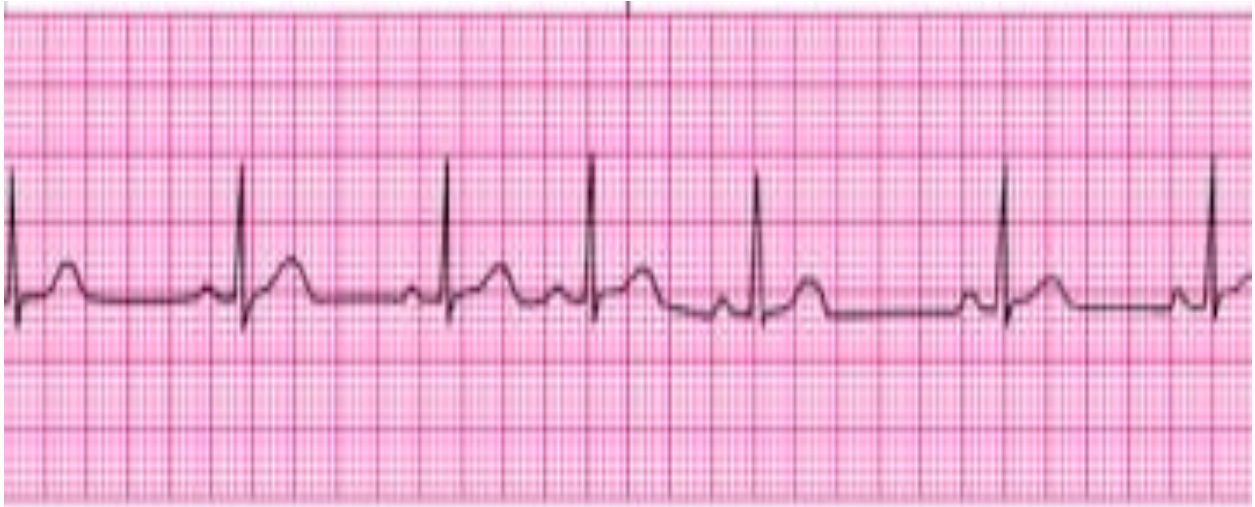● Important findings:

- Irregular rhythm
- Absent P-wave
- there is PVC

● Diagnosis:

- Atrial Fibrillation
- PVC

## 22 years old pre-op ECG



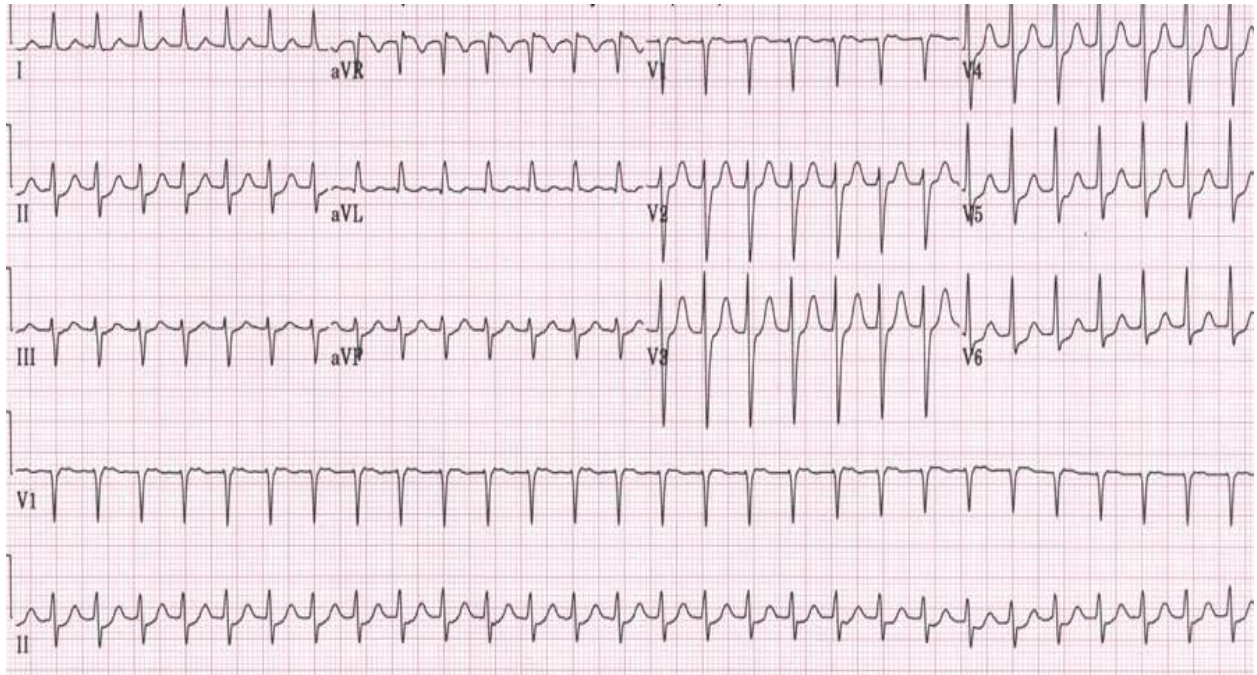
### Important findings:

- Irregular rhythm.
- Present P-wave before each QRS complex and there is QRS complex after every P-wave.
- normal PR interval.

### Diagnosis:

- Sinus arrhythmia.

## 32 years old male with Hx of SOB + Palpitation for 1 hour



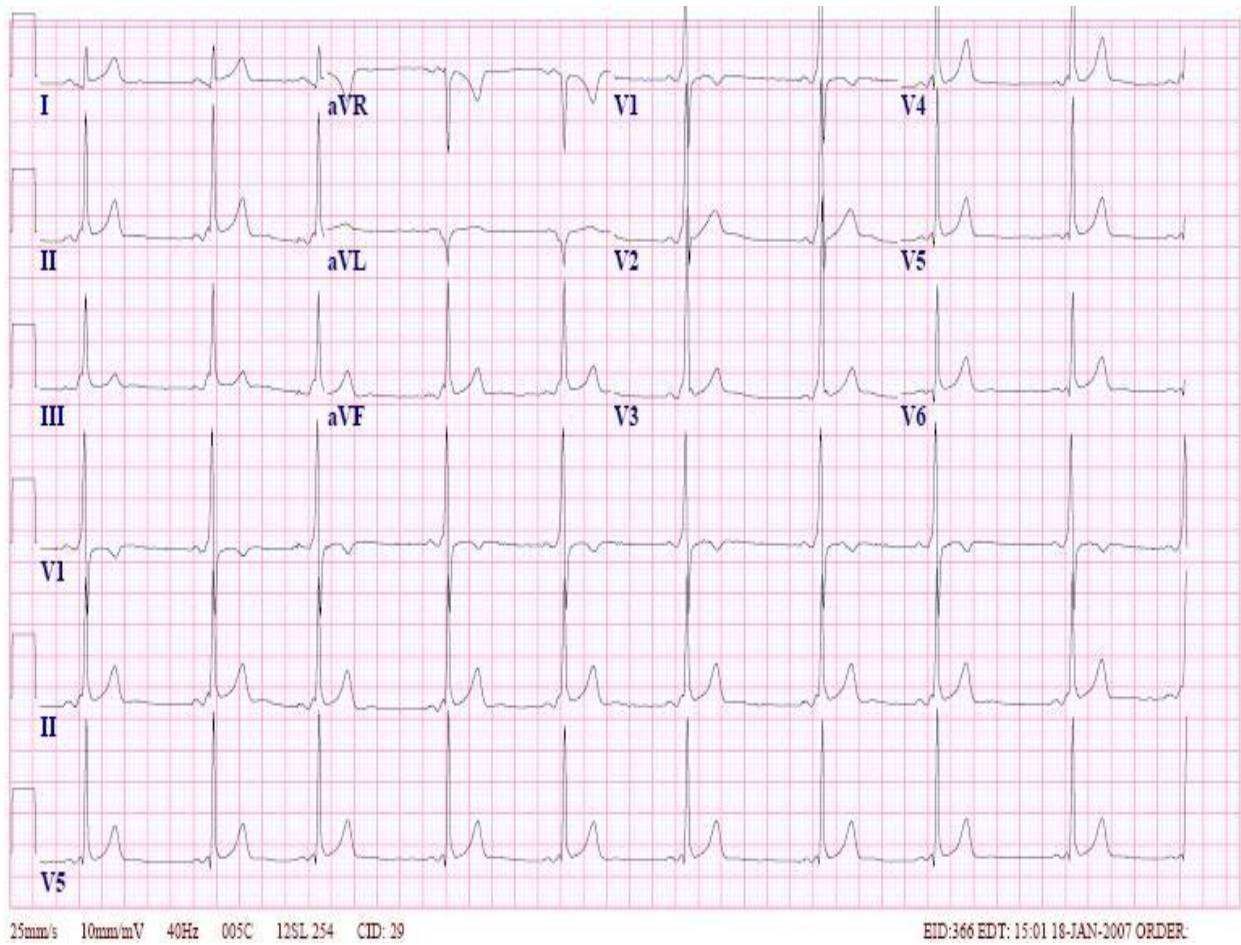
### Important findings:

- Regular tachycardia
- Absent P wave
- Normal QRS complex

### Diagnosis:

- SVT

47 years old with Hx of palpitation and dizziness



- Short PR interval and delta waves consistent with Wolff-Parkinson-White (WPW) syndrome

Good Luck☺